

We are IntechOpen, the world's leading publisher of Open Access books Built by scientists, for scientists

4,800

Open access books available

122,000

International authors and editors

135M

Downloads

Our authors are among the

154

Countries delivered to

TOP 1%

most cited scientists

12.2%

Contributors from top 500 universities

**WEB OF SCIENCE™**Selection of our books indexed in the Book Citation Index
in Web of Science™ Core Collection (BKCI)

Interested in publishing with us?
Contact book.department@intechopen.com

Numbers displayed above are based on latest data collected.

For more information visit www.intechopen.com

Retinoblastoma: Presentation, Evaluation, and Diagnosis

Spencer T. Langevin and Brian P. Marr

Abstract

Retinoblastoma was initially described in a case series by Dr. James Wardrop in 1809. Since then, the evaluation and diagnosis of retinoblastoma has progressed significantly, thus providing a framework for successful therapy with up to 97% survival rate in developed nations. Here we outline the presentation, evaluation, and detailed diagnostic steps of any child presenting with signs and symptoms of retinoblastoma (RB). We detail the questions and pertinent history to obtain, describe in detail the examination under anesthesia, ancillary testing, and recommendations for both anesthesia and neuroimaging. We also cover the differential diagnosis of retinoblastoma and the most common simulating lesions to present to an ophthalmologist. We describe the ways to determine if a patient has retinoblastoma or some simulating lesion, and the characteristics associated with each possibility. Finally, we briefly address genetic counseling and the next steps after diagnosis.

Keywords: retinoblastoma, intraocular tumors, oncology, children, b-scan ultrasonography, leukocoria, evaluation, diagnosis

1. Introduction

Pawius of Amsterdam is the first physician credited with recognizing retinoblastoma in the autopsy of a young child in 1597 [1]. In 1809, a Scottish surgeon from Edinburgh, James Wardrop, published a monograph entitled “*Observations on the fungus haematodes, or soft cancer, in several of the most important organs of the human body*”. His monograph included clinical histories of 15 children diagnosed with an intraocular tumor at the age of 1–6 years [2]. Dr. Wardrop described the tumors as “white in colour and brain-like in substance”, and he concluded as well that they were of retinal origin. He even went so far as to recommend enucleation to save the life of the children, in which his peers did not agree with him at the time. The first case in American literature was by Dr. Steven at New York Hospital in 1818 [3]. At the time, retinoblastoma was known as *fungus haematodes* which was initially described by Dr. Hey of Leeds, England [4]. Virchow in 1845 renamed the entity *glioma of the retina* [5]. Hirschberg further described the glioma into *exophytum* and *endophytum* [6]. Flexner described the histologic findings of cellular rosettes in the tumor in 1891 [7]. In 1897, Wintersteiner described the lumen of the rosette [8]. Finally Verhoeff named the tumor *retinoblastoma* which was adopted by the American Ophthalmological Society in 1926, thus arriving at the terminology we use to this day [9].

2. Presentation, evaluation, and diagnosis

2.1 Clinical presentation

The initial signs and symptoms of retinoblastoma (RB) are usually noticed by friends or family members, or at times from an abnormal “red reflex”, more specifically, a white reflex or (leukocoria) from a photograph. Medical professionals, such as pediatricians during a routine examination, or a pediatric ophthalmologist, may also notice signs and symptoms consistent with RB, however less often. In very rare circumstances the intraocular mass may be picked up on head imaging for non-ophthalmic reasons. In developed nations such as the United States, the most common presenting finding for intraocular retinoblastoma is leukocoria or “cats eye reflex” (43%), followed by strabismus (22%), pseudo cellulitis, (9%), microphthalmia (5%), routine screening examination (17%), and rarely the presence of an intraocular mass on non-ophthalmic imaging (<1%) [10].

On average the ophthalmic oncologist is the third medical professional to evaluate a child suspicious for having RB. According to a large study on referral patterns there is an average delay of 1.1 months between initial symptoms and evaluation with any medical professional, and 2.0 months before an appointment with an ophthalmic oncologist [10]. As of 2014, mortality from retinoblastoma in the United States is approximately 3%, however in developing countries is close to 60%. Although our treatment has improved greatly, in many parts of the world access to care is a large barrier to successful therapy. Mean age at diagnosis in Asia is 22 months, compared to North America and Europe which are 12 and 9 months, respectively. On a more significant note, there are approximately 3000 new cases of retinoblastoma in Asia compared to only 300 new cases in North America, even further highlighting the need for improved access to care. As there are relatively few specialists and centers who treat such a rare condition, it is important to use the internet, telemedicine, and other social services to help train ancillary staff and improve access to triage services to improve prognosis for children.

2.2 Misdiagnosis and differential diagnosis

A review of the literature demonstrates a historic misdiagnosis rate of 11–40% based on histopathologic analysis of enucleated specimens, and a clinical misdiagnosis rate from 16 to 53% [10]. Fortunately the accuracy in diagnosis at specialized ophthalmic oncology centers in the United States is believed to exceed 99%. In a recent review of referring physician patterns the most common simulating lesions (>5% of analyzed lesions) were: Persistent fetal vasculature, Coat’s Disease, Astrocytic Hamartoma, Intraretinal hemorrhage, and retinal detachment. Retinopathy of prematurity and congenital cataract were previously misdiagnosed often, but increased awareness of these conditions and better examination practices are likely the cause of reduced misdiagnosis of these two entities. Misdiagnosis of RB may be due to the fact that the condition is exceedingly rare, large differential diagnosis, and the challenges of examining children. Thus, any suspicion for the condition should warrant prompt referral to specialized care [11].

2.3 Evaluation and diagnosis of retinoblastoma

We will describe an organized approach in a stepwise manner for evaluating and properly diagnosis of RB. This will consist of: detailed history, initial office examination, ultrasonographic testing, examination under anesthesia, and current

consensus on imaging and genetic testing. Modifications dependent on specific patient encounters should be left to the treating physician.

2.3.1 History

For any child with suspicion of retinoblastoma, a very detailed history is the most useful step in establishing an appropriate differential diagnosis and accurate examination, and in cases may establish the diagnosis. History should be taken prior to examination to ensure an appropriate focused examination. It should include details of the pregnancy, labor, and delivery of the child. History of birth weight, birth trauma, maternal infection, history of prematurity, oxygen therapy, and whether leukocoria was present at birth or developed later. Also, history of hearing abnormalities at birth or during young childhood should be taken into consideration as well. History of animal/pet exposure should also be elicited. These questions should help direct the clinician to the diagnosis of cataract, retinopathy of prematurity, persistent fetal vasculature, toxocariasis, and congenital rubella, which all can mimic retinoblastoma. The time course of when parents or clinicians first noticed an abnormality and the course of their visits with other health care providers should be carefully elicited. Most children with retinoblastoma do not have an obvious ocular abnormality at birth. They tend to develop signs such as esotropia, visual disturbances, or other strabismus between 6 months and 2 years of age. Leukocoria is also unlikely to be present at birth and will occur around the same time frame as the strabismus. For children suspected to have retinoblastoma a detailed family history including number and health of their siblings should be noted, along with any history of family medical conditions. A history of poor vision, blindness, or loss of an eye should be requested. A positive history of retinoblastoma in parents should point to the diagnosis, as simulating lesions do not usually occur in patients with a positive family history. If the child's parents or siblings have not had recent dilated fundus examinations they should be performed as soon as possible [12]. About 1% of patients with history of retinoblastoma may develop spontaneous regression with retinoma/retinocytoma present on dilated examination [13]. Some parents may be unaware that they were treated for retinoblastoma as children and examination may be able to elicit this finding.

2.3.2 Office examination

The initial examination of the child should occur while history taking, by watching the child's behavior, visual interaction with the world, and evaluating for any abnormalities in size of the child, proportions, or for any facial abnormalities. The external examination of a child with retinoblastoma should be otherwise normal except for the ocular exam unless the child has a 13q deletion syndrome. Before the formal examination, the ability to notice leukocoria, decreased visual function, strabismus, or periorbital swelling should be noted upon gross examination. Assessment of vision is obviously dependent on age of patient, and his or her individual cooperation, but the size and symmetry of each eye should be recorded, as asymmetric size can suggest other diagnoses as well as retinoblastoma. Presence or absence of heterochromia should be noted during this portion of the examination as well [12]. Pupil response should also be documented. Using a direct ophthalmoscope or retinoscope, the pupillary light reflex should be noted in both eyes and leukocoria can be noted at that time.

The next step should be instillation of dilating eyedrops (0.5% tropicamide and 2.5% phenylephrine). Cyclopentolate is not necessary for this examination. If the

child is large enough or a portable slit lamp is available, slit lamp examination should be performed, care to note, presence or absence of cataract, conjunctival or scleral injection, anterior segment shallowing, neovascularization of the iris, iris seeding or iris atrophy. Evaluate for retrolental membranes to assess presence of retinopathy of prematurity or persistent fetal vasculature. Most patients with retinoblastoma have normal anterior segments but may have anterior cells or nodules on the iris. In exophytic tumors, visualization of retinal vasculature behind the lens may be possible as well. Indirect ophthalmoscopy should be performed to evaluate the posterior pole and fundus. Depending on the age of the child, they may cooperate or family members may be needed to help secure the patient in a supine position. Very young children may be swaddled with a blanket to secure their limbs. The indirect exam in the office should be used to rule out simulating lesions when possible and to also increase or decrease suspicion for retinoblastoma, thus determining whether examination under anesthesia (EUA) is needed for full evaluation and diagnosis. An eyelid speculum may be needed for proper dilated examination, and a topical anesthetic such as 0.5 or 1% proparacaine should be instilled prior to speculum insertion. Scleral depression may be indicated, if it can be reserved for examination under anesthesia it is less traumatic but can be done in the office setting.

2.3.3 Ophthalmic ultrasound

An ophthalmic ultrasound can be performed in the A and B scan mode using a 10 mHz transducer to evaluate for intraocular masses, retinal detachment, or calcification. In retinoblastoma, the ultrasound should reveal an irregular mass, which is more echogenic than the vitreous, and commonly has fine calcifications (highly reflective foci mostly with acoustic shadowing) since upon histologic study, 95% of retinoblastoma contains calcification [14] (**Figure 1**). Measurements should be taken as a baseline to compare to in the future following treatment.

2.4 Exam under anesthesia (EUA) considerations

If EUA is warranted, general anesthesia will be needed to conduct detailed examination and ancillary testing at one time. Preparation of the room for EUA should consist of examination materials including: external photography, portable slit lamp, tonometry, indirect ophthalmoscope with condensing lens and scleral

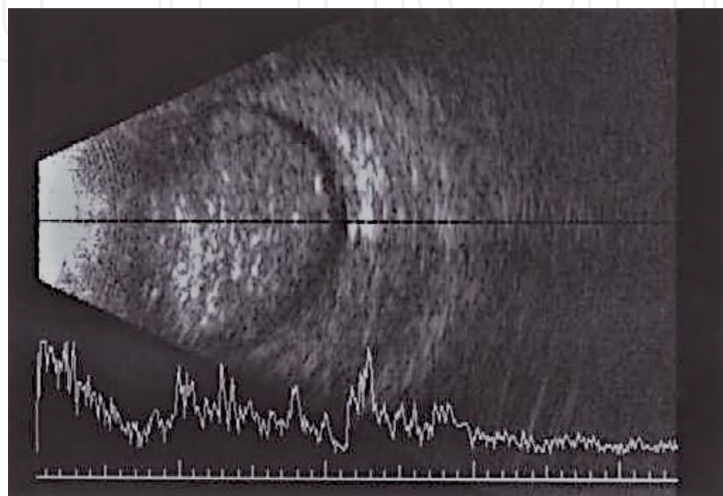


Figure 1. 10 mHz ultrasound in A and B scan mode showing a large intraocular retinoblastoma with irregular mass and intrinsic calcification with acoustic shadowing.

depressor, wide-angle hand-held fundus camera, intravenous fluorescein dye, high resolution ophthalmic ultrasound, ultrasound biomicroscopy, electroretinography. When retinoblastoma is confirmed, an MRI of the brain and orbits with and without contrast should be ordered at the time of the EUA to assess for extrascleral extension, orbital anatomy, posterior portion of the optic nerve, and presence of pinealoblastoma in trilateral disease.

2.5 Anesthesia

The type of general anesthetic and airway support varies depending on institution and available resources. Safe anesthesia methods range from mask anesthesia, to laryngeal mask airway (LMA), to complete endotracheal intubation. Both inhaled anesthetics and intravenous anesthetics, or a combination of the two, are suitable for examination. General guidelines recommend that heavy fatty meals be discontinued 8 h prior to procedure, light meals, formula, and nonhuman milk 6 h prior to surgery, human milk 4 h prior to anesthesia, and clear liquids 2 h prior to anesthesia [15]. These recommendations will vary by location and anesthesiologist, and type of anesthesia administered. Recently there has been literature support for use of LMA without placement of intravenous lines, which reduces total time under anesthesia without increased anesthesia complications, all of which were managed successfully without long term sequelae [16].

2.6 Examination under anesthesia

2.6.1 External examination

An orderly approach to the exam should be taken to efficiently access and treat the patient to avoid prolonged anesthesia exposure. The overall features of the child should be assessed, evaluating for any abnormalities that are consistent with retinoblastoma and a 13Q deletion syndrome which is strongly associated with retinoblastoma risk (**Figure 2**). Patient's with 13Q deletion syndrome may have hypotelorism, micrognathia, hypoplasia of midface, absent nasal bones, large ears, hypoplastic thumbs, cleft palate, or microcephaly [17].

2.6.2 Anterior examination

Intraocular pressures should be measured using Schiottz tonometer, tonopen, Perkins tonometer, or pneumotonometer. Elevated intraocular pressure in patients with retinoblastoma can be secondary to iris neovascularization or angle closure, and has been associated with increased risk of optic nerve invasion and metastatic disease [18].

After intraocular pressure is checked, corneal diameter should be measured with a caliper both in horizontal and vertical directions. Conditions such as persistent fetal vasculature (PFV) is associated with asymmetric corneal diameter size as well as eyes with congenitally elevated intraocular pressures can be associated with buphthalmos and increased corneal diameter.

A portable slit lamp should be used to assess the anterior segment. The clinician should evaluate anterior depth, clarity of the lens, neovascularization of the iris or atrophy, retrolental membrane, anterior chamber cells, nodules of the iris, or anterior vitreous seeds seen behind the lens. Presence of a pseudohypopyon should raise suspicion for endophytic tumor and anterior chamber seeding of cancer. It may be possible to visualize retinal vascular, retrolental masses, or retrolental membranes. Retrolental retinal tissue should reveal blood vessel branching patterns

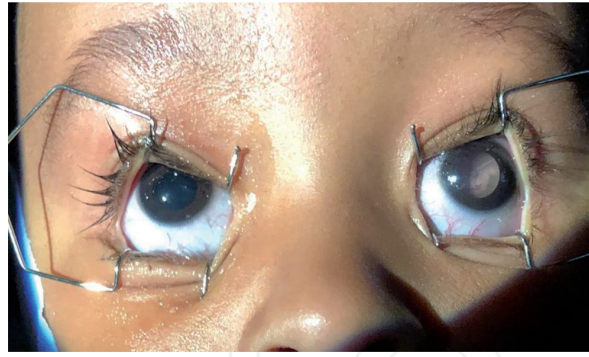


Figure 2.
External photograph of young child with leukocoria of the left eye secondary to intraocular retinoblastoma.

extending towards the periphery of the lens which could be secondary to exophytic tumor, whereas the persistent tunica vasculosa lentis in PFV, vessels should be noted to be growing towards the center of the posterior lens in a disorganized fashion. Retrolental membrane without vascular pattern is suggestive of retinopathy of prematurity rather than RB.

Binocular indirect ophthalmoscopy should then be performed in a step by step fashion. Initially the vitreous should be examined in both eyes for presence of seeding, vitreous hemorrhage, fibrous membranes, or inflammatory debris. If the posterior pole is visible, optic disc and macula should be examined and abnormal findings documented. Examination of the periphery should be performed with scleral depression of the ora serrata in a clockwise or counter-clockwise fashion, with examination of the midperipheral retina and posterior pole for 360 degrees in both eyes.

Small RB lesions can be difficult to detect as there can be poor contrast between the small translucent tumor and the surrounding fundus. Meticulous examination and depression is needed to observe these tumors stereoscopically. Medium sized tumors become more opaque and start appearing white. Large tumors (>4–5 mm) in diameter will begin to have visually obvious blood supply and visually significant feeder vessels should be noted. Many very large lesions (>6 mm) will develop chalky-white calcifications within the body of the tumor. The size and number of all tumors should be noted, with evaluation of subretinal fluid, retinal detachment, and presence of seeding (subretinal or vitreous) (**Figure 3**), and should all be incorporated into a detailed retinal drawing along with fundus photography [12]. Drawing and photography can help the clinician classify the tumor according to existing classification schemes at a later time.

2.6.3 Ancillary testing

2.6.3.1 Photography

It is important to obtain photographs of both the anterior segment as well as the vitreous cavity and posterior segment for documentation. The most useful method is using a wide-angle fundus camera. Photographs should be obtained during every EUA to help document response to therapy (**Figures 4, 5A, B, and 6A, B**). The clinician should try to standardize the photographs, so comparisons to each exam can be readily performed. As an example, start with a posterior pole photograph centered on the fovea then sequentially take peripheral photos superiorly, inferiorly, temporally and nasally keeping the optic nerve visible at the respective edge of the photograph to use as a point of reference for peripheral lesions. Then any other areas of special interest can be photographed separately.

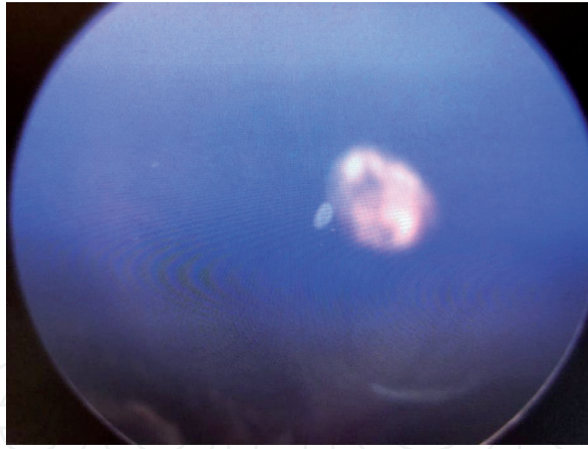


Figure 3.
RetCam photograph of the left eye with defocusing to document free-floating vitreous seeding.

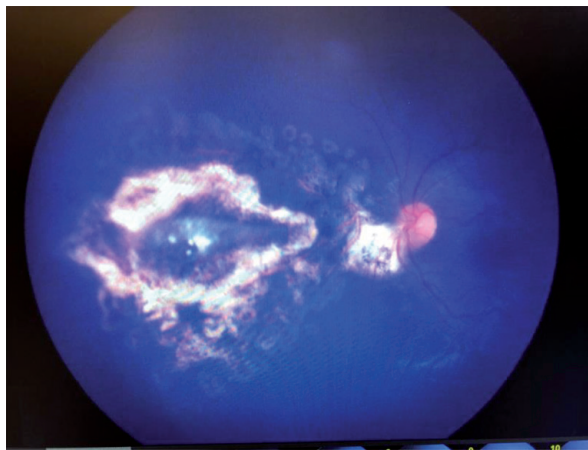


Figure 4.
A retinoblastoma of the left eye with tumor scar showing type 3 regression.

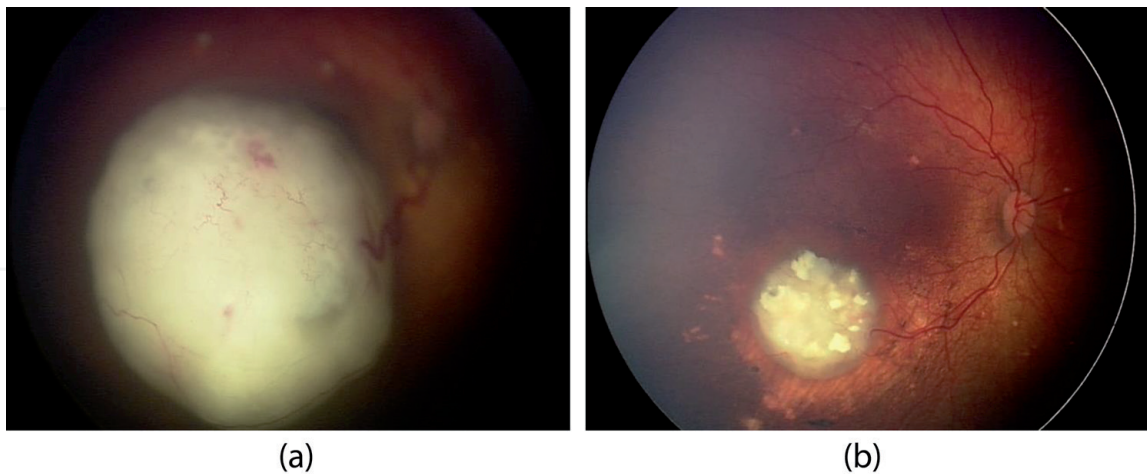


Figure 5.
(A) RetCam photograph of class C retinoblastoma of the right eye prior to intra-arterial chemotherapy and (B) RetCam photograph of the right eye showing class C retinoblastoma after treatment with intra-arterial chemotherapy.

2.6.3.2 Fluorescein angiography

Thanks to advances in photography as described in the above section, fluorescein angiography (FA) can be readily performed during an EUA and can help one

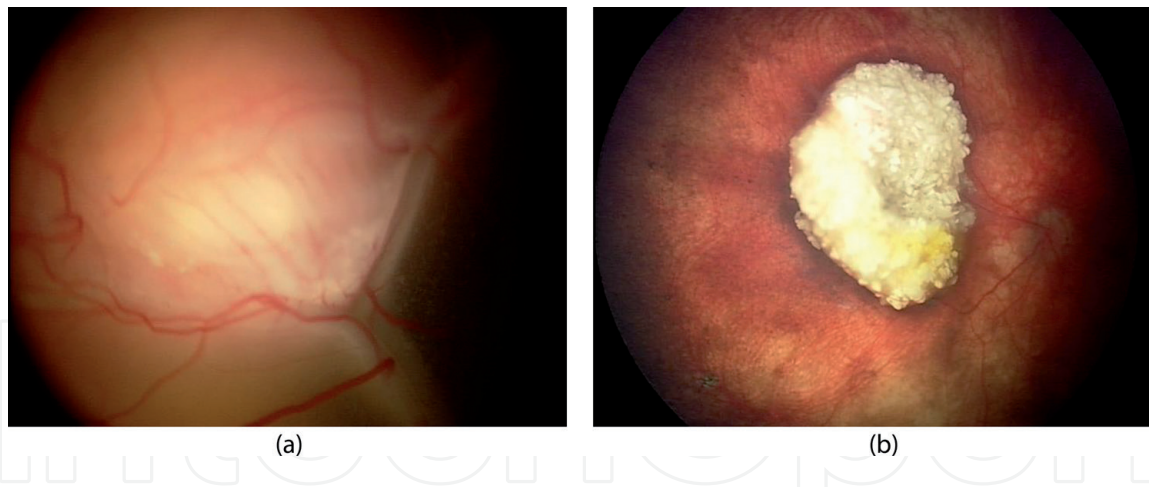


Figure 6.
(A) RetCam photograph of the left eye showing class D retinoblastoma prior to intra-arterial chemotherapy and (B) RetCam photograph of the left eye showing class D retinoblastoma after intra-arterial chemotherapy.

differentiate RB from simulating lesions. Firstly, subclinical neovascularization of the iris (NVI) can be distinguished using Retcam FA. In a recent study, eyes with advanced retinoblastoma, NVI was documented appearing as placoid or patchy areas of hyper fluorescence involving one or more sectors of the iris [19]. This finding typically occurred between 1 and 2 min. Retinoblastoma in the fundus should show dilated and tortuous vessels, with retinal arteries which “feed” the tumor of the largest caliber. Also, microaneurysms, retinal hemorrhages, and arteriovenous shunts can also be noted. In the same study, as the tumors enlarged, the abnormal vascularization was no longer consistent with normal retinal anatomy, and were contained entirely within the tumor itself. Intrinsic vessels of the tumor had disorganized and complex branching patterns, irregular caliber, and terminated early within the body of the tumor. This multi-level involvement of vascular abnormality helps the clinician readily distinguish RB from Coat’s disease which has large dilated vessels which remain within one level of the retina and show extensive peripheral non-perfusion (**Figure 7A and B**). Lastly, after 3 min diffuse leakage from retinal vessels can lead to inability to discern fine details of the fundus, so the clinician should try to obtain all valuable information within the first 3 min of the study.

2.6.3.3 Ophthalmic ultrasonography

During the EUA, ultrasound imaging of both eyes can be used to assess the orbit for extraocular extension, to measure thickness of the lesions, and to obtain axial lengths of the eyes to evaluate for normal size and symmetry. Ophthalmic ultrasound has traditionally been used for diagnosing and monitoring treatment of retinoblastoma and distinguishing it from simulating lesions [20, 21]. As described previously in the chapter, a 10 MHz transducer in the A and B scan mode should be used to image the posterior pole and evaluate the size and location of tumors, evaluate for retinal detachment, and look for extraocular extension of tumor (**Figure 8**). Ultrasound is especially useful in cases when ophthalmoscopy is limited by a poor view or in presence of a cataract. As described previously in this chapter, large retinoblastoma lesions undergo dystrophic calcification from necrosis, and these can be readily observed as areas of hyper-reflection with acoustic shadowing.

2.6.3.4 Ultrasound biomicroscopy

Ultrasound biomicroscopy (UBM) can also be helpful for visualizing the iris, pars plana, pars plicata, and ciliary body during an EUA. It is extremely helpful to

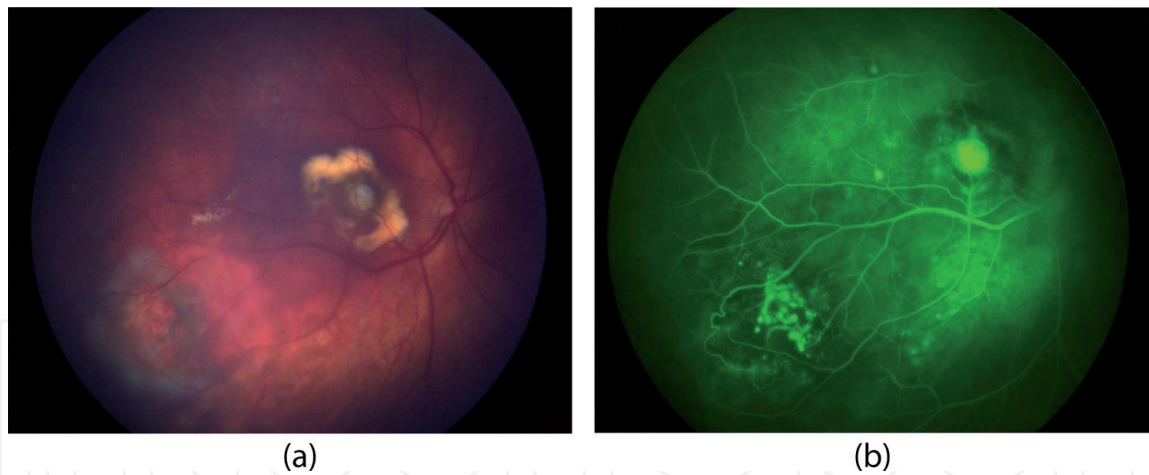


Figure 7.
(A) A portable wide field photograph showing a simulating lesion of retinoblastoma in the right eye showing a white macular lesion, close attention to the far periphery shows vascular telangiectasia and non-perfusion and (B) accompanying fluorescein angiogram confirming diagnosis of Coat's disease in 8 year old boy, again notice vascular telangiectasias and non-perfusion within a single plane of the retina.

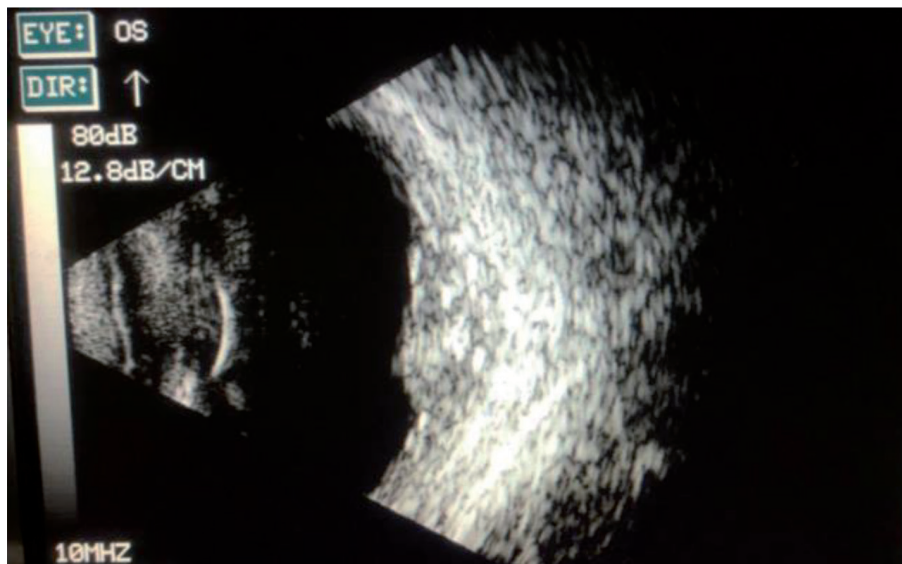

Figure 8.
10 mHz B-scan ultrasonography of the left eye showing treated intraocular retinoblastoma with intrinsic calcifications and acoustic shadowing.

assess the anterior extent of tumor burden or to obtain more information regarding the pars panna and ciliary body as well as anterior chamber seeding. It is especially important to use UBM to rule out pars plana tumor involvement in cases where intravitreal injections of chemotherapy are being considered to choose a proper injection site.

2.6.3.5 Electroretinogram

Electroretinograms (ERG) has been used to monitor retinal function before, during, and after therapy with intra-arterial chemotherapy. It is especially helpful in preverbal children who are unable to describe their level of visual function during the treatment course. Also it provides information regarding the cumulative effects of retinal damage secondary to therapy, chemotherapy toxicity, and tissue destruction from treatments including radiation, laser photocoagulation, and cryotherapy. During the EUA, a 30-Hz flicker has been tested and shown to be

informative prior to the physical examination portion of the exam [22]. One must be cautious to not manipulate the eyes before obtaining the ERG, as ocular manipulation including scleral depression, photography, and ophthalmoscopy can affect the ERG readings thus confounding results [23].

2.6.3.6 Imaging for retinoblastoma

Historically computerized tomography (CT) scans were used to evaluate patients ocular, orbital, optic nerve, and brain involvement from the tumor, since CT detection of calcifications in retinoblastoma have a sensitivity of 81–96% and an even higher specificity [24]. Magnetic resonance imaging (MRI) however is currently considered to be of higher accuracy and value due to its superior soft-tissue contrast for determining extent of tumor into orbit, optic nerve, and for evaluation of the presence of pinealoblastoma in trilateral disease. CT scanning is also felt to unnecessarily increase patient exposure to ionizing radiation with limited diagnostic value now that MRI is available. MRI of the brain and orbits with and without contrast is now ordered routinely on all patients with retinoblastoma at the time of diagnosis. The general practice among groups in the United States is to repeat imaging every 6–12 months for germline cases until the age of 5–6 years old to screen to pineal tumors. Transaxial or sagittal T1-weighted images will reveal an RB tumor which is slightly hyperintense with respect to the vitreous body. Transaxial or sagittal heavily T2-weighted imaging provides a low signal intensity of retinoblastoma and is helpful for detecting retinal detachment. Transaxial and sagittal oblique contrast enhanced T11 weighted spin echo provides information of the enhancement of retinal, invasive optic nerve, invasive eye wall, and anterior segment lesions.

2.6.3.7 Genetic counseling

After all of the steps outlined in this chapter are followed, and a diagnosis of retinoblastoma is made, the clinician can hold a discussion with the family regarding therapeutic options and the genetic counseling needed for the patient and their loved ones. A treatment plan can be devised and initiated, but is outside the scope of this chapter, and will be covered in other portions of this text.

3. Conclusion

Accurate and consistent diagnosis of retinoblastoma, and its simulating lesions begin with the initial consult. This involves a systematic approach starting with a detailed history and high level of suspicion for patients presenting with leukocoria, decreased vision, strabismus, periorbital swelling, or dysmorphic facial features. Initial examination should involve a detailed dilated fundus exam with ophthalmic ultrasound, which will either push the clinician towards or away from the diagnosis of retinoblastoma. Any suspicion should warrant an examination under anesthesia as outlined above to obtain all of the information needed for an accurate diagnosis. The examination under anesthesia should follow a consistent, careful, and repeatable fashion as described earlier in the chapter. The techniques above, if followed, should aid the clinician in consistent diagnosis of retinoblastoma and its simulating lesions. Once diagnosed, appropriate brain and body imaging, and referral for genetic counseling should be performed. Treatment of this rare condition, along with survival and preservation of the eye is continuing to improve and will be covered in other portions of this text.

Acknowledgements

The authors would like to thank David McMahon for his assistance in obtaining many of the photographs used in this chapter.

Conflict of interest

The authors have no conflicts of interests to declare in the production of this book chapter.

Author details

Spencer T. Langevin and Brian P. Marr*
Harkness Eye Institute Columbia University, New York, NY, USA

*Address all correspondence to: bpm2133@cumc.columbia.edu

IntechOpen

© 2019 The Author(s). Licensee IntechOpen. This chapter is distributed under the terms of the Creative Commons Attribution License (<http://creativecommons.org/licenses/by/3.0>), which permits unrestricted use, distribution, and reproduction in any medium, provided the original work is properly cited. 

References

- [1] Pawius P. Observationed anatomical. Cited by Bartolini. Bartolini Hafniae. 1657;16:336
- [2] Kivela T. 200 year of success initiated by James Wardrop's 1809 monograph on retinoblastoma. *Acta Ophthalmologica*. 2009;87:810-812
- [3] Stevens A. Case Report. Medical & Surgical, Register. New York: Collins & Co; 1818:117
- [4] Wardrop J. Observations on Fungus Haematodes or Soft Cancer. Edinburgh: George Ramsey & Co; 1809. p. 213
- [5] Virchow R. Die Krankehaften Geschwulste. Vol. 2. Berlin: August Hirshwald; 1864. pp. 151-169
- [6] Hirschberg J. Die Markschwann Die Natzhaut. Berlin: Hirschwald; 1869:3
- [7] Flexner S. A peculiar glioma (neuroepithelioma?) of the retina. *Bulletin of the Johns Hopkins Hospital*. 1891;2:115-119
- [8] Wintersteiner H. Das Neuroepithelioma Retinae: Eine Anatomisfche Und Klinsche Studie. Vienna: Franz Deuticke; 1897:12-16
- [9] Verhoeff FH, Jackson E. Minutes of the proceedings, 62nd annual meeting. *Transactions of the American Ophthalmological Society*. 1926;24:38-43
- [10] Maki JL, Marr BP, Abramson DH. Diagnosis of retinoblastoma: How good are referring physicians? *Ophthalmic Genetics*. 2009;30(4):199-205
- [11] Grossniklaus HE. Retinoblastoma. Fifty years of progress: The LXXI Edward Jackson memorial lecture. *American Journal of Ophthalmology*. 2014;158(8):875-891
- [12] Shields JA, Augsburger JJ. Current approaches to the diagnosis and management of retinoblastoma. *Survey of Ophthalmology*. 2014;25(6):347-372
- [13] Gallie BL, Ellsworth RM, Abramson DH, Philips RA. Retinoma: Spontaneous regression of retinoblastoma or benign manifestation of the mutation? *British Journal of Cancer*. 1982;45:513-521
- [14] de Graaf P, Göricke S, Rodjan F, Galluzzi P, Maeder P, Castelijns JA, et al. Guidelines for imaging retinoblastoma: Imaging principles and MRI standardization. *Pediatric Radiology*. 2012;42:2-14
- [15] Basel A, Bajic D. Preoperative evaluation of the pediatric patient. *Anesthesiology Clinics*. 2018;36:689-700
- [16] Lin BA, Messieha ZS, Hoffman WE. Safety and efficacy of pediatric general anesthesia by laryngeal mask airway without intravenous access. *International Journal of Clinical Medicine*. 2011;2:328-331
- [17] Quelin C, Bendavid C, Dubourg C, de la Rochebrochard C, Lucas J, Henry C, et al. Twelve new patents with 13q deletion syndrome: Genotype-phenotype analyses in progress. *European Journal of Medical Genetics*. 2009;52:41-46
- [18] Shields CL, Shields JA, Baez K, Carter JR, De Potter P. Optic nerve invasion of retinoblastoma; metastatic potential and clinical risk factors. *Cancer*. 1994;73(3):692-698
- [19] Kim JW, Ngai LK, Sadda S, Murakami Y, Lee DK, Murphree AL. Retcam fluorescein angiography findings in eyes with advanced retinoblastoma. *The British Journal of Ophthalmology*. 2014;98:1666-1671

[20] Sterns GK, Coleman DJ, Ellsworth RM. Characterization and evaluation of retinoblastoma by ultrasonography. *Bibliotheca Ophthalmologica*. 1975;**83**:125-129

[21] Abramson DH, Ellsworth RM. Ancillary tests for the diagnosis of retinoblastoma. *Bulletin of the New York Academy of Medicine*. 1980;**56**:221-231

[22] Liu CY, Jonna G, Francis JH, Marr BP, Abramson DH, Brodie SE. Non-selectivity of ERG reductions in eyes treated for retinoblastoma. *Documenta Ophthalmologica*. 2014;**128**:12-23

[23] Francis JH, Abramson DH, Marr BP, Brodie SE. Ocular manipulation reduces both ipsilateral and contralateral electroretinograms. *Documenta Ophthalmologica*. 2013;**227**:113-122

[24] Kamihara J, Bourdeaut F, Foulkes WD, Molenaar JJ, Mosse YP, Nakagawara A, et al. Retinoblastoma and neuroblastoma predisposition and surveillance. *Clinical Cancer Research*. 2017;**23**(13):e98-e106

IntechOpen