

# We are IntechOpen, the world's leading publisher of Open Access books Built by scientists, for scientists

4,800

Open access books available

122,000

International authors and editors

135M

Downloads

Our authors are among the

154

Countries delivered to

TOP 1%

most cited scientists

12.2%

Contributors from top 500 universities



WEB OF SCIENCE™

Selection of our books indexed in the Book Citation Index  
in Web of Science™ Core Collection (BKCI)

Interested in publishing with us?  
Contact [book.department@intechopen.com](mailto:book.department@intechopen.com)

Numbers displayed above are based on latest data collected.

For more information visit [www.intechopen.com](http://www.intechopen.com)



# Fat Embolism: What We Have Learned from Animal Models

*Alan M. Poisner and Agostino Molteni*

## Abstract

Pulmonary fat embolism may not be diagnosed before unrelated autopsy and have little clinical impact or lead to acute lung injury with fulminant fat embolism syndrome (FES). The fat may come from various anatomic locations, bone marrow being the most common. There is no specific treatment. This review discusses animal models that can lead to a better understanding of pathophysiological mechanisms underlying this condition and indicates the importance of specific cellular constituents. A hypothesis is postulated that there is a vicious cycle involving oleic acid and angiotensin II (both of which are pulmonary toxicants): oleic acid is derived from lipid embolism by pulmonary lipases that are stimulated by angiotensin; oleic acid also promotes local generation of angiotensin. The potential role of fatty acid receptors and the resolution of this cycle are discussed. Studies show there is potential for long-term effects that might not be revealed in the immediate post-recovery period. Evidence is reviewed that animals are vulnerable to “second hit” effects at a time remote from the initial event. Some beneficial pharmacological treatments are described. These include different drugs acting on the renin-angiotensin system (RAS) that could eventually serve alone or in combination for treatment or prevention. Future therapeutic developments are discussed.

**Keywords:** fat embolism, lung, renin-angiotensin system, rat, drug treatment, time course, second hit, animal model, histopathology, triolein

## 1. Introduction

Fat embolism was described many years ago. As early as 1862 [1] as cited in a 1971 review by Herndon [2], there was a report of fat droplets in the lungs of a factory worker who died after a crushing injury to his chest and abdomen. The term “fat embolism” itself includes many types of conditions in which some type of fatty substance is embedded in a tissue remote from its source. The most common source is from bone marrow that escapes into the venous system after trauma and surgery, including bone marrow reaming [3], liposuction [4], fat injection [5], or necrosis, as in sickle cell disease resulting in acute chest syndrome [6]. There are also some forms that do not result from trauma or surgery [7]. What distinguishes fat embolism from other strictly physical forms is that in addition to the physical obstruction of the vasculature that can accompany the lodging in capillaries, there are also biochemical consequences in response to the ensuing lipid metabolism and also pathological processes that are triggered intracellularly after engulfing of the fat. The most common target for embolic fat is the lung, but other significant sites include the skin, the eyes, and the brain with subsequent clinical sequelae [8].

The clinical consequences of fat embolism have been reviewed many times over the years, including this year [8]. The symptoms may be so minor that they can be missed [9] or appear after an interval as much as 48–96 h leading to acute respiratory distress syndrome [ARDS] with mortality ranging from 10 to 15% [8, 9]. This has been called fat embolism syndrome [FES], sometimes with accompanying CNS [10], ocular [11] or dermal pathology [12]. Treatment has been supportive: recent reviews indicate that there is no specific treatment available [8, 12]. Although a patent foramen ovale is sometimes a contributing factor in systemic consequences of fat embolism, for instance, in the eye and the brain, this is clearly not the case in most cases of FES.

Therefore, there have been many attempts to produce an animal model in hopes of delineating the underlying pathophysiology, so specific treatment could be obtained. Animal models have included rats [13], mice [14], rabbits [15], dogs [16], sheep [17], pigs [18], and even baboons [19]. While a majority of these studies have focused on orthopedic-related problems [20], it would help to examine a wide variety of initiating causes in order to find some common underlying pathophysiological processes. This might lead to more specific methods to treat or prevent this condition before the array of downstream mediators, such as peptides and cytokines, have been activated. The aim of this chapter is to review what has been learned from the diverse animal studies and provide one unifying concept based on the role of the renin-angiotensin system as a key player in fat embolism syndrome.

## **2. Studies on bone**

### **2.1 Reaming and nailing**

In order to simulate in animals the surgical procedure used in humans that can lead to fat embolism syndrome, a number of different animals have been subjected to nailing, with or without reaming [3]. It was concluded that more experiments should be carried out in order to determine the optimal method to perform the surgical procedures. It was also made clear that other factors influence the development of systemic and pulmonary complications [3]. A comprehensive review of animal studies of intramedullary nailing concludes that events that may predispose to adverse postsurgical impact are important and that studies should take these into consideration [20].

### **2.2 Bone marrow fat and non-bone marrow fat injection**

A number of studies have been carried out with infusions of bone marrow extracts or non-marrow fat. An excellent review on animal studies of acute lung injury, which includes oleic acid as a possible model for fat embolism, indicates that this model does not really mimic the clinical syndrome of FES [21]. In addition, a study on rats showed that the intravenous injection of oleic acid, unlike neutral fat, did not result in the deposition of fat droplets [22].

A study on liposuction in rats performed on the lateral flank and the abdomen showed that fat was delivered to the lungs and other organs [23]. Some animal studies on fat embolism have utilized subcutaneous fat [22]. This has clinical parallels in which subcutaneous injection in humans has caused fatal fat embolism [24].

## **3. Triolein: the prototype fat embolism model**

Since neutral fat seems to be the main culprit in fat embolism and is the major fat in bone marrow and subcutaneous tissues [25] and pulmonary emboli [26], the

neutral fat triolein has been the most studied *in vivo* and *in vitro*. Although a number of species have been studied, the rat has been studied the most, particularly after the groundbreaking work of L.F. Peltier [27–29]. He studied fat embolism in cats and dogs but mostly in rats. This work included description of the fat content of bone marrow and body fat, distribution of labeled triolein after *i.v.* injection, changes in blood and lung lipase after embolism, kinetics of the phenomena, and other studies in animals and patients. Some advantages of triolein studies in the rat are described below.

### **3.1 Advantages of triolein and our model**

Triolein [glyceryl trioleate] is available as a pure liquid that can be injected *i.v.* directly or after emulsification. We have used conscious animals since there are studies indicating that anesthesia alters pulmonary response to fat embolism [30]. Although oleic acid is a well-known pulmonary toxicant, as mentioned above, it is not a suitable model for fat embolism syndrome. The conversion of triolein to oleic acid by pulmonary tissue [31] provides support for the proposed sequence of events postulated by Szabo [32].

### **3.2 Findings in the conscious rat triolein model of fat embolism**

#### *3.2.1 Time course of changes in pulmonary histopathology*

Initial histopathological studies on the time course of triolein-induced lung injury revealed changes as early as 12–24 h which included thickening of the arterial and arteriolar media, mostly with myofibroblasts and inflammation in the septa with increased numbers of macrophages. Bronchial alveolar lavage (BAL) at 24 h revealed macrophages, some of which showed inflammatory response and fat droplets. Inflammation was still present at 11 days with damage to the bronchial epithelium [33].

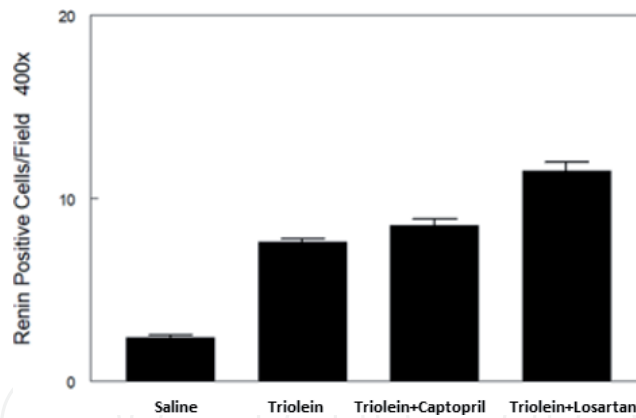
Later studies at 3 and 6 weeks showed that after the first peak [48–72 h] and partial resolution, there were persistent and progressive inflammatory and fibrotic changes up to 6 weeks after injection of triolein [34]. This was associated with an increase in angiotensin peptides [34], implicating the renin-angiotensin system (RAS) in the pathophysiology (see below).

In order to determine if the lungs of the animals at this late time would be especially sensitive to another pulmonary insult, the animals were exposed to the known pulmonary toxicant lipopolysaccharide (LPS) at 6 weeks. Forty-eight hours after this “second hit,” there was an enhanced histopathological response in animals previously exposed to triolein [35].

These animals had apparently recovered completely at 6 weeks from the initial triolein treatment as judged by normal weight gain and no observable behavioral changes. It was concluded that the compromised lungs seen at 6 weeks exposed the vulnerability of animals long after they had seemingly recovered. The histopathology was also found at 10 weeks along with the persistence of some small fat droplets extracellularly and also in some macrophages [36] [see below].

## **4. Role of the renin-angiotensin system**

Because the renin-angiotensin system (RAS) has been implicated in a wide variety of other pulmonary experimental models [37, 38], we examined whether this might hold true for the fat embolism model, and in fact it has since been proposed that most forms of pulmonary inflammatory disease involve the RAS, but that list did not include fat embolism [39]. We found that three different agents that interfere



**Figure 1.**

*Triolein increases lung renin staining: enhanced by captopril and losartan [64].*

with the RAS were found to ameliorate the pulmonary damage found at 48 h after triolein: the angiotensin-converting enzyme (ACE) inhibitor captopril [40], the angiotensin II type 1 receptor blocker losartan [40], and the renin inhibitor aliskiren [41]. In addition, it was found that the remaining inflammation that was evident at 6 weeks was also reduced when losartan was given at this late time period and the animals were sacrificed 4 weeks later (10 weeks after the initial exposure to triolein) [36]. These results suggest that angiotensin II, produced by the angiotensin-converting enzyme (ACE) and acting on the type 1 receptor, is a critical pathological actor in the pathophysiology of fat embolism both acutely and after a substantial delay. However, it does not indicate precisely where this peptide comes from or how it is formed. All of the components of the RAS have been found or implicated in the lung [42]. Possible players in its formation prior to ACE activity could be renin or prorenin that is catalytically active when bound to its receptor [43]. Furthermore, other angiotensin peptides with anti-inflammatory and antifibrotic activity could be counterbalancing forces as well. Most of the extrarenal renin is in the form of prorenin which also has angiotensin-independent pro-fibrotic properties [44–46].

There are many possible cells that could provide components of the RAS to the pulmonary inflammatory process. These include mast cells [47], fibroblasts [48], myofibroblasts [49], vascular smooth muscle [50], and macrophages [51].

There are a number of studies suggesting a critical role of mast cells in RAS mediation of pulmonary pathology [52–54]. It has been suggested that activated macrophages stimulate pulmonary mast cells to release renin and the subsequent production of angiotensin peptides leads to adverse reactions [54]. Mast cells have also been shown to stimulate fibroblasts in the lung [55]. Triolein increases mast cell accumulation in a chronic model, and their appearance is reduced by losartan [56], and aliskiren reduces the triolein-induced increase of mast cell number found at 48 hours [57]. Another mast cell enzyme that has been implicated in angiotensin formation is chymase [58, 59]. It is known that there is mast cell heterogeneity in rodents and humans [60–62], and in humans this includes the presence of renin and its localization within the lungs [62].

In support of the importance of renin/prorenin in fat embolism, we have found an increase in renin staining at 48 hours (**Figure 1**) and 6 weeks after triolein-induced fat embolism [63, 64].

## 5. The nexus of fat metabolism and action and the RAS in the lungs

It has long been speculated that angiotensin II, acting through the type 1 receptor, was a primary inflammatory molecule [65]. In recent years it has become apparent that angiotensin II acting through its type 2 receptor has anti-inflammatory



actions [66] and the literature on similar anti-inflammatory actions through the Ang 1-7/Mas receptor have exploded [67]. It appears that the pathophysiological state of the lungs is a balance between the pro-inflammatory, pro-fibrotic arm of the RAS, and the counterbalancing peptide/receptor activity. It is not surprising that Ang 1-7 has been found to have beneficial effects in the lung [68, 69].

How is the renin-angiotensin system activated in fat embolism, and what is the connection to fat (neutral and fatty acids)? One suggestion based on the work of Gonzalez et al. [52, 54, 70] would have a sequence of fat engulfment by macrophages, and subsequently the activated cells would release monocyte chemoattractant-1 (MCP-1) that stimulates mast cells (nearby or remote) to release renin and angiotensin generation. However, activated macrophages themselves might act in an autocrine or paracrine manner to release renin, and there is evidence for intracrine generation of angiotensin as well [71, 72]. There may be intracrine actions of angiotensin as well on mitochondria and nuclei.

If the RAS is involved in many aspects, including initiating a cascade of downstream malevolent molecules, where does the fat enter the picture? As a host of review articles have discussed, there is a strictly mechanical phase during which the fat emboli obstruct capillaries and cause a short-term hypoxia. It is known that hypoxia itself can lead to pulmonary dysfunction and this can be offset experimentally by angiotensin-converting enzyme inhibition (ACEI) [73] and is associated with an increase in circulating angiotensin peptides [74].

It is clear from the vast literature on metabolism of fat after embolism that most of the lipolysis of neutral fat (mostly triolein) takes place near pulmonary endothelial cells that convert triolein to the toxic oleic acid by lipoprotein lipase. It is now known that oleic acid, although not thought to enter cells [21], can activate its own fatty acid receptor (FFAR/GPR120) which can evoke pulmonary edema [75, 76]. Interestingly, the toxic effects of oleic acid (including pulmonary edema) are antagonized by the non-specific angiotensin receptor blocker 1-sarcosine, 8-isoleucine angiotensin II [77]. This implicates angiotensin II in another way as a key mediator in pulmonary pathology. It has also been reported that oleic acid and angiotensin II are synergistic in promoting a mitogenic effect in vascular smooth muscle [78]. Oleic acid emanating from triolein thus is a co-conspirator in evoking pulmonary (and probably other) pathological conditions, such as cerebral fat embolism [10, 79]. Pathways that oleic acid and angiotensin utilize in producing pathological responses are listed in **Figure 2**.

### **5.1 A vicious cycle of oleic acid and angiotensin II in fat embolism syndrome**

To explain how the sudden appearance of fat in the pulmonary circulation can sometimes produce an acute respiratory distress syndrome and why the neutral fat (primarily triolein) has the potential to lead to longer-term pulmonary damage, the following hypothesis is presented (**Figure 3**). The initial mechanical phase of vascular obstruction which leads to hypoxia is known to be ameliorated by the angiotensin receptor blocker losartan [80].

The delayed metabolic phase is related to breakdown of the most abundant fat in emboli which is hydrolyzed by several triglyceride lipases to yield oleic acid. These include endothelial lipase (EL) and lipoprotein lipase (LIPL) [81, 82] as well as macrophage LIPL [83]. This in turn leads to the evolution of free fatty acids, mainly oleic acid, which is toxic to the endothelium and is released in part in close proximity to endothelial cells. Macrophages become activated after phagocytosing lipid particles which leads to paracrine and endocrine activation of mast cells that induces angiotensin generation [54].

In addition, there is generation of angiotensin and oleic acid intracellularly in macrophages (both of which are toxic to mitochondria [84, 85]). Since oleic acid

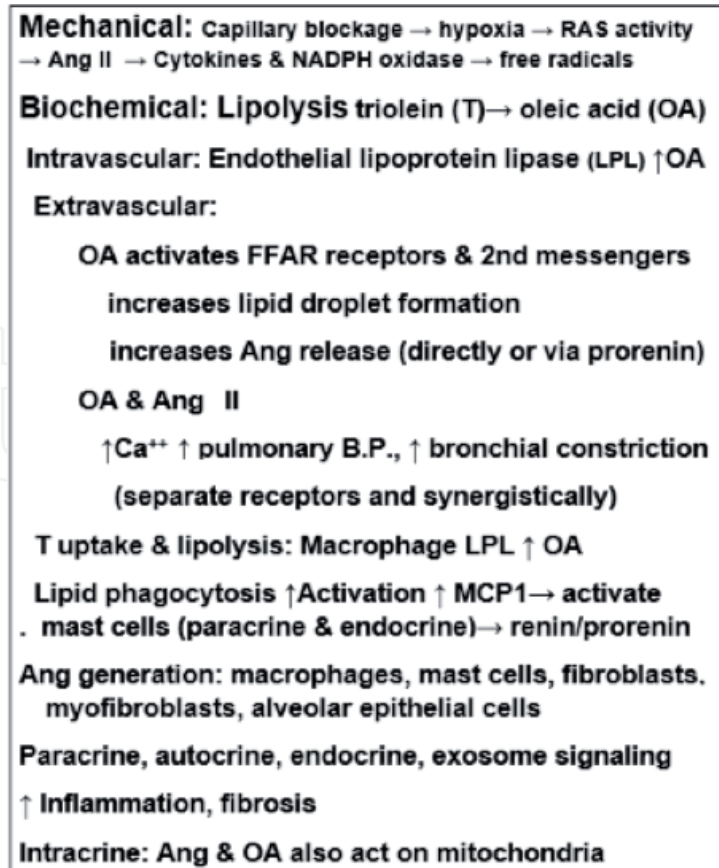


Figure 2.  
Fat embolism pathways.

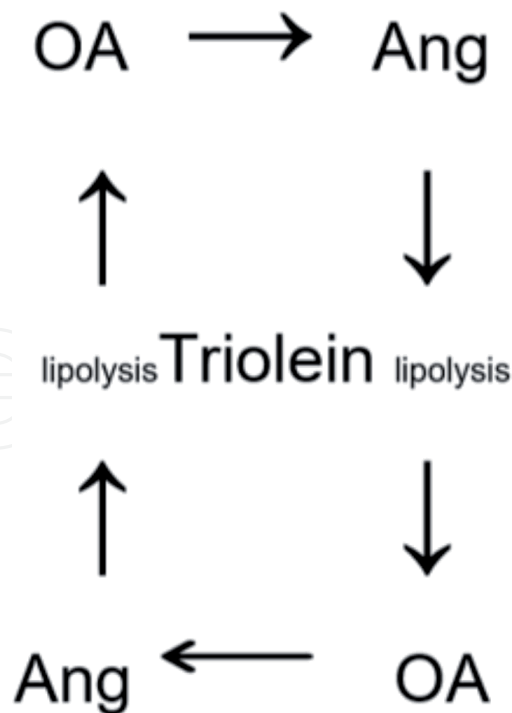


Figure 3.  
Oleic acid-angiotensin cycle: OA ↑ Ang release; Ang ↑ triolein lipolysis.

has been shown to increase angiotensin II release from several cell types [86] and angiotensin increases the expression of various lipases [87], the cycle continues until rescue mechanisms ensue (Figure 4). It should be noted that losartan and perindopril, ACE inhibitors, prevent fatty acid-induced endothelial dysfunction

Clearance by opening of blood vessels  
Clearance of lipid droplets: lymphatic and renal  
Metabolism and uptake of neutral fat  
Metabolism of oleic acid  
Metabolism of angiotensin II: angiotensinases  
Actions of Ang II on AT2 receptors  
Actions of Ang (1-7) on Mas receptors

**Figure 4.**  
*Repair mechanisms for fat embolism.*

in humans in response to elevated blood lipids [88]. Furthermore, oleic acid also increases serum renin and angiotensin, and its effects on pulmonary edema are blocked by blocked by an ACE inhibitor [89].

Most cases of fat embolism do not lead to fat embolism syndrome because the amount of the fat is not of sufficient volume or due to the countervailing mechanisms. These include actions of angiotensin II on AT2 receptors, metabolism of angiotensin II by angiotensinases, anti-inflammatory actions of its metabolite, angiotensin (1-7), metabolism of oleic acid, clearance of lipids via vascular or lymphatic channels, and ultimately renal excretion (**Figure 4**).

## 6. Conclusions and prospects

It is proposed that elements of the renin-angiotensin system are central mediators of tissue injury after fat embolism. Although hypoxia due to capillary blockage is a contributing factor to lung injury, oleic acid liberated from triolein hydrolysis is a crucial step, and it also is associated with angiotensin biology. Angiotensin II through its type 1 receptor is the major offender. Our animal experiments have indicated that three US Food and Drug Administration (FDA)-approved drugs (captopril, losartan, and aliskiren) may have protective value as mentioned above. However, in a clinical setting where trauma or surgery may be involved, stability of blood pressure may be compromised by these agents. Therefore, it is suggested that some of these types of agents (or a combination) could be administered by inhalation.

Rather than antagonizing the angiotensin II generation with ACE or renin inhibitors or angiotensin type 1 activity with antagonists (ARBs), it may be possible to treat/prevent fat embolism injury by stimulating the angiotensin type 2 receptor (AT2) with peptide or non-peptide agonists such as C21 [90]. Another possible therapeutic approach would be to activate the ACE2/angiotensin [1-7]/MAS axis with a peptide or non-peptide agonist, such as AVE0091 [68]. A more promising avenue for preventing or treating fat embolism will more likely be satisfactory if multiple points of the early stages of the pathophysiology are attacked simultaneously. That would include not only the RAS drugs mentioned above but also possibly mast stabilizers that can be given by the inhalation route and some of the newly described drugs that act on the FFA receptors mentioned above. In addition it is possible that some of the newer triglyceride lipase inhibitors could be of value as preventive treatment.

Although the emphasis in this review is on pulmonary fat embolism, there is ample evidence from clinical experience and animal experiments that the eyes, particularly the retina, are frequently targets of fat embolism. Both triolein and oleic acid have been implicated in ocular pathology [91, 92], and the RAS is thought to be an important mediating system in many ocular diseases [93].



Another non-pulmonary target of fat embolism in clinical FES is the brain, and cerebral fat embolism can be fatal [94]. Although a patent foramen ovale is sometimes an important factor in cerebral fat embolism, this is clearly not the case in many instances, and animal models have not provided any new insights of cardiac defects being major players. In a rat model, there is some evidence that cerebral fat embolism may involve a serine protease [79] and maybe this could be related to a non-renin generation of angiotensin by a chymase-like enzyme. The RAS is now believed to be important for much CNS pathology [95].

There now is reason to be optimistic that the next comprehensive review of fat embolism syndrome will describe some new available therapeutic options based on animal experiments. This reinforces the goal of animal experiments to delineate the pathophysiological mechanisms underlying human disease, so specific treatment can be implemented.

## **Acknowledgements**

We acknowledge the support of Dr. Gary Salzman, M.D., and the Mary Catherine Geldmacher Foundation of St. Louis, MO, the graphical help from Dr. Doud Arif, and the inspiration to begin this research from the late Dr. Federico Adler.

## **Author details**

Alan M. Poisner<sup>1\*</sup> and Agostino Molteni<sup>2</sup>

<sup>1</sup> University of Kansas Medical Center, Kansas City, KS, USA

<sup>2</sup> University of Missouri Kansas City School of Medicine, Kansas City, MO, USA

\*Address all correspondence to: [apoisner@kumc.edu](mailto:apoisner@kumc.edu)

## **IntechOpen**

© 2019 The Author(s). Licensee IntechOpen. This chapter is distributed under the terms of the Creative Commons Attribution License (<http://creativecommons.org/licenses/by/3.0>), which permits unrestricted use, distribution, and reproduction in any medium, provided the original work is properly cited. 

## References

- [1] Zenker FA. Beiträge zur normalen und pathologischen Anatomie der Lungen. Braunsnsdorf: Dresden; 1862
- [2] Herndon JH, Riseborough EJ, Fischer JE. Fat embolism: A review of current concepts. *The Journal of Trauma*. 1971;**11**(8):673-680
- [3] Hildebrand F, Andruszkow H, Barkatali BM, Pfeifer R, Lichte P, Kobbe P, et al. Animal models to assess the local and systemic effects of nailing: Review of the literature and considerations for future studies. *Journal of Trauma and Acute Care Surgery*. 2014;**76**(6):1495-1506
- [4] Cantu CA, Pavlisko EN. Liposuction-induced fat embolism syndrome: A brief review and postmortem diagnostic approach. *Archives of Pathology & Laboratory Medicine*. 2018;**142**(7):871-875
- [5] Cardenas-Camarena L, Bayter JE, Aguirre-Serrano H, Cuenca-Pardo J. Deaths caused by gluteal lipoinjection: What are we doing wrong? *Plastic and Reconstructive Surgery*. 2015;**136**(1):58-66
- [6] Vichinsky E, Williams R, Das M, Earles AN, Lewis N, Adler A, et al. Pulmonary fat embolism: A distinct cause of severe acute chest syndrome in sickle cell anemia. *Blood*. 1994;**83**(11):3107-3112
- [7] Schulz F, Trubner K, Hildebrand E. Fatal fat embolism in acute hepatic necrosis with associated fatty liver. *The American Journal of Forensic Medicine and Pathology*. 1996;**17**(3):264-268
- [8] Fukumoto LE, Fukumoto KD. Fat embolism syndrome. *The Nursing Clinics of North America*. 2018;**53**(3):335-347
- [9] Eriksson EA, Pellegrini DC, Vanderkolk WE, Minshall CT, Fakhry SM, Cohle SD. Incidence of pulmonary fat embolism at autopsy: An undiagnosed epidemic. *Journal of Trauma*. 2011;**71**(2):312-315
- [10] Dines DE, Burgher LW, Okazaki H. The clinical and pathologic correlation of fat embolism syndrome. *Mayo Clinic Proceedings*. 1975;**50**(7):407-411
- [11] Spirn MJ, Biousse V. Retinal fat emboli. *The Journal of Emergency Medicine*. 2005;**29**(3):339-340
- [12] Shaikh N. Emergency management of fat embolism syndrome. *Journal of Emergencies, Trauma, and Shock*. 2009;**2**(1):29-33
- [13] Inoue H, Hanagama M, Kamiya M, Shinone K, Nata M. Experimental pulmonary fat embolism induced by injection of triolein in rats. *Legal Medicine*. 2008;**10**:26-30
- [14] Zhang Y, Tian K, Wang Y, Zhang R, Shang J, Jiang W, et al. The effects of aquaporin-1 in pulmonary edema induced by fat embolism syndrome. *International Journal of Molecular Sciences*. 2016;**17**(7):1183
- [15] Woo OH, Yong HS, Oh YW, Shin BK, Kim HK, Kang EY. Experimental pulmonary fat embolism: Computed tomography and pathologic findings of the sequential changes. *Journal of Korean Medical Science*. 2008;**23**(4):691-699
- [16] Byrick RJ, Mullen JB, Mazer CD, Guest CB. Transpulmonary systemic fat embolism. Studies in mongrel dogs after cemented arthroplasty. *American Journal of Respiratory and Critical Care Medicine*. 1994;**150**:1416-1422
- [17] Aebli N, Krebs J, Davis G, Walton M, Williams MJ, Theis JC. Fat embolism and acute hypotension during

vertebroplasty: An experimental study in sheep. *Spine* [Phila Pa 1976 ]. 2002;**27**(5):460-466

[18] Wang AZ, Zhou M, Jiang W, Zhang WX. The differences between venous air embolism and fat embolism in routine intraoperative monitoring methods, transesophageal echocardiography, and fatal volume in pigs. *The Journal of Trauma*. 2008;**65**(2):416-423

[19] Kropfl A, Davies J, Berger U, Hertz H, Schlag G. Intramedullary pressure and bone marrow fat extravasation in reamed and unreamed femoral nailing. *Journal of Orthopaedic Research*. 1999;**17**(2):261-268

[20] Pape HC, Hildebrand F, Krettek C, Green J, Giannoudis PV. Experimental background—Review of animal studies. *Injury*. 2006;**37**(Suppl 4):S25-S38

[21] Matute-Bello G, Frevert CW, Martin TR. Animal models of acute lung injury. *American Journal of Physiology. Lung Cellular and Molecular Physiology*. 2008;**295**(3):L379-L399

[22] Takada M, Chiba S, Nagai T, Takeshita H, Kanno S, Ikawa T, et al. Inflammatory responses to neutral fat and fatty acids in multiple organs in a rat model of fat embolism syndrome. *Forensic Science International*. 2015;**254**:126-132

[23] Lim KR, Cho JM, Yoon CM, Lee KC, Lee SY, Ju MH. Correlation between the time elapsed after liposuction and the risk of fat embolism: An animal model. *Archives of Plastic Surgery*. 2018;**45**(1):14-22

[24] Mofid MM, Teitelbaum S, Suissa D, Ramirez-Montanana A, Astarita DC, Mendieta C, et al. Report on mortality from gluteal fat grafting: Recommendations from the ASERF Task Force. *Aesthetic Surgery Journal*. 2017;**37**(7):796-806

[25] Peltier LF, Wheller DH, BOYD HM, Scott JR. Fat embolism. II. The chemical

composition of fat obtained from human long bones and subcutaneous tissue. *Surgery*. 1956;**40**(4):661-664

[26] Sherr S, Montemurno R, Raffer P. Lipids of recovered pulmonary fat emboli following trauma. *The Journal of Trauma*. 1974;**14**(3):242-246

[27] Peltier LF. Fat embolism following intramedullary nailing; report of a fatality. *Surgery*. 1952;**32**(4):719-722

[28] Peltier LF. Fat embolism: A pulmonary disease. *Surgery*. 1967;**62**(4):756-758

[29] Peltier LF. Fat embolism. A perspective. *Clinical Orthopaedics and Related Research*. 1988;**232**:263-270

[30] Wang AZ, Ma QX, Zhao HJ, Zhou QH, Jiang W, Sun JZ. A comparative study of the mortality rate of rats receiving a half lethal dose of fat intravenously: Under general anaesthesia versus under spinal anaesthesia. *Injury*. 2012;**43**(3):311-314

[31] Compton SK, Hamosh M, Hamosh P. Hydrolysis of triglycerides in the isolated perfused rat lung. *Lipids*. 1982;**17**:696-702

[32] Szabo G, Magyar Z, Reffy A. The role of free fatty acids in pulmonary fat embolism. *Injury*. 1977;**8**(4):278-283

[33] McIff TE, Poisner AM, Herndon B, Lankachandra K, Schutt S, Haileselassie B, et al. Fat embolism: Evolution of histopathological changes in the rat lung. *Journal of Orthopaedic Research*. 2010;**28**(2):191-197

[34] Poisner AM, Adler F, Uhal B, McIff TE, Schroepfel JP, Mehrer A, et al. Persistent and progressive pulmonary fibrotic changes in a model of fat embolism. *Journal of Trauma and Acute Care Surgery*. 2012;**72**(4):992-998

- [35] Poisner AM, Herndon B, Lankachandra K, Likhitsup A, Al Hariri A, Kesh S, et al. Fat embolism sensitizes rats to a “second hit” with lipopolysaccharide: An animal model of pulmonary fibrosis. *Journal of Trauma and Acute Care Surgery*. 2015;**78**:552-557
- [36] Poisner A, Herndon B, Bass D, Fletcher A, Jain A, England JP, et al. Evidence for angiotensin mediation of the late histopathological effects of fat embolism: Protection by losartan in a rat model. *Experimental Lung Research*. 2019;**44**:363-367
- [37] Molteni A, Moulder JE, Cohen EF, Ward WF, Fish BL, Taylor JM, et al. Control of radiation-induced pneumopathy and lung fibrosis by angiotensin-converting enzyme inhibitors and an angiotensin II type 1 receptor blocker. *International Journal of Radiation Biology*. 2000;**76**(4):523-532
- [38] Molteni A, Ward WF, Ts’ao CH, Solliday NH, Dunne M. Monocrotaline-induced pulmonary fibrosis in rats: Amelioration by captopril and penicillamine. *Proceedings of the Society for Experimental Biology and Medicine*. 1985;**180**(1):112-120
- [39] Tan WSD, Liao W, Zhou S, Mei D, Wong WF. Targeting the renin-angiotensin system as novel therapeutic strategy x for pulmonary diseases. *Current Opinion in Pharmacology*. 2018;**40**:9-17
- [40] McIff TE, Poisner AM, Herndon B, Lankachandra K, Molteni A, Adler F. Mitigating effects of captopril and losartan on lung histopathology in a rat model of fat embolism. *The Journal of Trauma*. 2011;**70**:1186-1191
- [41] Fletcher A, Molteni A, Ponnappureddy R, Patel C, Plum M, Poisner AM. The renin inhibitor aliskiren protects rat lungs from the histopathological effects of fat embolism. *Journal of Trauma and Acute Care Surgery*. 2017;**82**:338-344
- [42] Marshall RP. The pulmonary renin-angiotensin system. *Current Pharmaceutical Design*. 2003;**9**(9):715-722
- [43] Ahmed BA, Seda O, Lavoie JL. [Pro]renin receptor as a new drug target. *Current Pharmaceutical Design*. 2011;**17**(33):3611-3621
- [44] Sealey JE, Rubattu S. Prorenin and renin as separate mediators of tissue and circulating systems. *American Journal of Hypertension*. 1989;**2**:358-366
- [45] Sihn G, Rousselle A, Vilianovitch L, Burckle C, Bader M. Physiology of the [pro]renin receptor: Wnt of change? *Kidney International*. 2010;**78**(3):246-256
- [46] Hennrikus M, Gonzalez AA, Prieto MC. The prorenin receptor in the cardiovascular system and beyond. *American Journal of Physiology. Heart and Circulatory Physiology*. 2018;**314**(2):H139-H145
- [47] Silver RB, Reid AC, Mackins CJ, Askwith T, Schaefer U, Herzlinger D, et al. Mast cells: A unique source of renin. *Proceedings of the National Academy of Sciences of the United States of America*. 2004;**101**(37):13607-13612
- [48] Dostal DE, Rothblum KN, Conrad KM, Cooper GR, Baker KM. Detection of angiotensin I and II in cultured rat cardiac myocytes and fibroblasts. *The American Journal of Physiology*. 1992;**263**:C851-C863
- [49] Katwa LC, Campbell SE, Tyagi SC, Lee SJ, Cicila GT, Weber KT. Cultured myofibroblasts generate angiotensin peptides de novo. *Journal of Molecular and Cellular Cardiology*. 1997;**29**:1375-1386



- [50] Iwai N, Matsunaga M, Kita T, Tei M, Kawai C. Regulation of renin-like enzyme in cultured human vascular smooth muscle cells. *Japanese Circulation Journal*. 1988;**52**:1338-1345
- [51] Iwai N, Inagami T, Ohmichi N, Kinoshita M. Renin is expressed in rat macrophage/monocyte cells. *Hypertension*. 1996;**27**:399-403
- [52] Gonzalez NC, Allen J, Schmidt EJ, Casillan AJ, Orth T, Wood JG. Role of the renin-angiotensin system in the systemic microvascular inflammation of alveolar hypoxia. *American Journal of Physiology. Heart and Circulatory Physiology*. 2007;**292**:H2285-H2294
- [53] Veerappan A, O'Connor NJ, Brazin J, Reid AC, Jung A, McGee D, et al. Mast cells: A pivotal role in pulmonary fibrosis. *DNA and Cell Biology*. 2013;**32**(4):206-218
- [54] Chao J, Blanco G, Wood JG, Gonzalez NC. Renin released from mast cells activated by circulating MCP-1 initiates the microvascular phase of the systemic inflammation of alveolar hypoxia. *American Journal of Physiology. Heart and Circulatory Physiology*. 2011;**301**(6):H2264-H2270
- [55] Garbuzenko E, Berkman N, Puxeddu I, Kramer M, Nagler A, Levi-Schaffer F. Mast cells induce activation of human lung fibroblasts in vitro. *Experimental Lung Research*. 2004;**30**:705-721
- [56] Poisner AM, Hamidpour S, Ho A, Skaria P, Fletcher A, Simon S, et al. Losartan blocks the recruitment of mast cells in the lungs of rats subjected to fat embolism with or without a second hit with LPS. *The FASEB Journal*. 2016;**30**:700.2
- [57] Kesh S, Fletcher A, Voelker P, Guidos P, Poisner A, Tylski E, et al. Aliskiren, a direct renin inhibitor, reduces mast cell accumulation in lungs of rats after fat embolism. *QJM: An International Journal of Medicine*. 2016;**109**(Suppl 1):S48
- [58] Reilly CF, Tewksbury DA, Schechter NM, Travis J. Rapid conversion of angiotensin I to angiotensin II by neutrophil and mast cell proteinases. *The Journal of Biological Chemistry*. 1982;**257**:8619-8622
- [59] Hultsch T, Ennis MF, Heidtmann HH. The role of chymase in ionophore-induced histamine release from human pulmonary mast cells. *Advances in Experimental Medicine and Biology*. 1988;**240**:133-136
- [60] Tainsh KR, Pearce FL. Mast cell heterogeneity: Evidence that mast cells isolated from various connective tissue locations in the rat display markedly graded phenotypes. *International Archives of Allergy and Immunology*. 1992;**98**(1):26-34
- [61] Irani AM, Schwartz LB. Mast cell heterogeneity. *Clinical and Experimental Allergy*. 1989;**19**(2):143-155
- [62] Andersson CK, Mori M, Bjermer L, Lofdahl CG, Erjefalt JS. Novel site-specific mast cell subpopulations in the human lung. *Thorax*. 2009;**64**(4):297-305
- [63] Poisner A, Herndon B, Al Hariri A, Qin C, Quinn T. Renin as a mediator of pulmonary damage caused by fat embolism and LPS. *The FASEB Journal*. 2013;**27**(1 Supplement):lb444
- [64] Hamidpour S, Poisner A, Molteni A, Al-Husseinawi A, Colson J, Samir H, et al. Increased staining for renin/prorenin in the lungs in a rat model of fat embolism is enhanced by captopril and losartan which ameliorate the pulmonary damage. *American Journal of Respiratory and Critical Care Medicine*. 2018;**197**:A1859
- [65] Das UN. Is angiotensin-II an endogenous pro-inflammatory

molecule? *Medical Science Monitor*. 2005;**11**(5):RA155-RA162

[66] Karnik SS, Unal H, Kemp JR, Tirupula KC, Eguchi S, Vanderheyden PM, et al. Angiotensin receptors: Interpreters of pathophysiological angiotensinergic stimuli. *Pharmacological Reviews*. 2015;**67**(4):754-819

[67] Gironacci MM. Angiotensin-[1-7]: Beyond its central effects on blood pressure. *Therapeutic Advances in Cardiovascular Disease*. 2015;**9**(4):209-216

[68] Klein N, Gembardt F, Supe S, Kaestle SM, Nickles H, Erfinanda L, et al. Angiotensin-[1-7] protects from experimental acute lung injury. *Critical Care Medicine*. 2013;**41**(11):e334-e343

[69] Uhal BD, Nguyen H, Dang M, Gopallawa I, Jiang J, Dang V, et al. Abrogation of ER stress-induced apoptosis of alveolar epithelial cells by angiotensin 1-7. *American Journal of Physiology-Lung Cellular and Molecular Physiology*. 2013;**305**(1):L33-L41

[70] Gonzalez NC, Wood JG. Alveolar hypoxia-induced systemic inflammation: What low PO<sub>2</sub> does and does not do. *Advances in Experimental Medicine and Biology*. 2010;**662**:27-32

[71] Dezso B, Nielsen AH, Poulsen K. Identification of renin in resident alveolar macrophages and monocytes: HPLC and immunohistochemical study. *Journal of Cell Science*. 1988;**91**(Pt 1):155-159

[72] Chao J, Wood JG, Gonzalez NC. Alveolar hypoxia, alveolar macrophages, and systemic inflammation. *Respiratory Research*. 2009;**10**:54

[73] Zakheim RM, Mattioli L, Molteni A, Mullis KB, Bartley J. Prevention of pulmonary vascular changes of

chronic alveolar hypoxia by inhibition of angiotensin I-converting enzyme in the rat. *Laboratory Investigation*. 1975;**33**(1):57-61

[74] Zakheim RM, Molteni A, Mattioli L, Park M. Plasma angiotensin II levels in hypoxic and hypovolemic stress in unanesthetized rabbits. *Journal of Applied Physiology*. 1976;**41**(4):462-465

[75] Mizuta K, Zhang Y, Mizuta F, Hoshijima H, Shiga T, Masaki E, et al. Novel identification of the free fatty acid receptor FFAR1 that promotes contraction in airway smooth muscle. *American Journal of Physiology. Lung Cellular and Molecular Physiology*. 2015;**309**(9):L970-L982

[76] Rohwedder A, Zhang Q, Rudge SA, Wakelam MJ. Lipid droplet formation in response to oleic acid in Huh-7 cells is mediated by the fatty acid receptor FFAR4. *Journal of Cell Science*. 2014;**127**(Pt 14):3104-3115

[77] Yukioka T, Yukioka N, Aulick LH, Goodwin CW, Mason AD Jr, Sugimoto T, et al. Evaluation of [1-sarcosine, 8-isoleucine] angiotensin II as a therapeutic agent for oleic acid-induced pulmonary edema. *Surgery*. 1986;**99**(2):235-244

[78] Lu G, Meier KE, Jaffa AA, Rosenzweig SA, Egan BM. Oleic acid and angiotensin II induce a synergistic mitogenic response in vascular smooth muscle cells. *Hypertension*. 1998;**31**(4):978-985

[79] Xiong L, Sun L, Liu S, Zhu X, Teng Z, Yan J. The protective roles of urinary trypsin inhibitor in brain injury following fat embolism syndrome in a rat model. *Cell Transplantation*. 2018;**963689718814766**:1-9

[80] Kiely DG, Cargill RI, Lipworth BJ. Acute hypoxic pulmonary vasoconstriction in man is attenuated by type I angiotensin II receptor

blockade. *Cardiovascular Research*. 1995;**30**:875-880

[81] Coonrod JD, Karathanasis P, Lin R. Lipoprotein lipase: A source of free fatty acids in bronchoalveolar lining fluid. *Journal of Laboratory and Clinical Medicine*. 1989;**113**(4):449-457

[82] Gal S, Bassett DJ, Hamosh M, Hamosh P. Triacylglycerol hydrolysis in the isolated, perfused rat lung. *Biochimica et Biophysica Acta*. 1982;**713**:222-229

[83] Okabe TF, Yorifuji HF, Murase TF, Takaku F. Pulmonary macrophage: A major source of lipoprotein lipase in the lung. *Biochemical and Biophysical Research Communications*. 1984;**125**:273-278

[84] Re RN, Cook JL. The mitochondrial component of intracrine action. *American Journal of Physiology. Heart and Circulatory Physiology*. 2010;**299**(3):H577-H583

[85] Hirabara SM, Silveira LR, Alberici LC, Leandro CV, Lambertucci RH, Polimeno GC, et al. Acute effect of fatty acids on metabolism and mitochondrial coupling in skeletal muscle. *Biochimica et Biophysica Acta*. 2006;**1757**(1):57-66

[86] Azekoshi Y, Yasu T, Watanabe S, Tagawa T, Abe S, Yamakawa K, et al. Free fatty acid causes leukocyte activation and resultant endothelial dysfunction through enhanced angiotensin II production in mononuclear and polymorphonuclear cells. *Hypertension*. 2010;**56**(1):136-142

[87] Shimokawa Y, Hirata K, Ishida T, Kojima Y, Inoue N, Quertermous T, et al. Increased expression of endothelial lipase in rat models of hypertension. *Cardiovascular Research*. 2005;**66**(3):594-600

[88] Watanabe S, Tagawa T, Yamakawa K, Shimabukuro M, Ueda S. Inhibition

of the renin-angiotensin system prevents free fatty acid-induced acute endothelial dysfunction in humans. *Arteriosclerosis, Thrombosis, and Vascular Biology*. 2005;**25**(11):2376-2380

[89] Leeman M, Lejeune P, Naeije R. Inhibition of angiotensin-converting enzyme by perindopril diacid in canine oleic acid pulmonary edema. *Critical Care Medicine*. 1987;**15**(6):567-573

[90] Bruce E, Shenoy V, Rathinasabapathy A, Espejo A, Horowitz A, Oswald A, et al. Selective activation of angiotensin AT2 receptors attenuates progression of pulmonary hypertension and inhibits cardiopulmonary fibrosis. *British Journal of Pharmacology*. 2015;**172**(9):2219-2231

[91] Chuang EL, Miller FS, Kalina RE. Retinal lesions following long bone fractures. *Ophthalmology*. 1985;**92**(3):370-374

[92] Lee JE, Jea SY, Oum BS, Kim HJ, Ohn YH. Effect of fat embolism with triolein emulsion on blood-retinal barrier. *Ophthalmic Research*. 2009;**41**(1):14-20

[93] Choudhary R, Kapoor MS, Singh A, Bodakhe SH. Therapeutic targets of renin-angiotensin system in ocular disorders. *Journal of Current Ophthalmology*. 2017;**29**(1):7-16

[94] Berlot G, Bussani R, Shafiei V, Zarrillo N. Fulminant cerebral fat embolism: Case description and review of the literature. *Case Reports in Critical Care*. 2018;**7813175**

[95] Jackson L, Eldahshan W, Fagan SC, Ergul A. Within the brain: The renin angiotensin system. *International Journal of Molecular Sciences*. 2018;**19**(3):876-879