View metadata, citation and similar papers at core.ac.uk

brought to you by CORE

provided by IntechOpen

# We are IntechOpen, the world's leading publisher of Open Access books Built by scientists, for scientists

**4,800**
Open access books available

**122,000**
International authors and editors

**135M**
Downloads

**154**
Countries delivered to

Our authors are among the

**TOP 1%**
most cited scientists

**12.2%**
Contributors from top 500 universities

WEB OF SCIENCE™

Selection of our books indexed in the Book Citation Index in Web of Science™ Core Collection (BKCI)

## Interested in publishing with us? Contact book.department@intechopen.com

Numbers displayed above are based on latest data collected.
For more information visit www.intechopen.com

Chapter

# Amyloidosis: Systems-Based Therapies

*Eileen Ly, Anu Stephen, Yasmeen Alhomsy, Asal Homayouni, Joshua Fisher, Kayla Sheehan, Prashanth Venkataraman, Quinto Gesiotto, Matthew Habib and Matthew Zabel*

## Abstract

In this chapter, the authors will discuss the epidemiology and clinical presentations of amyloidosis. The main body of this chapter will concentrate on treatment options, both FDA-approved and experimental, specific to the various forms of amyloidosis. Since this set of diseases can affect multiple organ systems, we tackle the therapeutic avenues and the current challenges in each system under clinical investigation, including neurological, psychiatric, gastrointestinal, cardiovascular, endocrine, renal and hematologic, in addition to options for palliative treatment for severe symptom management and improved quality of life. Several recent groundbreaking discoveries have opened up the potential for successful treatment of peripheral and central neurological amyloidoses making this an exciting and evolving field.

**Keywords:** transthyretin, antisense oligonucleotide, protein aggregation

## 1. Epidemiology

Amyloidosis is a rare, albeit likely underdiagnosed, disorder [1]. Claims data in the United States shows prevalence of amyloid light-chain (AL) amyloidosis increased between 2007 and 2015 from 15.5 to 45 cases per million [2]. Incidence did not significantly increase over this time period, but ranged from 9.7 to 14 cases per million-person years [2]. This equates to more than 12,000 people in the US currently living with this disorder. Older data, from 1950 to 1989, found 9 cases per million people, more evidence of an increasing prevalence over time [3]. The trend in age- and sex-adjusted incidence rate of amyloidosis per million person years from 1950 to 1989 was not found to be significant (**Figure 1**).

This phenomenon could be explained by increased detection and diagnosis. Studies in the United Kingdom and Sweden demonstrated a prevalence of 20 cases per million and incidence of 5 cases per million-person years, 3 of them being AL, and 1 amyloid A (AA) amyloidosis [1, 4]. A US study found a mean age at diagnosis of AL amyloidosis of 63 with a standard deviation of 12, 55% male [2]. International studies also show that men are slightly more likely to be diagnosed with AL, however, AA amyloidosis more commonly affects women, possibly due to higher prevalence of underlying rheumatoid arthritis [1].

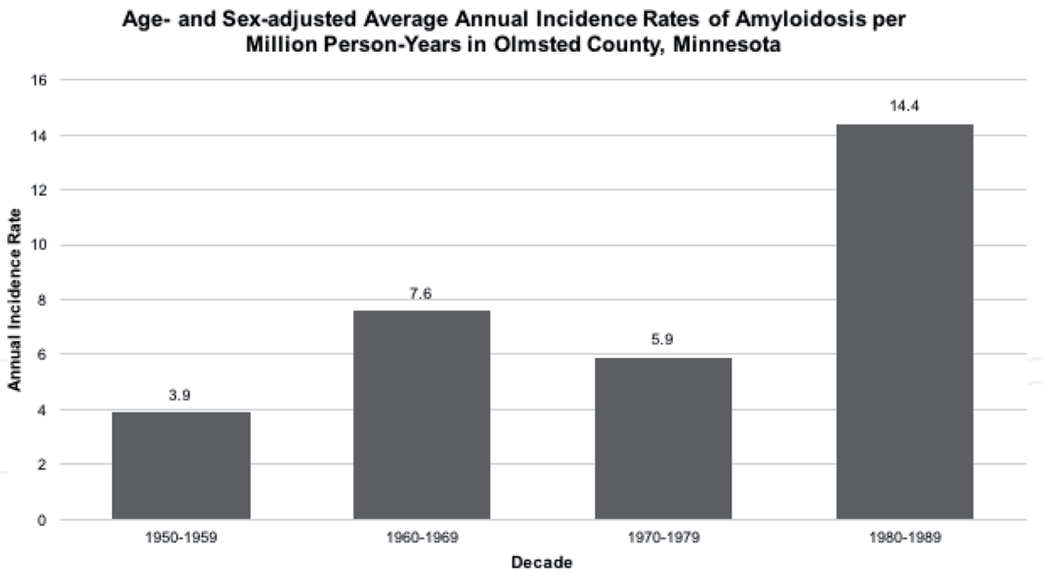


**Figure 1.**
*Age- and sex-adjusted average annual incidence rates of amyloidosis per million person-years in Olmsted County, Minnesota from 1950 to 1989.*

AL amyloidosis is more prevalent than AA amyloidosis in developed countries, however, in developing countries and some Mediterranean countries, AA is more prevalent (**Figure 2**). Other studies have shown AL to be more prevalent than AA in developed countries, but in developing nations AA has a higher prevalence than AL [1].

This follows the logic of the epidemiologic transition, since as a country develops, diseases transition from infectious to chronic disease states. In developing nations, endemic infections such as tuberculosis or leprosy lead to AA amyloidosis,

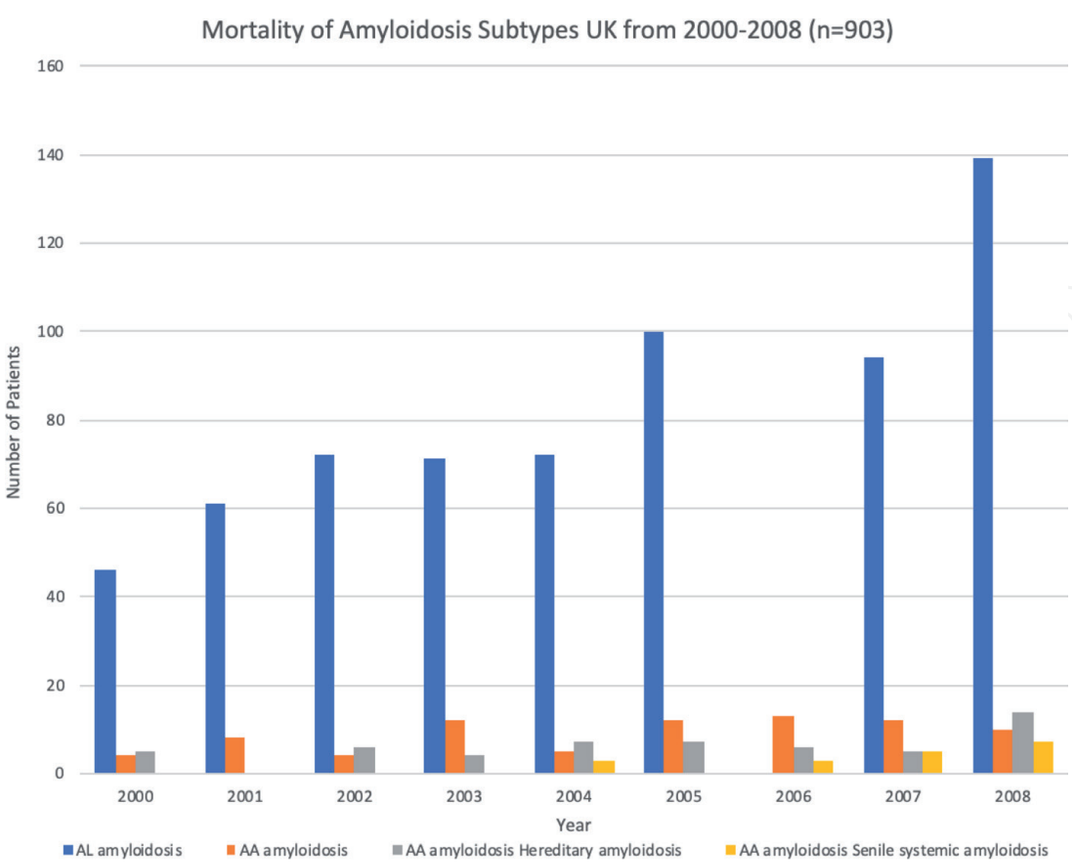


**Figure 2.**
*Mortality of amyloidosis subtypes UK from 2000 to 2020,008 (n = 903).*

while in developed nations chronic diseases lead to AL amyloidosis. The exception to this is Mediterranean nations, while developed, have a higher prevalence of AA amyloidosis. This is likely due to relatively high prevalence autoinflammatory diseases such as familial Mediterranean fever. For example, in Spain, AL amyloidosis has become the most prevalent subtype, increasing in frequency relative to other subtypes from 21% in 1977 to 44% in 2013 [5].

The prognosis for amyloidosis varies by subtype, treatment modality, extent of cardiac involvement and, to a lesser degree, hepatic and autonomic involvement [1]. A Swedish study estimated median survival to be 3, 4, and 6 years for AL, AA, and localized amyloidosis [6]. In regards to systemic amyloidosis, a median survival time of 32 months was seen in the UK [4]. Older studies found untreated median survival time ranging from 6 months to 4 years [1].

## 2. Palliative treatments for amyloidosis

The protein deposition and accumulation inherent in amyloidosis causes a wide range of systemic symptoms, and patients may also suffer from side effects of curative therapies. Though many mistakenly believe palliative interventions are only for end of life care, palliative treatments can be implemented at any stage of illness, and may help curb severe symptoms. In many forms of cancer, early palliative interventions have been shown to increase quality of life for both patients and caregivers [7]. While no studies have been conducted to evaluate the effectiveness of palliative therapies on amyloidosis specifically, palliative treatments for many of the common sequelae of amyloidosis have been well researched [8].

### 2.1 Pain

Neuropathic pain (NP) is the most common pain sensation reported in people with amyloidosis. NP is notoriously difficult to control, and is often not responsive to typical pain regimens. Antidepressants, anticonvulsants, opioids, and topical medications are the most common pharmacologic agents used. Unfortunately, many of these agents have their own side effects, and should be used with caution [8].

### 2.2 Depression

There has long been a link noted between depression and dementia, and depression has been viewed as both a prodrome and a risk factor for dementia. About half of patients with late-onset depression are found to have cognitive impairment, and the prevalence of dementia in depression has been reported between 9 and 68% [9]. A past history of depression is a known risk factor for developing Alzheimer's disease and vascular dementia, even when the episode of depression occurred over 10 years prior. Rather than a prodrome, depression seems to be a risk factor for Alzheimer's disease, as evidenced by a neuropathological study showing increased neurofibrillary tangles and plaques in the hippocampus in those with a history of depression [10]. Depression is linked to hypercortisolemia, which may cause prolonged damage to the hippocampus. Depression may also be a psychological reaction to the diagnosis of cognitive impairment, and may even reveal previously clinically silent cognitive impairment by depleting cognitive reserve [11]. Additionally, the use of tricyclic antidepressants in the elderly may also contribute to clinical dementia due to their anticholinergic effects.

The link between depression and Alzheimer disease may involve mechanisms in the metabolism of β-amyloid peptides in the brain. A recent study has shown

significant associations between geriatric depression and β-amyloid peptide deposits in the insula, hippocampus, and amygdale [12]. Another recent study showed the link between hereditary gelsolin amyloidosis (AGel) and neuropsychiatric changes. The gelsolin mutation is associated with cerebrovascular fragility, and is an autosomal dominant form of systemic amyloidosis. The study found visuoconstructional difficulties in the AGel group in both the block design and drawing tasks. While overall processing speed was similar in both groups, the AGel group produced more errors [13]. The behavioral and psychological symptoms of people with dementia result in greater cognitive and functional impairment, and are associated with greater amyloid deposition in the neurodegenerative process leading to Alzheimer's disease [14].

### 2.3 Sexual dysfunction

The pathophysiology of sexual dysfunction in amyloidosis can range from medication side effects (corticosteroids, opioids), to primary hypogonadism (amyloid deposition in the testes), and depression. Determining the etiology of sexual dysfunction is key in selecting the proper treatment. For erectile dysfunction, sildenafil has been shown to be effective. Testosterone replacement may help in cases of hypogonadism, but has not been studied in patients with amyloidosis.

## 3. Renal amyloidosis

Renal amyloidosis is often the major cause of death for individuals with AL, AA, and hereditary amyloidosis; untreated, it usually progresses to end-stage renal disease. Understanding how amyloid fibrils form, and how the renal amyloidosis manifests are crucial in determining treatment approaches specific to each type of amyloidosis.

While amyloid can be found anywhere in the kidney, it often predominates in the glomerulus, forming nodules composed of amyloid protein that disrupt glomerular function. Consequently, patients with renal amyloidosis present with the components of nephrotic syndrome: severe proteinuria, hypoalbuminemia, edema, decreased GFR. When the amyloid protein is in the tubulointerstitium or vasculature, the patient will instead demonstrate minimal proteinuria with a decrease in GFR. (Vascular involvement may also come with HTN.) Generally, renal impairment progresses more rapidly with glomerular involvement. Patients mostly present with normal-sized kidneys but amyloidosis can cause enlargement of the kidneys.

Of the three main categories of renal amyloidoses, AL remains the most common, accounting for 81 and 68% of amyloidosis cases in two recent studies from the U.S. and Italy [15, 16]. In 50% of patients with systemic Ig-related amyloidosis, kidney disease presents as the most common manifestation [17].

### 3.1 Renal AL amyloidosis

Because AL amyloidosis is commonly associated with an underlying plasma cell dyscrasia, the purpose of treatment is to destroy amyloid-producing plasma cells. Therefore, treating AL amyloidosis is based on anti-myeloma therapy, which must be tailored to each patient's age, comorbidities, extent of organ involvement, and patient's wishes. The standard treatment was repeated cycles of oral melphalan and prednisone with an increase in median survival to 1.5 years [18]; however, this has changed in the past decade. In an 8 year longitudinal study by [19], 25–50% of patients who underwent high-dose intravenous melphalan followed by autologous stem cell transplantation(HDM/SCT to support bone marrow recovery demonstrated

complete hematologic responses. In 2006, Seldin et al. followed 43 patients who received HDM/SCT between 1994 and 1996, and found that median survival rate of 10 years for patients with a complete hematologic response [20]. In 2011, Sanchorawala et al. followed the long-term outcome of 421 patients and reported a long-term survival of up to 20 years [19]. More research is being done on the effectiveness of repeated HDM/SCT treatments, some of them reporting favorable outcomes in patients who did not achieve a complete hematologic response the first time.

Despite the success of HDM/SCT, treatment-associated mortality is 12–14% with a higher prevalence in those with cardiac amyloidosis. Because stem cell mobilization requires high doses of growth factors, this can be complicated in patients with nephrotic syndrome or heart failure due to fluid retention. In addition to increased risks for splenic rupture (especially in patients with splenic amyloid), thrombocytopenia, and neutropenia, patients may also be subject to acute renal failure as reported by two different studies [21]. The British Journal of Hematology published guidelines in 2014 for HDM/SCT as first line treatment for selected patients up to 60–75 years of age with eGFR >50 ml/min, low cardiac biomarkers, low level plasma cell infiltration in the bone marrow, and lacking the following contraindications: cardiac amyloidosis, severe autonomic neuropathy, significant GI bleeding due to amyloid, advanced renal failure, age over 7 years, symptomatic recurrent amyloid related pleural effusions [22].

As an alternative to HDM/SCT, a combination of oral melphalan and high dose dexamethasone was shown by Pallidini et al. to have a 33% complete hematologic response in patients who are ineligible for HDM/SCT [23]. In addition to the oral melphalan and dexamethasone, patients can use proteasome inhibitor-based regimens and a bortezomib-alkylator-steroid combination for a rapid response [22].

### 3.2 Renal AA amyloidosis

Because AA amyloidosis is often associated with the production of serum amyloid A (SAA), an acute phase reactant protein from an underlying inflammatory disease, the goal of treatment is to treat the cause. Stopping the inflammatory processes of familial Mediterranean fever (FMF), rheumatoid arthritis (RA), and other causes of AA has been shown by several studies to prevent amyloidosis. For example, colchicine is used to inhibit Familial Mediterranean Fever-associated inflammation, which prevented amyloidosis production [24]. In a 2002 study, Elkyam et al. treated a patient with infliximab for rheumatoid arthritis, whose proteinuria resolved [25]. It is thought that these agents have additional anti-amyloid effects by suppressing cytokine production or by altering expression of specific mediators of cellular toxicity [26].

A new treatment approach involving fibrillogenic inhibition is currently underway, involving eprosidate, a sulfonated, negatively charged molecule like heparan sulfate. The molecule competitively binds to glycosaminoglycan-binding sites on SAA, and inhibits fibril polymerization and amyloid deposition. In a multicenter, randomized, double-blind, placebo controlled trial, Dember et al. demonstrated that eprodisate slowed the decline of renal function in AA amyloidosis patients [27]. The results from the second Phase III study will help determine whether eprosidate will become one of the new treatment approaches in fighting renal AA amyloidosis [28].

### 3.3 Dialysis and kidney transplantation

For patients with renal amyloidosis who are in ESRD, dialysis or kidney transplantation is other options. Currently, the literature for dialysis differs for AL amyloidosis patients and AA amyloidosis patients, but the consensus is a poor prognosis

for AL amyloidosis patients on dialysis, especially those with cardiac involvement. For AA amyloidosis patients on dialysis, Guillaume et al. reported a 15% mortality rate, a better prognosis overall [29]. Treating patients who are on dialysis with HDM/SCT has shown no difference between the hematologic response rate and treatment -associated mortality are similar in dialysis-dependent patients compared with the overall population of patients who undergo this treatment [27].

Kidney transplantation is a good option for patients who have a complete hematologic response in AL amyloidosis and do not have significant extrarenal disease. In 2012, Gurusu et al. examined survival rates of 44 patients with amyloidosis who had undergone kidney transplantation and found the same outcomes with patients with other kidney diseases [30]. This indicates that amyloidosis patients should be accepted as transplant candidates.

### 3.4 Bortezomib, a game changer for multiple myeloma and AL amyloidosis

Monoclonal antibody therapy has become a mainstay of treatment in plasma cell disorders such as multiple myeloma and primary systemic (AL) amyloidosis. Bortezomib (Velcade), a proteasome inhibitor, has shown effectiveness as an initial therapy of multiple myeloma in stem cell transplant (SCT) eligible patients [31, 32]. Bortezomib has been especially effective in younger patients and contributed significantly to improvements in survival seen in the early 2000s [33]. Bortezomib and other proteasome inhibitors are associated with less cardiotoxic risk than chemotherapeutics such as melphalan, cyclophosphamide, and doxorubicin [34]. Modern induction therapy for multiple myeloma now consists a combination of bortezomib and dexamethasone (BD), plus thalidomide or melphalan for both transplant-eligible and SCT ineligible patients. A phase IIIB study found no difference in outcomes or survival between BD, BD plus thalidomide, or BD plus melphalan in transplant-ineligible patients [35]. Bortezomib is also effective as a consolidation

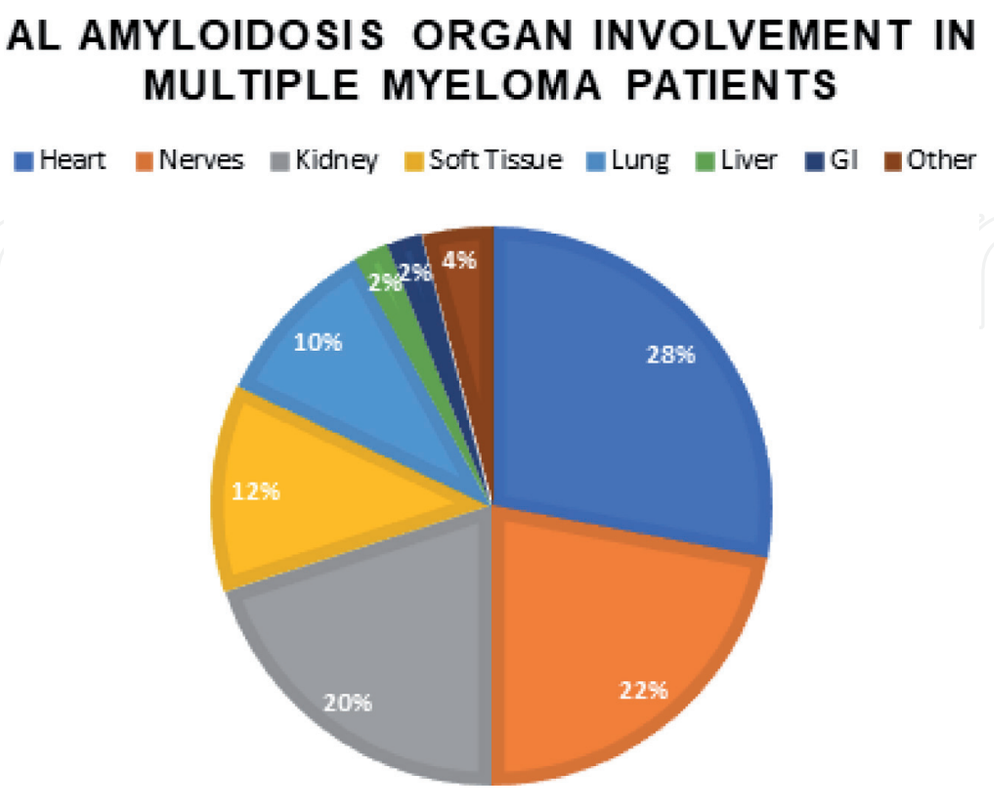


**Figure 3.**
*AL amyloidosis organ involvement pattern in patients with multiple myeloma.*

and maintenance therapy, prolonging progression-free survival and overall survival in patients with partial or very good partial response following induction/consolidation therapy [36].

AL amyloidosis can present spontaneously or in association with other blood cell disorders such as multiple myeloma and lymphoplasmocytic lymphoma. AL amyloidosis is a well-recognized complication of multiple myeloma in particular, occurring in approximately 10–15% of patients (**Figure 3**) [37]. Not surprisingly, bortezomib therapy is now a recommended treatment for primary AL amyloidosis both in SCT ineligible patients and post SCT patients [38, 39]. Reece et al. showed bortezomib to be a particularly effective and well-tolerated therapy in relapsed AL amyloidosis patients, evidenced by once and twice-weekly treatments both effectively inducing a hematological response in this population [40, 41]. A randomized phase III trial showed more profound and frequent hematological responses to bortezomib versus melphalan plus dexamethasone in patients with newly diagnosed AL amyloidosis, indicating bortezomib as a promising initial therapy [42].

## 4. Amyloidosis and the nervous system

Neurologic involvement of systemic amyloidosis has been observed in over 20% of cases, and the median duration of neuropathic symptoms prior to diagnosis is 2 years [43]. The pathophysiology of amyloid deposition contributing to the clinical manifestation of neurodegenerative disorders, including Alzheimer's Dementia, Parkinson's Disease, and Huntington's Disease, has been well-documented [44]. Furthermore, cerebral amyloid angiopathy is a well-known cause/risk factor for intracerebral hemorrhage in the elderly [45]. Lastly, systemic amyloidosis (classically, primary amyloidosis) affects not only the central nervous system, but is a well-known cause of peripheral and autonomic neuropathy [46]. Thus, the deposition of abnormally folded proteins has not only been linked to progressive and acute devastating CNS disorders, but also to neurologic sequelae throughout the body. In this section, we describe some of the novel treatments and their mechanisms of action for both CNS and PNS manifestations of the illness.

### 4.1 Amyloid beta: Alzheimer's dementia, and cerebral amyloid angiopathy

There are no current therapies that modify the deposition of A beta amyloid in the CNS. Therefore the focus of treatment has been mainly symptomatic with acetylcholinesterase inhibitors, antidepressants and antipsychotics. However, new research focusing on monoclonal antibodies reducing plaque load prove to have promising results in the mice model [47]. Modest levels of peripherally administration antibodies against the amyloid beta-peptide crossed the blood brain barrier entering the CNS and inducing clearance of preexisting amyloid via activation of microglial cells [48]. Bapineuzumab, Solanezumab, Gantenerumab, Crenezumab, Ponezumab, BAN2401, and Aducaumab are anti-amyloid beta monoclonal antibodies that have progressed to human trials and paved the pathway for the development of more effective therapies.

The mechanism of Bapineuzumab, one of the first humanized monoclonal IgG1 antibody used in humans, attaches to soluble and fibrillar amyloid beta via the five N-terminal residues inducing Fc receptor-mediated microglial phagocytosis of amyloid beta deposits. In phase 1, 30 patients were divided into low dose (0.5 mg/kg), medium (1.5 mg/kg) and high dose (5 mg/kg), and overall the drug was considered to be safe. 3/10 participants in the high dose category developed MRI findings typical of vasogenic edema that eventually resolved. Amyloid-related imaging abnormalities

(ARIA) were coined to describe imaging abnormalities as a result of treatment, for example ARIA-H for microhemorrhage and hemosiderosis and ARIA-E for effusion or vasogenic edema. IV infusion in phase 2 of the trial showed no significant treatment differences in patients with mild to moderate Alzheimer's disease. A parallel phase 2, as well as retrospective study done by neuroradiologists resulted in the conclusion that there is an increased occurrence of ARIA-E in carriers of APOE4, necessitating the incorporation of biomarkers to qualify for treatment, but increased numbers of symptomatic ARIA-E resulted in discontinuation of bapineuzumab trials.

Solanezumab, another humanized IgG1 monoclonal antibody, completed phase 3 testing without meeting efficacy requirements. It binds the mid-domain of amyloid beta residues to increase clearance of monomers, and continues in preclinical Alzheimer's disease trials to see if there is a benefit to earlier intervention. Phases 1 and 2 showed a relationship between dose and CSF Amyloid-beta protein. In phase 3 studies, termed EXPEDITION 1 and EXPEDITION 2, 18 month trials of IV solanezumab 400 mg against IV placebo, did not demonstrate any significant benefit. However, it demonstrated the drugs favorable safety profile with only 0.9% incidence of ARIA-E compared to 0.4% seen in the placebo. A third phase 3 trial, EXPEDITION 3, also showed nonsignificant results with solanezumab and eventually led to the drug's discontinuation for dementia.

As opposed to the previously mentioned therapies, Gantenerumab was the first fully human IgG1 antibody against the conformational epitope expressed on amyloid beta fibrils that contain both the N-terminal and central amino acids. Phase 1 trials with patients who had mild to moderate Alzheimer's disease showed that seven IV infusions (60–200 mg) every 4 weeks reduced brain burden. It also showed the drug's favorable safety profile. 2 out of 6 patients in the high dose group experienced ARIA-E. Initial phase 2 trials included 360 participants and doses of subcutaneous 105 mg or 225 mg every 4 weeks for 2 years, but was later expanded to a phase 2/3 with 799 participants showed no significant treatment effects for CDE-SB or changes in the amount of brain amyloid beta. Currently Gantenerumab, like solanezumab, is being explored for patients with fast progression and autosomal dominant Alzheimer's disease.

Other therapies that have proven to have non-significant results in the treatment of amyloid beta deposition within the CNS include Crenezumab, Ponezumab, BAN2401, and Aducaumab. Despite these findings, the tolerability of monoclonal antibodies lends hope for developing therapies for this pathology. Moreover, future studies should focus on the importance of brain entry of anti-amyloid beta monoclonal antibodies, as it is not currently clear whether therein lies any benefit as only 0.1% cross the blood brain barrier. Dosage and stage of disease are two other important points for consideration in improving the efficacy of these therapies, and whether the lack of efficacy was due to insufficient amounts of drug or late stage disease [49].

### 4.2 Transthyretin amyloidosis

Transthyretin is a liver-derived protein, that when misfolded can accumulate in the liver, kidney, GI tract, and the peripheral nerves. Multiple genetic abnormalities have been shown to contribute to increased predisposition and familial forms of transthyretin amyloidosis. These have led to syndromes such as familial amyloidotic cardiomyopathy and familial amyloidotic polyneuropathy [49, 50].

Familial amyloidotic polyneuropathy (FAP) is a fatal condition that is caused by the substitution of a methionine residue for a valine residue at the 30th position of the TTR gene [51]. In this section, we briefly discuss the role of liver transplantation and more thoroughly introduce the use of RNA interference molecules to decrease transthyretin production.

## 5. Liver transplantation

Around 95% of transthyretin is produced by the liver, and thus, it was postulated that liver transplantation would provide great benefit for patients with transthyretin amyloidosis. The first liver transplantation for transthyretin amyloidosis was done in 1990 in Sweden and showed promising results. Since then, liver transplantation has been a standard treatment for this devastating disorder [51].

Liver transplantation has been shown to be of benefit if intervention is taken earlier in the disease course. The risks and prognostic factors for liver transplantation have been well-documented, including the long wait times for an available transplantable organ. However, additional prognostic factors for survival post liver transplantation in patients with amyloidotic polyneuropathy include hereditary and geographic factors, duration of the disease, initial degree of polyneuropathy, presence of autonomic dysfunction, co-morbid cardiac, kidney/bladder, and GI impairment, and prior nutritional status. Liver transplantation is usually not a procedure that will improve the patient's condition, but rather, prevent further decline.

### 5.1 IDOX, doxycycline, and RNAi therapy

Since the difficulties associated with liver transplantation prevented adequate treatment of FAP patients, new non-surgical treatment methods were researched. It was initially shown that 4′iodo′4′-doxy-doxorubicin (IDOX) inhibits amyloid formation and promotes the resorption of amyloid deposits. Initially shown that IDOX can induce amyloid resorption in patients with immunoglobulin light chain amyloidosis, it was further studied for all types of amyloid deposition disorders. It is hypothesized that IDOX exerts its effects by inhibiting fibril growth and increasing the solubility of amyloid deposits. This, in turn, facilitates amyloid clearance. These results have been consistent in both in vivo and in vitro studies through two distinct binding sites between IDOX and amyloid fibrils [52].

At around the same time as IDOX was being investigated, Doxycycline became the next promising medication that showed similar success in both FAP transgenic mice and phase II human trials with transthyretin amyloidosis. It's theorized mechanism of action involves amyloid fibril destructuration and promotion of amyloid deposition. In one phase II trial, doxycyclin plus tauroursodeoxycholic acid resulted in stable cardiac and neuropathy symptoms after 1 year of treatment. When used in conjunction with TTR stabilizers, therapy could both block formation and promote clearance of existing amyloid simultaneously [53, 54].

The most recent research for transthyretin amyloidosis treatment has surrounded RNA interference (RNAi) therapy. RNAi therapy decreases transthyretin production from the liver by directly suppressing mRNA transcription of the gene that codes for the transthyretin protein. Due to the specific nature of this pharmacology, long-term side-effects of RNAi therapy have not been reported. Two medications, Patisiran and Inotersen, have become FDA approved in the past 5 years after studies have shown a dose-dependent reduction of both mutant and nonmuntant tranthyretin production and deposition. This RNAi therapy has been shown to cause between 50 and 80% reduction in transthyretin levels as early as 2–3 weeks after therapy initiation. Furthermore, these medications have provided significant neurologic symptomatic benefit in a majority of patients when compared to placebo therapy. Since these medications affect both mutant and nonmutant transthyretin production, they have been shown to not only have decreased side-effects to liver transplantation, but better long-term efficacy. The most common side effect to the medication reported has been transfusion-related reactions in 8–20% of patients [49, 55, 56].

## 6. Cardiac amyloidosis

Along with the kidneys, the heart is one of the most commonly affected organs in cases of amyloidosis, as amyloid fibrils deposit in its parenchyma and impair it from functioning optimally. The deposition of either light chain amyloid (AL) or transthyretin (TTR) in the cardiac myocardium is responsible for the vast majority (>95%) of cases of amyloid cardiomyopathy [57]. This infiltration of the myocardial tissue essentially results in a clinical presentation of heart failure with preserved ejection fraction; therefore, the treatment is twofold and is targeted at both the primary, underlying disease process and at the secondary heart failure.

### 6.1 AL amyloid

In regards to the primary disease, treatment varies substantially based on the nature of the abnormal protein that is deposited in the cardiac tissue. AL amyloid, or primary amyloid, affects the heart by depositing abnormally-folded proteins into the myocardium, rendering the ventricles concentrically thickened, thus impairing their ability to accommodate adequate filling volumes. Some studies suggest that the amyloidogenic proteins also have direct cytotoxic effects on the myocardial cells. The pathogenic proteins in AL amyloid are misfolded immunoglobulin light chains produced by a number of clonal plasma cells in the bone marrow; therefore, cytotoxic therapies against these cells have been proven to be effective. A combination of oral melphalan, dexamethasone, autologous stem cell transplantation and/or bortezomib is often utilized and tailored to each individual case based on various factors such as age, stage of disease, and patient's desire for treatment. These drug regimens are further discussed in the section on renal amyloidosis treatment.

### 6.2 TTR amyloid

In transthyretin amyloidosis, the protein transthyretin (TTR) loses stability, misfolds, and deposits in organs throughout the body, including the cardiac myocardium. In contrast to other types of amyloidosis, which may or may not involve the heart, TTR almost always features cardiac involvement and myocardial protein deposition. The consequences of protein deposition in the heart are essentially the same across all types of amyloidosis as the ventricles thicken and result in a restrictive type of cardiomyopathy that prevents the heart from properly filling with blood during the diastolic phase of the cardiac cycle. The restrictive cardiomyopathy leads to a clinical picture of heart failure, with symptoms that often significantly decrease the patient's quality of life. The most definitive treatment for TTR amyloidosis is liver transplantation. This is because the TTR protein is produced in the liver and eliminating the source of the protein would eliminate the pathogenic process altogether. Liver transplantation, however, may not be an option for patients who are not candidates for the procedure. This is where a recently studied drug, Tafamidis, plays a key role. Tafamidis is an agent that exhibits its therapeutic effect by stabilizing the TTR protein, thus preventing its misfolding and subsequent deposition in organs of the body. In a randomized, placebo-controlled, double blind study performed in September 2018, Tafamidis was found to improve the quality of life of amyloidosis patients by slowing the progression of the disease and reducing the functional impairment of affected nerves and systems throughout the body [58, 59]. Other drugs that also may be beneficial in TTR amyloidosis cases include an NSAID called Diflunisal, doxycycline, and an antisense therapy called ISIS-TTRrx. Both Diflunisal and doxycycline are thought to have the same mechanism of action as Tafamidis, as they stabilize the TTR protein and prevent amyloidogenesis. ISIS-TTRrx's mechanism of action differs and works by directly

suppressing the gene that expresses the TTR protein. These agents are still being investigated for efficacy in experiments and clinical trials [59].

### 6.3 Heart failure

Heart failure secondary to cardiac amyloidosis is treated rather differently than heart failure that is organic or secondary to other causes. Agents that typically play key roles in heart failure management, such as beta blockers, ace inhibitors, and calcium channel blockers, are avoided and, sometimes, even contraindicated. These drugs are ineffective in cases of amyloid cardiomyopathy due to the pathophysiology of protein deposition rather than intrinsic cellular dysfunction of the cardiac cells. Utilization of calcium channel blockers, for example, results in an apparent amplification of the drugs' negative inotropic effects and a resultant decompensation of the amyloid cardiomyopathy [60, 61]. One class of drugs- the loop diuretics- remains the cornerstone medication utilized even in cases of heart failure due to amyloid cardiomyopathy. A loop diuretic combined with an aldosterone antagonist has been found to be the most efficacious combination of treatment for amyloid-associated heart failure [57, 62]. Along with drug therapy, other vital lifestyle changes include salt and fluid restriction, as well as regular weight measurements to monitor volume status.

## 7. Amyloidosis of the respiratory tract

Amyloidosis is characterized by pathological misfolding of the amyloid protein and its deposition as fibrils leading to organ dysfunction. Amyloidosis of the respiratory tract can be localized or a part of a systemic picture of dysfunction. Pulmonary amyloidosis is only symptomatic if amyloid deposits are present on the alveoli, causing impaired gas exchange. Amyloid deposition in the lung parenchyma may manifest as nodular deposits or lead to localized lymphomas.

Tissue deposits of misfolded amyloid protein in the form of fibrils characterize systemic amyloidosis. There are 15 different kinds of systemic amyloidoses, defined based on the characteristics of the deposited amyloid protein [63]. The primary kinds of amyloidosis that impact the lungs are systemic AL and localized AL consisting of monoclonal light chains, AA amyloid consisting of apolipoprotein serum amyloid A, and ATTRwt consisting of wild-type transthyretin [64]. Regardless of the type of amyloid fibril that is deposited, all fibrils have the same backbone structure that the Congo red stain binds in order to reveal an apple-green birefringence under polarized light [65]. Tissue biopsy is central to diagnosis of amyloidosis as treatment modalities vary based on the type of amyloid protein that is deposited. Less invasive procedures like abdominal fat biopsy and fine needle biopsy are indicated over more invasive procedures like transbronchial biopsy [66, 67]. Once a biopsy is obtained, it is evaluated using immunohistochemistry. The lungs are a common site of amyloid deposition, although not always symptomatic. There are three main kinds of pulmonary amyloidosis: nodular, diffuse, and tracheobronchial. Systemic amyloidosis is symptomatic, and often as a result of chronic inflammation.

### 7.1 Nodular pulmonary amyloidosis

Nodular amyloid deposits involving the lung are usually an incidentaloma on chest imaging and usually consist of AL light chain or mixed AL-AH light chain-heavy chain [68, 69]. Nodular amyloidosis has been associated with mucosa associated lymphoid tissue (MALT) and Sjogren disease [68]. In a study of 49 individuals with nodular AL amyloidosis, surgical resection and systemic chemotherapy

were the major forms of treatment [64]. In fact, conservative excision in nodular AL amyloidosis presents with a great prognosis, although intervention is rarely required as a whole.

### 7.2 Diffuse alveolar amyloidosis

Presence of amyloid deposits on the alveolar walls and adjoining blood vessels signifies diffuse alveolar amyloidosis [70–72]. Since pulmonary impairment is not prominent in diffuse alveolar amyloidosis, it is often observed as a finding of post-mortem studies [73]. Positron emission tomography using radiolabeled florbetapir is one of the modalities that can help identify the diffuse alveolar variant of amyloidosis [74]. Diffuse alveolar amyloidosis has a progressive course of interstitial lung disease involving an infiltrative imaging pattern and dyspnea [75].

Diffuse alveolar amyloidosis is most commonly a manifestation of systemic AL amyloidosis, which is why treatment takes the form of targeting the underlying systemic amyloidosis. Burden reduction of free light chain is deemed to be central principle of treatment. Chemotherapy like low-dose Melphalan derived for multiple myeloma currently drives the treatment modalities used for diffuse alveolar amyloidosis [76–78]. Prednisolone is another medication used for treatment purposes. However, it is important to fashion treatment on a personalized basis based on patient needs. Pulmonary amyloidosis especially complicates the scenario when diffusion capacity reduces to less than 50%, although stem cell transplantation is an option in these cases [79]. Lung transplant is yet another option to treat isolated lung amyloidosis [80].

### 7.3 Laryngeal amyloidosis

Usually localized in nature, laryngeal amyloidosis is manifested by amyloid deposits superior to the glottis. The larynx is the most common location for isolated amyloid deposition in the head and neck, and symptomatically presents with stridor, dyspnea, and hoarseness [81]. Larger lesions are often surgically removed with an endoscopic excision or laryngofissure [82, 83]. Smaller lesions can be treated with carbon dioxide laser evaporation [84, 85].

### 7.4 Tracheobronchial amyloidosis

Tracheobronchial amyloidosis is characterized by submucosal plaques with occasional involvement of the trachea and larynx [86, 87]. Cough, dyspnea, and hemoptysis are common manifestations, with tracheal and bronchial thickening and calcifications being diagnostic markers on CT [88, 89]. Stenting is also used to prevent airway collapse in an already compromised respiratory circuit. Although treatment modalities for tracheobronchial amyloidosis are limited, systemic chemotherapy is sometimes used [89]. Tracheobronchial involvement can be symptomatically treated with debridement, bronchoscopic resection, and external beam radiation [90, 91].

### 7.5 A peek into the future

Agents are being developed that aim to help stabilize amyloid in their native morphology and slow down or even halt fibril deposition. Glycosaminoglycans (GAG)-like molecules inhibitors and Secreted Aspartyl Proteinase (SAP)-binding inhibitors are currently being developed. GAG binding to amyloid enhances amyloid fibril deposition, while SAP potentiates amyloidosis [92, 93]. Like mentioned earlier, it is paramount to mold each treatment plan according to the recipient to best suit the patient's needs and goals of care.

IntechOpen

IntechOpen

## Author details

Eileen Ly, Anu Stephen, Yasmeen Alhomsy, Asal Homayouni, Joshua Fisher, Kayla Sheehan, Prashanth Venkataraman, Quinto Gesiotto, Matthew Habib and Matthew Zabel*
College of Medicine, California Northstate University, Elk Grove, CA, USA

*Address all correspondence to: matthew.zabel9352@cnsu.edu

IntechOpen

© 2019 The Author(s). Licensee IntechOpen. This chapter is distributed under the terms of the Creative Commons Attribution License (http://creativecommons.org/licenses/by/3.0), which permits unrestricted use, distribution, and reproduction in any medium, provided the original work is properly cited.

## References

[1] Nienhuis HL, Bijzet J, Hazenberg BP. The prevalence and management of systemic amyloidosis in Western countries. Kidney Diseases. 2016;**2**(1):10-19

[2] Quock TP, Yan T, Chang E, Guthrie S, Broder MS. Epidemiology of AL amyloidosis: A real-world study using US claims data. Blood Advances. 2018;**2**(10):1046-1053

[3] Kyle R, Linos A, Beard C, Linke R, Gertz M, O'Fallon W, et al. Incidence and natural history of primary systemic amyloidosis in Olmsted County, Minnesota, 1950 through 1989. Blood. 1992;**79**(7):1817-1822

[4] Pinney JH, Smith CJ, Taube JB, Lachmann HJ, Venner CP, Gibbs SD, et al. Systemic amyloidosis in England: An epidemiological study. British Journal of Haematology. 2013;**161**(4):525-532

[5] de Asúa D, Costa R, Galván JM, Filigheddu MT, Trujillo D, Cadiñanos J. Systemic AA amyloidosis: Epidemiology, diagnosis, and management. Clinical Epidemiology. 2014;**6**:369-377

[6] Hemminki K, Li X, Försti A, Sundquist J, Sundquist K. Incidence and survival in non-hereditary amyloidosis in Sweden. BMC Public Health. 2012;**12**:974

[7] El-Jawahri A, Greer JA, Pirl WF, Park ER, Jackson VA, Back AL, et al. Effects of early integrated palliative care on caregivers of patients with lung and gastrointestinal cancer: A randomized clinical trial. The Oncologist. 2017;**22**(12):1528-1534

[8] Tsukanov J, Fabbro ED. Palliative care and symptom management in amyloidosis: A review. Current Problems in Cancer. 2016;**40**(5-6):220-228

[9] Muliyala K, Varghese M. The complex relationship between depression and dementia. Annals of Indian Academy of Neurology. 2010;**13**(Suppl 2):S69-S73

[10] Rapp M, Schnaider-Beeri M, Grossman H, Sano M, Perl D, Purohit D, et al. Increased hippocampal plaques and tangles in patients with Alzheimer disease with a lifetime history of major depression. Archives of General Psychiatry. 2006;**63**(2):161-167

[11] Ganguli M. Depression, cognitive impairment and dementia: Why should clinicians care about the web of causation? Indian Journal of Psychiatry. 2009;**51**(Suppl 1):S29-S34

[12] Kim H, Kong E, Cheon E, Kim H, Koo B. Association between cerebral amyloid deposition and clinical factors including cognitive function in geriatric depression: Pilot study using amyloid. Clinical Psychopharmacology and Neuroscience. 2016;**14**(4):378-382

[13] Kantanen M, Kiuru-Enari S, Salonen O, Kaipainen M, Hokkanen L. Subtle neuropsychiatric and neurocognitive changes in hereditary gelsolin amyloidosis (AGel amyloidosis). Peer J. 2014;**2**:e493

[14] Bensamoun D, Guignard R, Furst A, Derreumaux A, Manera V, Darcourt J, et al. Associations between neuropsychiatric symptoms and cerebral amyloid deposition in cognitively impaired elderly people. Journal of Alzheimer's Disease. 2016;**49**(2):387-398

[15] Said M, Johnson H, Nonyane B, Deloria-Knoll M, O'Brien K, Andreo F, et al. Estimating the burden of pneumococcal pneumonia among adults: a systematic review and meta-analysis of diagnostic techniques. PLoS One. 2013;**8**(4):e60273

[16] Bergesio F, Ciciani A, Manganaro M, Palladini G, Santostefano M, Brugnano R, et al. Renal involvement in systemic amyloidosis: an Italian collaborative study on survival and renal outcome. Nephrology Dialysis Transplantation. 2008;**23**(3):941-51

[17] Mazdak A, Wallace W, Palma-Diaz M. Amyloid nephropathy. Clinical Kidney Journal. Apr 2014;**7**(2):97-106

[18] Seldin D, inner OB, Quillen K, Finn K. Relapse rate and long-term survival of AL amyloidosis patients treated with high-dose melphalan and autologous stem cell transplantation (HDM/SCT). Blood. 2006;**108**:3094

[19] Skinner M, Sanchorawala V, Seldin D, Dember L, Falk R, Berk J, et al. High-dose melphalan and autologous stem-cell transplantation in patients with AL amyloidosis: An 8-year study. Amyloid and Amyloidosis. 2004;**140**(2):85-93

[20] Seldin M, Shigeta R, Villoslada P, Selmi C, Tuomilehto J, Silva G, et al. European Population Substructure: Clustering of Northern and Southern Populations. PLoS Genetics. 2006; **2**(9):e143

[21] Leung N, Griffin DA, Haugen E, Gloor J, Schwab T, et al. Living donor kidney and autologous stem cell transplantation for primary systemic amyloidosis (AL) with predominant renal involvement. American Journal of Transplantation. 2005;**5**(7):1660-1670

[22] Wechalekar A, Gillmore J, Bird J, Cavenagh J, Hawkins S, Kazmi M, et al. Guidelines on the management of AL amyloidosis. British Journal of Haematology. 2015;**168**(2):186-206

[23] Palladini G, Perfetti V, Obici L, Caccialanza R, Semino A, Adami F, et al. Association of melphalan and high-dose dexamethasone is effective and well tolerated in patients with AL (primary) amyloidosis who are ineligible for stem cell transplantation. Blood. 2004;**103**(8):2936-2938

[24] Ozen S. Renal amyloidosis in familial mediterranean fever. Kidney International. 2004;**65**(3):1118-1127

[25] Elkayam O, Hawkins P, Lachmann H, Yaron M, Caspi D. Rapid and complete resolution of proteinuria due to renal amyloidosis in a patient with rheumatoid arthritis treated with infliximab. Arthritis and Rheumatism. 2002;**46**(10):2571-2573

[26] Yan DS, Zhu H, Zhu A, Golabek A, Du H, Roher A, et al. Receptor-dependent cell stress and amyloid accumulation in systemic amyloidosis. Nature Medicine. 2000;**6**(6):643-651

[27] Dember L, Hawkins P, Hazenberg B, Gorevic P, Merlini G, Butrimiene I, et al. Eprodisate for the treatment of renal disease in AA amyloidosis. NEJM. 2007;**356**(23):2349-2360

[28] Rumjon A, Coats T, Javaid M. Review of eprodisate for the treatment of renal disease in AA amyloidosis. International Journal of Nephrology and Renovascular Disease. 2012;**5**:37-43

[29] Guillaume B, N Straetmans N, Jadoul M, Cosyns J, Ferrant A. Allogeneic bone marrow transplantation for AL. Bone Marrow Transplantation. 1997;**20**:907-908

[30] Gursu M, Yelken B, Caliskan Y, Kazancioglu R, Yazici H, Kilicaslan I, et al. Outcome of patients with amyloidosis after renal transplantation: a single-center experience. International Journal of Artificial Organs. 2012; **35**(6):444-449

[31] Moreau P, Avet-Loiseau H, Facon T, Attal M, Tiab M, Hulin C, et al. Bortezomib plus dexamethasone versus reduced-dose bortezomib, thalidomide plus dexamethasone as

induction treatment prior to autologous stem cell transplantation in newly diagnosed multiple myeloma. Blood. 2011;**118**(22):5752-5758

[32] Kumar S, Dispenzieri A, Lacy M, Gertz M, Buadi F, Pandey S, et al. Continued improvement in survival in multiple myeloma: Changes in early mortality and outcomes in older patients. Leukemia. 2014;**28**(5):1122-1128

[33] Brenner H, Gondos A, Pulte D. Recent major improvement in long-term survival of younger patients with multiple myeloma. Blood. 2008;**111**(5):2521-2526

[34] Bringhen S, Milan A, Ferri C, Wäsch R, Gay F, Larocca A, et al. Cardiovascular adverse events in modern myeloma therapy–incidence and risks. A review from the European myeloma network (EMN) and Italian Society of Arterial Hypertension. Haematologica. 2018;**103**(9):1422-1432

[35] Niesvizky R, Flinn I, Rifkin R, Gabrail N, Charu V, Clowney B, et al. Community-based phase IIIB trial of three UPFRONT bortezomib-based myeloma regimens. Journal of Clinical Oncology. 2015;**33**(33):3921-3929

[36] Cerrato C, Raimondo DF, Paoli DL, Spada S, Patriarca F, Crippa C, et al. Maintenance in myeloma patients achieving complete response after upfront therapy: A pooled analysis. Journal of Cancer Research and Clinical Oncology. 2018;**144**(7):1357-1366

[37] Madan S, Dispenzieri A, Lacy M, Buadi F, Hayman S, Zeldenrust S, et al. Clinical features and treatment response of light chain (AL) amyloidosis diagnosed in patients with previous diagnosis of multiple myeloma. Mayo Clinic Proceedings. 2010;**85**(3):232-238

[38] Kastritis E, Anagnostopoulos A, Roussou M, Toumanidis S, Pamboukas C, et al. Treatment of light chain (AL) amyloidosis with the combination of bortezomib and dexamethasone. Haematologica. 2007;**92**(10):1351-1358

[39] Chaulagain C, Comenzo R. How we treat systemic light-chain amyloidosis. Clinical Advances in Hematology & Oncology. 2015;**13**(5):315-324

[40] Reece D, Hegenbart U, Sanchorawala V, Merlini G, Paladini G, Blade J, et al. Long-term follow-up from a phase 1/2 study of single-agent bortezomib in relapsed systemic AL amyloidosis. Blood. 2014;**124**(16):2498-2506

[41] Reece D, Hegenbart U, Sanchorawala V, Merlini G, Paladini G, Blade J, et al. Efficacy and safety of once-weekly and twice-weekly bortezomib in patients with relapsed systemic AL amyloidosis: Results of a phase 1/2 study. Blood. 2011;**118**(4):865-873

[42] Kastritis E, Leleu X, Arnulf B, Zamagni E, Cibeira M, et al. A randomized phase III trial of melphalan and dexamethasone (MDex) versus bortezomib, melphalan and dexamethasone (BMDex) for untreated patients. Blood. 2016;**128**:646

[43] Lasek-Bal A, Holecki M, Czapska A, Karuga A, Dulawa J. Primary clinical manifestation of systemic amyloidosis in the central nervous system. Polskie Archiwum Medycyny Wewnętrznej. 2014;**124**(3):138-139

[44] Adav S, Gallart-Palau X, Tan K, Lim S, Tam J, et al. Dementia-linked amyloidosis is associated with brain protein deamidation as revealed by proteomic profiling of human brain tissues. Molecular Brain. 2016;**9**(20):1-10

[45] Banerjee G, Carare R, Cardonnier C, Greenberg S, Schneider J, et al. The increasing impact of cerebral amyloid angiopathy: Essential new insights for

clinical practice. Journal of Neurology, Neurosurgery, and Psychiatry. 2017;**88**(11):982-994

[46] Shin SC, Robinson-Papp J. Amyloid neuropathies. Mount Sinai Journal of Medicine: A Journal of Translational and Personalized Medicine. 2012;**79**(6):733-748

[47] Bard F, Cannon C, Barbour R, Burke R, medicine GD. Peripherally administered antibodies against amyloid β-peptide enter the central nervous system and reduce pathology in a mouse model of alzheimer disease. Nature. 2000;**6**:916-919

[48] Van Dyck C. Anti-amyloid-β monoclonal antibodies for Alzheimer's disease: Pitfalls and promise. Biological Psychiatry. 2018;**83**(4):311-319

[49] Coelho T, Adams D, Silva A, Lozeron P, Hawkins P, Mant T, et al. Safety and efficacy of RNAi therapy for transthyretin amyloidosis. NEJM. 2013;**369**:819-829

[50] Sekijima Y, Yazaki M, Oguchi K, Ezawa N, Yoshinaga T, Yamada M, et al. Cerebral amyloid angiopathy in posttransplant patients with hereditary ATTR amyloidosis. Neurology. 2016;**87**:1-9

[51] Suhr OB, Herlenius G, Friman S, Ericzon B. Liver transplantation for hereditary transthyretin amyloidosis. Liver Transplantation. 2000;**6**(3):263-276

[52] Merlini G, Ascari E, Amboldi N, Bellotti V, Arbustini E, Perfetti V, et al. Interaction of the anthracycline 4′-iodo-4′-deoxydoxorubicin with amyloid fibrils: Inhibition of amyloidogenesis. PNAS. 1995;**92**(7):2959-2963

[53] Cardoso I, Saraiva M. Doxycycline disrupts transthyretin amyloid: Evidence from studies in a FAP transgenic mice model. The FASEB Journal. 2006;**20**(2):234-239

[54] Obici L, Cortese A, Lozza A, Lucchetti J, Amyloid GM. Doxycycline plus tauroursodeoxycholic acid for transthyretin amyloidosis: a phase II Study. Amyloid: the international journal of experimental and clinical investigation. 2012;**19**(1):34-36

[55] Adams D, Gonzalez-Duarte A, O'Riordan WD, Yang C-C, Ueda M, Kristen AV, et al. Patisiran, an RNAi therapeutic, for hereditary transthyretin amyloidosis. New England Journal of Medicine. 2018;**379**(1):11-21

[56] Benson MD, Waddington-Cruz M, Berk JL, Polydefkis M, Dyck PJ, Wang AK, et al. Inotersen treatment for patients with hereditary transthyretin amyloidosis. New England Journal of Medicine. 2018;**379**(1):22-31

[57] Donnelly JP, Hanna M. Cardiac amyloidosis: An update on diagnosis and treatment. Cleveland Clinic Journal of Medicine. 2017;**84**(12 Suppl 3):12-26

[58] Maurer MS, Schwartz JH, Gundapaneni B, Elliott PM, Merlini G, Waddington-Cruz M, et al. Tafamidis treatment for patients with transthyretin amyloid cardiomyopathy. New England Journal of Medicine. 2018;**379**(11):1007-1016

[59] Mesquita E, Jorge A, Junior C, de Andrade T. Cardiac amyloidosis and its new clinical phenotype: Heart failure with preserved ejection fraction. Arquivos Brasileiros de Cardiologia. 2017;**109**(1):71-80

[60] Gertz MA, Falk RH, Skinner M, Cohen AS, Kyle RA. Worsening of congestive heart failure in amyloid heart disease treated by calcium channel-blocking agents. The American Journal of Cardiology. 1985;**55**(13):1645

[61] Pollak A, Falk RH. Left ventricular systolic dysfunction precipitated by verapamil in cardiac amyloidosis. Chest. 1993;**104**(2):618-620

[62] Patel K, Hawkins P. Cardiac amyloidosis: Where are we today? Journal of Internal Medicine. 2015;**278**(2):126-144

[63] Sipe JD, Benson MD, Buxbaum JN, Ikeda S, Merlini G, Saraiva MJ, et al. Amyloid fibril proteins and amyloidosis: Chemical identification and clinical classification International Society of Amyloidosis 2016 nomenclature guidelines. Amyloid. 2016;**4**:1-5

[64] Milani P, Basset M, Russo F, Foli A, Palladini G, Merlini G. The lung in amyloidosis. European Respiratory Review. 2017;**26**(145):170046

[65] Riek R, Eisenberg DS. The activities of amyloids from a structural perspective. Nature. 2016;**539**(7628):227-235

[66] Foli A, Palladini G, Caporali R, Verga L, Morbini P, Obici L, et al. The role of minor salivary gland patients. Amyloid. 2011;**18**(sup1):80-82

[67] de Larrea C, Verga L, Morbini P, Klersy C, Lavatelli F, Foli A, et al. A practical approach to the diagnosis of systemic amyloidoses. Blood. 2015;**125**(14):2239-2244

[68] Grogg KL, Aubry M-C, Vrana JA, Theis JD, Dogan A. Nodular pulmonary amyloidosis is characterized by localized immunoglobulin deposition and is frequently associated with an indolent B-cell lymphoproliferative disorder. The American Journal of Surgical Pathology. 2013;**37**(3):406

[69] Kaplan B, Martin BM, Boykov O, Gal R, Pras M, Shechtman I, et al. Co-deposition of amyloidogenic immunoglobulin light and heavy chains in localized pulmonary amyloidosis. Virchows Archiv. 2005;**447**(4):756-761

[70] Hui A, Koss M, Hochholzer L, Wehunt W. Amyloidosis presenting in the lower respiratory tract. Clinicopathologic, radiologic, immunohistochemical, and histochemical studies on 48 cases. Archives of Pathology & Laboratory Medicine. 1986;**110**(3):212-218

[71] Nivas R, Singh N, Gupta K, Gupta D. Pulmonary amyloidosis in Sjogren's syndrome: A case report and systematic review of the literature. Respirology. 2010;**15**(5):860-866

[72] BoydKing A, Sharma O, Stevenson K. Localized interstitial pulmonary amyloid: A case report and review of the literature. Current Opinion in Pulmonary Medicine. 2009;**15**(5):517

[73] Smith R, Hutchins GM, Moore GW, Humphrey RL. Type and distribution of pulmonary parenchymal and vascular amyloid correlation with cardiac amyloidosis. The American Journal of Medicine. 1979;**66**(1):96-104

[74] Park M-A, Padera RF, Belanger A, Dubey S, Hwang DH, Veeranna V, et al. 18F-Florbetapir binds specifically to myocardial light chain and transthyretin amyloid deposits. Circulation. Cardiovascular Imaging. 2018;**8**(8):e002954

[75] Ohdama S, Akagawa S, Matsubara O, Yoshizawa Y. Primary diffuse alveolar septal amyloidosis with multiple cysts and calcification. European Respiratory Journal. 1996;**9**(7):1569-1571

[76] Kyle RA, Gertz MA, Greipp PR, Witzig TE, Lust JA, Lacy MQ, et al. A trial of three regimens for primary amyloidosis: Colchicine alone, melphalan and prednisone, and melphalan, prednisone, and colchicine. New England Journal of Medicine. 1997;**336**(17):1202-1207

[77] Comenzo R, Vosburgh E, Falk R, Sanchorawala V, Reisinger J, Dubrey S, et al. Dose-intensive melphalan with blood stem-cell support for

the treatment of AL (amyloid light-chain) amyloidosis: Survival and responses in 25 patients. Blood. 1998;**91**(10):3662-3670

[78] Gillmore JD, Davies J, Iqbal A, Madhoo S, Russell NH, Hawkins PN. Allogeneic bone marrow transplantation for systemic AL amyloidosis. British Journal of Haematology. 1998;**100**(1):226-228

[79] Gertz M, Lacy M, Dispenzieri A, Kumar S, Dingli D, Leung N, et al. Refinement in patient selection to reduce treatment-related mortality from autologous stem cell transplantation in amyloidosis. Bone Marrow Transplantation. 2013;**48**(4):557

[80] Ware L, Keith F, Gordon R, Ries C, Seitz R, Gold W, et al. Lung transplantation for pulmonary amyloidosis: A case report. The Journal of Heart and Lung Transplantation. 1998;**17**(11):1129-1132

[81] Lewis JE, Olsen KD, Kurtin PJ, Kyle RA. Laryngeal amyloidosis: A clinicopathologic and Immunohistochemical review. Otolaryngology–Head and Neck Surgery. 1991;**106**(4):372-377

[82] Darcy F. Localized amyloidosis of the larynx. The Journal of Laryngology & Otology. 1972;**86**(9):929-931

[83] Walker PA, Courey MS, Ossoff RH. Staged endoscopic treatment of laryngeal amyloidosis. Otolaryngology–Head and Neck Surgery. 1996;**114**(6):801-805

[84] Finn DG, Farmer JC. Management of amyloidosis of the larynx and trachea. Archives of Otolaryngology. 1982;**108**(1):54-56

[85] Mcilwain J, Shepperd H. Laser treatment of primary amyloidosis of the larynx. The Journal of Laryngology & Otology. 1986;**100**(9):1079-1080

[86] Utz J, Swensen S, Gertz M. Pulmonary amyloidosis. The Mayo clinic experience from 1980 to 1993. Annals of Internal Medicine. 1996;**124**(4):407-413

[87] Graham C, Stern E, Finkbeiner W, Webb W. High-resolution CT appearance of diffuse alveolar septal amyloidosis. AJR American Journal of Roentgenology. 1992;**158**(2):265-267

[88] Crestani B, Monnier A, Kambouchner M, Battesti J, Reynaud P, Valeyre D. Tracheobronchial amyloidosis with hilar lymphadenopathy associated with a serum monoclonal immunoglobulin. The European Respiratory Journal. 1993;**6**(10):1569-1571

[89] O'Regan A, Fenlon HM, Beamis JF, Steele MP, Skinner M, Berk JL. Tracheobronchial amyloidosis: The Boston University experience from 1984 to 1999. Medicine. 2000;**79**(2):69

[90] Monroe AT, Walia R, Zlotecki RA, Jantz MA. Tracheobronchial amyloidosis a case report of successful treatment with external beam radiation therapy. Chest. 2004;**125**(2):784-789

[91] Neben-Wittich MA, Foote RL, Kalra S. External beam radiation therapy for tracheobronchial amyloidosis. Chest. 2007;**132**(1):262-267

[92] Botto M, Hawkins PN, Bickerstaff M, Herbert J, Bygrave AE, Mcbride A, et al. Amyloid deposition is delayed in mice with targeted deletion of the serum amyloid P component gene. Nature Medicine. 1997;**3**(8):nm0897-nm0855

[93] Kisilevsky R, Lemieux LJ, Fraser PE, Kong X, Hultin PG, Szarek WA. Arresting amyloidosis in vivo using small-molecule anionic sulphonates or sulphates: Implications for Alzheimer's disease. Nature Medicine. 1995;**1**(2):143