

We are IntechOpen, the world's leading publisher of Open Access books Built by scientists, for scientists

4,800

Open access books available

122,000

International authors and editors

135M

Downloads

Our authors are among the

154

Countries delivered to

TOP 1%

most cited scientists

12.2%

Contributors from top 500 universities



WEB OF SCIENCE™

Selection of our books indexed in the Book Citation Index
in Web of Science™ Core Collection (BKCI)

Interested in publishing with us?
Contact book.department@intechopen.com

Numbers displayed above are based on latest data collected.

For more information visit www.intechopen.com



Tips and Pitfalls in Robotic Mitral Valve Surgery

Takashi Murashita

Abstract

Robotic mitral valve repair is now routinely and safely performed all over the world. There are many literatures which showed advantages of reduced blood loss, lower risk of infection, lower risk of atrial fibrillation, shorter length of hospital stay, quicker return to normal activities, and a superior cosmetic result, compared with a conventional sternotomy. However, the introduction of new technique requires a learning curve even for expert mitral valve surgeons. There are complications specifically related to robotic mitral valve surgery, such as major vascular complications, inadequate myocardial protection, and unilateral pulmonary edema. The purpose of this chapter is to characterize the tips and pitfalls of robotic mitral valve repair and to discuss the controversial issues in the contemporary practice.

Keywords: robotic surgery, mitral valve repair, complication

1. Introduction

Since the introduction of robotic mitral valve repair in the late 1990s, the number of this procedure has been increasing worldwide. Many centers have reported excellent outcomes of robotic mitral valve repair [1–8]. In the beginning, it was mainly applied in selected patients with a simple repair case and relatively low risk cases. However, with the accumulation of surgical experience, the indication has been broadened to complicated repair cases or aged patients.

Wang et al. reviewed the Society of Thoracic Surgeons database and compared surgical outcomes of robotic and surgical mitral valve repair in patients aged 65 years and older [9]. They found that robotic mitral valve repair was associated with less postoperative atrial fibrillation, less blood transfusion, and shorter intensive care unit and hospital stay compared with surgical mitral valve repair without a difference in 3-year mortality, heart failure readmission, or mitral valve reintervention.

2. Tips and pitfalls

2.1 Applying to a robot platform

Robotic mitral valve repair is usually done thorough a right thoracotomy; thus, intra-thoracic pathology such as previous right thoracotomy, severe pulmonary dysfunction, and chest deformity can be a contraindication [10]. Patients at risk

for coronary artery disease should undergo a cardiac catheterization, and severe coronary artery disease requiring coronary artery bypass grafting is another contraindication of robotic mitral valve repair. In addition, significant pulmonary hypertension or severe right ventricular dysfunction is included to contraindications.

Usually, robotic mitral valve repair is done with a 5- to 6-cm right thoracotomy [11]. A specific attention should be paid for inserting robotic instruments into the right chest. The insertion of service ports can injure the right lung, vessels, diaphragm, liver, and mediastinal structures. **Figure 1** shows our regular setup for robotic instruments. The thoracotomy is made through fourth or fifth intercostal space. We carefully review the preoperative computer tomography and decide which intercostal space would give us the best exposure for mitral valve. The port for left arm is usually inserted through second or third intercostal space. The port for left atrial retractor is usually inserted through the same intercostal space with thoracotomy. The port for right arm is usually inserted through sixth or seventh intercostal space. The camera port is inserted one higher intercostal space than thoracotomy.

2.2 The interaction between the operator and the assistance

After the robotic instruments are inserted, the surgeon moves to the robotic console, and the assistant will move to the patient's right side and has an access to the operative field through the thoracotomy. From the console, the surgeons can perform precise movements inside the heart using the mechanical instruments. The mechanical instruments include forceps, scissors, needle holders, and electrocautery. The surgeons use two mechanical instruments, and the changes of the instruments were manipulated by the bedside assistant.

The role of the surgeon on console is to accomplish a mitral valve repair by cutting, suturing, and sizing with two mechanical instruments, whereas, the role of bedside assistant is suctioning the field, suture following, and knot tying. Since the operative field is very limited, the bedside assistant should be trained for knot-tying instruments.

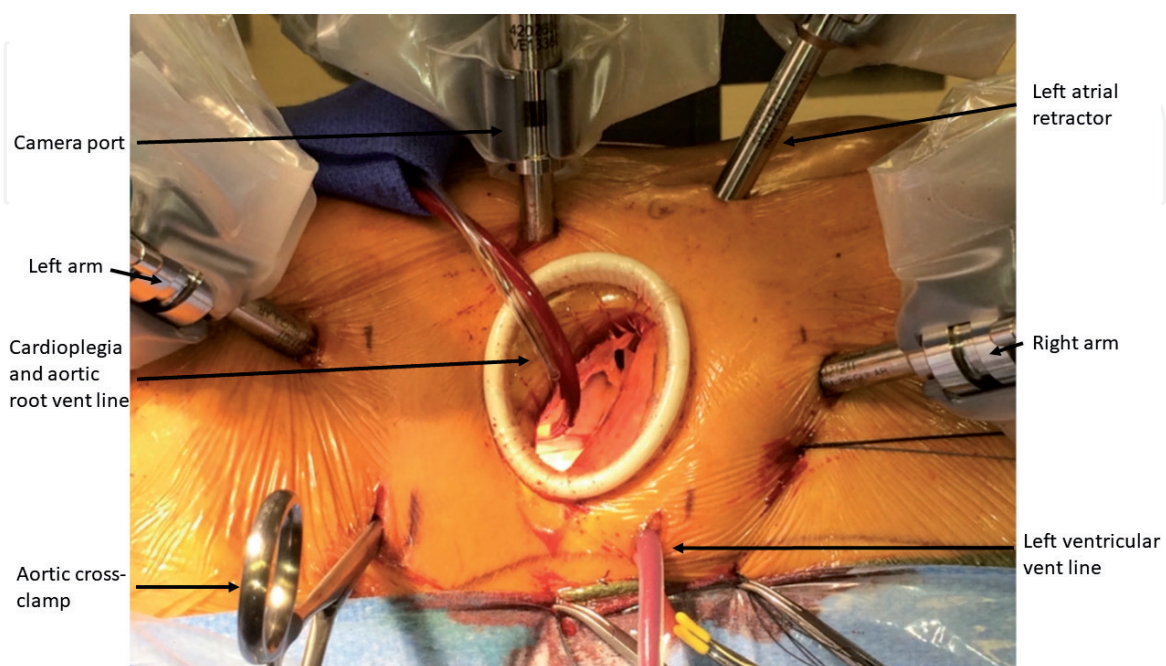


Figure 1.
The picture of a standard setup for robotic mitral valve surgery.

2.3 Establishment of a cardiopulmonary bypass

In a robotic mitral valve repair, cardiopulmonary bypass is established either via an antegrade perfusion with a central cannulation or via a retrograde perfusion with a peripheral cannulation. It is a controversy in which perfusion strategy is optimal [12].

Murzi et al. reviewed 1421 patients who underwent antegrade perfusion and 141 patients who underwent retrograde perfusion [13]. They reported that retrograde perfusion was associated with higher incidence of stroke than antegrade perfusion (3.5 vs. 1.1%). In the meantime, LaPietra et al. reviewed 1501 patients, and found that stroke rate was low (about 1.5%) regardless of cannulation technique [14]. Nowadays, several experienced centers routinely apply retrograde femoral perfusion during minimally invasive mitral valve surgery [1, 3, 6].

In establishing the peripheral cannulation, the venous drainage for cardiopulmonary bypass is obtained by a placement of cannula, usually via the right femoral vein and right internal jugular vein. It is essential to introduce cannula under a transesophageal echocardiography to avoid the risk of extravasation, migration of the cannula, or other types of complications [15]. Arterial cannula is usually inserted to the right femoral artery. It is also essential to obtain a preoperative multidetector computed tomography angiography for the assessment of aortoiliac atherosclerosis in order to plan an optimal surgical approach [16].

2.4 Aortic cross-clamp

For aortic cross-clamp, there are basically two options: endoaortic or transthoracic clamp (**Figure 2**). The endoaortic cross-clamp is performed with an

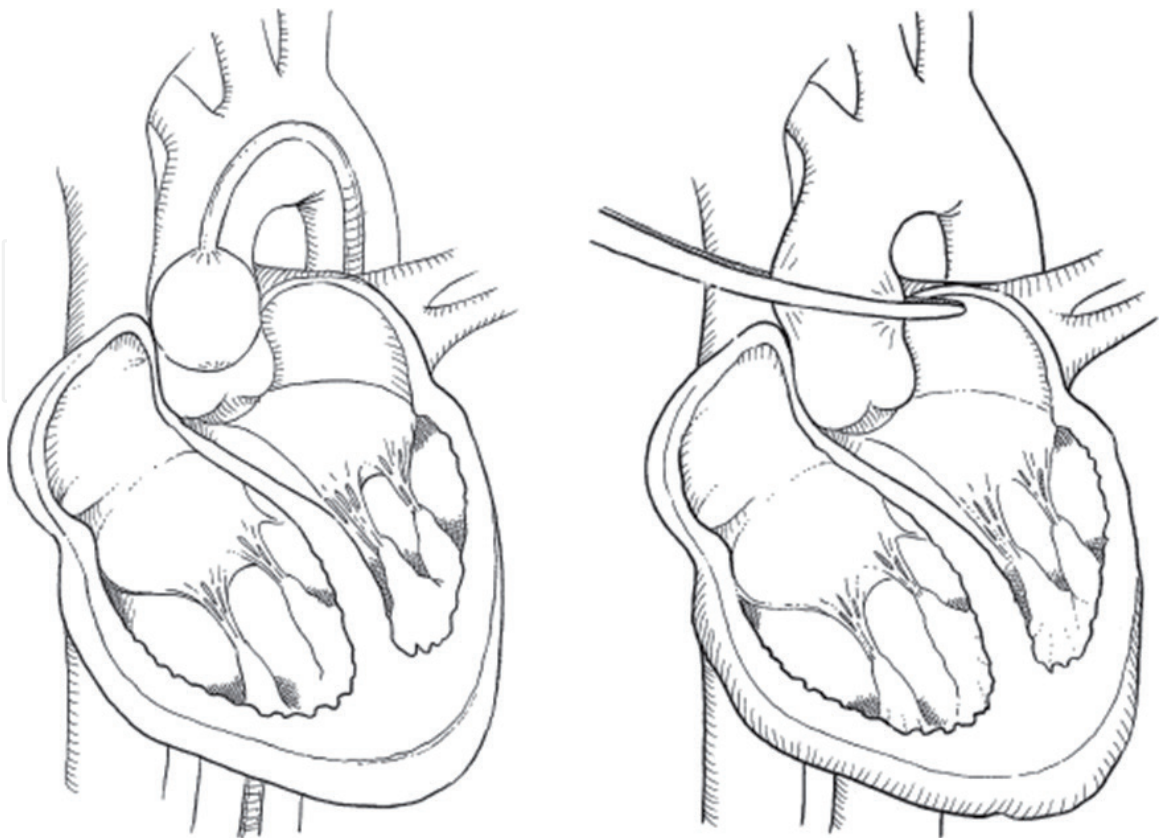


Figure 2.
Left: endoaortic cross-clamping with an endoaortic balloon. Right: transthoracic cross-clamping using a Chitwood clamp.

endoaortic balloon, which comprises a triple lumen catheter mostly introduced usually through a left femoral artery with an inflatable balloon at the tip. The central lumen is used for delivery of cardioplegia and aortic root vent. The remaining lumen is used for balloon inflation and deflation as well as pressure monitoring. The transthoracic clamp is called Chitwood clamp, and is introduced through the intercostal space and positioned around the aorta.

Maselli et al. monitored embolic events with a transcranial Doppler during minimally invasive mitral valve surgery, and found that brain embolism occurred predominantly at the time of ascending aorta clamping and declamping with an endoaortic balloon [17]. In the meantime, the application of an external cross-clamp to the ascending aorta may cause the embolic events and traumatic injury.

The superiority between two methods of aortic cross-clamp has been controversial.

Kowalewski et al. performed a meta-analysis of observational studies [18]. They found that there was no difference of cerebrovascular events, all-cause mortality, and kidney injury between endoaortic and transthoracic cross-clamp; however, endoaortic balloon occlusion was associated with a higher risk of iatrogenic aortic dissection (0.93 vs. 0.13%) and higher risk of leg ischemia (0.47 vs. 0.20%) than transthoracic cross-clamp.

Kesavuori et al. reported their initial 5-year results of robotic mitral valve repairs [19]. The postoperative complications included conversion to sternotomy, reoperations for bleeding, and low cardiac output states requiring extracorporeal membrane oxygenation. They reported that early major robotic complications were related to the use of endoaortic balloon occlusion.

In the meantime, Barbero et al. reviewed three centers' experience of minimally invasive mitral valve surgery, and did not find differences in respiratory failure, major vascular complication, stroke, and in-hospital mortality between endoaortic and transthoracic aortic clamping [20].

2.5 Myocardial protection

Although several ways of myocardial protection have been advocated in minimally invasive mitral valve surgery, the optimal method has been controversial. There is a choice of antegrade or retrograde, intermittent or continuous, and crystalloid or blood cardioplegia.

One of the earliest approaches were antegrade cardioplegia via the endoaortic balloon, as described in the "aortic cross-clamp." Lebon et al. compared 118 patients undergoing minimally invasive mitral valve surgery and 118 patients undergoing open mitral valve surgery, and found no difference in the incidence of difficult weaning from bypass and intra-aortic balloon pump use between two groups [21].

When applying transthoracic cross-clamp, direct cardioplegia insertion into the ascending aorta through a long antegrade cardioplegia catheter is necessary. As the insertion site of cardioplegia catheter gets far in the thoracotomy, the insertion and decannulation of the catheter can be associated with higher risk of bleeding than sternotomy.

In the setting of aortic insufficiency, retrograde cardioplegia might be desirable. Retrograde cardioplegia can be performed by placement of a percutaneous coronary sinus catheter via the internal jugular vein, but that requires specialized skills with an increased cost of a specialized catheter. In addition, the retrograde cardioplegia catheter insertion can cause catheter displacement, coronary sinus rupture, and inadequate protection of the right ventricle [22]. Another option of retrograde cardioplegia is to directly insert a catheter through a purse-string in the right atrium under a transesophageal echocardiography.

There are two types of cardioplegia solution: crystalloid and blood. Blood cardioplegia is usually chosen in the open-heart surgery, as it has two advantages over pure crystalloid cardioplegia. First, blood cardioplegia can deliver oxygen to the myocardium, and secondly, the additional crystalloid volume is small; thus, hemodilution or myocardial edema can be avoided. Therefore, some centers still use blood cardioplegia in minimally invasive mitral valve surgery.

However, some centers prefer crystalloid-based cardioplegia: histidine-tryptophan-ketoglutarate cardioplegia [19, 23]. The advantage of this cardioplegia is that a single antegrade shot can maintain adequate myocardial protection up to 2 hours; thus, potentially aortic cross-clamp time and cardiopulmonary bypass time can be reduced.

2.6 Unilateral pulmonary edema

Unilateral pulmonary edema is known as an uncommon, but frequently lethal complication following minimally invasive robotic cardiac surgery. The clinical presentation of this condition includes severe right lung edema developing within the first several minutes to hours after coming off from a cardiopulmonary bypass (**Figure 3**), which leads to profound hypoxia, hypercapnia, pulmonary hypertension, and hemodynamic instability.

The mechanism of this condition is yet to be fully understood. Lung deflation is shown to be associated with the sequestration of inflammatory response. Minamiya et al. reported that during atelectasis, polymorphonuclear leukocytes accumulate in

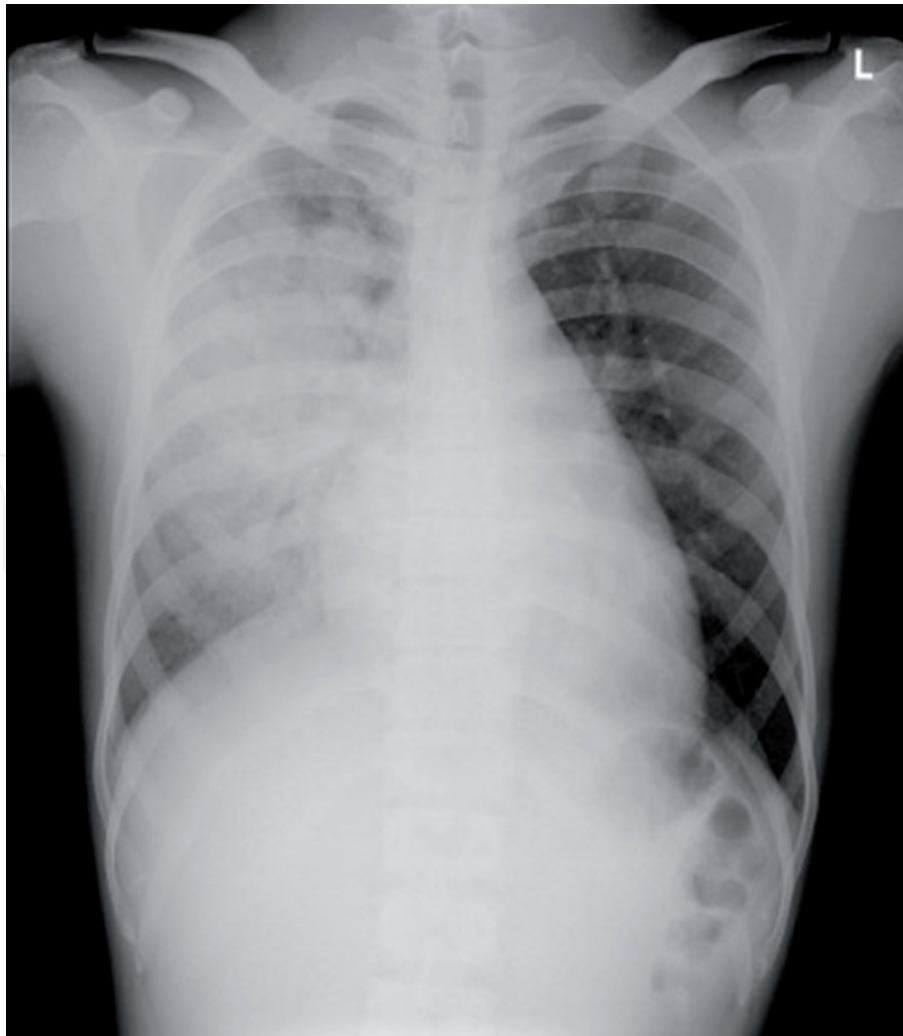


Figure 3.
A typical chest X-ray imaging showing unilateral pulmonary edema on the right side.

the lung, and after pulmonary reexpansion, polymorphonuclear leukocytes respiratory bursting occurs [24]. The inflammatory response may be aggravated by the use of cardiopulmonary bypass. It is reported that prolonged cardiopulmonary bypass time and lung collapse are associated with the occurrence of unilateral pulmonary edema. Other factors such as obesity and intraoperative blood product use may affect the inflammatory response.

Renner et al. reviewed their 256 patients who underwent minimally invasive mitral valve surgery, and they encountered five cases (2.0%) of unilateral pulmonary edema, which required postoperative extracorporeal membrane oxygenation; two of them had in-hospital mortality [25]. They reported that preoperative high C-reactive protein and long cardiopulmonary bypass time were associated with the occurrence of unilateral pulmonary edema.

Irisawa et al. reviewed 381 patients who underwent minimally invasive cardiac surgery, and found 8 (2.1%) patients developed unilateral pulmonary edema [26]. They reported that preoperative use of steroid or immunosuppressive drugs and prolonged aortic cross-clamp time were the risk factors for unilateral pulmonary edema.

Keyl et al. reported that the use of dexamethasone significantly reduced the incidence of unilateral pulmonary edema from 12.9 to 4.0% [27]. Moss et al. reported their modifications to the robotic mitral valve repair technique in an effort to reduce the incidence of unilateral pulmonary edema [28]. They hypothesized that unilateral pulmonary edema results from severe right lung ischemia due to insufficient bronchial artery flow. Their modifications were focused on right lung oxygen supply, and included minimization of right lung deflation before cardiopulmonary bypass, infusion of unheated CO₂ into the right chest, active cooling to low systemic temperature, maintaining high mean arterial pressure during cardiopulmonary bypass, and restoration of right lung ventilation was early as possible.

3. Conclusions

Although many reports demonstrated the efficacy and safety of robotic mitral valve repair, there are some specific pitfalls, which surgeons do not encounter in a conventional open heart surgery. In order to achieve a good success of robotic mitral valve repair, surgeons need to understand these particular issues and avoid robotic-related complications.

Author details

Takashi Murashita

University of Missouri, One Hospital Drive, Columbia, Missouri, USA

*Address all correspondence to: tmurashita@gmail.com

IntechOpen

© 2019 The Author(s). Licensee IntechOpen. This chapter is distributed under the terms of the Creative Commons Attribution License (<http://creativecommons.org/licenses/by/3.0>), which permits unrestricted use, distribution, and reproduction in any medium, provided the original work is properly cited. 

References

- [1] Gillinov AM, Mihaljevic T, Javadikasgari H, Suri RM, Mick SL, Navia JL, et al. Early results of robotically assisted mitral valve surgery: Analysis of the first 1000 cases. *The Journal of Thoracic and Cardiovascular Surgery*. 2018;**155**:82-91. DOI: 10.1016/j.jtcvs.2017.07.037
- [2] Javadikasgari H, Suri RM, Tappuni B, Lowry AM, Mihaljevic T, Mick S, et al. Robotic mitral valve repair for degenerative posterior leaflet prolapse. *Annals of Cardiothoracic Surgery*. 2017;**6**:27-32. DOI: 10.21037/acs.2017.01.07
- [3] Kim HJ, Kim JB, Jung SH, Lee JW. Clinical outcomes of robotic mitral valve repair: A single-center experience in Korea. *Annals of Cardiothoracic Surgery*, 2017;**6**:9-16. DOI: 10.21037/acs.2016.10.02
- [4] Mihaljevic T, Jarrett CM, Gillinov AM, Williams SJ, DeVilliers PA, Stewart WJ, et al. Robotic repair of posterior mitral valve prolapse versus conventional approaches: Potential realized. *The Journal of Thoracic and Cardiovascular Surgery*. 2011;**141**:72-80. DOI: 10.1016/j.jtcvs.2010.09.008
- [5] Navarra E, Mastrobuoni S, De Kerchove L, Glineur D, Watremez C, Van Dyck M, et al. Robotic mitral valve repair: A European single-centre experience. *Interactive Cardiovascular and Thoracic Surgery*. 2017;**25**:62-67. DOI: 10.1093/icvts/ivx060
- [6] Ramzy D, Trento A, Cheng W, De Robertis MA, Mirocha J, Ruzza A, et al. Three hundred robotic-assisted mitral valve repairs: The cedars-Sinai experience. *The Journal of Thoracic and Cardiovascular Surgery*. 2014;**147**:228-235. DOI: 10.1016/j.jtcvs.2013.09.035
- [7] Suri RM, Taggarse A, Burkhart HM, Daly RC, Mauermann W, Nishimura RA, et al. Robotic mitral valve repair for simple and complex degenerative disease: Midterm clinical and echocardiographic quality outcomes. *Circulation*. 2015;**132**:1961-1968. DOI: 10.1161/CIRCULATIONAHA.115.017792
- [8] Murphy DA, Moss E, Binongo J, Miller JS, Macheers SK, Sarin EL, et al. The expanding role of endoscopic robotics in mitral valve surgery: 1,257 consecutive procedures. *The Annals of Thoracic Surgery*. 2015;**100**:1675-1681. DOI: 10.1016/j.athoracsur.2015.05.068
- [9] Wang A, Brennan JM, Zhang S, Jung SH, Yerokun B, Cox ML, et al. Robotic mitral valve repair in older individuals: An analysis of the Society of Thoracic Surgeons database. *The Annals of Thoracic Surgery*. 2018;**106**:1388-1393. DOI: 10.1016/j.athoracsur.2018.05.074
- [10] Suri RM, Dearani JA, Mihaljevic T, Chitwood WR Jr, Murphy DA, Trento A, et al. Mitral valve repair using robotic technology: Safe, effective, and durable. *The Journal of Thoracic and Cardiovascular Surgery*. 2016;**151**:1450-1454. DOI: 10.1016/j.jtcvs.2016.02.030
- [11] Nifong LW, Chitwood WR, Pappas PS, Smith CR, Argenziano M, Starnes VA, et al. Robotic mitral valve surgery: A United States multicenter trial. *The Journal of Thoracic and Cardiovascular Surgery*. 2005;**129**:1395-1404
- [12] Badhwar V. Are we going backwards or forwards in minimally invasive mitral valve surgery? Three eras of perfusion strategy. *Seminars in Thoracic and Cardiovascular Surgery*. 2015;**27**:104-105. DOI: 10.1053/j.semtcvs.2015.09.002
- [13] Murzi M, Cerillo AG, Gasbarri T, Margaryan R, Kallushi E, Farneti P, et al. Antegrade and retrograde

perfusion in minimally invasive mitral valve surgery with transthoracic aortic clamping: A single-institution experience with 1632 patients over 12 years. *Interactive Cardiovascular and Thoracic Surgery*. 2017;**24**:363-368. DOI: 10.1093/icvts/ivw370

[14] LaPietra A, Santana O, Mihos CG, DeBeer S, Rosen GP, Lamas GA, et al. Incidence of cerebrovascular accidents in patients undergoing minimally invasive valve surgery. *The Journal of Thoracic and Cardiovascular Surgery*. 2014;**148**:156-160. DOI: 10.1016/j.jtcvs.2013.08.016

[15] Rehfeldt KH, Andre JV, Ritter MJ. Anesthetic considerations in robotic mitral valve surgery. *Annals of Cardiothoracic Surgery*. 2017;**6**:47-53. DOI: 10.21037/acs.2017.01.10

[16] Moodley S, Schoenhagen P, Gillinov AM, Mihaljevic T, Flamm SD, Griffin BP, et al. Preoperative multidetector computed tomography angiography for planning of minimally invasive robotic mitral valve surgery: Impact on decision making. *The Journal of Thoracic and Cardiovascular Surgery*. 2013;**146**:262-268. DOI: 10.1016/j.jtcvs.2012.06.052

[17] Maselli D, Pizio R, Musumeci F. Multifrequency transcranial Doppler for intraoperative automatic detection and characterisation of cerebral microemboli during port-access mitral valve surgery. *Interactive Cardiovascular and Thoracic Surgery*. 2006;**5**:32-35

[18] Kowalewski M, Malvindi PG, Suwalski P, Raffa GM, Pawliszak W, Perlinski D, et al. Clinical safety and effectiveness of endoaortic as compared to transthoracic clamp for small thoracotomy mitral valve surgery: Meta-analysis of observational studies. *The Annals of Thoracic Surgery*. 2017;**103**:676-686. DOI: 10.1016/j.athoracsur.2016.08.072

[19] Kesävuori R, Raivio P, Jokinen JJ, Sahlman A, Teittinen K, Vento A. Early experience with robotic mitral valve repair with intra-aortic occlusion. *The Journal of Thoracic and Cardiovascular Surgery*. 2018;**155**:1463-1471. DOI: 10.1016/j.jtcvs.2017.10.076

[20] Barbero C, Krakor R, Bentala M, Casselman F, Candolfi P, Goldstein J, et al. Comparison of endoaortic and transthoracic aortic clamping in less-invasive mitral valve surgery. *The Annals of Thoracic Surgery*. 2018;**105**:794-798. DOI: 10.1016/j.athoracsur.2017.09.054

[21] Lebon JS, Couture P, Fortier A, Rochon AG, Ayoub C, Viens C, et al. Myocardial protection in mitral valve surgery: Comparison between minimally invasive approach and standard Sternotomy. *Journal of Cardiothoracic and Vascular Anesthesia*. 2018;**32**:656-663. DOI: 10.1053/j.jvca.2017.08.040

[22] Bainbridge D, Fernandes P, Chu MWA. Cardioplegia during minimally invasive mitral valve surgery, a team approach. *Journal of Cardiothoracic and Vascular Anesthesia*. 2018;**32**:664-665. DOI: 10.1053/j.jvca.2017.10.012

[23] Garbade J, Davierwala P, Seeburger J, Pfannmueller B, Misfeld M, Borger MA, et al. Myocardial protection during minimally invasive mitral valve surgery: Strategies and cardioplegic solutions. *Annals of Cardiothoracic Surgery*. 2013;**2**:803-808. DOI: 10.3978/j.issn.2225-319X.2013.09.04

[24] Minamiya Y, Saito H, Takahashi N, Kawai H, Ito M, Hosono Y, et al. Polymorphonuclear leukocytes are activated during atelectasis before lung reexpansion in rat. *Shock*. 2008;**30**:81-86. DOI: 10.1097/SHK.0b013e31815dd221

[25] Renner J, Lorenzen U, Borzikowsky C, Schoeneich F, Cremer J,

Haneya A, et al. Unilateral pulmonary oedema after minimally invasive mitral valve surgery: A single-centre experience. *European Journal of Cardio-Thoracic Surgery*. 2018;**53**:764-770. DOI: 10.1093/ejcts/ezx399

[26] Irisawa Y, Hiraoka A, Totsugawa T, Chikazawa G, Nakajima K, Tamura K, et al. Re-expansion pulmonary oedema after minimally invasive cardiac surgery with right mini-thoracotomy. *European Journal of Cardio-Thoracic Surgery*. 2016;**49**:500-505. DOI: 10.1093/ejcts/ezv089

[27] Keyl C, Staier K, Pingpoh C, Pache G, Thoma M, Günkel L, et al. Unilateral pulmonary oedema after minimally invasive cardiac surgery via right anterolateral minithoracotomy. *European Journal of Cardio-Thoracic Surgery*. 2015;**47**:1097-1102. DOI: 10.1093/ejcts/ezu312

[28] Moss E, Halkos ME, Binongo JN, Murphy DA. Prevention of unilateral pulmonary edema complicating robotic mitral valve operations. *The Annals of Thoracic Surgery*. 2017;**103**:98-104. DOI: 10.1016/j.athoracsur.2016.05.100

IntechOpen