

# We are IntechOpen, the world's leading publisher of Open Access books Built by scientists, for scientists

**4,800**

Open access books available

**122,000**

International authors and editors

**135M**

Downloads

Our authors are among the

**154**

Countries delivered to

**TOP 1%**

most cited scientists

**12.2%**

Contributors from top 500 universities



**WEB OF SCIENCE™**

Selection of our books indexed in the Book Citation Index  
in Web of Science™ Core Collection (BKCI)

Interested in publishing with us?  
Contact [book.department@intechopen.com](mailto:book.department@intechopen.com)

Numbers displayed above are based on latest data collected.

For more information visit [www.intechopen.com](http://www.intechopen.com)



# Distal Cholangiocarcinoma

*Ahmad Abdullah Madkhali and Faisal Al-alem*

## Abstract

Cholangiocarcinoma arises from the epithelial lining of the biliary tree. It accounts for approximately 3% of all gastrointestinal malignancies. This chapter looks at the new advances that have been made in the management of distal cholangiocarcinoma, based on a literature review. Diagnosis of the disease resides mainly in clinical presentation and radiological diagnosis and biopsy indicated in selected cases. Surgical resection is the main curative treatment for distal cholangiocarcinoma, and resectability of the tumor can now be assessed using multiple radiological imaging studies. Resection margins and lymph node invasion status are the two important prognostic factors after surgery. Pancreaticoduodenectomy is the standard surgical treatment of choice in distal cholangiocarcinoma; however, combined major vascular and hepatopancreaticoduodenectomy can be indicated in selected cases. Adjuvant therapy is clearly indicated after surgical resection with survival improvement, but optimal adjuvant treatment strategy has not yet been established.

**Keywords:** cholangiocarcinoma, bile duct cancer, pancreaticoduodenectomy

## 1. Introduction

Cholangiocarcinoma arises from the epithelial lining of the biliary tree. Given the biliary tree anatomical differences and diversity, biliary tree cancers are most commonly classified according to their location into intrahepatic and extrahepatic cholangiocarcinomas, which are further classified into perihilar and distal type. Over all, these malignancies account for approximately 3% of all gastrointestinal malignancies [1]. Perihilar cholangiocarcinoma accounts for 50% of them, followed by distal cholangiocarcinoma (40%), and the remainder is intrahepatic disease [2].

Cholangiocarcinoma can also be classified based on its macroscopic growth pattern into three types: mass-forming exophytic type, periductal infiltrative type, or intraductal polypoid type. For distal cholangiocarcinoma, the periductal infiltrative type is the most common macroscopic growth pattern identified [3].

## 2. Staging and survival

Over all, biliary malignancies have poor prognosis. Surgical resection is the mainstay of treatment and it is possible only for localized disease without distant spread. The resection rate of bile duct cancer is different based on its location, and distal bile duct cancer has the highest respectability rate among other types [4]. In distal bile duct cancer, patients usually manifest jaundice early in the disease course

and likely seek medical care prior to metastasis development. Lymph node involvement, perineural invasion, lymphatic invasion, vascular invasion, and pancreatic invasion in addition to tumor depth of invasion are important prognostic factors and correlated with survival [5–8]. However, achieving negative resection margins is proposed to be the single most important predictor of survival [8]. The 8th AJCC UICC 2017 categorized cholangiocarcinoma based on its location in intrahepatic,

<b>Primary tumor (T)</b>			
<b>T category</b>	<b>T criteria</b>		
TX	Primary tumor cannot be assessed		
Tis	Carcinoma in situ/high-grade dysplasia		
T1	Tumor invades the bile duct wall with a depth less than 5 mm		
T2	Tumor invades the bile duct wall with a depth of 5–12 mm		
T3	Tumor invades the bile duct wall with a depth greater than 12 mm		
T4	Tumor involves the celiac axis, superior mesenteric artery, and/or common hepatic artery		
<b>Regional lymph nodes (N)</b>			
<b>N category</b>	<b>N criteria</b>		
NX	Regional lymph nodes cannot be assessed		
N0	No regional lymph node metastasis		
N1	Metastasis in one to three regional lymph nodes		
N2	Metastasis in four or more regional lymph nodes		
<b>Distant metastasis (M)</b>			
<b>M category</b>	<b>M criteria</b>		
M0	No distant metastasis		
M1	Distant metastasis		
<b>Prognostic stage groups</b>			
<b>When T is...</b>	<b>And N is...</b>	<b>And M is...</b>	<b>Then the stage group is...</b>
Tis	N0	M0	0
T1	N0	M0	I
T1	N1	M0	IIA
T1	N2	M0	IIIA
T2	N0	M0	IIA
T2	N1	M0	IIB
T2	N2	M0	IIIA
T3	N0	M0	IIB
T3	N1	M0	IIB
T3	N2	M0	IIIA
T4	N0	M0	IIIB
T4	N1	M0	IIIB
T4	N2	M0	IIIB
Any T	Any N	M1	IV

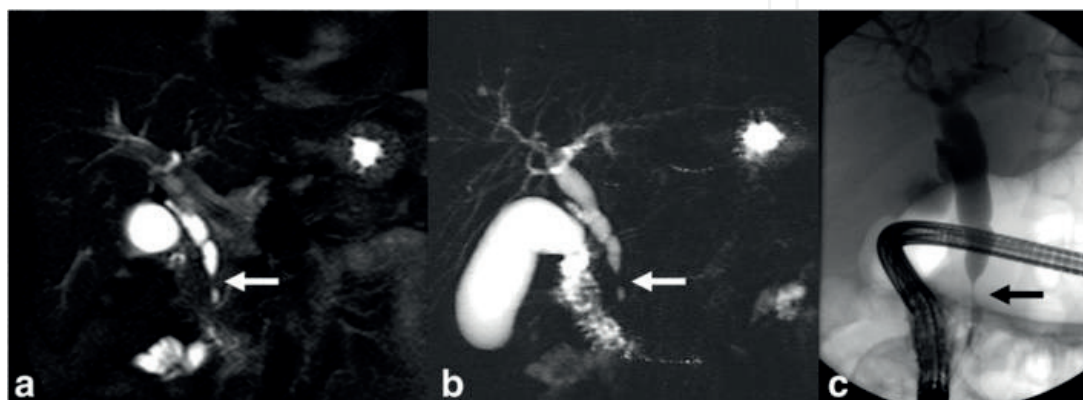
**Table 1.** Distal bile duct cancer TNM staging AJCC UICC 2017 [12].

hilar, and distal type and provided separate staging system for each one. The recent changes in distal CBD cancer designated the T level according to the depth of invasion rather than invaded structures, and N stage would include the number of involved lymph nodes rather than being involved or not. N1 will be given for involvement of 1–3 lymph nodes and N2 for the involvement of 4 and more lymph nodes **Table 1**. These changes improved the survival stratification between the stages based on the TNM stage [9, 10]. The overall 5-year survival of stages I, II, and III was 59.0, 35.4, and 14.7%, respectively [10].

### 3. Clinical presentation and diagnosis

The typical presentation of distal cholangiocarcinoma is painless jaundice in patients in the 5th–7th decade of life, while 10% of patients will have cholangitis as their initial presentation. A total of 56% of patients will present with constitutional symptom of malignancy like anorexia, fatigue, and weight loss [11]. Serum biochemical testing will show cholestatic jaundice pattern with elevated alkaline phosphatase, gamma-glutamyl transpeptidase and bilirubin levels. CA 19-9 is a tumor marker used in the workup of bile duct cancer. It has low sensitivity and specificity for cholangiocarcinoma, and it can also be elevated in biliary obstruction of benign disease. CA 19-9 seems to be correlated with prognosis and stage of the disease [12, 13], but its role as a diagnostic test is limited.

Cross sectional, enhanced contrast imaging is essential diagnostic modality in patients with distal cholangiocarcinoma, and it should be obtained before biliary intervention since its accuracy will be diminished after stent as a result of decompression, image artifact, or as consequence of local complication to the biliary intervention [14, 15]. Cholangiocarcinoma may be seen as stricture (**Figure 1**) in periductal infiltrative type or mass forming lesion in intraductal polypoid type or exophytic type. High resolution CT can identify biliary dilatation, tumor extent, and its relationship with the vascular system and adjacent organ, anatomical variation, lymphadenopathy, and distant metastasis. Periductal infiltrative type may manifest as thickened bile duct wall, which is often seen on CT as hypoattenuated on portovenous and hyperattenuated on delayed phase [16, 17]. Magnetic resonance imaging (MRI) with magnetic resonance cholangiopancreatography (MRCP) is a noninvasive modality that is competent to provide cholangiography for assessing the extent of bile duct extension and considered the preferred imaging for the diagnosis of suspected cholangiocarcinoma. Utilizing the high soft tissue contrasts and multiplanar capability, it is better at detecting infiltrative ductal tumor and its



**Figure 1.** Distal cholangiocarcinoma. Images showing narrowing segment in distal common bile duct (stricture) (arrow) with proximal biliary dilatation in coronal T2-weighted image (a), MRCP (b), and ERCP (c) [20].

local extent of tumor, biliary anatomy, invasion to surrounding structure, and liver metastasis. However, it is inferior to high resolution CT for vascular involvement and distant metastasis [18–21]. Infiltrating periductal cholangiocarcinoma can be identified on MRI as irregular wall thickening of bile duct, with proximal biliary dilatation, which enhances gradually to peak on delayed image, while intraductal polypoid type is typically identified as enhancing intraductal mass with proximal biliary dilation [22, 23]. MRCP is an essential noninvasive cholangiography to evaluate the longitudinal tumor extension in the bile duct proximal and distal to the obstruction and provides valuable preoperative biliary mapping [24]. It has higher sensitivity, specificity, and accuracy in differentiating benign from malignant biliary obstruction compared to ERCP [24].

Cholangiocarcinoma can be evaluated also by direct cholangiography with endoscopic retrograde cholangiopancreatography (ERCP) (**Figure 1**) or percutaneous transhepatic cholangiography (PTC), which typically present as dominant stricture or filling defect. They can delineate biliary anatomy and determine the level of bile duct involvement, which will help to identify resectability and surgical planning. It also allows for bile sampling for brush cytology and relieves the biliary obstruction. The diagnostic yield of cytology has a low sensitivity of 42% but a high specificity of 98% and a positive predictive value of 98% of patients who had cancers [25]. The sensitivity of brush cytology can be improved further more to 46–68% by using fluorescence in situ hybridization (FISH) to detect cancerous epithelial cells [26, 27]. EUS is an important diagnostic tool in the evaluation of distal biliary obstruction because it is very specific in predicting unresectability [28], and it is challenging some time to differentiate distal cholangiocarcinoma from other periampullary tumors based on other diagnostic modality. It helps to assess the extrahepatic biliary system, regional lymph node, and local extension to adjacent structure [24, 29]. It can also detect small lesions that were missed by another modality [28]. The sensitivity and specificity of EUS in detecting malignant biliary stricture are reported to be, in meta-analysis, 78 and 84%, respectively [30]. EUS also facilitates FNA cytology assessment which will increase the diagnostic yield of EUS. Recent meta-analysis found that EUS-FNA has a sensitivity of 80% and a specificity of 97% for diagnosing malignant biliary stricture [31].

The diagnostic algorithm is controversial in the literature, and it depends on institutional availability and experience of different diagnostic modalities. However, a general concept in evaluating distal cholangiocarcinoma is to determine tumor resectability, by assessing local extension of the tumor and its relationship with adjacent organs including vascular structure and presence of distant metastasis, and biliary tree mapping to assess longitudinal tumor extension. Cross-sectional, enhanced contrast imaging with MRI and/or CT with MRCP is the preferred diagnostic modality [32, 33] for assessing bile duct cancer. Direct cholangiography with ERCP/PTC is necessary in unresectable patients or in patients who need therapeutic intervention [33]. For patients with resectable disease, preoperative pathological diagnosis is not necessary [32, 33], especially in highly suspicious cases of malignant biliary obstruction, since diagnostic yield of preoperative tissue biopsy is low and cannot rule out malignancy. In patients with unresectable disease or when the diagnosis is not clear, then, biopsy is indicated. Serum IgG4 should also be considered if diagnosis is not clear because IgG4-associated cholangitis may present with jaundice and stricture, mimicking cholangiocarcinoma [33]. Preoperative biliary drainage is definitely indicated in patients with acute cholangitis or if patients will have delayed surgery for preoperative optimization [15, 24]. Preoperative routine drainage is not preferred owing to increased postoperative complication with no added benefit compared to no drainage [34, 35].

## 4. Surgical treatment

Surgical resection with curative intent is the only cure for distal cholangiocarcinoma. In most cases, pancreaticoduodenectomy is the surgical procedure for periampullary tumors, including distal cholangiocarcinoma. The goal of curative resection is to resect the tumor and regional lymph node with negative resection margin [36, 37]. Achieving a precise review of imaging to assess local extension of the tumor, lymph node, proximal ductal involvement, and presence of distant metastasis is an essential step in surgical planning to reach to the best outcome. The presence of peritoneal or distant metastasis (lung, liver, bone, or paraaortic lymph node) considered a contraindication for surgery [38, 39]. En-bloc major vascular resection may be necessary to achieve complete oncologic resection and does not preclude curative resection. Portal vein and/or hepatic artery resection and reconstruction are indicated if the tumor is locally advanced and invading them. Pancreaticoduodenectomy combined with vascular resection is reported to be a feasible technique with acceptable mortality, morbidity, and survival benefit [40].

Lymph node metastasis is an independent predictor for poor survival in distal cholangiocarcinoma [41]. Adequate lymphadenectomy for regional lymph node is important for complete oncologic resection, staging purpose, and planning of postoperative adjuvant therapy. Regional lymph node of distal bile duct is defined to be the lymph node along the porta hepatis, hepatic artery, anterior and posterior to the head of pancreas, and the lymph node along superior mesenteric artery [42].

Resection margin status of bile duct is highly correlated with survival in cholangiocarcinoma. Adequate assessment of the biliary system before any surgical planning is a critical step to achieve negative resection margin. Identification of the proximal extent of the disease helps to define the level of proximal resection and identify the patients who need a more extensive procedure to undergo preoperative optimization. Patients who have extensive periductal infiltration into the intrahepatic biliary duct may benefit from hepatopancreaticoduodenectomy (HPD) and should not be precluded from curative resection [33]. It is considered aggressive surgical resection for extrahepatic cholangiocarcinoma; however, with the improvement in surgical techniques and perioperative care, the postoperative mortality improved, compared to early experience, and it demonstrated favorable survival once the negative resection margin was achieved [43]. This procedure may be justified in well-selected and prepared patients, which may include perioperative biliary drainage and portal vein embolization to augment future liver remnant hypertrophy, with advanced cholangiocarcinoma [44]. Intraoperative frozen section of the proximal duct margin is required to assess margin status, and further re-resection is indicated when it is feasible to achieve negative resection margin. However, sometimes, the frozen section is repeatedly positive and no more extrahepatic bile duct to be excised, which conveys a challenging situation. If the frozen section report is carcinoma in situ, then no resection is required because it has comparable oncologic outcome with negative resection margin [45, 46], but if the frozen section is positive for invasive cancer, then unplanned hepatopancreaticoduodenectomy (HPD) may be indicated in selected cases. Minor or major central liver resection in this situation can help to achieve negative resection margin and preserve functional liver parenchyma, especially in those patients who are not well prepared for major hepatectomy, with no decreased long-term survival been reported in hilar cholangiocarcinoma literature. Left hepatectomy can also be an option in cases with left hepatic duct only involvement, because it reserves more future liver remnant in comparison to right hepatectomy or trisegmentectomy [47, 48]. However, it is a comorbid procedure, and risks and benefits should critically be evaluated and balanced before attempting liver resection in this situation.

After curative resection, the risk of recurrence dictates the need for additional treatment modality to improve disease-free and overall survival. The role of adjuvant therapy in cholangiocarcinoma is not yet agreed on because most of these studies combine different types of hepatobiliary cancers and nonrandomized studies. However, the available data, including randomized trial, showed survival benefit and suggested that chemotherapy can decrease the risk of distant recurrences while radiotherapy or chemoradiation can reduce the risk of local recurrence [49]. This survival benefit is clearly observed in patients with lymph node positive and/or margin positive although an optimal adjuvant treatment strategy has not yet been established [32, 33]. The suggested treatment options by NCCN guidelines are fluoropyrimidine-based or gemcitabine-based chemotherapy or fluoropyrimidine chemoradiation followed by additional fluoropyrimidine or gemcitabine chemotherapy [33].

## **5. Advanced cholangiocarcinoma**

Advanced distal cholangiocarcinoma, including locally advanced or metastatic, has overall poor prognosis. Most of them have obstructive jaundice due to biliary obstruction and they may also experience pruritus, pain, or cholangitis. Therefore, they are in need for palliative therapy to relieve their symptom, improve survival, and have a better quality of life.

Biliary drainage is indicated to relieve the symptom of biliary obstruction which will improve their quality of life and prepare some of those patients for chemotherapy. It can be obtained nonsurgically via endoscopic biliary drainage (EBD) or percutaneous transhepatic biliary drainage (PTBD). There is no difference between the two approaches in therapeutic success rate, overall complication, and 30 days mortality; however, PTBD has lower incidence of cholangitis [50, 51]. In regard to stent type, metallic stent is found to be better than plastic stent because it provides longer stent patency and lower risk of recurrent obstruction [52]. The classical way of biliary drainage is the surgical bypass with biliary-enteric anastomosis. Surgical bypass provides excellent relieve of jaundice with low mortality and morbidity [53–55]. A meta-analysis of endoscopic versus surgical bypass in malignant biliary obstruction revealed no differences between surgical bypass and endoscopic plastic stents in the rates of technical success, therapeutic success, survival, and quality of life; however, the risk of all complication was in favor of plastic stent, and recurrent biliary obstruction was in favor of surgical bypass. But, the lower risk of biliary obstruction in surgical bypass is likely to result also in metallic stent. Therefore, nonsurgical stenting is the preferred first choice in malignant biliary obstruction in patients with short life expectancy. Surgical bypass can be considered in patients found to be unresectable during attempted curative resection and in patients with expected prolonged survival [4, 54, 56].

Systemic chemotherapy has proven to prolong the survival of advanced cholangiocarcinoma compared with best supportive care, with cisplatin/gemcitabine combination as a standard of care. Chemoradiation is another treatment strategy used for advanced cholangiocarcinoma, which provides effective local control and may prolong survival; however, it is recommended to patients with locally advanced disease without distant metastasis [33]. Photodynamic therapy is another local ablative technique that uses laser therapy to destruct bile duct cell cancer that has absorbed photosensitizing agent either through percutaneous transhepatic cholangiography or with ERC. It yields a good result in terms of increased survival benefit, improvement in biliary drainage, and better quality of life compared to biliary stent only [57, 58].

IntechOpen

IntechOpen


### **Author details**

Ahmad Abdullah Madkhali\* and Faisal Al-alem  
Hepatobiliary Unit, Department of Surgery, College of Medicine, King Saud  
University, Riyadh, Saudi Arabia

\*Address all correspondence to: [ahmadmadkhali@gmail.com](mailto:ahmadmadkhali@gmail.com)

### **IntechOpen**

---

© 2019 The Author(s). Licensee IntechOpen. This chapter is distributed under the terms of the Creative Commons Attribution License (<http://creativecommons.org/licenses/by/3.0>), which permits unrestricted use, distribution, and reproduction in any medium, provided the original work is properly cited. 



## References

- [1] Vauthey JN, Blumgart LH. Recent advances in the management of cholangiocarcinomas. *Seminars in Liver Disease*. 1994;**14**(2):109-114
- [2] DeOliveira ML, Cunningham SC, Cameron JL, et al. Cholangiocarcinoma: Thirty-one-year experience with 564 patients at a single institution. *Annals of Surgery*. 2007;**245**(5):755-762
- [3] Lim JH. Cholangiocarcinoma: Morphologic classification according to growth pattern and imaging findings. *American Journal of Roentgenology*. 2003;**181**(3):819-827
- [4] Moss AC, Morris E, Leyden J, MacMathuna P. Malignant distal biliary obstruction: A systematic review and meta-analysis of endoscopic and surgical bypass results. *Cancer Treatment Reviews*. 2007;**33**(2):213-221
- [5] Kiriya M, Ebata T, Aoba T, et al. Prognostic impact of lymph node metastasis in distal cholangiocarcinoma. *The British Journal of Surgery*. 2015;**102**(4):399-406
- [6] Ito K, Ito H, Allen PJ, et al. Adequate lymph node assessment for extrahepatic bile duct adenocarcinoma. *Annals of Surgery*. 2010;**251**(4):675-681
- [7] Hong SM, Pawlik TM, Cho H, et al. Depth of tumor invasion better predicts prognosis than the current American Joint Committee on cancer T classification for distal bile duct carcinoma. *Surgery*. 2009;**146**(2):250-257
- [8] Zhou Y, Liu S, Wu L, Wan T. Survival after surgical resection of distal cholangiocarcinoma: A systematic review and meta-analysis of prognostic factors. *Asian Journal of Surgery*. 2017;**40**(2):129-138
- [9] Chun YS, Pawlik TM, Vauthey JN. 8th Edition of the AJCC cancer staging manual: Pancreas and hepatobiliary cancers. *Annals of Surgical Oncology*. 2018;**25**(4):845-847
- [10] Jun SY, Sung YN, Lee JH, Park KM, Lee YJ, Hong SM. Validation of the eighth American Joint Committee on cancer staging system for distal bile duct carcinoma. *Cancer Research and Treatment*. 2019;**51**(1):98-111
- [11] Razumilava N, Gores GJ. Classification, diagnosis, and management of cholangiocarcinoma. *Clinical Gastroenterology and Hepatology*. 2013;**11**(1):13-21 e11. Quiz e13-14
- [12] Chen CY, Shiesh SC, Tsao HC, Lin XZ. The assessment of biliary CA 125, CA 19-9 and CEA in diagnosing cholangiocarcinoma—The influence of sampling time and hepatolithiasis. *Hepato-Gastroenterology*. 2002;**49**(45):616-620
- [13] Patel AH, Harnois DM, Klee GG, LaRusso NF, Gores GJ. The utility of CA 19-9 in the diagnoses of cholangiocarcinoma in patients without primary sclerosing cholangitis. *The American Journal of Gastroenterology*. 2000;**95**(1):204-207
- [14] Choi JY, Kim MJ, Lee JM, et al. Hilar cholangiocarcinoma: Role of preoperative imaging with sonography, MDCT, MRI, and direct cholangiography. *American Journal of Roentgenology*. 2008;**191**(5):1448-1457
- [15] Mansour JC, Aloia TA, Crane CH, Heimbach JK, Nagino M, Vauthey JN. Hilar cholangiocarcinoma: Expert consensus statement. *The Official Journal of the International Hepato Pancreato Biliary Association*. 2015;**17**(8):691-699
- [16] Han JK, Choi BI, Kim AY, et al. Cholangiocarcinoma: Pictorial essay

of CT and cholangiographic findings. *Radiographics*. 2002;**22**(1):173-187

[17] Slattery JM, Sahani DV. What is the current state-of-the-art imaging for detection and staging of cholangiocarcinoma? *The Oncologist*. 2006;**11**(8):913-922

[18] Vilgrain V. Staging cholangiocarcinoma by imaging studies. *The Official Journal of the International Hepato Pancreato Biliary Association*. 2008;**10**(2):106-109

[19] Rizvi S, Gores GJ. Pathogenesis, diagnosis, and management of cholangiocarcinoma. *Gastroenterology*. 2013;**145**(6):1215-1229

[20] Henedige TP, Neo WT, Venkatesh SK. Imaging of malignancies of the biliary tract—An update. *Cancer Imaging*. 2014;**14**:14

[21] Jhaveri KS, Hosseini-Nik H. MRI of cholangiocarcinoma. *Journal of Magnetic Resonance Imaging*. 2015;**42**(5):1165-1179

[22] Gulliver DJ, Baker ME, Cheng CA, Meyers WC, Pappas TN. Malignant biliary obstruction: Efficacy of thin-section dynamic CT in determining resectability. *American Journal of Roentgenology*. 1992;**159**(3):503-507

[23] Chung YE, Kim MJ, Park YN, et al. Varying appearances of cholangiocarcinoma: Radiologic-pathologic correlation. *Radiographics*. 2009;**29**(3):683-700

[24] Khan SA, Davidson BR, Goldin RD, et al. Guidelines for the diagnosis and treatment of cholangiocarcinoma: An update. *Gut*. 2012;**61**(12):1657-1669

[25] De Bellis M, Sherman S, Fogel EL, et al. Tissue sampling at ERCP in suspected malignant biliary strictures (part 1). *Gastrointestinal Endoscopy*. 2002;**56**(4):552-561

[26] Trikudanathan G, Navaneethan U, Njei B, Vargo JJ, Parsi MA. Diagnostic yield of bile duct brushings for cholangiocarcinoma in primary sclerosing cholangitis: A systematic review and meta-analysis. *Gastrointestinal Endoscopy*. 2014;**79**(5):783-789

[27] Blechacz B. Cholangiocarcinoma: Current knowledge and new developments. *Gut and Liver*. 2017;**11**(1):13-26

[28] Mohamadnejad M, DeWitt JM, Sherman S, et al. Role of EUS for preoperative evaluation of cholangiocarcinoma: A large single-center experience. *Gastrointestinal Endoscopy*. 2011;**73**(1):71-78

[29] Rerknimitr R, Angsuwatcharakon P, Ratanachu-ek T, et al. Asia-Pacific consensus recommendations for endoscopic and interventional management of hilar cholangiocarcinoma. *Journal of Gastroenterology and Hepatology*. 2013;**28**(4):593-607

[30] Garrow D, Miller S, Sinha D, et al. Endoscopic ultrasound: A meta-analysis of test performance in suspected biliary obstruction. *Clinical Gastroenterology and Hepatology*. 2007;**5**(5):616-623

[31] Sadeghi A, Mohamadnejad M, Islami F, et al. Diagnostic yield of EUS-guided FNA for malignant biliary stricture: A systematic review and meta-analysis. *Gastrointestinal Endoscopy*. 2016;**83**(2):290-298 e291

[32] Valle JW, Borbath I, Khan SA, et al. Biliary cancer: ESMO clinical practice guidelines for diagnosis, treatment and follow-up. *Annals of Oncology*. 2016;**27**(suppl 5):v28-v37

[33] Network NCC. Hepatobiliary Cancer (Version 1). 2019. Available from: [https://www.nccn.org/professionals/physician\\_gls/pdf/hepatobiliary.pdf](https://www.nccn.org/professionals/physician_gls/pdf/hepatobiliary.pdf)

- [34] Fang Y, Gurusamy KS, Wang Q, et al. Meta-analysis of randomized clinical trials on safety and efficacy of biliary drainage before surgery for obstructive jaundice. *The British Journal of Surgery*. 2013;**100**(12):1589-1596
- [35] Sewnath ME, Karsten TM, Prins MH, Rauws EJ, Obertop H, Gouma DJ. A meta-analysis on the efficacy of preoperative biliary drainage for tumors causing obstructive jaundice. *Annals of Surgery*. 2002;**236**(1):17-27
- [36] Yao D, Kunam VK, Li X. A review of the clinical diagnosis and therapy of cholangiocarcinoma. *The Journal of International Medical Research*. 2014;**42**(1):3-16
- [37] Komaya K, Ebata T, Shirai K, et al. Recurrence after resection with curative intent for distal cholangiocarcinoma. *The British Journal of Surgery*. 2017;**104**(4):426-433
- [38] Jarnagin WR, Fong Y, RP DM, et al. Staging, resectability, and outcome in 225 patients with hilar cholangiocarcinoma. *Annals of Surgery*. 2001;**234**(4):507-517. Discussion 517-509
- [39] Miyazaki M, Yoshitomi H, Miyakawa S, et al. Clinical practice guidelines for the management of biliary tract cancers 2015: The 2nd English edition. *Journal of Hepato-Biliary-Pancreatic Sciences*. 2015;**22**(4):249-273
- [40] Chua TC, Saxena A. Extended pancreaticoduodenectomy with vascular resection for pancreatic cancer: A systematic review. *Journal of Gastrointestinal Surgery*. 2010;**14**(9):1442-1452
- [41] Murakami Y, Uemura K, Hayashidani Y, et al. Prognostic significance of lymph node metastasis and surgical margin status for distal cholangiocarcinoma. *Journal of Surgical Oncology*. 2007;**95**(3):207-212
- [42] Miyazaki M, Ohtsuka M, Miyakawa S, et al. Classification of biliary tract cancers established by the Japanese Society of hepato-biliary-pancreatic surgery: 3rd English edition. *Journal of Hepato-Biliary-Pancreatic Sciences*. 2015;**22**(3):181-196
- [43] Ebata T, Yokoyama Y, Igami T, Sugawara G, Mizuno T, Nagino M. Review of hepatopancreatoduodenectomy for biliary cancer: An extended radical approach of Japanese origin. *Journal of Hepato-Biliary-Pancreatic Sciences*. 2014;**21**(8):550-555
- [44] Zhou Y, Zhang Z, Wu L, Li B. A systematic review of the safety and efficacy of hepatopancreatoduodenectomy for biliary and gallbladder cancers. *The Official Journal of the International Hepato Pancreato Biliary Association*. Oxford: HPB; 2016 Jan;**18**(1):1-6. DOI: 10.1016/j.hpb.2015.07.008. [Epub 2015 Nov 30]
- [45] Igami T, Nagino M, Oda K, et al. Clinicopathologic study of cholangiocarcinoma with superficial spread. *Annals of Surgery*. 2009;**249**(2):296-302
- [46] Wakai T, Shirai Y, Moroda T, Yokoyama N, Hatakeyama K. Impact of ductal resection margin status on long-term survival in patients undergoing resection for extrahepatic cholangiocarcinoma. *Cancer*. 2005;**103**(6):1210-1216
- [47] Ebata T, Yokoyama Y, Igami T, et al. Hepatopancreatoduodenectomy for cholangiocarcinoma: A single-center review of 85 consecutive patients. *Annals of Surgery*. 2012;**256**(2):297-305
- [48] Xiang S, Lau WY, Chen XP. Hilar cholangiocarcinoma: Controversies on the extent of surgical resection aiming at cure. *International Journal of Colorectal Disease*. 2015;**30**(2):159-171

- [49] Brandi G, Venturi M, Pantaleo MA, Ercolani G, GICO. Cholangiocarcinoma: Current opinion on clinical practice diagnostic and therapeutic algorithms: A review of the literature and a long-standing experience of a referral center. *Digestive and Liver Disease*. 2016;**48**(3):231-241
- [50] Duan F, Cui L, Bai Y, Li X, Yan J, Liu X. Comparison of efficacy and complications of endoscopic and percutaneous biliary drainage in malignant obstructive jaundice: A systematic review and meta-analysis. *Cancer Imaging*. 2017;**17**(1):27
- [51] Zhao XQ, Dong JH, Jiang K, Huang XQ, Zhang WZ. Comparison of percutaneous transhepatic biliary drainage and endoscopic biliary drainage in the management of malignant biliary tract obstruction: A meta-analysis. *Digestive Endoscopy*. 2015;**27**(1):137-145
- [52] Yuan TW, Liu HQ, Wang SB, Cao J. Comparison of plastic stents with self-expandable metal stents in palliative treatment of malignant biliary obstruction: A meta-analysis. *European Review for Medical and Pharmacological Sciences*. 2017;**21**(12):2847-2857
- [53] Kuhlmann KF, van Poll D, de Castro SM, et al. Initial and long-term outcome after palliative surgical drainage of 269 patients with malignant biliary obstruction. *European Journal of Surgical Oncology*. 2007;**33**(6):757-762
- [54] Muller MW, Friess H, Koninger J, et al. Factors influencing survival after bypass procedures in patients with advanced pancreatic adenocarcinomas. *American Journal of Surgery*. 2008;**195**(2):221-228
- [55] Nieveen van Dijkum EJ, Romijn MG, Terwee CB, et al. Laparoscopic staging and subsequent palliation in patients with peripancreatic carcinoma. *Annals of Surgery*. 2003;**237**(1):66-73
- [56] Witzigmann H, Lang H, Lauer H. Guidelines for palliative surgery of cholangiocarcinoma. *The Official Journal of the International Hepato Pancreato Biliary Association*. 2008;**10**(3):154-160
- [57] Leggett CL, Gorospe EC, Murad MH, Montori VM, Baron TH, Wang KK. Photodynamic therapy for unresectable cholangiocarcinoma: A comparative effectiveness systematic review and meta-analyses. *Photodiagnosis and Photodynamic Therapy*. 2012;**9**(3):189-195
- [58] Lu Y, Liu L, Wu JC, Bie LK, Gong B. Efficacy and safety of photodynamic therapy for unresectable cholangiocarcinoma: A meta-analysis. *Clinics and Research in Hepatology and Gastroenterology*. 2015;**39**(6):718-724