

We are IntechOpen, the world's leading publisher of Open Access books Built by scientists, for scientists

4,800

Open access books available

122,000

International authors and editors

135M

Downloads

Our authors are among the

154

Countries delivered to

TOP 1%

most cited scientists

12.2%

Contributors from top 500 universities



WEB OF SCIENCE™

Selection of our books indexed in the Book Citation Index
in Web of Science™ Core Collection (BKCI)

Interested in publishing with us?
Contact book.department@intechopen.com

Numbers displayed above are based on latest data collected.
For more information visit www.intechopen.com



Reconstruction after Laparoscopic Distal Gastrectomy

Satoshi Kanda and Tetsu Fukunaga

Additional information is available at the end of the chapter

<http://dx.doi.org/10.5772/intechopen.80630>

Abstract

Laparoscopy-assisted distal gastrectomy (LADG) has advanced much in the past 10 years in the eastern countries, due to the high gastric cancer incidences. Reconstruction is the major hurdle for perfect laparoscopic distal gastrectomy (LDG). Initially, hand-associated or small incisional open laparotomy reconstruction, the so-called associated operation, was performed. A full laparoscopic operation is much better for the patient—small wound, less pain, and quick recovery. Several reconstruction methods have been developed by experts during more than 10 years. The question of what method is the best after distal gastrectomy is still controversial. This chapter focuses on the reconstruction methods in the total laparoscopy distal gastrectomy (LDG) operation, explains the merits and demerits of several methods, and introduces our original method, named augmented rectangle technique (ART).

Keywords: LDG, Billroth I and II, R-Y, delta, ART

1. Introduction

Gastric cancer operations have the most impact on food intake and body weight loss, resulting in more changes in patient's circumstances than any other surgery [1–3]. Its morbidity and mortality are, respectively, ranked fifth and third in the world—with the incidence in China, Japan, and Korea, the highest in the world. Even now, with chemotherapy and immunotherapy well progressed, surgery is still required for the curable treatment for that cancer [4, 5].

Laparoscopy-assisted distal gastrectomy (LADG) with gastroduodenostomy for early gastric cancer was first reported in 1994 by professor Kitano. Initially, hand-associated or small incisional open laparotomy reconstruction, the so-called associated operation, was performed. Full laparoscopic operation is much better for the patients, due to small wound, less pain, and quick recovery. According to the 12th Nationwide Survey of Endoscopic Surgery in Japan, in

2013, 52.7% of patients who underwent distal gastrectomy underwent laparoscopic surgery [1]. After distal gastrectomy, several reconstruction methods are available, and the choice of reconstruction is usually dependent on surgeons or institutions. There are three famous reconstruction methods, Billroth I and II and Roux-en-Y. Studies comparing gastroduodenostomy with gastrojejunostomy are still lacking and inconsistent; therefore, controversy remains regarding which method is the best after distal gastrectomy.

Billroth I gastroduodenostomy is one of most common reconstruction methods, and it offers advantages such as the following: (1) it is the only way to preserve the physiological root of the food passing through the duodenum, (2) it has technical simplicity during open surgery, and (3) it confers a lower incidence of internal hernia or adhesions. However, the risk of anastomotic failure is higher, and the laparoscopic gastrointestinal anastomosis involves a high degree of difficulty. Of course, if the size of gastric remnant is too small, Billroth I reconstruction cannot be done. These methods for total laparoscopic operation are the most difficult and have developed by experts during more than 10 years.

Billroth II gastrojejunostomy shares some pros and cons with the Billroth I and Roux-en-Y methods. It enables a wide stomach resection without anastomotic tension and is relatively easy during laparoscopic surgery. However, postoperative bile reflux into the remnant stomach is more frequent, and, although rare, afferent loop syndrome can develop.

Roux-en-Y gastrojejunostomy prevents bile reflux [1]. Other advantages over Billroth I are as follows. It is acceptable if the gastric remnant is too small to perform Billroth I, and there is less anastomotic tension. However, the high incidence of Roux stasis syndrome is one of its major drawbacks and, although rare, leakage of duodenal stump is a severe complication.

2. Billroth I

Billroth I is the most common and physiological reconstruction method after distal gastrectomy. For laparoscopy-assisted distal gastrectomy (LADG), Billroth I reconstruction can be performed by an extracorporeal or intracorporeal method. Initially, hand-associated or small incisional open laparotomy reconstruction, so-called associated operation, was performed. Due to an increasing number of laparoscopic gastrectomies, the laparoscopic technique has become possible for total laparoscopic distal gastrectomy (TLDG). This portion describes old extra-methods and new intra-methods.

2.1. Extracorporeal Billroth I anastomosis

Extracorporeal Billroth I anastomosis has several merits when compared to intracorporeal anastomosis. Tumor location is identified by palpitation. It is easily and rapidly performed like conventional open surgery, and it uses fewer staples than the intracorporeal anastomosis. For the problem of the cost, extracorporeal Billroth I is still the most common reconstruction method for LADG. Additionally, extracorporeal anastomosis is a procedure that should be considered as the first choice in view of safety in the inexperienced facility learning laparoscopic gastrectomy.

2.1.1. Extracorporeal hemi-double stapling technique

After lymph node dissection, a 4–6 cm minilaparotomy is made at the upper midline (**Figure 1**) [6]. The stomach is pulled out of the peritoneal cavity through the small incision, which is applied by a wound retractor (**Figure 2**). A purse-string instrument is applied to the duodenum distal to the resection line. A Lister forceps is applied just proximal to the purse-string clamp, and the duodenum is transected between the two clamps (**Figure 3**). The duodenal stump is unclamped and held by Alice forceps equally at three points. An anvil is inserted into the duodenal stump, and a purse-string suture is tied over the anvil (**Figure 4**). Then, the duodenal stump is returned to the abdominal cavity; at this time, the purse-string suture thread is clamped without cutting it, leaving the clamp outside of the abdominal cavity. The greater curvature side of the proximal resection margin is transited with an 80-mm linear stapler (**Figure 5**). Thereafter, an entry hole is made along the lesser curvature side of the previous staple line at the disbanded of 3 cm to the lesser curvature; the shaft of the circular stapler is introduced into the gastric remnant through the gastrostomy (**Figure 6**). The shaft is rotated toward the duodenum with the distal stomach, and then the trocar is advanced to penetrate the corner of the stapling line at the greater curvature (**Figure 7**). The trocar is connected to the anvil placed in the duodenum. The instrument is closed and fired, completing the end-to-end gastroduodenostomy. After checking for bleeding at the anastomotic line, the lesser curvature side of proximal resection margin is transected with another linear stapler (**Figure 8**).

2.1.2. Extracorporeal end-to-side posterior wall method

The distal gastrectomy procedure is the same as for the abovementioned method [6]. For resection of the proximal margin, the stomach is transected 5 cm from the greater curvature to the middle of the planned resection line using two clamps, and the remaining proximal resection is done using an 80-mm linear stapler. After distal gastrectomy, the head of the circular stapler is inserted into the remnant stomach through the opening of the greater curvature side of the proximal resection, which was temporarily clamped. The trocar is advanced

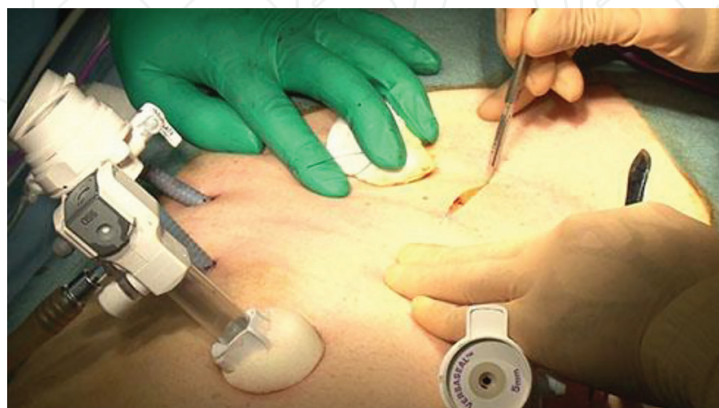


Figure 1. Extracorporeal hemi-double stapling technique – depiction of procedure as described in the text, step 1.

to pass through the posterior wall of the remnant stomach and then coupled on the anvil placed in the duodenum. The device is closed and fired, completing the end-to-side gastro-duodenostomy. Finally, the opening in the remnant stomach is shuttered using an additional linear stapler.

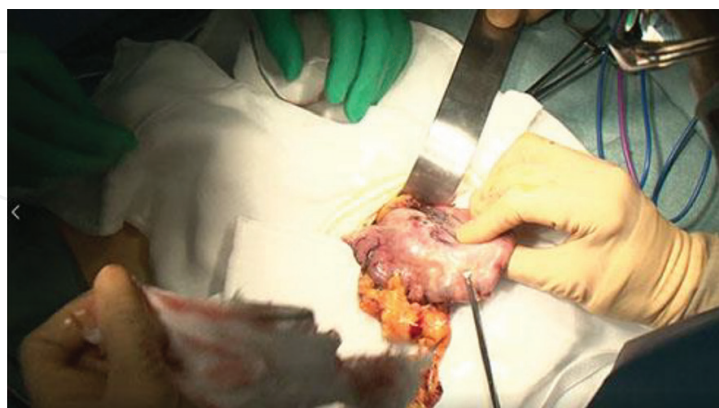

Figure 2. Extracorporeal hemi-double stapling technique – depiction of procedure as described in the text, step 2.

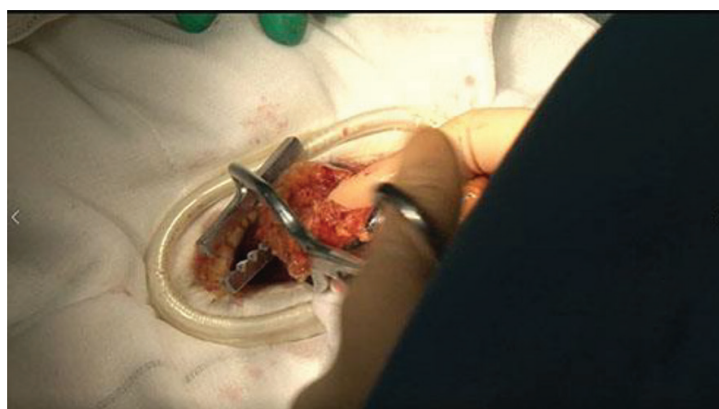


Figure 3. Extracorporeal hemi-double stapling technique – depiction of procedure as described in the text, step 3.

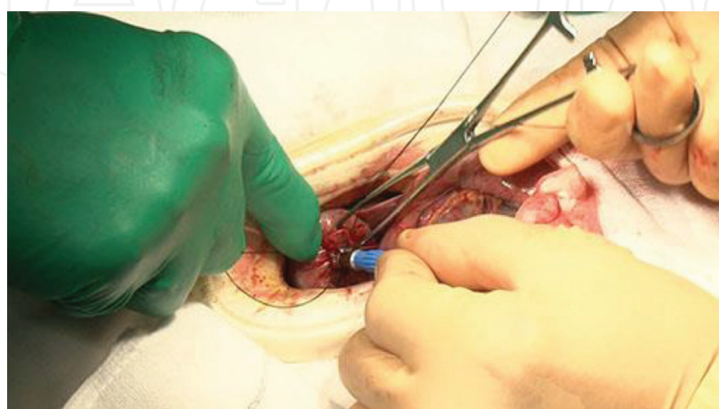


Figure 4. Extracorporeal hemi-double stapling technique – depiction of procedure as described in the text, step 4.

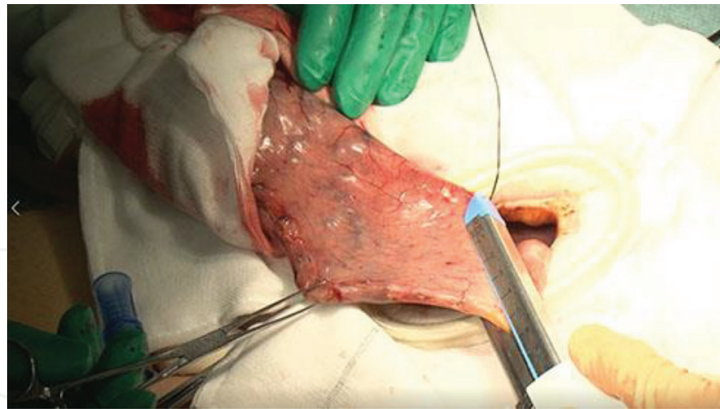


Figure 5. Extracorporeal hemi-double stapling technique – depiction of procedure as described in the text, step 5.

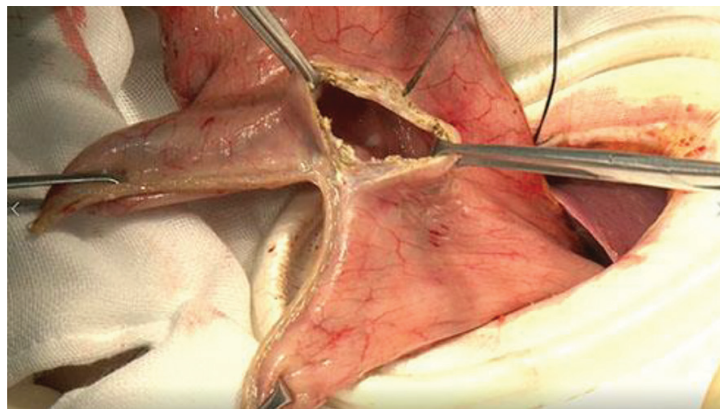


Figure 6. Extracorporeal hemi-double stapling technique – depiction of procedure as described in the text, step 6.

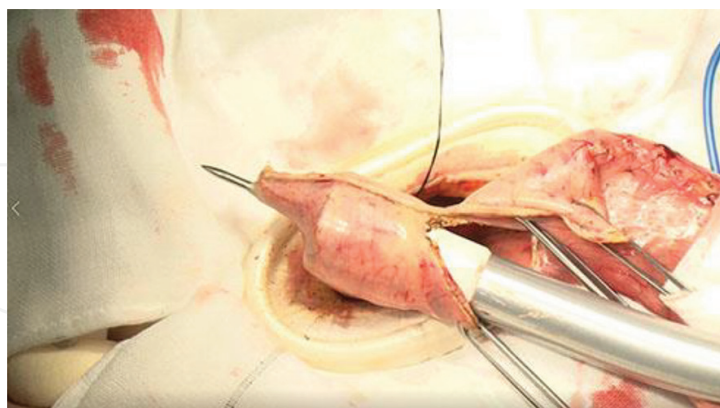


Figure 7. Extracorporeal hemi-double stapling technique – depiction of procedure as described in the text, step 7.

In this method, there is no overlap between the liner stapler and circular stapler, which is said to be likely to cause anastomotic leakage in general, but the possibility of an ischemic area remaining between the liner stapler and the circular stapler is considered a problem. In order to avoid this complication, it is said to set the place to puncture the back wall ten from liner stapler, but then the “dog’s ear” deformation remains widely.

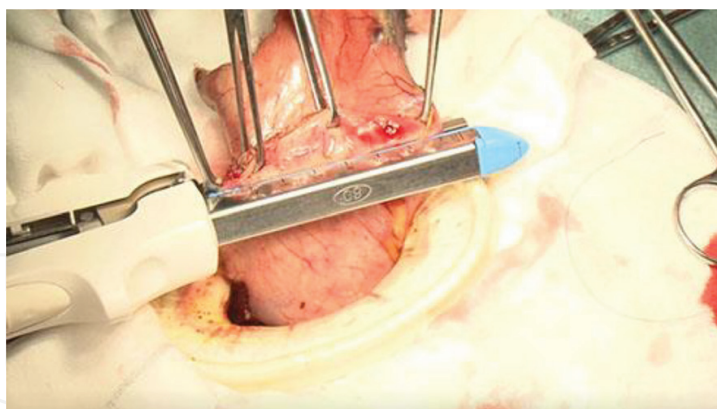


Figure 8. Extracorporeal hemi-double stapling technique – depiction of procedure as described in the text, step 8.

2.2. Intracorporeal Billroth I anastomosis

2.2.1. Delta-shaped anastomosis

The delta-shaped anastomosis originally created by Professor Kanaya is a functional end-to-end gastroduodenostomy technique using endoscopic linear staplers [7].

For the duodenal bulbus resection, the direction of the stapling is more vertical than the mesenteric-antimesenteric direction. End-to-end anastomosis is done vertically to maintain an enough blood supply to the anastomosis and to preserve a space for the jaw of 45-mm linear stapler to be inserted into the entry hole. Before stapler firing, the staple line on the remnant stomach is rotated to the left side, and the staple line on the duodenal stump is rotated to the right side to form a side-to-side gastroduodenostomy between the posterior wall of the remnant stomach and the posterior wall of the duodenum. After firing the stapler, a relatively large entry hole is made, and the operator checks for anastomotic bleeding through this hole. After transient approximation of the entry hole with clips, the hole is closed by two consecutive firings of a 45-mm liner stapler.

2.2.2. Intracorporeal triangular anastomotic technique (INTACT)

The other intracorporeal anastomosis method, novel intracorporeal triangular anastomotic technique, was reported by Omori et al. [8].

After all dissection of lymph nodes is finished, the stomach and duodenal bulb are staple-transected parallelly, and the resected stomach with dissected LNs is retrieved through the umbilical incision. Small entry holes are made on the greater curvature side, for each of the remnant stomach and the duodenal bulb, leaving a space almost 1 cm away from each stapling line. The cartridge side of the linear stapler (45-mm articulating medium/thick cartridge) is inserted to the transection line of the stomach. Then, the linear stapler fork side is carefully inserted into the bulb via the hole parallelly. This process makes The cartridge side is inserted parallel to the transection line of the stomach. The posterior walls, so-call V-shaped anastomosis, of both the gastric remnant and the bulbs, the dorsal side of the posterior suture line of the Billroth I. After arresting hemorrhage of the suture line, the entry hole is sutured by 2–3 points temporarily, avoiding slipping the liner staple. Finally, the entry hole is closed by a 45-mm linear stapler suture and created completing the anterior half of the anastomosis. The almost

60° anastomotic angle between the second anastomotic line and the first suture line is best designed for passing the food. This second anastomotic line length should be approximately 30 mm without the ventral staple lines. Thirdly, the linear stapler with a 60-mm articulating medium/thick cartridge is placed in the direction toward the posterior wall and also placed almost perpendicular to the transection line of the stomach for resecting the blood less area. Those three staplers created the triangular anastomosis and simultaneously removed three staple lines of the duodenal transection line, the ventral line of the first anastomosis, the end of gastric transection line, and the ischemic tissues in between these staple lines. This technique yielded an end-to-end anastomosis of a triangular orifice [9].

2.2.3. Augmented rectangle technique

We have reported that laparoscopy-assisted distal gastrectomy (LADG) with extended lymph node dissection for gastric cancer was technically feasible and had favorable oncologic outcomes compared to the open gastrectomy [1, 10]. Unlike the extracorporeal anastomosis performed during the LADG, a standardized reconstruction method has not been established for the Billroth I (BI) gastroduodenostomy in the totally laparoscopic distal gastrectomy (LDG). A triangle anastomosis or a delta-shaped anastomosis is reported for the LDG without associated laparotomy. However, these two methods seem complicated for the LDG because of the need for stay sutures and further have the risks of ischemia or stenosis postoperatively. Therefore, we have developed an “augmented rectangle technique (ART)” as a new BI anastomosis performed during the LDG. The ART does not need stay sutures and therefore facilitates the LDG.

A 12-mm trocar for the laparoscope is inserted into the umbilicus. A 12-mm trocar is introduced into the left premaxillary line 1 cm below the costal margin. A second 12-mm trocar is inserted into the left midclavicular line 2 cm above the umbilicus. A 5-mm trocar is inserted into the right premaxillary line 1 cm below the costal margin. A third 12-mm trocar is placed by the camera assistant between the patient’s legs (**Figure 9**).

Duodenal resection is performed with the surgeon’s right hand using a 60-mm endoscopic linear stapler (ELS) from the greater curvature side of duodenum to lesser curvature side. The duodenum is transected just below the pyloric ring because it is necessary to preserve a long duodenum for anastomosis (**Figure 10**).

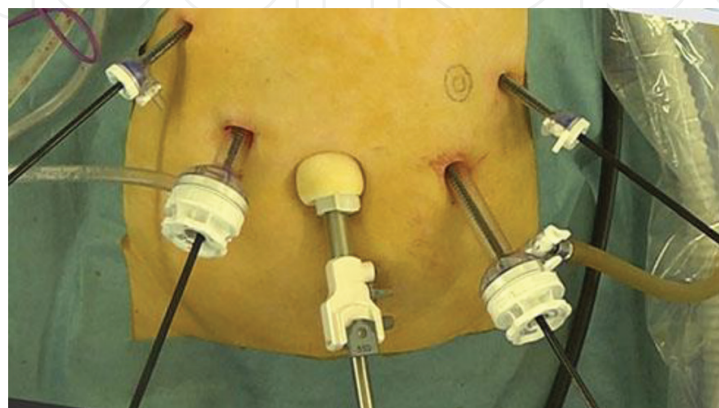


Figure 9. Augmented rectangle technique – depiction of procedure as described in the text, step 1.

Gastric resection is also done using two 60-mm ELS through the 12-mm trocar of the left lower quadrant from greater curvature to lesser curvature (**Figure 11**).

The superior duodenal vessels along the lesser curvature are transected to mobilize the duodenum (**Figure 12**).

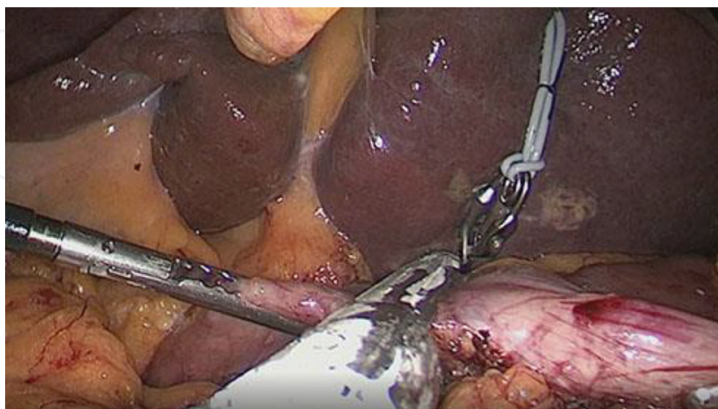

Figure 10. Augmented rectangle technique – depiction of procedure as described in the text, step 2.

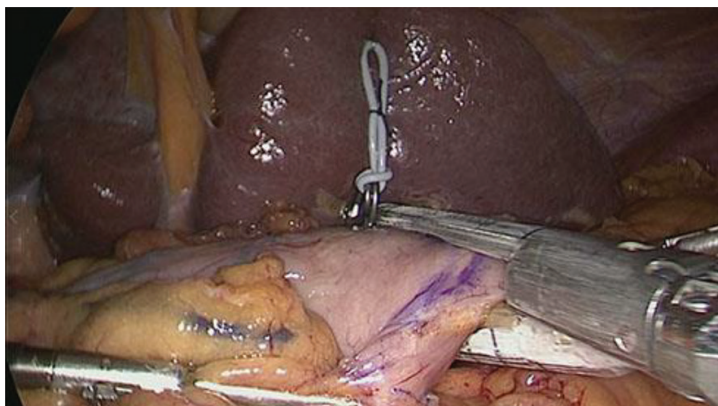


Figure 11. Augmented rectangle technique – depiction of procedure as described in the text, step 3.

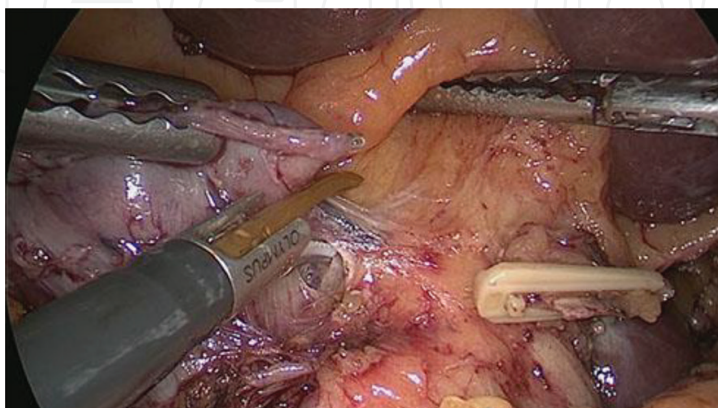


Figure 12. Augmented rectangle technique – depiction of procedure as described in the text, step 4.

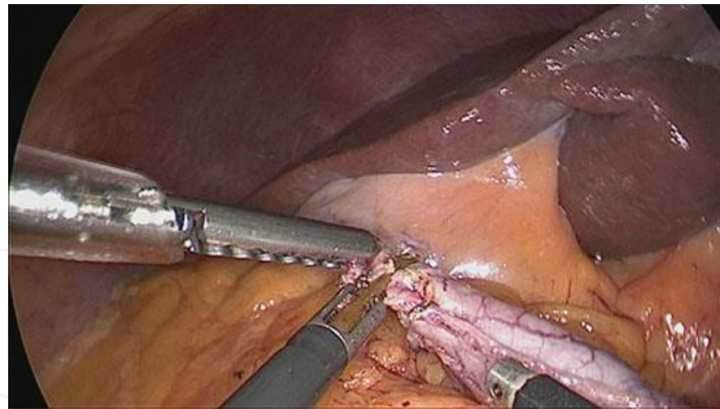


Figure 13. Augmented rectangle technique – depiction of procedure as described in the text, step 5.

An entry hole is made on the tip of the greater curvature side of the duodenal stump. The surgeon holds the tip of greater curvature side of the duodenal stump by his left hand located upside, and the assistant holds the tip of lesser curvature side of the duodenal stump by her right hand. Also, an assistant holds a suction by her left hand to prevent contamination by digestive tract contents in the abdominal cavity. A 5-mm incision is created in the previous stapled line at the greater curvature side of duodenal stump (**Figure 13**). Also, an entry hole is made on the tip of greater curvature side of remnant stomach (**Figure 14**).

The thicker cartridge fork of the 60-mm ELS is inserted into the stomach through the 12-mm trocar of the left lower quadrant. At this time, the tip of the ELS is pressed against the posterior gastric wall 2 cm away from the gastric resection margin, and the ELS is used to grasp the tissue close to the suture line near the ELS entry hole (**Figure 15**).

An ELS gently holding the posterior wall of the remnant stomach is rotated clockwise to the duodenal side, which is then ready for the gastroduodenostomy. The surgeon, who is standing on the patient's right, opens the ELS and moves its thinner jaw to cover the duodenum. The margin of resection at the lesser curvature end of the duodenum is rotated externally by 90° (**Figure 16**). The entire length of the ELS is inserted, and the device is then closed and

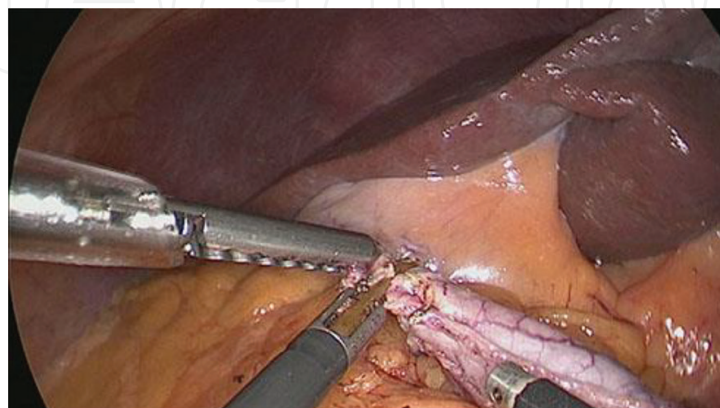


Figure 14. Augmented rectangle technique – depiction of procedure as described in the text, step 6.

fired. The ELS is withdrawn, the lumen is examined to confirm the absence of hemorrhage, and the residual duodenum and stomach are once again placed under adequate traction (**Figure 17**).

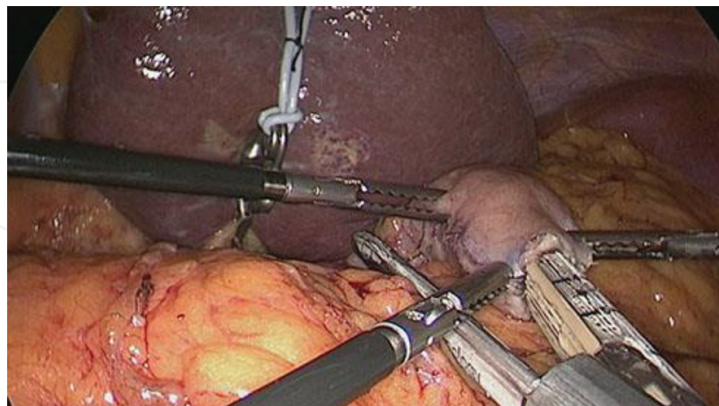


Figure 15. Augmented rectangle technique – depiction of procedure as described in the text, step 7.

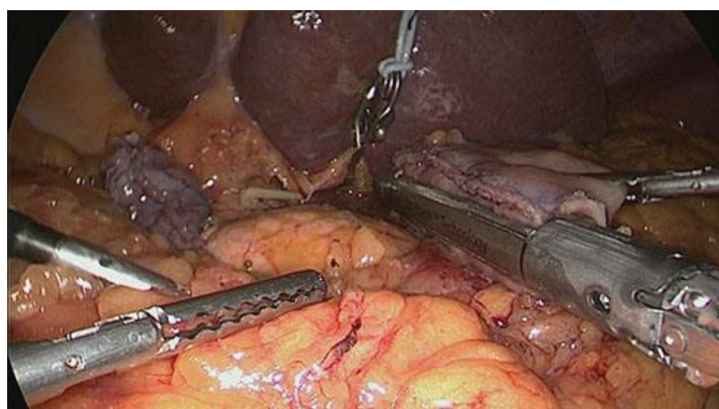


Figure 16. Augmented rectangle technique – depiction of procedure as described in the text, step 8.

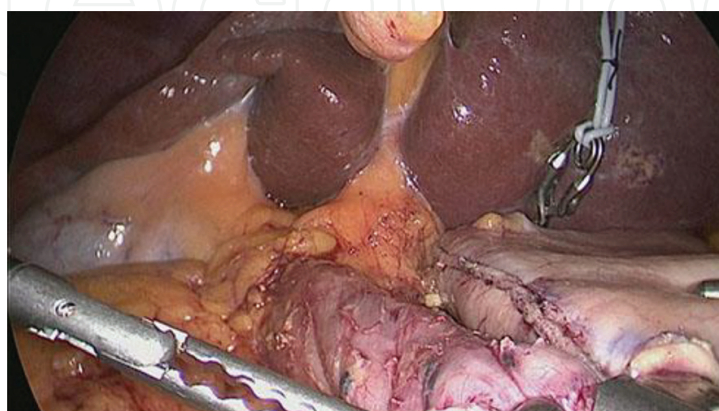


Figure 17. Augmented rectangle technique – depiction of procedure as described in the text, step 9.

Next, the insertion hole is closed, and a margin is created with the use of a 30-mm ELS. This margin is closed on this side to avoid the need for stapling the transected duodenal margin (Figure 18). The surgeon grasps the cranial ends of a V-shaped suture line created with the first ELS, and care is taken to ensure that the gastric and duodenal resection margins remain

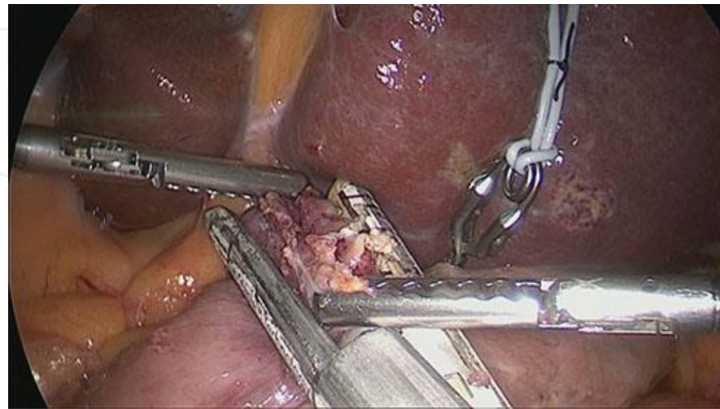


Figure 18. Augmented rectangle technique – depiction of procedure as described in the text, step 10.

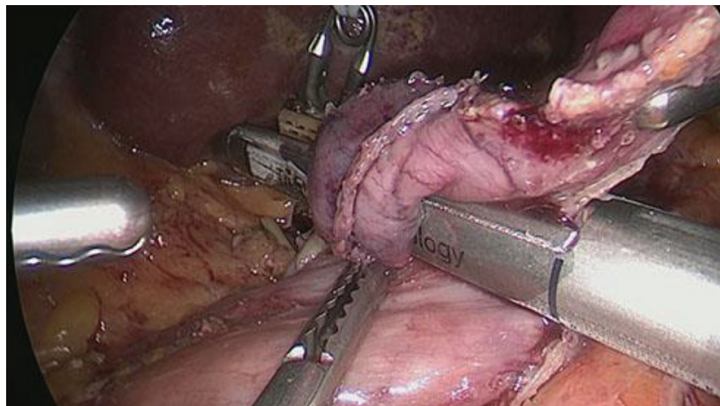


Figure 19. Augmented rectangle technique – depiction of procedure as described in the text, step 11.

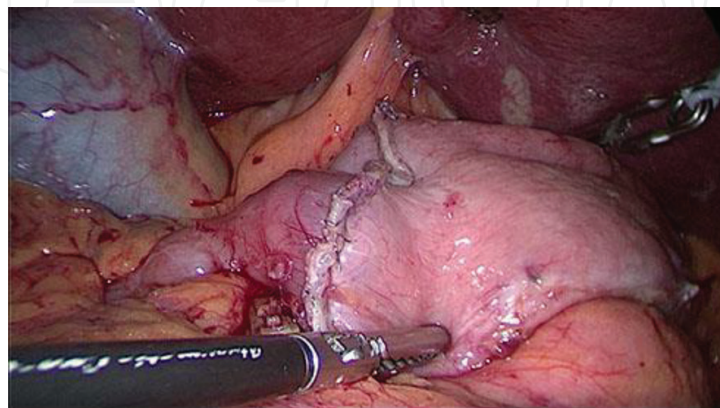


Figure 20. Augmented rectangle technique – depiction of procedure as described in the text, step 12.

close together. This creates the third side of a rectangle. Next, a 60-mm ELS is used to create the fourth side of the rectangle, while the entire stapled duodenal stump is being removed. The surgeon places caudolateral traction on the duodenal stump. Meanwhile, the assistant adjusts the position of the ELS to ensure overlap between the two suture lines, the first being along the second staple line and the second being along the gastric stump (**Figure 19**). With this suturing, the end-to-end anastomosis with an augmented rectangular gastroduodenal anastomotic stoma is complete (**Figure 20**).

3. Roux-en-Y reconstruction (RY)

Roux-en-Y reconstruction is one of the standard options after distal gastrectomy. In 1995, Kitano et al. used an extracorporeal gastrojejunostomy with manual suturing as a reconstruction procedure for distal gastrectomy. The improvements in stapling devices contributed to easy access to the site of operation. The advantage and disadvantage of RY reconstruction compared with Billroth I are as follows: prevention of bile reflex and reduction in incidence of anastomotic leakage.

3.1. Antecolic isoperistaltic RY reconstruction

A 12-mm trocar is inserted through the umbilical region by the open procedure, and then CO₂ pneumoperitoneum is established. A 12-mm trocar is introduced into the left pre-axillary line 1 cm below the costal margin. A 5-mm trocar is inserted into the left midclavicular line 2 cm above the umbilicus. The second 5-mm trocar is inserted into the right pre-axillary line 1 cm below the costal margin. Another 12-mm trocar is placed by the camera assistant between the patient's legs.

Laparoscopic mobilization of the stomach and lymph node dissection are carried out in a conventional procedure. The duodenum is divided distal to the pylorus with a 60-mm ELS; then, the stomach is divided with two ELSs. The specimen is removed through an extended 4-cm incision in the umbilical port. Following re-establishment of the pneumoperitoneum, the jejunum 20 cm distal to the ligament of Treitz is prepared for Roux limb, and the mesentery of this jejunum is divided for a distance of 8 cm. The prepared jejunum is then divided with an ELS to ensure a gastrojejunostomy without tension. A side-side jejunojejunostomy is fashioned 25 cm distal to the planned gastrojejunostomy using an ELS under direct vision through the umbilical incision. The jejunojejunostomy defect is closed with absorbable suture in an intermittent fashion. Following re-pneumoperitoneum, the jejunal limb is brought to the gastric remnant through an antecolic route. A right-oriented Roux limb is created such that the cut end of the Roux limb faces the greater curvature of remnant stomach. The jejunal limb is anastomosed to the greater curvature of remnant stomach side to side with an ELS; then, the site of entry hole is closed using an absorbable barbed suture. The duodenal stump is embedded with seromuscular suture and then fixed with the alimentary limb on the duodenal stump in a proper radian.

3.2. Antecolic antiperistaltic RY reconstruction

The duodenum and stomach are divided distal to the pylorus with three 60-mm ELSs. The specimen is removed through an extended 4-cm incision in the umbilical port. After

re-pneumoperitoneum, the proximal jejunum is identified and divided 25 cm distal to the Treitz ligament, and the mesentery of the jejunum is divided. The jejunum is divided with a 60-mm ELS. Small holes are made at the tips of linear stapler of the greater curvature side of the remnant stomach and distal side of jejunal stump. The gastrojejunostomy is performed between the posterior wall of remnant stomach and antimesenteric border of the distal jejunum with a 60-mm ELS. The common entry hole is closed with a 60-mm ELS. The jejunojejunostomy is performed through an umbilical minilaparotomy with a 60-mm ELS and hand-sewn suture.

4. Billroth II anastomosis

A Billroth II gastrojejunostomy enables wide stomach resection without anastomotic tension and is relatively easy during laparoscopic surgery. However, postoperative bile reflux into the remnant stomach is bothersome, and although rare, afferent loop syndrome can develop. So, Billroth II is rarely performed in Japan, but according to a nationwide survey conducted in 2014 in Korea, Billroth II was the adopted reconstruction after distal gastrectomy in 35.8% of cases [2].

4.1. Surgical procedure of Billroth II gastrojejunostomy

Herein, a laparoscopy-assisted uncut Roux-en-Y operation after distal gastrectomy as reported by Uyama et al. is described [11].

A laparoscopic mobilization of the stomach and en bloc lymph node dissection is performed, with a 4-cm long minilaparotomy made on the upper abdomen, through which the en bloc mobilized stomach and lymph nodes were delivered and the stomach is transected.

Laparoscopy-assisted reconstruction is then started. First, the transverse colon is retracted cephalad to expose the ligament of Treitz, and the jejunum 25 cm distal to this ligament is delivered via the minilaparotomy. The position of the gastrojejunostomy, whose length is 4 cm, is determined. Next, a Braun anastomosis is created extracorporeally. A stapler without a blade is placed across the afferent jejunal limb just distal to the created Braun anastomosis. This stapler is closed and fired extracorporeally, which enables occlusion of the afferent jejunal lumen without division of the jejunum. Seromuscular sutures are placed on this staple line, and delivered jejunum is replaced into the abdominal cavity. The operation turns again to a laparoscopic procedure. The gastrojejunostomy is started while observing the created Braun anastomosis and stapling across the jejunum laparoscopically. The corner of the greater curvature of the stomach stump is cut, and a small hole is made on the site of the planned gastrojejunostomy, using laparoscopic coagulating shears.

One jaw of the endoscopic linear stapler is inserted into the jejunum and the other into the stomach. The device is closed and fired, creating a gastrojejunostomy. The firing of the stapler converts the two holes into one common entry hole, which is closed by a laparoscopic hand-sewn technique. Two seromuscular sutures are placed between the afferent loop and lesser curvature of the gastric remnant to lift up the afferent loop, with the aim of preventing food flowing into the afferent loop. Finally, the seromuscular suture between the stomach and efferent loop is placed on the top of created V-shaped anastomosis, because this is the weakest point, due to the remaining tension.

5. Discussion

Our policy of reconstruction after distal gastrectomy is as follows. The first choice is Billroth I reconstruction. If the remnant stomach is too small for Billroth I reconstruction, we perform isoperistaltic RY reconstruction.

To date, we have used ART in 160 patients who underwent laparoscopic distal gastrectomy for stomach cancer between December 2013 and August 2017. These included 50 women and 110 men, with a mean age of 69.5 years and a mean body mass index (BMI) of 21.8. D1+ lymphadenectomy was performed in 81 patients, and D2 lymphadenectomy in 79 patients. The mean operation time was 227 minutes, and the mean blood loss volume was 47.3 mL. There were no intraoperative complications associated with reconstruction of the gastrointestinal tract, and none of the patients required conversion to open surgery. There were also no postoperative complications, such as anastomotic leakage or stenosis, associated with the reconstruction, and the mean postoperative hospital stay was 12 days (**Table 1**). Postoperative endoscopic examinations typically confirmed a large, elliptical anastomotic stoma (**Figure 21**).

Sex
Age
Body mass index
Operation time
Intraoperative blood loss
Extent of lymph node dissection
D1+/D2
Clinical stage
I/II/III/IV
Conversion to open surgery
Postoperative complications
Anastomosis-related complications
Anastomotic leakage
Anastomotic hemorrhage
Delayed gastric emptying
Non-anastomosis-related complications
Pancreatic fistula
Intra-abdominal infection
Intraperitoneal hemorrhage
Surgical site infection
Time to oral intake
Postoperative hospital stay

Table 1. Characteristics of patients in whom ART-based anastomosis was performed ($n = 160$).

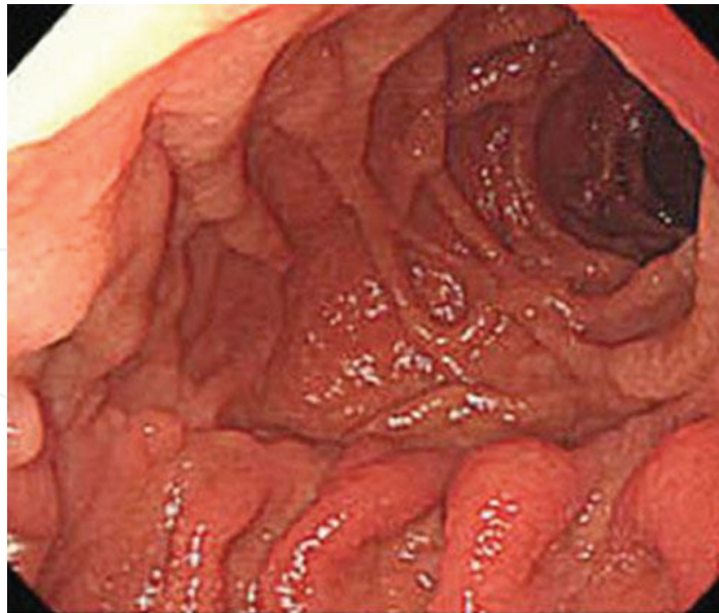


Figure 21. Elliptical anastomotic stoma in postoperative examination.

We performed antecolic isoperistaltic RY reconstruction in 52 consecutive patients who underwent laparoscopic gastrectomy for gastric cancer between April 2015 and December 2017. There were 32 women and 20 men, with a mean age of 70.4 years and mean body mass index of 22.3. D1+ lymphadenectomy was performed in 35 patients, and D2 lymphadenectomy in 17 patients. The mean operation time was 282 min, and the mean blood loss volume was 35.8 ml. All of the procedures were free of intraoperative complications. There were no postoperative complications, such as anastomotic leakage, intestinal obstruction, and duodenal stump leakage.

Conflict of interest

The authors declare no conflict of interest.

Author details

Satoshi Kanda* and Tetsu Fukunaga

*Address all correspondence to: st-kanda@juntendo.ac.jp

Gastroenterology and Minimally Invasive Surgery, Juntendo University, Tokyo, Japan

References

- [1] Fukunaga T, Ishibashi Y, et al. Augmented rectangle technique for Billroth I anastomosis in totally laparoscopic distal gastrectomy for gastric cancer. *Surgical Endoscopy*. 2018. DOI: 10.1007/s00464-018-6266-1

- [2] He Z, Zang L. Reconstruction after laparoscopic assisted gastrectomy: Technical tips and pitfalls. *Translational Gastroenterology and Hepatology*. 2017;**2**:66
- [3] Japan Society for Endoscopic Surgery: 12th Nationwide Survey of Endoscopic Surgery in Japan. *Journal of Japan Society for Endoscopic Surgery*. 2014;**19**:495-640
- [4] Bandoh T, Shiraishi N, et al. Endoscopic surgery in Japan: The 12th national survey (2012-2013) by the Japan Society for Endoscopic Surgery. *Asian Journal of Endoscopic Surgery*. 2017;**10**:345-353
- [5] Clark CJ, Thirlby RC, Picozzi V, Schembre DB, Cummings FP, Lin E. Current problems in surgery: Gastric cancer. *Current Problems in Surgery*. 2006;**43**:566-670
- [6] Kitano S, Yang H-K. *Laparoscopic Gastrectomy for Cancer*. Springer; 2012. pp. 89-93
- [7] Kanaya S, Gomi T, et al. Delta-shaped anastomosis in totally laparoscopic billroth I gastrectomy: New technique of intraabdominal gastroduodenostomy. *Journal of the American College of Surgeons*. 2002;**195**:284-287
- [8] Omori T, Matsuzawa T, et al. A simple and safe method for Billroth I reconstruction in single-incision laparoscopic gastrectomy using a novel intracorporeal triangular anastomotic technique. *Journal of Gastrointestinal Surgery*. 2014;**18**:613-616
- [9] The Information Committee of Korean Gastric Cancer Association. Korean gastric cancer association nationwide survey on gastric cancer in 2014. *Journal of Gastric Cancer*. 2016;**16**(3):131-140
- [10] *Annals of Surgical Oncology*. 2013;**20**:2676-2682
- [11] Uyama I, Sakurai Y, et al. Laparoscopy-assisted uncut roux-en Y operation after distal gastrectomy for gastric cancer. *Gastric Cancer*. 2005;**8**:253-257