

We are IntechOpen, the world's leading publisher of Open Access books Built by scientists, for scientists

4,800

Open access books available

122,000

International authors and editors

135M

Downloads

Our authors are among the

154

Countries delivered to

TOP 1%

most cited scientists

12.2%

Contributors from top 500 universities

**WEB OF SCIENCE™**Selection of our books indexed in the Book Citation Index
in Web of Science™ Core Collection (BKCI)

Interested in publishing with us?
Contact book.department@intechopen.com

Numbers displayed above are based on latest data collected.

For more information visit www.intechopen.com

The Treatment of Meniere's Disease by the Intratympanic Therapy

*Maria Stella A. Amaral, Henrique F. Pauna,
Ana Claudia M.B. Reis and Miguel A. Hyppolito*

Abstract

Meniere's disease represents one of the most frequent vestibulopathy, with prevalence of 46–200 cases per 100,000, without difference between genders and manifests in fourth decade of life. Features include dizziness/vertigo, hearing loss, tinnitus, and ear fullness. Individuals with Meniere's disease have poor quality of life due to dizziness, regarding physical, functional, and emotional aspects. The therapeutic measures are proposed, depending on the stage of the disease. About 95% of the patients are well controlled with conservative clinical treatment. The remaining 5% have incapacitating symptoms. These patients are candidates for surgical treatments classics, decompression of the endolymphatic sac, vestibular neurectomy, or labyrinthectomy. Intratympanic gentamicin injections emerged as an alternative to surgical treatments, whose risk and benefit ratio has been shown to be much more satisfactory. Aminoglycosides, such as gentamicin have been used since the decade of 1950 for the vestibular chemical ablation in cases of intractable vertigo. The drawback is that gentamicin causes irreversible destruction to cochlear hair cells with hearing loss. The selective vestibulotoxicity in the treatment of Meniere's disease can be used in the treatment of the vertigo promoting a chemical labyrinthectomy.

Keywords: Meniere's disease, vestibulopathy, vertigo treatment, chemical labyrinthectomy, vestibulotoxicity

1. Introduction

Meniere's disease (MD) is a clinical entity characterized by episodic vertigo, fluctuant sensorineural hearing loss (SNHL), tinnitus, and a pressure sensation of the ear. It can happen uni- or bilaterally, and diagnosis is made clinically, according to the classification of the American Academy of Otolaryngology—Head and Neck Surgery, updated in 2015 (**Table 1**) [1, 2]. MD is a chronic condition affecting about 190/100,000 patients in US, a general incidence about 50–200/100,000 per year, and a lower incidence of 17/100,000 per year in Japan [3].

The diagnosis of MD remains eminently clinical and its manifestations are widely variable. Many patients have audiological symptoms, some have mainly vestibular complaints and few patients have a combination of auditory and vestibular symptoms. The bilateral involvement can be observed in 10–50% of the patients, which leads to a condition difficult to treat and with unfavorable prognosis [4].

Definite	Two or more episodes of vertigo* plus audiometrically confirmed low- to medium-frequency SNHL in one ear on at least one occasion before, during, or after one of the episodes of vertigo; fluctuating aural symptoms** in the affected ear; not better accounted for by another vestibular diagnosis
Probable	Two or more episodes of vertigo or dizziness, each lasting 20 min to 24 h; fluctuating aural symptoms** in the affected ear; other causes excluded

*Defined as spontaneous, rotational vertigo lasting 20 min to 12 h.

**Hearing, tinnitus, or fullness.

Table 1.
Criteria of diagnosis of MD.

2. Otopathology

Prosper Meniere, who worked as a director of the first school for the deaf-mute in Paris, described in 1861, a combination of vertigo, imbalance, and hearing impairment reflecting an inner ear disease [1]. But, only in 1937, with the discovery of endolymphatic hydrops (EH) in human temporal bones by Yamakawa and Hallpike and Cairns, the pathologic displacement of Reissner's membrane into the scala vestibuli—and so with the dilation of the scala media of the cochlea—was first established (**Figure 1**) [5].

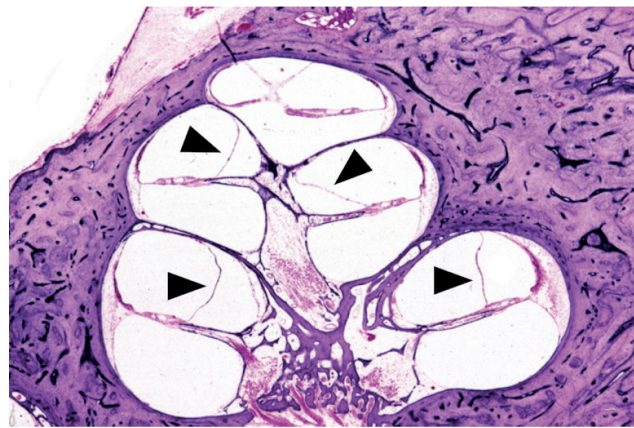


Figure 1.
Reissner's membrane displaced in a temporal bone with hydrops (arrowheads).

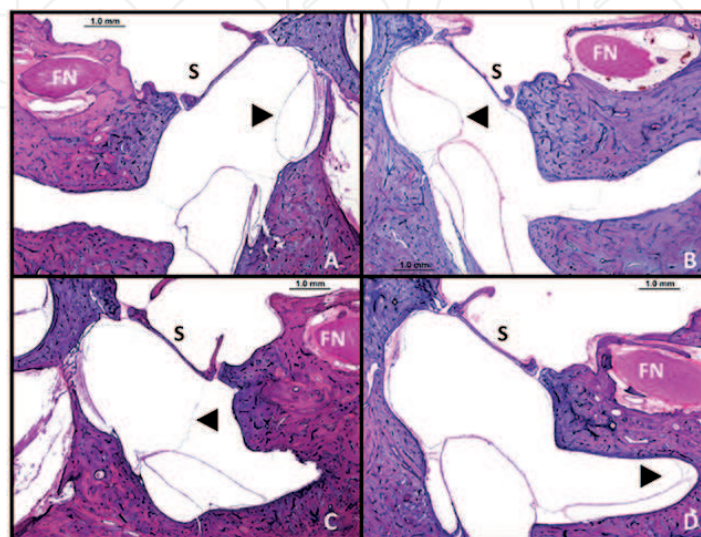


Figure 2.
Membranous structures displaced in MD. The arrowhead points the membranous structure called saccule, in different stages of hydrops (A, normal; B, slight; C, moderate; and D, severe). FN-facial nerve; S-stapes.

Many other disorders can be related with hydrops, as aforementioned: temporal bone fracture, otosclerosis, diabetes mellitus, syphilis, hormonal disorders, migraine, and others. Diseases that can cause MD are as follows: food allergy, dyslipidemia, and autoimmune diseases [3, 6]. These disorders can also affect inner ear composition and displace in various degrees other membranous structures, including saccule, utricle, and the ampullae of the semicircular canals (**Figure 2**) [5].

3. Audiological findings

Several tests and evaluation methods have been employed for the diagnosis of MD. These include audiological tests, vestibular, radiological, clinical, and biochemical parameters. However, the lack of a definitive diagnostic test makes the process of diagnosis sometimes longer or frustrating. For this reason, the professional should be well experienced in the decision of when and what test should be used for the diagnostic process and, especially, to know how to interpret the results [7].

Although MD is not a rare condition, there is a delay in the diagnosis. Probably this is due to factors such as the difficulty of the differential diagnosis between other inner ear diseases, mainly due to the occurrence of nonspecific symptoms in the early stages of the disease and the absence of specific tests, in addition to the floating characteristic of MD which hinders the interpretation of the tests [8].

Patients with hearing loss and balance disorders are commonly diagnosed as having MD, which sometimes characterizes a diagnostic error, due to the lack of specific diagnostic tests [7, 8].

The main objective of early diagnosis is the early intervention, aiming to reduce the frequency and intensity of the crisis of vertigo and, at the same time, to preserve the hearing and vestibular functions [7]. Nonetheless, it is common among patients with MD, psychological suffering and loss in quality of life due to the crisis of vertigo [9, 10].

Some procedures significantly collaborate for the diagnosis of MD; however, it is important to emphasize the correlation of clinical history and symptoms with the results of the behavioral evaluation and testing goals for the conclusion of the case. In MD, a progressive hearing loss occurs with disappearance of vertigo in 70% of cases.

In addition, the audiological evaluation is important in monitoring treatment, as in the case of chemistry labyrinthectomy with gentamicin.

Tonal threshold audiometry is the basic examination used in the process of diagnosis and follow-up of MD and has a decisive role in treatment decisions. The progressive sensorineural hearing loss, with impairment of low frequencies and the fluctuations, is typical result observed in MD.

The degree of hearing loss seems to be related to the stage of the disease and has a relationship with the symptomatic period. It is common for MD patients a sensorineural hearing loss to moderate to severe before or on the first diagnosis. The settings of the hearing loss may vary; the most common is the ascendant or inverted "U." The flat configuration appears in more advanced stages of the disease. However, different audiometric results can be found and variations in the degree and configuration of hearing loss may be observed, depending on the stage of the disease. Although the low frequencies are generally more affected, hearing loss may be present in all frequencies when in an advanced state of the disease, configuring sometimes an audiogram with flat curve [11]. In this way, the diagnosis of MD should not be established in accordance with the configuration of the audiogram, because there is not a specific audiometric pattern [12]. There is no consensus in the literature that the auditory thresholds for pure tone should be investigated, including thresholds of air and bone conduction and, at least for the frequencies 250 Hz–8 kHz. A difference ≥ 10 dB is accepted as the float hearing for the MD.

Relationship was found between the occurrence of fluctuation and the severity or progression of the hearing loss. Authors report that the hearing losses affecting the averages (between 500 and 2000 Hz) and high frequencies (between 3000 and 8000 Hz) suggest a worse prognosis than that one affects the low frequencies (between 125 and 500 Hz) [13]. The value of the results of the hearing evaluation by means of ATL has been shown to be significant, and the cochlear symptoms have been described in the literature as the most common initial sign of the disease and, many times, to appear before the vertigo.

The speech perception tests are also compromised. The percentage index of speech recognition (PISR) and the speech recognition threshold (SRT) are altered in MD [12, 13]. The average score of the PISR, when there is hearing loss can be around 56% or less if the MD is of long duration. In cases of unilateral hearing loss, percentages of PISR worst in relation to expected, considering the results of the auditory thresholds for pure tone. The speech in noise tests has helped in the intervention of the patients with MD; individuals with MD unilaterally submitted to simultaneous labyrinthectomy have improvement in sound localization and in speech understanding with and without competitive noise [13]. Acoustic immittance measures course with a type A configuration tympanometry, although in some patients with severe hearing loss of long term may present tympanometry curve characteristic of tubal dysfunction. The acoustic reflex threshold decreases in cochlear pathologies due to recruitment, the difference between the acoustic reflex thresholds of the frequencies of 500, 1000, and 2000 Hz and the tonal auditory thresholds obtained by air, the same frequencies of 60 dB or less, and outcome goal that suggests the presence of cochlear pathology (recruitment) [13]. It is worth mentioning that the acoustic immittance measures can be very useful in the diagnosis of MD, in cases of MD floating and nonfloating and with respect to the prediction of endolymphatic hydrops reversible and irreversible.

Electrocochleography (ECoChG) can be used for MD diagnosis. The presence of endolymphatic hydrops is determined by the enlargement of the summation potential (SP) in relation to the action potential (AP), reflecting an increase in relation SP/AP. The SP enlargement is more evident when the patient presents fullness and mild hearing loss. In the initial stages of the MD, the increase in the endolymphatic volume alters the hydromechanical properties of cochlear stretching medium scale and changing SP. The specificity of the relationship SP/AP is larger than the sensitivity in MD. The increase of SP/AP relationship suggests the diagnosis of MD, but only in about 50% of the cases, the disease really exists [13].

4. Available treatments

The characteristics of the MD are well documented, as well as the treatments for this pathology. The available literature is focused to identify the etiology and how to clinically approach the symptomatic patient. The symptomatic treatment can be pharmacological and/or surgical.

The symptomatic treatment does not prevent the progression of the disease. This treatment may involve diet, vestibular therapy, and drug treatment [11]. In acute vertigo crisis, drugs that block the vestibular reflexes in the vestibule-cerebral shaft can be used. They are chlorpromazine, cinnarizine, promethazine, and diazepam [5, 14].

The endolymphatic hydrops found in MD is treated aiming to prevent its progression. In this way, there is a low sodium diet and use of diuretics, such as furosemide and hydrochlorothiazide [6].

Vasodilators are used for long-term treatment based on the fact that the hydrops can be caused by ischemia of the stria vascularis. Currently, the medical treatment of maintenance is betahistine with or without diuretic [6, 10].

5. Symptomatic chemical-surgical treatment

Studies have shown that the toxic effects of aminoglycosides in the sensorineural epithelium of the inner ear, particularly in the labyrinth, can be considered as a therapy for MD [6, 10].

In cases of MD with bilateral vestibular symptoms is difficult to control and with important hearing loss, has already been given in the past to ablation of the maze with systemic aminoglycosides because they control the vertigo. However, the cumulative doses of aminoglycosides increase the risk of ototoxicity with permanent cochlear damage and the possibility of causing ataxia and oscillopsia. Currently, with the possibility of injecting substances via transtympanic route, the indications for systemic use of aminoglycosides are limited [15].

6. Surgical treatment

In about 70% of the cases, MD evolves to progressive hearing loss with improvement to the vestibular symptoms. For the other 30% who do not present an improvement of vestibular symptoms, even with the clinical treatment, surgical treatment should be thought.

The decision to operate and the choice of procedure are often dictated by the understanding and experience of each surgeon [3]. Surgical treatment to be considered varies from conservative to destructive, depending on whether or not there is a hearing loss [3]. The surgery that is the most popular is the endolymphatic sac decompression, and it is known as a conservative surgical procedure and is widely accepted.

This surgery was first described by Portmann, in 1927, but the precise role by which the surgery works remains undefined [16]. Among the destructive surgical treatments, we have a vestibular neurectomy, the cochleo-sacculotomy, the transcanal labyrinthectomy, or postauricular labyrinthectomy [4].

7. Transtympanic treatment

The use of systemic aminoglycosides was replaced by intratympanic gentamicin instillations that are administered once a day by a limited number of days. The intratympanic administration of drugs for the treatment of the MD was primarily described by Schuknecht in 1957 [17]. The intratympanic injections of gentamicin provide a high rate of success in the control of vertigo with reduced number of side effects on hearing [18, 19].

The intratympanic injections of gentamicin were proposed by Stokroos. After anesthesia of the tympanic membrane, gentamicin is administered in the middle ear through a fine needle of lumbar puncture in a fixed dose of 30 mg/ml [20, 21].

One other substance that can be used is steroid, which may decrease the inflammatory reaction in the inner ear, thus decreasing the endolymphatic hydrops. It has been reported that the use of corticosteroids may help to control the inner ear dysfunction, thereby decreasing vestibular symptoms up to 91% of MD patients (with 1–4 injections of dexamethasone at a concentration of 12 mg/ml) [22, 23].

Another substance to be injected is methylprednisolone, with higher concentrations and with the possibility to last longer in the perilymph. However, many authors described data suggesting same effectiveness of both steroids [24, 25].

Both gentamicin and steroids are absorbed by perilymph through the round window membrane (which is semipermeable), the annular ligament of the oval window, and by the small lacunar mesh that surrounds the inner ear [25].

A randomized, double-blind controlled study compared the use of transtympanic gentamicin (40 mg/ml) and corticosteroids (methylprednisolone [62.5 mg/ml]), and no difference was observed regarding the effectiveness of both groups of treatments [26].

8. Injection protocols

1. Patient positioned at supine position;
2. Head is positioned in a slightly hyper-extension with 30° contralateral rotation;
3. Instillation 2% lidocaine in ear canal, removing completely after 15 min;
4. Under microscopic examination, tympanic membrane is anesthetized with 80–90% phenol solution at inferior and posterior tympanic membrane quadrant;
5. In few minutes, the transtympanic access could be performed using a spinal needle and a flexible catheter mounted on an insulin syringe;
6. Slow instillations of 1 ml of 26–40 mg/ml, not buffered with bicarbonate sodium in two 0.5 ml injection with 30 min apart;
7. Patient remained motionless for 30 min.

This protocol can be repeated each week or monthly for six times.

To maintain auditory function, patients must be evaluated with tone pure audiometry on every 2 weeks or before beginning each section. The treatment must be stopped in case of hearing thresholds becoming higher than 10 dB or in a case of decreasing in speech audiometry of more than 15%. A supportive drug treatment may be necessary until the vertigo control. A pretreatment auditory test is very important. The bone conduction pure tone thresholds average (0.5, 1.0, 2.0, and 3.0 kHz) is considered and repeated every 2 weeks and 2 weeks after treatment. The final audiometric exam is performed up to 12 months after transtympanic protocol initiation.

The success rate in transtympanic injection of gentamicin is about 87% in vertigo control, being a simple and safe procedure with few risks to hearing loss and tympanic membrane perforation [24, 27].

Acknowledgements

The authors wish to thank FAEPA and CAPES.

Conflict of interest

No conflict of interest.

IntechOpen

Author details

Maria Stella A. Amaral¹, Henrique F. Pauna¹, Ana Claudia M.B. Reis² and Miguel A. Hyppolito^{1*}

¹ Department of Ophthalmology, Otorhinolaryngology and Head and Neck Surgery, Ribeirão Preto Medical School—University of São Paulo, Ribeirão Preto, São Paulo, Brazil

² Department of Health Sciences, Ribeirão Preto Medical School—University of São Paulo, Ribeirão Preto, São Paulo, Brazil

*Address all correspondence to: mahyppo@fmrp.usp.br

IntechOpen

© 2019 The Author(s). Licensee IntechOpen. This chapter is distributed under the terms of the Creative Commons Attribution License (<http://creativecommons.org/licenses/by/3.0>), which permits unrestricted use, distribution, and reproduction in any medium, provided the original work is properly cited. 

References

- [1] Gürkov R, Pyykö I, Zou J, Kentala E. What is Ménière disease? A contemporary re-evaluation of endolymphatic hydrops. *Journal of Neurology*. 2016;**263**:71-81
- [2] Lopez-Escamez JA, Carey J, Chung W-H, et al. Diagnostic criteria for Ménière's disease. *Journal of Vestibular Research*. 2015;**25**:1-7
- [3] Wright T. Ménière's disease. *BMJ Clinical Evidence*. 2015;**11**:505
- [4] Saeed SR. Fortnightly review. Diagnosis and treatment of Ménière's disease. *British Medical Journal*. 1998;**316**(7128):368-372
- [5] Salt AN, Plontke SK. Endolymphatic hydrops: Pathophysiology and experimental models. *Otolaryngologic Clinics of North America*. 2010;**43**(5):971-983
- [6] Soderman AC, Bagger-Sjoberg D, Bergenius J, Langius A. Factors influencing quality of life in patients with Ménière's disease, identified by a multidimensional approach. *Otology & Neurotology*. 2002;**23**(6):941-948
- [7] Brookes GB. The pharmacological treatment of Ménière's disease. *Clinical Otolaryngology and Allied Sciences*. 1996;**21**(1):3-11. Review
- [8] Maudonnet EN, de Oliveira JA, Rossato M, Hyppolito MA. Gentamicin attenuates gentamicin-induced ototoxicity—Self-protection. *Drug and Chemical Toxicology*. 2008;**31**(1):11-25
- [9] Strose A, Hyppolito MA, Colombari GC, Rossato M, Oliveira JA. Lack of protection against gentamicin ototoxicity by auditory conditioning with noise. *Brazilian Journal of Otorhinolaryngology*. 2014;**80**(5):390-396
- [10] Hellström S, Ödkvist L. Pharmacological labyrinthectomy. *Otolaryngologic Clinics of North America*. 1994;**27**:307-315
- [11] Güneri EA, Çakır A, Mutlu B. Validity and reliability of the diagnostic tests for Ménière's disease. *Turkish Archives of Otorhinolaryngology*. 2016;**54**:124-130
- [12] Hoa M, Friedman RA, Fisher LM, Derebery MJ. Prognostic implications of and audiometric evidence for hearing fluctuation in Ménière's disease. *The Laryngoscope*. 2015;**125**(12):S1-S12
- [13] Carey JP. Ménière's disease. *Handbook of Clinical Neurophysiology*. Elsevier; Baltimore, United States: 2010. pp. 371-381. DOI: 10.1016/S1567-4231(10)09028-3
- [14] Santos PM, Hall RA, Snyder JM, Hughes LF, Dobie RA. Diuretic and diet effect on Ménière's disease evaluated by the 1985 Committee on Hearing and Equilibrium guidelines. *Otolaryngology and Head and Neck Surgery*. 1993;**109**(4):680-689
- [15] Nedzelski JM, Schessel DA, Bryce GE, Pheiderer AG. Chemical labyrinthectomy local application of gentamicin for the treatment of unilateral Ménière's disease. *The American Journal of Otology*. 1992;**13**:18-22
- [16] Portmann G. Vertigo: Surgical treatment by opening the saccus endolymphaticus. *Archives of Otolaryngology*. 1927;**83**:316-319
- [17] Beck C. Intratympanic application of gentamicin for treatment of Ménière's disease. *The Keio Journal of Medicine*. 1986;**35**(1):36-41
- [18] Cohen-Kerem R, Kisilevsky V, Einarson TR, et al. Intratympanic gentamicin for Ménière's disease: A

meta-analysis. *The Laryngoscope*. 2004;**114**:2085-2091

[19] Diamond C, O'Connell DA, Hornig JD, et al. Systematic review of intratympanic gentamicin in Ménière's disease. *The Journal of Otolaryngology*. 2003;**32**:351-361

[20] Stokroos R, Kingma H. Selective vestibular ablation by intratympanic gentamicin in patients with unilateral active Meniere's disease: A prospective, double-blind, placebo-controlled, randomized clinical trial. *Acta Oto-Laryngologica*. 2004;**124**(2):172-175

[21] Sam G, Chung DW, van der Hoeven R, Verweij S, Becker M. The effect of intratympanic gentamicin for treatment of Ménière's disease on lower frequency hearing. *International Journal of Clinical Pharmacy*. 2016;**38**(4):780-783. DOI: 10.1007/s11096-016-0295-4

[22] Trune DR, Kempton JB, Kessi M. Aldosterone (mineralocorticoid) equivalent to prednisolone (glucocorticoid) in reversing hearing loss in MRL/MpJ-Fas1pr autoimmune mice. *The Laryngoscope*. 2000;**110**:1902-1906

[23] Boleas-Aguirre MS, Lin FR, Della Santina CC, Minor LB, Carey JP. Longitudinal results with intratympanic dexamethasone in the treatment of Ménière's disease. *Otology & Neurotology*. 2008;**29**(1):33-38. DOI: 10.1097/mao.0b013e31815dbafc

[24] Parnes LS, Sun AH, Freeman DJ. Corticosteroid pharmacokinetics in the inner ear fluids: An animal study followed by clinical application. *The Laryngoscope*. 1999;**109**(7 Pt 2):1-17

[25] Patel M. Intratympanic corticosteroids in Ménière's disease: A mini-review. *The Journal of Otolaryngology*. 2017;**12**(3):117-124. DOI: 10.1016/j.joto.2017.06.002

[26] Patel M, Agarwal K, Arshad Q, et al. Intratympanic methylprednisolone versus gentamicin in patients with unilateral Meniere's disease: A randomized, double-blind, comparative effectiveness trial. *Lancet*. 2016;**388**(10061):2753-2762

[27] Chia SH, Gamst AC, Anderson JP, et al. Intratympanic gentamicin therapy for Ménière's disease: A meta-analysis. *Otology & Neurotology*. 2004;**25**:544-552