

We are IntechOpen, the world's leading publisher of Open Access books Built by scientists, for scientists

4,800

Open access books available

122,000

International authors and editors

135M

Downloads

Our authors are among the

154

Countries delivered to

TOP 1%

most cited scientists

12.2%

Contributors from top 500 universities



WEB OF SCIENCE™

Selection of our books indexed in the Book Citation Index
in Web of Science™ Core Collection (BKCI)

Interested in publishing with us?
Contact book.department@intechopen.com

Numbers displayed above are based on latest data collected.

For more information visit www.intechopen.com



Turbinate Surgery in Chronic Rhinosinusitis: Techniques and Ultrastructural Outcomes

Giampiero Neri, Fiorella Cazzato, Elisa Vestrini, Pasquina La Torre, Giampaolo Quaternato, Letizia Neri and Lucia Centurione

Abstract

Chronic nasal obstruction due to hypertrophic rhinitis is commonly associated with perennial allergic and nonallergic rhinitis. It is not a simple enlargement of mucosal and submucosal tissues, but it is characterized by deep histological modifications. This pathology, a very frequent condition encountered in rhinological practice, has a significant impact on quality of life. Patients usually complain about sneezing, rhinorrhea, frontal headache, postnasal drip, snoring, blocked nasal ducts, and sleep disorders. When medical therapy fails, surgical reduction of inferior turbinates is mandatory. A large variety of surgical techniques in literature exist, but there is a lack of consensus about which is the proper technique to perform. In this chapter, we describe the most important techniques of inferior turbinate reduction with advantages and disadvantages of each one.

Keywords: turbinate hypertrophy, nasal obstruction, nasal surgery, techniques, turbinoplasty

1. Introduction

Chronic nasal obstruction is a very frequent condition in rhinological practice that severely interferes with the quality of life [1]. The most common cause of this complaint is chronic hypertrophic rhinitis. It consists of a chronic swelling of the inferior turbinate [2].

Turbinate hypertrophy, commonly associated with perennial allergic and nonallergic rhinitis [1], is not a simple enlargement of mucosal and submucosal tissues, but it is characterized by deep histological modifications such as severe damage of the epithelial barrier, disappearance of ciliated and goblet cells, inflammatory infiltration of the lamina propria, fibrosis, prominent venous congestion, and basement membrane interruption [2].

Patients generally complain about sneezing, rhinorrhea, postnasal drip, frontal headache, blocked nasal passages, sleep disturbance, and snoring [3].

When medical treatment with topical corticosteroids, antihistamines, and decongestants fails, surgical reduction of inferior turbinates could be attempted.

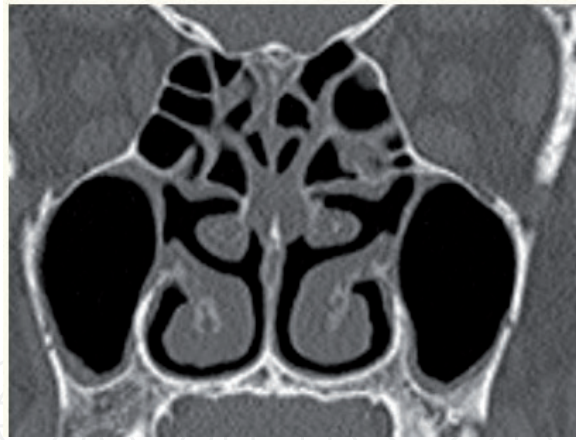

Figure 1. The radiologic study with head-CT shows a normal anatomy of the turbinates and the nasosinusal system.

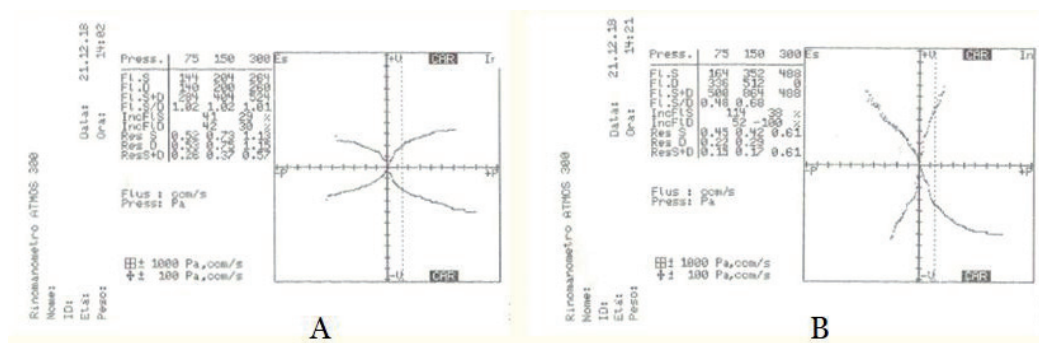


Figure 2. Rhinomanometric evaluation before (A) and after (B) application of nasal topical decongestant shows the improvement of respiratory nasal flux.

The goal of turbinate surgery is to improve nasal patency by minimizing complications such as postoperative hemorrhage, crusting, foul odor, and the “empty nose syndrome” [4].

There is a variety of turbinate procedures, but there is a lack of consensus about which technique is the best [5].

Turbinate hypertrophy can be divided into primary and secondary. The primary hypertrophy is related to the submucosal component, while the secondary hypertrophy is due to contralateral septal deviation and is related to the bony component of the turbinate. It is important to distinguish these two types of hypertrophy in order to decide the proper procedure to perform. The anatomic radiologic study (Figure 1) and the rhinomanometric evaluation (Figure 2) are mandatory for surgical indication [6].

2. Surgical techniques

Turbinate reduction techniques can be divided into four categories [7]:

1. Extramucosal debulking procedures
2. Superficial extramucosal procedures
3. Dislocation procedures
4. Submucosal procedures

2.1 Extramucosal debulking procedures

These procedures include:

1. Total turbinectomy
2. Partial turbinectomy
3. Microdebrider-assisted turbinoplasty (extramucosal technique)

2.1.1 Total turbinectomy

It is a technique that was described for the first time in the last 10 years of the nineteenth century. Jones in 1895 and Holmes in 1900 introduced the concept of total turbinectomy [8].

This technique is considered the most radical surgical technique on the inferior turbinate. After having fractured, the bone plate of the inferior turbinate (**Figure 3**), levering from the inferior meatus, with an angled scissors, the inferior turbinate is dissected for its entire length remaining adherent to the lateral wall of the nasal cavity.

For the immediate benefit that the patient obtains, it is often considered as safe and effective though its major complication is the possible bleeding, avoidable, however, both using adequate nasal swabs and avoiding to treat patients who take anticoagulants [9].

Unfortunately, this type of surgery, extremely aggressive, can later lead to dry nose syndrome or even the syndrome of the empty nose with a paradoxical obstruction. The obstructive event is due to the loss of normal nasal resistance and the formation of a laminar air column. This situation causes a poor contact between the air and the nasal walls, the mucosa, due to the absence of the sensory fibers of the inferior turbinate, shows a reduction or even a loss of the respiratory flow [6].

The altered aerodynamics pattern, due to total turbinectomy, generates many complications such as copious postoperative bleeding, quantitative reduction of the ciliary movement, mucosal dryness, and deficit of mucus clearance. All this

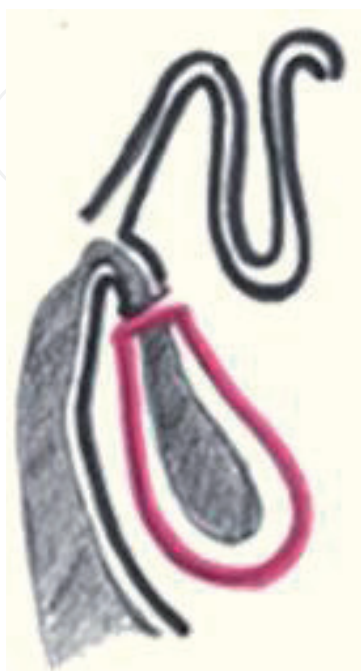

Figure 3.
Total turbinectomy.

creates stagnation of secretions, crusts formations (sometimes foul-smelling), and frequent infections with gradual development of dry inflammatory forms affecting the pharynx and larynx. Precisely because of its complications, this technique has now fallen into disuse [9].

TASCA states that it is wrong to transform the nasal cavities into rigid and inanimate tubes, unable to perform the functions of congestion and decongestion, depriving them of their natural function [10]; and for Huizing and de Groot, total turbinectomy is a nasal crime, and they do not consider it useful to perform the resection of more than a third or half of the inferior turbinate unless it is a tumor [11].

2.1.2 Partial turbinectomy

The partial turbinectomy (**Figure 4**) is used to limit the large surgical resections that are performed with total turbinectomy, and consists in the removal of the mucosa and bones of the anterior third of the inferior turbinate. The degree of resection is directly proportional to the degree of hypertrophy. Initially, the mucosal and the submucosal tissue are removed, and if there is bone hypertrophy, a small bone resection is also performed. There are several partial turbinectomy techniques.

The oldest technique is the crushing and trimming introduced by Kressner in 1930. Other technique is selective mucosotomy, which consists of the removal of the anterior or/and the posterior region of the turbinate following defined section lines. The diagonal resection consists in a sagittal exeresis with the purpose of preserving the head of the turbinate and eluting the posterior region of the turbinate. The horizontal resection of the inferior edge of the turbinate avoids the risk of bleeding from the sphenopalatine artery [12], which instead occurs in the diagonal resection [7].

The degloving technique was proposed by Chevetton et al. It consists of the resection of a large part of the turbinate, leaving the bone and the periosteum intact [7, 13].

TASCA et al. reported that the only appropriate techniques are “Crushing with remodeling” and “Resection of the tail.” It is preferable to perform a resection of the posterior region of the inferior turbinate, because the elimination of the head of turbinate causes a great functional damage. It creates a deficit of the mucociliary clearance and the inferior turbinate loses its function of directing the inspiring currents [10].

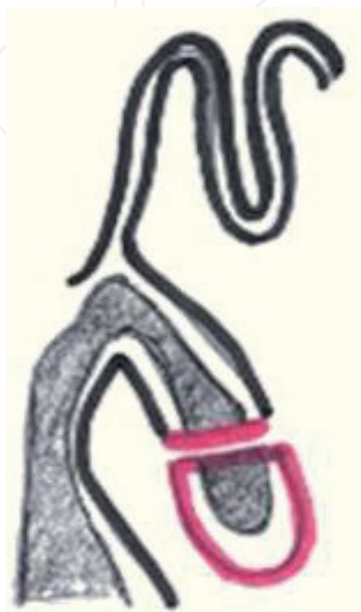

Figure 4.
Partial turbinectomy.

Crushing with remodeling is indicated if the hypertrophy is both anterior and posterior and allows to respect the functional capacity of the remaining portion of the turbinate. The turbinate is compressed using specific pliers and then reduced by cutting parallel or slightly diagonal strips starting from the lower edge. After the medial fracture of the turbinate performed with a smooth and chamfered instrument (the handle of a Cottle chisel can be used), it is squeezed with modified-Kressner tongs both anteriorly and posteriorly. The size of the turbinate is reduced by removing a strip from its rather flaccid bottom edge with Heymann-type scissors. If necessary, a part of bone is removed. Finally, the turbinate remaining laterally is repositioned. It is advised to perform a second surgical time if the hypertrophic tissue is excessive, avoiding to remove it in a single time [14].

Resection of degenerated tissue: if a part of the turbinate is damaged irreversibly, it is removed using long angled scissors or a loop [14].

Even if partial inferior turbinectomy is a simple and effective surgical procedure, it is equally troublesome if not performed correctly. Excessive resection of the inferior turbinate can lead to peri- or postoperative bleeding, from medial and inferior surface of the inferior turbinate, synechiae with the nasal septum and floor of nasal cavity, frequent post nasal blood drip, nasal crusting, and atrophic rhinitis. By using appropriate tools and limiting demolition, these complications can be avoided [15].

A study by Passali et al. demonstrated how the partial turbinectomy technique performed at the level of the inferior turbinate resolves most of the nasal obstruction. This technique however, even if minimally, causes damage to the nasal mucosa and therefore it is necessary that the surgeon is experienced to avoid complications [1, 16].

Sapci et al. reported that the use of radiofrequency to reduce hypertrophy of turbinates leads to an improvement of nasal obstruction and does not alter the ciliary mucus clearance. With the partial turbinectomy technique, the results obtained were similar to those of results with the radiofrequency tissue ablation technique [1, 17].

Salzano et al. enrolled four groups of patients each treated with radiofrequency, high-frequency electrocautery treatments, and lower partial turbinotomy to reduce the hypertrophied lower turbinates. They show that the partial inferior nasal turbinectomy is the best method of treatment, because it does not cause damage to the nasal mucosa or underlying sensibility nerves [18].

In the 1996, the microdebrider was first used by Davis and Nishioka to remove both medial and inferior redundant mucosal tissue and hypertrophied cavernous sinusoid of the inferior turbinate and the anterior head region of the inferior turbinate, up the superficial layer to the periosteum [19].

Generally, if the microdebrider-assisted turbinoplasty is limited to the decongestion of the turbinates only, the patient undergoes local anesthesia with vasoconstrictive drugs to create a large ischemia avoiding intraoperative bleeding. General anesthesia is necessary in the event that a septal or paranasal sinus surgery is also associated. In our experience, the local anesthesia is performed using soaked gauzes with Xylocain hydrochloride 5% and naphazoline 0.02% set on the nasal floor and on the medial wall of the inferior turbinate. We have left the infiltration of the turbinate and given the possible neurovegetative complications described by Ravikumar et al. [20].

This procedure is performed under the endoscopic guidance using an 0° endoscope 4-mm diameter. The microdebrider is a device that consist of a handpiece on which is positioned a rotating blade protected by a blunt end that sucks and removes the hypertrophic tissue. The surgeon moves the blade of the microdebrider, with 2300–3000 rev/s speed of oscillation, along the inferior turbinate from posterior to anterior region and with continuous suction. It is suggested to proceed in posteroanterior direction to obtain a clean field, free of blood. The timing of

surgery necessary to accomplish the procedure is about 1–2 min long for each nasal cavity [3, 20]. At the end of the surgery, nasal packing of variable length between 8 and 10 cm are placed.

Nasal packing are used to prevent postoperative bleeding and to fill the dead space inside the nasal cavity [21], where it remains only for 48 h and does not change the functional recovery of the mucosa [3]. The patient is advised to instill nasal drops containing vitamin A and Vaseline oil for about a month after surgery [3].

Microdebrider technique is mainly discussed because of its supposed interference on mucociliary clearance.

According to Lee and Lee [21], the microdebrider causes minimal mucosal damage that does not significantly modify the ciliary mucus transport time. In fact, the entire respiratory epithelium of the nasal cavities, and not only the mucosa of the inferior turbinate, is responsible for this physiological mechanism.

According to a study conducted by our University Clinic in the 2012, the microdebrider does not damage the respiratory epithelium, but rather stimulated its regeneration. Studies conducted on animal models have shown that basal cells move the bare mucosa forward after a mechanical injury. The cells undergo transient squamous metaplasia, and then they differentiate both goblet and ciliated cells. This mechanism has also been demonstrated in human nasal cavities. The debridement of the mucosa leads to an improvement in nasal obstruction, rhinorrhea, hyposmia, headaches, snoring, and postnasal drip. It is never associated with consequences such as dryness, crusts, or nasal irritation or with alteration of mucosal function [3].

According to a study conducted by Van et al. [22], the use of the microdebrider technique allowed a success of 93% and only 17 patients presented temporary complications such as bleeding, crusting, and synechia [21]. Lee and Lee have demonstrated, through a 2006 study, that the use of the microdebrider is more effective than the group of patients who have been treated with coblation in obstructive symptomatology and in reducing the volume of the mucosa of the head of the inferior turbinate 12 months after the intervention [21]. It has been defined as the best technique for the treatment of inferior turbinates hypertrophy [3].

2.2 Superficial extramucosal procedures

Superficial extramucosal procedures include

1. Laser-assisted ablation
2. Electrocautery
3. Chemosurgery
4. Cryoturbinectomy
5. Argon plasma coagulation
6. Infrared coagulation

2.2.1 Laser-assisted ablation

Argon laser has been the first application of laser surgery for inferior turbinate, and has been performed by Lenz et al. in 1977 [23], even if was popularized only in the 1990s [24].

Laser surgery has been described with many different procedures such as interstitial, contact, or noncontact. This technique has been performed in topical anesthesia, with slow risk of bleeding, with high compliance of patient.

Many types of lasers have been used for turbinate reduction. They differ in wavelength: CO₂ (λ : 10,600 nm), diode (λ : 940 nm), Ho:YAG laser (λ : 2080 nm), Nd:YAG laser (λ : 1064 nm), argon-ion (λ : 488–514 nm), and potassium-titanyl-phosphate (KTP) with a wavelength similar to Argon laser [25].

The CO₂ laser, Nd:YAG laser, and diode laser has been the light source most used [10] in surgery. Pulsed light mode has been safer than continuous light mode with lesser local damage.

The application of light can be straight as longitudinal strip (laser-strip carbonization) with cross-light beams (cross hatched) and in “single-spots” at a range of 1–2 mm. The most used is the laser strip carbonization. Many studies showed that the best use of this kind of laser for the turbinate is “single-spots,” because to be able to preserve healthy portions of mucous for the rapid epithelization [26].

The CO₂ laser has a high cutting precision and superficial vaporization, but is not more maneuverable; above all, for the posterior section of the inferior turbinate, indeed it does not have a flexible optical fiber. CO₂ laser has worse capacity of coagulation, higher price, and worse handling than Ho:YAG, argon-ion, Nd:YAG, and KTP lasers.

Diode laser has been used for the turbinate surgery because it has a good capacity of coagulation of soft tissue with minimal risk to damage the periosteum [27].

YAG laser has a good capacity of penetration of deep tissue respecting the superficial epithelium with a good intraoperative hemostasis but in literature has been reported the presence of post operative edema with an initial respiratory obstruction, for this reason its use has greatly reduced over time [28].

Potassium titanyl phosphate (KTP) laser is an efficient method to treat a tissue with a high vascularity, as the inferior turbinate had a wavelength that is selectively absorbed by endogenous chromophore as melanin and hemoglobin [29]. In this way, it has a selective action toward submucosal tissue, sparing surface mucosa. Tissue sample treated with KTP surgery is evaluated macroscopically and histologically: necrotizing sialometaplasia, cartilage destruction, and dilated glands with excess mucus occurred, whereas cilia were present [30].

Many authors agree that laser surgery produces permanent histologic changes in turbinate soft tissue [31]: reduction of gland serum mucous and damage of the superficial epithelium with reduction of mucociliary transport [32]. All these change have implications for the postoperative period with presence of scabs and dry mucous. Despite its first listed disadvantages, CO₂ laser is the least damaging of all lasers [33].

2.2.2 Electrocautery

This method uses the heat to clot the soft tissue, causing necrosis and fibrosis with volume reduction of the turbinate. The risk of intra- and postoperative bleeding is uncommon, but the presence of scab and scarring is frequent. Due to the high temperature achieved, this technique is destructive on the mucous and can reduce the efficiency of mucociliary transport [34]. The electrocautery exist in two modalities: monopolar and bipolar. The use of bipolar mode is safer and more effective for significant nasal obstruction reduction [35].

2.2.3 Chemosurgery

In 1926, Denker and Kahler described the use of trichloroacetic acid [36] (TCA) solution to the inferior turbinate in the hypertrophic rhinitis. The effect of TCA

consists in protein degeneration [37]. This action on turbinate mucosa is aggressive and damages the mucociliary function. We can study the mucociliary function with the “saccharine time” (ST) [36]: when a saccharine granule is adhered to the nasal mucosa it is dissolved within 1 min, the molecules are then transported to the nasopharynx where the patient recognizes the sweet taste, if the ST is short there is an efficient mucociliary function. In 2008, many authors showed that the “saccharine time” (ST) has been reduced in the early and late period after the TCA application. TCA treatment can induce inhibition of Th2 cell infiltration, a condition typical of allergic rhinitis [38].

2.2.4 Cryoturbinectomy

This method is characterized by an application on the surface of inferior turbinate of nitrous oxide for a period of 90–120 s at the $-40/-80^{\circ}\text{C}$. The cryotherapy causes the formation intracellular of ice crystals and the demolition of cell membrane [39]. A recent paper suggests that regeneration of healthy ciliated nasal epithelium is a constant feature without evidence of scarring [40]. The efficacy on vasomotor rhinitis has been showed [39], but is not sustainable overtime [41].

2.2.5 Argon plasma coagulation

Argon plasma coagulation (APC) originally has been used on gastrointestinal lesions under endoscopy then it has been introduced into otolaryngological field [42]. In this method, the current flow is conducted through ionized argon gas (so-called plasma) [43]. The equipment consists of a deliverer of argon gas connected to a high-frequency current generator; the argon, ionized by the monopolar current, covers the surface of the area to be coagulated, without touching it, with a penetration inside the tissue of not more than 2–3 mm [44]. The short tissue vaporization, the rapid application, and the very short propagation of postcoagulation smoke bring further advantages in the performance of small operations in restricted areas as into nasal region [45].

2.2.6 Infrared coagulation

Infrared coagulation (IC) has been performed for the first time in 1975 by Nath and Kiefhaber [45]. The light reflects from a 15-V tungsten-halogen lamp from a gold surface. The reflected light has been a spectral maximum in the infrared range: 10,000 Å. The tip causes a thermal necrosis on the tissue at 100°C without surface adhesion or carbonization [46]. IC of inferior turbinate seems to be easy to use and safe. It has low cost and patient acceptance. These features make it an attractive alternative to other methods currently used for turbinate reduction [46]. However, the efficacy of this method is especially on the head of inferior turbinate, because the tip is bulky and has an angle of 30° with their column and is hard to perform on the posterior portion of the turbinate [46].

2.3 Turbinate dislocation techniques

Turbinate dislocation techniques include:

1. Inferior turbinate lateralization (or outfracture)
2. Conchopexy

2.3.1 Inferior turbinate lateralization

The inferior turbinate lateralization is a routinely performed procedure. It is a simple technique introduced by Killian in 1904 in order to avoid turbinectomy complications [34, 47]. It is usually performed by using a Goldman or a Freer elevator or a long nosed nasal speculum. The procedure usually begins with an infracture of the inferior turbinate bone (the inferior aspect of the turbinate is pulled medially). An external force is then applied to the turbinate leading to a bone fracture and a dislocation of the turbinate to the lateral nasal wall (**Figure 5**) [48]. This procedure does not modify the anatomy of the surrounding structures, dislocate the uncinate process [49], and close the Hassner valve; hence, there is no blockage of lacrimal duct.

However, the outfracture provides only a temporary improvement of nasal respiration, because the dislocated turbinate often resumes its original position [50]. Generally, this procedure is associated with septoplasty or rhinoplasty. It is also associated with other turbinate reduction techniques because it does not treat the hypertrophy of the turbinate. It is particularly indicated in cases of bony hypertrophy. In order to perform this procedure, it is necessary that the inferior meatus is sufficiently large to contain the dislocated turbinate [51].

In 1990, O'Flynn et al. invented the "multiple submucosal outfracture" (**Figure 6**) in order to improve the efficacy of the outfracture procedure: a little incision is practiced at the cephalic portion of the turbinate near the turbinate bone; the mucosa and the submucosa are elevated with a periosteal elevator and the turbinal bone is fractured into six to eight portions and the bony fragments are dislocated laterally [52].

2.3.2 Conchopexy or concho-antropexy

It was described for the first time by Fateen in 1967. It consisted in a dislocation of the inferior turbinate into the maxillary sinus after antrostomy or demolition of part of the lateral nasal wall [53]. Although the efficacy of this technique had no success, it is now considered obsolete.

2.4 Submucosal procedures

Submucosal procedures include:

1. Submucous resection (or turbinectomy)
2. Cold technique turbinoplasty
 - i. With manual instrumentation
 - ii. With electronic tools
3. Thermal turbinoplasty
 - i. Diatermocoagulation
 - ii. Laser surgery
 - iii. Radiofrequency (RFAIT)
 - iv. Radiofrequency coblation technique (RFCT)

v. Ultrasound

vi. Quantic molecular resonance

vii. Submucosal corticosteroids injection

2.4.1 Submucous resection

Submucous resection was first described by Spielberg in 1924 [54] and then elaborated by Howard House in 1951 [32]. It consists of removing the inferior turbinal bone and the submucosal erectile tissue with preservation of the overlying mucosa [55]. A premedication with vasoconstrictors and local anesthetics is used for both the medial and lateral surfaces of the turbinal mucosa. The Freer knife is used to perform incision over the head of turbinate and is inserted to the previously exposed anterior edge of the conchal bone. The mucosa is separated from the bone by repeated small cutting strokes. The mucoperiosteum is separated from the medial and the lateral surfaces of the bone for a distance of 1.5 cm. The thick

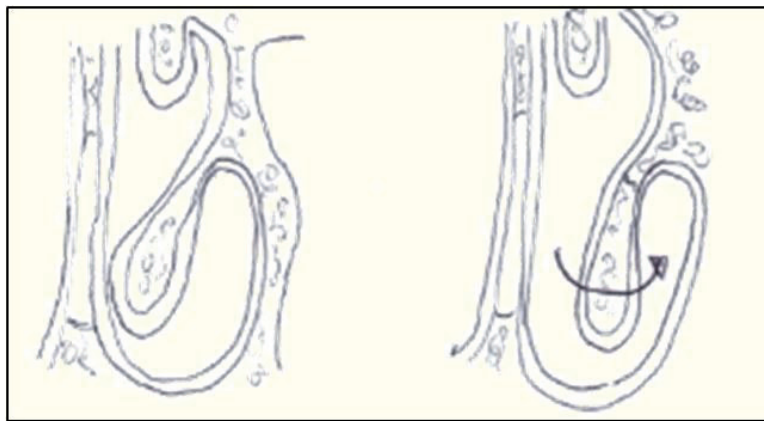


Figure 5.
Inferior turbinate outfracture.

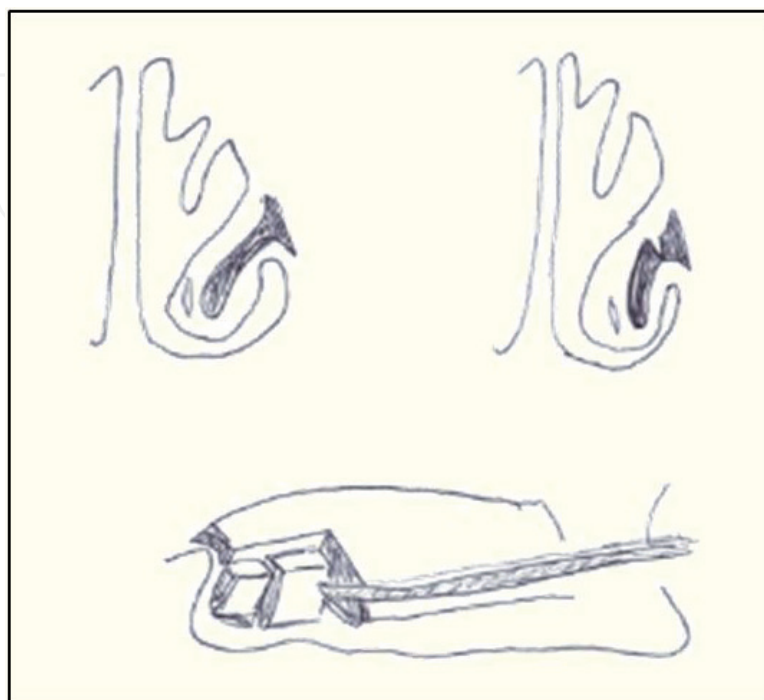


Figure 6.
Multiple submucosal outfracture.

anterior portion of the turbinal bone is grasped with the Takahashi forceps, rotated and then removed. The remaining 2/3 of the bones are very thin, so there is no need to remove it. Sutures are not necessary [32]. By maintaining the mucosal flaps, the normal nasal function is preserved. There is a minimum risk for crusts formation, except for the incision site. There is a low risk for postoperative bleeding, but postoperatively nasal packing is necessary. This technique is particularly effective in cases of prominent bony hypertrophy. A mucosal shredding in inexperienced hands may occur [55]. The submucosal resection leads to fibrosis of the submucosal tissue from the deep layers of the turbinate with the reduction of the immunocompetent cells and IgE. The resection also provokes a damage of the postnasal nerve fibers resulting in the reduction of sneezing and rhinorrhea in allergic patients [56, 57].

2.4.2 Cold turbinoplasty

2.4.2.1 Cold turbinoplasty with manual instrumentation

Turbinoplasty was first described by Mabry in 1982 (**Figure 7**). According to Mabry's technique, a No. 15 blade is used to make an incision from the inferior tip of the turbinate, down to the level of conchal bone, until the posterior edge of the turbinate. A mucosal flap is prepared and elevated from the medial surface. The inferior and lateral part of the turbinate (including bone, soft tissue and lateral mucosa) are then removed with forceps. The residual mucosal-covered soft tissue flap is then curled upon itself to form a "neoturbinate" [58].

2.4.2.2 Cold turbinoplasty with electronic tools (microdebrider)

Powered microdebrider-assisted turbinoplasty is an effective technique with fewer complications of crusting and similar favorable outcomes to manual submucosal resection [55]. It is performed under endoscopic guidance. Local infiltration is given in the inferior turbinate. A vertical incision is made in the anterior tip of the inferior turbinate. The microdebrider is then introduced through the incision and by rotating continuously in a circular fashion it removes all stromal tissue [59]. Finally, anterior nasal packing is kept in nasal passages for 48 h [1]. Microdebrider offers preservation of both the mucosa and the anatomy/physiology of the turbinate. However, this technique is associated with a major risk of postoperative bleeding [55].

2.4.3 Thermal turbinoplasty

2.4.3.1 Submucosal electrocauterization (Diathermy)

This technique was first introduced by Beck in 1930. It is performed using an Abbey needle at 20 W of power. Under endoscopic guidance, the needle is introduced in the anterior tip of the inferior turbinate until the posterior edge. A second pass is performed along the inferior medial edge and a third pass midway between the previous passes. This technique is associated with more complications, such as postoperative bleeding, crusts formation, mucosal dryness, edema, and avascular necrosis [60, 61].

2.4.3.2 Laser surgery

Laser treatment of the inferior turbinates is generally used as extra mucosal technique. Potassium-titanyl-phosphate (KTP) laser has been applied directly inside the turbinate to reduce the vascular tissue. KPT laser energy is well absorbed by hemoglobin and pigmented tissue. Thus, the engorged vessels strongly absorb

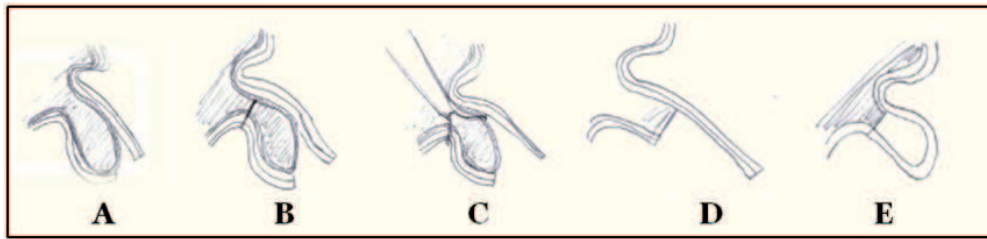


Figure 7.

Cold turbinoplasty with manual instrumentation (Mabry's technique) (A) incision from the inferior tip of the turbinate, (B) mucosal flap, (C and D) the bone and soft tissue of the inferior and lateral part of the turbinate lateral mucosa removal. (E) Residual mucosal curled upon itself to form a "neoturbinate."

the laser energy resulting in shrinkage of the vessels and submucosal tissue. The procedure is conducted as described: an 18-gauge needle is inserted into the submucosa of the inferior turbinate from its anterior edge to about 2 cm. KTP laser is delivered by inserting the fiber through lumen of the needle previously applied, the needle is removed and a retrograde photocoagulation is performed. Results seem to be good with the respect of the mucosa. Patients complain about the long period they have to wait for healing [62, 63].

2.4.3.3 Radiofrequency ablation of the inferior turbinate (RFAIT)

Among the thermal techniques, radiofrequency ablation of the inferior turbinate is one the most performed because of its simple utilization, the possibility to be performed even only under local anesthesia, and its rare complications [64, 65].

This method works generating a high frequency, but low intensity energy. The instrument consists of a monopolar or bipolar generator and a handpiece (probe) that contains electrodes [66]. The electrodes do not get heated themselves [67]. They induce an ionic stirring, and collision between ions and tissue molecules gives out heat over the surrounding submucosal layer of the turbinates (2–4 mm around the active portion of the electrode), preserving overlying mucosal integrity within its mucociliary function. The temperature achieved is always controlled (60–90°C) and carbonization phenomena are excluded [68].

The tip of the electrodes can be introduced in front part (or "head") of the inferior turbinate in one time and pushed across all its length (single insertion site technique) or in three steps (head, body, tail of turbinate), ideally under endoscopic guide. Some authors usually manage just the anterior hypertrophy of the turbinate, as responsible of most nasal resistances [69].

The reduction of the volume of the turbinate is visible just during the surgery, but long term results cannot be estimated during the procedure.

In the first 24–48 h, nasal obstruction can get worse because of the edematous reaction [69], to improve in the following 2–3 weeks, in which the original tissue is replaced by scar tissue, which has a lower thickness. The shrinkage of turbinates enhances with the partial subsequent reabsorption of the scar tissue and the submucosal fibrosis [68] that join the mucosa to the periosteum of the inferior nasal concha. Blood flow is reduced too. Intraoperative and postoperative complications (such as hemorrhage) are rare, and usually there is no need in nasal cavity packing [68].

This surgical option is repeatable and its repetition can stabilize results over time [68].

2.4.3.4 Radiofrequency coblation technique

A different type of radiofrequency bipolar technique is the so-called coblation (term that derives from the union of the words "Cold" and "Ablation") that consists

of a bipolar wand and a standard electrosurgical unit. The thermal lesion of the submucosal tissue is caused by the ionic agitation of an electrically conductive fluid (normal saline) added in the space between the electrode and the tissue. This ionic agitation determines a molecular disintegration that is minimal because of the minimum distance between the active and passive electrodes. For the turbinate surgery, two probes are available: the “Reflex Ultra 45 wand” and the “Hummingbird wand” [70, 71].

The surgeon, using the wand, under optical guidance, can create a tissue channel or more, depending on the size of the inferior turbinate to be reduced. In this technique, which can be conducted even under local anesthesia, the infiltration of the turbinate with saline solution is important. Radiofrequency energy promotes a submucosal fibrosis process, which leads to the dimensional reduction of the turbinate, in the absence of involvement of the mucosal lining and/or of the mucociliary transport system. Nasal packing is not required [70].

In the short-term postoperative period, often it is usual to observe a “rebound swelling” of the turbinate, due to the tissue edema, that can last even 10 days, to resolve its self in about 6 weeks. As the common radiofrequency technique or even more frequently, additional therapeutic sessions can be necessary, because of a gradual recurrence of symptoms after some time. Patients with the lowest preoperative nasal conductance of airflow gain greatest objective benefit from turbinate coblation. This means that patient selection with objective measurements is very important [72].

2.4.3.5 Ultrasound

The mechanism of action of this technique consists of the transformation of low frequency ultrasounds (44 + 4.4 KHz) into mechanical oscillations, induced by an acoustic transducer, through a piezoelectric phenomenon. The probe, introduced into the turbinate submucosa through the creation of two parallel intraparenchymal tunnels, ultimately produces a process of ultrasonic disintegration, particularly evident at the level of the cavernous and connective tissue, with reduction of the volume of the turbinate due to the formation of abundant intramural fibrotic tissue. A histopathological analysis with an electronic microscope showed regeneration of respiratory epithelium (ciliary regeneration), after 3 months reduction of hyperplasia; decrease in the number of goblet cells and glandular elements; and restoration of a normal pseudo-layered ciliated epithelium, after 6 months [73, 74].

2.4.3.6 Molecular quantum resonance (QMR)

Unlike the other existing technologies, which base their operating principle on a transfer of thermal energy (heat generated by the passage of current), the molecular quantum resonance scalpel suitably modulated to produce tissue separation not by thermal vaporization, but as a consequence of the “resonance” effect at the cellular level. The energetic quanta, opportunely calibrated for the tissue to be treated, are able to break the molecular bonds inside the cell, without increasing the kinetic energy and, therefore, without increasing the temperature. The result is an extremely precise and delicate biological result, in the absence of damage necrosis. The temperature reached does not exceed 45°C. For the coagulation process, the frequencies are slightly modified, so as to make the molecules vibrate inside the cell and induce a modest rise in temperature (up to about 63°C), which in turn allows to obtain the coagulation of the tissue affected by fibrinogen protein decline. Submucosal decongestion of the turbinate is performed by means of insertion with

a headpiece, activated by a QMR machine, so-called Quantum (Telea, Sandrigo-Vicenza, Italy), for a total of 20–30 s, at an intensity force of 3.5, with immediate causes a shrinkage of the mucosa. Since this is a substantially new technique, even if a special dedicated bipolar electrode exists and it is already operating regularly, there are only a few references in the current literature [6, 75].

2.4.3.7 Submucosal corticosteroids injection

The injection of a “long acting” steroid solution is a minimally invasive method, which still guarantees a rather limited benefit over time (it is maximum after 1 week and generally lasts for no longer than a month). It is performed by a slow submucosal injection of triamcinolone acetonide at the level of the turbinate head. A possible complication, even if extremely rare, consists of a transient or permanent loss of sight, which is thought to derive from a retinal vasospasm or a retrograde embolization affecting the retinal circulation (devastating retinal thromboses can also occur) [6, 76, 77].

3. Conclusions

The great interest in turbinate surgery is documented by the large number of surgical techniques proposed over the years and by the production of specific surgical devices by the healthcare industry. However, this diversity of opinions and the quantity of proposed techniques, all valid and scientifically documented, underlines the continuous research to balance the need to solve the obstruction and to maintain the function of the nasal mucosa that unfortunately, in chronic pathologies, like vasomotor rhinitis, is still severely damaged. In literature, in fact, a reduction in epithelial thickness and disappearance of ciliated and goblet cells, the absence of tight junctions, nasal mucus overproduction, inflammatory infiltration in lamina propria [73], marked disruption of the intercellular spaces, and frequent basement membrane interruption [78] can be observed. The lack of mucociliary clearance, absence of tight junctions, widening of intercellular spaces, and discontinuity of the basement membrane induce a reduction in epithelial defense functions, so that environmental factors may directly act on subepithelial structures. As a result, in the nasal respiratory mucosa, an increased responsiveness of trigeminal afferent fibers and secretory and vascular reflexes might occur representing the basis of symptoms [79].

The presence of these profound alterations makes us understand that a preservation of histologically altered mucosa translates inevitably into maintaining an impaired nasal function. On the other hand, it was to demonstrate [2] that the total removal of the nasal mucosa with “cold technique,” without high temperatures, that burned and damaged the edges of the removed mucosa, results in a subsequent complete ultrastructural restoration of the healthy tissue.

For this reason, any technique, among those described, the surgeon want to adopt, in any case will have to follow any simple rules: do not use high temperatures, do not remove bone tissue and remove all the hypertrophic and damaged mucosa.

Acknowledgements

I have to thank Dr. Fiorella Cazzato who, with skill and ability, illustrated the present work by enriching it with the original explanatory drawings of various techniques.

Conflict of interest

The authors declare that there is no conflict of interest regarding the publication of this article. All authors have seen and approved the manuscript being submitted. We warrant that this chapter is the authors' original work. We warrant that the chapter has not received prior publication and is not under consideration for publication elsewhere. This research has not been submitted for publication nor has it been published in whole or in part elsewhere. We attest to the fact that all authors listed on the title page have contributed significantly to the work, have read the manuscript, attested to the validity and legitimacy of the data and its interpretation, and agreed to its submission.

Author details

Giampiero Neri^{1*}, Fiorella Cazzato¹, Elisa Vestrini¹, Pasquina La Torre¹,
Giampaolo Quaternato¹, Letizia Neri¹ and Lucia Centurione²

¹ Neurosciences, Imaging and Clinical Sciences Department, University
“G. d’Annunzio”, Chieti-Pescara, Italy

² Medicine and Aging Sciences Department, Section of Human Morphology,
University “G. d’Annunzio”, Chieti-Pescara, Italy

*Address all correspondence to: neri@unich.it

IntechOpen

© 2019 The Author(s). Licensee IntechOpen. This chapter is distributed under the terms of the Creative Commons Attribution License (<http://creativecommons.org/licenses/by/3.0>), which permits unrestricted use, distribution, and reproduction in any medium, provided the original work is properly cited. 

References

- [1] Romano A, Dell'Aversana Orabona G, Salzano G, Abbate V, Iaconetta G, Califano L. Comparative study between partial inferior turbinectomy and microdebrider-assisted inferior turbinoplasty. *The Journal of Craniofacial Surgery*. 2015;**26**(3):235-238
- [2] Neri G, Cazzato F, Mastronardi V, Pugliese M, Centurione MA, Di Pietro R, et al. Ultrastructural regenerating features of nasal mucosa following microdebrider-assisted turbinoplasty are related to clinical recovery. *Journal of Translational Medicine*. 2016;**14**:164-170
- [3] Neri G, Mastronardi V, Traini T, D'Orazio F, Pugliese M, Cazzato F. Respecting nasal mucosa during turbinate surgery: End of the dogma? *Rhinology*. 2013;**51**(4):368-375
- [4] Berger G, Balum-Azim M, Ophir D. The normal inferior turbinate: histomorphometric analysis and clinical implications. *Laryngoscope*. 2003;**113**(7):1192-1198
- [5] Anderson M, Liang J. Trends in inferior turbinate surgery: Analysis of patients using the Medicare database. *International Forum of Allergy & Rhinology*. 2018;**8**(10):1169-1174
- [6] Pagella F, Pusateri A, Danè G, et al. Indicazioni alla chirurgia riduttiva dei turbinati inferiori e work-up preoperatorio acta. In: XXXIV National Congress AOOI; 14-15 October 2010. Verona, Italy; 2010. pp. 207-208
- [7] Ferrario F. La chirurgia riduttiva dei turbinati inferiori: Classificazione, rassegna analitica e criteri di selezione degli interventi. In: Acta XXXIV National Congress AOOI; 14-15 October 2010. Verona, Italy; 2010. pp. 213-268
- [8] Jones AS, Lancer JM. Does submucosal diathermy to the inferior turbinate reduce nasal resistance to airflow in the long term? *The Journal of Laryngology and Otology*. 1987;**101**(5):448-451
- [9] Talmon Y, Samet A, Gilbey P. Total inferior turbinectomy: Operative results and technique. *The Annals of Otology, Rhinology, and Laryngology*. 2000;**109**(12):1117-1119
- [10] Tasca I, Ceroni Compadretti G, Sorace F, Bacciu A. La chirurgia dei turbinati. In: Tasca I, Manzini M, editors. *La chirurgia funzionale del naso. Quaderni Monografici di Aggiornamento A.O.O.I. Galatina, Italy: TorGraf; 2006. p. 85*
- [11] Huizing EH, deGroot JA. Nasal Pyramid Surgery. In: Huizing EH, de Groot JA, editors. *Functional Reconstructive Nasal Surgery*. Rome, Italy: Verduci Editore. 2006. p. 278
- [12] Garth RJ, Cox HJ, Thomas MR. Haemorrhage as a complication of inferior turbinectomy: A comparison of anterior and radical trimming. *Clinical Otolaryngology and Allied Sciences*. 1995;**20**(3):236-238
- [13] Chevretton EB, Hopkins C, Black IM, Tierney P, Smeeton NC. Degloving of the inferior turbinates: Pilot study to assess the effectiveness of a new technique in turbinate reduction. *The Journal of Laryngology and Otology*. 2003;**117**(11):866-870
- [14] Huizing EH. Functional surgery in inflammation of the nose and paranasal sinuses. *Rhinology - Supplement*. 1988;**5**:5-15
- [15] Kumar D, Rajashekar M. Comparative study of improvement of nasal symptoms following septoplasty with partial inferior turbinectomy

- versus septoplasty alone in adults by NOSE Scale: A prospective study. *Indian Journal of Otolaryngology and Head & Neck Surgery*. 2016;**68**(3):275-284
- [16] Passali D, Bellussi L, Damiani V, et al. Allergic rhinitis in Italy: Epidemiology and definition of most commonly used diagnostic and therapeutic modalities. *Acta Otorhinolaryngologica Italica*. 2003;**23**:257-264
- [17] Sapçi T, Sahin B, Karavus A, Akbulut UG. Comparison of the effects of radiofrequency tissue ablation, CO₂ laser ablation, and partial turbinectomy applications on nasal mucociliary functions. *The Laryngoscope*. 2003;**113**(3):514-519
- [18] Salzano FA, Mora R, Dellepiane M, et al. Radiofrequency, high-frequency, and electrocautery treatments vs partial inferior turbinotomy: Microscopic and macroscopic effects on nasal mucosa. *Archives of Otolaryngology – Head & Neck Surgery*. 2009;**135**(8):752-758
- [19] Davis WE, Nishioka GJ. Endoscopic partial inferior turbinectomy using a power microcutting instrument. *Ear, Nose, & Throat Journal*. 1996;**75**(1):49-50
- [20] Ravikumar A, Griffith TD, Flood LM, McNeela BJ. An unusual complication following inferior turbinectomy. *The Journal of Laryngology and Otology*. 1995;**109**(6):559-561
- [21] Lee JY, Lee JD. Comparative study on the long-term effectiveness between coblation- and microdebrider-assisted partial turbinoplasty. *The Laryngoscope*. 2006;**116**(5):729-734
- [22] Van delden MR, Cook PR, Davis WE. Endoscopic partial inferior turbinoplasty. *Otolaryngology and Head and Neck Surgery*. 1999;**121**(4):406-409
- [23] Lenz H, Eichler J, Schafer G, Salk J. Parameters for argon-laser surgery of the lower human turbinates. *Acta Oto-Laryngologica*. 1977;**83**(3-4):360-365
- [24] Bergmark RW, Gray ST. Surgical management of turbinate hypertrophy. *Otolaryngologic Clinics of North America*. 2018;**51**(5):919-928
- [25] Freer OT. The inferior turbinate: Its longitudinal resection for chronic intumescence. *Laryngoscope*. 1911;**21**:1136-1144
- [26] Lippert BM, Werner JA. Comparison of carbon dioxide and neodymium: Yttrium-aluminum-garnet lasers in surgery of the inferior turbinate. *The Annals of Otology, Rhinology, and Laryngology*. 1997;**106**(12):1036-1042
- [27] Janda P, Sroka R, Tauber S, Baugartner R, Grevers G, Leunig A. Diode laser treatment of hyperplastic inferior nasal turbinates. *Lasers in Surgery and Medicine*. 2000;**27**(2):129-139
- [28] Metson R. Holmium:YAG laser endoscopic sinus surgery: A randomized, controlled study. *The Laryngoscope*. 1996;**106**(Suppl. 77):1-18
- [29] Wang HK, Tsai YH, Wu YY, Wang PC. Endoscopic potassium-titanyl-phosphate laser treatment for the reduction of hypertrophic inferior nasal turbinate. *Photomedicine and Laser Surgery*. 2004;**22**(3):173-176
- [30] Somogyvári K, Móricz P, Gerlinger I, Kereskai L, Szanyi I, Takács I. Morphological and histological effects of radiofrequency and laser (KTP and Nd:YAG) treatment of the inferior turbinates in animals. *Surgical Innovation*. 2017;**24**(1):5-14
- [31] Wexler DB, Berger G, Derowe A, Ophir D. Long-term histologic effects of inferior turbinate laser surgery.

Otolaryngology and Head and Neck Surgery. 2001;**124**(4):459-463

[32] House HP. Submucous resection of the inferior turbinal bone. *Laryngoscope*. 1951;**61**(7):637-648

[33] Martinez SA, Nissen AJ, Stock CR, Tesmer T. Nasal turbinate resection for relief of nasal obstruction. *Laryngoscope*. 1983;**93**(7):871-875

[34] Hol MKS, Huizing EH. Treatment of inferior turbinate pathology: A review and critical evaluation of the different techniques. *Rhinology*. 2000;**38**(4):157-166

[35] Rao SUP, Basavaraj P, Yempalle SB, Ramachandra AD. A prospective study of different methods of inferior turbinate reduction. *Journal of Clinical and Diagnostic Research*. 2017;**11**(5):MC01-MC03

[36] Sakakura Y, Ukai K, Majima Y, Murai S, Harada T, Miyoshi Y. Nasal mucociliary clearance under various conditions. *Acta Oto-Laryngologica*. 1983;**96**(1-2):167-173

[37] Unsal Tuna EE, Ozbek C, Koç C, Ozdem C. Evaluation of nasal symptoms and mucociliary function in patients with allergic rhinitis treated with chemosurgery using trichloroacetic acid. *American Journal of Otolaryngology*. 2008;**29**(1):37-41. DOI: 10.1016/j.amjoto.2006.12.006

[38] Yao K, Sato K, Usui D, Kurihara R, Okamoto M, Iguchi Y, et al. Chemosurgery with trichloroacetic acid for allergic rhinitis: Evaluation of the efficacy in terms of inhibition of Th2 cell infiltration. *Auris, Nasus, Larynx*. 2009;**36**(3):292-299

[39] Bumstead RM. Cryotherapy for chronic vasomotor rhinitis: Technique and patient selection for improved results. *The Laryngoscope*. 1984;**94**(4):539-544

[40] Principato JJ. Chronic vasomotor rhinitis: Cryogenic and other surgical modes of treatment. *The Laryngoscope*. 1979;**89**(4):619-638

[41] Rakover Y, Rosen G. A comparison of partial inferior turbinectomy and cryosurgery for hypertrophic inferior turbinates. *The Journal of Laryngology and Otology*. 1996;**110**(8):732-735

[42] Ferri E, Armato E, Cavaleri S, Capuzzo P, Ianniello F. Argon plasma surgery for treatment of inferior turbinate hypertrophy: A long-term follow-up in 157 patients. *ORL: Journal for Otorhinolaryngology and Its Related Specialties*. 2003;**65**(4):206-210

[43] Scheithauer MO. Surgery of the turbinates and "empty nose" syndrome. *GMS Current Topics in Otorhinolaryngology - Head and Neck Surgery*. 2010;**9**:1-28

[44] Farin G, Grund KE. Technology of argon plasma coagulation with particle regard to endoscopic application. *Endoscopic Surgery and Allied Technologies*. 1994;**2**(1):71-77

[45] Nath G. The new principle of infra-red coagulation in medicine and its physical fundamentals. *Coloproctology*. 1981;**3**:379-381

[46] Moulton-Barrett R, Passy V, Horlick D, Brauel G. Infrared coagulation of the inferior turbinate: A new treatment for refractory chronic rhinitis. *Otolaryngology and Head and Neck Surgery*. 1994;**111**(5):674-679

[47] Salam MA, Wengraf C. Concho-antropexy or total inferior turbinectomy for hypertrophy of the inferior turbinates? A prospective randomized study. *The Journal of Laryngology and Otology*. 1993;**107**:1125-1128

[48] Jourdy D. Inferior turbinate reduction. *Operative Techniques in Otolaryngology*. 2014;**25**:160-170

- [49] Lee KC, Lee SS, Lee JK, Lee SH. Medial fracturing of the inferior turbinate: Effect on the ostiomeatal unit and the uncinata process. *European Archives of Oto-Rhino-Laryngology*. 2009;**266**(6):857-861
- [50] Goode RL. Surgery of the turbinates. *The Journal of Otolaryngology*. 1978;**7**:262-268
- [51] Saunders WH. Surgery of the inferior nasal turbinates. *The Annals of Otolaryngology, Rhinology, and Laryngology*. 1982;**91**:445-447
- [52] O'Flynn PE, Milford CA, Mackay JS. Multiple submucosal out-fractures of inferior turbinates. *The Journal of Laryngology and Otology*. 1990;**104**(3):239-240
- [53] Fateen M. Concho-antropexy in vasomotor rhinitis and chronic nasal obstruction. *Rhinology*. 1967;**5**:20-24
- [54] Spielberg W. The treatment of nasal obstruction by submucous resection of the inferior turbinate bone. *Laryngoscope*. 1924;**34**:197-203
- [55] Nurse LA, Duncavage JA. Surgery of the inferior and middle turbinate. *Otolaryngologic Clinics of North America*. 2009;**42**(2):295-309
- [56] Mori S, Fujieda S, Yamada T, Limura Y, Takahashi N, Saito H. Long-term effect of submucous turbinectomy in patients with perennial allergic rhinitis. *Laryngoscope*. 2002;**112**:866-869
- [57] El Henawi Del D, Ahmed MR, Madian YT. Comparison between power-assisted turbinoplasty and submucosal resection in the treatment of inferior turbinate hypertrophy. *ORL*. 2011;**73**(3):151-155
- [58] Mabry RL. Inferior turbinoplasty. *Laryngoscope*. 1982;**92**:459-461
- [59] Bruggers S, Sindwani R. Innovations in microdebrider technology and design. *Otolaryngologic Clinics of North America*. 2009;**42**:781-787
- [60] Beck JC. Pathology and intramural electrocoagulation of inferior turbinate. *The Annals of Otolaryngology, Rhinology, and Laryngology*. 1930;**39**:349-363
- [61] Hurd LM. Bipolar electrode for electrocoagulation of the inferior turbinate. *Archives of Otolaryngology*. 1931;**13**:442
- [62] Vijayakumar S, Divakaran S, Parida PK, Gopalakrishnan S. Potassium titanyl phosphate laser turbinate reduction in the management of allergic inferior turbinate hypertrophy: Our experience. *Allergy & Rhinology*. 2016;**7**(1):29-33
- [63] Supiyaphun P, Aramwatanapong P, Kerekhanjanarong V, Sastarasadhit V. KTP laser inferior turbinoplasty: An alternative procedure to treat the nasal obstruction. *Auris Nasus Larynx*. 2003;**30**:59-64
- [64] Means C, Camacho M, Capasso R. Long-term outcomes of radiofrequency ablation of the inferior turbinates. *Indian Journal of Otolaryngology and Head & Neck Surgery*. 2016;**68**(4):424-428
- [65] Rhee CS, Kim DY, Won TB, Lee HJ, Park SW, Kwon TY, et al. Changes of nasal function after temperature-controlled radiofrequency tissue volume reduction for the turbinate. *The Laryngoscope*. 2001;**111**(1):153-158
- [66] Hytönen ML, Bäck LJJ, Malmivaara AV, Roine RP. Radiofrequency thermal ablation for patients with nasal symptoms: A systematic review of effectiveness and complications. *European Archives of Oto-Rhino-Laryngology*. 2009;**266**:1257-1266
- [67] Smith TL, Correa AJ, Kuo T, Reinisch L. Radiofrequency tissue ablation of the inferior turbinates using

a thermocouple feedback electrode. *Laryngoscope*. 1999;**109**:1760-1765

[68] Elwany S, Gaimae R, Fattah HA. Radiofrequency bipolar submucosal diathermy of the inferior turbinates. *American Journal of Rhinology*. 1999;**13**:145-149

[69] Cavaliere M, Mottola G, Iemma M. Comparison of the effectiveness and safety of radiofrequency turbinoplasty and traditional surgical technique in treatment of inferior turbinate hypertrophy. *Otolaryngology and Head and Neck Surgery*. 2005;**133**(6):972-978

[70] Di Rienzo Businco L, Di Rienzo Businco A, Lauriello M. Comparative study on the effectiveness of Coblation-assisted turbinoplasty in allergic rhinitis. *Rhinology*. 2010;**48**(2):174-178

[71] Chang CW, Ries WR. Surgical treatment of the inferior turbinate: New techniques. *Current Opinion in Otolaryngology & Head and Neck Surgery*. 2004;**12**:53-57

[72] Farmer SE, Quine SM, Eccles R. Efficacy of inferior turbinate coblation for treatment of nasal obstruction. *The Journal of Laryngology and Otology*. 2009;**123**(3):309-314

[73] Gindros G, Kantas I, Balatsouras DG, Kandiloros D, Manthos AK, Kaidoglou A. Mucosal changes in chronic hypertrophic rhinitis after surgical turbinate reduction. *European Archives of Oto-Rhino-Laryngology*. 2009;**266**:1409-1416

[74] Nousia C, Gouveris H, Giatromanolaki A, Ypsilantis P, Katotomichelakis M, Watelet J-B, et al. Ultrasound submucosal inferior nasal turbinate reduction technique: Histological study of wound healing in a sheep model. *Rhinology*. 2010;**48**:169-173

[75] Di Rienzo Businco L, Di Rienzo Businco A, Ventura L, Laurino S. Turbinoplasty with quantic molecular resonance in the treatment of persistent moderate-severe allergic rhinitis: Comparative analysis of efficacy. *American Journal of Rhinology & Allergy*. 2014;**28**(2):164-168

[76] Simmons MW. Intranasal injection of corticosteroids. *California Medicine*. 1960;**92**:155-158

[77] Simmons MW. Intranasal injection of corticosteroids in nasal disorders: Further observations. *Pacific Coast Oto-Ophthalmological Society*. 1964;**45**:95-103

[78] Berger G, Gass S, Ophir D. The histopathology of the hypertrophic inferior turbinate. *Archives of Otolaryngology – Head & Neck Surgery*. 2006;**132**:588-594

[79] Giannessi F, Fattori B, Ursino F, Giambelluca A, Soldani P, Scavuzzo MC, et al. Ultrastructural and ultracytochemical study of the human nasal respiratory epithelium in vasomotor rhinitis. *Acta Otolaryngologica*. 2003;**123**:943-949