

We are IntechOpen, the world's leading publisher of Open Access books Built by scientists, for scientists

4,800

Open access books available

122,000

International authors and editors

135M

Downloads

Our authors are among the

154

Countries delivered to

TOP 1%

most cited scientists

12.2%

Contributors from top 500 universities



WEB OF SCIENCE™

Selection of our books indexed in the Book Citation Index
in Web of Science™ Core Collection (BKCI)

Interested in publishing with us?
Contact book.department@intechopen.com

Numbers displayed above are based on latest data collected.

For more information visit www.intechopen.com



The Role of Radiotherapy in the Treatment of Primary Central Nervous System Lymphomas

Meral Kurt, Candan Demiröz Abakay and Ali Altay

Abstract

Primary central nervous system (PCNS) lymphomas are rare disease entities, though the incidence is increasing due to various immunosuppressive situations. The brain, eyes, and the spinal cord could be affected without any systemic disease involvement. Untreated PCNS lymphoma has been a rapidly fatal course. However, combined modality treatments have positive impact on overall survival. Pretreatment plan is formed by evaluating the treatment options to be used, disease involvement, and individual comorbidity. The PCNS lymphomas are known to be very sensitive to irradiation and chemotherapy treatments. The treatment plan is also generated according to the neurological condition and functional status of patients. The mainstay of induction therapy has been high dose methotrexate administration for most patients. The addition of radiotherapy as a consolidation treatment increases progression-free survival. The use of reduced irradiation dose and different fractionation schemes has been investigated in different studies to avoid the increased toxicity of high-dose whole-brain radiotherapy. High-dose chemotherapy, autologous hematopoietic cell transplantation, and whole-brain radiotherapy are alternative applications in patients with insufficient response to induction therapy. Stereotactic radiotherapy is another option in case of relapsed or refractory disease. Age and performance are also important indicators of survival and tumor progression.

Keywords: primary central nervous system lymphoma, radiotherapy, new techniques

1. Introduction

Primary central nervous system lymphomas (PCNSLs) are rare disease entities. The brain, eyes, and the spinal cord could be affected without any systemic disease involvement [1]. PCNSL is an uncommon subtype of extranodal non-Hodgkin lymphoma that accounts for $\approx 3\text{--}4\%$ of newly diagnosed central nervous system tumors [2]. The overall incidence rate of PCNSL is 0.47 per 100.000 person-years. Its incidence has increased during the last 3 decades and has been reported in both immunocompromised and immunocompetent patients. Immunocompromised patients are affected at a younger age compared with immunocompetent patients. The incidence is significantly higher in males compared with females.

The most significant increase in the incidence rates for PCNSLs over time has occurred in the oldest adults (aged 75+ years) [3]. There is an increase in

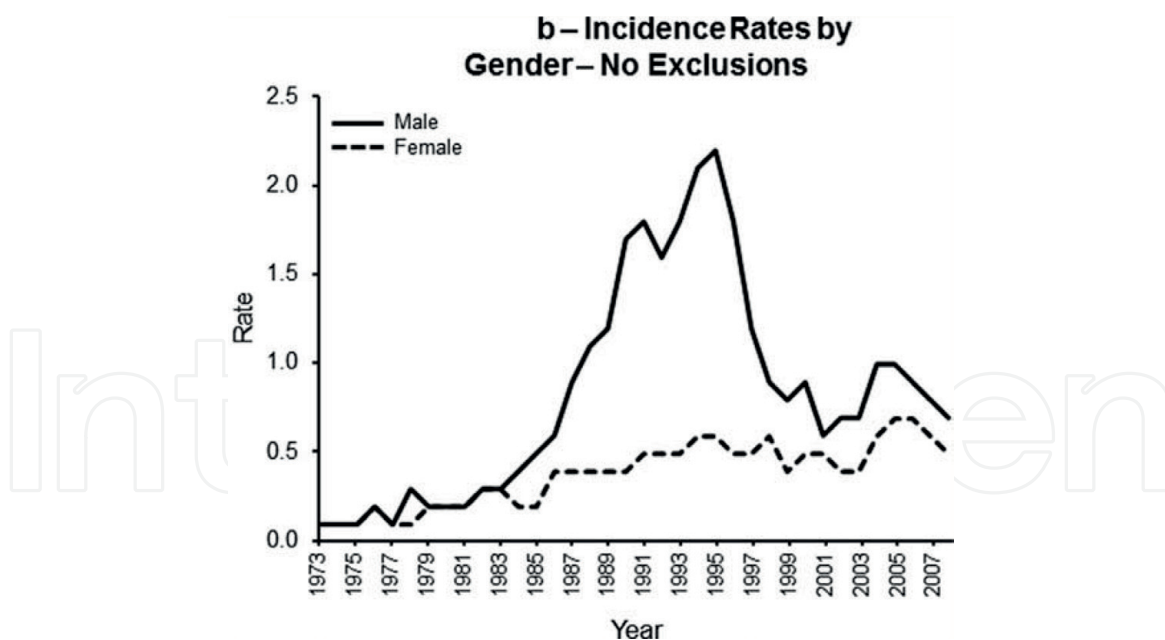


Figure 1.
The incidence rates of PCNSLs by gender from 1973 to 2007 [4].

incidence of PCNSLs in the elderly, and survival remains poor and is negatively dominated by factors associated with HIV infection and advanced age. Such changes were largely driven by PCNSL cases in men between the ages of 20 and 64 years [4]. There has been an overall decline in incidence of PCNSL from 1998 to 2008. Thus the trend has been attributed in large part to changes in HIV/AIDS incidence and management over the same time period. In contrast, the incidence rates continued to increase in women at all ages and men aged 65 and older (Figure 1).

In immunocompetent individuals, they occur at a median age of about 55 years [5]. The incidence of this tumor in immunocompetent individuals has risen three-fold during the last decades from 0.027 to 0.075; 100.000 person. Immunodeficient individuals, especially patients with AIDS, transplant recipients, and patients with congenital immunodeficiencies are at increased risk of developing PCNSLs. In patients with such severe immunodeficiencies, survival is heavily influenced by the underlying disease [6]. Autoimmune diseases that predispose to lymphoma include rheumatoid arthritis, systemic lupus erythematosus, Sjögren syndrome, myasthenia gravis, sarcoidosis, and vasculitis [6].

Presenting symptoms and signs vary, depending on the tumor location. Periventricular lesions and related symptoms are common in patients with primary cerebral lymphoma. The majority of the lesions are located in the periventricular area, whereas in a few, they are located in the supratentorial area. In about 60% of cases, PCNSLs originate from periventricular areas such as the thalamus, the basal ganglia, and the corpus callosum, which are followed by the frontal lobe, parietal lobe, temporal lobe, and occipital lobe (20, 18, 15, and 4%, respectively). Immunocompetent patients tend to present predominantly with solitary lesions in 70% of cases, compared with 50% in AIDS patients [1].

2. Pathogenesis

The central nervous system normally lacks lymphoid aggregates. The cellular and molecular events leading to neoplastic lymphocytic infiltration of the central nervous system are seen in PCNSLs [7].

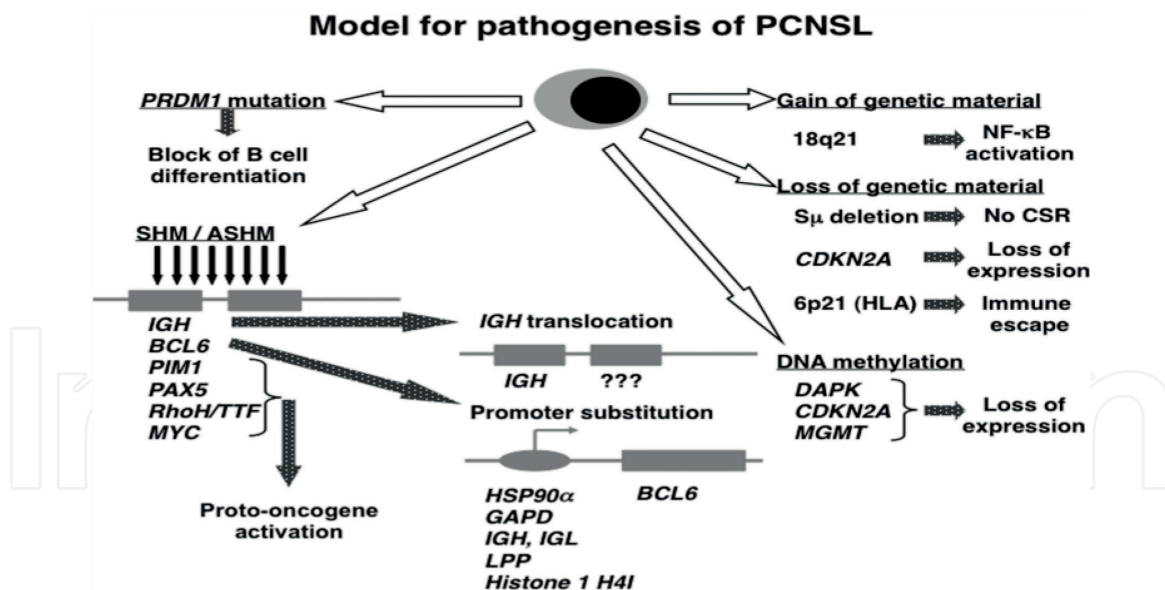


Figure 2. Model of pathogenesis for PCNSLs. Schematic presentations of several pathways involved in the pathogenesis of PCNSLs, SHM, somatic hypermutation; ASHM, aberrant somatic hypermutation; and CSR, class switch recombination [7].

Primary lymphoma of the central nervous system (CNS) is defined as diffuse large B cell lymphoma confined to the central nervous system. Morphology does not distinguish between PCNSLs and extra-cerebral DLBCL [7]. While most cases of PCNSLs are composed of aggressive lymphoma subtypes, a small number of patients show indolent CNS lymphomas. The median growth fraction is 4% [8]. Three major issues need to be addressed to understand the nature of PCNSLs and develop specific therapeutic regimens (**Figure 2**):

1. The histogenetic origin of the tumor cells.
2. The transforming events.
3. The role of the microenvironment of the CNS.

The underlying molecular pathogenesis of PCNSL has yet to be elucidated. Because of the fact that PCNSL is closely associated with EBV infection in immunocompromised individuals, involving mechanisms in PCNSL development are directed toward the immunologic reactions against EBV infection. On the other hand, the EBV infected B cells are controlled by T cells in nonimmunocompromised individuals. Therefore, a decline in T cells leads to the proliferation and dissemination of abnormal B cells in immunodeficiency states [6]. In addition, occasionally, patients with EBV DNA in spinal fluid have PCNSL. But EBV DNA is often found together with other microbial findings in CSF of immunocompromised patients [9]. PCNSL may be a consequence of EBV-mediated clonal expansion and malignant transformation of B-lymphocytes, a process that may be regulated by immune mechanisms [10].

3. Clinical presentation

The location of the lymphoma in the CNS determines the clinical presentation. Presenting symptoms and signs vary, depending on the site of involvement PCNSL can manifest in the brain, its coverings, spinal cord, and the eye. Distinct clinico-pathologic entities have been described. In a large series with immunocompetent

patients with PCNSL, focal neurologic deficits were found to be the most common sign that was seen in 70% of patients. Other important complaints include neuropsychiatric symptoms, the signs of raised intracranial pressure such as headache, nausea, and vomiting, followed by seizures and ocular symptoms [1]. Presenting symptoms may include headaches, blurred vision, motor difficulties, and personality changes. Personality changes are most often associated with lesions of the frontal lobes, periventricular white matter, or corpus callosum. Visual hallucinations may result from infiltration of visual pathways or the brainstem or may result from ocular or leptomeningeal involvement. This may result in delayed diagnosis that usually prompts neurologic evaluation. Cranial neuropathies can occur as a result of either meningeal involvement, infiltration of the brainstem, or invasion of isolated cranial nerves or their roots. Headache, especially late, in the course of the disease, involving the leptomeninges may be indicative of increased intracranial pressure.

In primary leptomeningeal lymphoma, up to 40% of patients with cerebral PCNSL may have evidence of meningeal involvement at the time of diagnosis based on analysis and imaging. The frequency of meningeal dissemination (MD) in primary CNS lymphoma, its prognostic impact, and optimal management have yet to be defined. But involvement of the leptomeninges by high risk systemic lymphoma is also a common relapse pattern. On the other hand, primary leptomeningeal lymphoma without synchronous cerebral/spine or systemic disease is very rare, making up less than 10% of all cases of PCNSLs. MD was concluded in the case of cytological detection of lymphoma cells, or light-chain restricted B cell population demonstrated by immunocytology or flow cytometry, or existence of a dominant amplicon in PCR analysis, or clear evidence of MD on MRI [11].

Major patient's characteristics and therapy did not significantly differ between patients with MD versus those without MD [12]. Progression-free survival (PFS) and overall survival (OS) were not significantly different in patients with MD versus without MD. Median OS, of MD+ and MD- patients, was 21.5 months versus 24.9 months ($p = 0.98$) [12]. Primary leptomeningeal lymphoma is a rare form of primary CNS lymphoma. Patients usually present with multifocal symptoms, with evidence of leptomeningeal enhancement and diagnostic CSF analysis. Presenting symptoms are multifocal in 68%. The most common presenting signs are cranial neuropathies 58%, especially of eye movements and with cranial nerve VI palsy 31%, presented with headache 44%. In another study, leptomeningeal enhancement was seen in 74% and the CSF profile was abnormal in all cases. CSF cytology detected malignant lymphocyte in 67% [13].

The third process neurolymphomatosis (NL) is a rare clinical entity characterized by infiltration of peripheral nerves, nerve roots, plexus, or cranial nerves by malignant lymphocytes. Symptoms include loss of sensation or motor function, for example, weakness of the extremities [14]. These patients showed lymphomatous cell invasion that was more prominent in the proximal portion of the nerve trunk and induced demyelination without macrophage invasion and subsequent axonal degeneration in the portion distal from the demyelination site [14]. NL is poorly localized severe pain in the absence of parenchymal lesions of the brain or spinal cord or obvious lymphoma in the CSF. The process frequently spares the meninges.

The International PCNSL Collaborative Group retrospectively analyzed 50 patients assembled from 12 centers in 5 countries over a 16-year period. NL was related to NHL in 90%. It occurred as the initial manifestation of malignancy in 26% cases. The affected neural structures included peripheral nerves 60%, spinal nerve roots 48%, cranial nerves 46%, and plexus 40% with multiple site involvement 58%. CSF cytology was positive in 40% and nerve biopsy confirmed the diagnosis in 88%. Thus, instead of insufficient CSF cytology studies, could be nerve biopsy [15].

4. Evaluation

The baseline evaluation of any newly diagnosed patient with PCNSL should include a comprehensive physical and neurologic examination. Age and performance status are the two most widely documented prognostic variables and must be recorded in every patient. Evaluation of cognitive function is important at baseline, and follow-up assessments are critical both to determine the benefit of therapy as well as monitor for treatment-related neurocognitive decline.

4.1 Examination of disease extension

Before the initiation of therapy, a careful examination for the disease extension has to be carried out, in order to perform optimal treatment modality. The evaluation processes of patients suspected of having PCNSL should include:

- Optimal imaging of the brain parenchyma requires a gadolinium enhanced MRI scan. Contrast enhanced CT scans may be substituted in patients in whom MRI is medically contraindicated (e.g., cardiac pacemaker) or unavailable. Involvement of the spinal cord parenchyma is sufficiently rare that gadolinium enhanced MRI of the total spine is warranted only in patients with spinal symptoms.
- All patients should have a lumbar puncture for CSF cytology unless medically contraindicated due to elevated intracranial pressure. CSF should be sampled before or 1 week after surgical biopsy to avoid false positive results. CSF protein levels should only be assessed on lumbar puncture samples because ventricular CSF has a lower normal value. Additional CSF studies that may be helpful include cell count, beta-2 microglobulin, immunoglobulin H gene rearrangement, and flow cytometry.
- A detailed ophthalmologic examination, including dilated fundus examination, should be done to exclude vitreous, retinal, or optic nerve involvement. Fluorescein angiography may be helpful to confirm lymphomatous involvement of the retina.
- Testicular ultrasound may be considered in older men to exclude an occult testicular lymphoma metastatic to brain.

Complete systemic staging is warranted in every patient. CT scan of the chest, abdomen, and pelvis and bone marrow biopsy with aspirate are the recommended staging procedures. Body positron emission tomography imaging may be incorporated into the evaluation of systemic disease.

The diagnostic procedure of choice for PCNSL is a stereotactic needle biopsy because patients derive no clinical benefit from surgical resection, and deep seated nature of most lesions increases the risk of surgical complications. Histopathological diagnosis is strongly needed, because of the fact that some intracranial processes, such as multiple sclerosis, sarcoidosis, and occasional gliomas may mimic similar appearance and treatment response to corticosteroids [16]. In general, the use of corticosteroids prior to biopsy should be avoided, as these agents are lymphocytotoxic; a single injection is known to alter proper histopathological evaluation, and a short course of treatment may cause the tumor to disappear temporarily [17].

Whenever possible, the tumor should be characterized by immunophenotyping. Characterizing the basic molecular and genetic abnormalities of PCNSL will foster the future development and application of target specific therapies in this disease [16].

5. Radiographic features

Contrast-enhanced MRI of the brain is the preferred imaging modality. The radiographic lesion tends to be solitary nonhemorrhagic mass, situated in the deep white matter adjacent to the ventricular surface. The borders are sharply circumscribed and supratentorial location in the majority of lesions 87%, but may be ill defined in 15% [1, 18]. Mass effect and tumor edema are seen in over half of the cases. Contrast enhancement is encountered in all lesions but ring enhancement is uncommon [18]. Lesions appear isodense to hyperdense on CT images and isointense to hypointense on T2-weighted MRI images and enhance homogeneously after contrast administration. Diffusion weighted MRI images, sensitive to the intracellular water of masses of lymphoma cells, are frequently abnormal. The role of positron emission tomography scans in diagnosis is unclear. In a study, baseline PET imaging demonstrated hypermetabolism consistent with aggressive lymphoma in 75% of patients [19]. PET scans can be used to distinguish glucose-absorbing neoplastic lesions from areas of radiation necrosis, infection, or inflammation, which may also enhance on conventional CT/MRI [20]. Prompt initiation of therapy is important in patients with PCNSL. Intensive chemotherapy and immunotherapy in patients with PCNSL in study, treatment delay was the most important clinical variable associated with decreased survival, and its independent from baseline performance status or risk score [21].

6. Treatment of PCNSL

PCNSL tends to be highly sensitive to both radiation and selected chemotherapeutic agents, which distinguishes it from most other malignant primary brain neoplasms. Surgery has a limited, mainly diagnostic role. Neurologic deficits and decreased functional status related to the tumor tend to improve rapidly with successful therapy, such as chemotherapy or radiation therapy. The disease can be exquisitely sensitive to glucocorticoids as well and patients will allow functional status particularly if they show an early response to steroids. Methotrexate (MTX), given at sufficiently high dose to penetrate the CNS, is the most active single agent against PCNSL identified. High dose intravenous MTX should therefore be the backbone of induction therapy in most patients. The goal of induction chemotherapy is a radiographic complete response, which can be achieved in over half of the patients with MTX-based therapy and is generally associated with superior outcomes. Most patients, even those in complete response do not achieve long-term disease control or survival with induction chemotherapy alone. The optimal consolidation therapy has not been established, however, and all strategies have the potential for increased toxicity. The three main consolidation approaches being explored include high dose chemotherapy with autologous hematopoietic cell transplant rescue, nonmyeloablative chemotherapy, and whole brain radiation therapy (WBRT).

High dose MTX-based chemotherapy is a standard component of initial therapy for PCNSL. The available data suggest that chemotherapy regimens that include high-dose systemic MTX are more effective against PCNSL than other regimens. WBRT may improve outcome, but is associated with increased risk for neurological side-effects in elderly patients [22]. The optimal high-dose MTX-based regimen for PCNSL is unknown, and there is variation in clinical practice. Most patients with a good performance status suggest using MTX-based combination regimen rather than MTX alone. Examples of reasonable regimens include MTX plus cytarabine, or temozolomide, or procarbazine, or vincristine. Rituximab is included in all regimens, except in rare cases of CD 20 negative or T cell PCNSL. The goal of induction therapy is to achieve a complete radiographic response before proceeding with

consolidation therapy in eligible patients. Complete response is achieved in approximately 30 to 60% patients with high-dose MTX-based induction therapy. While high-dose MTX-based induction chemotherapy prolongs survival over WBRT alone, at least half of the patients with PCNSL who achieve a complete response will relapse within 5 years. This late relapse results from residual systemic malignant cell. WBRT remains an alternative consolidation approach in younger patients, particularly those with contraindications, which has been shown to improve PFS compared with induction chemotherapy alone. The consolidation approach in older adults, who are at increased risk for both relapse and toxicities of high dose chemotherapy and radiation, is unknown.

6.1 Radiation therapy

PCNSL is extremely sensitive to radiation therapy, but its use in the initial treatment of PCNSL has waned overtime as chemotherapy-based induction regimens have been optimized. Phase III trial patients with newly diagnosed PCNSL were randomly assigned therapy to six cycles of chemotherapy alone (intravenous MTX+ Ifosfamide) or the same chemotherapy with WBRT (45 Gy in 1.5 Gy fractions) [23–25] (**Figure 3**). A total of 13% patients died during initial chemotherapy; 551 patients were enrolled and randomized, of whom 318 were treated per protocol of these, and 90 patients had a major protocol violation. In the per protocol population, median overall survival was 32.4 months in patients receiving WBRT (n = 154) versus 37.1 months in those not receiving WBRT (n = 164) HR: 1.06. Thus primary hypothesis was not proven. Median progression-free survival was 18.3 months in patients receiving WBRT and 11.9 months in those not receiving WBRT. Treatment-related neurotoxicity in patients with sustained complete response was more common in patients receiving WBRT 49% by clinical assessment and 71% by neuroradiology than in those who did not 26% and 46% (**Figure 4**).

After a median follow up of 81.2 months, patients who received WBRT had a nonsignificant improvement in PFS (18.2 versus 11.9 month HR, 0.83) and significant PFS from last HDMTX (25.5 versus 12 month, HR, 0.65, p = 0.001) but without OS prolongation (**Figure 5**).

This trial prospectively monitored Quality of Life (QoL), to determine whether WBRT might lead to quality of life relevant late neurotoxicity. In year 2 after randomization, cognitive functioning and global health status were reduced in the early WBRT arm as compared to the no early WBRT arm. Also, fatigue, appetite loss, and

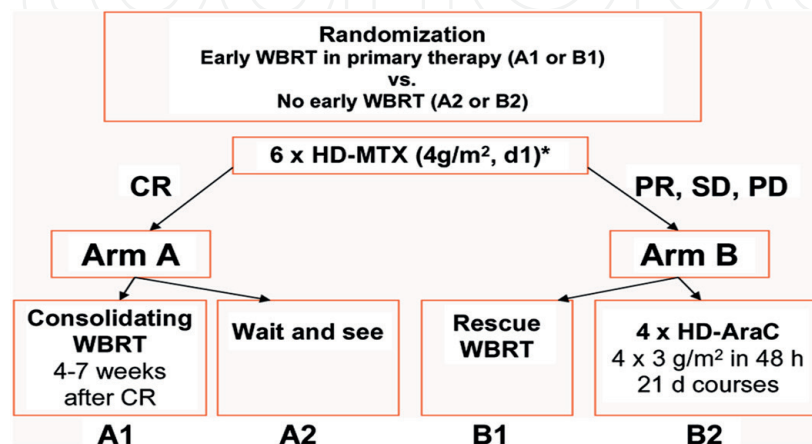


Figure 3. The G-PCNSL-SG-1 trial. Abbreviations: WBRT: whole brain radiotherapy; HD-MTX: high-dose methotrexate; CR: complete response; PR: partial response; SD: stable disease; PD: progressive disease; and HD-AraC: high-dose cytarabine. * Combined with ifosfamide 1.5 g/m² daily, d3–5, since 2006 [23].

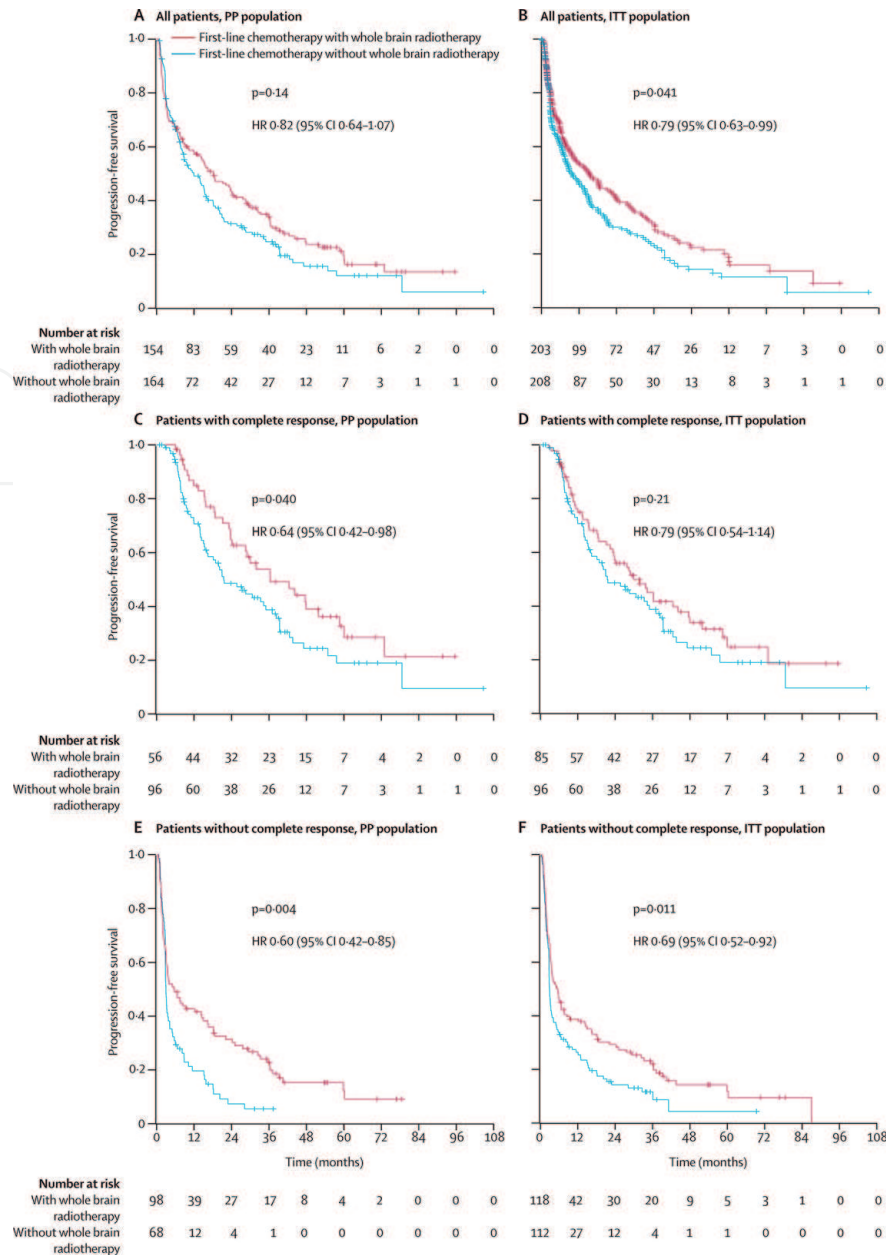


Figure 4. Progression-free survival in the per-protocol and intention-to-treat populations by treatment group PP = per protocol. ITT = intention to treat. HR = hazard ratio [24].

hair loss were more intense in the early WBRT arm. Mini mental state examination testing revealed lower values ($p = 0.002$) in the early WBRT arm [25] (**Figure 6**).

As can be seen in **Figure 6**, G-PCNSL-SG-1 trial was the first PCNSL trial documenting a negative influence of early WBRT on QoL parameters. A phase II study combined modality therapy, based on high dose MTX, results in improved survival outcomes in PCNSL. The risk of neurotoxicity for patients aged >60 years is unacceptable with this regimen (1 g/m^2 MTX on days 1 and 8 followed by WBRT 45–50.4 Gy), although survival outcomes for patients aged >60 years were higher than in many other series [26]. At these studies and other demonstrations, the major drawback in the use of WBRT in conjunction with chemotherapy for patients with PCNSL is the high incidence of cognitive worsening and white matter damage [27–29]. Neurotoxicity may present as a rapidly progressive dementia that develops after a variable delay from the end of combined modality treatment. Also, the 5 year cumulative incidence of neurotoxicity was found to be increased over time [27]. Radiological examinations showed diffuse white matter disease as well as cortical-subcortical atrophy. Older age, mental status, changes at diagnosis, and radiotherapy predicted neurotoxicity [27].

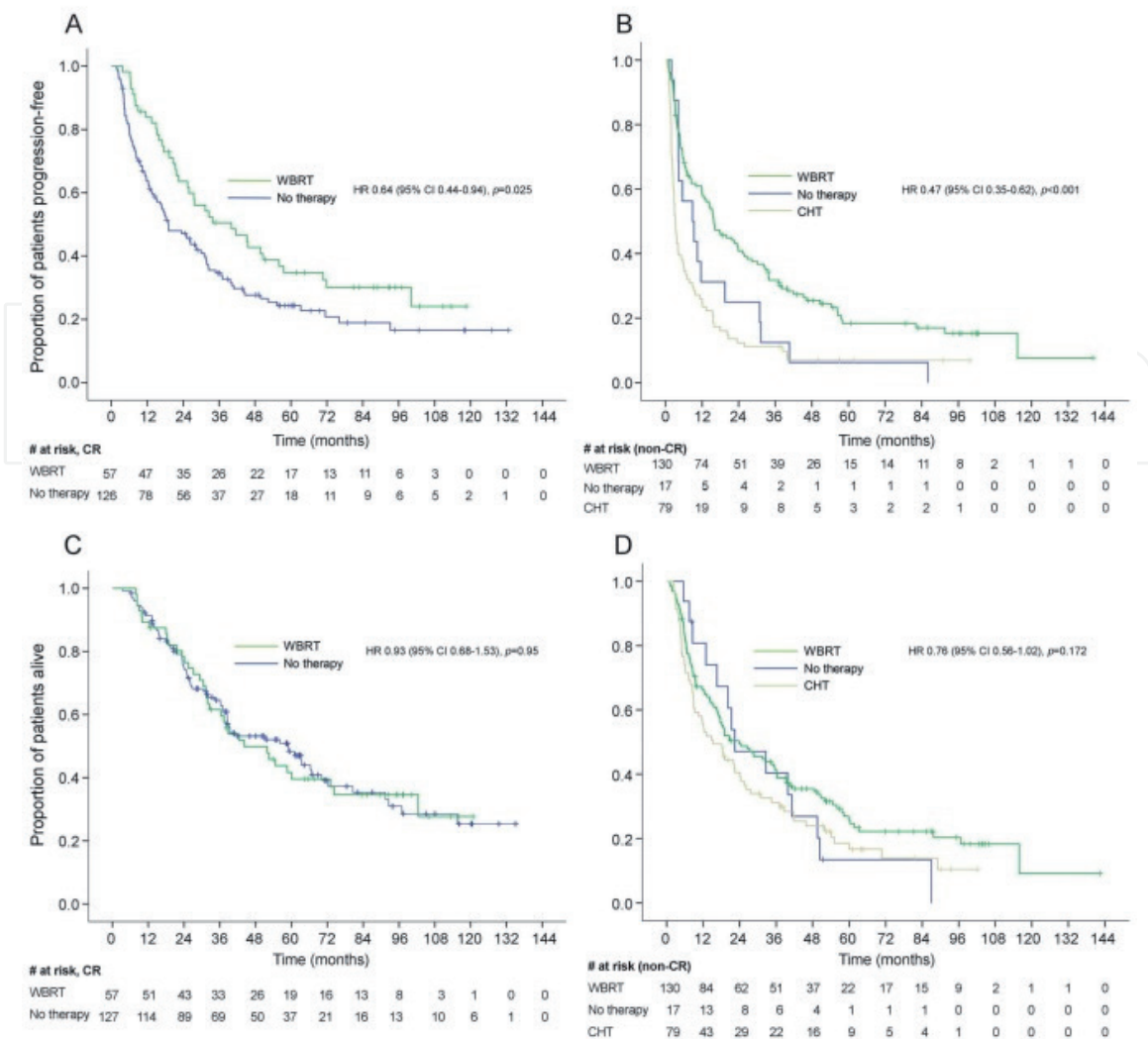


Figure 5. PFS from last high-dose methotrexate-based chemotherapy and overall survival analyzed as-treated in the ITT population. (A) Progression-free survival (PFS) from last high-dose methotrexate (HDMTX)-based chemotherapy (CHT) in patients with complete response (CR). (B) PFS from last HDMTX-based CHT in patients without CR. (C) Overall survival (OS) in patients with CR. (D) OS in patients without CR. The good outcome of the non-CR patients without further treatment can be explained by the fact that 6 of them probably did in fact have CR after HDMTX-based CHT. They were documented as having CR upon follow-up without further therapy. Moreover, one additional patient received whole-brain radiotherapy (WBRT) without progression 6 months after HDMTX-based CHT. CI = confidence interval; HR = hazard ratio; and ITT = intent-to-treat [25].

Different radiation field and reduced dose WBRT consolidation in responding patients have been explored in studies and appear to be associated with higher response and decreased neurotoxicity rates compared with higher dose WBRT [30–33]. An example of the impact on the outcome and neurologic performance of different radiation fields and doses was assessed in a study in which 33 patients with PCNSL who achieved complete response after MTX-containing chemotherapy were referred to consolidation WBRT [30]. The study demonstrated that higher irradiation doses (≥ 40 Gy) were not associated with improved disease control compared to lower doses (30–36 Gy). Also, disease control does not significantly differ with regard to irradiation doses to the tumor bed, while functional impairment as assessed by mini mental status examination was significantly more common in patients treated with a WBRT dose ≥ 40 Gy. Thus, one can consider that consolidation with WBRT 36 Gy is advisable in patients with PCNSL in complete response after HD-MTX based chemotherapy. Higher doses do not change the outcome and could increase the risk of neurotoxicity. The findings of this important study are illustrated in **Figure 7** [30].

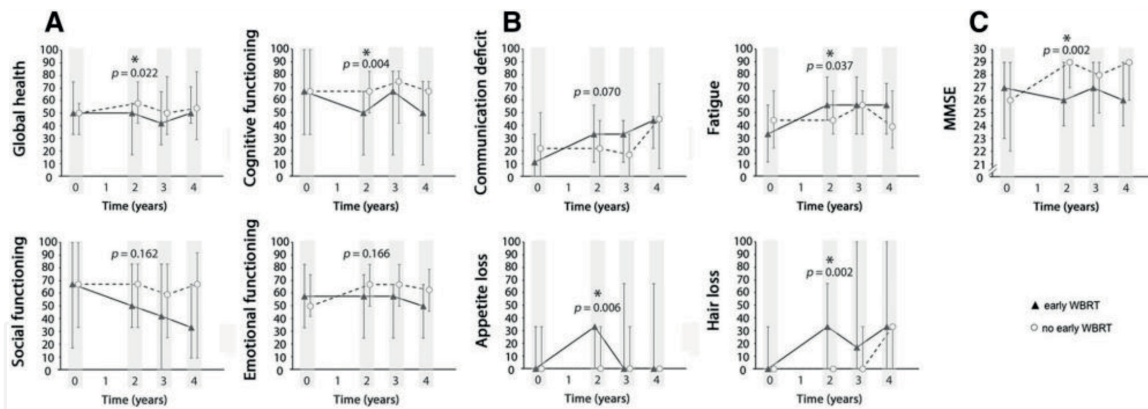


Figure 6.

Comparison of early-whole brain radiotherapy (WBRT) with no early-WBRT with regard to global health, cognitive-emotional-social functioning using the time course of median scores, interquartile ranges (IQR) for EORTC-QLQ-C30, BN20 dimensions, and the mini mental state examination (MMSE) of the G-PCNSL-SG-1 trial * $p < 0.05$. (A) scores for emotional and social functioning, (B) symptom scores and (C) Mini Mental State Examination (MMSE) [23].

As a different radiation fractionation, a phase I/II, NRG Oncology RTOG 0227 study of MTX, Rituximab and Temozolomide, plus hyperfractionated WBRT (36 Gy in twice daily 1.2 Gy fractions) in 66 patients with PCNSL was associated with an objective response rate of 85.7%. This study demonstrated that OS and PFS were improved compared with historical controls from RTOG-9310. Among patients, 66% had grade 3 and 4 toxicities before hWBRT, and 45% of patients experienced grade 3 and 4 toxicities attributable to post hWBRT chemotherapy. Cognitive function and QoL improved or stabilized after hWBRT [31].

Other consecutive prospective studies, the R-MPV (rituximab, MTX, procarbazine, and vincristine) induction chemotherapy followed by consolidation reduced dose WBRT (23.4 Gy/ 1.8 Gy fraction), and cytarabine were found to be feasible and effective. In these studies, patients with ocular involvement were irradiated without orbital shielding to the full dose 23.4 Gy (patients in complete response) or to a dose of 36 Gy (patients with less than a complete response). Response rates were high (79% complete response) allowing a large proportion of patients to receive rdWBRT. These patients achieved durable disease control (2 year PFS 77%) associated with favorable neurocognitive outcomes. Median overall survival could not be reached (median follow-up for survivors, 5.9 years); 3 year OS was 87%. Cognitive assessments showed improvements in terms of executive function and verbal memory after chemotherapy [32, 33].

The mechanisms resulting in radiation-induced neurotoxicity remain to be clarified. However, tissue oxidative stress, vasculopathy, demyelination, and depletion of progenitor oligodendroglial/neural stem cells have been postulated [34].

In addition to its ongoing role as an alternative to second line chemotherapy in younger patients who fail to achieve a complete response with first line systemic chemotherapy alone, WBRT is also a reasonable palliative option in patients who have contraindications to chemotherapy or relapsed, chemotherapy refractory disease.

Stereotactic radiotherapy may be an option for patients who have received WBRT. Prognosis is also influenced by therapy, which may include WBRT or stereotactic radio surgery (SRS). In a study [35], patients who had recurred after WBRT were treated with salvage SRS. The study demonstrated acceptable local control and survival after SRS.

On the other hand, WBRT remains a reasonable salvage therapy in patients who have not responded adequately to induction chemotherapy. In addition, WBRT plus corticosteroids may be used for the palliation of patients who are not candidates

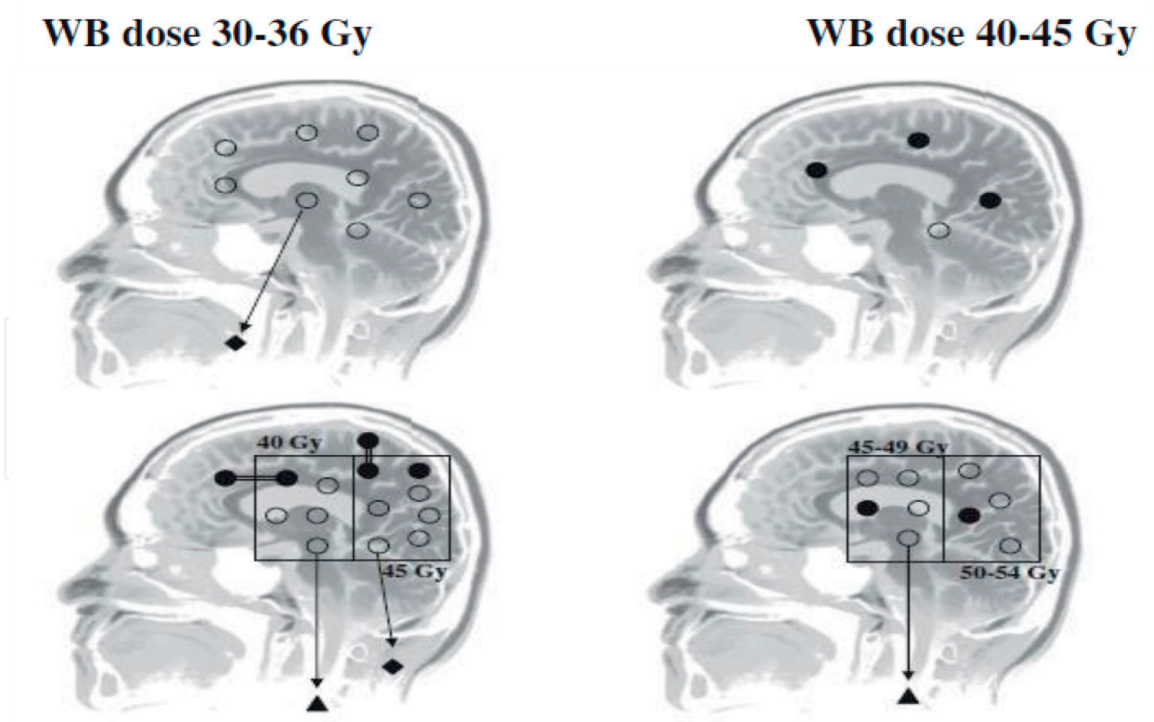


Figure 7.
 Pattern of relapse according to radiation therapy fields and doses. Graphics at the left: patients treated with a WBRT dose of 30–36 Gy. Graphics at the right: patients treated with a WBRT dose 40 Gy. Upper graphics: patients treated without a tumor bed boost. Lower graphics: patients irradiated with a tumor bed boost. Symbols: o = irradiated lesion in continuous CR; ● = relapsed lesion; ●=● = relapse with lesions both within and outside the boosted volume; ▲: = relapse in nonirradiated central nervous system areas (i.e., meninges and spinal cord); ◆ = systemic extra-central nervous system relapse. (Adopted from ref. [30]).

for chemotherapy. Complete responses can be obtained in most patients treated with standard fractionation to 20–40 Gy (for a 74% overall response rate). The median survival from initiation of WBRT was 16 months. The median time to PCNSL progression was 10 months. Treatment associated neurotoxicity is more common among those exposed to a total radiation dose >36 Gy, patients treated within 6 months of receiving MTX, and those older than 60 years of age [36, 37]. Treatment-related neurotoxicity was observed in 22% of patients. Salvage WBRT is effective for recurrent and refractory PCNSL.

7. Follow-up and monitoring

After completion of the initially planned treatment of PCNSL, patients should be evaluated to determine the disease response to treatment and should be followed longitudinally for relapse and long-term treatment toxicities.

Patients should be evaluated no more than 2 months after the completion of planned therapy to determine their response to treatment. Gadolinium-enhanced MRI scans are the standard for the evaluation of bulky parenchymal brain disease. Detailed ophthalmologic examination and lumbar puncture for cytology are required only if these studies were initially positive or if clinically indicated by new symptoms or sign. An interdisciplinary, international consensus group has devised the following response criteria [16].

7.1 Response criteria

The following criteria were developed on the basis of anatomic and radiographic definitions.

Complete response requires the following:

1. Complete disappearance of all enhancing abnormalities on gadolinium-enhanced MRI.
2. No evidence of active ocular lymphoma as defined by the absence of cells in the vitreous and resolution of any previously documented retinal or optic nerve infiltrate.
3. Negative CSF cytology. If the CSF is examined, patients with an Ommaya reservoir should have samples taken for the reservoir and lumbar puncture.
4. At the time a complete response is determined, the patient should have discontinued use of all corticosteroids for at least 2 weeks. Patients who met the criteria for CR may have the following features/limitations:
 - A. Any patient who otherwise meet all criteria for CR but needs steroid therapy should be regarded as unconfirmed CR.
 - B. Some patients will have a small but persistent enhancing abnormality on MRI related to biopsy or focal hemorrhage.
 - C. Patients with a persistent minor abnormality on follow-up ophthalmologic examination.

Partial response (PR) was concluded for patients who met all of the following criteria: equal or more than 50% decrease in the contrast enhancing lesion that was seen on MRI compared to baseline imaging and a decrease in the vitreous cell count or retinal cellular infiltrate. PR was thought to be irrelevant to corticosteroid dose. CSF cytological examination may be negative or continue to show persistent malignant or suspicious cell providing no new sites of disease.

Progressive disease was defined as the following; more than 25% increase in the contrast enhancing lesion that was seen on MRI as compared to the best response, the progression of ocular disease, and the appearance of any new lesion.

Relapsed disease was considered as the appearance of any new lesion. Stable disease is that which does not meet the criteria for CR, CRu, PR, or progressive disease.

8. Prognosis

Untreated PCNSL has a rapidly fatal course, with survival of approximately 1.5 month from the time of diagnosis. Survival increases with combined therapy. In population-based studies, among HIV uninfected cases, a 5-year survival increased from 19.1 (1992–1994) to 30.1% (2004–2006) [38]. Long-term survival is achieved in approximately 15–20% of patients treated with MTX-based therapy and radiation in contemporary clinical trial [39]. In a study on 41 patients treated with MATILDE chemotherapy regimen followed by WBRT, overall response rate was 76% after chemotherapy and 83% after chemotherapy plus radiotherapy. At a median follow-up of 12 years, approximately 75% patients experienced an event, with a 5-year PFS of 24%. At 10 years from diagnosis, no patient showed chronic toxicities, with a mini-mental state examination score of ≥ 29 in all cases but one.

The most consistent prognostic factors are age and performance status. In order to adequately assess patients with disorder, standardized systems for prognosis have

been proposed [40]. Age, PS, LDH serum level, CSF protein concentration, and involvement of deep structures of brain were independent predictors of survival. A prognostic score including these 5 parameters seems advisable in distinguishing different risk groups in PCNSL. The 2 year OS is seen in 80% for patients with zero to one, 48% for patients with two to three, and 15% for patients with four to five unfavorable features.

9. Conclusion

Primary brain lymphoma is an uncommon variant of extranodal NHL. Therapeutic options include treatment with high dose MTX plus combined chemotherapy regimens and WBRT. Patients over age 60 generally succumb to a higher risk of treatment-related neurotoxicity. The optimal consolidation strategy in these patients has yet to be determined, and the best treatment modality should be individualized. By increasing the understanding of the molecular knowledge, and the clinical data originating from new researches, more effective treatment approaches and the best way to the integration of them into the treatment field of PCNSL would be determined.

Thanks

For the endless support, we are thankful to Medical Oncologist Ender KURT.


IntechOpen

Author details

Meral Kurt*, Candan Demiröz Abakay and Ali Altay
Faculty of Medicine Radiotherapy Center, Uludağ University, Bursa, Turkey

*Address all correspondence to: mkurt@uludag.edu.tr

IntechOpen

© 2019 The Author(s). Licensee IntechOpen. This chapter is distributed under the terms of the Creative Commons Attribution License (<http://creativecommons.org/licenses/by/3.0>), which permits unrestricted use, distribution, and reproduction in any medium, provided the original work is properly cited. 

References

- [1] Bataille B, Delwail V, Menet E, et al. Primary intracerebral malignant lymphoma: Report of 248 cases. *Journal of Neurosurgery*. 2000;**92**:261. DOI: 10.3171/jns.2000.92.2.0261
- [2] Hoffman S, Propp JM, McCarthy BJ. Temporal trends in incidence of primary brain tumors in the United States, 1985-1999. *Neuro-Oncology*. 2006;**8**:27. DOI: 10.1215/S1522851705000323
- [3] Villano JL, Koshy M, Shaikh H, et al. Age, gender, and racial differences in incidence and survival in primary CNS lymphoma. *British Journal of Cancer*. 2011;**105**:1414. DOI: 10.1038/bjc.2011.357
- [4] O'Neill BP, Decker PA, Tieu C, Cerhan JR. The changing incidence of primary central nervous system lymphoma is driven primarily by the changing incidence in young and middle-aged men and differs from time trends in systemic diffuse large B-cell non-Hodgkin's lymphoma. *American Journal of Hematology*. 2013;**88**:997. DOI: 10.1002/ajh.23551
- [5] Herrlinger U, Schabet M, Clemens M, et al. Clinical presentation and therapeutic outcome in 26 patients with primary CNS lymphoma. *Acta Neurologica Scandinavica*. 1998;**97**:257. DOI: 10.1111/j.1600-0404.1998.tb00647.x
- [6] Bhagavathi S, Wilson JD. Primary central nervous system lymphoma. *Archives of Pathology & Laboratory Medicine*. 2008;**132**:1830. DOI: 10.1043/1543-2165-132.11.1830
- [7] Montesinos-Rongen M, Siebert R, Deckert M. Primary lymphoma of the central nervous system: Just DLBCL or not? *Blood*. 2009;**113**:7. DOI: 10.1182/blood-2008-04-149005
- [8] Jahnke K, Thiel E, Schilling A, et al. Low-grade primary central nervous system lymphoma in immunocompetent patients. *British Journal of Haematology*. 2005;**128**:616. DOI: 10.1111/j.1365-2141.2004.05361.x
- [9] Martelius T, Lappalainen M, Palomäki M, Anttila VJ. Clinical characteristics of patients with Epstein-Barr virus in cerebrospinal fluid. *BMC Infectious Diseases*. 2011;**11**:281. DOI: 10.1186/1471-2334-11-281
- [10] Rock JP, Cher L, Hochberg FH, et al. Primary CNS lymphoma. In: Yomans JR, editor. *Neurological Surgery*. 4th ed. Philadelphia: WB Saunders; 1996. p. 2688
- [11] Kiewe P, Fischer L, Martus P, et al. Meningeal dissemination in primary CNS lymphoma: Diagnosis, treatment, and survival in a large monocenter cohort. *Neuro-Oncology*. 2010;**12**:409. DOI: 10.1093/neuonc/nop053
- [12] Korfel A, Weller M, Martus P, et al. Prognostic impact of meningeal dissemination in primary CNS lymphoma (PCNSL): Experience from the G-PCNSL-SG1 trial. *Annals of Oncology*. 2012;**23**:2374. DOI: 10.1093/annonc/mdr627
- [13] Taylor JW, Flanagan EP, O'Neill BP, et al. Primary leptomeningeal lymphoma: International primary CNS lymphoma collaborative group report. *Neurology*. 2013;**81**:1690. DOI: 10.1212/01.wnl.0000435302.02895.f3
- [14] Tomita M, Koike H, Kawagashira Y, et al. Clinicopathological features of neuropathy associated with lymphoma. *Brain*. 2013;**136**:2563. DOI: 10.1093/brain/awt193
- [15] Grisariu S, Avni B, Batchelor TT, et al. Neurolymphomatosis: An international primary CNS

lymphoma collaborative group report. *Blood*. 2010;**115**:5005. DOI: 10.1182/blood-2009-12-258210

[16] Abrey LE, Batchelor TT, Ferreri AJ, et al. Report of an international workshop to standardize baseline evaluation and response criteria for primary CNS lymphoma. *Journal of Clinical Oncology*. 2005;**23**:5034. DOI: 10.1200/JCO.2005.13.524

[17] Porter AB, Giannini C, Kaufmann T, et al. Primary central nervous system lymphoma can be histologically diagnosed after previous corticosteroid use: A pilot study to determine whether corticosteroids prevent the diagnosis of primary central nervous system lymphoma. *Annals of Neurology*. 2008;**63**:662. DOI: 10.1002/ana.21366

[18] Bühring U, Herrlinger U, Krings T, et al. MRI features of primary central nervous system lymphomas at presentation. *Neurology*. 2001;**57**:393. DOI: <https://doi.org/10.1212/WNL.57.3.393>

[19] Mohile NA, Deangelis LM, Abrey LE. Utility of brain FDG-PET in primary CNS lymphoma. *Clinical Advances in Hematology & Oncology*. 2008;**6**:818

[20] Karantanis D, O'Neill BP, Subramaniam RM, et al. Contribution of F-18 FDG PET-CT in the detection of systemic spread of primary central nervous system lymphoma. *Clinical Nuclear Medicine*. 2007;**32**:271. DOI: 10.1097/01.rlu.0000257269.99345.1b

[21] Rubenstein JL, Hsi ED, Johnson JL, et al. Intensive chemotherapy and immunotherapy in patients with newly diagnosed primary CNS lymphoma: CALGB 50202 (Alliance 50202). *Journal of Clinical Oncology*. 2013;**31**:3061. DOI: 10.1200/JCO.2012.46.9957

[22] Kasenda B, Ferreri AJ, Marturano E, et al. First-line treatment and outcome of elderly patients with primary

central nervous system lymphoma (PCNSL)—A systematic review and individual patient data meta-analysis. *Annals of Oncology*. 2015;**26**:1305. DOI: 10.1093/annonc/mdv076

[23] Herrlinger U, Schäfer N, Fimmers R, et al. Early whole brain radiotherapy in primary CNS lymphoma: Negative impact on quality of life in the randomized G-PCNSL-SG1 trial. *Journal of Cancer Research and Clinical Oncology*. 2017;**143**:1815. DOI: 10.1007/s00432-017-2423-5

[24] Thiel E, Korfel A, Martus P, et al. High-dose methotrexate with or without whole brain radiotherapy for primary CNS lymphoma (G-PCNSL-SG-1): A phase 3, randomised, non-inferiority trial. *The Lancet Oncology*. 2010;**11**:1036. DOI: 10.1016/S1470-2045(10)70229-1

[25] Korfel A, Thiel E, Martus P, et al. Randomized phase III study of whole-brain radiotherapy for primary CNS lymphoma. *Neurology*. 2015;**84**:1242. DOI: 10.1212/WNL.0000000000001395

[26] O'Brien PC, Roos DE, Pratt G, et al. Combined-modality therapy for primary central nervous system lymphoma: Long-term data from a phase II multicenter study (trans-Tasman radiation oncology group). *International Journal of Radiation Oncology, Biology, Physics*. 2006;**64**:408. DOI: 10.1016/j.ijrobp.2005.07.958

[27] Omuro AM, Ben-Porat LS, Panageas KS, et al. Delayed neurotoxicity in primary central nervous system lymphoma. *Archives of Neurology*. 2005;**62**:1595. DOI: 10.1001/archneur.62.10.1595

[28] Schuurmans M, Bromberg JE, Doorduijn J, et al. Primary central nervous system lymphoma in the elderly: A multicentre retrospective

analysis. *British Journal of Haematology*. 2010;**151**:179. DOI: 10.1111/j.1365-2141.2010.08328.x

[29] Doolittle ND, Korfel A, Lubow MA, et al. Long-term cognitive function, neuroimaging, and quality of life in primary CNS lymphoma. *Neurology*. 2013;**81**:84. DOI: 10.1212/WNL.0b013e318297eeba

[30] Ferreri AJ, Verona C, Politi LS, et al. Consolidation radiotherapy in primary central nervous system lymphomas: Impact on outcome of different fields and doses in patients in complete remission after upfront chemotherapy. *International Journal of Radiation Oncology, Biology, Physics*. 2011;**80**:169. DOI: 10.1016/j.ijrobp.2010.01.066

[31] Glass J, Won M, Schultz CJ, et al. Phase I and II study of induction chemotherapy with methotrexate, rituximab, and Temozolomide, followed by whole-brain radiotherapy and postirradiation temozolomide for primary CNS lymphoma: NRG oncology RTOG 0227. *Journal of Clinical Oncology*. 2016;**34**:1620. DOI: 10.1200/JCO.2015.64.8634

[32] Morris PG, Correa DD, Yahalom J, et al. Rituximab, methotrexate, procarbazine, and vincristine followed by consolidation reduced-dose whole-brain radiotherapy and cytarabine in newly diagnosed primary CNS lymphoma: Final results and long-term outcome. *Journal of Clinical Oncology*. 2013;**31**:3971. DOI: 10.1200/JCO.2013.50.4910

[33] Shah GD, Yahalom J, Correa DD, et al. Combined immunochemotherapy with reduced whole-brain radiotherapy for newly diagnosed primary CNS lymphoma. *Journal of Clinical Oncology*. 2007;**25**:4730. DOI: 10.1200/JCO.2007.12.5062

[34] Omuro AM, Martin-Duverneuil N, Delattre JY. Complications of

radiotherapy to the central nervous system. *Handbook of Clinical Neurology*. 2012;**105**:887-901. DOI: 10.1016/B978-0-444-53502-3.00030-6

[35] Chao ST, Barnett GH, Vogelbaum MA, et al. Salvage stereotactic radiosurgery effectively treats recurrences from whole-brain radiation therapy. *Cancer*. 2008;**113**:2198. DOI: 10.1002/cncr.23821

[36] Nguyen PL, Chakravarti A, Finkelstein DM, et al. Results of whole-brain radiation as salvage of methotrexate failure for immunocompetent patients with primary CNS lymphoma. *Journal of Clinical Oncology*. 2005;**23**:1507. DOI: 10.1200/JCO.2005.01.161

[37] Hottinger AF, DeAngelis LM, Yahalom J, Abrey LE. Salvage whole brain radiotherapy for recurrent or refractory primary CNS lymphoma. *Neurology*. 2007;**69**:1178. DOI: 10.1212/01.wnl.0000276986.19602.c1

[38] Shiels MS, Pfeiffer RM, Besson C, et al. Trends in primary central nervous system lymphoma incidence and survival in the U.S. *British Journal of Haematology*. 2016;**174**:417. DOI: 10.1111/bjh.14073

[39] Ferreri AJ, Ciceri F, Brandes AA, et al. MATILDE chemotherapy regimen for primary CNS lymphoma: Results at a median follow-up of 12 years. *Neurology*. 2014;**82**:1370. DOI: 10.1212/WNL.0000000000000314

[40] Ferreri AJ, Blay JY, Reni M, et al. Prognostic scoring system for primary CNS lymphomas: The international Extranodal lymphoma study group experience. *Journal of Clinical Oncology*. 2003;**21**:266. DOI: 10.1200/JCO.2003.09.139