

We are IntechOpen, the world's leading publisher of Open Access books Built by scientists, for scientists

4,800

Open access books available

122,000

International authors and editors

135M

Downloads

Our authors are among the

154

Countries delivered to

TOP 1%

most cited scientists

12.2%

Contributors from top 500 universities



WEB OF SCIENCE™

Selection of our books indexed in the Book Citation Index
in Web of Science™ Core Collection (BKCI)

Interested in publishing with us?
Contact book.department@intechopen.com

Numbers displayed above are based on latest data collected.

For more information visit www.intechopen.com



Oral Mucosal Trauma and Injuries

Meltem Koray and Tosun Tosun

Abstract

Trauma-related oral lesions are common in clinical practice of dentistry and they can impair patients' normal oral function and cause pain in patients' eating, chewing, and talking. An injury to the oral mucosa can result from physical, chemical, or thermal trauma. Such injuries can result from accidental tooth bite, hard food, sharp edges of the teeth, hot food, or excessive tooth brushing. Some injuries can also be caused by iatrogenic damage during dental treatment or other procedures related to oral cavity. In this chapter, oral mucosal trauma and injuries will be examined in four subclasses: physical and mechanical traumas of oral mucosa; chemical injuries of the oral mucosa; radiation injuries; and electrical, thermal burns.

Keywords: trauma, soft tissue injuries, mucosa, traumatic injuries

1. Introduction

Trauma-related oral lesions are common in clinical practice of dentistry. Such lesions can impair patients' normal oral function and can cause pain in patients' eating, chewing, and talking. After receiving a diagnosis with anamnesis, treatment can be provided if the causative factor is removed. An injury to the oral mucosa can result from physical, chemical, or thermal trauma. Such injuries can result from accidental tooth bite, hard food, sharp edges of the teeth, hot food, or excessive tooth brushing. Some injuries can also be caused by iatrogenic damage during dental treatment or other procedures related to oral cavity [2]. This section focuses on common causes, diagnoses, and treatment of traumatic injuries. In the following, a proposed classification of oral mucosal trauma and injuries is described:

Classification of oral mucosal trauma and injuries:

A. Physical and mechanical traumas of oral mucosa

1. Linea alba
2. Chronic biting
3. Epulis fissuratum
4. Inflammatory papillary hyperplasia
5. Denture stomatitis
6. Traumatic ulcer
7. Recurrent aphthous stomatitis

8. Nicotine stomatitis
9. Lip-licking dermatitis
10. Traumatic fibroma
11. Trauma associated with sexual practice

B. Chemical injuries of the oral mucosa

1. Chemical burn
2. Post-anesthetic ulceration of palate
3. Contact allergic stomatitis

C. Radiation injuries

1. Oral mucositis
2. Actinic cheilitis

D. Electrical and thermal burn

1. Electrical burn
2. Thermal burn

2. Physical and mechanical traumas of oral mucosa

2.1 Linea alba (white line)

Localization: Buccal mucosa, at the level of the occlusal line of the teeth. It is a horizontal streak on the buccal mucosa at the level of the occlusal plane extending from the commissure to the posterior teeth.

Clinical features: Lesions are mostly asymptomatic. The common visual symptom of linea alba is the presence of whitish, linear, filament-like plicae formations, horizontally parallel to the occlusal level of bicuspid and molar teeth in both left and right sides of buccal mucosa (**Figure 1**). Palpation should give a tactile sensation of normal mucosa texture. It is more prominent in individuals with reduced overjet of the posterior teeth. It is often scalloped and restricted to dentulous areas. The diagnosis is based on clinical grounds alone [11].

Etiology: Lesions mainly arise from occlusal traumas of posterior teeth generated due to the parafunctional cheek sucking of patient. The sucking habit is also associated with friction between buccal tubercles and irritates the buccal mucosa by pressure. Prevalence of such lesions is about 6.2–13% in the population [4, 5, 9].

Treatment: No treatment is required; the white streak may disappear spontaneously in some people. But very sharp-edged teeth can be corrected.

2.2 Chronic biting (*Morsicatio buccarum*)

Localization: The lesions made by chronic bite trauma (nibbling) on the buccal mucosa generally cause keratinized shreds, tissue tags, or erosive and desquamative surfaces [20]. These lesions according to their localizations are called as “morsicatio buccarum” if they are localized on the buccal mucosa, “morsicatio labiorum” if they

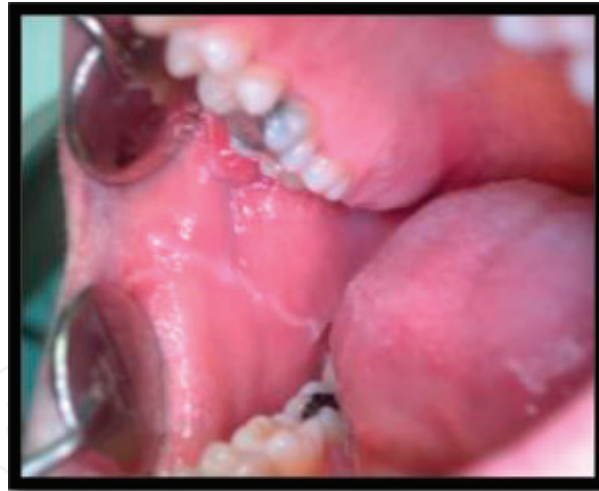

Figure 1.
Linea alba seen on the buccal mucosa.

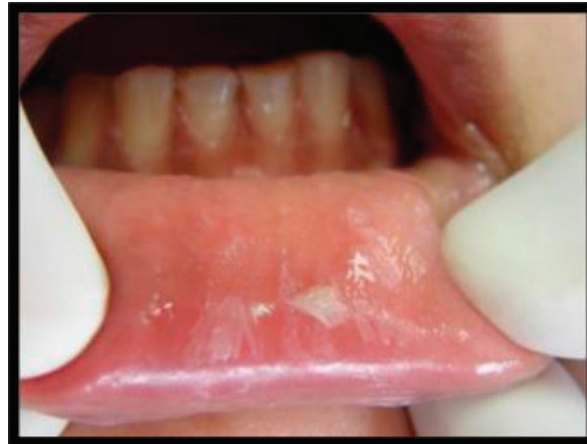

Figure 2.
Diffuse irregular white area of lower lip due to chronic biting.

appear on the labial mucosa, and “morsicatio linguarum” if they occur on the lateral borders of the tongue [21]. The lesions are seen on the buccal mucosa, bilateral chewing line, labial mucosa, and lateral edges of the tongue.

Clinical features: Lesions are apparent as shallow whitish wrinkles which are diffuse and present irregularly on the buccal, labial mucosa, and tongue. Epithelial desquamation occurs on the surface (**Figures 2 and 3**). In some cases, erosions and petechiae may be seen. The lesions could be diagnosed by clinical inspection [11].

Etiology: It is often related to chronic biting of the oral mucosa seen in psychologically tense patients. Parafunctional bite of the buccal mucosa, lips, and tongue until wear of superficial epithelium and wound formation is consciously made by those patients. The incidence of morsicatio buccarum was reported to be 2.5% in Caucasian populations [16].

Treatment: Treatment is usually unnecessary. It is recommended to stop the habit. Psychological treatment can be suggested for stopping a bad habit. Acrylic splint can be made on the occlusal surface of the teeth. It is accepted as a precancerous lesion.

2.3 Epulis fissuratum

Localization: The lesion presents as multiple or single inflamed and elongated papillary folds, usually in the mucolabial or mucobuccal grooves around poorly fitting partial or complete denture.

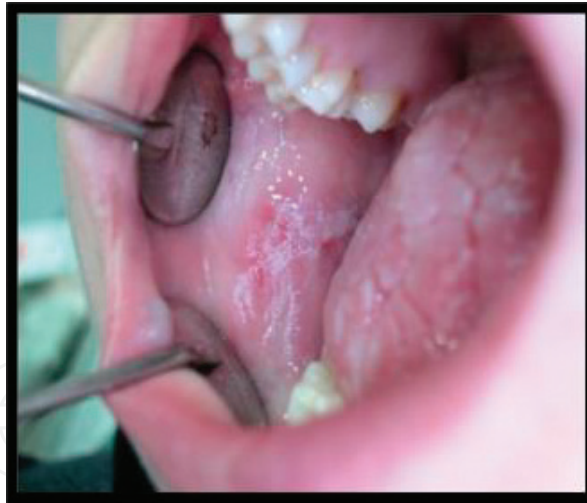

Figure 3.
Chronic biting of the buccal mucosa with diffuse irregular lesions.

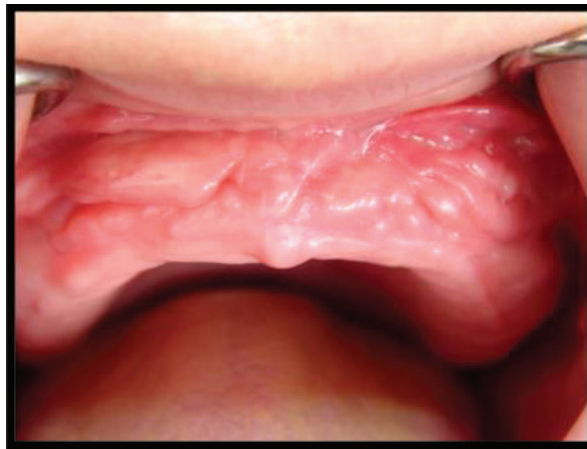

Figure 4.
Epulis fissuratum.

Clinical features: Epulis fissuratum, reactive fibrous hyperplasia, or denture-induced fibrous hyperplasia is a relatively common hyperplasia of the fibrous connective tissue. Clinically, it presents as a raised sessile lesion in the form of folds with a smooth surface with normal or erythematous overlying mucosa. Because of chronic irritation, it may get traumatized and present with an ulcerated surface. It is considered as an overgrowth of intraoral tissues resulting from chronic irritation. This mucogingival hyperplasia is a reactive condition of oral mucosa to excessive mechanical pressure on mucosa (**Figure 4**).

Etiology: Trauma and irritation are the two main etiological factors responsible for occurrence of epulis. It is attributed to reactive tissue response to chronic irritation and trauma caused by a poorly fitted partial or complete prosthesis [13]. Prevalence of epulis fissuratum lesions was found to be 4.3% in Chilean population [22].

Treatment: Surgical excision and construction of a new denture adequate for the newly established mucosal contours. Excision can be performed by either conventional surgical approaches or by use of laser.

2.4 Inflammatory papillary hyperplasia

Localization: Inflammatory papillary hyperplasia of the palate is a benign epithelial proliferation that develops in patients who have complete acrylic maxillary dentures. Lesions are mostly seen in the hard palate. In few examples, they could be detected also in the lower jaw.

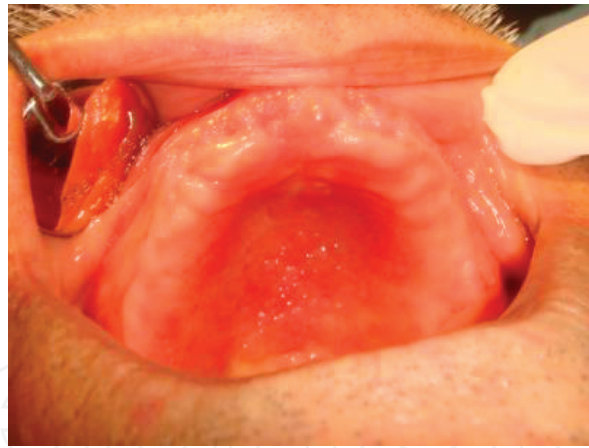


Figure 5.
Inflammatory papillary hyperplasia on the hard palate.

Clinical features: Inflammatory papillary hyperplasia lesions are generally asymptomatic and have color spectrums varying from red to pink. It presents as hyperplastic nodules 3–4mm wide, with erythematous and cobblestone appearance (**Figure 5**).

Etiology: Most often, patients wearing removable upper dentures show symptoms of inflammatory papillary hyperplasia. But rarely, it can be seen also in maxillary normal dentition. Pathogenic etiology is unclear. Continuous usage of prosthesis without night rest, inadequate denture flange edges, poor oral hygiene habits, allergic reactions against denture liners, abuse of tobacco, senility, and several systemic reactions are other reasons [6].

These dentures are often old, ill-fitting, badly cleaned, and worn all the time.

Treatment: Surgical excision and construction of a new denture. Different techniques have been described, including supra-periosteal excision, the blade-loop technique, or electrosurgery, with or without soft tissue grafts, cryosurgery, and laser [8]. Iegami et al. [23], reported that inflammatory papillary hyperplasia could completely be eliminated by the generated pressure combined with antioxidant and anti-inflammatory pastes and following this, a new set of complete dentures could be delivered to the patient.

2.5 Denture stomatitis

Localization: Denture stomatitis is seen under ill-fitting total or partial dentures.

Clinical features: It is characterized by diffuse erythema, edema, and sometimes petechiae and white spots that represent accumulations or *Candida* hyphae (**Figure 6**). Denture stomatitis is usually asymptomatic.

Etiology: Mechanical irritation from *C. albicans* dentures or a tissue response to microorganisms living beneath the dentures.

Treatment: Improvement of denture fit, oral hygiene, and topical or systemic antifungals or tissue disinfection by diode laser irradiation [3]. In the management of denture stomatitis, a more conservative approach regarding the usage of mouth rinses was advised by Koray et al. [19], in order to prevent the adverse effects and complications of systemic drugs.

2.6 Traumatic ulcers

Localization: Presence of traumatic ulcers is a relatively common finding in dental practice. Such lesions arise from trauma related to bite of buccal mucosa, lateral border of the tongue or lips during chewing. Traumatic ulcers seen in the mucobuccal folds

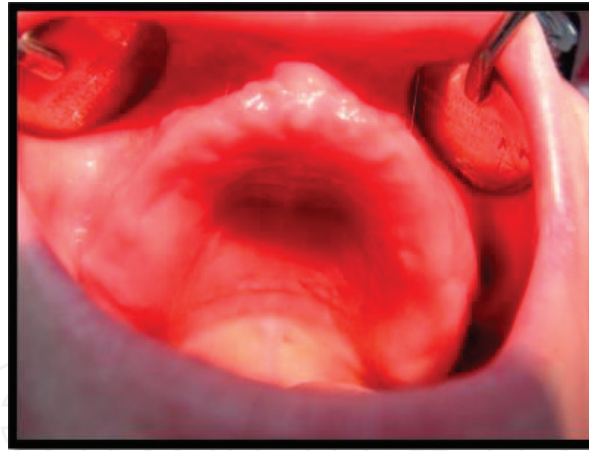


Figure 6.
Denture stomatitis located on the denture-bearing area of maxilla.

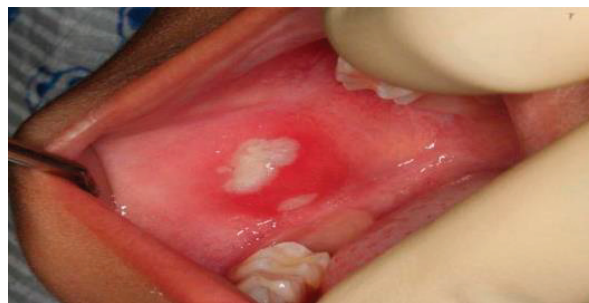

Figure 7.
Traumatic ulcer after accidental mucosal biting.

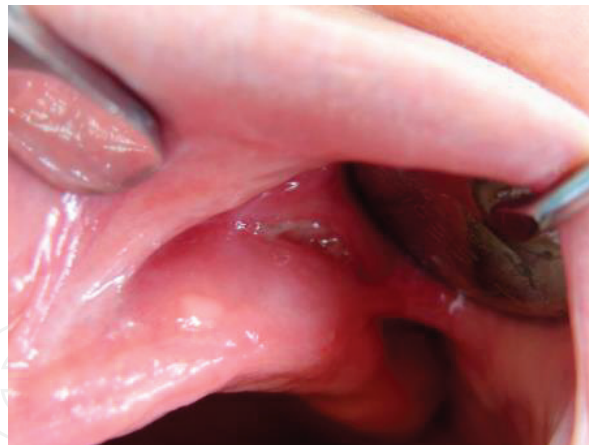

Figure 8.
Traumatic ulcer caused by sharp edges of prosthesis.

and gingiva are related to different irritant factors such as hard foods and inappropriate hard brushing. Traumatic ulcer due to lip biting after inferior dental nerve block is seen on the lower lip. During orthodontic treatment, traumatic ulcers can occur especially on the buccal mucosa due to the irritation of braces or appliance wires.

Clinical features: Traumatic ulcers could be of solitary shallow or deep discontinuity type showing on the epithelium and are associated with peripheral keratosis of mild to severe degree [2]. The bottom of the ulcerative lesions is made of whitish or yellow pseudomembrane. Upon elimination of the causative factor, often the ulcer heals with or without scar depending on the extent of the damage occurred.

Etiology: They could originate from accidental mucosal biting (**Figure 7**), sharp edges of prosthesis (**Figure 8**), sharp or pointed food stuff (**Figure 9**), during

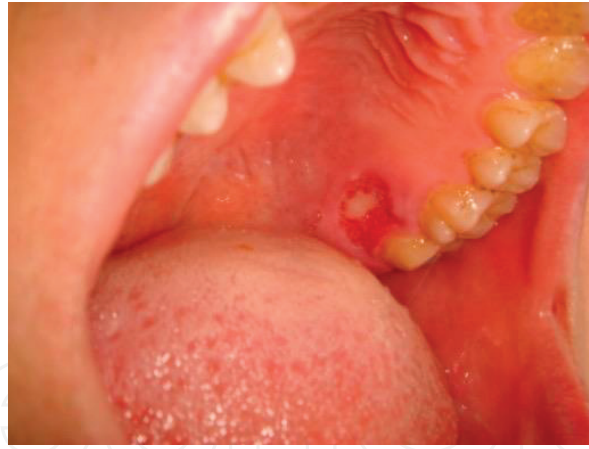

Figure 9.
Traumatic ulcer caused by sharp or puncturing food stuff.

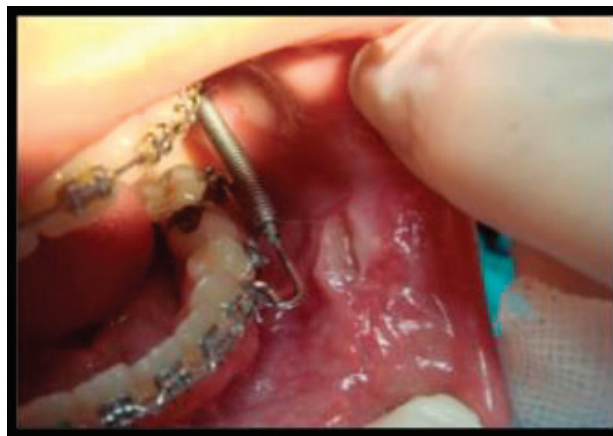

Figure 10.
Traumatic ulcers during orthodontic treatment.

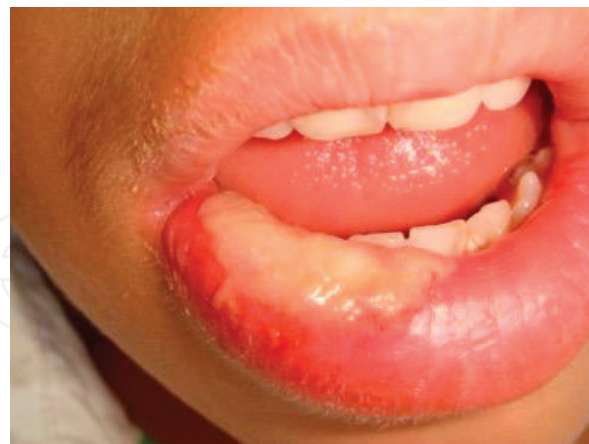

Figure 11.
Lip biting after injection of local anesthetic solutions.

orthodontic treatment (**Figure 10**), lip biting after injection of local anesthetic solutions (**Figure 11**), neonatal teeth (**Figure 12**), or faulty tooth brushing [1]. During dental treatments, iatrogenic damages can result in traumatic ulcer formation. Some medical treatments can cause oral ulcerations, such as brutal intubation for general anesthesia, ENT surgeries, or endoscopic interventions and iatrogenic malpractice applications. A high prevalence of traumatic ulcer of about 21.5% was reported among lower classes of Brazilian population [24]. Most prevalent types of lesions were reported to be traumatic ulcer and actinic cheilitis (7.5% for each) [25]. Among the

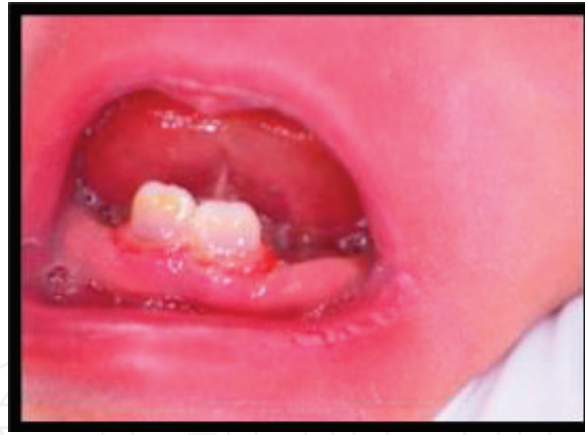

Figure 12.
Traumatic ulcer caused by neonatal teeth.

etiological factors of traumatic ulcers could be mentioned traumas caused by bites, dental appliances, inappropriate tooth brushing, misfit of removable partial or total dentures, irritating caries edges, malocclusion and puncturing restorations [25].

Treatment: Most often, traumatic ulcers can heal spontaneously and uneventfully without complications in a brief period of time. But, in case of persistent traumatic factors, such as presence of sharp tooth morphology, cutting edges of restorations, and puncturing appliance contours, especially inadequate surfaces of removable prosthesis, continuous trauma arising from above-mentioned causes can lead to formation of chronic ulcers.

2.7 Recurrent aphthous stomatitis

Localization: Non-keratinized oral mucosa is most frequently affected.

Clinical features: Recurrent lesions related to multifactorial chronic inflammation named as recurrent aphthous stomatitis (RAS) exhibit round or ovoid shape, pseudomembrane-covered ulcerations on the non-keratinized oral mucosa. Ulcers are surrounded by erythematous halo with superficial necrotic center and they are painful [10] (**Figure 13**).

Etiology: RAS is a complicated condition and the precise etiology still remains unknown. Several predisposing factors have been reported, such as trauma allergy, genetic predisposition, endocrine disturbances, emotional stress, and hematological deficiencies. Detailed examination of RAS history can explore the original etiology [27].

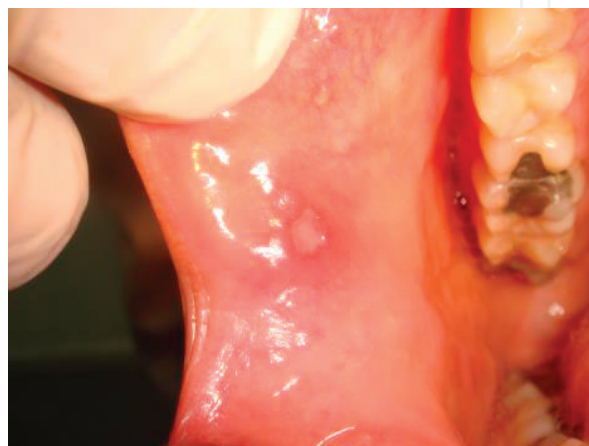

Figure 13.
Recurrent aphthous stomatitis on the buccal mucosa.

Treatment: The real etiological factors of RAS are still unclear and all treatment strategies are symptomatic. Fruit consumption would be useful to replace antioxidants via vitamin replenishment. Topical therapies such as mouth rinses are preferred as they have less risk of adverse effects [26, 27]. Pain relief is the main strategy of treatment. Anti-inflammatory coverage and reduction in function helps to decrease lesion duration, frequency, and recurrence. Topically applied medicaments such as antibiotics, local analgesics, glucocorticoids, astringents, hyaluronic acid gel, and low-level laser therapy are treatments of choice [10].

2.8 Nicotine stomatitis (smoker's palate)

Localization: Nicotine stomatitis is a common tobacco-related type of keratosis that exclusively occurs on the hard palate.

Clinical features: The palatal mucosa initially appears with redness. Subsequently, around the minor salivary gland ducts with inflamed and dilated orifices, many micronodules of punctate red centers form and make diffuse, grayish-white color wrinkles [5]. This type of lesion is not precancerous.

Etiology: Elevated temperature, rather than the tobacco chemicals, is responsible for this lesion. Among elderly Indian and Thai people, the general oral mucosal lesion type is smoker's palate with an incidence of 43%. Lesions mostly involve maxillary hard palate region with a prevalence of 23.1% [17, 18].

Treatment: Cessation of smoking.

2.9 Lip-licking dermatitis

Localization: Lips and its surrounding dermis

Clinical features: Erythematous lesions involve perioral skin and lips. Lesions may be associated with skin peeling, crusting, and fissuring to different degrees (Figure 14). Most often a burning sensation is present [11].

Etiology: Chronic licking

Treatment: Elimination of licking, and topical steroids.

2.10 Traumatic fibroma

Localization: The most common sites of traumatic fibroma are the tongue, buccal mucosa, and lower labial mucosa.

Traumatic or irritation fibroma is a common benign exophytic and reactive oral lesion that develops secondary to injury.

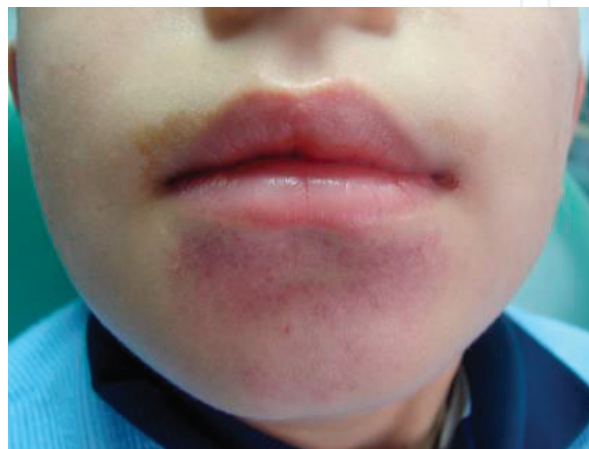

Figure 14.
Lip-licking dermatitis due to sucking a ball all day.

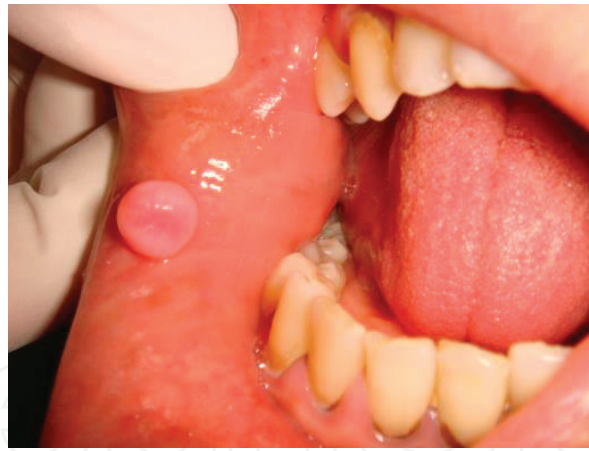

Figure 15.
Traumatic fibroma of the buccal mucosa.

Clinical features: Lesions are shown as broad-based, with light color in respect to neighboring normal tissue, superficially whitish as the secondary trauma causes formation of hyperkeratotic ulcerative surface.

Etiology: Recurrent repair process triggers the formation of fibromas which are accompanied by granulation and scar tissue. Fibroma is a result of a chronic repair process that includes granulation tissue and scar formation resulting in a fibrous submucosal mass. After surgical removal, recurrence may happen if repetitive trauma factor is not eliminated. Otherwise, lesions do not have malign neoplastic character and risk of repeated lesion formation [14] (**Figure 15**). According to Sangle et al. [28], traumatic fibroma with an incidence of 36.5% is the most common clinical lesion type; whereas histologically, the fibrous hyperplasia was found to be the most common one with a recurrence of 37.4%. Clinically, lesions with reactive characteristics may be sessile (51%) or pedunculated (49%) [28].

Treatment: Surgical excision.

2.11 Trauma associated with sexual practice

Localization: Oro-genital stimulation has become a popular practice during the last few decades and this is more common among homosexual males and females

Clinical features: This generally manifests as erythema, ecchymosis, or petechiae in the soft palate. These lesions may be noticed during routine oral examinations.

Etiology: Dentists should be aware of the reason and oral symptoms of lesions related to oro-genital sex habit. Among oro-genital sex actions, the most traumatic one is so called “fellatio” where male genital organ is taken into the mouth of partner to suck it and can cause lacerations to buccal mucosa and cheeks [2].

Treatment: The lesions are generally asymptomatic and heal within 7–10 days.

3. Chemical injuries of the oral mucosa

3.1 Chemical burn

Localization: Gingiva and mucobuccal folds are main localization regions of such lesions.

Clinical features: The wounds have irregular shape and white color, are overlaid by a pseudomembrane, and are very painful. Lesions can cover an extended area. If the lesions are contacted shortly, a shallow whitish and wrinkled appearance occurs. Brief contacts cannot cause necrosis [5].

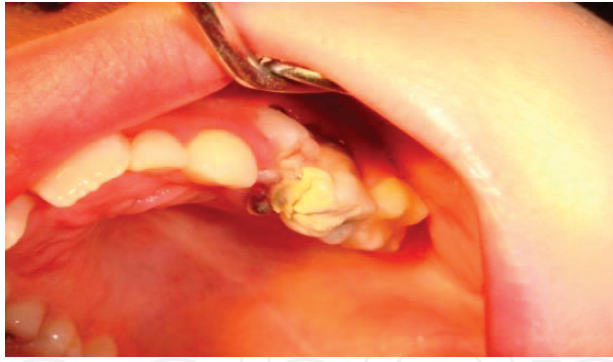

Figure 16.
Acid/arsenic injury.

Etiology: Caustic chemical and drug materials when they come in contact with the oral mucosa are often very irritating and cause direct mucosal trauma. Inappropriate usage of medications, such as aspirin application onto the neighboring mucosa of painful teeth with decay, may result in mucosal trauma. Iatrogenically, during dental treatments irrigant solutions (sodium hypochlorite or formalin) or some endodontic pastes with arsenic can irritate the mucosa [2] (**Figure 16**). However, such injuries are not very common since the introduction of rubber dam in dental practice.

Treatment: The best treatment of chemical burns of the oral cavity is prevention. The proper use of a rubber dam during endodontic procedures reduces the risk of iatrogenic chemical burns. Superficial burns of mucosa can heal in a short period of time (within 1 or 2 weeks) as the turn-over of oral mucosa is very high [5]. Oral surgery and antibiotics are necessary in very rare cases. Gel with hyaluronic acid can accelerate the healing process. Possible treatments after chemical injuries, in relation with the severity of wounds, are topical and intralesional corticosteroid applications, caustic acid ingestion, commissuroplasty, mucosal flaps, free radial forearm flap and free jejunal graft, surgeries made with electrocautery or soft tissue laser, and wound coverage by periodontal pack [29].

3.2 Post-anesthetic ulceration of palate

Localization: Post-anesthetic ulceration due to dental nerve block is seen on palatal mucosa. Ischemic necrosis of tissues may follow injections of local anesthetics. This can be due to the irritating nature of a solution, pressure from large volumes, or constriction of the vasculature by vasopressors [30, 31].

Clinical features: The floor of the ulcer is covered with grayish-white necrotic slough with sloping edge and erythematous margins; on palpation, the ulcer is slightly tender with no indurations present.

Etiology: Post-anesthetic ulceration can occur following the rapid injection of local anesthetic solutions, particularly those containing a vasoconstrictor.

Treatment: Management is usually conservative. It mainly consists of reassuring the patient, prescribing analgesics, and combination of topical antiseptic and anesthetic preparations. Healing generally occurs within 8–10 days after the onset of the lesion. Rarely surgical intervention is necessary when ulcer does not heal. An oral protective emollient orabase paste can also be prescribed [7].

3.3 Contact allergic stomatitis

Localization: Contact area of oral mucosa due to denture base materials, restorative materials, mouthwashes, dentifrices, chewing gums, food, and other substances. Various chemical or natural agents in contact with the mucosa can irritate and cause

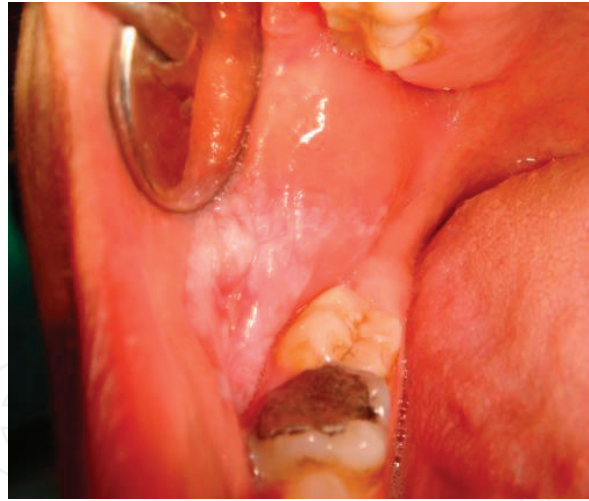

Figure 17.
Contact allergic stomatitis due to amalgam.

contact stomatitis. For example, cinnamaldehyde or cinnamon essential oil, which are commonly used as flavoring agents in foods, beverages, candies, and hygiene products by contact with mucosal surfaces, may trigger the formation of allergic stomatitis [32].

Clinical features: Diffuse erythema, edema, occasionally small vesicles, and shallow erosions appear immediately after contact with the allergen on the affected mucosal surfaces. Lesions are associated with burning symptom. In chronic allergies, whitish, hyperkeratotic, erythematous lesions form [11].

Etiology: Denture base materials, restorative materials like amalgam (**Figure 17**), mouthwashes, dentifrices, chewing gums, food, and other substances may be responsible.

Treatment: Contact allergic stomatitis can be diagnosed by an accurate examination and clear understanding of medical history of the patient. Clinician's diagnostic ability and experience are highly important to avoid further unnecessary examinations, invasive and expensive diagnostic procedures [32]. Treatments include removal of suspected allergens, and use of topical or systemic corticosteroids, antihistamines.

4. Radiation injuries

4.1 Oral mucositis

Localization: Developments in oncology have led to improved survival rates for different cancers. Unfortunately, those treatment regimens have side effects such as formation of oral mucosal lesions. The most common wound type during chemotherapy is oral mucositis which appears by inflamed erosive or ulcerative lesions on mucosal surfaces in the oral cavity [33]. Generally, buccal mucosa is affected by radiation treatment of head and neck tumors [15].

Clinical features: After radiotherapy, at the end of first week, the first oral manifestations can appear. Lesions are erythematous and edematous. In the following days, ulcerative erosions with whitish-yellow exudate appear. As salivary glands are involved, xerostomia occurs and is followed by tongue papillary changes with loss of taste, burning sensation, and pain during function. Speech is also affected negatively [11].

Etiology: Chemotherapy, radiotherapy, or their combinations can lead oral mucositis. The majority of patients (approximately 20–40%) receiving conventional chemotherapy regimens for solid tumors, in relation to the dose and

cytotoxicity of the drug used, have oral mucositis. It is a side effect of radiation treatment of head and neck tumors.

Treatment: Supportive care, cessation of radiation treatment, B-complex vitamins, and sometimes low doses of corticosteroids are suggested.

4.2 Actinic cheilitis

Localization: This type of lower lip lesion is mainly caused by solar irradiation (chronic or excessive exposure to sun light) [35]. Actinic cheilitis (AC) generally involves vermillion border of lower lip.

Clinical features: At the beginning, vermillion border of the lower lip is involved with mild erythema associated with edema, dryness, and fine desquamation. In later phases, smooth epithelium, small whitish-gray areas mixed with red regions, and scaly formations appear. Thin nodules and erosive surfaces may develop with time. The lesions could be precancerous [11].

Etiology: Long-term exposure to sunlight can lead to AC. People exposed to sun light exhibited AC with a prevalence of 9.16%. AC is more frequent among those patients who were exposed to solar irradiation more than 10 years, compared to those who were exposed for less than 10 years. AC is mostly seen in Caucasian males over 50 years of age.

Treatment: Surgical and non-surgical treatment options of AC are available. Surgical treatment or vermilionectomy is an invasive treatment choice and may include some side effects, such as secondary wound healing with delayed re-epithelialization, non-aesthetic appearance of lip, pain during the healing phase, edema, secondary infection, scarring, and disaesthesia [37]. Conventional surgical intervention or electrosurgery, laser ablation, and cryosurgery are alternative methods [38]. Except scalpel vermilionectomy, the other surgical methods mainly do not permit the histopathological examination of all tissues removed as they change the protein nature of specimen by thermal side effects [36, 38]. Among non-surgical therapies include the usage of topical pharmacotherapy with 5-fluorouracil, trichloroacetic acid, imiquimod, ingenol mebutate, and diclofenac. The non-surgical approach is less invasive and has fewer secondary effects. But contrarily, in a systematic review by Carvalho et al. [34], the surgical treatment was found to be more favorable than non-surgical for AC. However, it is very important to protect lips from sunlight.

5. Electrical and thermal burn

5.1 Electrical burn

Localization: Commissures of the mouth often result in severe facial scarring and deformation. Most commissural electrical burns involve mucosa, submucosa, muscle, nerve, and vascular tissue.

Clinical features: Damage made accidentally to lingual or/and labial arteries can cause abundant bleeding. When burned tissues spontaneously start to loosen or slough and occasional trauma occurs, this type of bleeding happens. Generally, this is observed 3–4 days after burn injury [12]. Pressure should be applied to the hemorrhage site to stop the bleeding and the patient should be taken to the nearest hospital emergency room for definitive care.

Etiology: The majority of electrical burns are home accidents. Generally, children play with live electric extension cables/cords and may contact or suck them and are injured by current. Especially in the cable/plug junctions, in non-fitted appliance plugs, the electric current flows through tongue or oral cavity when they are in contact with saliva, and the electric energy burns oral tissues. Children under three years of age are mostly affected by this type of injury [12].

Treatment: Whatever is the severity of burned injury, the basic treatment strategy involves pain relief, infection control, and acceleration of wound repair [39]. Application of antibiotic ointments to the burn area has been recommended by some authors. Systemic antibiotics are recommended by most clinicians to prevent wound infection. Facial disfigurement takes place if splints are not applied. Microstomia reduces mouth opening, renders oral hygiene difficult, and decreases functions of speech and chewing. Most of the cases need plastic surgery. [12].

5.2. Thermal burn

Localization: Oral mucosa, especially tongue and palatal mucosa.

Clinical features: Clinically, the condition appears as a red or white, painful erythema that may undergo desquamation, leaving erosions (**Figure 18**). In excessive damage to tissues, necrosis could appear. In mild lesions, wounds can heal spontaneously within a week [11].

Etiology: Thermal burns mostly happen by accidental ingestion of hot substances. High incidence of thermal burns with a prevalence of 24.6% is seen among children and young patients [40]. Usually caused due to contact with very hot foods, liquids, hot metal objects or iatrogenic usage of lasers (diodes, Nd:YAG, Er:YAG or CO₂), piezoelectric surgery, or electrosurgery devices.

Treatment: No treatment is required for simple lesions. Care should be taken in deep lesions to avoid contamination during healing period. Saline would be prescribed to accelerate wound healing and avoid bacterial ingrowth. Ozone therapy and laser biomodulation could help for good prognosis. In severe damages, prophylactic antibiotic coverage is recommended. In hard tissue damages related to thermal burn, the necrotic area should be removed surgically in order to avoid damage to surrounding vital tissues and obtain blood supply for repair and subsequent regeneration.

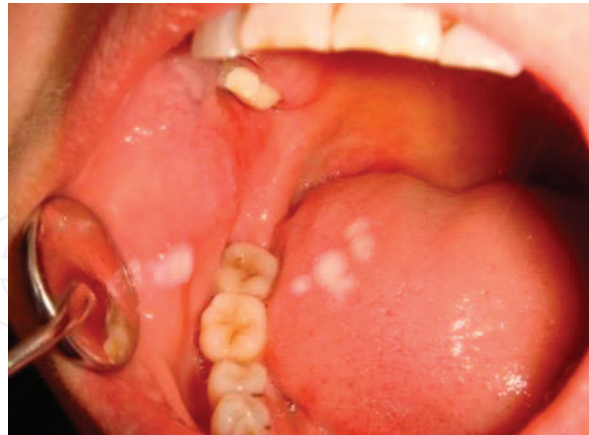

Figure 18.
Thermal iatrogenic burn during aerator usage.

IntechOpen

Author details

Meltem Koray^{1*} and Tosun Tosun²

1 Department of Oral and Maxillofacial Surgery, Dental School, Istanbul University, Istanbul, Turkey

2 Department of Oral and Maxillofacial Surgery, Dental School, Istanbul Aydin University, Istanbul, Turkey

*Address all correspondence to: mkoray@istanbul.edu.tr

IntechOpen

© 2019 The Author(s). Licensee IntechOpen. This chapter is distributed under the terms of the Creative Commons Attribution License (<http://creativecommons.org/licenses/by/3.0>), which permits unrestricted use, distribution, and reproduction in any medium, provided the original work is properly cited. 

References

- [1] Ahmed A, Zardawi FM, Mohammed GN. Oral mucosal and periodontal changes of patients under treatment with manual invisalign and fixed labial orthodontic appliances. *IOSR Journal of Dental and Medical Sciences*. 2015;14(3):102-107
- [2] Ariyawardana A. Traumatic oral mucosal lesions: A mini review and clinical update. *Oral Health and Dental Management*. 2014;13(2):254-259
- [3] deSenna AM, Vieirab MMF, Machado-de-Senac RM, Bertolind AO, Núñeze SC, Ribeirof MS. Photodynamic inactivation of *Candida* ssp. on denture stomatitis. A clinical trial involving palatal mucosa and prosthesis disinfection. *Photodiagnosis and Photodynamic Therapy*. 2018;22:212-216
- [4] El Toum S, Cassia A, Bouchi N, Kassab I. Prevalence and distribution of oral mucosal lesions by sex and age categories: A retrospective study of patients attending Lebanese school of dentistry. *International Journal of Dentistry*. 2018;6. DOI: 10.1155/2018/4030134
- [5] Greenberg MS, Glick M. *Oral Medicine Diagnosis & Treatment* Burket's Tenth Edition. BC Decker Inc.; 2003
- [6] Gual-Vaqués P, Jané-Salas E, Egido-Moreno S, Ayuso-Montero R, MaríRoig A, López-López J. Inflammatory papillary hyperplasia: A systematic review. *Medicina Oral, Patología Oral y Cirugía Bucal*. 2017;22(1):e36-e42
- [7] Gupta R, Garg M, Pawah S, Gupta A. Postanesthetic ulceration of palate: A rare complication. *National Journal of Maxillofacial Surgery*. 2016;7(1):86-88
- [8] Infante-Cossio P, Martinez-de-Fuentes R, Torres-Carranza E, Gutierrez-Perez JL. Inflammatory papillary hyperplasia of the palate: Treatment with carbon dioxide laser, followed by restoration with an implant-supported prosthesis. *British Journal of Oral and Maxillofacial Surgery*. 2007;45:658-660
- [9] Kashani HG, Mackenzie IC, Kerber PE. Cytology of *Linea alba* using a filter imprint technique. *Clinical Preventive Dentistry*. 1980;2:21-24
- [10] Koray M, Ofloglu D, Senemtasi A, İşsever H, Yaltirik M. The efficacy of hyaluronic acid gel in pain control of recurrent aphthous stomatitis. *International Journal of Dentistry and Oral Science*. 2016;3(6):273-275
- [11] Laskaris G. *Pocket Atlas of Oral Diseases*. New York: Thieme Med. Publ; 1998
- [12] LeCompteand EJ, Goldman BM. Oral lectrical burns in children-early treatment and appliance fabrication. *Pediatric Dentistry*. 1982;4(4):333-337
- [13] Mohan RPS, Verma S, Singh U, Agarwal N. Epulis fissuratum: Consequence of ill-fitting prosthesis. *BML Case Reports*. 2013. DOI: 10.1136/bcr-2013-200054
- [14] Rathva VJ. Traumatic fibroma of tongue. *BMJ Case Reports*. 2013. DOI: 10.1136/bcr-2012-008220
- [15] Sonis ST, Costa JW Jr. Oral complications of radiotherapy. In: Kufe DW, Pollock RE, Weichselbaum RR, et al., editors. *Holland-Frei Cancer Medicine*. 6th ed. Hamilton (ON): BC Decker; 2003
- [16] Tortorici S, Corrao S, Natoli G, Difalco P. Prevalence and distribution of oral mucosal non-malignant lesions in the western Sicilian population. *Minerva Stomatologica*. 2016;65(4):191-206

- [17] Intapa C, Na Ayudhya CC, Puangsombat A, Boonmoon B, Janyasurin T, Tonum U. Prevalence of oral mucosal lesions in geriatric patients living in lower Northern Thailand: A 10 years retrospective study. *Journal of International Dental and Medical Research*. 2017;**10**(3):868-871
- [18] Patil S, Doni B, Maheshwari S. Prevalence and distribution of oral mucosal lesions in a geriatric Indian population. *Canadian Geriatrics Journal*. 2015;**18**(1):11-14
- [19] Koray M, Ak G, Kürklü E, İşsever H, Tanyeri G, Kulekçi G, et al. Fluconazole and/or hexetidine for management of oral candidiasis associated with denture-induced stomatitis. *Oral Disease*. 2005;**11**:309-313
- [20] Woo SB, Lin D. Morsicatio mucosae oris—A chronic oral frictional keratosis, not a leukoplakia. *Journal of Oral and Maxillofacial Surgery*. 2009;**67**:140-142
- [21] Neville BW, Damm DD, Allen CM, Bouquot JE. *Oral and Maxillofacial Pathology*. Philadelphia: Saunders; 2009
- [22] Rivera C, Droguett D, Arenas-Márquez MJ. Oral mucosal lesions in a Chilean elderly population: A retrospective study with a systematic review from thirteen countries. *Journal of Clinical and Experimental Dentistry*. 2017;**9**(2):e276-83
- [23] Iegami CM, Tamaki R, Neto PT. A 5-week non-surgical approach towards denture induced hyperplasia. *The Open Dentistry Journal*. 2017;**11**:151-154
- [24] Vieira-Andrade RG, Zuquim Guimarães Fde F, Vieira Cda S, Freire ST, Ramos-Jorge ML, Fernandes AM. Oral mucosa alterations in a socioeconomically deprived region: Prevalence and associated factors. *Brazilian Oral Research*. 2011;**25**(5):393-400
- [25] Cury PR, Araujo NS, Oliveira MGA, Santos JN. Association between oral mucosal lesions and crack and cocaine addiction in men: A cross-sectional study. *Environmental Science and Pollution Research*. 2018;**25**:19801-19807
- [26] Altenburg A, El-Haj N, Micheli C, et al. The treatment of chronic recurrent oral aphthous ulcers. *Deutsches Ärzteblatt International*. 2014;**111**:665-673
- [27] Saikaly SK, Saikaly TS, Saikaly LE. Recurrent aphthous ulceration: A review of potential causes and novel treatments. *Journal of Dermatological Treatment*. 2018. DOI: 10.1080/09546634.2017.1422079
- [28] Sangle VA, Pooja VK, Holani A, Shah N, Chaudhary M, Khanapure S. Reactive hyperplastic lesions of the oral cavity: A retrospective survey study and literature review. *Indian Journal of Dental Research*. 2018;**29**(1):61-66
- [29] Rallan M, Malhotra G, Rallan NS, et al. BML Case Reports Published online. DOI: 10.1136/bcr-2013-009083
- [30] Malamed SF. *Handbook of Local Anesthesia*. 5th ed. St. Louis: The C.V. Mosby Co; 2004
- [31] Becker DE, Reed KL. Local anesthetics: Review of pharmacological considerations. *Anesthesia Progress*. 2012;**59**:90-101
- [32] Vivas APM, Migliari DA. Cinnamon-induced oral mucosal contact reaction. *The Open Dentistry Journal*. 2015;**9**:257-259
- [33] Lalla RV, Saunders DP, Peterson DE. Chemotherapy or radiation-induced oral mucositis. *Dental Clinics of North America*. 2014;**58**:341-349
- [34] Carvalho MV, Moraes SLD, Lemos CAA, Santiago JJF, Vasconcelos BC,

Pellizzer EP. Surgical versus non-surgical treatment of actinic cheilitis: A systematic review and meta-analysis. *Oral Diseases*. 2018. DOI: 10.1111/odi.12916

[35] Gomes JO, de Vasconcelos Carvalho M, Fonseca FP, Gondak RO, Lopes MA, Vargas PA. CD1a+ and CD83+ Langerhans cells are reduced in lower lip squamous cell carcinoma. *Journal of Oral Pathology & Medicine*. 2016;**45**(6):433-439. DOI: 10.1111/jop.12389

[36] Calcaianu N, Popescu SA, Diveica D, Lascar I. Surgical attitude in premalignant lesions and malignant tumors of the lower lip. *Journal of Medicine and Life*. 2015;**8**(1):109-111

[37] Castiñeiras I, Del Pozo J, Mazaira M, Rodríguez-Lojo R, Fonseca E. Actinic cheilitis: Evolution to squamous cell carcinoma after carbon dioxide laser vaporization. A study of 43 cases. *Journal of Dermatological Treatment*. 2010;**21**(1):49-53. DOI: 10.3109/09546630902887203

[38] Vieira RA, Minicucci EM, Marques ME, Marques SA. Actinic cheilitis and squamous cell carcinoma of the lip: Clinical, histopathological and immunogenetic aspects. *Anais Brasileiros de Dermatologia*. 2012;**87**(1):105-114

[39] Kang S, Kufta K, Sollecito TP, Panchal N. A treatment algorithm for the management of intraoral burns: A narrative review. *Burns*. 2018;**44**:1065-1076

[40] Cowan D, Ho B, Sykes KJ, Wei JL. Pediatric oral burns: A ten-year review of patient characteristics, etiologies and treatment outcomes. *International Journal of Pediatric Otorhinolaryngology*. 2013;**77**(8):1325-1328