

We are IntechOpen, the world's leading publisher of Open Access books Built by scientists, for scientists

4,800

Open access books available

122,000

International authors and editors

135M

Downloads

Our authors are among the

154

Countries delivered to

TOP 1%

most cited scientists

12.2%

Contributors from top 500 universities



WEB OF SCIENCE™

Selection of our books indexed in the Book Citation Index
in Web of Science™ Core Collection (BKCI)

Interested in publishing with us?
Contact book.department@intechopen.com

Numbers displayed above are based on latest data collected.
For more information visit www.intechopen.com



A Brief Overview of Ophthalmic Ultrasound Imaging

*David B. Rosen, Mandi D. Conway, Charles P. Ingram,
Robin D. Ross, Leonardo G. Montilla and Gholam A. Peyman*

Abstract

Ultrasound is one of the oldest imaging modalities. Sound waves are emitted into the body, and the returning echoes can be interpreted. It has become widely used because it can easily be done at bedside with a relatively small apparatus and does not expose the patient to any ionizing radiation. While this technique has seen widespread acceptance in other fields such as cardiology or obstetrics and gynecology, the general use in ophthalmology has been somewhat limited. However, recent advancements in ultrasonic arrays can be a powerful tool in the evaluation of ophthalmic pathology. Such systems can quickly generate very high detail images and 3D reconstructions without the need for extensive manual scanning. The application of this technology includes evaluation of traumatic eye injuries; assessing presence and location of an intraocular foreign body; evaluation of intraocular tumors, including small tumors that have not yet caused visual distortion; evaluation of retinal detachment; and evaluation of vascular disease. The goal of this article is to briefly review the history and development of ultrasound and to provide an overview of the most current systems and applications of ultrasound use in ophthalmologic clinical evaluation.

Keywords: ultrasound, 3D reconstruction, ultrasonic biomicroscopy, Doppler ultrasonography, ultrasonic array

1. Introduction

One of the most common and well recognized technologies in modern medicine is ultrasonography. Its use has been used in many medical fields, and new methods and devices using ultrasound are frequently emerging. While there have been many recent advancements, ultrasound has a rich history dating back centuries.

Some consider the earliest investigation into ultrasound beginning with the ancient Greeks [1]. Pythagoras invented the sonometer to study music; Boethius compared the waves generated by dropping a pebble into water to sound waves.

In 1880, French scientists and brothers, Pierre and Jacques Curie, discovered piezoelectricity [2]. When certain materials (such as some crystals) are exposed to an electric field they undergo mechanical changes. The reverse is also true: when piezoelectric materials have mechanical force exerted on them they generate an electric charge. Thus, these crystals can both transmit and receive sound. Such piezoelectric devices are the basis of ultrasound transducers [3]. When voltage is applied to the transducer sound waves are emitted; when the reflected waves are

picked up by the transducer, they generate voltage. This electrical signal can then be processed to produce an “image” based on the reflected sound waves.

While the Curie brothers discovered the piezoelectric effect in the 1880s, it wasn't utilized for ultrasonography until a few decades later. One of their students, Paul Langevin, was commissioned by the French government to develop technology to detect enemy submarines [2]. His studies became the base for what was to later become known as sound navigation ranging (SONAR), which was developed extensively in World War II [4, 5].

Later, ultrasound started to see use in medicine. Karl Dussik used it to study brain tissue; George Ludwig used ultrasound to help detect gallstones [2]. In 1951, John Wild and John Reid built the first B-mode scanner [6]. B-mode (brightness-mode) scanners are what is most often thought of when one refers to ultrasound. B-mode produces a two-dimensional reconstructed image of internal body structures based on reflected sound waves. The first commercially available handheld B-mode scanner was produced in 1963 [6]. Around the same time, many researchers started looking into Doppler applications with ultrasound to detect blood flow as well.

The 1960s and 1970s proved to be a time of rapid development for the use of ultrasound in medicine [2, 6]. Its application in cardiology and obstetrics and gynecology became more widespread. The field of medical sonography continued to grow, and various societies and institutions dedicated to medical sonography began to emerge.

2. Ultrasound use in ophthalmology

In the 1950s, ultrasound was first used in ophthalmology and optometry [7, 8]. These early explorations aimed at using measurements of the depth and velocity of sound waves in the eye to try to distinguish various conditions. This type of ultrasonography is known as A-scanning (amplitude scanning). Further advances in the 1960s used A-mode scanning to better measure the length of the eye, distances within the eye [9], and visual axis of the eye [10]. The axial A-scanning was also used to help determine intraocular lens power [11]. Diagnostic A-scan works by emitting a sonic pulse and measuring the time and amplitude of the echo. This information can then be interpreted to give information on the number of interfaces the wave has passed through. For example, the waveform produced from passing through normal structures of the eye versus a hemangioma versus a more solid lesion will all look different [7]. While A-scanning can give important data on some basic characteristics of the eye, such as lens power and length of the eye, it does not produce a visual re-creation of internal ocular structures. Because of this, its use is somewhat limited and must be combined with B-scan (**Figures 1 and 2**).

Another valuable application of ultrasound is the use of Doppler flow ultrasonography. Doppler was a physicist and astronomer in the mid 1800s who demonstrated that blue stars appeared that color because they were moving toward the observer while red stars appeared red because they were moving away from the observer [12]. This became known as the Doppler effect, and held true not only for electromagnetic waves but also acoustic waves; thus, the Doppler effect can be applied to ultrasound to help measure the magnitude and direction of flow.

Doppler found early application in cardiology, where the evaluation of flow was obvious [13, 14]. Doppler ultrasound soon found other applications, though. It proved useful in monitoring and measuring peripheral vasculature [15–18]. This proved useful for applications such as detecting tumor neovascularization [19, 20] and evaluation for ectopic pregnancy [21].

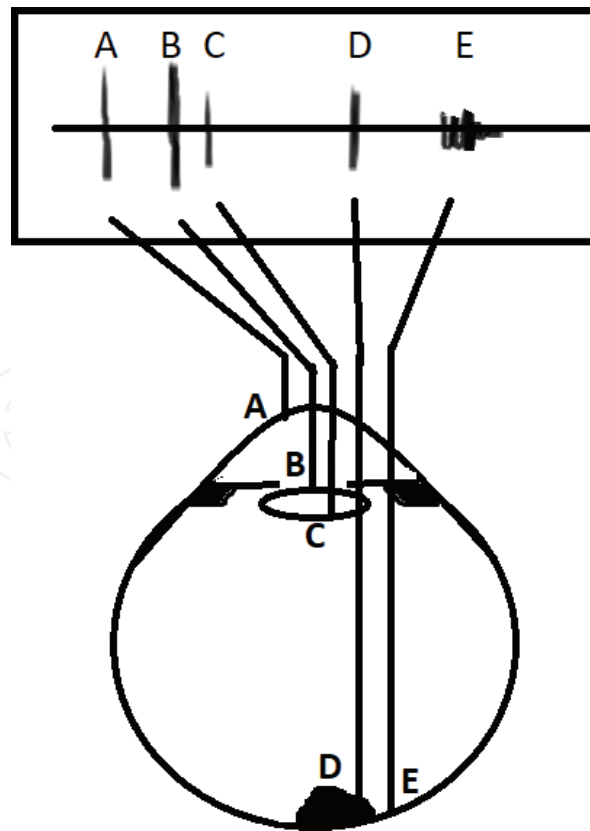


Figure 1.
A diagram illustrating the various sources of reflected waves within the eye and how they would appear on the view screen.



Figure 2.
Example of an ultrasound probe designed specifically for ophthalmic use.

Doppler ultrasonography was also shown to be useful in estimating the degree of stenosis in vasculature, which proved especially useful in evaluating carotid artery disease [22]. This is of special interest because the ophthalmic artery is the first branch of the internal carotid artery, and disease affecting the internal carotid has the propensity to affect ocular vasculature either indirectly secondary to decreased flow or directly through embolism of atherosclerotic plaque [23]. Doppler was also shown to be helpful in diagnosis and evaluation of open angle glaucoma [24]. Doppler has also been used in ophthalmology to evaluate the ocular fundus [25] and flow through the retinal artery [26].

While A-mode scanning and Doppler flow ultrasound had their specific uses, B-mode scanning was explored more broadly. Devices became more accessible with handheld transducers and options to attach to a TV screen for viewing [27, 28]. In addition, differently shaped probes were developed to aid in imaging for different

surface areas or structures [29]. B-mode proved an invaluable tool for evaluating intraocular foreign bodies, masses, hemorrhage, retinal detachment, and congenital abnormalities. It was first pioneered in ophthalmology Baum and Greenwood [30], and the first ocular specific probe was produced by Bronson [27].

One of the first ways B-mode ultrasonography was used in ophthalmology was for evaluation of an opaque eye [30]. For example, if there is a potential foreign body in the eye and there is clouding of the cornea or lens, the object may not be able to be observed directly. Furthermore, if it is radio-opaque, it will not be visible via X-ray. This makes ultrasound an excellent modality for evaluation in such instances. Another advantage is that ultrasonographic evaluation of the eye can be done bedside with the need for minimal equipment, making it ideal for traumatic evaluation [31–33].

B-mode was also used early on for evaluation of intraocular tumors [34–36]. Similar to the above example of foreign object location, if there is a soft tissue lesion that is in a position not easily visible by direct ophthalmoscopy or if there is clouding of anterior structures, such that a direct view is not possible, B-mode ultrasonography can aid in evaluation of intraocular soft tissue masses (**Figure 3**). This has been especially explored in the setting of diagnosing choroidal melanoma [37]. B-mode scanning can help ascertain the position, size, and height of ocular melanoma.

While early scans for evaluation of intraocular masses were focused on identifying presence and location, later research focused on better quantifying such tumors [38, 39]. By taking serial cross-sectional scans over the shape of the tumor, the shape and volume of the tumor could be estimated [40, 41]. This helped to improve evaluation and characterization of intraocular masses and guided radioactive plaque placement.

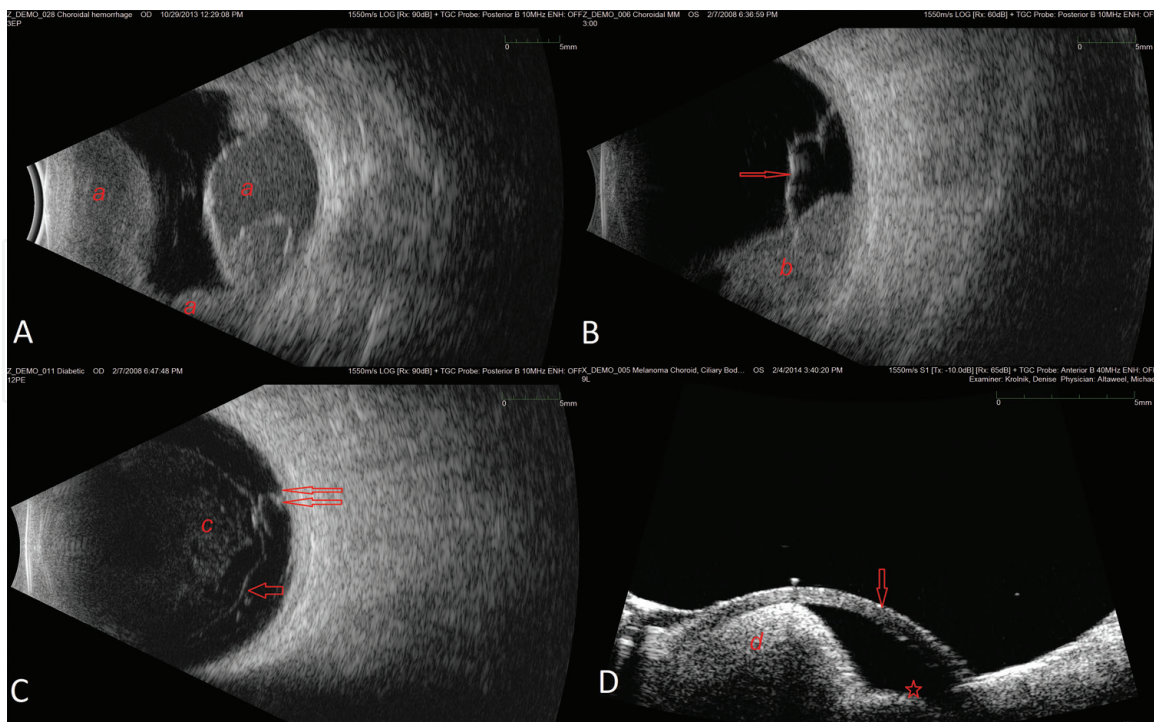


Figure 3.

Examples of images from B-scan ultrasound. (A) An image of choroidal hemorrhage. Areas of hemorrhage indicated by (a). (B) Choroidal melanoma (b) with associated superior retinal detachment (arrow). (C) A diabetic patient with vitreous retinal traction. Area of vitreous hemorrhage shown by (c); single arrow indicates posterior hyaloid membrane; double arrow shows point of fibrovascular adhesion. (D) Ciliary melanoma (d) invading into the anterior chamber; arrow indicates cornea while star shows the location of the iris. Images used courtesy of Ellex.

Despite the many applications of ultrasonography for ocular evaluation, there are some limitations. The depth of penetration of ultrasonic waves is inversely proportional to the frequency used [42]; a transducer using a 10 MHz frequency can penetrate 50 mm, where as a system using 60 MHz frequency will only penetrate 5 mm. Furthermore, the image resolution is limited by the frequency used, with higher frequency systems achieving higher resolution images. Ultrasonic imaging using high frequencies has been termed “ultrasonic microscopy” or “ultrasonic backscatter microscopy” (UBM) [43, 44]. Such systems use very high frequency waves (60-100 MHz) to achieve high resolution images at depths in the 4 mm range. This technique is ideal for high resolution imaging the anterior chamber, ciliary body and its structures, as well as parts of the peripheral retina [45]. Because images can get distorted at the close interface between the transducer and the object being imaged, eye-cup devices are used to create an offset distance between the transducer and the surface of what is being imaged (**Figure 4**) [42].

The use of high frequency ultrasonic biomicroscopy has been applied in several ways. One study used UBM for tracking corneal changes related to the laser-assisted in-situ keratomileusis (LASIK) procedure [46]. 50 MHz scanning was used to map the cornea before and after LASIK. They showed that this technique was an accurate and feasible way to track changes in corneal shape and thickness following LASIK. Another application of ultrasonic biomicroscopy was the characterization of the lens [47]. By being able to better characterize the natural lens, more accurate synthetic lenses can be produced (**Figure 5**). A similar approach was used to better categorize the ciliary body [48]. In contrast to anterior structures such as the cornea and lens can be easily evaluated via direct visualization with methods such as slit lamp examination, the ciliary body is obscured from direct visual view. Because of this, UBM is an ideal modality for evaluation of ciliary body pathology, small tumors in particular [49–51]. UBM has also been useful in identifying structural morphologies contributing to glaucoma, such as iris plateau syndrome [52]. These examples illustrate how high frequency, high resolution ultrasonic biomicroscopy can practically be applied to ocular evaluation and how this imaging can change practice and drive innovation.

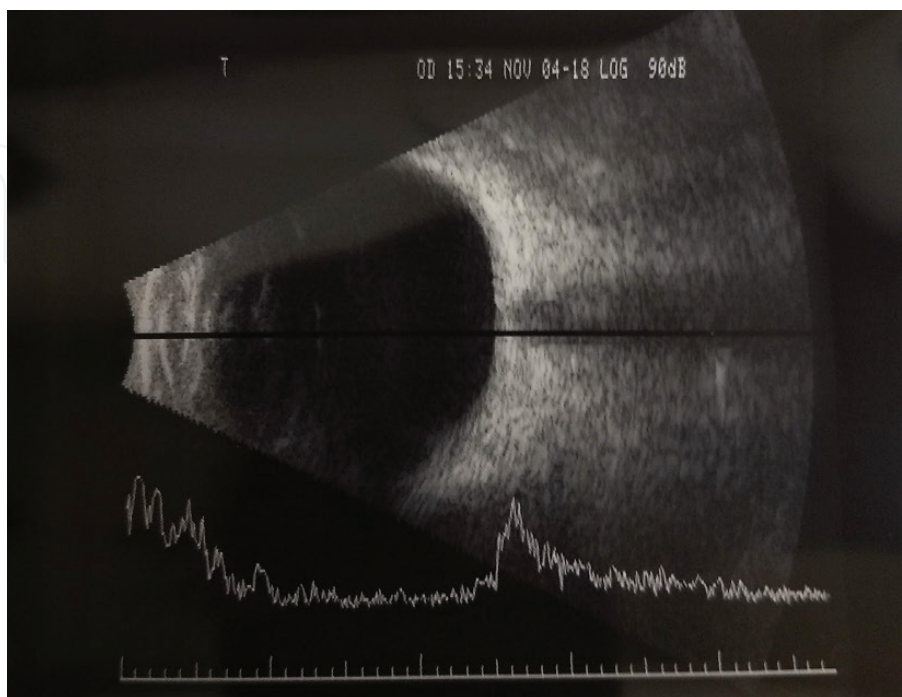


Figure 4. The 2D image is an example of B-scan ultrasonography of a human eye. The lower section of the image shows a superimposed A-scan for comparison.

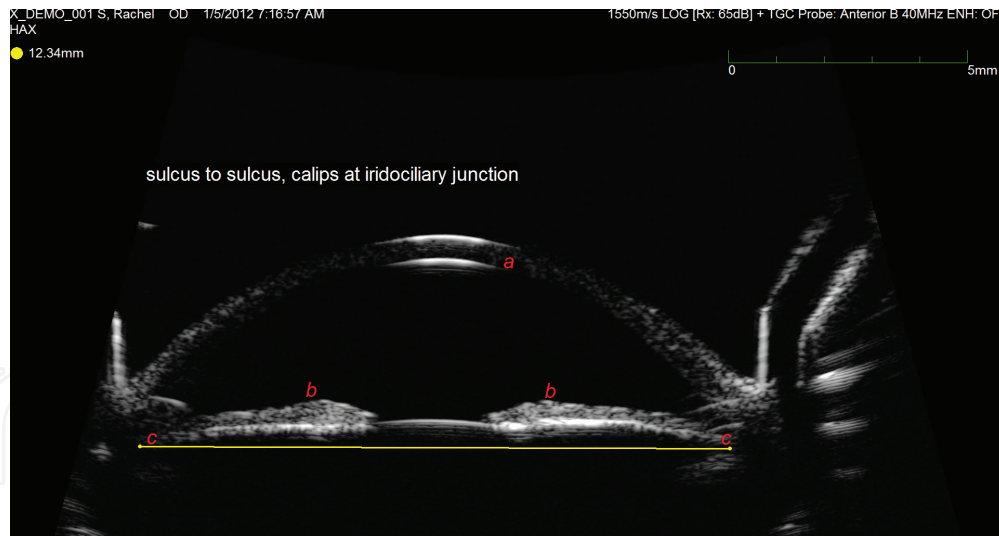


Figure 5.
Example of UBM for visualization of anterior structures. Cornea indicated by (a), iris by (b), and ciliary body by (c). This technique can be used for measurements for intraocular lens placement, or to assess ciliary body tumors which would not be directly visible. Image used courtesy of Ellex.

Despite advances in high resolution imaging and faster B-scanning, there were still limitations. One is that ultrasonic evaluation can be time consuming and the quality of the exam is dependent of how skillful the examiner is. Another limitation is that traditional B-mode scanning can only evaluate structures directly opposite to the probe and cannot provide information in the XY plane without 3D reconstruction. While 3D reconstruction was shown to be possible [40, 41] and could give information about the XY planes, such imaging required time consuming serial acquisition of small 2D image slices and subsequent reconstruction. This meant that while 3D reconstruction is possible, it is too cumbersome to be used frequently in the average clinical setting. Much research went into designing systems that were able to scan faster to produce more reliable 3D reconstructions of ocular models [53, 54]. This included using array systems that were able to image at both high frequencies and traditional frequencies to obtain a reconstruction with as much detail as possible at multiple depths [54]. As opposed to traditional A-mode and B-mode transducers which have a single piezoelectric element (and thereby a fixed depth of focus), arrays use a transducer with many elements (over 100) in each transducer head [55].

Despite the valuable information that can be gained from an array system that utilizes both traditional and high frequency waves, such systems have not been readily adopted [56, 57]. One potential reason for the underutilization of high frequency systems may be because of the equipment constraints. Because array transducers require over 100 piezoelectric parts aligned in close proximity within a relatively small transducer head, the production is technically challenging [55, 58]. Moreover, the frequency generated is inversely proportional to the size and spacing of the piezoelectric elements [58]: lower frequency systems can use larger more widely spaced piezoelectric crystals.

A combined low and high frequency array system called the Vevo 2100 (VisualSonics, Toronto, Ontario, Canada) has been tested for use in ophthalmologic evaluation and shows promise [55]. This system uses an array transducer with 256 elements in each transducer head. By utilizing an array system, most of the imaged field can be kept in focus, allowing high-resolution real-time imaging. This system has two linear array transducer probes: a 25 MHz probe and a 50 MHz probe (**Figure 6**). This system generates 3D reconstructions in seconds utilizing a mechanical motor for efficient scanning. A scan using the 50 MHz probe yields high definition data on the anterior eye structures, while a second scan using the 25 MHz probe will




Figure 6.
(A) Picture of the Vevo 2100 system (VisualSonics, Toronto, Ontario, Canada). (B) Picture of the 25 MHz and 50 MHz probe utilized by this system. Used with permission from Gholam A. Peyman.

produce data on the posterior segment and orbit. Each scan with 3D reconstruction takes about 10 seconds. An initial evaluation would be a scan with the 50 MHz transducer to assess anterior structures followed by a scan using the 25 MHz probe to image the rest of the eye. By choosing an appropriate transducer and frequency, the whole eye can efficiently be scanned, and a 3D reconstruction generated either from a specific area or the whole eye in less than 1 minute. In addition to generation of 3D reconstructions (**Figures 7 and 8**), this system can perform several other scanning functions, including B-mode, M-mode, PW Doppler, Color Doppler, Power Doppler, Tissue Doppler, Contrast Mode, and Photoacoustic Imaging.

One important application of this system is in emergency evaluation of traumatic eye injuries. Traditional hand-held B-mode evaluation is an excellent tool for detecting foreign bodies but is not without risk. Extreme caution must be used when scanning an injured eye, which must be considered as a potential open globe. It is critical to avoid placing pressure and extruding intraocular contents through a penetrating wound. This system can perform a mechanized scan through a closed eyelid with a coupling medium. There is decreased risk of causing further injury to the eye. This feature, combined with the high-resolution 3D reconstruction, will provide detailed information in seconds on the extent of ocular injury, presence and position of a foreign body (**Figure 9**).

This system is also useful for routine clinical outpatient evaluation. The 50 MHz transducer can provide a very high level of detail on eyelid, including Meibomian glands (**Figure 10**), and anterior ocular structures: cornea, iris, ciliary body, and lens. Because of the very high level of resolution, it could be a powerful tool for assessing Meibomian gland disease. By using this scan routinely, small tumors or lesions behind the iris or in the choroid may be detected early, before they caused visual distortion or metastases. Small retinal detachments at the peripheral retina can also be detected using this transducer. This may be very helpful in children with retinal detachment.

In summary, the 50 MHz transducer can provide fine detail of anterior structures, a subsequent scan using the 25 MHz transducer can provide information on the remainder of the eye. This is useful for assessment in the setting of trauma, additionally it can also provide valuable information on retinal detachment, size and location of intraocular masses, and information on the optic nerve head drusen or edema. Because this system can provide simultaneous B-mode scanning and Doppler flow imaging, both anatomic assessment and evaluation of vascular disease

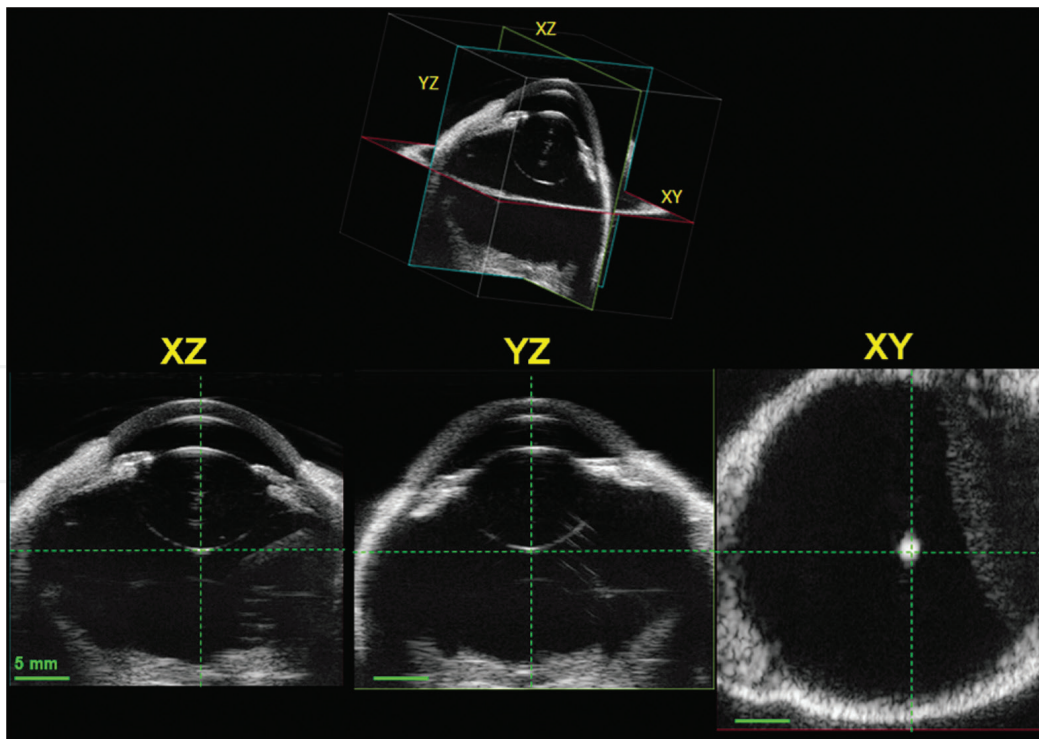


Figure 7. The lower panels depict 2D slices of a pig eye in different planes obtained with the 25 MHz probe. The upper image is a 3D perspective. Used with permission from Gholam A. Peyman.

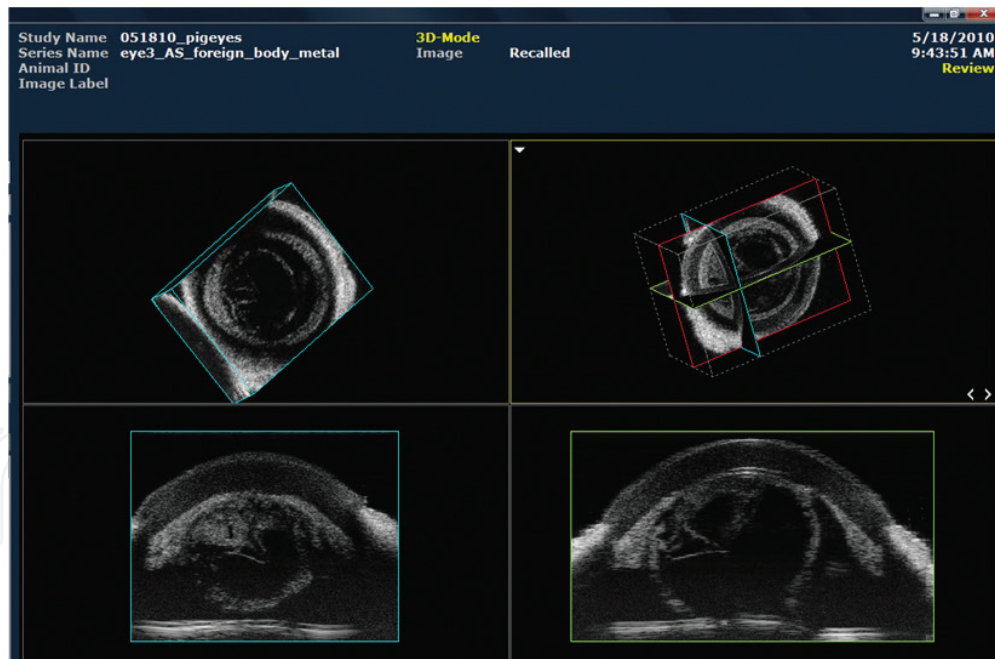


Figure 8. Example of 3D reconstruction of a pig eye with anterior lens injury. Various planes are shown. Used with permission from Gholam A. Peyman.

of the optic nerve head can be performed. Doppler flow imaging can also be utilized to assess other vascular diseases, such as temporal arteritis (**Figure 11**).

Overall, the Vevo 2100 system (VisualSonics, Toronto, Ontario, Canada) potentially is a powerful tool for emergency and routine evaluation of ophthalmic pathology. By utilizing an array system in the transducer head, real-time images well focused throughout the scan may be obtained. The mechanical scanning function can produce 3D models in seconds with decreased risk of expulsion of

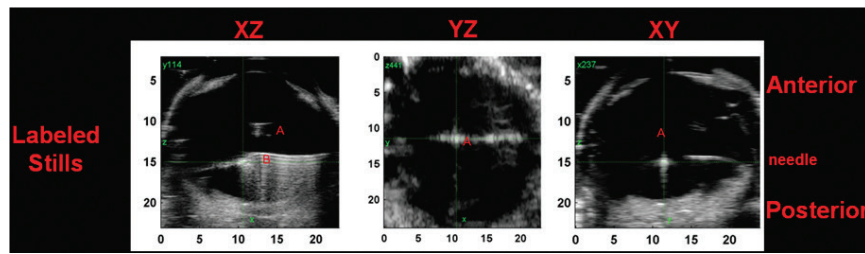


Figure 9.
 This image shows the presence of a linear foreign body (A) and secondary acoustic shadowing (B). The images were generated using Matlab (Mathworks, Natick, MA) and a point-and-click technique in which an object is found in one plane, clicked on, and automatically images in the two other planes are generated. used with permission from Gholam A. Peyman.

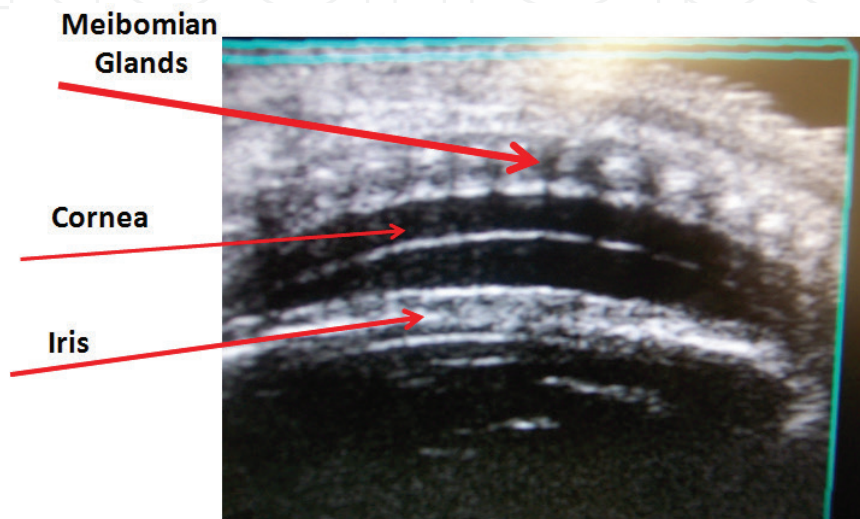


Figure 10.
 Image obtained from a scan using the 50 MHz transducer. Structures visible, including the Meibomian glands, are labeled. used with permission from Gholam A. Peyman.

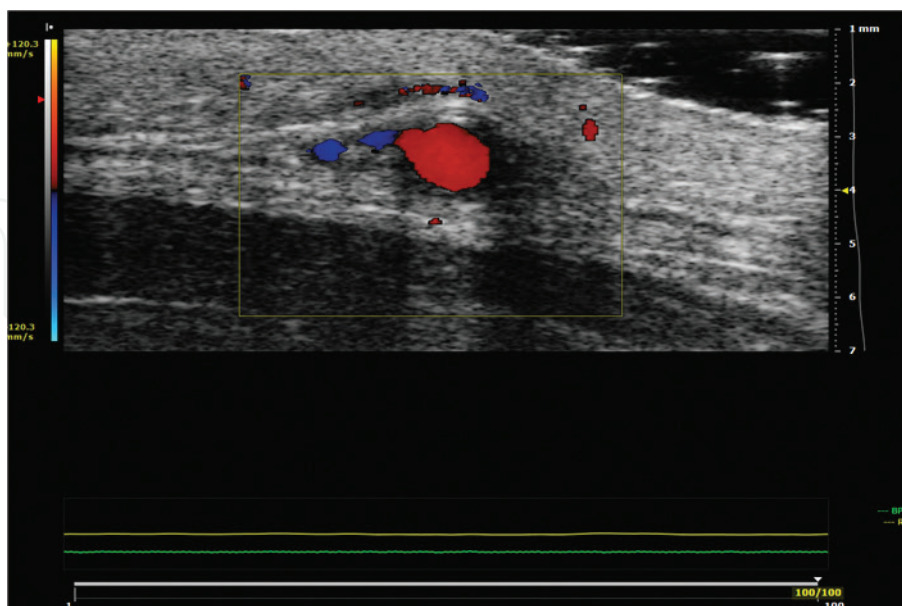


Figure 11.
 Example of color Doppler image showing flow through temporal artery. Obtained using 50 MHz transducer. Used with permission from Gholam A. Peyman.

ocular contents following trauma. These 3D reconstructions provide information in planes traditional B-scanning methods cannot assess. The level of detail produced using this system can provide information on a wide array of ocular disease, from

Meibomian gland, evaluation of intraocular tumors or foreign bodies, vascular diseases affecting the optic nerve head, glaucomatous cupping, drusen and optic nerve edema as well as orbital tumors (**Figure 12** and **Table 1**).

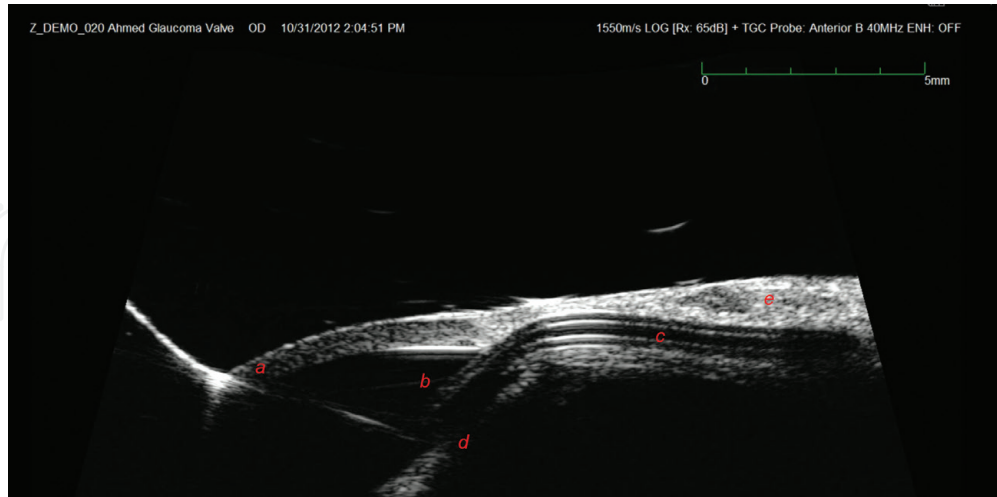

Figure 12.
Example of an ultrasound image showing the correct placement of an Ahmed valve for treatment of glaucoma. The cornea is visible (a) with the tip of the valve in the anterior chamber (b) with the iris labeled (d). The main tubing (c) lies within the sclera (e).

Clinical uses of ocular ultrasonography	
Use	Clinical comment
Intraocular foreign bodies (see Figure 9)	<ul style="list-style-type: none"> • Ideal for emergent evaluation of traumatic eye. • Can detect objects in periphery (not easily seen on direct visualization). • 3D reconstruction can yield detailed information on size and location.
Intraocular tumors (see Figure 3B)	<ul style="list-style-type: none"> • Useful in diagnosing intraocular soft tissue masses. • Can detect malignant melanoma.
Vascular disease	<ul style="list-style-type: none"> • Doppler can be used to assess flow through ocular vasculature. • Evaluate condition of retinal artery. • Evaluation of temporal arteritis.
Ciliary body pathology (see Figure 5)	<ul style="list-style-type: none"> • UBM provides fine level of detail. • Can be used to assess ciliary body disease. • Can detect ciliary body tumors that cannot be directly observed.
Structural changes in glaucoma (see Figure 12)	<ul style="list-style-type: none"> • Detect iris plateau syndrome. • Assess glaucoma drainage devices. • Measurement of anterior chamber depth. • Evaluate optic nerve cupping.
Evaluation of an opaque eye (see Figure 3A)	<ul style="list-style-type: none"> • Evaluation of pathology that could ordinarily be directly visible such as: <ul style="list-style-type: none"> ○ Retinal detachment ○ Vitreous hemorrhage ○ Presence and location of foreign bodies or tumors ○ Glaucomatous cupping ○ Optic nerve edema

Table 1.
Examples of clinical applications of ultrasonic evaluation in ophthalmology.

3. Conclusion

Ultrasound is an established diagnostic imaging modality. There are many systems which are relatively small with handheld probes. No ionizing radiation is used, but the image resolution can be limited compared to other visualization modalities. Advances have allowed high resolution imaging possible, especially of the anterior segment with the ability to create 3D reconstructions of ocular tissues and foreign bodies to aid in diagnosis and management of many disorders. Doppler flow can be an invaluable tool in the real time diagnosis of vasculopathies. However, 3D systems with rapid scan acquisition are not yet readily available.

Acknowledgements

The authors thank Global Retina Institute for providing funding and for Ellex, Inc for use of ultrasound images.

Conflict of interest

No author has a conflict of interest related to this work.

Abbreviations

SONAR	sound navigation imaging
UBM	ultrasonic backscatter microscopy
LASIK	laser-assisted in-situ keratomileusis

IntechOpen

Author details

David B. Rosen¹, Mandi D. Conway^{1,2*}, Charles P. Ingram³, Robin D. Ross^{1,4},
Leonardo G. Montilla³ and Gholam A. Peyman^{1,2,5}

1 Department of Ophthalmology, University of Arizona College of Medicine, USA

2 Department of Ophthalmology, Tulane University College of Medicine, USA


3 Department of Radiology, University of Arizona, Tucson, Arizona, USA

4 Department of Bioethics and Medical Humanism, University of Arizona College
of Medicine, Phoenix, Arizona, USA

5 College of Optical Sciences, University of Arizona, USA

*Address all correspondence to: mconway1@yahoo.com

IntechOpen

© 2019 The Author(s). Licensee IntechOpen. This chapter is distributed under the terms of the Creative Commons Attribution License (<http://creativecommons.org/licenses/by/3.0>), which permits unrestricted use, distribution, and reproduction in any medium, provided the original work is properly cited. 

References

- [1] Baker J. Ultrasound history. *Radiology Today* 2008;**9**:28. Available from: https://www.radiologytoday.net/archive/rt_120108p28.shtml [Accessed: October 27, 2018]
- [2] Baker JP. The history of sonographers. *Journal of Ultrasound in Medicine*. 2005;**24**:1-14. DOI: 10.7863/jum.2005.24.1.1
- [3] Moeller D-PF. Whitepaper-ultrasound PIEZO elements IN medical technology. *Ultrasound Piezo Elements in Medical Technology Tool, Therapeutic Device and Sensor*. Karlsruhe. n.d.
- [4] Kimmelman B. *Medical Diagnostic Ultrasound: A Retrospective on its 40th Anniversary*. Bethesda: Eastman Kodak Co; American Institute of Ultrasound in Medicine; 1988
- [5] Craig M. *Introduction to Ultrasonography and Patient Care*. Philadelphia: WB Saunders Co; 1993
- [6] Hagen-Ansert SL. Society of diagnostic medical sonographers—A timeline of historical events in sonography and the development of the SDMS: In the beginning.... *Journal of Diagnostic Medical Sonography*. 2006;**22**:272-278. DOI: 10.1177/8756479306291456
- [7] Mundt GH, Mundt GH, Hughes WF. *Ultrasonics in ocular diagnosis.pdf*. *American Journal of Ophthalmology*. 1956;**41**:488-498. DOI: 10.1016/0002-9394(56)91262-4
- [8] Oksala A, Lehtinen A. Measurement of the velocity of sound in some parts of the eye. *Acta Ophthalmologica*. 1975:633-639
- [9] Jansson F. Measurement of intraocular distances by ultrasound and comparison between optical and ultrasonic determinations of the depth of the anterior chamber. *Acta Ophthalmologica*. 1963;**41**:25-61. DOI: 10.1111/j.1755-3768.1963.tb02420.x
- [10] Coleman DJ, Carlin B. A new system for visual Axis measurements in the human eye using ultrasound. *Archives of Ophthalmology*. 1967;**77**:124-127. DOI: 10.1001/archophth.1967.00980020126027
- [11] Sanders DR, Kraff MC. Improvement of intraocular lens power calculation using empirical data. *American Intra-Ocular Implant Society Journal*. 1980;**6**:263-267. DOI: 10.1016/S0146-2776(80)80075-9
- [12] Doppler C. *Ueber das farbige Licht der Doppelsterne und einer anderer Gestirne des Himmels*. Prag K Bohm. 1842
- [13] Kasai C, Namekawa K, Koyano A, Omoto R. Real-time two-dimensional blood flow imaging using an autocorrelation technique. *IEEE Transactions on Sonics and Ultrasonics*. 1985;**32**:458-464. DOI: 10.1109/T-SU.1985.31615
- [14] Ciccone TJ, Grossman SA. Cardiac ultrasound. *Emergency Medicine Clinics of North America*. 2004;**22**:621-640. DOI: 10.1016/j.emc.2004.04.012
- [15] Hein IA, O'Brien WD. A flexible blood flow phantom capable of independently producing constant and pulsatile flow with a predictable spatial flow profile for ultrasound flow measurement validations. *IEEE Transactions on Biomedical Engineering*. 1992;**39**:1111-1122. DOI: 10.1109/10.168687
- [16] Ferrara KW, Algazi VR, Liu J. The effect of frequency dependent scattering and attenuation on the estimation of blood velocity using ultrasound. *IEEE Transactions on Ultrasonics, Ferroelectrics, and Frequency Control*. 1992;**39**:754-767. DOI: 10.1109/58.165561

- [17] Martin PJ, Evans DH, Naylor AR, Bell PRF. Transcranial colour coded sonography as an aid to measurement of blood flow velocity in the basal cerebral arteries. *Ultrasound in Medicine & Biology*. 1993;**19**:711-716. DOI: 10.1016/0301-5629(93)90088-6
- [18] Macsweeney JE, Cosgrove DO, Arenson J. Colour Doppler energy (power) mode ultrasound. *Clinical Radiology*. 1996;**51**:387-390. DOI: 10.1016/S0009-9260(96)80155-3
- [19] Cosgrove DO, Kedar RP, Bamber JC, al-Murrani B, Davey JB, Fisher C, et al. Breast diseases: Color Doppler US in differential diagnosis. *Radiology*. 1993;**189**:99-104. DOI: 10.1148/radiology.189.1.8372225
- [20] Guerriero S, Alcazar JL, Ajossa S, Galvan R, Laparte C, García-Manero M, et al. Transvaginal color Doppler imaging in the detection of ovarian cancer in a large study population. *International Journal of Gynecological Cancer*. 2010;**20**:781-786
- [21] Emerson DS, Cartier MS, Altieri LA, Felker RE, Smith WC, Stovall TG, et al. Diagnostic efficacy of endovaginal color Doppler flow imaging in an ectopic pregnancy screening program. *Radiology*. 1992;**183**:413-420. DOI: 10.1148/radiology.183.2.1561342
- [22] AbuRahma AF, Srivastava M, Stone PA, Mousa AY, Jain A, Dean LS, et al. Critical appraisal of the carotid duplex consensus criteria in the diagnosis of carotid artery stenosis. *Journal of Vascular Surgery*. 2011;**53**:53-60. DOI: 10.1016/j.jvs.2010.07.045
- [23] Luo J, Yan Z, Jia Y, Luo R. Clinical analysis of 42 cases of ocular ischemic syndrome. *Journal of Ophthalmology*. 2018;**2018**:1-7. DOI: 10.1155/2018/2606147
- [24] Mokbel TH, Shahin MM, El-Said EM, El-Ghaffar WMA. Potential diagnostic value of fluorescein angiography and color Doppler imaging in primary open angle glaucoma. *European Journal of Ophthalmology*. 2009;**19**:957-962. DOI: 10.1177/112067210901900610
- [25] Yamamoto Y. Doppler examination of blood flow in the ocular fundus. *Bibliotheca Ophthalmologica*. 1975;**83**:32-40
- [26] Dennis KJ, Dixon RD, Winsberg F, Ernest JT, Goldstick TK. Variability in measurement of central retinal artery velocity using color Doppler imaging. *Journal of Ultrasound in Medicine*. 1995;**14**:463-466
- [27] Bronson NR. Development of a simple B-scan ultrasonoscope. *Transactions of the American Ophthalmological Society*. 1972;**70**:365-408
- [28] Coleman DJ, Konig WF, Katz L. A hand-operated, ultrasound scan system for ophthalmic evaluation. *American Journal of Ophthalmology*. 1969;**68**:256-263. DOI: 10.1016/0002-9394(69)94068-9
- [29] Foster FS, Pavlin CJ, Harasiewicz KA, Christopher DA, Turnbull DH. Advances in ultrasound biomicroscopy. *Ultrasound in Medicine & Biology*. 2000;**26**:1-27. DOI: 10.1016/S0301-5629(99)00096-4
- [30] Baum G, Greenwood I. The application of ultrasonic locating techniques to ophthalmology. *A.M.A. Archives of Ophthalmology*. 1958;**60**:263. DOI: 10.1001/archophth.1958.00940080279015
- [31] Coleman DJ, Lucas BC, Rondeau MJ, Chang S. Management of intraocular foreign bodies. *Ophthalmology*. 1987;**94**:1647-1653. DOI: 10.1016/S0161-6420(87)33239-7
- [32] Bronson NR II. Management of intraocular foreign bodies.

- American Journal of Ophthalmology. 1968;**66**:279-284. DOI: 10.1016/0002-9394(68)92075-8
- [33] Coleman DJ, Jack RL, Franzen LA, Coleman J. Ultrasonography in ocular trauma. American Journal of Ophthalmology. 1978;**75**:279-288. DOI: 10.1016/S0002-9394(14)76689-9
- [34] BAUM G, GREENWOOD I. Ultrasonography—An aid in orbital tumor diagnosis. Archives of Ophthalmology. 1960;**64**:180-194. DOI: 10.1001/archophth.1960.01840010182003
- [35] Oksala A. Echogram in melanoma of the choroid. The British Journal of Ophthalmology. 1959;**43**:408-414
- [36] Oksala A. Ultrasound diagnosis in intraocular melanoma. Annals of the New York Academy of Sciences. 1963;**100**:18-28. DOI: 10.1111/j.1749-6632.1963.tb57110.x
- [37] Baum G. Ultrasonographic characteristics of malignant melanoma. Archives of Ophthalmology. 1967;**78**:12-15. DOI: 10.1001/archophth.1967.00980030014003
- [38] Coleman DJ. Reliability of ocular and orbital diagnosis with B-scan ultrasound. 2. Orbital diagnosis. American Journal of Ophthalmology. 1972;**74**:704-718
- [39] Coleman DJ. Reliability of ocular and orbital diagnosis with B-scan ultrasound; 1. Ocular diagnosis. American Journal of Ophthalmology. 1972;**73**:501-516. DOI: 10.1016/0002-9394(72)90002-5
- [40] Coleman DJ, Silverman RH, Rondeau MJ, Lizzi FL. New perspectives: 3-D volume rendering of ocular tumors. Acta Ophthalmologica. 2009;**70**:22-22. DOI: 10.1111/j.1755-3768.1992.tb04918.x
- [41] Silverman RH, Coleman DJ, Rondeau MJ, Woods SM, Lizzi FL. Measurement of ocular tumor volumes from serial, cross-sectional ultrasound scans. Retina. 1993;**13**:69-74
- [42] Pavlin CJ. Ultrasound Biomicroscopy. Ophthalmology Rounds. Vol. 2. 2004
- [43] Stuart Foster F, Pavlin CJ, Lockwood GR, Ryan LK, Harasiewicz KA, Berube L, et al. Principles and applications of ultrasound backscatter microscopy. IEEE Transactions on Ultrasonics, Ferroelectrics, and Frequency Control. 1993;**40**:608-617. DOI: 10.1109/58.238115
- [44] Sherar MD, Foster FS. Ultrasound backscatter microscopy. In: IEEE 1988 Ultrason. Symp. Proceedings. Chicago: IEEE; 1988. pp. 959-966. DOI: 10.1109/ULTSYM.1988.49519
- [45] Pavlin CJ, Sherar MD, Foster FS. Subsurface ultrasound microscopic imaging of the intact eye. Ophthalmology. 1990;**97**:244-250. DOI: 10.1016/S0161-6420(90)32598-8
- [46] Reinstein DZ, Silverman RH, Raevsky T, Simoni GJ, Lloyd HO, Najafi DJ, et al. Arc-scanning very high-frequency digital ultrasound for 3D pachymetric mapping of the corneal epithelium and stroma in laser in situ keratomileusis. Journal of Refractive Surgery. 2001;**16**:414-430
- [47] Coleman DJ, Fish SK. Presbyopia, accommodation, and the mature catenary. Ophthalmology. 2001;**108**:1544-1551. DOI: 10.1016/S0161-6420(01)00691-1
- [48] Silverman RH, Lizzi FL, Ursea BG, Rondeau MJ, Eldeen NB, Kalisch A, et al. High-resolution ultrasonic imaging and characterization of the ciliary body. Investigative Ophthalmology & Visual Science. 2001;**42**:885-894
- [49] Pavlin CJ, McWhae JA, McGowan HD, Foster FS. Ultrasound

biomicroscopy of anterior segment tumors. *Ophthalmology*. 1992;**99**:1220-1228. DOI: 10.1016/S0161-6420(92)31820-2

[50] Varghese M, Ramappa R, Kamath S. Pseudotumor of Ciliary body. *Case Reports in Ophthalmological Medicine*. 2014;**2014**:1-3. DOI: 10.1155/2014/458683

[51] Velazquez-Martin JP, Krema H, Fulda E, Yücel YH, Simpson ER, Pavlin CJ. Ultrasound biomicroscopy of the ciliary body in ocular/oculodermal melanocytosis. *American Journal of Ophthalmology*. 2013;**155**:681-687.e2. DOI: 10.1016/J.AJO.2012.10.006

[52] Suwan Y, Jiamsawad S, Supakontanasan W, Teekhasaene C. Hidden mechanisms beyond the pupillary block in acute angle closure: Ultrasound biomicroscopic study. *Clinical & Experimental Ophthalmology*. 2017;**45**:366-370. DOI: 10.1111/ceo.12867

[53] Fisher Y, Hanutsaha P, Tong S, Fenster A, Mazarin G, Mandava N. Three-dimensional ophthalmic contact B-scan ultrasonography of the posterior segment. *Retina*. 1998;**18**:251-256

[54] Cusumano A, Coleman DJ, Silverman RH, Reinstein DZ, Rondeau MJ, Ursea R, et al. Three-dimensional ultrasound imaging. Clinical applications. *Ophthalmology*. 1998;**105**:300-306

[55] Peyman GA, Ingram CP, Montilla LG, Witte RS. A high-resolution 3D ultrasonic system for rapid evaluation of the anterior and posterior segment. *Ophthalmic Surgery, Lasers, and Imaging*. 2012;**43**:143-151. DOI: 10.3928/15428877-20120105-01

[56] Susal AL, Gaynon MW, Walker JT. Linear Array multiple transducer ultrasonic examination of the eye.

Ophthalmology. 1983;**90**:266-271. DOI: 10.1016/S0161-6420(83)34564-4

[57] Blaivas M, Theodoro D, Sierzenski PR. A study of bedside ocular ultrasonography in the emergency department. *Academic Emergency Medicine*. 2002;**9**:791-799

[58] Cannata JM, Williams JA, Zhou Q, Ritter TA, Shung KK. Development of a 35-MHz piezo-composite ultrasound array for medical imaging. *IEEE Transactions on Ultrasonics, Ferroelectrics, and Frequency Control*. 2006;**53**:224-236. DOI: 10.1109/TUFFC.2006.1588408