

We are IntechOpen, the world's leading publisher of Open Access books Built by scientists, for scientists

4,800

Open access books available

122,000

International authors and editors

135M

Downloads

Our authors are among the

154

Countries delivered to

TOP 1%

most cited scientists

12.2%

Contributors from top 500 universities



WEB OF SCIENCE™

Selection of our books indexed in the Book Citation Index
in Web of Science™ Core Collection (BKCI)

Interested in publishing with us?
Contact book.department@intechopen.com

Numbers displayed above are based on latest data collected.
For more information visit www.intechopen.com



Clinical Application of Optical Coherence Tomography in the Corneal Degenerations

Constanza Caramello Álvarez, María A. del Buey, Paula Casas, Sara Marco, Enrique Mínguez and Francisco J. Ascaso

Abstract

Anterior segment optical coherence tomography (AS-OCT) has become an essential tool in the diagnosis and management of corneal degenerations. AS-OCT optical findings and thickness measurements are useful for the proper evaluation of the ocular surface diseases. AS-OCT imaging provides noninvasive information necessary to decide clinical and surgical management. This device helps to achieve a correct pre-intervention investigation and will allow physicians to compare the corneal status after the surgical process. Thus, it is useful to evaluate the corneal thickness, areas of hyper-reflective material, and corneal fibrosis in certain disorders such as **Salzmann's nodular degeneration (SND)** and **Terrien's marginal degeneration (TMD)**, before and following the surgical process.

Keywords: anterior segment optical coherence tomography, corneal degenerations, Salzmann's nodular degeneration, Terrien's marginal degeneration, Dellen, band keratopathy, ocular surface disease, keratoplasty, lamellar keratoplasty

1. Introduction

Optical coherence tomography (OCT) was developed to assess the ocular posterior segment. **Anterior segment OCT (AS-OCT)** was not described until 1994, and the first AS-OCT device was commercialized in 2005 [1–3].

The improvement from time domain to spectral domain OCT allowed higher axial resolution images. AS-OCT devices can achieve high-resolution imaging, ranging from less than 5 μm (ultra-high-resolution) to greater than 5 μm (high-resolution), providing a noninvasive, in vivo, cross-sectional image of the ocular surface and corneal structure [4, 5].

Spectral domain OCT (SD-OCT) devices include the **Spectralis® HRA + OCT system (Heidelberg Engineering GmbH, Germany)**. It can achieve 40,000 A-scans/second and has a 3.9–7 μm axial resolution, a 14 μm transverse resolution, a 1.9 mm scan depth, and an 870 nm average wavelength [4–6]. This AS-OCT device has been used to capture the corneal OCT images showed along this chapter (**Figure 1**).

AS-OCT is clinically useful for the examination, diagnosis, and management of most of the anterior segment pathologies [4, 7–9] (**Figure 2**). Additionally, it is



Figure 1.

Corneal AS-OCT imaging from Heidelberg Spectralis OCT system. The corneal AS-OCT image displays a normal corneal tissue. The layers with the highest hyper-reflectivity are the anterior surface of the cornea and the posterior limit of the cornea with the anterior chamber. The stroma appears as a large band of variable intensity, increasing the signal in the apical zone, due to the perpendicular impact of light reflection on the disposition of collagen fibers.

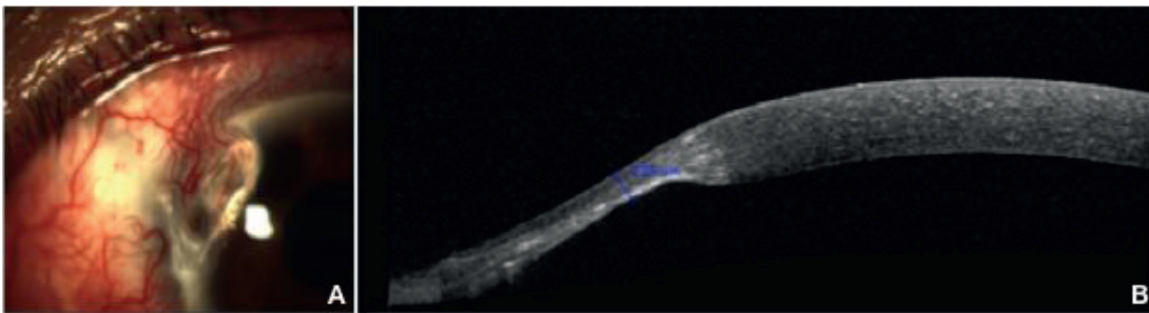


Figure 2.

(A) Anterior segment (AS) slit-lamp biomicroscopy shows a corneal Dellen due to a previous pterygium surgery: the perilimbar elevation produces an inadequate hydration of the adjacent cornea. (B) Corneal AS-OCT imaging demonstrates a thinning peripheral zone. This thinning area can be measured, and periodic controls can be made by AS-OCT.

helpful for planning and performing surgery as well as monitoring postoperative cares [1]. AS-OCT imaging requires no contact, which prevents patient discomfort and image distortion. The development of axial resolution, the improvement in scans speeds, and the deeper tissue penetrance allow corneal AS-OCT to recognize structural details in the corneal epithelium, stroma, and conjunctiva, allowing a characterization of corneal disorders [9].

Clinical evaluation and anterior segment (AS) slit-lamp biomicroscopy exam are still the first step in the diagnosis of corneal pathologies and cannot be replaced by corneal AS-OCT images. This technique has to be used as an adjunctive tool, especially in cases in which the diagnosis is clinically equivocal [4, 10]. Corneal AS-OCT imaging has shown to be useful helping to decide the pathology management and to assess the disease resolution. Unfortunately, in some corneal diseases, a histopathologic corneal exam will be necessary to confirm the diagnosis [10].

Corneal AS-OCT imaging can provide optical diagnostic signs for some specific corneal disorders [11]. Thus, corneal hyper-reflectivity can be defined as an increased whiteness compared to corneal tissue of the same location seen in normal subjects, whereas corneal hypo-reflectivity can be defined as an increased darkness compared to corneal tissue of the same location seen in normal individuals [10] (Figures 2 and 3). In cases of pathological cornea, a variable increase in reflectivity can be found in case of scars, edema, fibrosis, or material deposits. An attenuated signal is shown in case of fluid accumulation and cystic lesions [10]. In certain cases, AS slit-lamp biomicroscopy evaluation is not able to differentiate an inflammatory disorder from a degenerative disease. In patients with clinical history of inflammation and corneal thinning, corneal AS-OCT imaging shows a hyper-reflective band under the corneal epithelium in the area of thinning, which is not

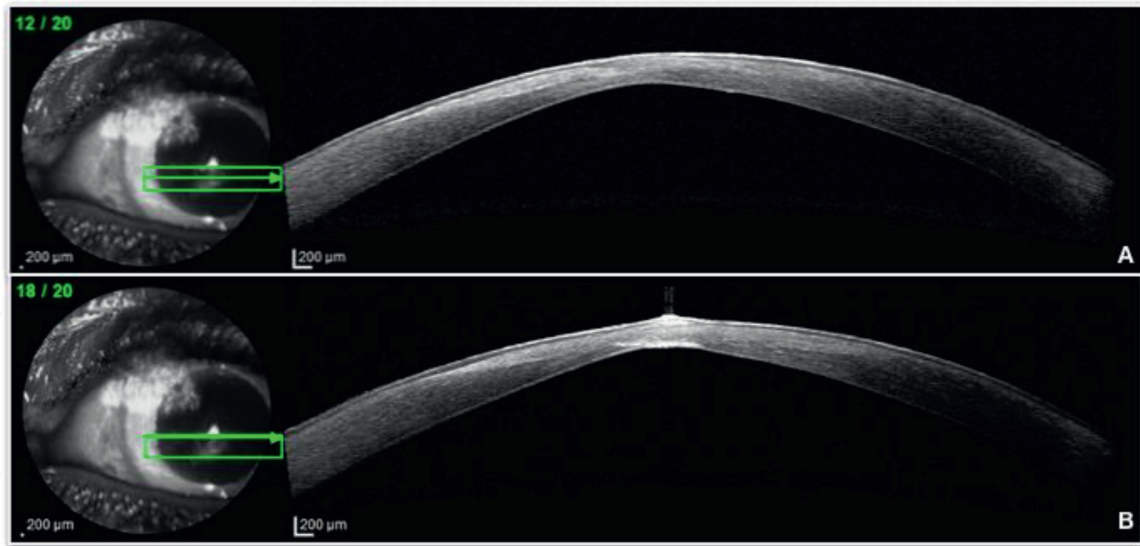


Figure 3.
(A and B) Corneal AS-OCT imaging from the Heidelberg Spectralis OCT device. The image demonstrated a thinning central corneal area with a hyper-reflective signal. The hyper-reflective zone is due to a subepithelial, anterior stroma and endothelial fibrosis.

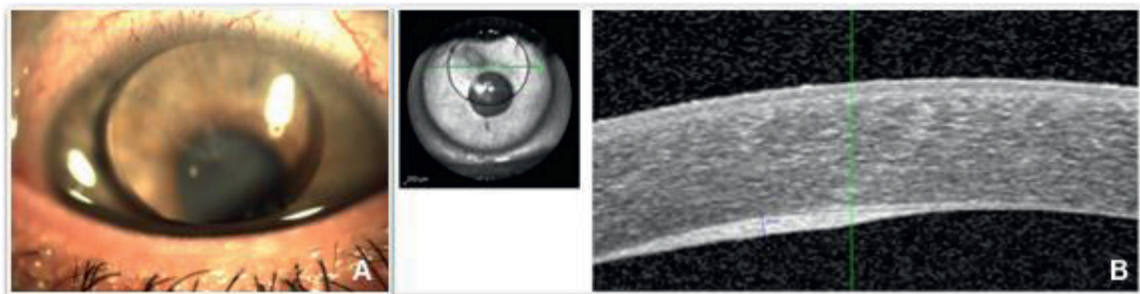


Figure 4.
(A) AS slit-lamp evaluation showing a silicone bubble in the anterior chamber following a retinal detachment surgery. (B) Corneal AS-OCT analysis demonstrated a corneal posterior hyper-reflective zone and fibrosis. The corneal fibrosis area is caused by the silicone direct damage in the endothelial cells.

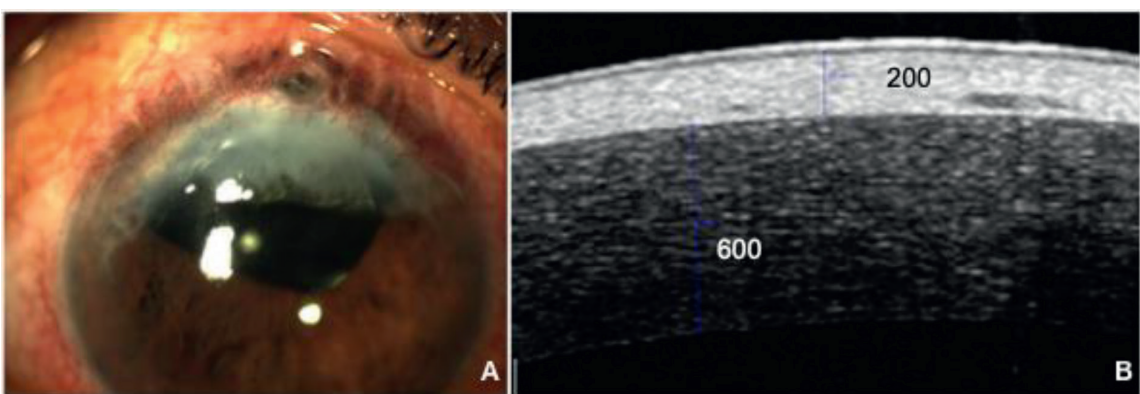


Figure 5.
(A) AS slit-lamp examination showing a corneal superior opacity with iris incarceration due to a previous retinal detachment and a complicated cataract surgery. (B) AS-OCT imaging demonstrated a hyper-reflective and fibrotic area. The opacified zone can be measured by the Heidelberg Spectralis OCT caliper tool.

seen in patients with noninflammatory melts and thinning [4]. This phenomenon can be helpful to achieve a correct management of corneal pathologies (Figure 4).

Corneal AS-OCT imaging is also useful for the measurements of corneal scar depth [1] (Figure 5). It has demonstrated to be able to define the rim of a corneal opacity

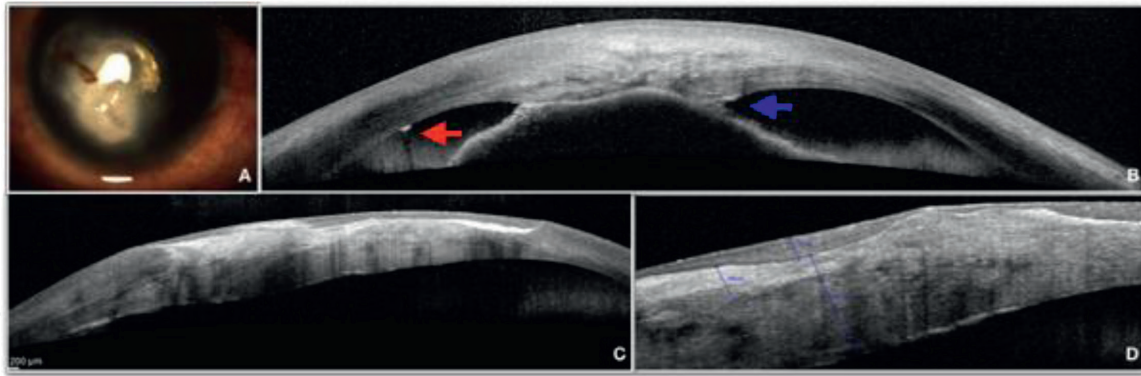


Figure 6. (A) AS slit-lamp biomicroscopy demonstrates a central and deep corneal opacification due to a traumatic perforation in a child. (B) AS-OCT evaluation shows a strange foreign body in the corneal endothelium (red arrow). The iris is incarcerated in the posterior corneal layers because of the perforating traumatism (blue arrow). (C) AS-OCT imaging displays an irregular stroma with hyper-reflective zones in the fibrosis areas. (D) The caliper tool can measure the respective corneal areas helping the physician to achieve a correct surgical management.

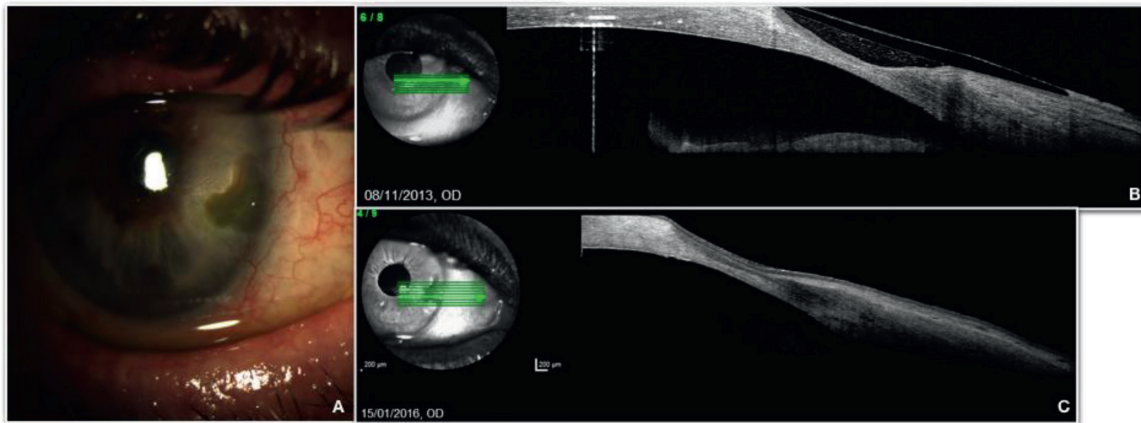


Figure 7. (A) AS slit-lamp evaluation shows a corneal Dellen due to a previous pterygium surgery in the peripheral nasal area. (A, B) AS-OCT analysis demonstrating a thinning area in corneal periphery, allowing direct comparison between scans. (B) An evaluation from November 2013 and (C) an evaluation from January 2016. Even though there are some minimal changes in the thinning morphology, the length is almost equal, and the corneal Dellen can be considered stable during the last years.

(Figures 5 and 6) and measure the corneal scar depth before choosing a surgical procedure [12]. A noninvasive surgical technique, such as lamellar keratoplasty (LK) or phototherapeutic keratectomy (PTK), can be chosen when only the anterior corneal layers have been affected, while in other cases, penetrating keratoplasty (PKP) will be the unique option to restore the normal corneal structure. Corneal AS-OCT device also allows direct measurements and comparison with prior scans (Figure 5).

Corneal AS-OCT device allows direct measurements and comparison with prior scans (Figure 7). The device is essential to evaluate cases with high risk of corneal perforation [13].

Degeneration can be defined as a gradual disruption of the normal condition of a tissue with a subsequent loss of functionality [14]. Corneal degeneration can be related with systemic diseases, local inflammation, or direct toxic action. In this chapter three corneal degenerations will be described: **Salzmann's nodular degeneration (SND)**, **Terrien's marginal degeneration (TMD)**, and **band keratopathy (BK)**. **Arcus senilis** is not present in the developing due to benign nature of the disease.

2. Salzmann's nodular degeneration

SND is a noninflammatory, slowly progressive, degenerative corneal disease. It is characterized by the presence of elevated, bluish white to gray subepithelial nodules located in the anterior cornea. The size of the nodules oscillates from 1 to 2 mm. Nevertheless, larger nodules have been described as a result of the fusion of several smaller nodules [15, 16] (**Figure 8**).

SND was identified by Maximilian Salzmann in 1925. He described the corneal nodules, usually related to phlyctenular or atheromatous keratitis [17]. SND is often associated with chronic corneal inflammation and irritation. Multiple risk factors have been reported. Interstitial keratitis, vernal keratoconjunctivitis, dry eye disease, meibomian gland dysfunction, pterygium, soft contact lens wearers, and previous trauma or surgical procedures are some disorders that predispose to suffer the pathology.

SND usually occurs in female patients, ranging from 50 to 60 years old. Patients can present unilateral or bilateral disease (**Figure 8**). The number of nodules oscillates from one to eight. These nodules generally adopt a round shape. However, in some cases, they can be conical, prismatic, or wedge-like. Most nodules are avascular although some can be associated with blood vessels. They are normally located in the superior and inferior cornea. In cases of previous pterygium surgery, they will be often located in the edge of the blood vessels; in patients with history of contact lens wearing, in the interpalpebral portion; and in keratoconus patients, in the apex of the cornea.

Corneal AS-OCT SND images display prominent, hyper-reflective, subepithelial deposits overlying Bowman's membrane [1]. The corneal opacities are located under a normally reflective, thin epithelium [10, 16]. The intraepithelial fibrosis overgrowth can result in a corneal surface elevation above Bowman's layer. The central part of nodule has heterogeneous signal intensities, and the nodule margin can be differentiated by subepithelial triangle spike. An irregular stromal scarring can be seen below the nodules, limited to the stromal superficial layers. An epithelial hypertrophy may also be observed around the nodules in an attempt to regularize the corneal surface. The structure of the posterior stroma, Descemet's membrane, and endothelium is not affected by the fibrosis, but the AS-OCT imaging shows a modification of the posterior corneal curvature (**Figure 9**). Both modifications of anterior and posterior corneal curvature induce astigmatic changes and visual loss in these patients.

The destruction of Bowman's layer is considered the most important property in the pathophysiology of the disease [18]. Bowman's layer is replaced by a granular periodic acid Schiff-positive (PAS-positive) eosinophilic material that resembles

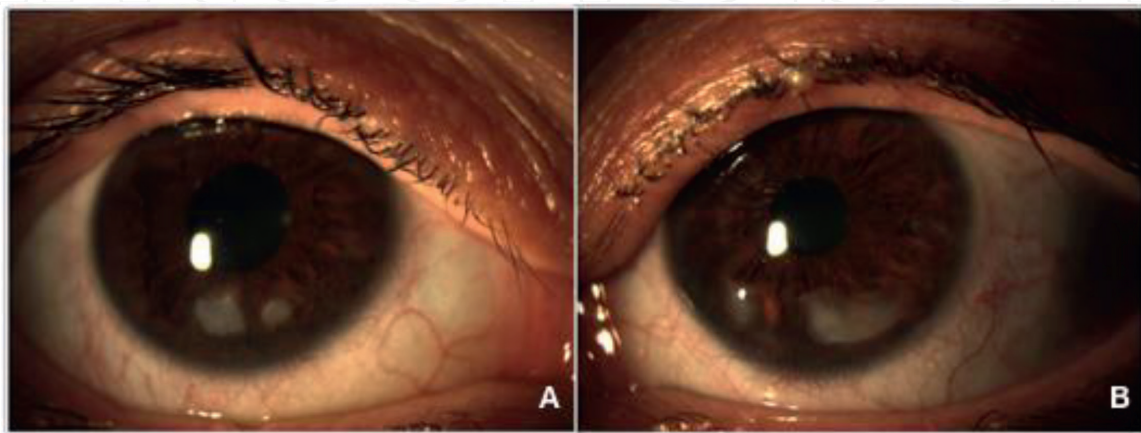


Figure 8.
(A and B) AS slit-lamp biomicroscopy image shows the bluish to white nodules localized in the mid-peripheral inferior cornea. The corneal opacity is present in both eyes of a 56-year-old female SND patient.

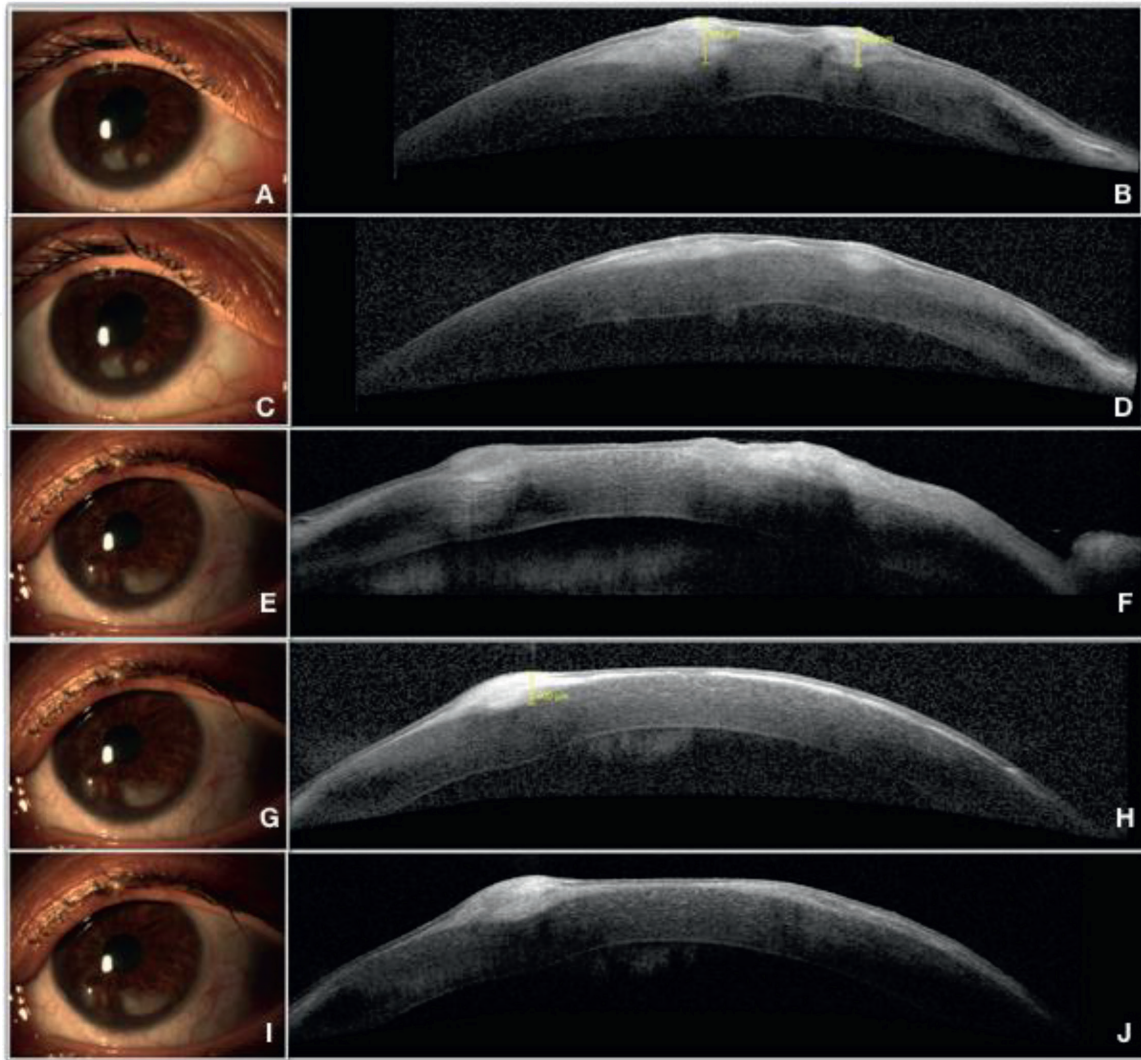


Figure 9.

(A and C) AS slit-lamp biomicroscopy shows two nodules in the right eye of a female patient. (F, H, J) AS-OCT corneal scans display how the prominent nodules overgrow and produce a corneal anterior surface elevation. (B and D) Corneal AS-OCT images demonstrate the SND nodules localized in the anterior corneal layers, destroying Bowman's layer and producing fibrosis in the anterior stroma. The nodules can be measured using the OCT caliper tool. The device allows the comparison of the nodules sizes between visits. (E, G, I) AS slit-lamp biomicroscopy demonstrates two nodules in the inferior corneal zone on the left eye of the same SND female patient. AS-OCT corneal scans display how the prominent nodules overgrow and produce a corneal anterior surface elevation. The corneal nodules are dense and hyper-reflective. An epithelial hypertrophy may also be observed around the nodules in an attempt to regularize the corneal surface. The structure of the posterior stroma, Descemet's membrane, and endothelium is not affected by the fibrosis, but AS-OCT imaging shows a modification of the posterior corneal curvature.

a basement membrane. The progression of the pathology will be determined by Bowman's layer destruction (**Figure 10**). The involvement of the Bowman layer indicates that surgical delamination of the nodules may be more difficult.

Although most SND cases are asymptomatic, the symptoms can appear depending on the location of the nodules. When they are peripheral, the main symptom is a foreign body sensation, and when they are mid peripheral, the patients complain of decrease in visual acuity. The loss of vision can be attributed to the presence of the corneal opacity and modification of the corneal axis, resulting in an astigmatic change. Other referrals symptoms are severe pain, irritation, and epiphora. The peripheral nodules can produce a flattening of the central cornea, inducing a hyperopic change. This phenomenon has to be considered in the intraocular lens (IOL) power calculation previous to the cataract surgery. The corneal central flattening can cause a refractive postoperative miscalculation [17].

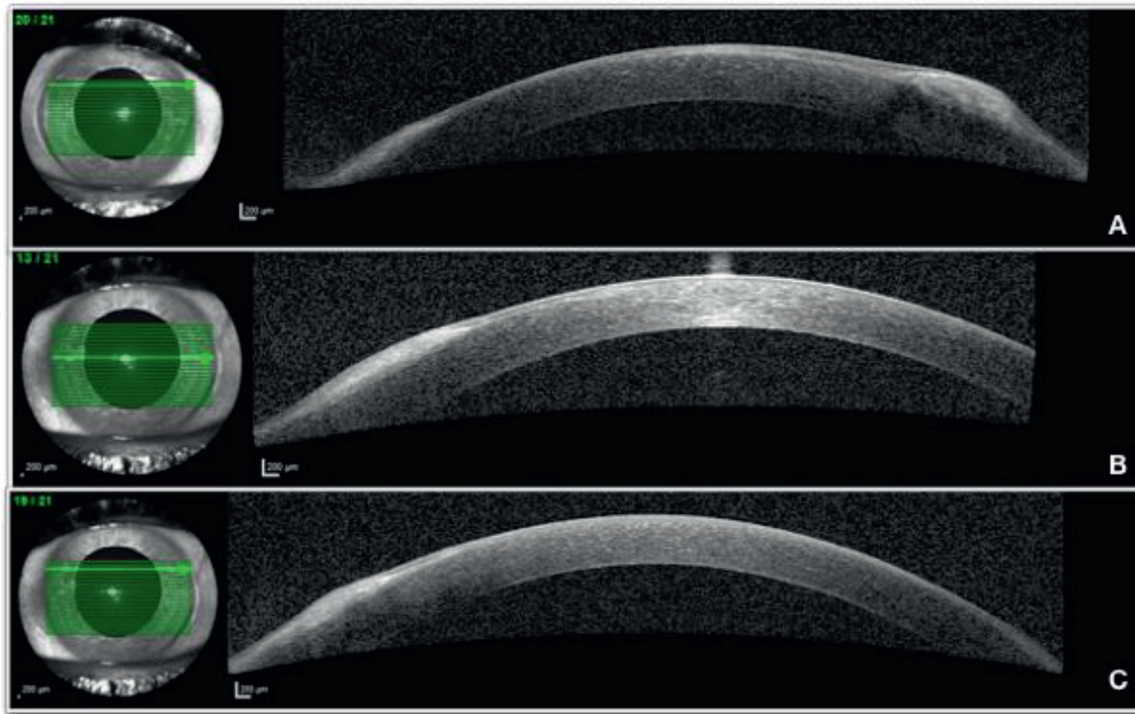


Figure 10. Corneal AS-OCT evaluation of a SND patient. The scans demonstrate Bowman's layer destruction by the nodule overgrowth. (A) A prominent nodule produces the corneal anterior surface deformation. (B and C) Another nodule extends superficially in the peripheral nasal cornea producing a hyper-reflective area in the subepithelial zone.

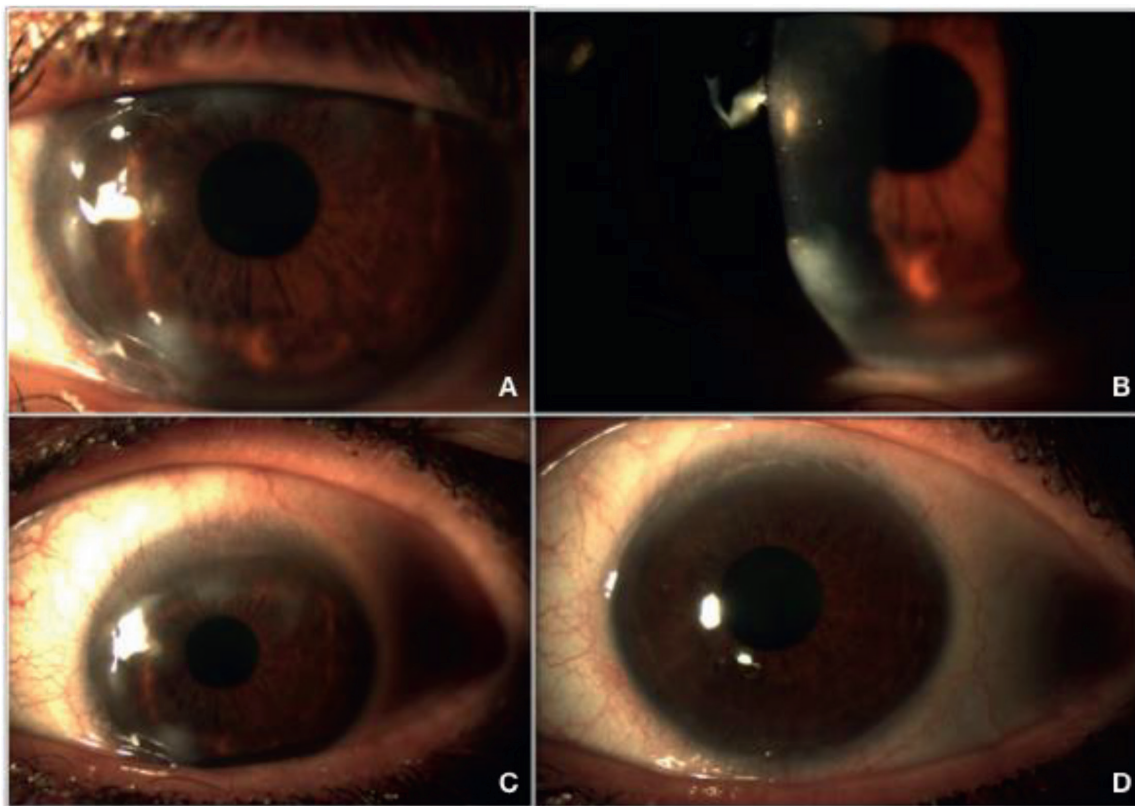


Figure 11. (A–C) Digital AS slit-lamp biomicroscopy of a SND female patient. The nodules are present all around the peripheral cornea. (D) The same patient following a superficial keratectomy and alcohol-assisted epithelial delamination. The superficial corneal nodules have disappeared.

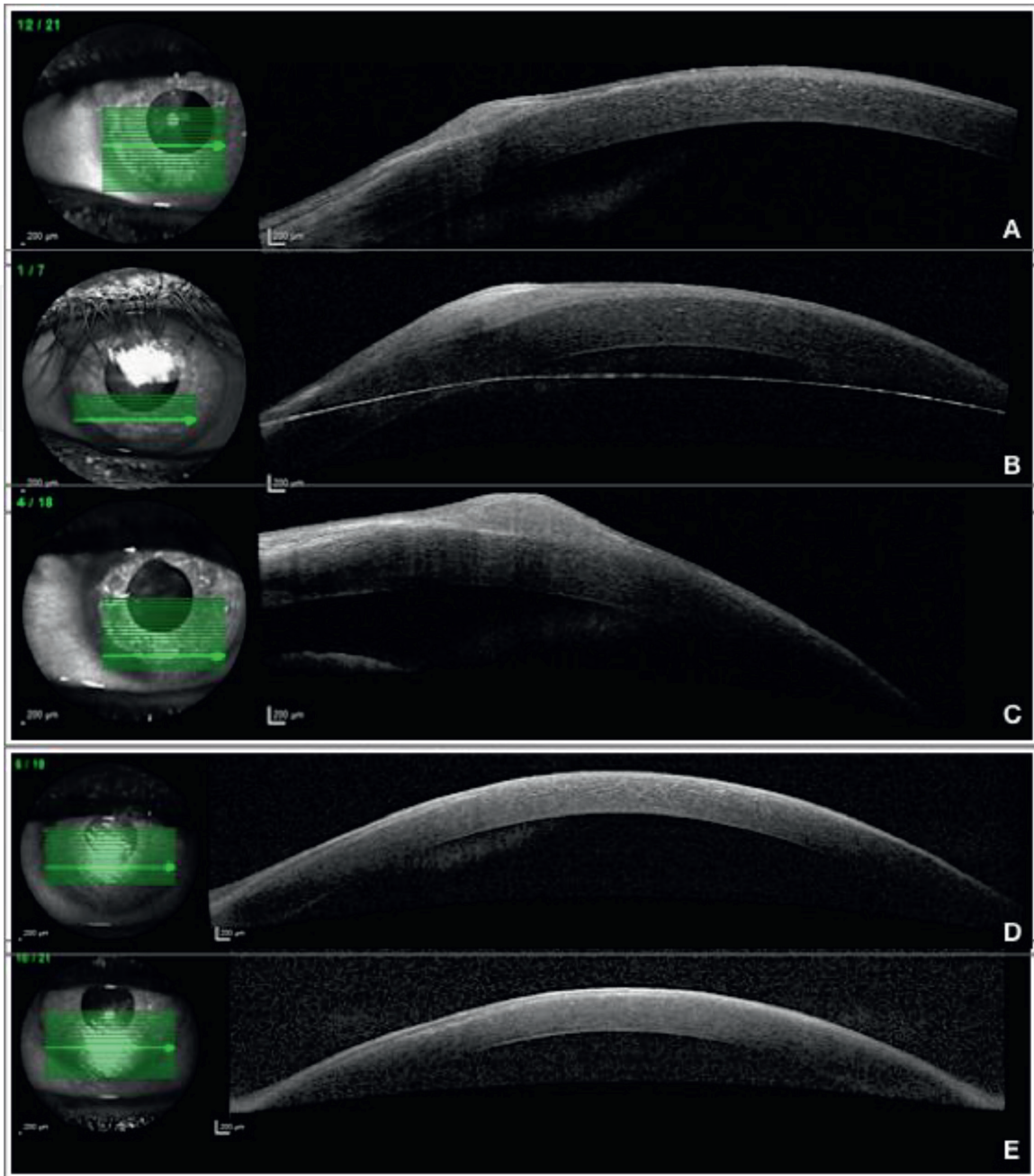


Figure 12. (A) Corneal AS-OCT analysis of the same SND female patient of **Figure 11**. (A, B, C) Hyper-reflective nodules can be seen in the mid-peripheral and inferior cornea. (D, E) Corneal AS-OCT scans from the same patient following superficial keratectomy and alcohol-assisted epithelial delamination. The nodules have been removed. The hyper-reflective corneal areas have disappeared, and the anterior surface has restored the morphology.

In asymptomatic SND patients, conservative treatments will be enough to manage the pathology. The medical therapy with preservative-free lubricants and lid hygiene is appropriated. Autologous serum at 20–50% can be also used. In symptomatic patients, or when inflammation is present, an anti-inflammatory treatment is required. Topical cyclosporine 0.05%, topical preservative-free corticosteroids, and oral doxycycline are useful for the management of SND pathology.

Corneal surgical procedures will be required in persistent symptomatic nodules after medical therapy and in patients with a visual acuity decrease. The main techniques are superficial keratectomy (**Figures 11** and **12**) alone or followed by phototherapeutic keratectomy (PTK). Both procedures can be associated with alcohol-assisted epithelial delamination (**Figures 11** and **12**), amniotic membrane transplantation, or mitomycin-C application.

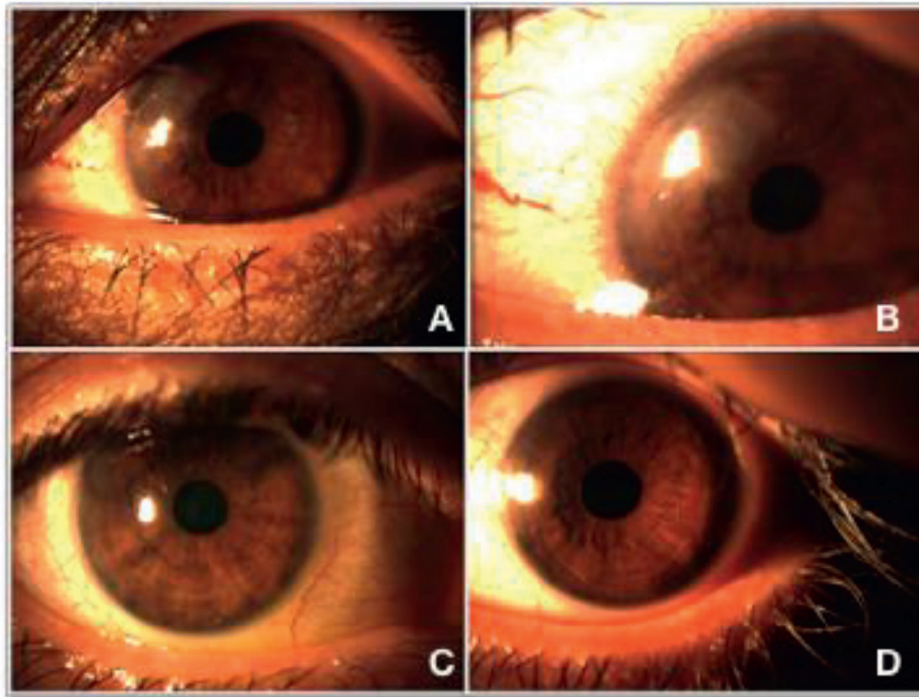


Figure 13. AS slit-lamp biomicroscopy from a SND patient. (A, B, C) The fibrosis area can be seen in the nasal peripheral corneal zone. (D) The fibrosis has been removed by keratectomy and alcohol-assisted epithelial delamination technique.

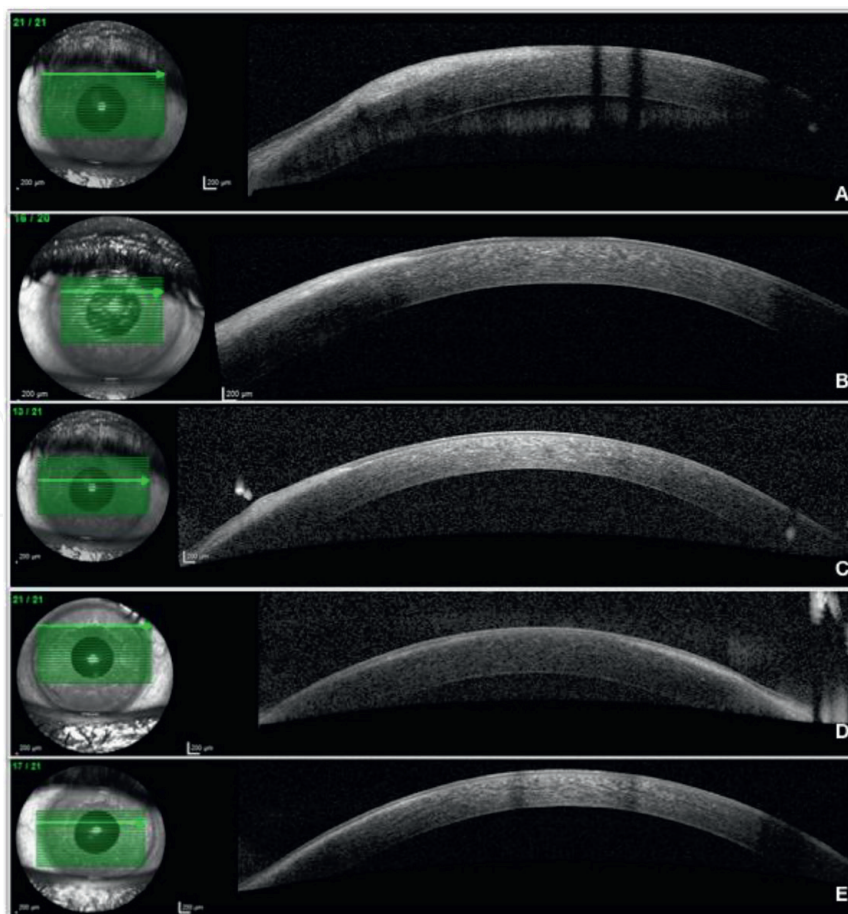


Figure 14. AS-OCT evaluation from the same SND patient of **Figure 13**. (A–C) The AS-OCT scans show a hyper-reflective zone in the fibrotic areas. (D and E) The fibrosis has been removed by keratectomy and alcohol-assisted epithelial delamination. The hyper-reflective areas are not present.

Superficial keratectomy will be the surgical first-line therapy in most cases (**Figure 13**). The results will be conditioned by the degree of involvement of the superficial cornea and the degree of affection of the Bowman's layer described in the corneal AS-OCT images (**Figure 14**). An unbroken Bowman's layer or an altered Bowman's layer could be predictive of the strength of the adhesion of the nodules to the anterior stroma [16]. The method used to remove mechanically the opacities will be "peeling the nodules," referred in the bibliography as "Salzmann nodulectomy." In areas of excessive thinning, a careful manual dissection will be required [17].

Keratoplasty will be used in the most severe SND cases. Fortunately, as the mid stroma and Descemet membrane are intact in most SND cases, a lamellar keratoplasty (LK) will be enough to eliminate the opacities. Penetrating keratoplasty (PKP) will be rarely required in SND patients. PKP will be reserved for cases of intraoperative perforation during LK or full-thickness corneal alterations in association with another disease [17].

Corneal AS-OCT images in SND patients have an excellent correlation with the histopathologic exam. AS-OCT analysis is a useful technique that sustained SND diagnosis and helped the clinicians to decide the management and follow-up of the disease progression.

3. Terrien's marginal degeneration (TMD)

TMD is a rare corneal degeneration form. The disease is characterized by a non-ulcerative peripheral corneal thinning [19]. It has a slow and chronic progression, bilaterally and asymmetric. TMD etiology still remains unknown [20]. The pathology has been associated with arthritis and meibomian gland dysfunction. TMD is more frequent in middle-aged males but can occur at any age and in females [21].

TMD is a lipid keratopathy [19]. The slit-lamp biomicroscopy evaluation displays lipid depositions at the edge of the peripheral corneal thinning [21, 22] (**Figure 15**). This lipid accumulation produces yellow-white stromal opacities [22] with superficial neovascularization. Histopathological exams demonstrate intracellular and extracellular vacuoles [21] charged with lipids in the corneal stroma. There is stromal fibrillary degeneration with fatty infiltration of collagen fibers [21, 22]. This stroma degradation produces a decrease in the number of lamellas. TMD lesions have an intact corneal epithelium and an altered Bowman's layer. Electron microscopy studies show the corneal basal membrane and the Bowman layer broken and fragmented.

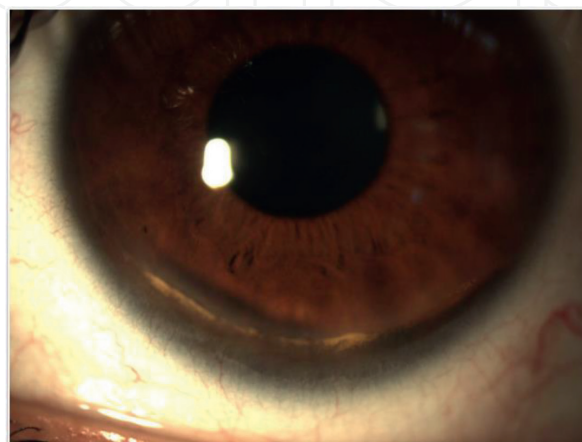


Figure 15.

AS slit-lamp evaluation of a TMD patient. The image demonstrates the lipid deposition in the inferior peripheral corneal area producing yellow-white stromal opacities.

TMD corneal changes can produce an increase in the corneal astigmatism [21], which clinically manifests with a visual acuity decreased. Topography evaluation is essential for a complete pathology study [23].

Two types of TDM have been described. The classic one, more common, generally affects older population [20]. It is usually asymptomatic, noninflammatory, and with a slowly, chronic progress. The second type affects young patients and has a more prominent inflammatory clinical course with a faster evolution [20]. This inflammatory variant is believed to initiate hypersensitivity responses [24, 25] to an immunogenic component of the basal membrane, secreted by the degenerated basal epithelial cells [21]. It can also be produced by phagocytosis of the stromal collagen by histiocyte-like cells [26]. Thinning of the peripheral cornea, corneal opacification, neovascularization, and possible positive fluorescein staining are typically signs of the TMD inflammatory type [21].

Due to the slow progression [22], TMD is generally asymptomatic. Sometimes the diagnosis is incidental because of mild irritation symptoms. Topographic evaluation demonstrates a flattening over the corneal peripheral thinning areas and steepening of the corneal meridian perpendicular to the corneal lesion [21]. TMD slit-lamp biomicroscopy shows the yellowish-white opacities and thinning of the peripheral cornea. The pathology generally initiates at the superior or supero-nasal area. The corneal perforation rate is 15% [21]. It can debut with redness, watering, and sudden decrease of visual acuity. The corneal perforation can cause a deep impact on the vision prognosis regardless of the surgical intervention.

Corneal AS-OCT provides a high-resolution cross-sectional image in TMD patients, and its caliper can take precise and repeatable pachymetry measurements to verify the corneal thickness in the thinner areas (**Figure 16**). It is a safe, rapid, and noninvasive digital technique that depicted structural or morphologic corneal changes. It is a digital precise method to compare the size lesions between the clinical appointments [19, 22]. Medical visits are recommended every 3 months when the minimal corneal thickness is 250 μm [21].

AS-OCT displays the corneal stromal thinning area in TMD disease. The lesions have a non-affected epithelium. In the classic TDM type, the stroma has the same reflectivity as the normal cornea [4]. In the inflammatory TDM, the progressive stromal thinning induces corneal cavity formation with intact epithelial and endothelial layers around the lesion [4, 22] (**Figures 17 and 18**). The external epithelial layer has a normal reflectivity, and the internal endothelial layer is continuous with

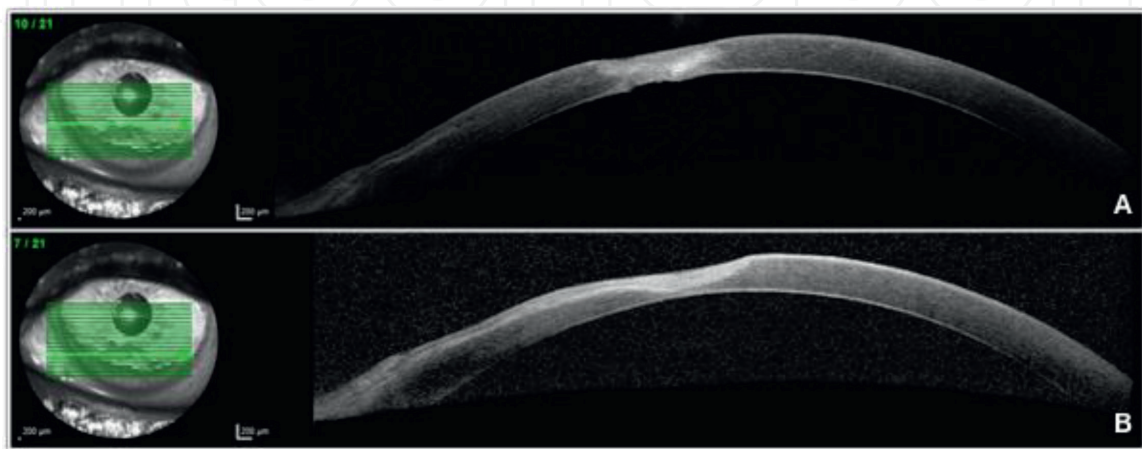


Figure 16. (A and B) AS-OCT scan demonstrates a corneal thinning area and a hyper-reflective zone in an inflammatory TMD patient. The anterior and the posterior corneal surfaces have their curvatures altered.

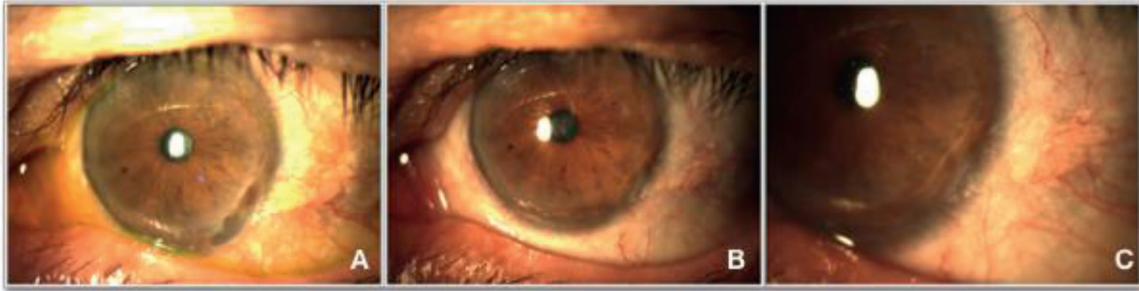


Figure 17. AS slit-lamp evaluation of a TMD patient. (A) The corneal periphery has a lipid deposition and an extensive thinning area. (B and C) Same TMD patient after an amniotic membrane grafting technique. The image demonstrates how the corneal disorder has been restored.

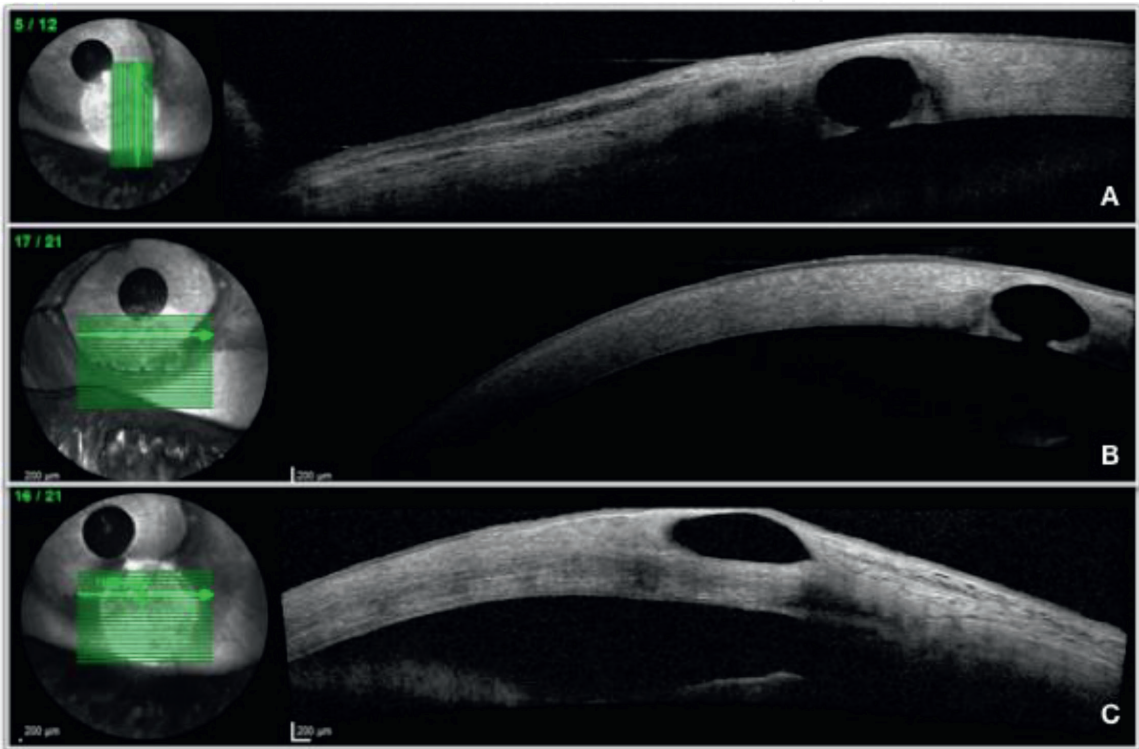


Figure 18. Corneal AS-OCT of the same TMD patient of **Figure 17**. (A) Longitudinal scan analysis demonstrates corneal cavitation. (B, C) Transversal scan evaluation also shows the cavitation in the stromal area.

the rest of the normal endothelial corneal tissue. The corneal thinning areas can show hyper-reflectivity, and AS-OCT evaluation is able to demonstrate corneal cavities not visible in the slit-lamp biomicroscopy [22] (**Figures 17 and 18**).

AS-OCT also evaluates the anterior and the posterior corneal curvatures. Classically, TMD is classified in five clinical stages depending on the disease progression. Recently, a new staging method has been reported [19]. The new classification is based on the anterior and posterior curvatures and the size of the thinnest area, analyzed by corneal AS-OCT. This new staging is useful to evaluate the TMD progression and to plan the surgical management, evidencing the importance of the AS-OCT images to supervise the pathology development.

Due to the slow progression of most TMD cases, the pathology can be managed conservatively in most patients. Noneffective pharmacotherapy has been demonstrated. Nonsurgical interventions include spectacle prescription, rigid gas-permeable contact lenses, scleral lenses, and prosthetic replacement of the ocular surface ecosystem (PROSE) [21]. Eye rubbing has to be avoided.

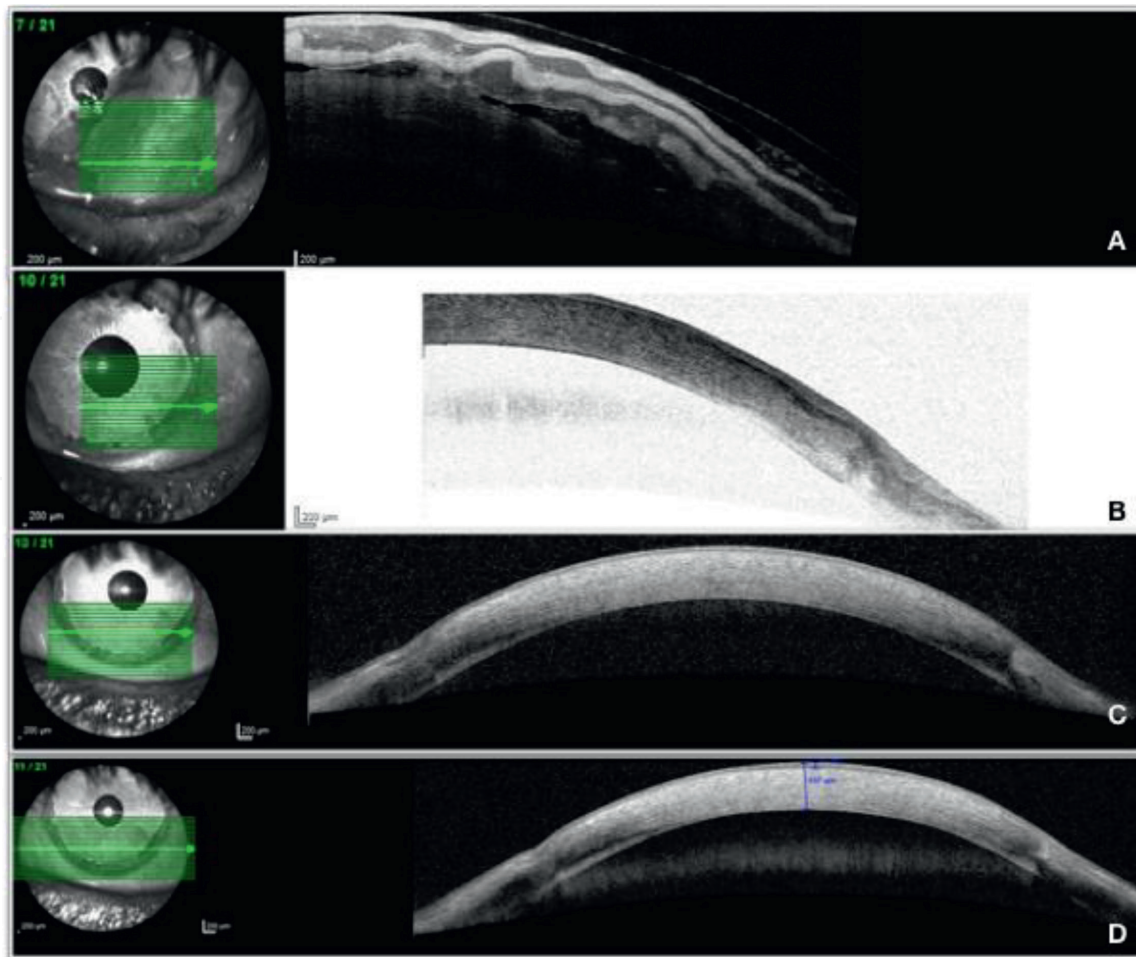


Figure 19. AS-OCT image from the same TMD patient from **Figure 18**. (A) The cavitation zone following an amniotic membrane grafting replace technique. The amniotic membrane layers can be distinguished in the scan. (B–D) The image shows how the amniotic membrane has been integrated in the corneal area and has replaced the cavitation zone.

Surgical procedures are considered when the corneal thickness decreased $150\ \mu\text{m}$. Nevertheless, some authors prefer an expectant attitude even when the cornea reaches this cross-sectional length [27]. Surgical interventions include the tectonic grafting, whose purpose is to prevent or repair perforation areas in the absence of the donor cornea. The main techniques are conjunctival flaps, scleral autotransplantation, and amniotic membrane grafting (**Figure 19**). Keratoplasty is considered in patients who want to improve their visual acuity. LK is the first technique to consider in this TMD patient [22]. If not, PKP is another possible surgical procedure in more severe cases.

Corneal collagen cross-linking has recently been reported as a good option before performing surgical procedures. It seems to stop the disease evolution, return the thinning area, and improve visual acuity [28].

4. Band keratopathy

Band keratopathy is characterized by calcium deposition in Bowman's layer, most frequently in the interpalpebral zone. The pathology is usually associated with systemic disorders, such as hypercalcemia, or ocular diseases, such as uveitis, chemical burns, intraocular silicone oil, and phthisis eyes after surgeries [28].

AS-OCT imaging is useful for the analysis and measure of the calcium deposition and helpful in achieving a correct pathology management. It shows a

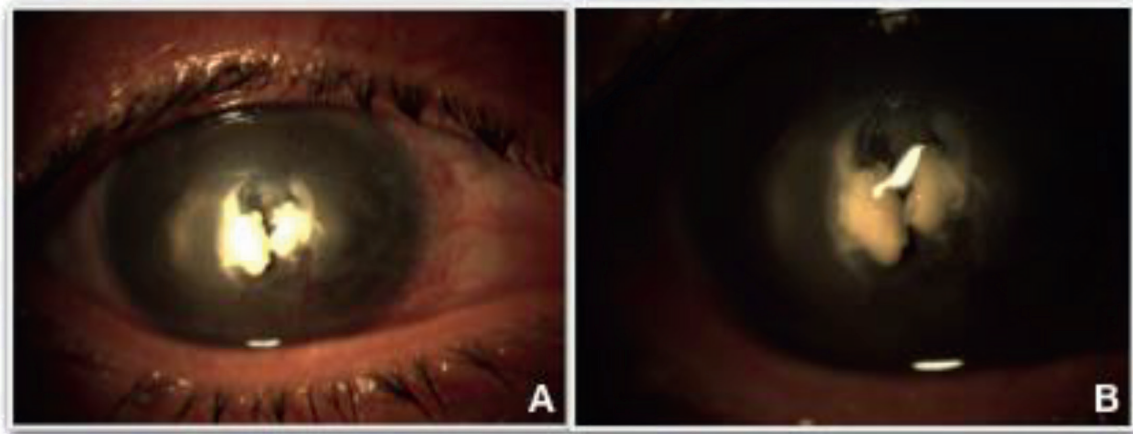


Figure 20.

(A, B) AS slit-lamp evaluation showing calcium deposition in the superficial cornea of a patient with band keratopathy.

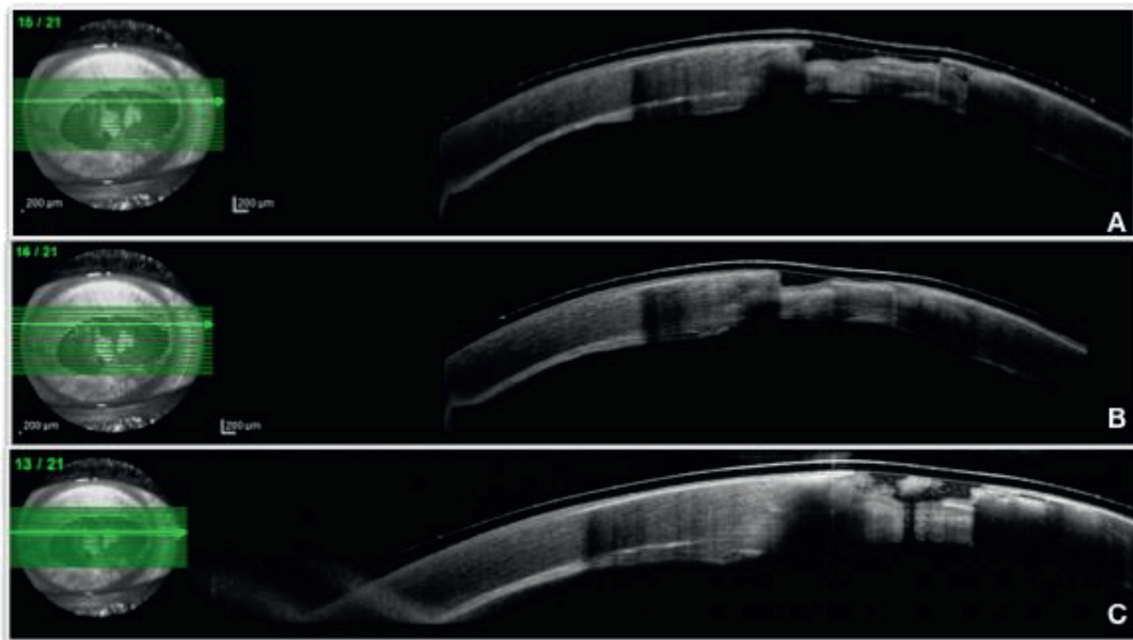


Figure 21.

(A, B, C) AS-OCT evaluation from the same patient of **Figure 20**. There is a hyper-reflective zone in the calcium deposition areas causing shadows in the corneal stroma below the lesions.

hyper-reflective material around Bowman's layer causing shadowing in the posterior cornea stroma [3, 29, 30] (**Figures 20** and **21**).

The calcium deposition can result in a loss of visual acuity. The aim of the surgical techniques will be to restore the corneal transparency. AS-OCT imaging can help to decide the optimal surgical technique as the scans show the depth of the lesions [28].

5. Conclusions

AS-OCT imaging is a useful technique that helps physicians to achieve a correct diagnosis and a proper management of the corneal pathologies. Probably, it will become an essential device in the anterior segment disease assessment, as it has occurred in the posterior segment. It is necessary to recognize the AS-OCT specific optical signs of the corneal degenerations, to decide the best therapeutic choice. The

scans have to be studied carefully in association with the traditional clinic evaluations. The anterior segment specialists have the responsibility to deepen in the AS-OCT corneal degeneration signs to facilitate the diagnosis and to advance in the knowledge of these pathologies.

IntechOpen

Author details

Constanza Caramello Álvarez^{1,2*}, María A. del Buey^{1,2}, Paula Casas^{1,2}, Sara Marco^{1,2}, Enrique Mínguez^{1,2} and Francisco J. Ascaso^{1,2}

1 Department of Ophthalmology, Hospital Clínico Universitario “Lozano Blesa”, Zaragoza, Spain

2 Aragon Health Research Institute (IIS Aragon), Zaragoza, Spain

*Address all correspondence to: coni_86@hotmail.com

IntechOpen

© 2019 The Author(s). Licensee IntechOpen. This chapter is distributed under the terms of the Creative Commons Attribution License (<http://creativecommons.org/licenses/by/3.0>), which permits unrestricted use, distribution, and reproduction in any medium, provided the original work is properly cited. 

References

- [1] Han SB, Liu YC, Noriega KM, Mehta JS. Applications of anterior segment optical coherence tomography in cornea and ocular surface diseases. *Journal of Ophthalmology*. 2016;2016:4971572
- [2] Kanellopoulos AJ, Asimellis G. Anterior-segment optical coherence tomography investigation of corneal deturgescence and epithelial remodeling after DSAEK. *Cornea*. 2014;33:340-348. DOI: 10.1097/ico.0000000000000053
- [3] Venkateswaran N. Optical coherence tomography for ocular surface and corneal diseases: A review. *Eye and Vision*. 2018;5:13. DOI: 10.1186/s40662-018-0107-0
- [4] Rodriguez M, Yesilirmak N, Chhadva P, Goldhagen B, Karp C, Galor A. High-resolution optical coherence tomography in the differentiation of inflammatory versus noninflammatory peripheral corneal thinning. *Cornea*. 2017;36:48-52
- [5] Yasuno Y, Madjarova VD, Makita S, Akiba M, Morosawa A, Chong C, et al. Three-dimensional and high-speed swept-source optical coherence tomography for in vivo investigation of human anterior eye segments. *Optics Express*. 2005;13:10652-10664
- [6] Shapiro BL, Cortés DE, Chin EK, et al. High-resolution spectral domain anterior segment optical coherence tomography in type 1 Boston keratoprosthesis. *Cornea*. 2013;32:951-955
- [7] Vajzovic LM, Karp CL, Haft P, Shousha MA, Dubovy SR, Hurmeric V, et al. Ultra high-resolution anterior segment optical coherence tomography in the evaluation of anterior corneal dystrophies and degenerations. *Ophthalmology*. 2011;118:1291-1296. DOI: 10.1016/j.ophtha.2010.12.015
- [8] Kieval JZ, Karp CL, Abou Shousha M, Galor A, Hoffman RA, Dubovy SR, et al. Ultra-high resolution optical coherence tomography for differentiation of ocular surface squamous neoplasia and pterygia. *Ophthalmology*. 2012;119:481-486. DOI: 10.1016/j.ophtha.2011.08.028
- [9] Thomas BJ, Galor A, Nanji AA, El Sayyad F, Wang J, Dubovy SR, et al. Ultra high-resolution anterior segment optical coherence tomography in the diagnosis and management of ocular surface squamous neoplasia. *The Ocular Surface*. 2014;12:46-58. DOI: 10.1016/j.jtos.2013.11.001
- [10] Nanji AA, Sayyad FE, Galor A, Dubovy S, Karp CL. High-resolution optical coherence tomography as an adjunctive tool in the diagnosis of corneal and conjunctival pathology. *The Ocular Surface*. 2015;13:226-235. DOI: 10.1016/j.jtos.2015.02.001
- [11] Shousha MA, Karp CL, Canto AP, Hodson K, Oellers P, Kao AA, et al. Diagnosis of ocular surface lesions using ultra-high-resolution optical coherence tomography. *Ophthalmology*. 2013;120:883-891. DOI: 10.1016/j.ophtha.2012.10.025
- [12] Zhou SY, Wang CX, Cai XY, Huang D, Liu YZ. Optical coherence tomography and ultrasound biomicroscopy imaging of opaque corneas. *Cornea*. 2013;32:e25-e30
- [13] Ang M, Baskaran M, Werkmeister RM, Chua J, Schmidl D, Aranha Dos Santos V, et al. Anterior segment optical coherence tomography. *Progress in Retinal and Eye Research*. 2018;66:132-156. DOI: 10.1016/j.preteyeres.2018.04.002
- [14] Trufanov SV, Salovarova EP, Tekeeva LY. Corneal degenerations. *Vestnik Oftalmologii*. 2018;134:282-288. DOI: 10.17116/oftalma2018134051282

- [15] Marcon AS, Rapuano CJ. Excimer laser phototherapeutic keratectomy retreatment of anterior basement membrane dystrophy and Salzmann's nodular degeneration with topical mitomycin C. *Cornea*. 2002;**21**:828-830
- [16] Hurmeric V, Yoo SH, Karp CL, et al. In vivo morphologic characteristics of Salzmann nodular degeneration with ultra-high-resolution optical coherence tomography. *American Journal of Ophthalmology*. 2010;**151**:248-256.e2
- [17] Maharana PK, Sharma N, Das S, Agarwal T, Sen S, Prakash G, et al. Salzmann's nodular degeneration. *The Ocular Surface*. 2016;**14**:20-30. DOI: 10.1016/j.jtos.2015.08.006
- [18] Das S, Link B, Seitz B. Salzmann's nodular degeneration of the cornea: A review and case series. *Cornea*. 2005;**24**:772-777
- [19] Wang N, Wang CX, Lian XF, Duan SJ, Huang D, Zhou SY. Staging of development in Terrien's degeneration based on corneal curvatures detected by optical coherence tomography. *Graefes Archive for Clinical and Experimental Ophthalmology*. 2015;**253**:1757-1764. DOI: 10.1007/s00417-015-3057-4
- [20] Lee TL, Lee HY, Tan JCH. Terrien marginal degeneration complicated by a corneoscleral cyst. *Cornea*. 2018;**37**:658-660. DOI: 10.1097/ICO.0000000000001546
- [21] Ding Y, Murri MS, Birdsong OC, Ronquillo Y, Moshirfar M. Terrien marginal degeneration. *Survey of Ophthalmology*. 12 Oct 2018. pii: S0039-6257(18)30047-X. DOI: 10.1016/j.survophthal.2018.09.004. Review. PubMed PMID: 30316804. [Epub ahead of print]
- [22] Hattori T, Kumakura S, Mori H, Goto H. Depiction of cavity formation in Terrien marginal degeneration by anterior segment optical coherence tomography. *Cornea*. 2013;**32**:615-618. DOI: 10.1097/ICO.0b013e318259c970
- [23] Fernandes M. Scanning slit topography: Diagnostic boon in presumed unilateral Terrien's marginal degeneration. *Contact Lens & Anterior Eye*. 2011;**34**:282-286
- [24] Iwamoto T, DeVoe a FRL. Electron microscopy in cases of marginal degeneration of the cornea. *Investigative Ophthalmology*. 1972;**11**:241-257
- [25] Austin P, Brown SI. Inflammatory Terrien's marginal corneal disease. *American Journal of Ophthalmology*. 1981;**92**:189-192
- [26] Süveges I, Lévai G, Alberth B. Pathology of Terrien's disease: Histochemical and electron microscopic study. *American Journal of Ophthalmology*. 1972;**74**:1191-1200. DOI: 10.1016/0002-9394(72)90742-8
- [27] Galvis V, Tello A, Niño CA, Larrea J. Terrien marginal degeneration: Clinical characteristics and outcomes. *American Journal of Ophthalmology*. 2016;**164**:151-152. DOI: 10.1016/j.ajo.2016.01.001
- [28] Hafezi F, Gatziofufas Z, Seiler TG, Seiler T. Corneal collagen cross-linking for Terrien marginal degeneration. *Journal of Refractive Surgery*. 2014;**30**:498-500. DOI: 10.3928/1081597X-20140527-02
- [29] Mansour AM, Haddad R. Optical coherence tomography of band keratopathy. *BML Case Reports*. 2016;**2016**: pii: bcr2016218216. doi: 10.1136/bcr-2016-218216
- [30] Moisseiev E, Gal A, Addadi L, Caspi D, Shemesh G, Michaeli A. Acute calcific band keratopathy: Case report and literature review. *Journal of Cataract and Refractive Surgery*. 2013;**39**:292-294. DOI: 10.1016/j.jcrs.2012.12.020