

We are IntechOpen, the world's leading publisher of Open Access books Built by scientists, for scientists

4,800

Open access books available

122,000

International authors and editors

135M

Downloads

Our authors are among the

154

Countries delivered to

TOP 1%

most cited scientists

12.2%

Contributors from top 500 universities

**WEB OF SCIENCE™**Selection of our books indexed in the Book Citation Index
in Web of Science™ Core Collection (BKCI)

Interested in publishing with us?
Contact book.department@intechopen.com

Numbers displayed above are based on latest data collected.
For more information visit www.intechopen.com



Eye Movement Abnormalities in Neurodegenerative Diseases

*Roberto Rodríguez-Labrada, Yaimeé Vázquez-Mojena
and Luis Velázquez-Pérez*

Abstract

Neurodegenerative disorders consist in heterogeneous group of neurological conditions characterized by a wide spectrum of clinical features resulting from a progressive involvement of distinct neuron populations. Oculomotor abnormalities take a key place in the clinical picture of these disorders because the neurodegenerative processes involve the brain circuits of eye movements. The most common abnormalities include the saccadic dysfunction, fixation instability, and abnormal smooth pursuit. The clinical assessment of oculomotor function can help to differentiate diagnosis, while electrophysiological measures provide useful biomarkers for the understanding of disease physiopathology and progression. In this chapter, we review the state of the art of the eye movement's deficits in some neurodegenerative diseases, such as Parkinson's disease, Alzheimer's disease, amyotrophic lateral sclerosis, Huntington's disease, and the hereditary ataxias.

Keywords: eye movements, oculomotor abnormalities, neurodegenerative disorders, biomarkers, Parkinson's disease, Alzheimer's disease, dementia, hereditary ataxias

1. Introduction

Neurodegenerative disorders encompass a highly heterogeneous group of complex neurological disorder characterized by progressive dysfunction and loss of neuron populations leading a wide spectrum of clinical features that cause notable motor and/or intellectual disabilities regularly incompatible with the life [1]. Consequently, some of these conditions represent important public health concern and has been identified as a research priority. Although physiopathological mechanisms generally differ among neurodegenerative diseases, a great number of them are characterized by abnormal accumulation of misfolded protein resulting in the loss of their physiological function and/or the gain of toxic functions [2, 3].

Classification of neurodegenerative disorders can be established by both the cardinal clinical features and the disease proteins (**Figure 1**). The former characterization distinguishes those conditions characterized by dementia syndromes and the movement disorders. Among dementias, the most commonly recognized disorder is the Alzheimer's disease. Other dementia syndromes include the frontotemporal dementia, the posterior cortical atrophy, the corticobasal syndrome, and others. Movement disorders comprise hypokinetic (such as Parkinson's disease) and hyperkinetic (such as Huntington's disease) conditions, as well

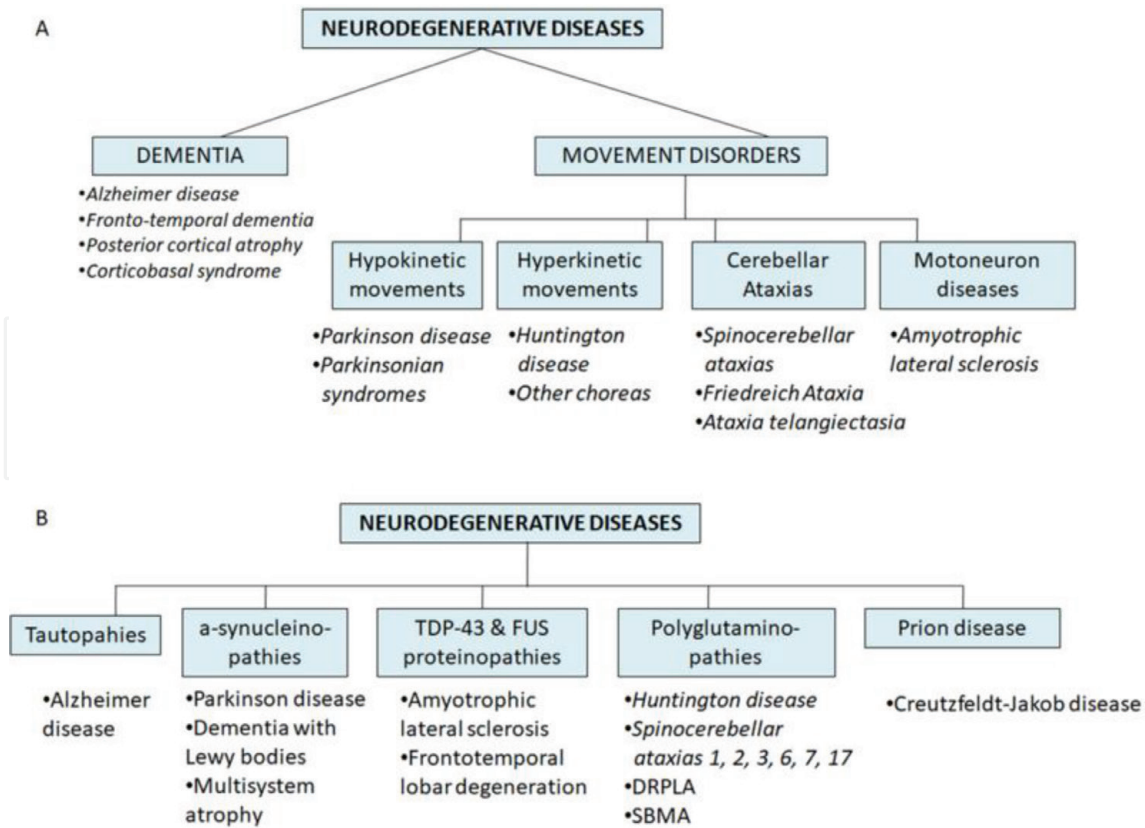


Figure 1. Classification of neurodegenerative diseases according to cardinal syndrome (A) and disease proteins (B).

as cerebellar ataxias and motor neuron diseases (such as amyotrophic lateral sclerosis) [1, 4].

The protein-based classification includes the tauopathies, the a-synucleinopathies, the TDP-43 and FUS proteinopathies, the polyglutamine diseases, and the prion disease. Tauopathies are caused by abnormal accumulation of tau protein and B-amyloids and are represented by the Alzheimer dementia, whereas among the a-synucleinopathies are recognized as the Parkinson’s disease, dementia with Lewy bodies, and multisystem atrophy. Abnormal accumulation of TDP-43 and FUS proteins defines the physiopathology of the amyotrophic lateral sclerosis and frontotemporal lobar degeneration, whereas the polyglutamine diseases result from the accumulation of proteins with abnormally expanded polyglutamine domains and include the Huntington’s disease; the spinocerebellar ataxias 1, 2, 3, 6, 7, and 17; the dentatorubral-pallidoluysian atrophy; and the spinal and bulbar muscular atrophy. Finally, the Creutzfeldt-Jakob disease is classified as a prion disease [1, 4].

Although the phenotypical features of neurodegenerative disorders generally differ between distinct disorders due to the differential involvement of specific functional systems, most of these conditions are characterized by altered oculomotor function as a result of the high vulnerability of the oculomotor system to the toxic protein deposition and other physiopathological mechanisms causing neurodegenerative diseases [5, 6]. Accordingly, the assessment of oculomotor function has become a helpful approach to diagnose some of the neurodegenerative diseases. Besides, eye movements are usually used for monitoring of disease progression [6, 7].

This chapter is focused to review the state of the art of the eye movement’s deficits in some neurodegenerative diseases, such as Parkinson’s disease, Alzheimer’s disease, amyotrophic lateral sclerosis, Huntington’s disease, and the hereditary ataxias.

2. Brief overview of eye movements

Eye movements facilitate the clear vision stabilizing images on the retina, particularly against head and body movements, capturing and keeping specific stimuli on the fovea and aligning the retinal images in the two eyes to ensure the single vision and stereopsis. Ocular motility is guaranteed by five basic types of eye movements: the vestibulo-ocular reflex, the optokinetic reflex, the saccadic movements, the smooth pursuit movements, and the vergence [8].

Although they differ in various aspects, such as their velocity, reaction time, reflexivity/volitional degree, and their neurobiological substrates [9], all have generic kinematic properties and share a common final path represented by three cranial nerve nuclei and the three pairs of eye muscles that they control [8, 10]. Cranial nerve III (oculomotor) innervates the superior, inferior, and medial rectus muscles as well as the inferior oblique muscle, whereas trochlear (IV) and abducens (VI) nerves innervate the superior oblique and lateral rectus, respectively [10].

The vestibulo-ocular reflex (VOR) is elicited by the vestibular system in response to body/head rotations and consists on compensatory eye movements in opposite direction to body/head movements to guarantee the image stabilization on the retina [11]. When head/body rotations are very large and continued, the VOR is depressed, and thus, it is complemented by the optokinetic reflex (OKR), in which the speed and direction of a full-field image motion are computed to develop eye movements with two phases: a slow phase that alternates with resetting a quick phase [12].

Saccades are ballistic and conjugate eye movements that redirect the fovea from one object of interest to another, allowing to explore accurately the visual scenes. For that, saccadic system processes information about the distance and direction of a target image from the current position of gaze. Saccades are the fastest eye movements, reaching up to 800/s. Behaviorally, saccades may be classified as reflex-guided saccades and intentional or volitional saccades. The first ones are evoked by suddenly appearing targets, whereas the second ones, called also as higher-order saccades, are made purposefully. Therefore, intentional saccades involve high-cognitive processing and include voluntary, memory-guided and delayed saccades, as well as antisaccades [13, 14].

Smooth pursuit eye movements enable us to maintain the image of a moving object relatively stable on or near the fovea by matching eye velocity to target velocity [10]. Smooth pursuit performance is optimal for target speeds ranging between 150/s and 300/s, but pursuit velocity can reach up to 100/s [8, 15].

Vergence eye movements are disjunctive movements that provide the binocular alignment in response to changing fixation of target distances, requiring that both eyes point in contrary directions. These movements are elicited by retinal disparity (when a fixation target is not on both foveae) and retinal blur (when a target is not in focus). Therefore, these movements are closely related to the lens accommodation and pupillary reflexes [16].

3. Oculomotor disturbances in neurodegenerative diseases

3.1 Parkinson's disease and other parkinsonian disorders

3.1.1 Parkinson's disease

Parkinson's disease is a progressive disorder pathologically defined by the degeneration of the dopaminergic neurons in the *substantia nigra* and formation

of α -synuclein-containing Lewy bodies in the residual dopaminergic neurons. Consequently, the clinical picture is characterized by progressive motor symptoms that include bradykinesia, muscular rigidity, rest tremor, as well as postural and gait impairment. The disease is also associated with many non-motor symptoms, some of which precede the motor dysfunction by more than a decade [17]. Global prevalence of PD ranges between 100 and 200 cases per 100,000 inhabitants, with an annual incidence around 15 cases per 100,000 [18]. Although the etiology of PD is commonly unknown, monogenic causes can be considered in 5–10% of the cases [19].

Findings about oculomotor function in PD are certainly inconsistent due to the reduced number of patients included in the majority of the studies and the heterogeneity of the disease phenotype [7]. Nevertheless, saccadic hypometria is recognized as the most striking oculomotor feature in PD patients, which can be documented both at bedside and by electrophysiological approaches even early in the disease course. As a result of the saccade hypometria, PD patients frequently require multistep sequences to reach the target [20]. This behavior is more pronounced during memory-guided saccades, and it is considered as a disease biomarker [21, 22]. The marked saccade hypometria in PD can be explained by the neurodegenerative changes in the basal ganglia causing the decrease of pre-oculomotor drive through the substantia nigra to the superior colliculus [21]. Alongside the saccade hypometria, PD patients also show abnormally prolonged latency of voluntary saccades such as the memory-guided saccades and the antisaccades; nevertheless, the latency of externally triggered saccades to visual targets is normal [23]. Distinct to the saccade hypometria, the deficits in the saccade initiation are detectable later in the disease course and are closely related with the cognitive impairments and the involvement of non-dopaminergic pathways such as the frontal and parietal eye fields, the premotor cortex, and the lateral prefrontal cortex [24].

The delayed prosaccade and the antisaccade tasks reveal an impaired inhibition of saccades as evidence of deficit of automatic response inhibition. PD patients show increased timing error rates in the delayed prosaccade paradigm, which are closely associated with abnormal neuropsychological performance, whereas antisaccade paradigm reveals higher directional error rates [25]. Antisaccade errors can be detected early in the disease course [26]. Beyond saccadic impairments, PD patients show slight alterations in other eye movements, such as reduced gain of the smooth pursuit movements [27] and slow and hypometric divergence movements, but normal convergence movements [28].

3.1.2 Other parkinsonian disorders

Oculomotor findings of patients suffering from other parkinsonian disorders are varied and usually distinctive to the PD. In cases with multisystem atrophy with predominant Parkinsonism (MSA-P), the clinical assessments of oculomotor function usually reveal increased square wave jerks, saccade hypometria, as well as abnormal smooth pursuit and vestibulo-ocular reflex [29, 30]. Less common oculomotor features in MSA-P include downbeat nystagmus, head-shaking nystagmus, and mild vertical supranuclear gaze palsy [29, 31].

In the progressive supranuclear palsy with Parkinsonism (PSP-P), the most important oculomotor feature is the slowing of vertical saccades, which progresses to supranuclear gaze palsy in the 70% of the cases but appear lately in the disease course than in the classic PSP [32]. In addition, these patients show reduced gains of the smooth pursuit movements and saccadic eye movements at similar extent that in classic PSP [27].

3.2 Alzheimer's disease and other dementias

3.2.1 Alzheimer's disease

Alzheimer's disease (AD) is the most common neurodegenerative disorder worldwide with a global prevalence above 20 million of affected people, which is estimated to grow notably in the next decades. The histopathological hallmark of the disease is the deposition of insoluble protein aggregates such as amyloid- β ($A\beta$) plaques and neurofibrillary tangles of tau in the brain, causing a significant brain atrophy and subsequent cognitive features such as memory disturbances, executive dysfunction, difficulties with language, and other cognitive skills that affect a person's ability to perform every day [33]. Similar to PD, the etiology of Alzheimer's disease (AD) is not fully understood, but several environmental and genetic factors are assumed to contribute to the disease etiopathogenesis [34].

Oculomotor testing in Alzheimer's disease reveals a varied group of eye movement abnormalities, but no specific oculomotor feature is distinguished. Among oculomotor features of AD patients, the saccadic intrusions are one of the most common [35, 36]. These unwanted microsaccades are mainly oblique and can be detected even in subjects with mild cognitive impairment which identify this oculomotor feature as a potential biomarker of Alzheimer's disease at early stages [37]. These microsaccades are more frequent in those patients with higher dementia scores [38], which support the notion that gaze-fixation instability in AD results from the involvement of cognitive processes such as the attention and working memory. Nevertheless, the impairment of the saccade pathways could also explain the high occurrence of saccadic intrusions, mainly at later disease stages [39].

Reflexive and voluntary saccades of AD patients are usually characterized by prolonged latencies, reduced velocity, and hypometria. Antisaccadic paradigm reveals increased directional error rate alongside with the reduction of the error correction, which are closely associated with the severity of dementia [40]. Both prosaccadic and antisaccadic alterations in AD are proposed to result from impaired inhibitory control and attentional failures, as well as from the later involvement of saccadic circuitry at brainstem [39]. In addition, AD patients show increased latency to initiate smooth pursuit movements, with decreased gain velocity and increased catch-up (compensatory) saccades. Similar to the saccadic intrusions and antisaccadic deficits, the rate of compensatory saccades during the smooth pursuit is narrowly related with the dementia severity [40–42].

3.2.2 Other dementias

In the posterior cortical atrophy (PCA), an atypical variant of AD, the most frequent oculomotor abnormalities include increased saccade latency and decreased saccade amplitude, but the saccade velocity is normal. Also, the PCA patients show increased time to saccadic target fixation, even higher than subjects with typical AD. Moreover, these patients show large saccadic intrusions whose frequency is correlated with generalized reductions in cortical thickness. Smooth pursuit gain is slightly reduced in these patients [43, 44]. Moreover, individuals with frontotemporal dementia (FTD) show increased reflexive saccade latency and higher rates of antisaccadic errors, but the error correction abilities are preserved. In addition, the smooth pursuit movements are characterized by the reduction of gains and accelerations [40, 45, 46].

3.3 Huntington's disease

Huntington's disease is a neurodegenerative disorder caused by the abnormal expansion of cytosine-adenine-guanine (CAG) trinucleotide repeats in the huntingtin gene on chromosome 4, encoding the huntingtin protein. The mutation results in an excessively long polyglutamine stretch near the N-terminus of this protein, which identifies this disorder as a polyglutamine disease. Mutant HTT affects some cellular processes, including protein-protein interaction, protein clearance, mitochondrial function, axonal trafficking, gene transcription, posttranslational modification, and others that ultimately cause the loss of striatal neurons [47].

Clinically, the disease is characterized by a progressive motor, cognitive, and psychiatric disturbance. The motor phenotype includes chorea as a cardinal feature, as well as dystonia and Parkinsonism, whereas the cognitive dysfunction comprises dysexecutive signs, as well as memory and attentional dysfunction. Psychiatric features are usually depression, anxiety, apathy, obsessive-compulsive behaviors, and others. Similar to other polyglutamine disorders, the age at onset of HD is highly influenced by the CAG repeat length, but other genetic and environmental modifying factors are proposed to also control the age at onset variability [47, 48].

Oculomotor abnormalities of patients with HD include saccade slowing and deficits in the initiation and suppression of these movements. The reduction of saccade velocity appears in around 60% of patients and is commonly observed in the vertical plane, but in those cases in advanced disease stages, the saccade slowing reaches also the horizontal movements [49, 50]. Saccade latencies are significantly prolonged and show a marked variability, which is more pronounced in patients showing higher disease severity. Studies using the antisaccadic paradigm have revealed an increased rate of directional errors, which are also closely correlated with the severity of the disease. Moreover, increases of latency variability and timing errors are observed in the memory-guided saccade task. The deficits of the suppression and initiation of the saccades can be explained by the neurodegenerative changes in the frontal cortex and in the basal ganglia [51, 52]. So, a recent imaging research revealed a close association between the voluntary saccade inhibition deficits and the white-matter corticobasal atrophy in patients [53].

Several authors have evaluated saccadic eye movements in asymptomatic carriers of the HD mutation. These studies have found a significant delay in the initiation of voluntary eye movements, increase in the variability of saccadic latency, and increase in the rate of antisaccadic errors [54–56]. A longitudinal follow-up of these alterations demonstrated their usefulness as preclinical markers due to the high replicability and consistency of these measures [22]. Imaging studies in asymptomatic carriers of HD have shown a significant correspondence between alterations in saccadic latency and the decrease in the number of fronto-striatal fibers that project into the caudate nucleus and the atrophy of gray matter in cortical structures, which deepens in the pathophysiology of saccadic alterations in this disease [57, 58]. A recent paper demonstrated that the horizontal ocular pursuit item of the Unified Huntington's Disease Rating Scale is useful for detecting differences between premanifest individuals and controls [59].

3.4 Amyotrophic lateral sclerosis

Amyotrophic lateral sclerosis (ALS) is the most common and devastating age-related motor neuron disease, characterized by a progressive loss of upper and lower motoneurons, causing paralysis and death in approximately 3 years. The pathological hallmark of ALS is the presence of abundant cytoplasmic inclusions containing ubiquitin and TDP-43, a RNA-binding protein. The clinical picture

comprises progressive muscle weakness alongside hyperreflexia and spasticity associated with fibrillations and fasciculations [60]. The disease has a global prevalence around five cases per 100,000 inhabitants. Most of ALS cases are sporadic, and only the 5% of patients are familial, with at least 12 genes implicated, such as the superoxide dismutase 1 (SOD1), trans-activate response DNA-binding protein (TARDBP), C9ORF72, FUS, and the ataxin-2 genes [61, 62].

Some evidences have demonstrated the involvement of the oculomotor system in ALS, leading a broad range of eye movement deficits affecting the saccades and the smooth pursuit movements [63–66]. The most prominent and early oculomotor alterations of ALS patients are related with abnormal executive oculomotor control as evidence of frontal lobe involvement. They primarily includes the increase of error rates in anti-saccades and delayed saccade paradigms as well as reduced voluntary gaze shift and increased number of saccadic intrusions. In general, these oculomotor alterations are correlated with the severity of the disease and the neurocognitive measures. In a following stage of oculomotor abnormalities, some ALS cases can show slow saccades, saccade hypometria, and interrupted smooth pursuit, as evidences of the involvement of the brainstem and pre-cerebellar/pon-tine circuits [67].

3.5 Hereditary ataxias

Hereditary ataxias consist in a heterogeneous group of genetic disorders phenotypically characterized by gait ataxia, limb incoordination, dysmetria, dysarthria, oculomotor disturbances, and other motor and non-motor features. These disorders are associated with atrophy of the cerebellum, which can be accompanied with the degeneration of other regions in the central and peripheral nervous system in various genetic subtypes [68].

Hereditary ataxias are classified into four main groups regarding their inheritance patterns: autosomal dominant (also referred as spinocerebellar ataxias), autosomal recessive, X-linked, and mitochondrial ataxias [68, 69]. Till now, 46 subtypes of spinocerebellar ataxias have been identified, which imply at least 37 distinct genes [70]. The most common subtypes are caused by polyglutamine (polyQ)-coding CAG repeat expansions (SCA1,2,3,6,7,17, DRPLA) [71]. Regarding the recessive ataxias, nearly 100 genes have been identified, with the highest prevalence for the Friedreich's ataxia (FRDA), caused by GAA repeat expansions or point mutations in the frataxin (FXN) [68, 72]. Global prevalence of hereditary ataxias is estimated around three cases per 100,000 inhabitants, but there are large regional variations of prevalence due to founder effects of some genes [73].

Oculomotor disturbances of SCA patients are varied and result from the cerebellar and/or brainstem involvement. The former abnormalities are the most common and include the presence of pathological nystagmus, abnormal smooth pursuit, and saccadic dysmetria, whereas the impaired VOR, saccadic slowing, and ophthalmoplegia are related with pontine degeneration. Nevertheless, the notable overlapping of oculomotor features between SCA subtypes implies the requirement of other clinical criteria or the genetic testing for sensitively discriminating among these diseases [74–78] (**Figure 2**).

In the case of SCA2, an early and severe saccadic slowing is observed even more than a decade before the ataxia onset [79], which identifies it as important preclinical biomarker of the disease. Interestingly, the SCA2 saccade slowing is tightly influenced by the expanded CAG repeats in the ATXN2 gene [80] and shows a significant familiar aggregation which leads to the suitability of this disease feature as endophenotype marker [81], with potential usefulness for the search of modifier genes and neurobiological underpinnings of the disease and as outcome measure

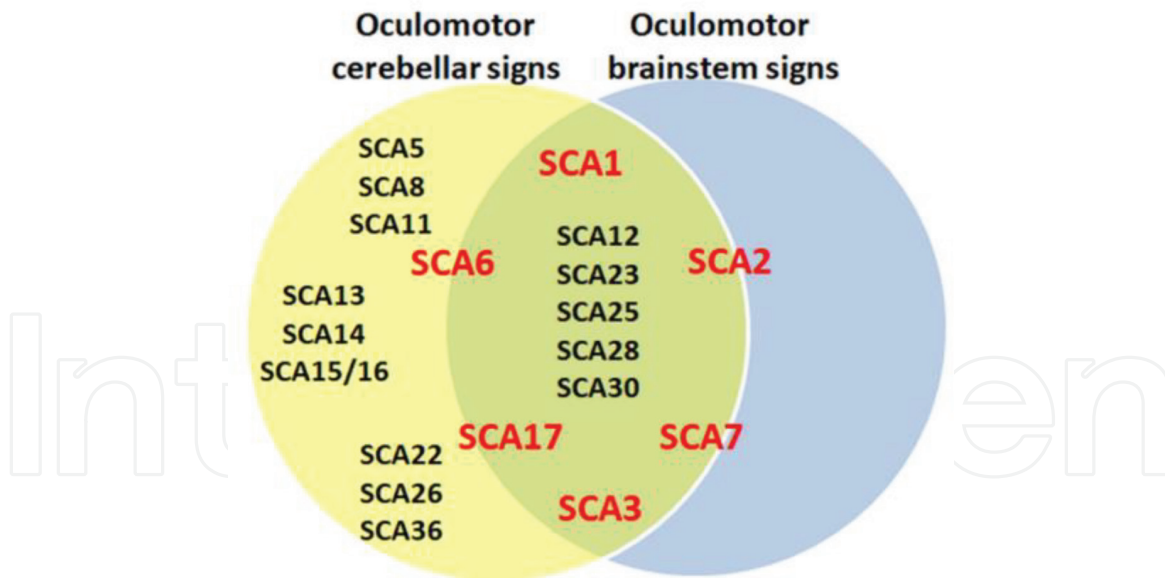


Figure 2.
Cerebellar and/or brainstem origin of oculomotor features in SCAs.

in future neuroprotective clinical trials. Moreover, the saccade slowing in SCA2 progresses significantly along time providing novel insight into the cumulative polyglutamine neurotoxicity and supporting the usefulness of saccade peak velocity as a sensitive biomarker during the natural history of the disease [82]. Saccade pathology in SCA2 is also characterized by abnormal prolongation of reflexive and voluntary latencies and increases of the antisaccade error rate. The later feature is also detected in prodromal stage and is significantly correlated with the mutation size [83–85].

The main eye movement abnormalities of SCA1 patients include saccadic dysmetria, gaze-evoked nystagmus, and depressed smooth pursuit [86]. Saccadic hypermetria is observed in majority of cases, appears at an early stage of the disease, and progresses quickly [75, 76, 87]. SCA3 is characterized by a higher frequency of gaze-evoked and rebound nystagmus [88], in addition to decreased smooth pursuit gain and saccadic dysmetria. These patients also show decreased VOR gain, which correlated with the CAG repeats, suggesting the pathologic involvement of the vestibular nuclei in the lateral brainstem [74–76]. Divergence insufficiency and strabismus are also common oculomotor features of these patients [89, 90].

In SCA6, a higher frequency of spontaneous downbeat nystagmus and square wave jerks is detected [76, 91, 92]. The square wave jerks together with subtle abnormalities of saccades and smooth pursuit movements can be detected even before the disease onset [93]. The major saccadic alteration in SCA7 is the slowing of saccades, together with saccadic dysmetria [94, 95]. These alterations may precede cerebellar and retinal manifestations by some years [96]. Patients with SCA17 show hypometric saccades which are increased with disease duration but neither with ataxia score nor CAG repeats number [97].

Eye movement disturbances are frequent in FRDA. The most prominent abnormalities consist in fixation instability such as multiple square wave jerks and ocular flutter, which are also complemented by abnormal smooth pursuit, saccadic dysmetria, prolongation of saccade latency, gaze-evoked nystagmus, and impaired VOR. Interestingly, the prolongation of saccade latency and the square wave jerks are significantly correlated with the disease severity and age at disease onset, respectively [98, 99]. Moreover, antisaccades and memory-guided saccades are also abnormal in these patients as evidence of the disruption of the higher-order processes controlling the saccade movements [100].

4. Concluding remarks

Eye movement abnormalities are among the most common phenotypic manifestations of patients with neurodegenerative diseases. The prominent features include the saccadic abnormalities, fixation instability, and abnormal smooth pursuit. Thus, the examination of eye movements is a very useful, but not determinant, approach for the differential diagnosis of these disorders. For example, the increased square wave jerks and the slowing of vertical saccades may be useful features for the clinicians in order to distinguish between the MSA-P and the PSP-P from the idiopathic Parkinson's disease, respectively. In addition, the early and severe saccadic slowing with rare pathological nystagmus distinguishes SCA2 from other autosomal dominant ataxias, whereas the marked abnormalities of smooth pursuit, VOR and OKR, in association with pathological nystagmus and rare saccadic slowing may help to define a SCA6 phenotype. Nonetheless, the notable overlapping of oculomotor features between neurodegenerative disorders suggests the necessity of other diagnostic criteria for sensitively discriminating among diseases with similar symptomatology.

Besides, the assessment of oculomotor function in neurodegenerative disorders leads to the identification of disease biomarkers, which acquire key values in the clinical and research practice of neurodegenerations. Many eye movement markers of neurodegenerative disorders allow to assess the disease stage and disease progression, because their changes over time are significantly linked with clinical outcome of syndrome severity, and interestingly some oculomotor disturbances precede the clinical diagnosis of the disease, which identify them as useful preclinical markers to detect the early stages of the neurodegenerative process, to evaluate the genetic susceptibility of the asymptomatic relatives, and to identify individuals for enrolment in early intervention trials.

Moreover, the study of eye movements in neurodegenerative diseases offers valuable advantages to assess the cognitive functioning in these conditions, mainly those measures that reflect the high-order processes underlying the oculomotor functions such as the antisaccade and memory-guided saccade task outcomes, the saccade latency, and others.

In conclusion, although by decades the oculomotor system has been widely studied in neurodegenerative diseases, further efforts are warranted to study their involvement in other—less common—disorders, to understand the physiopathological mechanisms underlying oculomotor disturbances and to certify the role of oculomotor features as sensitive outcome measures in further neuroprotective trials.

Acknowledgements

We are very indebted to Cuban Ministry of Public Health for their collaboration.

Conflict of interest

Authors declared no conflict of interest.

Appendices and nomenclature

AD	Alzheimer's disease
ALS	amyotrophic lateral sclerosis

CAG	cytosine-adenine-guanine trinucleotide
DRPLA	dentatorubral-pallidoluysian atrophy
FRDA	Friedreich's ataxia
FTD	frontotemporal dementia
FXN	frataxin
HD	Huntington's disease
MSA-P	multisystem atrophy with predominant Parkinsonism
OKR	optokinetic reflex
PCA	posterior cortical atrophy
PD	Parkinson's disease
PSP-P	progressive supranuclear palsy with Parkinsonism
SCA	spinocerebellar ataxia
VOR	vestibulo-ocular reflex

Author details

Roberto Rodríguez-Labrada^{1*}, Yaimeé Vázquez-Mojena¹ and Luis Velázquez-Pérez^{1,2}

¹ Centre for the Research and Rehabilitation of Hereditary Ataxias, Holguin, Cuba

² Cuban Academy of Sciences, Havana, Cuba

*Address all correspondence to: robertrl1981@gmail.com

IntechOpen

© 2019 The Author(s). Licensee IntechOpen. This chapter is distributed under the terms of the Creative Commons Attribution License (<http://creativecommons.org/licenses/by/3.0>), which permits unrestricted use, distribution, and reproduction in any medium, provided the original work is properly cited. 

References

- [1] Kovacs GG. Concepts and classification of neurodegenerative diseases. *Handbook of Clinical Neurology*. 2017;**145**:302-307
- [2] Carrell RW, Lomas DA. Conformational disease. *Lancet*. 1997;**350**:134-138
- [3] Csizmok V, Tompa P. Structural disorder and its connection with misfolding diseases. In: Ovadi J, Orosz F, editors. *Protein Folding and Misfolding: Neurodegenerative Diseases, Focus on Structural Biology*. Vol. 7. Dordrecht: Springer; 2009. pp. 1-20. ISBN: 978-1-4020-9433-0
- [4] Kovacs GG. Classification of neurodegenerative diseases. In: Kovacs GG, editor. *Neuropathology of Neurodegenerative Diseases: A Practical Guide*. Cambridge: Cambridge University Press; 2016. pp. 1-7. ISBN: 978-1-107-44242-9
- [5] MacAskill MR, Anderson TJ. Eye movements in neurodegenerative diseases. *Current Opinion in Neurology*. 2016;**29**:61-68
- [6] Gorges M, Pinkhardt EH, Kassubek J. Alterations of eye movement control in neurodegenerative movement disorders. *Journal of Ophthalmology*. 2014;**2014**:658243
- [7] Anderson TJ, MacAskill MR. Eye movements in patients with neurodegenerative disorders. *Nature Reviews Neurology*. 2013;**9**:74-85
- [8] Bruce CH, Friedman HR. Eye movements. *Encyclopedia of the Human Brain*. 2002;**2**:269-297
- [9] Sparks DL. The brainstem control of saccadic eye movements. *Nature Reviews Neuroscience*. 2002;**3**:952-964
- [10] Leigh RJ, Zee DS. *The Neurology of Eye Movements*. 4th ed. New York, USA: Oxford University Press; 2006
- [11] Aw ST, Haslwanter T, Halmagyi GM, Curthoys IS, Yavor RA, Todd MJ. Three-dimensional vector analysis of the human vestibuloocular reflex in response to high-acceleration head rotations. I. Responses in normal subjects. *Journal of Neurophysiology*. 1996;**76**:4009-4020
- [12] Tusa R, Zee D. Cerebral control of smooth pursuit and optokinetic nystagmus. *Current Opinion in Ophthalmology*. 1989;**2**:115-146
- [13] Müri RM, Nyffeler T. Neurophysiology and neuroanatomy of reflexive and volitional saccades as revealed by lesion studies with neurological patients and transcranial magnetic stimulation (TMS). *Brain and Cognition*. 2008;**68**:284-292
- [14] Leigh RJ, Kennard C. Using saccades as a research tool in the clinical neurosciences. *Brain*. 2004;**127**:460-477. ISSN 1460-2156
- [15] Lencer R, Trillenber P. Neurophysiology and neuroanatomy of smooth pursuit in humans. *Brain and Cognition*. 2008;**68**:219-228
- [16] Zee DS, Levi L. Neurological aspects of vergence eye movements. *Revista de Neurologia*. 1989;**145**:613-620
- [17] Kalia LV, Lang AE. Parkinson's disease. *Lancet*. 2015;**386**:896-912
- [18] Tysnes OB, Storstein A. Epidemiology of Parkinson's disease. *Journal of Neural Transmission (Vienna)*. 2017;**124**(8):901-905
- [19] Singleton AB, Farrer MJ, Bonifati V. The genetics of Parkinson's disease: Progress and therapeutic implications. *Movement Disorders*. 2013;**28**:14-23

- [20] DeJong JD, Jones GM. Akinesia, hypokinesia, and bradykinesia in the oculomotor system of patients with Parkinson's disease. *Experimental Neurology*. 1971;**32**:58-68
- [21] Kimmig H, Haussmann K, Mergner T, Lucking CH. What is pathological with gaze shift fragmentation in Parkinson's disease? *Journal of Neurology*. 2002;**249**:683-692
- [22] Blekher T, Weaver M, Rupp J, Nichols WC, Hui SL, Gray J, et al. Multiple step pattern as a biomarker in Parkinson disease. *Parkinsonism & Related Disorders*. 2009;**15**:506-510
- [23] Terao Y, Fukuda H, Ugawa Y, Hikosaka O. New perspectives on the pathophysiology of Parkinson's disease as assessed by saccade performance: A clinical review. *Clinical Neurophysiology*. 2013;**124**(8):1491-1506
- [24] Pernecky R, Ghosh BC, Hughes L, Carpenter RH, Barker RA, Rowe JB. Saccadic latency in Parkinson's disease correlates with executive function and brain atrophy, but not motor severity. *Neurobiology of Disease*. 2011;**43**:79-85
- [25] van Stockum S, MacAskill MR, Anderson TJ, Dalrymple-Alford JC. Don't look now or look away: Two sources of saccadic disinhibition in Parkinson's disease? *Neuropsychologia*. 2008;**46**:3108-3115
- [26] Antoniadou CA, Demeyere N, Kennard C, et al. Antisaccades and executive dysfunction in early drug-naive Parkinson's disease: The discovery study. *Movement Disorders*. 2015;**30**:843-847
- [27] Pinkhardt EH, Jürgens R, Lulé D, Heimrath J, Ludolph AC, Becker W, et al. Eye movement impairments in Parkinson's disease: Possible role of extradopaminergic mechanisms. *BMC Neurology*. 2012;**12**:2-8
- [28] Hanuska J, Bonnet C, Rusz J, et al. Fast vergence eye movements are disrupted in Parkinson's disease: A video-oculography study. *Parkinsonism & Related Disorders*. 2015;**21**:797-799
- [29] Anderson T, Luxon L, Quinn N, Daniel S, David Marsden C, Bronstein A. Oculomotor function in multiple system atrophy: Clinical and laboratory features in 30 patients. *Movement Disorders*. 2008;**23**:977-984
- [30] Linder J, Wenngren BI, Stenlund H, Forsgren L. Impaired oculomotor function in a community-based patient population with newly diagnosed idiopathic parkinsonism. *Journal of Neurology*. 2012;**259**:1206-1214
- [31] Lee JY, Lee WW, Kim JS, Kim HJ, Kim JK, Jeon BS. Perverted head-shaking and positional downbeat nystagmus in patients with multiple system atrophy. *Movement Disorders*. 2009;**24**:1290-1295
- [32] Williams DR et al. Characteristics of two distinct clinical phenotypes in pathologically proven progressive supranuclear palsy: Richardson's syndrome and PSP-parkinsonism. *Brain*. 2005;**128**:1247-1258
- [33] Ballard C, Gauthier S, Brayne C, Aarsland D, Jones E. Alzheimer's disease. *Lancet*. 2011;**377**:1019-1031
- [34] Jiang T, Yu JT, Tian Y, Tan L. Epidemiology and etiology of Alzheimer's disease: From genetic to non-genetic factors. *Current Alzheimer Research*. 2013;**10**:852-867
- [35] Jones A, Friedland RP, Koss B, Stark L, Thompkins-Ober BA. Saccadic intrusions in Alzheimer-type dementia. *Journal of Neurology*. 1983;**229**:189-194

- [36] Fletcher WA, Sharpe JA. Saccadic eye movement dysfunction in Alzheimer's disease. *Annals of Neurology*. 1986;**20**:464-471
- [37] Kapoula Z, Yang Q, Otero-Millan J, et al. Distinctive features of microsaccades in Alzheimer's disease and in mild cognitive impairment. *Age*. 2014;**36**:535-543
- [38] Bylsma FW, Rasmusson DX, Rebok GW, Keyl PM, Tune L, Brandt J. Changes in visual fixation and saccadic eye movements in Alzheimer's disease. *International Journal of Psychophysiology*. 1995;**19**:33-40
- [39] Parvizi J, Van Hoesen GW, Damasio A. The selective vulnerability of brainstem nuclei to Alzheimer's disease. *Annals of Neurology*. 2001;**49**:53-66
- [40] Garbutt S, Matlin A, Hellmuth J, Schenk AK, Johnson JK, Rosen H, et al. Oculomotor function in frontotemporal lobar degeneration, related disorders and Alzheimer's disease. *Brain*. 2008;**131**:1268-1281
- [41] Shafiq-Antonacci R, Maruff P, Masters C, Currie J. Spectrum of saccade system function in Alzheimer disease. *Archives of Neurology*. 2003;**60**:1272-1278
- [42] Yang Q, Wang T, Su N, Liu Y, Xiao S, Kapoula Z. Long latency and high variability in accuracy-speed of prosaccades in Alzheimer's disease at mild to moderate stage. *Dementia and Geriatric Cognitive Disorders Extra*. 2011;**1**:318-329
- [43] Shakespeare TJ, Kaski D, Yong KX, Paterson RW, Slattery CF, Ryan NS, et al. Brain. Abnormalities of fixation, saccade and pursuit in posterior cortical atrophy. 2015;**138**(Pt 7):1976-1991
- [44] Suarez Gonzalez A, Henley SM, Walton J, Crutch SJ. Posterior cortical atrophy: An atypical variant of Alzheimer disease. *The Psychiatric Clinics of North America*. 2015;**38**:211-220
- [45] Meyniel C, Rivaud-Pechoux S, Damier P, Gaymard B. Saccade impairments in patients with fronto-temporal dementia. *Journal of Neurology, Neurosurgery, and Psychiatry*. 2005;**76**:1581-1584
- [46] Boxer AL, Garbutt S, Seeley WW, Jafari A, Heuer HW, Mirsky J, et al. Saccade abnormalities in autopsy-confirmed frontotemporal lobar degeneration and Alzheimer's disease. *Archives of Neurology*. 2012;**69**:509-517
- [47] Bates GP, Dorsey R, Gusella JF, Hayden MR, Kay C, Leavitt BR, et al. Huntington disease. *Nature Reviews. Disease Primers*. 2015;**1**:15005. DOI: 10.1038/nrdp.2015.5
- [48] Kim SD, Fung VS. An update on Huntington's disease: From the gene to the clinic. *Current Opinion in Neurology*. 2014;**27**:477-483. DOI: 10.1097/WCO.0000000000000116
- [49] Leigh RJ, Newman SA, Folstein SE, Lasker AG, Jensen BA. Abnormal ocular motor control in Huntington's disease. *Neurology*. 1983;**33**:1268-1275
- [50] Lasker AG, Zee DS, Hain TC, Folstein SE, Singer HS. Saccades in Huntington's disease. Slowing and dysmetria. *Neurology*. 1998;**38**:427-431
- [51] Peltsch A, Hoffman A, Armstrong I, Pari G, Munoz DP. Saccadic impairments in Huntington's disease. *Experimental Brain Research*. 2008;**186**:457-469
- [52] Patel SS, Jankovic J, Hood AJ, Jeter CB, Sereno AB. Reflexive and volitional saccades: Biomarkers of Huntington disease severity and progression. *Journal of the Neurological Sciences*. 2012;**203**:35-41

- [53] Vaca-Palomares I, Coea BC, Brien DC, Munoz DP, Fernandez-Ruiz J. Voluntary saccade inhibition deficits correlate with extended white-matter cortico-basal atrophy in Huntington's disease. *NeuroImage: Clinical*. 2017;**15**:502-512
- [54] Blekher T, Johnson SA, Marshall J, White K, Hui S, Weaver M, et al. Saccades in presymptomatic and early stages of Huntington disease. *Neurology*. 2006;**67**:394-399
- [55] Golding CV, Danchaivijitr C, Hodgson TL, Tabrizi SJ, Kennard C. Identification of an oculomotor biomarker of preclinical Huntington disease. *Neurology*. 2006;**67**:485-487
- [56] Antoniadou CA, Altham PM, Mason SL, Barker RA, Carpenter R. Saccadometry: A new tool for evaluating presymptomatic Huntington patients. *Neuroreport*. 2007;**18**:1133-1136
- [57] Kloppel S, Draganski B, Golding CV, Chu C, Nagy Z, Cook PA, et al. White matter connections reflect changes in voluntary-guided saccades in presymptomatic Huntington's disease. *Brain*. 2008;**131**(Pt 1):196-204
- [58] Rupp J, Dziedzic M, Blekher T, West J, Hui S, Wojcieszek J, et al. Comparison of vertical and horizontal saccade measures and their relation to gray matter changes in premanifest and manifest Huntington disease. *Journal of Neurology*. 2012;**259**:267-276
- [59] Winder JY, Roos RA. Premanifest Huntington's disease: Examination of oculomotor abnormalities in clinical practice. *PLoS One*. 2018;**13**:e0193866
- [60] Wijesekera LC, Leigh PN. Amyotrophic lateral sclerosis. *Orphanet Journal of Rare Diseases*. 2009;**4**:3
- [61] Byrne S, Walsh C, Lynch C, et al. Rate of familial amyotrophic lateral sclerosis: A systematic review and meta-analysis. *Journal of Neurology, Neurosurgery, and Psychiatry*. 2011;**82**:623-627
- [62] Andersen PM, Al-Chalabi A. Clinical genetics of amyotrophic lateral sclerosis: What do we really know? *Nature Reviews. Neurology*. 2011;**7**:603-615
- [63] Jacobs L, Bozian D, Heffner RR Jr, Barron SA. An eye movement disorder in amyotrophic lateral sclerosis. *Neurology*. 1981;**31**:1282-1287
- [64] Averbuch-Heller L, Helmchen C, Horn AK, Leigh RJ, Buttner-Ennever JA. Slow vertical saccades in motor neuron disease: Correlation of structure and function. *Annals of Neurology*. 1998;**44**:641-648
- [65] Donaghy C, Pinnock R, Abrahams S, et al. Slow saccades in bulbar-onset motor neurone disease. *Journal of Neurology*. 2010;**257**:1134-1140
- [66] Sharma R, Hicks S, Berna CM, Kennard C, Talbot K, Turner MR. Oculomotor dysfunction in amyotrophic lateral sclerosis. A comprehensive review. *Archives of Neurology*. 2011;**68**:857-861
- [67] Gorges M, Müller HP, Lulé D, Del Tredici K, Pfandl K, Ludolph AC, et al. Eye movement deficits are consistent with a staging model of pTDP-43 pathology in amyotrophic lateral sclerosis. *PLoS One*. 2012;**10**:e0142546
- [68] Hershenson J, Haworth A, Houlden H. The inherited ataxias: Genetic heterogeneity, mutation databases, and future directions in research and clinical diagnostics. *Human Mutation*. 2012;**33**(9):1324-1332
- [69] Mancuso M, Orsucci D, Bonuccelli U. The genetics of ataxia: Through the labyrinth of the minotaur, looking for Ariadne's thread. *Journal of Neurology*. 2014;**261**(Suppl 2):S528-S541

- [70] Ashizawa T, Öz G, Paulson HL. Spinocerebellar ataxias: Prospects and challenges for therapy development. *Nature Reviews Neurology*. 2018;**14**(10):590-605. DOI: 10.1038/s41582-018-0051-6
- [71] Paulson HL, Shakkottai VG, Clark B, Orr HT. Polyglutamine spinocerebellar ataxias—From genes to potential treatments. *Nature Reviews Neuroscience*. 2017;**18**(10):613-626
- [72] Anheim M, Tranchant C, Koenig M. The autosomal recessive cerebellar ataxias. *New England Journal of Medicine*. 2012;**366**:636-646
- [73] Ruano L, Melo C, Silva MC, Coutinho P. The global epidemiology of hereditary ataxia and spastic paraplegia: A systematic review of prevalence studies. *Neuroepidemiology*. 2014;**42**:174-183. DOI: 10.1159/000358801
- [74] Burk K, Fetter M, Abele M, Laccone F, Brice A, Dichgans J, et al. Autosomal dominant cerebellar ataxia type I: Oculomotor abnormalities in families with SCA1, SCA2, and SCA3. *Journal of Neurology*. 1999;**246**:789-797. ISSN 0340-5354
- [75] Rivaud-Pechoux S, Durr A, Gaymard B, Cancel G, Ploner CJ, Agid Y, et al. Eye movement abnormalities correlate with genotype in autosomal dominant cerebellar ataxia type I. *Annals of Neurology*. 1998;**43**:297-302. ISSN 1531-8249
- [76] Buttner JA, Geschwind D, Jen JC, Perlman S, Pulst SM, Baloh RW. Oculomotor phenotypes in autosomal dominant ataxias. *Archives of Neurology*. 1998;**55**:1353-1357. ISSN 1538-3687
- [77] Rodríguez-Labrada R, Velazquez-Perez L. Eye movement abnormalities in spinocerebellar ataxias. In: Gazulla J, editor. *Spinocerebellar Ataxias*. Rijeka: Intech; 2012. pp. 59-76. ISBN 979-953-307-095-6
- [78] Seshagiri DV, Pal P, Jain S, Yadav R. Optokinetic nystagmus in SCA patients: A bedside test for oculomotor dysfunction grading. *Neurology*. 2018;**91**(13):e1255-e1261. DOI: 10.1212/WNL.0000000000006250
- [79] Velazquez-Perez L, Seifried C, Abele M, Wirjatijasa F, Rodriguez-Labrada R, Santos-Falcon N, et al. Saccade velocity is reduced in presymptomatic spinocerebellar ataxia type 2. *Clinical Neurophysiology*. 2009;**120**:632-635. ISSN 1388-2457
- [80] Velazquez-Perez L, Seifried C, Santos-Falcon N, Abele M, Ziemann U, Almaguer LE, et al. Saccade velocity is controlled by polyglutamine size in spinocerebellar ataxia 2. *Annals of Neurology*. 2004;**56**:444-447. ISSN 1531-8249
- [81] Rodríguez-Labrada R, Vázquez-Mojena Y, Canales-Ochoa N, Medrano-Montero J, Velázquez-Pérez L. Heritability of saccadic eye movements in Spinocerebellar ataxia type 2: Insights into an endophenotype marker. *Cerebellum & Ataxias*. 2017;**19**:19
- [82] Rodríguez-Labrada R, Velázquez-Pérez L, Auburger G, Ziemann U, Canales N, Medrano J, et al. Spinocerebellar ataxia type 2: Measures of saccade changes improve power for clinical trials. *Movement Disorders*. 2016;**31**:570-578
- [83] Rodríguez-Labrada R, Velázquez-Pérez L, Seifried C, et al. Saccadic latency is prolonged in spinocerebellar ataxia type 2 and correlates with the frontal-executive dysfunctions. *Journal of the Neurological Sciences*. 2011;**306**:106-107
- [84] Rodríguez-Labrada R, Velázquez-Perez L, Seifried-Oberschmidt C,

Peña-Acosta A, Canales-Ochoa N, Medrano-Montero J, et al. Executive deficit in spinocerebellar ataxia type 2 is related to expanded CAG repeats: Evidence from antisaccadic eye movements. *Brain and Cognition*. 2014;**91**:28-34

[85] Velázquez-Pérez L, Rodríguez-Labrada R, Cruz-Rivas EM, et al. Comprehensive study of early features in spinocerebellar ataxia 2: Delineating the prodromal stage of the disease. *Cerebellum*. 2014;**13**:568-579

[86] Matilla-Dueñas A, Goold R, Giunti P. Clinical, genetic, molecular, and pathophysiological insights into spinocerebellar ataxia type 1. *The Cerebellum*. 2008;**7**:106-114. ISSN 1473-4222

[87] Klostermann W, Zuhlke C, Heide W, Kompf D, Wessel K. Slow saccades and other eye movement disorders in spinocerebellar atrophy type 1. *Journal of Neurology*. 1997;**244**:105-111. ISSN 0340-5354

[88] Jardim LB, Pereira ML, Silveira I, Ferro A, Sequeiros J, Giugliani R. Neurologic findings in Machado-Joseph disease: Relation with disease duration, subtypes, and (CAG)_n. *Archives of Neurology*. 2011;**58**:899-904. ISSN 1538-3687

[89] Ghasia FF, Wilmot G, Ahmed A, Shaikh AG. Strabismus and microopsoclonus in Machado-Joseph disease. *Cerebellum*. 2016;**15**(4):491-497. DOI: 10.1007/s12311-015-0718-0

[90] Wong SH, Patel L, Plant GT. Acquired esotropia in cerebellar disease: A case series illustrating misdiagnosis as isolated lateral rectus palsy and progression over time. *Neuroophthalmology*. 2015;**39**:59-63. DOI: 10.3109/01658107.2014.991832

[91] Colen C, Ketko A, George E, Van Stavern G. Periodic alternating

nystagmus and periodic alternating skew deviation in spinocerebellar ataxia type 6. *Journal of Neuro-Ophthalmology*. 2008;**28**:287-288. ISSN 1536-5166

[92] Kim JM, Lee JY, Kim HJ, Kim JS, Kim YK, Park SS, et al. The wide clinical spectrum and nigrostriatal dopaminergic damage in spinocerebellar ataxia type 6. *Journal of Neurology, Neurosurgery & Psychiatry*. 2010;**81**:529-532. ISSN 1468-330X

[93] Christova P, Anderson JH, Gomez C. Impaired eye movements in presymptomatic spinocerebellar ataxia type 6. *Archives of Neurology*. 2008;**65**:530-536. ISSN 1538-3687

[94] Miller R, Tewari A, Miller J, Garbern J, Van Stavern GP. Neuro-ophthalmologic features of spinocerebellar ataxia type 7. *Journal of Neuro-Ophthalmology*. 2009;**29**:180-186, ISSN 1536-5166

[95] Manrique RK, Noval S, Aguilar-Amat MJ, Arpa J, Rosa I, Contreras I. Ophthalmic features of spinocerebellar ataxia type 7. *Journal of Neuro-Ophthalmology*. 2009;**29**:174-179, ISSN 1536-5166

[96] Oh AK, Jacobson KM, Jen JC, Baloh RW. Slowing of voluntary and involuntary saccades: An early sign in spinocerebellar ataxia type 7. *Annals of Neurology*. 2001;**49**:801-804. ISSN 1531-8249

[97] Hubner J, Sprenger A, Klein C, Hagenah J, Rambold H, Zuhlke C, et al. Eye movement abnormalities in spinocerebellar ataxia type 17 (SCA17). *Neurology*. 2007;**69**:1160-1168. ISSN 0028-3878

[98] Fahey MC, Cremer PD, Aw ST, Millist L, Todd MJ, White OB, et al. Vestibular, saccadic and fixation abnormalities in genetically confirmed Friedreich ataxia. *Brain*. 2008;**131** (Pt 4):35-45

[99] Hocking DR, Fielding J, Corben LA, Cremer PD, Millist L, White OB, et al. Ocular motor fixation deficits in Friedreich ataxia. *Cerebellum*. 2010;**9**(3):411-418

[100] Fielding J, Corben L, Cremer P, Millist L, White O, Delatycki M. Disruption to higher order processes in Friedreich ataxia. *Neuropsychologia*. 2010;**48**:235-242

IntechOpen