

We are IntechOpen, the world's leading publisher of Open Access books Built by scientists, for scientists

4,800

Open access books available

122,000

International authors and editors

135M

Downloads

Our authors are among the

154

Countries delivered to

TOP 1%

most cited scientists

12.2%

Contributors from top 500 universities



WEB OF SCIENCE™

Selection of our books indexed in the Book Citation Index
in Web of Science™ Core Collection (BKCI)

Interested in publishing with us?
Contact book.department@intechopen.com

Numbers displayed above are based on latest data collected.

For more information visit www.intechopen.com



Lateral and Medial Epicondylitis: Definition, Diagnosis, Screening and Treatment Algorithms

Yusuf Erdem and Cagri Neyisci

Abstract

Medial/lateral epicondylitis is related to repetitive work activities which causes loss of labor. It sometimes becomes a chronic painful pathology. The main effect to protect the patients from such pathology should focus on avoiding repetitive patterns of work actually; however, it is not possible generally. Traditional treatment modalities such as physical therapies with the use of epicondylitis bands and intralesional steroid injections should be combined with newer modalities such as prolotherapy and prp injections in the treatment algorithm. In this chapter stages of the disease will be explained and those newer techniques and the mechanism of the healing would be detailed.

Keywords: elbow, tendonitis, forceful, rotation, forearm

1. Introduction

Work-related musculoskeletal disorder is an injury that occurs in the workplace or during the work due to sudden exertion or prolonged use of tendons, muscles, joints and nerves to physical factors such as repetitive movement, force or awkward positions. Shoulder disorders, lateral-medial epicondylitis, wrist tendinitis, and carpal tunnel syndromes in addition to other nonspecific strains, sprains are classified as common upper limb musculoskeletal disorders [1].

Epicondylitis is a common disorder of the arm that happens as a result of resisted use of the flexor and extensor muscles of the wrist. The men and women are affected equally, especially between fourth and fifth decades [2, 3]. Lateral epicondylitis, termed as *tennis elbow*, commonly occur after repeated activities of supination/pronation of the forearm while the elbow in extension, whereas medial epicondylitis, termed as *golfer's elbow*, mostly occur in athletes, tennis players, and workers whose jobs (e.g., carpentry) require similar movements [4–7]. Lateral epicondylitis is seen 5–10 times more than the medial epicondylitis [7, 8].

Treatment starts with conservative management including anti-inflammatory drug administration, physical therapy, rest, and steroid injections with variable long-term success. as soon as the diagnosis is confirmed, On the other hand the novel biological therapies which includes injection of platelet-rich plasma (PRP), collagen-producing tenocyte-like cells, various types of stem cells at the site of the tendon lesion, or prolotherapy are used as the developing treatment strategies [2, 9, 10]. Other treatment options include ultrasonographically guided tenotomy, extracorporeal shock-wave therapy, and iontophoresis and phonophoresis to obtain deep penetration of

topical medications into the soft tissues [11]. Surgery is performed if there is no clinical response after 6–9 months of conservative treatment. Surgical techniques include open and arthroscopic approaches with dissection, release, and debridement of the degenerated and calcified tendons [12]. In our experience, we prefer a mini-open approach which allows a shorter recovery time and early postoperative mobilization therapy.

2. Elbow anatomy

2.1 Lateral elbow and epicondylitis

The extensor carpi radialis brevis, extensor digitorum communis, extensor carpi ulnaris, brachioradialis, extensor digiti minimi, supinator and extensor carpi radialis longus are called the wrist extensors, which allow the hand to move upward and extend. The wrist extensors form a strong conjoined tendon which is attached at the lateral epicondyle and lateral supracondylar ridge [13] (**Figure 1**). Repeated use of these tendons can cause microscopic tears and degeneration at the origin that can result forearm muscle weakness along with swelling and pain at the elbow. The ECRB forms the deep and anterior aspect of this common tendons and slides along capitellum's lateral edge during elbow extension and flexion. This contact and sliding may play a role in the pathophysiology of epicondylitis [4, 8, 14]. The essential lesion of lateral epicondylitis involves the ECRB mostly, followed by the extensor digitorum communis and to a lesser extent, other muscles and tendons of the lateral compartment. Capsular injury, thickening and tearing of the lateral ulnar collateral ligament (LUCL) and radial collateral ligament (RCL) have been also identified as another cause of lateral epicondylitis [14].

The lateral collateral ligament complex consists of the RCL, annular ligament, accessory lateral collateral ligament, and LUCL (**Figure 2**). Moreover, the LUCL runs along the lateral and posterior aspects of the radius to insert on the tubercle of the supinator crest of the ulna and disruption of which results in posterolateral rotatory instability of the elbow [14].

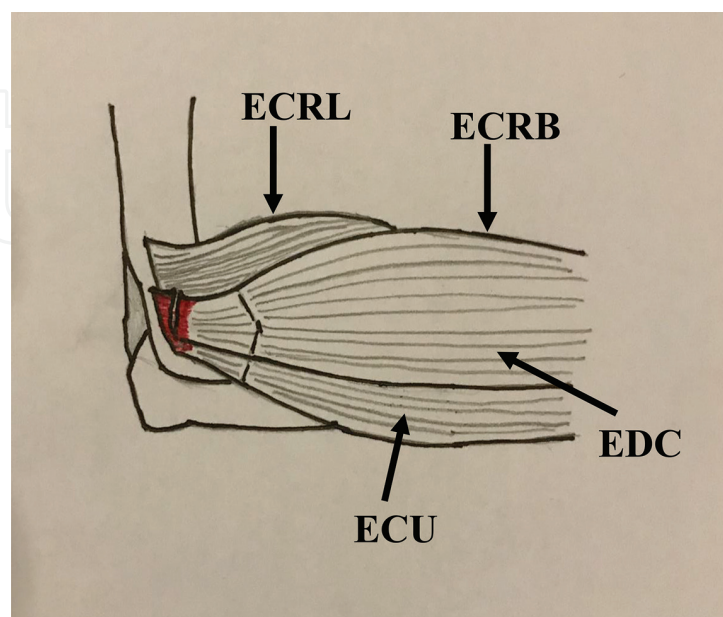


Figure 1.

Illustration shows the lateral elbow musculotendinous anatomy, close to the site of the tendon origin on the lateral epicondyle. ECRB = extensor carpi radialis brevis, CET = common extensor tendon, ECU = extensor carpi ulnaris, ECRL = extensor carpi radialis longus, and EDC = extensor digitorum communis [8].

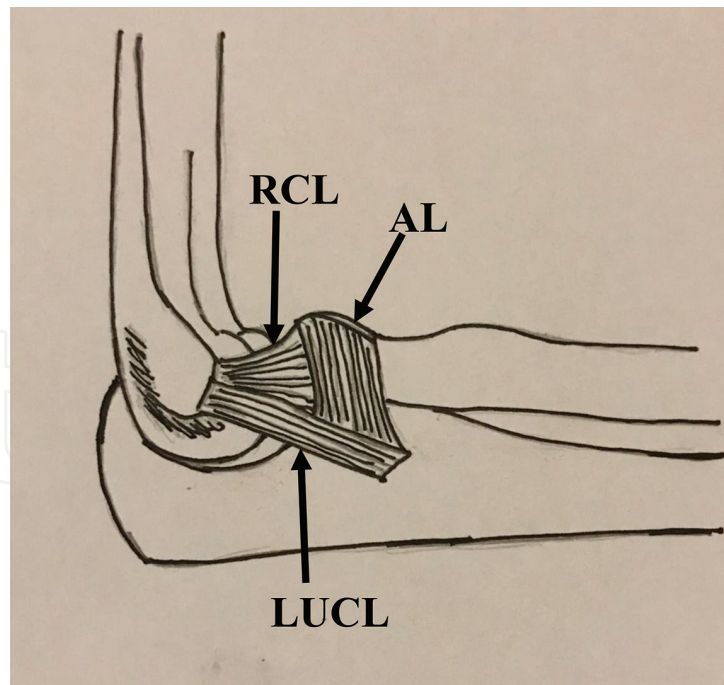


Figure 2.
Illustration shows the ligamentous anatomy of the lateral aspect of the elbow. AL = annular ligament, LUCL = lateral ulnar collateral ligament, and RCL = radial collateral ligament [8].

2.1.1 Etiology and pathophysiology

Lateral epicondylitis most commonly occurs between the ages of 30–50 years old. This pathology is caused by chronic stress to the forearm muscles with the repetitive activities of gripping and wrist extension. The most common movement that results with epicondylitis is radial deviation, extension of wrist, and forearm supination [15]. Many individuals develop lateral epicondylitis for no identifiable reason; however, poor mechanics or technique may be a reason in athletes.

As it is mentioned above, this condition is an overuse degenerative process of tendons of external carpi radialis brevis and extensor digitorum communis primarily. Beside clinical symptom of prolonged pain at the elbow, histological findings are granulation tissue, micro-rupture, an abundance of fibroblasts, vascular hyperplasia, unstructured collagen, and notably a lack of traditional inflammatory cells (macrophages, lymphocytes, neutrophils) within the tissue. In ultrasonographic evaluation calcifications, intrasubstance tears, thickening and heterogeneity of the common extensor tendon is mostly revealed [5, 15].

2.1.2 Physical examination

Provocative testing is done by performing the Cozen's test which is also known as resisted wrist extension test. During this test, the patient's elbow is stabilized in 90° of flexion by the examiner's thumb, while palpating over the patient's lateral epicondyle. The patient is then asked to make a fist, pronate the forearm, and radially deviate and extend the wrist while the manual resistance of the examiner. The test is considered positive if the test produces pain or reproductive of other symptoms in the area of the lateral epicondyle. Tenderness is usually seen over 5 mm. distal and anterior to the lateral epicondyle [15].

Mill's test is an alternative to Cozen's test, where the patient is asked to close the hand, with the wrist in dorsiflexion and the elbow extended. During the test, the wrist is forced into flexion, while palpating over the lateral epicondyle. The patient

denies to do any motion, if he/she feels any pain on lateral epicondyle, and the test is considered positive [16].

On the other hand, the differential diagnosis is broad (**Table 1**), and imaging is often necessary when refractory or confounding symptoms are present. In a report, 5% reason of lateral epicondylitis is related with radial tunnel syndrome [17].

2.1.3 Diagnostic testing

Imaging of lateral epicondylitis not only confirms the clinical suspicion but also allows assessment of the injury severity and location. Multiple modalities such as magnetic resonance imaging (MRI), computed tomographic (CT) imaging, ultrasonography and EMG have been described following initial elbow radiography.

An initial x-ray evaluation should be taken in three views: anterior-posterior (AP), lateral, and lateral oblique view. The AP graphy is performed with the elbow fully extended, palm of the hand pointing upward (exorotation) and forearm supinated to display medial and lateral epicondyles as well as radiocapitellar and ulnotrochlear articular surfaces. The lateral view should be obtained with the hand is turned vertically, elbow in 90° of flexion, palm of the hand pointing toward patient and forearm in neutral position. Articulation between the distal humerus and proximal forearm is seen on these X-rays. Moreover the lateral oblique view is similar to the AP view, however the hand and forearm are fully externally rotated to obtain the views of the radiocapitellar joint, medial epicondyle, radioulnar joint and coronoid process.

X-rays can be helpful in evaluating bony structures' pathology, such as osteophyte formation secondary to arthritis, as well as calcifications that may be present in tendon or muscle tissues as a result of injury. Radiographic evaluations show normal results in most cases, and are mainly useful for ruling out other abnormalities such as arthrosis, osteochondritis dissecans and intra-articular free bodies. When X-ray is inconclusive, further studies such as MRI, ultrasound, or CT scan may be ordered.

Sonography is an inexpensive, accessible and radiation-free test. Moreover high-frequency probes has an advantages of improved resolution, allowing application to extraarticular soft tissues for which it is increasingly used as an alternative to MRI [18]. Additionally, dynamic imaging can be performed in flexion/extension, supination/pronation, or under valgus/varus stress. Dynamic sonography is also an ideal method of image-guided intervention and can be used to provide real-time guidance of injections of local anesthetic, steroids, or platelet-rich plasma. However, its value is debatable because it is examiner-dependent.

In many cases MRI can be useful in evaluating the soft tissues for tears, fluid, inflammation, or other changes within the joint or surrounding tissues. It is a great tool to evaluate soft tissue damage due to chronic overuse injuries of the elbow. However the bony cortex is not as well evaluated at MR imaging compared with CT, but the ability to detect subtle signal intensity changes in the marrow and periosteal soft tissues increases sensitivity to early stress changes in bone. Patients positioning

Posterolateral rotatory instability, LUCL injury
Osteochondritis dissecans of the capitellum
Occult fracture
Radial tunnel syndrome
Osteoarthrosis

Table 1.
Differential diagnosis of lateral elbow pain.

can be either prone or supine, with the arm held at the side in anatomical position. Initial evaluation includes the assessment of the radiocapitellar, ulnohumeral and radioulnar articulations of the elbow. The following examination steps are tendons, muscles, ligaments, and the three major nerves of the elbow [19, 20].

CT imaging is particularly useful in demonstrating intraarticular extension of fractures, the distribution of small fracture fragments within and adjacent to the joint space, as well as any associated bony malalignment. CT can also be useful in evaluating chronic pain following injury and can readily identify abnormal ossifications or calcifications which can be seen as a sequela of trauma, including osteochondral bodies, heterotopic ossification, or myositis ossificans. Intraarticular contrast material can be injected for improved visualization of joint bodies and cartilage. Osseous manifestations of secondary degenerative change are also well evaluated with CT. Less often, CT arthrography is performed for evaluation of ligamentous integrity in patients with contraindications to MR imaging [18].

Aside from imaging, many elbow pain cases will require an electromyography/ nerve conduction study to investigate the function of forearm muscle in healthy and diseased. This test consists of two parts, and utilizes needle EMG to test the muscles in the extremity. It may be helpful in nerve compressive processes. The needle EMG may reveal the differentiation between denervation versus nerve injury or compression [21]. However future diagnosing studies are essential for this test.

In case of significant swelling or fever, blood work should be indicated whether the reason is systemic inflammation or not. This would help direct the treatment toward a systemic, rheumatologic, or infectious etiology [21, 22].

2.2 Medial elbow and epicondylitis

The medial epicondyle is the common origin of the flexor and pronator muscles of the forearm. Five muscles (flexor carpi radialis, palmaris longus, flexor carpi ulnaris, flexor digitorum superficialis and pronator teres) share the same origin and form the conjoined flexor tendons (**Figure 3**) [7]. The MCL, or known as ulnar collateral ligament, is formed by anterior, posterior, and oblique bands, which creates a triangular shape along the medial aspect of the elbow, deep to the pronator mass

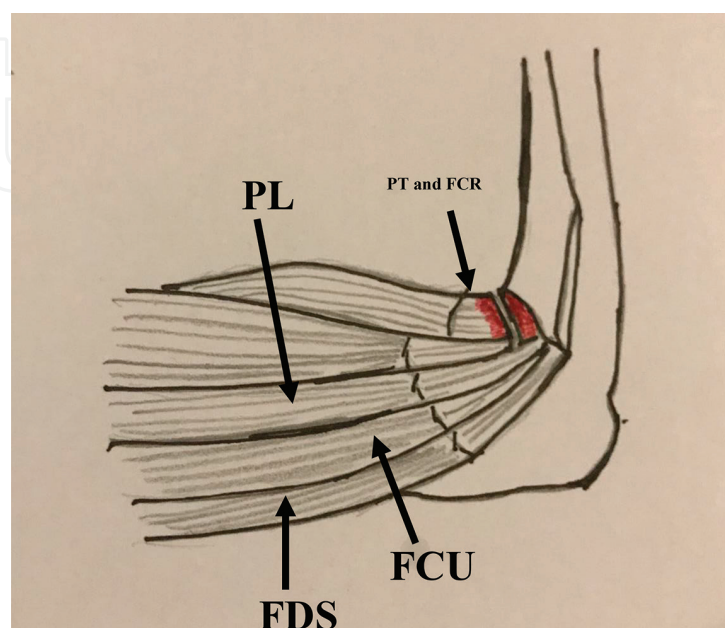


Figure 3. Illustration shows the medial elbow musculotendinous anatomy. FCU = flexor carpi ulnaris, FCR = flexor carpi radialis, FDS = flexor digitorum superficialis, PT = pronator teres, and PL = palmaris longus [8].

(**Figure 4**). MCL injury, specifically anterior band injury, is included in the differential diagnosis of medial elbow pain, and therefore the MCL must be evaluated. The MCL is also prone to concurrent injury with medial epicondylitis.

Medial epicondylitis is a tendinopathy of conjoined tendon due to overload or overuse. This pathology is also called golfer's elbow which mostly develops as a result of high energy valgus forces in athletes. However 90% of cases are not sports-related.

2.2.1 Physical examination

Patients with medial epicondylitis typically present with medial elbow pain, which often develops due to repetitive elbow use, gripping, or valgus stress. The pain is worse with forearm motion, hand gripping and throwing. It usually resolves with cessation of activity [4, 7, 23]. On physical examination, there may be tenderness, swelling, erythema or warmth. The tenderness is elicited by palpation over the 5–10 mm distal and anterior to the medial epicondyle [4].

Medial epicondylitis test involves an active and passive component where the pain is exacerbated by resisted wrist flexion and forearm pronation at an angle of 90° [7]. Test is positive when the patient endorses pain with this maneuver. Due to similar symptoms and associated valgus forces, C6–C7 radiculopathies, cubital tunnel syndrome, ulnar neuritis, anterior interosseous nerve entrapment, tardy ulnar palsy and MCL instability, as well as other causes of medial elbow pain (capsulitis, arthrofibrosis, loose bodies, or medial epicondyle avulsion fracture) should be considered in the differential diagnosis (**Table 2**). The Tinel sign (distal pain and tingling during direct compression of the nerve at the elbow) should be used to evaluate for ulnar neuropathy, and the ulnar collateral ligament should be stressed especially in athletes [23]. The elbow valgus stress test is used to assess the integrity of the medial collateral ligament by palpating the medial joint line and stabilizing the distal humerus in 20 degrees of elbow flexion, [23]. The tests are considered positive if the patient experiences pain or excessive laxity along the MCL compared to the contralateral side.

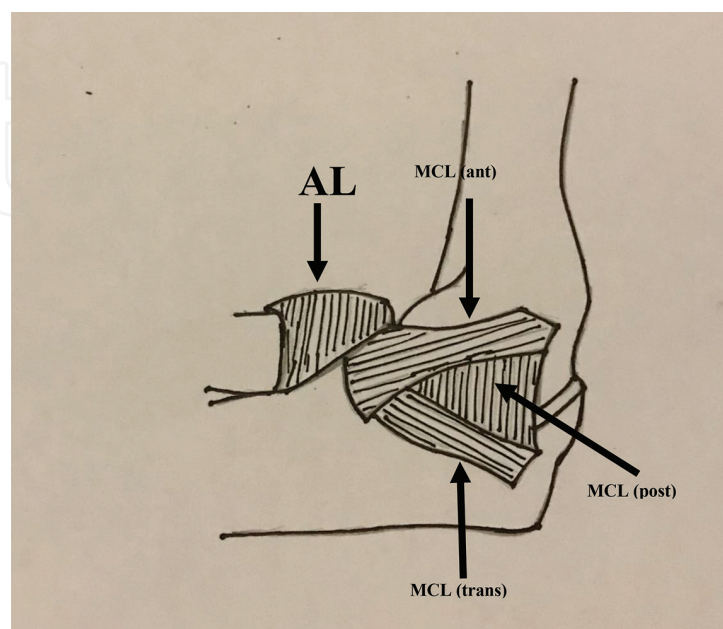


Figure 4. Picture shows the ligamentous anatomy of the medial aspect of the elbow. AL = annular ligament, ant = anterior band, and post = posterior band [8].

MCL Injury
Little League Elbow
Osteochondritis dissecans (OCD)
Ulnar neuropathy (ulnar neuritis, entrapment)
Flexor-pronator strain
Occult fracture

Table 2.
Differential diagnosis of medial elbow pain.

2.2.2 Etiology and pathophysiology

Medial epicondylitis is generally considered to start as a microtear due to chronic stress which is related with repetitive concentric or eccentric loading of the wrist flexors and pronator teres, resulting angiofibroblastic changes. Angiofibroblastic changes include mucoid degeneration of the tendinous origin and formation of reactive granulation tissue [24]. As a result focal necrosis or calcification can occur with decreasing collagen strength, scar tissue formation, and thickening of the tendons. Though it was thought that the pronator teres and flexor carpi radialis were most commonly affected, the studies suggest that all muscles except palmaris longus are affected equally [20].

Though the conservative treatment is a common intervention for the treatment, surgical treatment is applied to remove the pathologic tissues around these origins (the common flexor origin) to eliminate pain generators and decompression to promote tissue regeneration in chronic pathology.

2.2.3 Diagnostic testing

As in lateral epicondylitis, imaging is not always essential in the initial evaluation of medial epicondylitis. Radiographs are most useful to rule out other causes of elbow pain and usually normal in this pathology. Especially, in children where the diagnosis is uncertain, comparison to the unaffected arm may be necessary.

Sonography is also a quick, easy and cost-effective modality to evaluate tendon pathology and distinguish from other etiologies. Moreover dynamic evaluation can be done in areas of chronic degeneration.

MRI is the ideal diagnostic imaging modality in medial epicondylitis and rule out other possible causes of elbow pain like MCL strain, osteochondritis dissecans, or other soft tissue injuries.

Computed tomography, electromyogram and bone scan may be useful in refractory cases to rule out other etiologies as well [23].

2.2.4 Treatment

Once the diagnosis is clear, offending activities including decreasing the volume, frequency, or intensity should be cascaded. Beside, patients may respond to non-steroidal anti-inflammatory drugs and acetaminophen as an initial step. Also topical nitroglycerin patches have proven helpful in the treatment of tendinopathies. Most cases of epicondylitis are managed conservatively. Though medial epicondylitis is less common compared to lateral epicondylitis, the treatment is more difficult.

The primary goal of the first step of treatment includes pain and inflammation relief. Modification of life style is important. Physical therapy takes a great role for the management of treatment simultaneously. Multiple physical therapy

modalities including dry needling, extracorporeal shock wave therapy, iontophoresis, electrical stimulation and ultrasonography takes great role to overcome this pathology [25–28]. Theoretically, eccentric strengthening efficiently induces hypertrophy of the musculotendinous unit and increases its tensile strength, thereby reducing strain of the tendon. Therapy was more effective than rest and restriction of activities.

Counterforce bracing (forearm bands) inhibits full muscular expansion and decreases the force on the muscular tissue proximal to the brace. Night splinting with a cock up wrist splint and elbow kinesio taping may be helpful. In case of non-compliance or when these treatment modalities are not available injections are used. Currently corticosteroids (especially betamethasone sodium phosphate and dipropionate) and local anesthetic mixture is the most common, however recent studies have shown a new group of injectable substances such as botulinum toxin, autologous blood, platelet-rich plasma, hyaluronic acid and prolotherapy are being utilized [29]. Recent studies have shown that Visual Analog Scale (VAS) pain scores and functional scores during the first 2–6 weeks (acute period) have improved after the injections mentioned above [2]. However the dose and frequency of the corticosteroids or others is still controversial. Moreover the corticosteroid injection may result with local skin atrophy, depigmentation and muscle wasting [2].

Botulinum toxin A have been shown as an off-label treatment and have some literature support in refractory cases. It has also has the ability to cause a partial paralysis of the wrist flexors and extensors and allow the pathologic tissue to heal while avoiding micro trauma to the tendon. In a study, 60 patients who received a blinded injection of botulinum toxin or placebo have been evaluated with results of significant lower VAS pain scores at 4 and 12 weeks in the botulinum toxin group. On the other hand the major adverse effect seen with botulinum toxin injection is finger and wrist extensor weakness [30].

Autologous blood injection has been described by Edwards and Calandruccio [31]. Autologous platelet-rich plasma (PRP) have been shown to reduce pain and improve function in refractory epicondylitis [31]. Mishra and Pavelko reported significantly better VAS and functional scores at 8-week period compared to placebo [32]. In conclusion, the effect of remaining injection modalities, which are known as PRP and autologous whole blood, are about the chronic cases with a persistent efficacy during long term follow up. At the end hyaluronic acid and prolotherapy injections have also been studied for epicondylitis have been found to be effective in refractory cases however the mechanism is not well known [33, 34].

Surgical indications for medial and lateral epicondylitis include persistent pain and weakness of the forearm that persists after a period of at least 6 months of conservative care, however it is usually not needed. These surgeries involve release of the common flexor and extensor tendon at the epicondyle and debridement of pathologic tissue. The mini-open muscle resection involves removal of degenerative tissue of the flexor carpi radialis. Fascial elevation and tendon origin resection is another available technique [34]. The prognosis for recovery is very good with relief of pain, but often results in weakness of the forearm musculature [33].

3. Discussion

Medial and lateral epicondylitis is a chronic inflammation disease which results in loss of labor. Moreover these pathologies are related with other upper extremity abnormalities most of which are accompanied with cervical disc pathologies. Physician should be aware of other conditions which led to or mimics epicondylitis.

The patients' social status and job should be questioned at first intervention, thus the treatment varies depending on the situation. If a pure epicondylitis is diagnosed the treatment algorithm is defined above beginning conservatively at first to surgery at last. The aim of the treatment is directed to return to activity as well.

IntechOpen

Author details


Yusuf Erdem^{1*} and Cagri Neyisci²

1 Gulhane Training and Research Hospital, Ankara, Turkey

2 Gulhane Training and Research Hospital, Department of Orthopaedic Surgery, Ankara, Turkey

*Address all correspondence to: yerdem81@gmail.com

IntechOpen

© 2019 The Author(s). Licensee IntechOpen. This chapter is distributed under the terms of the Creative Commons Attribution License (<http://creativecommons.org/licenses/by/3.0>), which permits unrestricted use, distribution, and reproduction in any medium, provided the original work is properly cited. 

References

- [1] Bepko J, Mansalis K. Common occupational disorders: Asthma, COPD, dermatitis, and musculoskeletal disorders. *American Family Physician*. 2016;**93**(12):1000-1006
- [2] Tarpada SP, Morris MT, Lian J, Rashidi S. Current advances in the treatment of medial and lateral epicondylitis. *Journal of Orthopaedics*. 2018;**15**(1):107-110
- [3] Shiri R, Viikari-Juntura E, Varonen H, Heliövaara M. Prevalence and determinants of lateral and medial epicondylitis: A population study. *American Journal of Epidemiology*. 2006;**164**(11):1065-1074
- [4] Bernard FM, Regan WD. Elbow and forearm. In: DeLee JC, editor. *DeLee and Drez's Orthopaedic Sports Medicine*. 2nd ed. Philadelphia, PA: Saunders; 2003
- [5] Nirschl RP, Pettrone FA. Lateral and medial epicondylitis. In: Morrey BF, editor. *Master Techniques in Orthopedic Surgery: The Elbow*. New York, NY: Raven; 1994. pp. 537-552
- [6] Coonrad RW, Hooper WR. Tennis elbow: Its course, natural history, conservative and surgical management. *The Journal of Bone and Joint Surgery. American Volume*. 1973;**55**:1177-1182
- [7] Ciccotti MC, Schwartz MA, Ciccotti MG. Diagnosis and treatment of medial epicondylitis of the elbow. *Clinics in Sports Medicine*. 2004;**23**:693-705
- [8] Walz DM, Newman JS, Konin GP, Ross G. Epicondylitis: Pathogenesis, imaging, and treatment. *RadioGraphics*. 2010;**30**(1):167-184
- [9] Ikpe S, Lesniak B. Biologics and cell-based treatments for upper extremity injuries. *Operative Techniques in Orthopaedics*. 2016;**26**(3):177-181
- [10] Connell D, Datir A, Alyas F, Curtis M. Treatment of lateral epicondylitis using skin-derived tenocyte-like cells. *British Journal of Sports Medicine*. 2009;**43**(4):293-298
- [11] Faro F, Wolf JM. Lateral epicondylitis: Review and current concepts. *The Journal of Hand Surgery*. 2007;**32**:1271-1279
- [12] Cohen MS, Romeo AA, Hennigan SP, Gordon M. Lateral epicondylitis: Anatomic relationship of the extensor tendon origins and implications for arthroscopic treatment. *Journal of Shoulder and Elbow Surgery*. 2008;**17**:954-960
- [13] Blease S, Stoller DW, Safran MR, Li AE, Fritz RC. The elbow. In: Stoller DW, editor. *Magnetic Resonance Imaging in Orthopaedics and Sports Medicine*. 3rd ed. Philadelphia, PA: Lippincott, Williams & Wilkins; 2007. pp. 1463-1626
- [14] Bunata RE, Brown DS, Capelo R. Anatomic factors related to the cause of tennis elbow. *The Journal of Bone and Joint Surgery. American Volume*. 2007;**89**:1955-1963
- [15] Smidt N, Lewis M, Van Der Windt DA, Hay EM, Bouter LM, Croft P. Lateral epicondylitis in general practice: Course and prognostic indicators of outcome. *The Journal of Rheumatology*. 2006;**33**(10):2053-2059
- [16] Filho M, Cotovelo GR. In: Barros Filho TEP, Lech O, editors. *Exame Físico em Ortopedia*. São Paulo: Sarvier; 2001. pp. 138-156

- [17] Ferdinand BD, Rosenberg ZS, Schweitzer ME, et al. MR imaging features of radial tunnel syndrome: Initial experience. *Radiology*. 2006;**240**:161-168
- [18] Potter HG. Imaging of posttraumatic and soft tissue dysfunction of the elbow. *Clinical Orthopaedics*. 2000;**370**:9-18
- [19] Hoffman AD, Graviss ER. Imaging of the pediatric elbow. In: *The Elbow and its Disorders*. Philadelphia, PA: Saunders; 2000. pp. 155-163
- [20] Srinath CS, Srihari S, Miriam B. Magnetic resonance imaging of the elbow: A structured approach. *Sports Health*. 2013;**5**(1):34-49
- [21] Braddom RL, Chan L, Harrast MA, Kowalske KJ, Matthews DJ, Ragnarsson KT, et al. *Physical Medicine and Rehabilitation*. 4th ed. Philadelphia: Saunders; pp. 825-838
- [22] Bonica JJ. In: Fishman S, Ballantyne J, Rathmell JP, editors. *Bonica's Management of Pain*. Philadelphia: Lippincott Williams & Wilkins; 2010. pp. 1034-1028
- [23] Han SH, Lee JK, Kim HJ, Lee SH, Kim JW, Kim TS. The result of surgical treatment of medial epicondylitis: Analysis with more than a 5-year follow-up. *Journal of Shoulder and Elbow Surgery*. 2016;**25**(10):1704-1709
- [24] Goran R, Violeta Vm Mihaela M, Rodina N, Tzvetanka P, Francesco P, Annamaria I. Ultrasound assessment of the elbow. *Medical Ultrasonography*. 2012;**14**(2):141-146
- [25] Labelle H, Guibert R. "Efficacy of Diclofenac in lateral epicondylitis of the elbow also treated with immobilization." *The University of Montreal Orthopaedic Research Group. Archives of Family Medicine*. 1997;**6**:257-262
- [26] Burnham R, Gregg R, Healy P, Steadward R. The effectiveness of topical Diclofenac for lateral epicondylitis. *Clinical Journal of Sport Medicine*. 1998;**8**:78-81
- [27] Bisset L, Paungmali A, Vincenzino B, Beller E. A systematic review and meta analysis of clinical trials on physical interventions for lateral epicondylalgia. *British Journal of Sports Medicine*. 2005;**39**:411-422
- [28] Pettrone FA, McCall BR. Extracorporeal shock wave therapy without local anesthesia for chronic lateral epicondylitis. *The Journal of Bone and Joint Surgery. American Volume*. 2005;**87**:1297-1304
- [29] Groppe JL, Nirschl RP. A mechanical and electromyographical analysis of the effects of various joint counterforce braces on the tennis player. *The American Journal of Sports Medicine*. 1986;**14**:195-200
- [30] Sm W, Hui AC, Tong PY, Poon DW, Yu E, Wong LK. Treatment of lateral epicondylitis with botulinum toxin: A randomized, double-blind, placebo-controlled trial. *Annals of Internal Medicine*. 2005;**143**(1):793-797
- [31] Edwards SG, Calandruccio JH. Autologous blood injections for refractory lateral epicondylitis. *The Journal of Hand Surgery*. 2003 Mar;**28**(2):272-278
- [32] Mishra A, Pavelko T. Treatment of chronic elbow tendinosis with buffered platelet-rich plasma. *The American Journal of Sports Medicine*. 2006;**34**:1774-1778
- [33] Degen RM, Cancienne JM, Camp CL, Altchek DW, Dines JS, Werner BC. Patient-related risk factors for

requiring surgical intervention following a failed injection for the treatment of medial and lateral epicondylitis. *The Physician and Sportsmedicine*. 2017;**45**(4):433-437

[34] Raeissadat SA, Ranyegani SM, Hassanabadi H, Rahimi R, Sedighipour L, Rostami K. Is platelet-rich plasma superior to whole blood in the management of chronic tennis elbow: One year randomized clinical trial. *BMC Sports Science, Medicine and Rehabilitation*. 2014;**6**(1):12

IntechOpen