

# We are IntechOpen, the world's leading publisher of Open Access books Built by scientists, for scientists

**4,800**

Open access books available

**122,000**

International authors and editors

**135M**

Downloads

Our authors are among the

**154**

Countries delivered to

**TOP 1%**

most cited scientists

**12.2%**

Contributors from top 500 universities



**WEB OF SCIENCE™**

Selection of our books indexed in the Book Citation Index  
in Web of Science™ Core Collection (BKCI)

Interested in publishing with us?  
Contact [book.department@intechopen.com](mailto:book.department@intechopen.com)

Numbers displayed above are based on latest data collected.

For more information visit [www.intechopen.com](http://www.intechopen.com)



# Video-Assisted Thoracoscopy in the Management of Primary and Secondary Pneumothorax

*Kostantinos Poulidakis, Lee Gerson, John Costello  
and Wickii T. Vigneswaran*

## Abstract

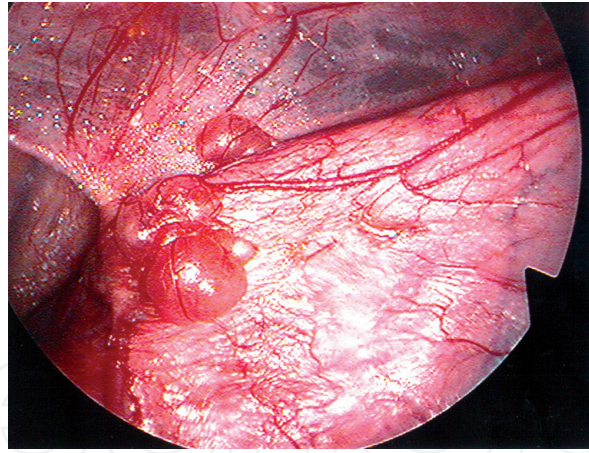
The management of primary and secondary spontaneous pneumothorax can have many variations depending on the surgeons and their expertise of practice. The end goal is to stop the recurrence. The history of treatment, clinical indications for surgery, and preoperative and postoperative decision-making for intervention are summarized. Surgical intervention plays an important role in the management of recurrent pneumothorax and complex initial pneumothorax. Over the years the surgical techniques have evolved, and currently, video-assisted thoracoscopic techniques are frequently used in the management. In this concise report, we attempt to analyze the surgical techniques currently in use and their outcomes. Furthermore, we attempt to integrate future innovations in the management of this common disorder.

**Keywords:** pneumothorax, video-assisted thoracoscopy, pleurodesis, thoracotomy

## 1. Background

Pneumothorax is a diverse entity with a wide array of clinical etiologies. It is more common in men than women [1–4]. Although pneumothorax can be defined simply as an abnormal collection of air in the pleural space, in order to accurately classify pneumothorax, it is helpful to group it broadly as either spontaneous or traumatic in nature [1, 2]. Overall, traumatic causes of pneumothorax account for greater than 50% of pneumothoraces on an annual basis [3]. These include injuries due to either true penetration or blunt traumatic events, including gunshot wounds, stabbings, blunt force trauma to the chest, or iatrogenic traumas sustained as part of medical procedures, such as central venous catheter placement, needle biopsies, and thoracentesis. Outside of trauma, the remainders of pneumothoraces are classified as spontaneous in nature. Although spontaneous pneumothorax accounts for less than half of all pneumothoraces, this type of pneumothorax is often the one that most demands the ongoing attention of the thoracic surgeon in the acute setting.

Spontaneous pneumothorax is itself classified into primary and secondary etiologies. Primary spontaneous pneumothorax is any pneumothorax that occurs without any identifiable inciting event in a patient without any known lung disease. Secondary spontaneous pneumothorax, on the other hand, defines any pneumothorax that develops in a patient as a complication of known underlying lung disease. Many diseases of the lung parenchyma can cause clinical pneumothorax; those



**Figure 1.**  
*Subpleural blebs of the apical lung with adhesion to the chest wall.*

most commonly associated with its development include necrotizing pneumonias, cystic fibrosis, chronic obstructive pulmonary disease, and malignancy. Chronic obstructive pulmonary disease is the cause of 50–70% of all secondary spontaneous pneumothoraces. Catamenial pneumothorax is a very interesting clinical entity that is another, although rare, type of secondary spontaneous pneumothorax.

It is important to note that despite the definition of primary spontaneous pneumothorax indicating that it occurs in the setting of patients with no known lung disease, this is not completely clinically accurate. The majority of these patients do in fact have underlying lung disease with subpleural blebs (**Figure 1**), and it is the spontaneous rupture of these blebs that leads to the development of their pneumothoraces [3]. Despite a wide array of potential clinical etiologies, the overall incidence of spontaneous pneumothorax has been estimated at 17–24/100,000 in males and 1–6/100,000 in the female population [1–3]. Smoking increases the risk of contracting a first pneumothorax approximately 9-fold among women and 22-fold among men [5]. Spontaneous pneumothorax recurrence rates were similar for both men and women, with approximately 26% of patients experiencing a recurrence within 5 years of initial pneumothorax diagnosis [6].

## **2. History**

The management of pneumothorax has seen large advancements over the past few decades. Surgical management of the disease did not begin until the 1940s when it was first documented by Tyson and Crandall in 1941 [7]. Treatment at that time involved a traditional transaxillary thoracotomy with resection of blebs. Later addition of pleurectomy or pleurodesis became routine in these patients. In the early 1990s, with the introduction of video-assisted thoracoscopy and mechanical stapling, minimally invasive chest surgery began to become popular for a variety of indications [8]. As a matter of fact, video-assisted thoracoscopic surgery (VATS) was first documented for pneumothorax [9]. Subsequently, VATS blebectomy, with the addition of pleurodesis or pleurectomy, began to take on popularity and remains often the choice of many. It was also demonstrated that VATS is superior to conservative treatment soon after [10].

## **3. Indications**

Failure of conservative management and recurrence of pneumothorax are the most frequent indications for surgical intervention. In spontaneous pneumothorax,

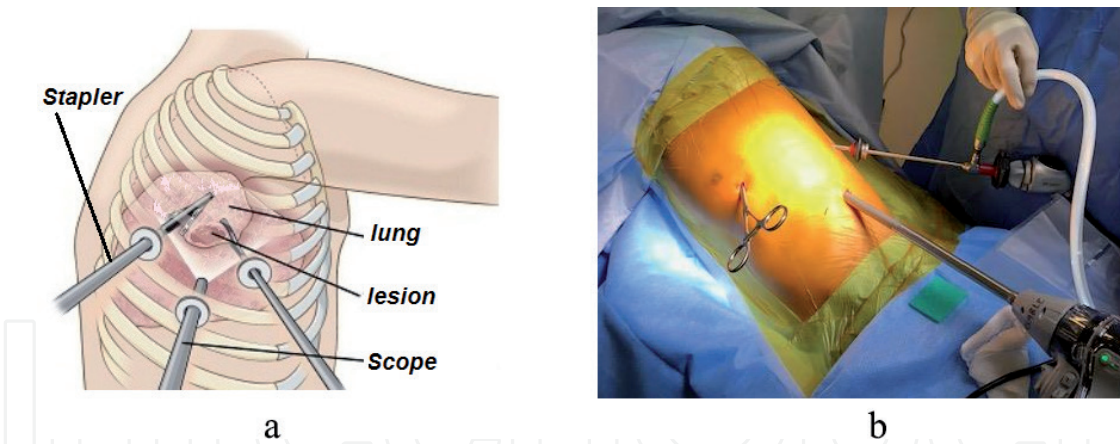
a large number of first episodes will be treated conservatively with non-operative intervention. Asymptomatic, small pneumothorax (less than 2 cm) can typically be observed with serial imaging. Larger symptomatic episodes need to be treated by drainage with needle decompression or with a chest tube. However, when the first episode is complicated and the pneumothoraces are unlikely to resolve using conservative management, surgical intervention may be necessary. These pneumothoraces include those complicated by hemothorax, bilaterality, persistent air leaks, or the inability of the lung to re-expand with conservative treatment [11–13].

#### 4. Management

Recurrence rates for primary and secondary pneumothorax, when the initial episode was treated with chest tube drainage, have been reported as high as 18% in primary and 40% in secondary pneumothoraces [13]. Review of inpatient-treated pneumothorax demonstrated approximately 75% of recurrent pneumothoraces, which occurred in the first year following the initial pneumothorax. The probability of recurrence varied, depending on age group and the presence of underlying lung disease. For example, male patients aged 15–34 years, with underlying chronic lung disorders, had the highest probability of recurrent pneumothorax within 5 years of initial pneumothorax (39.2% recurrence rate) [6]. Some centers have reported being aggressive with first episode pneumothorax by treating these first episodes with VATS, significantly decreasing the recurrence rate in these patients [13]. In the past, open thoracotomy was the mainstay of surgical treatment for spontaneous pneumothorax, but with the institution of video-assisted thoracoscopic treatments, the number of surgeons performing open cases has decreased significantly. The objective of each operation is to prevent recurrence by resecting apical bullae or other causative blebs and perform a pleurodesis so future pneumothoraces are unlikely [14]. With the heavy adoption of VATS, studies have attempted to identify differences in results and morbidity between the VATS and open thoracotomy techniques. VATS intervention was found to have recurrences in 3.8% compared to 1.8% in thoracotomy patients [15]. One meta-analysis, analyzing 4 randomized and 25 nonrandomized trials, assessed the recurrence rates of minimally invasive approach versus open [16]. It was stated that despite a fourfold increase recurrence rate for minimally invasive approach, this method was used three times more commonly than open in the United Kingdom [16]. Importantly however, the complication rates and pain can be significantly higher with thoracotomy than VATS, advocating a minimally invasive approach [15–17]. Some attribute the increased recurrence rate associated with VATS to the decreased amount of adhesions created with the smaller incisions than thoracotomy [17]. The decision as to the appropriate approach for these operations should involve a discussion with the patient for an informed decision, taking into consideration the balance between recurrence against decreased pain and recovery time.

The technical approach to VATS treatment of spontaneous pneumothorax involves patients undergoing general anesthesia with one-lung ventilation. The first incision is typically placed in the fifth or sixth interspace in the midaxillary line. Two additional incisions can typically be made in the fourth interspace in the anterior axillary line, as well as the fifth interspace in the auscultatory triangle [18]. There have been modifications to this strategy over the years, with variations in the number of incisions ranging to as low as one incision (**Figure 2**). Novel new methods are also being discussed such as a subxiphoid uniport incision [19]. This type of incision is currently being studied to assess for a decrease in the amount of intercostal nerve injury that is typically observed with intercostal incisions.

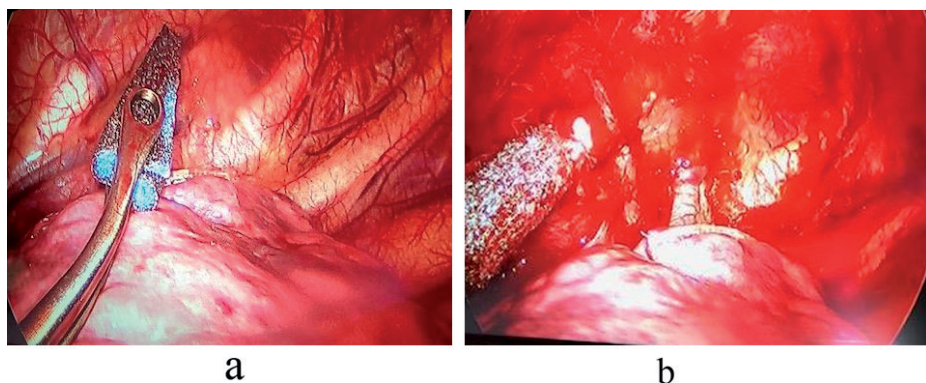




**Figure 2.** Port placements for the classical three-port video-assisted thoracoscopic surgery. Different configurations, change according to the visual and staple requirements (a) camera through central port (b) Camera through posterior port.

Once safely in the chest, the lungs are carefully inspected to identify any bullous changes and to detect the source of the air leak. Blebs will be air-filled areas of the lung less than 1 cm in size compared to bullae which are greater than 1 cm in size. Adhesions should be identified and lysed to allow for complete evaluation of the lung. Care should be taken to obtain hemostasis if any bleeding from the adhesions is encountered. Bullae that are identified can be stapled using an endo-stapler without crossing over any portion of the bullae in the staple line, as this may increase risk of recurrence. There should be good margin with the stapler traversing only “healthy” lung tissue in patients with spontaneous primary pneumothorax.

Mechanical pleurodesis involves creating abrasions to the pleural surface, or performing a limited pleurectomy, to initiate an inflammatory response which results in the formation of adhesions and prevents the lung from collapsing in situations of recurrence. The pleural abrasion is typically performed using an electrocautery scratch pad or gauze (**Figure 3**). Care should be taken when working at the apex, as a Horner’s syndrome can occur if there is any injury to the stellate ganglion of the sympathetic chain. Additional operative complications include bleeding, particularly from intercostal or mammary vessels, and pain. One randomized prospective study comparing wedge resection to wedge resection, and adjunct mechanical pleurodesis, resulted in no difference in recurrence rates but did show an increase in complications for the pleurodesis group [20]. A meta-analysis comparing the different combinations of intraoperative treatment for primary spontaneous pneumothorax found that wedge resection combined with chemical pleurodesis, as well as wedge resection, combined with both mechanical pleural abrasion and chemical pleurodesis, had the lowest recurrence rates. Although



**Figure 3.** Pleural abrasion using electrocautery scratch pad (a) before and (b) after.

the complications of these procedures were not taken into account favoring chemical or mechanical pleurodesis, in addition to wedge resection to remove the source of the air leak [21, 22]. Mechanical pleurodesis should be considered on a case-by-case basis with good clinical judgment. This should be avoided in patient who may have a bleeding tendency either due to medications or underlying disease. A chemical pleurodesis would be appropriate using an agent that cause aseptic inflammation in the pleura and facilitate pleural adhesion. Debate continues over the most effective chemical pleurodesis agent to use which has led to the widest variation in overall technique among all of these strategies. Graduated talcum of particle size <10 mic m is the most popular currently and has a long-standing history as an effective and trusted agent for pleurodesis. In the past, tetracycline and doxycycline have been used; however, the success rate is lower than the graduated talcum powder [23–25]. Marcheix et al. published a large study of 603 consecutive patients who underwent VATS pleurodesis using silver nitrate for primary spontaneous pneumothorax. While only 39.6% of these cases involved wedge resection and pleurodesis, the recurrence rate at 1 month was 0.5% in this group. The last 250 patients were included in a longer-term follow-up ( $2.9 \pm 2.3$  years) in which the recurrence rate was approximately 1.1%; however, only 73% of patients were actually contacted and this represents 31% of the total study population [26]. While it is difficult to draw concrete conclusions from this study, it is clear that silver nitrate can be an effective pleurodesis agent. Similar studies exist showing minocycline to be an effective agent as well [27].

When comparing VATS to other treatment modalities, such as aspiration, chest tube drainage, and pleurodesis, a recent meta-analysis of all available randomized control trials showed that VATS had the most favorable results with regard to recurrence and hospitalization days [21, 22]. The addition of pleurodesis to VATS bullectomy compared to VATS bullectomy alone further decreases recurrence rates, although this strategy comes with associated complications that include pain [21, 22]. Given the increased complications that arise from pleurodesis, some novel attempts at replacing the procedure, and at the same time achieving the same goal of promoting adhesions, have been developed. The use of an absorbable cellulose mesh and fibrin glue that are placed over blebectomy staple lines has been studied as an alternative to pleurodesis, with promising results [28]. This technique has been found to be non-inferior in terms of recurrence rates when compared to pleurodesis and is without the complications of bleeding, pain, and Horner's syndrome that are associated with mechanical pleurodesis. The cost of these biological materials should be taken into consideration when the approach is sought. The use of autologous blood as a pleurodesis agent needs mention. Although various chemical agents all pose some risks, namely, significant pain or rarely development of acute respiratory distress syndrome, pleurectomy carries with it significant pain and bleeding. Autologous blood has been utilized in some instances with good success [29]. The majority of the literature on this topic involves using blood to treat persistent air leaks in the postoperative period. While this data cannot be directly utilized to construct guidelines for spontaneous pneumothorax, based on the body of evidence that exists, its reported efficacy is so compelling that one wonders if it could be similarly effective in this operative setting.

Chang and colleagues compared pleurodesis combined with wedge resection utilizing "needlescopic" VATS technique with apical pleurectomy [30]. It is accurate to think of this technique as analogous to VATS, one 12 mm port for standard VATS instruments and the chest tube to that needlescopic technique which combines three 3 mm ports for "mini" endograspers and a "needlescope." In addition to demonstrating that pleurectomy was technically feasible, utilizing needlescopy with comparable pain indices, duration of chest tube drainage, and hospital stay, it also suggested a lower recurrence rate, 0%, when compared to the abrasion group, 8.6%. Studies comparing traditional VATS to needlescopic technique are lacking; however, in this author's experience, the former can be completed easily with only two 5 mm and

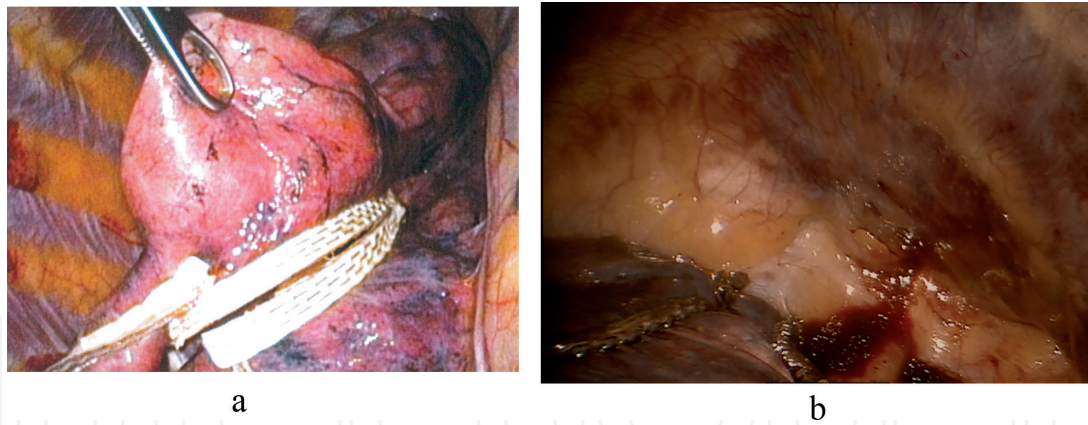
a 10 mm port, a similar total incision length to needlescopy with one less incision overall, and can even be accomplished with a single 5 mm and a single 10 mm port. This fact calls into question the benefit of this modification to traditional VATS.

Two additional trials demonstrating the superiority of pleurodesis with pleurectomy over abrasion are worth mentioning. Huh and colleagues performed a similar study of 207 consecutive patients who underwent VATS wedge and either apical pleurectomy or pleural abrasion at a single Korean institution [31]. Although the recurrence rate in the pleurectomy group was higher in this study at 9.1% than the previous study, it was still lower than that of the abrasion group, 12.8%, which reached statistical significance. The second study is from the pediatric literature and showed that when combined with apical bleb resection pleurectomy led to a significantly lower rate of pneumothorax recurrence when compared to pleural abrasion, 8.8 vs. 40%, in the management of spontaneous primary pneumothorax in teenage patients ranging from 14 to 17 years old [32]. It should be noted that although these were retrospective studies, the follow-up period for the VATS wedge with pleurectomy group in the two Asian studies was significantly longer than that of the wedge with abrasion group, raising the possibility that the recurrence rate in the latter group may be underreported.

Secondary pneumothorax in the majority includes patients with chronic obstructive pulmonary disease and emphysema. The underlying may have homogeneous or heterogeneous emphysema, and identifying the area of air leak can be difficult except in patients with large bullous disease. Other surgical strategies have been developed for the approach of pneumothorax in this patient population. When patients present with extensive emphysema of the underlying lung, the strategies of lung volume reduction surgery may be applicable. Lung volume reduction surgery (LVRS) is well studied by the National Emphysema Treatment Trial (NETT). LVRS in selected patients with emphysema as a treatment modality improved quality of life and length of survival compared to medical therapy alone [33]. A comparison of LVRS to medical therapy identified higher early mortality rates in the surgical group than medical treatment alone, 7.9 vs. 1.3%, though overall mortality saw no difference. The surgical group was further broken down into minimally invasive versus median sternotomy, identifying comparable mortality rates between the two arms. When comparing exercise capacity between the surgical and medical groups, there was a significant difference 24 months after treatment in favor of surgery, improving 15% of patients compared to 3% in the medical treatment arm. Application of NETT trial findings is useful and can provide clarity when approaching a patient presenting with secondary pneumothorax with severe emphysema. Work-up on these patients often show low FEV1 values with high residual volumes and lung capacity. In these patients applying the principle of lung volume reduction to include the suspected areas, this will help to treat the secondary pneumothorax as well as improving overall outcome. However this patient population should be approached with care and best treated in centers with expertise in LVRS. Often the staple lines will require reinforcement, and additional adjunctive procedures may be necessary such as pleural tent to manage air leak (**Figure 4a**) [34].

Patients presenting with secondary pneumothorax with underlying fibrotic parenchymal pathology present additional challenges [35]. These lungs have poor compliance, and air leak management will require a different approach that may need sealants rather than resection and use of pleural tent to manage the air leak and the space (**Figure 4b**). Use of tissue sealants instead of stapling, or in addition to stapling, may be necessary if the patient is deemed a candidate for surgical intervention. If not a surgical candidate, conservative approach with chemical pleurodesis would be appropriate.





**Figure 4.**  
(a) Using reinforcement techniques to reduce air leak at staple line and (b) using pleural tent to manage air leak and space in a noncompliant lung.

The most important consideration among patients with secondary spontaneous pneumothorax is that by definition, the patients are sicker than primary spontaneous pneumothorax patients because of the underlying lung condition at baseline. This lung pathology almost always accompanies in advanced age, with finding the mean age of patients presenting with primary spontaneous pneumothorax is younger than secondary pneumothorax. It stands to reason that this age brings with it more medical comorbidities and, as a result, reduced physiologic reserve, therefore necessitating prompt action, even when the size of the pneumothorax is relatively small. Furthermore, if one occurrence of pneumothorax in this patient population represents a life-threatening condition, then a recurrence could possibly be even more life-threatening. Therefore, one could argue that preventing recurrence of pneumothorax is more of a matter of life and death in secondary pneumothorax patient compared to primary spontaneous pneumothorax for the reasons listed above, as typically they have limited reserve [36, 37].

While agreement is coalescing that among patients treated with surgery for spontaneous pneumothorax, VATS should be the primary method of access. The diseased lung should be excised, and some form of pleurodesis should be added. Several other areas of interest warrant attention as well.

The strategy of postoperative chest tube management following surgical treatment for pneumothorax has not been extensively studied. Some surgeons advocate the placing of chest tubes to allow wall suction to increase the lung-chest wall apposition after pleurodesis, while others prefer to leave chest tubes on water seal in the immediate postoperative period. One study has compared these two strategies for chest tube management, demonstrating that placing patients on  $-20$  cm  $H_2O$  suction resulted in increased chest tube duration, hospital stay, and prolonged air leak compared to those patients on no suction [38]. As long as pleural apposition is noted on chest radiograph postoperatively, the use of suction can be avoided that suggest prolonged air leak and subsequent hospital stay.

Some suggest that the cost and length of hospital stay might be reduced by instituting “clever” drainage strategies. One such approach is the use of digital electronic drainage systems to manage chest tubes. Removal of chest drains remains an important factor in timing of discharge from the hospital following lung resection. Since data was first published on the first digital suction device in 2006, there has been increased interest in the idea of utilizing objective data from these devices to dictate timing of the removal of chest drains, thereby reducing inter-operator variability and hopefully length of stay [39]. A group in Korea expanded on this idea by utilizing Wi-Fi-enabled digital suction devices in the postoperative management of chest drainage tubes in patients undergoing VATS wedge resection for primary spontaneous pneumothorax



[40]. The devices utilized in this study could not only remotely deliver information to providers regarding suction power and volume of air leaks, but they could also allow the providers to remotely control settings on the suction device. In keeping with the growing reliance on mobile technology in our society, clinicians were able to monitor and control device parameters using a smartphone app. Findings in this randomized control trial were consistent with previous studies which showed a statistically significant decrease in chest tube duration, length of stay, and, consequently, overall cost. The investigators established the safety and feasibility of managing pleural drains remotely opening the possibility of discharging patients home with the drains in place and monitoring their progress at home. One limitation of this particular study was that investigators elected not perform any form of pleurodesis to limit the postoperative parameters, thereby reducing the generalizability of the data onto patients who received the gold standard of treatment for spontaneous pneumothoraces, namely, resection and pleurodesis. Despite this limitation, recurrences in this study with 6 months of follow-up data remained low at about 3.4%. Given the rapidity with which mobile technology is advancing, it is not hard to envision a time when physicians can monitor the character and volume of effluent from these devices as well, thereby decreasing the need for inpatient care to that of reaching a stable level of analgesia with only oral agents.

There are also financial implications that should be considered when evaluating the differences between open and minimally invasive approaches to the management of pneumothorax and use of adjuncts. In a small Italian study from 1996 comparing VATS versus thoracotomy for management of recurrent spontaneous pneumothorax at a time when reusable VATS instruments were not yet widely available, VATS was still found to have a 22.7% cost savings compared to thoracotomy even when expensive disposable VATS equipment was used. The cost savings at that time were realized in the decreased duration of postoperative hospitalization seen in patients treated with VATS compared to open thoracotomy [10, 41]. A more recent study identified these cost savings in complication, ICU admission, length of hospitalization, operative time, and chest tube duration [42], further supporting the argument of minimally invasive intervention compared to open.

As application of robotic techniques become readily available to thoracic surgeons, it is likely the technology could be developed in pinpointing air leak and precision application of treatment during surgical intervention. Furthermore, there is an increasing interest in using computerized chest drainage systems to allow for an early and safe removal of chest tube or remote management of the tube in outpatient settings.

Anesthetic concerns are typically left out of discussion of surgical treatment. However, one paper that deserves mention evaluated the feasibility of performing awake VATS bullectomy and abrasion. In this randomized control trial in Rome, Italy, patients were randomized to undergo either awake VATS with thoracic epidural anesthesia or traditional VATS with general anesthesia and single-lung ventilation [43]. The sample size was relatively small to be sure, with 21 in the investigational arm and 23 in the control arm, but the results of the trial were striking nonetheless. Not only was awake VATS technically feasible, with all cases being completed as planned and zero conversions to general anesthesia, but pain scores and patient satisfaction with anesthesia favored the awake approach over the traditional VATS. What is particularly interesting in this study is that the cost data also favored the awake technique ( $2540 \pm 352$  € vs.  $3550 \pm 435$  €,  $p < 0.0001$ ). This is mostly because anesthesia time ( $25.0 \pm 6.0$  min vs.  $35.5 \pm 10.0$  min,  $p < 0.001$ ), recovery room time ( $20 \pm 15.0$  min vs.  $30 \pm 15.0$  min,  $p = 0.001$ ), global OR time ( $78.0 \pm 20.0$  min vs.  $105.0 \pm 15.0$  min,  $p < 0.001$ ), and hospital stay ( $2.0 \pm 1.0$  d vs.  $3.0 \pm 1.0$  d,  $p < 0.0001$ ) were all shorter for the awake group [43]. With a significant portion of the debate over how best to control rising health-care costs with focus on resource utilization and hospital stay, it is a wonder why this technique is not more widely utilized, let alone discussed.

The rise of minimally invasive surgical treatment of spontaneous pneumothorax has had a great impact on the way in which these are approached. Prior to the adoption of VATS techniques, many patients were deemed too sick to tolerate either single-lung ventilation or the ventilator assistance required in the perioperative period or both. Ichinose and colleagues retrospectively evaluated the records of all patients operated on for secondary pneumothorax, 183 cases, at a single institution between 1993 and 2014 and reported on the outcome of their surgical treatment [37]. Other than the underlying lung pathology, of which interstitial pneumonia had the worst survival, the group identified open surgical treatment as the greatest risk factor for treatment failure defined as the occurrence of in-hospital mortality, postoperative complications, and death within 6 months or ipsilateral recurrence within 2 years. In noting the dearth of evidence regarding minimally invasive surgical techniques for secondary pneumothorax, Galvez and colleagues highlight the promise of non-intubated VATS (NI-VATS) surgery in this population [44]. In addition to the benefits of this technique described above for PSP, the benefits of avoiding general anesthesia in these patients also include decreasing risk of ventilator dependency, decreasing risk of pulmonary infections, secretions of orotracheal intubation, and a reduction in overall pulmonary complications by half. Much of the pleurodesis reported in this literature review involved fibrin glue, polyglycolic acid sheets, and autologous blood or some combination of these. It seems obvious that because of the decreased physiologic and cardiopulmonary reserve often seen in patients with secondary pneumothorax, there should be great interest in developing additional minimally invasive surgical techniques and investigating their benefits.

## **5. Conclusion**

Despite differences in etiology of pneumothorax, the management should be directed at expeditious bedside and, ultimately, surgical management for patients who do not completely resolve their pneumothorax non-operatively [45]. We advocate for bedside chest tube placement under local anesthetic for nearly all patients who present with spontaneous pneumothorax, except those with small pneumothorax that remain stable on follow-up radiographic imaging. Following chest tube placement, if the pneumothorax fully resolves and there is no ongoing air leak, these patients can have their chest tube water sealed and subsequently removed as early as the day after hospital presentation. Patients with recurrent bilateral pneumothorax, patients who present for the first time without ready access to medical care, patients with profession or hobbies that make them at higher risk from developing recurrence, or patients with persistent air leak should undergo surgical intervention whenever possible. The operative approach should favor VATS over open thoracotomy for both pleurodesis/pleurectomy and resection of blebs. Our approach is always to perform pleurodesis following the blebectomy or remove the source of the air leak. Our preferred approach in younger patients is mechanical pleurodesis, and in patients above 65 years of age, use graded talc. In patients presenting with recurrences following a previous pleurodesis, we reserve the apical pleurectomy. In patients with secondary pneumothorax, we have lower threshold to reinforce staple line or perform pleural tent in addition to the above. This overall strategy will facilitate timely treatment in this patient population and accomplish it in a minimally invasive manner that aligns with other modern surgical approaches in the field of thoracic surgery.

## **Conflict of interest**

None.

IntechOpen

IntechOpen

### **Author details**

Kostantinos Poulidikis\*, Lee Gerson, John Costello and Wickii T. Vigneswaran  
Loyola University Health System, Maywood, IL, USA

\*Address all correspondence to: [wickii.vigneswaran@lumc.edu](mailto:wickii.vigneswaran@lumc.edu)

### **IntechOpen**

---

© 2019 The Author(s). Licensee IntechOpen. This chapter is distributed under the terms of the Creative Commons Attribution License (<http://creativecommons.org/licenses/by/3.0>), which permits unrestricted use, distribution, and reproduction in any medium, provided the original work is properly cited. 



## References

- [1] Onuki T, Ueda S, Yamaoka M, et al. Primary and secondary spontaneous pneumothorax: Prevalence, clinical features, and in-hospital mortality. *Canadian Respiratory Journal*. 2017;**2017**:1-8. DOI: 10.1155/2017/6014967
- [2] Gupta D, Hansell A, Nichols T, Duong T, Ayres JG, Strachan D. Epidemiology of pneumothorax in England. *Thorax*. 2000;**55**(8):666-671. Available from: <http://www.ncbi.nlm.nih.gov/pubmed/10899243>
- [3] Sahn SA, Heffner JE. Spontaneous pneumothorax. *The New England Journal of Medicine*. 2000;**342**(12):868-874. DOI: 10.1056/NEJM200003233421207
- [4] Bobbio A, Dechartres A, Bouam S, et al. Epidemiology of spontaneous pneumothorax: Gender-related differences. *Thorax*. 2015;**70**(7):653-658
- [5] Bense L, Eklund G, Wiman LG. Smoking and the increased risk of contracting spontaneous pneumothorax. *Chest*. 1987;**92**(6):1009-1012. DOI: 10.1378/chest.92.6.1009
- [6] Hallifax RJ, Goldacre R, Landray MJ, et al. Trends in the incidence and recurrence of inpatient-treated spontaneous pneumothorax, 1968-2016. *Journal of the American Medical Association*. 2018;**320**(14):1471-1480. DOI: 10.1001/jama.2018.14299
- [7] Tyson M, Crandall W. The surgical treatment of recurrent idiopathic spontaneous pneumothorax. *The Journal of Thoracic Surgery*. 1941;**10**:566-570
- [8] Lewis RJ, Caccavale RJ, Sisler GE, Mackenzie JW. One hundred consecutive patients undergoing video-assisted thoracic operations. *The Annals of Thoracic Surgery*. 1992;**54**(3):421-426. Available from: <http://www.ncbi.nlm.nih.gov/pubmed/1510508>
- [9] Levi JF, Kleinmann P, Riquet M, Debesse B. Percutaneous parietal pleurectomy for recurrent spontaneous pneumothorax. *Lancet (London, England)*. 1990;**336**(8730):1577-1578. Available from: <http://www.ncbi.nlm.nih.gov/pubmed/1979386>
- [10] Schramel FM, Sutedja TG, Braber JC, van Mourik JC, Postmus PE. Cost-effectiveness of video-assisted thoracoscopic surgery versus conservative treatment for first time or recurrent spontaneous pneumothorax. *The European Respiratory Journal*. 1996;**9**(9):1821-1825
- [11] Lara-Guerra H, Waddell TK. *Pearson's Thoracic and Esophageal Surgery*. Philadelphia: Chirchill Livingstone; 2008. DOI: 10.1016/B978-0-443-06861-4.50014-9
- [12] Schoenenberger RA, Haefeli WE, Weiss P, Ritz RF. Timing of invasive procedures in therapy for primary and secondary spontaneous pneumothorax. *Archives of Surgery*. 1991;**126**(6):764-766. Available from: <http://www.ncbi.nlm.nih.gov/pubmed/2039365>
- [13] Hatz RA, Kaps MF, Meimarakis G, Loehe F, Müller C, Fürst H. Long-term results after video-assisted thoracoscopic surgery for first-time and recurrent spontaneous pneumothorax. *The Annals of Thoracic Surgery*. 2000;**70**(1):253-257. Available from: <http://www.ncbi.nlm.nih.gov/pubmed/10921718>
- [14] Treasure T. Minimally invasive surgery for pneumothorax: The evidence, changing practice and current opinion. *Journal of the Royal Society of Medicine*. Sep 2007;**100**(9):419-422. DOI: 10.1258/jrsm.100.9.419

- [15] Pagès PB, Delpy JP, Falcoz PE, et al. Videothoracoscopy versus thoracotomy for the treatment of spontaneous pneumothorax: A propensity score analysis. *The Annals of Thoracic Surgery*. 2015;**99**(1):258-263. DOI: 10.1016/j.athoracsur.2014.08.035
- [16] Barker A, Maratos EC, Edmonds L, Lim E. Recurrence rates of video-assisted thoracoscopic versus open surgery in the prevention of recurrent pneumothoraces: A systematic review of randomised and non-randomised trials. *Lancet*. 28 Jul 2007;**370**(9584):329-335. DOI: 10.1016/S0140-6736(07)61163-5
- [17] Sawada S, Watanabe Y, Moriyama S. Video-assisted thoracoscopic surgery for primary spontaneous pneumothorax: Evaluation of indications and long-term outcome compared with conservative treatment and open thoracotomy. *Chest*. 2005;**127**(6):2226-2230. DOI: 10.1378/chest.127.6.2226
- [18] Cardillo G, Facciolo F, Giunti R, et al. Videothoroscopic treatment of primary spontaneous pneumothorax: A 6-year experience. *The Annals of Thoracic Surgery*. 2000;**69**(2):357-361; discussion 361-2. Available from: <http://www.ncbi.nlm.nih.gov/pubmed/10735663>
- [19] Li L, Tian H, Yue W, Li S, Gao C, Si L. Subxiphoid vs intercostal single-incision video-assisted thoracoscopic surgery for spontaneous pneumothorax: A randomised controlled trial. *International Journal of Surgery*. 2016;**30**:99-103. DOI: 10.1016/j.ijssu.2016.04.035
- [20] Min X, Huang Y, Yang Y, et al. Mechanical pleurodesis does not reduce recurrence of spontaneous pneumothorax: A randomized trial. *The Annals of Thoracic Surgery*. Nov 2014;**98**(5):1790-1796. DOI: 10.1016/j.athoracsur.2014.06.034
- [21] Sudduth CL, Shinnick JK, Geng Z, McCracken CE, Clifton MS, Raval MV. Optimal surgical technique in spontaneous pneumothorax: A systematic review and meta-analysis. *The Journal of Surgical Research*. 2017. DOI: 10.1016/j.jss.2016.10.024
- [22] Vuong NL, Elshafay A, Thao LP, et al. Efficacy of treatments in primary spontaneous pneumothorax: A systematic review and network meta-analysis of randomized clinical trials. *Respiratory Medicine*. 2018;**137**:152-166. DOI: 10.1016/j.rmed.2018.03.009
- [23] Olsen PS, Anderson HO. Long term results after tetracycline pleurodesis in spontaneous pneumothorax. *The Annals of Thoracic Surgery*. 1992;**53**:1015-1017
- [24] Kennedy L, Sahn SA. Talc pleurodesis for the treatment of pneumothorax and pleural effusion. *Chest*. 1994;**106**:1215-1222
- [25] Maskell NA, Lee YC, Gleeson FV, Hedley EL, Pengelly G, Davies RJ. Randomized trials describing lung inflammation after pleurodesis with talc of varying particle size. *American Journal of Respiratory and Critical Care Medicine*. 2004;**170**(4):377-382. Epub 2004 May 13
- [26] Marcheix B, Brouchet L, Renaud C, et al. Videothoroscopic silver nitrate pleurodesis for primary spontaneous pneumothorax: An alternative to pleurectomy and pleural abrasion? *The European Journal of Cardio-Thoracic Surgery*. Jun 2007;**31**(6):1106-1109. DOI: 10.1016/j.ejcts.2007.03.017
- [27] Chen JS, Chan WK, Tsai KT, et al. Simple aspiration and drainage and intrapleural minocycline pleurodesis versus simple aspiration and drainage for the initial treatment of primary spontaneous pneumothorax: An open-label, parallel-group, prospective, randomised, controlled trial. *Lancet*. 13 Apr 2013;**381**(9874):1277-1282. DOI: 10.1016/S0140-6736(12)62170-9

- [28] Lee S, Kim HR, Cho S, et al. Staple line coverage after bullectomy for primary spontaneous pneumothorax: A randomized trial. *The Annals of Thoracic Surgery*. 2014;**98**(6):2005-2011. DOI: 10.1016/j.athoracsur.2014.06.047
- [29] Pathak V, Quinn C, Zhou C, Wadie G. Use of autologous blood patch for prolonged air leak in spontaneous pneumothoraces in the adolescent population. *Lung India*. 2018;**35**(4): 328-331. DOI: 10.4103/lungindia.lungindia\_462\_17
- [30] Chang YC, Chen CW, Huang SH, Chen JS. Modified needlescopic video-assisted thoracic surgery for primary spontaneous pneumothorax: The long-term effects of apical pleurectomy versus pleural abrasion. *Surgical Endoscopy and Other Interventional Techniques*. 2006;**20**(5):757-762. DOI: 10.1007/s00464-005-0275-6
- [31] Huh U, Kim Y-D, Cho JS, Hoseok I, Lee JG, Lee JH. The effect of thoracoscopic pleurodesis in primary spontaneous pneumothorax: Apical parietal pleurectomy versus pleural abrasion. *Korean Journal of Thoracic and Cardiovascular Surgery*. 2012;**45**(5):316-319. DOI: 10.5090/kjtcs.2012.45.5.316
- [32] Joharifard S, Coakley BA, Butterworth SA. Pleurectomy versus pleural abrasion for primary spontaneous pneumothorax in children. *Journal of Pediatric Surgery*. 2017. DOI: 10.1016/j.jpedsurg.2017.01.012
- [33] Fishman A, Martinez F, Naunheim K, et al. A randomized trial comparing lung-volume-reduction surgery with medical therapy for severe emphysema. *The New England Journal of Medicine*. 2003;**348**(21):2059-2073. DOI: 10.1056/NEJMoa030287
- [34] Vigneswaran WT, Podbielski FJ, Halldorsson A, Kong L, Schwab T, Janulitis C, et al. Single-stage, bilateral, video-assisted thoracoscopic lung volume reduction surgery for end-stage emphysema. *World Journal of Surgery*. 1998;**22**:799-802
- [35] Nishimoto K, Fujisawa T, Yoshimura K, Enomoto Y, Enomoto N, Nakamura Y, et al. The prognostic significance of pneumothorax in patients with idiopathic pulmonary fibrosis. *Respirology*. 2017;**23**:519-525
- [36] Isaka M, Asai K, Urabe N. Surgery for secondary spontaneous pneumothorax: Risk factors for recurrence and morbidity. *Interactive Cardiovascular and Thoracic Surgery*. 2013;**17**(2):247-252
- [37] Ichinose J, Nagayama K, Hino H, Nitadori J, et al. Results of surgical treatment for secondary spontaneous pneumothorax according to underlying diseases. *European Journal of Cardiothoracic Surgery*. 2016;**49**(4):1132-1136. DOI: 10.1093/ejcts/ezv256
- [38] Ayed AK. Suction versus water seal after thoracoscopy for primary spontaneous pneumothorax: Prospective randomized study. *The Annals of Thoracic Surgery*. 2003;**75**(5):1593-1596. Available from: <http://www.ncbi.nlm.nih.gov/pubmed/12735584>
- [39] Pompili C, Detterbeck F, Papagiannopoulos K, et al. Multicenter international randomized comparison of objective and subjective outcomes between electronic and traditional chest drainage systems. *The Annals of Thoracic Surgery*. 2014;**98**(2):490-497. DOI: 10.1016/j.athoracsur.2014.03.043
- [40] Cho HM, Hong YJ, Byun CS, Hwang JJ. The usefulness of Wi-Fi based digital chest drainage system in the post-operative care of pneumothorax. *Journal of Thoracic Disease*. 2016;**8**(3):396-402. DOI: 10.21037/jtd.2016.02.54



[41] Crisci R, Coloni GF. Video-assisted thoracoscopic surgery versus thoracotomy for recurrent spontaneous pneumothorax. A comparison of results and costs. *European Journal of Cardio-Thoracic Surgery*. 1996;**10**(7):556-560. Available from: <http://www.ncbi.nlm.nih.gov/pubmed/8855429>

[42] Joshi V, Kirmani B, Zacharias J. Thoracotomy versus VATS: Is there an optimal approach to treating pneumothorax? *Annals of the Royal College of Surgeons of England*. 2013;**95**(1):61-4.27

[43] Pompeo E, Tacconi F, Mineo D, Mineo TC. The role of awake video-assisted thoracoscopic surgery in spontaneous pneumothorax. *The Journal of Thoracic and Cardiovascular Surgery*. 2007;**133**(3):786-790. DOI: 10.1016/j.jtcvs.2006.11.001

[44] Galvez C, Bolufer S, Navarro-Martinez J, Lirio F, Corcoles JM, Rodriguez-Paniagua JM. Non-intubated video-assisted thoracic surgery management of secondary spontaneous pneumothorax. *The Annals of Translational Medicine*. 2015;**3**(8):104. DOI: 10.3978/j.issn.2305-5839.2015.04.24

[45] Vigneswaran WT, Odell JA. *Pneumothorax: In Decision Making in Thoracic Surgery*. New Delhi, India: Jaypee Brothers Medical Publishers Ltd; 2018. pp. 19-21