

We are IntechOpen, the world's leading publisher of Open Access books Built by scientists, for scientists

4,800

Open access books available

122,000

International authors and editors

135M

Downloads

Our authors are among the

154

Countries delivered to

TOP 1%

most cited scientists

12.2%

Contributors from top 500 universities



WEB OF SCIENCE™

Selection of our books indexed in the Book Citation Index
in Web of Science™ Core Collection (BKCI)

Interested in publishing with us?
Contact book.department@intechopen.com

Numbers displayed above are based on latest data collected.
For more information visit www.intechopen.com



Microscope-Integrated Intraoperative Optical Coherence Tomography in Retinal Surgery

Jesus Hernan Gonzalez-Cortes, Abraham Olvera-Barrios, Jesus Emiliano Gonzalez-Cantu and Jesus Mohamed-Hamsho

Abstract

Imaging techniques of the posterior segment of the eye have gradually evolved and tremendously improved during the last decade. A widespread implementation of optical coherence tomography (OCT) for the management and diagnosis of retinal conditions, with a concurrent advance in integrative technology, led to the integration of the OCT into the microscope for its intraoperative use. Regarding posterior segment eye surgery, some of the most common diagnoses in which microscope-integrated OCT (MIOCT) can result of great value are epiretinal membrane, macular hole (MH), proliferative diabetic retinopathy (PDR) and, less frequently, for inflammatory diseases, chorioretinal biopsies, and retinal implants. The impact on the surgical procedure and, possibly, on the postoperative outcome could relate to the definition of whether or not a membrane has been entirely peeled, the presence of residual membranes, and the option to perform a dissection without the need of vital dyes. The possibility of correct topographical location of hemorrhages, suspect lesions, or implants can also facilitate the surgical decision-making during biopsies or prosthesis implantation. Microscope-integrated OCT is a feasible and useful tool that can provide valuable information during surgery impact on decision-making, anatomic results, surgical safety and provide opportunity to individualize surgical treatment for each patient.

Keywords: intraoperative optical coherence tomography, retinal surgery, vitreomacular interface, membrane peeling, retinal detachment

1. Introduction

The development of microsurgery enhanced the precision with which ophthalmic surgical procedures are currently performed. Its origins date back to 1876, when the first binocular magnifying device was invented by T. Saemisch of Bonn [1]. It was not until 1953, with the manufacture of a microscope with coaxial illumination, that the use of the surgical microscope became more widely available and adapted to ocular surgery [2–4]. Three years later, in 1956, the term “microsurgery” was used for the first time by H. M. Dekking of Gönningen [5]. Almost two decades before the use of binocular magnifying devices, Hermann von Helmholtz invented ophthalmoscopy in 1851 and allowed us to see, for the first

time, the human retina [6]. Under this rapidly evolving background, the development of pars plana vitrectomy (PPV) in 1970 revolutionized retinal surgery with less invasive procedures and better results in terms of visual acuity and patient satisfaction [7].

In addition to the operating microscope, imaging techniques of the posterior segment of the eye have tremendously improved during the last two decades. Optical coherence tomography (OCT) became readily and more widely available during the last 10 years and has become one of the most commonly ordered diagnostic tests in ophthalmology [8–12]. The detail on the retinal architecture provided by OCT allows to better characterize, diagnose, manage, and give prognosis of a wide range of vitreoretinal conditions.

1.1 Integration of OCT into the operating theater

Further improvements in software and imaging started a new transition of this powerful technology to the operating room. Firstly, it was used as a perioperative tool to image pediatric patients, with clear limitations for image acquisition, portability, and sterility [13, 14], and then as a handheld OCT scan head: Bioptigen SDOIS/Envisu portable system (Bioptigen, Research Triangle Park, NC) and Optovue IVue (Optovue, Fremont, CA) [15–18]. Advantages of the handheld OCT imaging are flexibility of scan head orientation and dynamic positioning of the scan during acquisition. On the other hand, disadvantages were its poor reproducibility, optimal targeting, and the surgeon learning curve [16, 17, 19–21]. A further step forward was taken with the integration of an OCT scan head to the operating microscope, a model that allowed portability, stability, repeatability, efficiency, control from the foot pedal, and an easier learning curve for surgeons [16, 17, 22–24]. However, a major drawback of this system was the need to stop the surgical procedure to image the retina: a lack of real-time imaging. The 2-year results of the Prospective Intraoperative and Perioperative Ophthalmic ImagiNg With Optical CoherEncE TomogRaphy (PIONEER) study published in 2014 [17] demonstrated the potential of this imaging tool in the operating theater. A total of 531 eyes were enrolled, from which 256 underwent posterior segment surgery. The three most frequent retinal procedures in this study were epiretinal membrane (ERM) peeling (35%), macular hole (MH) surgery (23%), and rhegmatogenous retinal detachment (RRD) repair (17%). Intraoperative OCT impacted on the surgeons' understanding of the anatomical configuration of the region of interest and/or on the surgical procedure in 43% of the cases of retinal membrane peeling and impacted on surgical decision-making in at least 13% of the procedures in which the surgeon wanted to evaluate the outcome after initial membrane peeling [17].

Microscope-integrated OCT (MIOCT) provided real-time imaging when integrative technological progress allowed to incorporate a scanner head/system which is, ideally, coaxial and parfocal with the optical system to the operating microscope [25–28]. Haag-Streit (Haag-Streit, Koeniz, Switzerland), Leica (Leica Microsystems, Buffalo Grove, IL, USA), and Zeiss (Carl Zeiss Meditec, Jena, Germany) have currently available commercial MIOCT systems: iOCT, EnFocus, and Rescan 700, respectively [29–34]. Despite outcomes are still debatable, literature reports have suggested the feasibility and potentially significant usefulness of an intraoperative MIOCT [35–38]. The 3-year results of the Determination of Feasibility of Intraoperative Spectral-Domain Microscope Combined/Integrated OCT Visualization during En Face Retinal And Ophthalmic Surgery (DISCOVER) study were published in 2018 [33]. In this report, 877 eyes were enrolled, and 593 of those underwent retinal surgery. The use of MIOCT altered surgical decision-making in 29.2% of the procedures [33].

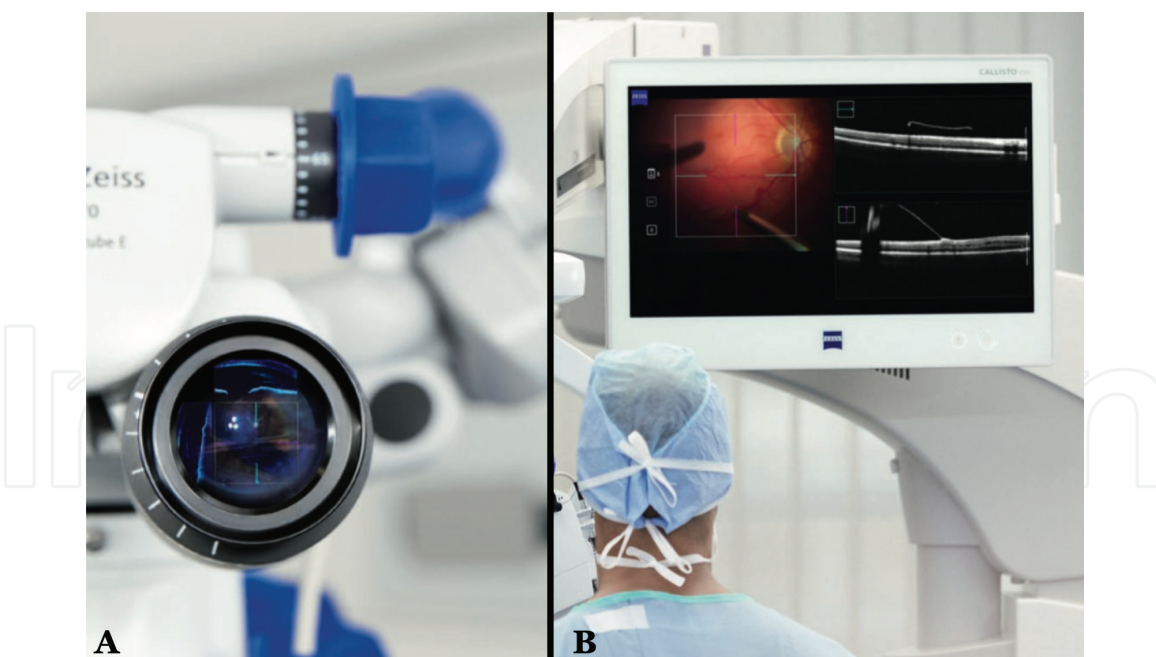


Figure 1. Display modalities of the microscope-integrated optical coherence tomography in the ZEISS RESCAN 700. (A) Heads-up display, showing a vertical and horizontal OCT scan within the oculars. (B) An external display screen allows the surgeon to review the scans in a more detailed manner. Images courtesy of Carl Zeiss Meditec.

In order to enhance the intraoperative use of MIOCT, optimized features like automation, effective display systems, and better software analysis are required for the near future. The recent devices allow real-time and static capture acquisition of anterior and posterior segment images during surgery [31–34]. Nevertheless, they lack automation, and surgeon or assistant input can be necessary. The imaging scan is delivered to the surgeon in a dual manner: as an external display screen or a heads-up display within the oculars, providing versatility and facilitating its intraoperative use (**Figure 1**) [33]. Microscope-integrated OCT provides the surgeon with an additional tool to better evaluate the case in a real-time fashion, enhance surgical precision, and facilitate surgical decision-making.

2. Surgical implications

The intraoperative advantages of the MIOCT during surgery are wide. **Table 1** summarizes the potential surgical implications according to different pathologies.

2.1 Vitreoretinal interface disorders

Conditions comprising vitreoretinal interface disorders (MH, vitreomacular traction (VMT), and ERM) result in one of the best scenarios for the use of MIOCT [34, 35, 37, 39, 40]. Intraoperative visualization of vitreomacular interface components and alterations can potentially contribute to surgical decision-making in membrane peeling procedures, because of the readiness to obtain real-time imaging of subclinical alterations (e.g., residual membranes, retinal elevations, microarchitectural perturbations in the distances between ellipsoid zone and retinal pigment epithelium (RPE), as well as alterations of the inner retinal surface) [15–17, 33, 39–42]. The ability to perform a membrane peeling with the MIOCT could result in a reduction of the use of vital dyes, a minimization of the risk of retinal pharmacotoxicity, and a reduction of surgical time [35, 43–45].

Preoperative diagnosis	Procedure	Utility
Vitreomacular interface disorders		
Macular hole		Differentiation between ERM and ILM Visualization of the ILM border Evidence or residual ILM or ERM Volumetric assessment of the retinal edges surrounding the MH Assessment of anatomical closure
Vitreomacular traction syndrome	Vitrectomy + ILM peeling	Potential reduction of the use of vital dyes Differentiation between ERM and ILM Visualization of the ILM border Evidence or residual ILM or ERM
Epiretinal membrane		Assessment of induced full-thickness macular or retinal holes Potential reduction of the use of vital dyes
Retinal detachment		
	Vitrectomy	Assessment of subretinal fluid Identification of subclinical MH Delimitation of PVR and assistance during dissection Evidence of subretinal migration of heavy liquids or silicone oil Assistance in removal of subretinal heavy liquids or silicone oil
Proliferative Diabetic Retinopathy		
	Vitrectomy	Evidence of membranes Identification of surgical planes Delineate areas of tractive retinal detachment Topographical localization of hemorrhages (Subhyaloid, sub-ILM, subretinal) Diagnose and assess (volume and ultrastructure) of center involved or clinically significant macular edema. Assist during ILM peeling with the previously listed advantages in the section of vitreomacular interface disorders of this table.
Pediatric retinal surgery		
Retinopathy of prematurity	Examination under general anesthesia + Vitrectomy	Delineation of surgical planes Assessment of preexisting/induced full-thickness macular or retinal holes
Retinoblastoma	Examination under general anesthesia	Two-dimensional assessment of masses Identification of subretinal fluid Assessment of calcification
Shaken baby syndrome	Examination under general anesthesia +/- Vitrectomy	Assessment of full-thickness macular or retinal holes Topographical localization of hemorrhages (Subhyaloid, sub-ILM, subretinal)
Other vitreoretinal conditions		
Chorioretinal biopsy		Identification of surgical planes Delineation of normal and pathological tissue
Retinal prostheses	Vitrectomy	Real-time visualization of aspiration needle/surgical instruments Assistance during the positioning of the implant

ILM: Internal limiting membrane; ERM: Epiretinal membrane; MH: Macular hole; PVR: Proliferative vitreoretinopathy

Table 1.
Surgical implications of microscope-integrated optical coherence tomography.

2.1.1 Macular hole

The dynamic nature of the internal limiting membrane (ILM) peeling has been evidenced with MIOCT [39, 46]. Modifications of the retinal ultrastructure and geometry of MH during the ILM peeling have been described [17, 31, 42, 47–49]. Assessment of the border of the ILM peeling (**Figure 2**), residual ILM, retinal trauma (**Figure 3**), and anatomical closure (**Figure 4**) can be easily made in a real-time fashion [39, 46]. A volume increase and base area increase of MH, with a concurrent decrease in the apex height, have been evidenced following ILM peeling

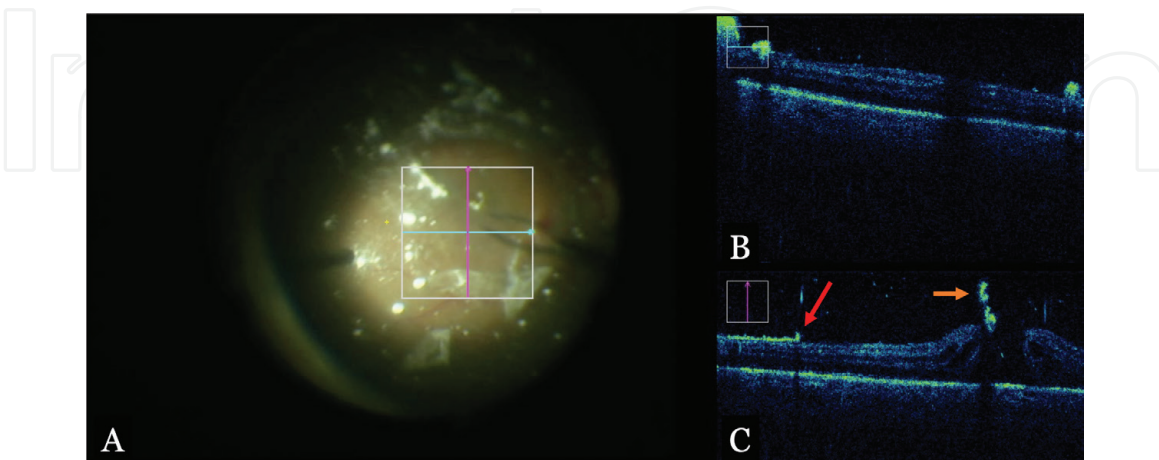


Figure 2.
Intraoperative assessment after internal limiting membrane (ILM) peeling with preservative-free triamcinolone of a macular hole (MH). (A) Color screenshot of the surgical video that delineates the area of the ILM peeling. White triamcinolone particles can be easily seen. (B) Horizontal scan just inferior to the MH. (C) the two-dimensional vertical image scan evidences the transitional zone of the ILM peeling; the red arrow demonstrates the border of the ILM tear inferiorly. Hyperreflective foci correlating with triamcinolone particles can be appreciated in the vitreous cavity, and an ILM remnant stained with triamcinolone is evidenced in the inferior border of the MH (orange arrow).

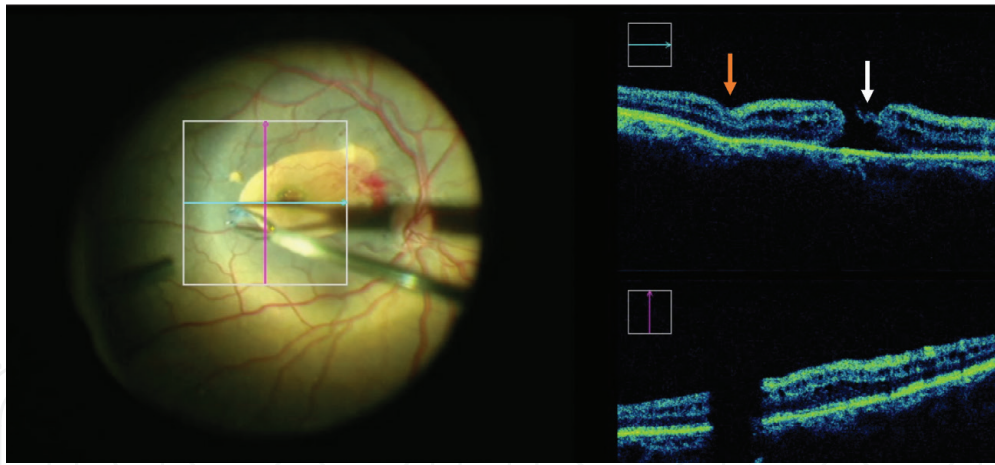


Figure 3.
Intraoperative scan after internal limiting membrane (ILM) peeling of a macular hole (MH). The imaging scan demonstrates a residual fragment of ILM in the nasal border of the MH (white arrow). Additionally, an indentation in the internal retinal layers is evidenced secondary to excessive manipulation of that area during the ILM peeling procedure (orange arrow). Preretinal hemorrhages are seen superotemporal to the optic nerve head.

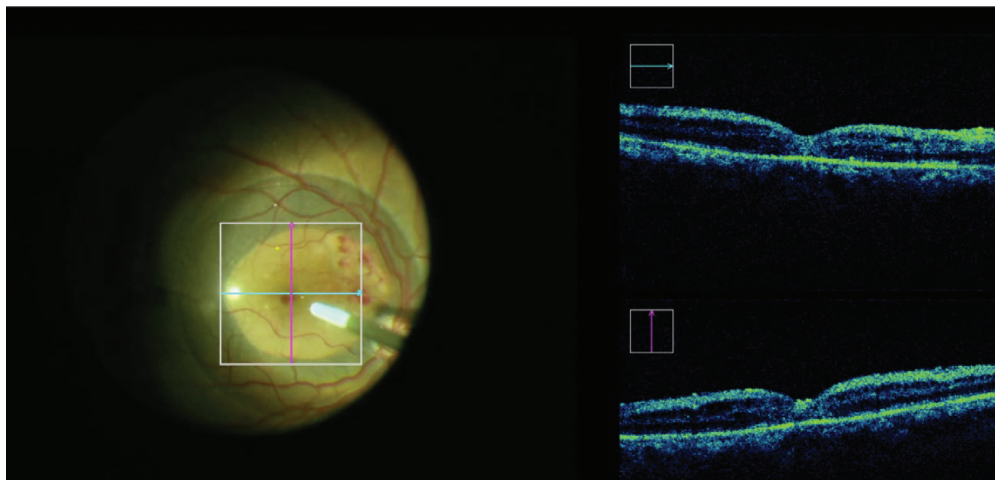


Figure 4.
Optical coherence tomography scan under the heavy liquid after internal limiting membrane (ILM) peeling. Anatomic closure was achieved after performing a gently passive suction maneuver with a 25G silicone-tipped cannula.

[39, 46, 47, 50]. Additionally, the distance between ellipsoid zone and RPE and the lateral extension of this expansion have been documented and associated with anatomical and functional outcomes [16, 17, 41, 42, 47, 50–52].

2.1.2 Vitreomacular traction syndrome

The use of MIOCT for these cases poses a potentially useful role. Release of the traction can be confirmed; dynamic anatomical modifications, changes in outer retinal relations of ellipsoid zone and EPR and residual membranes, and formations of full-thickness macular or retinal holes can be identified as well [15, 17, 20, 33].

2.1.3 Epiretinal membrane

Outer retinal modifications have also been documented following ERM and/or ILM peel in ERM. A decrease in subretinal reflectivity appreciated after these procedures correlates with a considerable expansion of the distance between the ellipsoid zone and the RPE [16, 17, 42, 47, 51]. These changes have been also

associated with visual and anatomical recovery rates; however, further studies are needed to confirm this correlation [51].

2.2 Retinal detachment

The surgical benefit of real-time OCT imaging in retinal detachment (RD) repair may not be straightforward. However, intraoperative anatomical features could be relevant for the prognosis of these cases [17, 24, 33]. Additionally, complex cases with severe vitreoproliferative retinopathy could be assisted with real-time imaging and successfully addressed (**Figure 5B**). It has been evidenced that nearly all eyes undergoing surgery with perfluorocarbon liquid tamponade have some degree of subretinal fluid (**Figure 5A,B**) [24, 53]. According to the literature, foveal microarchitecture, the amount of submacular fluid, and the integrity of the ellipsoid zone following application of perfluorocarbon liquid may be of significance for the visual outcomes [17, 24, 33]. In cases where subretinal migration of perfluorocarbon liquid is present, correct visualization of the liquid bubbles and complete removal can be verified [53]. Detection of subclinical MH, occult membranes, or retinal breaks is possible with this technology, an advantage that modifies the surgical procedure and has an impact on the patient outcome [33].

2.3 Proliferative diabetic retinopathy

Vitreoretinal proliferation in diabetic retinopathy poses some of the most complex cases of vitreoretinal surgeries. The use of MIOCT can facilitate the correct

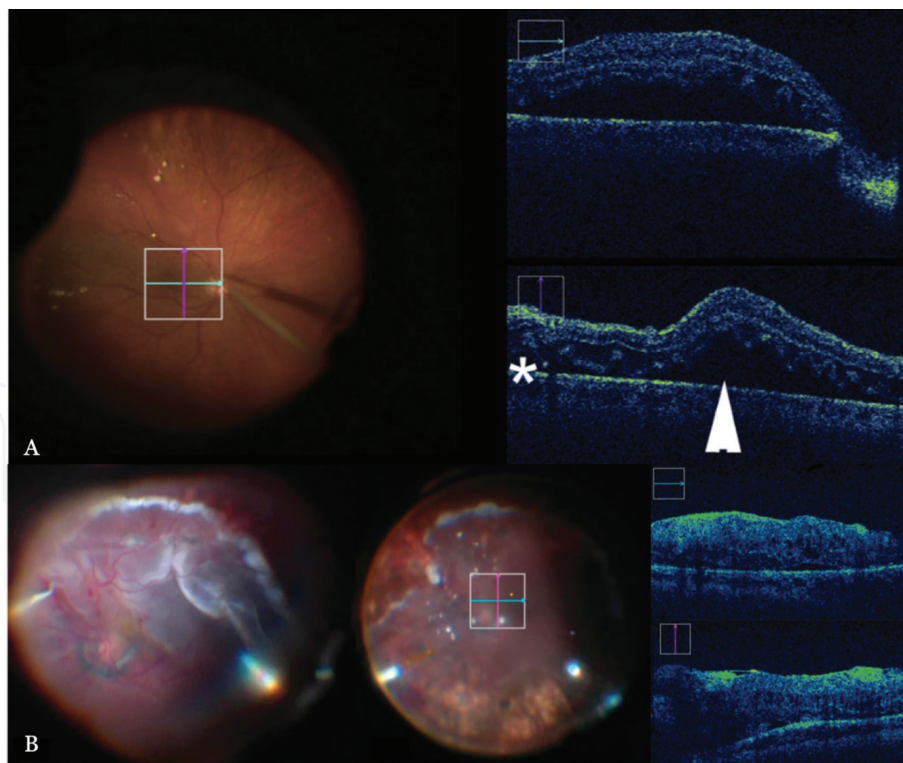


Figure 5. Color photographs and microscope-integrated optical coherence tomography (MIOCT) scans of retinal detachment surgeries. (A) Real-time horizontal and vertical MIOCT scans during retinal detachment repair under perfluorocarbon liquid evidence the progressive displacement of subretinal fluid (arrowhead) and a discrete subclinical remnant of subretinal fluid under the perfluorocarbon liquid (asterisk) [33]. (B) Complex retinal detachment repair. Color photograph evidences severe vitreoretinal proliferation and subretinal band; endodiathermy has been applied superiorly (left image). Visualization under perfluorocarbon liquid after retinectomy shows a flattened retina (center image). Horizontal and vertical MIOCT scans evidence the reattached retina with scant subclinical subretinal fluid and some residual focal membranes and retinal thickening (right images) [65].

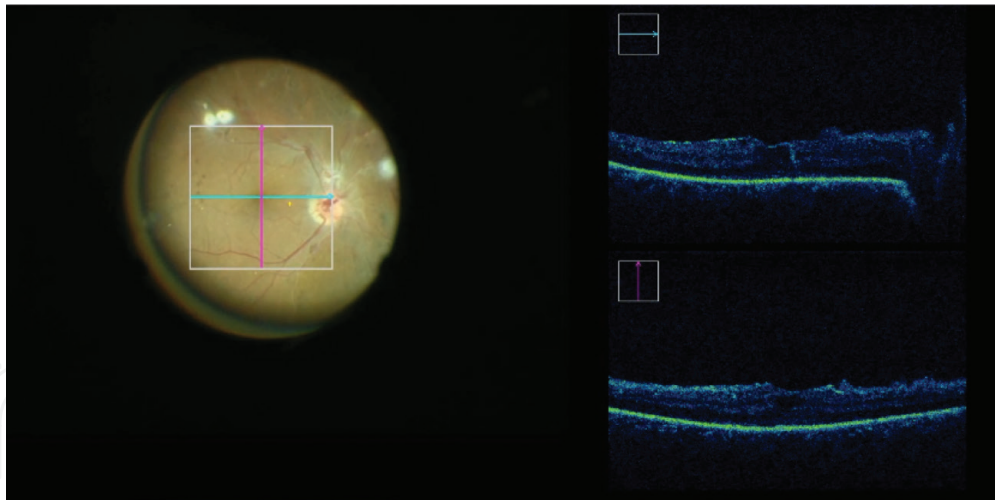


Figure 6.
Macular scan after pars plana vitrectomy in a patient with proliferative diabetic retinopathy. The b-scans evidence minor cystic edema and preserved macular architecture. After image assessment, the surgeon decided not to perform internal limiting membrane peeling.

identification and visualization of the surgical planes to aid membrane dissection, delineate areas of retinal detachment, or topographically localize hemorrhages (e.g., subhyaloid, sub-ILM, or subretinal hemorrhages) [31, 33, 54]. Cases of proliferative diabetic retinopathy with clinically significant macular edema can be optimally assessed to decide if an ILM peeling is needed (**Figure 6**) [55–58]. These clinical circumstances could potentially represent a scenario in which the use of MIOCT can facilitate surgery and enhance outcomes.

2.4 Pediatric retinal surgery

The age and cooperation of the pediatric patients make MIOCT a potentially useful tool to deploy in the examination under general anesthesia, in order to improve the understanding of pathologies such as retinopathy of prematurity (ROP), shaken baby syndrome, or any other vitreoretinal conditions that do not necessarily require VPP, like retinoblastoma [59–62]. Retinoschisis, preretinal structures and membranes, as well as lamellar or full-thickness retinal holes, which were not previously appreciated during an office examination, can be evidenced in ROP or shaken baby syndromes, respectively [59, 62].

2.5 Other vitreoretinal conditions

Chorioretinal biopsy cases could be benefitted by the correct identification of the anatomical layers conforming the surgical plane and differentiation between normal tissue and lesion. The aid of MIOCT can impact on retinal prostheses implantation (e.g., Argus II implants for retinitis pigmentosa), providing precise information of the implant location and allowing a correct positioning [33, 63, 64].

3. Conclusion

The rapid technological evolution of our era has allowed us to consider this potentially powerful field of imaging to further improve retinal surgery. Evidence has demonstrated that MIOCT is feasible and useful in the operating theater, providing valuable information to evaluate the surgical field in real time which can alter surgical decision-making, positively impact on short- and long-term

outcomes, and possibly promote the development of new surgical techniques. In the near future, improvements in OCT-compatible surgical instrumentation, feedback systems, and software are warranted to achieve an integration of this technology to our operating theaters.

Conflict of interest

The authors have no commercial or economic conflict of interest to disclose.

Author details

Jesus Hernan Gonzalez-Cortes*, Abraham Olvera-Barrios,
Jesus Emiliano Gonzalez-Cantu and Jesus Mohamed-Hamsho

Universidad Autonoma de Nuevo Leon, Ophthalmology Department, Faculty of Medicine and University Hospital “Dr. Jose Eleuterio Gonzalez”, Monterrey, Nuevo León, Mexico

*Address all correspondence to: drjesusgzz@gmail.com

IntechOpen

© 2019 The Author(s). Licensee IntechOpen. This chapter is distributed under the terms of the Creative Commons Attribution License (<http://creativecommons.org/licenses/by/3.0>), which permits unrestricted use, distribution, and reproduction in any medium, provided the original work is properly cited. 

References

- [1] Barraquer JI. The history of the microscope in ocular surgery. *Journal of Microsurgery*. 1980;**1**:288-299
- [2] Roper-Hall MJ. Microsurgery in ophthalmology. *The British Journal of Ophthalmology*. 1967;**51**(6):408-414. DOI: 10.1136/bjo.51.6.408
- [3] Littmann H. Ein neues Operations-Mikroskop. *Klinische Monatsblätter für Augenheilkunde*. 1954;**124**:473-476
- [4] Harms H, Mackensen G. *Augenoperationen unter dem Mikroskop*. Tübingen. Verlag. Stuttgart. 1966. *Ocular Surgery under the microscope*. Year Book Medical Publishers Chicago, 1967
- [5] Dekking H. Use of the binocular microscope in eye operations. *Archives of Ophthalmology*. 1956;**55**:114-117
- [6] Keeler CR. 150 years since Babbage's ophthalmoscope. *Archives of Ophthalmology*. 1997;**115**(11):1456-1457
- [7] Parel JM, Machemer R, Aumayr W. A new concept for vitreous surgery. 5. An automated operating microscope. *American Journal of Ophthalmology*. 1974;**77**(2):161-168. DOI: 10.1016/0002-9394(74)90668-0
- [8] Huang D, Swanson EA, Lin CP, et al. Optical coherence tomography. *Science*. 1991;**254**(5035):1178-1181. DOI: 10.1002/jcp.24872.The
- [9] Hee MR, Puliafito CA, Wong C, et al. Optical coherence tomography of macular holes. *Ophthalmology*. 1995;**102**(5):748-756. DOI: 10.1016/S0161-6420(95)30959-1
- [10] Chauhan DS, Marshall J. The interpretation of optical coherence tomography images of the retina. *Investigative Ophthalmology and Visual Science*. 1999;**40**:2332-2342
- [11] Adhi M, Duker JS. Optical coherence tomography-current and future applications. *Current Opinion in Ophthalmology*. 2013;**24**(3):213-221. DOI: 10.1097/ICU.0b013e32835f8bf8
- [12] Chen TC, Cense B, Pierce MC, et al. Spectral domain optical coherence tomography ultra-high speed, ultra-high resolution ophthalmic imaging. *Archives of Ophthalmology*. 2005;**123**(12):1715-1720. DOI: 10.1001/archophth.123.12.1715
- [13] Joshi MM, Trese MT, Capone A. Optical coherence tomography findings in stage 4A retinopathy of prematurity. A theory for visual variability. *Ophthalmology*. 2006;**13**(4):657-660. DOI: 10.1016/j.ophtha.2006.01.007
- [14] Vinekar A, Sivakumar M, Shetty R, et al. A novel technique using spectral-domain optical coherence tomography (Spectralis, SD-OCT+HRA) to image supine non-anaesthetized infants: Utility demonstrated in aggressive posterior retinopathy of prematurity. *Eye*. 2010;**24**(2):379-382. DOI: 10.1038/eye.2009.313
- [15] Dayani PN, Maldonado R, Farsiu S, Toth CA. Intraoperative use of handheld spectral domain optical coherence tomography imaging in macular surgery. *Retina*. 2009;**29**(10):1457-1468. DOI: 10.1097/IAE.0b013e3181b266bc
- [16] Ray R, Baraano DE, Fortun JA, et al. Intraoperative microscope-mounted spectral domain optical coherence tomography for evaluation of retinal anatomy during macular surgery. *Ophthalmology*. 2011;**118**(11):2212-2217. DOI: 10.1016/j.ophtha.2011.04.012
- [17] Ehlers JP, Dupps WJ, Kaiser PK, et al. The prospective intraoperative and perioperative ophthalmic imaging with optical coherence tomography

- (PIONEER) study: 2-year results. *American Journal of Ophthalmology*. 2014;**158**(5):999-1007. DOI: 10.1016/j.ajo.2014.07.034
- [18] Chavala SH, Farsiu S, Maldonado R, Wallace DK, Freedman SF, Toth CA. Insights into advanced retinopathy of prematurity using handheld spectral domain optical coherence tomography imaging. *Ophthalmology*. 2009;**116**(12):2448-2456. DOI: 10.1016/j.optha.2009.06.003
- [19] Maldonado RS, Izatt JA, Sarin N, et al. Optimizing hand-held spectral domain optical coherence tomography imaging for neonates, infants, and children. *Investigative Ophthalmology and Visual Science*. 2010;**51**(5):2678-2685. DOI: 10.1167/iovs.09-4403
- [20] Ehlers JP, Tam T, Kaiser PK, Martin DF, Smith GM, Srivastava SK. Utility of intraoperative optical coherence tomography during vitrectomy surgery for vitreomacular traction syndrome. *Retina*. 2014;**34**(7):1341-1346. DOI: 10.1097/IAE.0000000000000123
- [21] Branchini LA, Gurley K, Duker JS, Reichel E. Use of handheld intraoperative spectral-domain optical coherence tomography in a variety of vitreoretinal diseases. *Ophthalmic Surgery, Lasers and Imaging Retina*. 2016;**47**(1):49-54. DOI: 10.3928/23258160-20151214-07
- [22] Ehlers JP, Kernstine K, Farsiu S, Sarin N, Maldonado R, Toth CA. Analysis of pars plana vitrectomy for optic pit-related maculopathy with intraoperative optical coherence tomography: A possible connection with the vitreous cavity. *Archives of Ophthalmology*. 2011;**129**(11):1483-1486. DOI: 10.1001/archophthalmol.2011.316
- [23] Binder S, Falkner-Radler CI, Hauger C, Matz H, Glittenberg C. Feasibility of intrasurgical spectral-domain optical coherence tomography. *Retina*. 2011;**31**(7):1332-1336. DOI: 10.1097/IAE.0b013e3182019c18
- [24] Ehlers JP, Ohr MP, Kaiser PK, Srivastava SK. Novel microarchitectural dynamics in rhegmatogenous retinal detachments identified with intraoperative optical coherence tomography. *Retina*. 2013;**33**(7):1428-1434. DOI: 10.1097/IAE.0b013e31828396b7
- [25] Boppart SA, Bouma BE, Pitris C, et al. Intraoperative assessment of microsurgery with three-dimensional optical coherence tomography. *Radiology*. 1998;**208**(1):81-86. DOI: 10.1148/radiology.208.1.9646796
- [26] Lankenau E, Klinger D, Winter C, et al. Combining optical coherence tomography (OCT) with an operating microscope. *Advances in Medical Engineering*. 2007;**114**:343-348. DOI: 10.1007/978-3-540-68764-1_57
- [27] Tao YK, Ehlers JP, Toth CA, Izatt JA. Intraoperative spectral domain optical coherence tomography for vitreoretinal surgery. *Optics Letters*. 2010;**35**(20):3315-3317. DOI: 10.1364/OL.35.003315
- [28] Geerling G, Müller M, Winter C, et al. Intraoperative 2-dimensional optical coherence tomography as a new tool for anterior segment surgery. *Archives of Ophthalmology*. 2005;**123**(2):253-257. DOI: 10.1001/archophth.123.2.253
- [29] Steven P, Le Blanc C, Velten K, et al. Optimizing descemet membrane endothelial keratoplasty using intraoperative optical coherence tomography. *JAMA Ophthalmology*. 2013;**131**(9):1135-1142. DOI: 10.1001/jamaophthalmol.2013.4672
- [30] Ehlers JP, Kaiser PK, Srivastava SK. Intraoperative optical coherence tomography using the RESCAN 700: Preliminary results from the DISCOVER study. *The British Journal of*

- Ophthalmology. 2014;**98**(10):1329-1332. DOI: 10.1136/bjophthalmol-2014-305294
- [31] Ehlers JP, Goshe J, Dupps WJ, et al. Determination of feasibility and utility of microscope-integrated optical coherence tomography during ophthalmic surgery: The DISCOVER study RESCAN results. *JAMA Ophthalmology*. 2015;**133**(10):1124-1132. DOI: 10.1001/jamaophthalmol.2015.2376
- [32] Cost B, Goshe JM, Srivastava S, Ehlers JP. Intraoperative optical coherence tomography-assisted descemet membrane endothelial keratoplasty in the DISCOVER study. *American Journal of Ophthalmology*. 2015;**160**(3):430-437. DOI: 10.1016/j.ajo.2015.05.020
- [33] Ehlers JP, Modi YS, Pecun PE, et al. The DISCOVER study 3-year results: Feasibility and usefulness of microscope-integrated intraoperative OCT during ophthalmic surgery. *Ophthalmology*. 2018;**125**(7):1014-1027. DOI: 10.1016/j.ophtha.2017.12.037
- [34] Khan M, Srivastava SK, Reese JL, Shwani Z, Ehlers JP. Intraoperative OCT-assisted surgery for proliferative diabetic retinopathy in the DISCOVER study. *Ophthalmology Retina*. 2018;**2**(5):411-417. DOI: 10.1016/j.oret.2017.08.020
- [35] Falkner-Radler CI, Glittenberg C, Gabriel M, Binder S. Intrasurgical microscope-integrated spectral domain optical coherence tomography-assisted membrane peeling. *Retina*. 2015;**35**(10):2100-2106. DOI: 10.1097/IAE.0000000000000596
- [36] Hahn P, Migacz J, O'Connell R, et al. Preclinical evaluation and intraoperative human retinal imaging with a high-resolution microscope-integrated spectral domain optical coherence tomography device. *Retina*. 2013;**33**(7):1328-1337. DOI: 10.1097/IAE.0b013e3182831293
- [37] Leisser C, Hackl C, Hirnschall N, et al. Visualizing macular structures during membrane peeling surgery with an intraoperative spectral-domain optical coherence tomography device. *Ophthalmic Surgery, Lasers and Imaging Retina*. 2016;**47**(4):328-332. DOI: 10.3928/23258160-20160324-04
- [38] Pfau M, Michels S, Binder S, Becker MD. Clinical experience with the first commercially available intraoperative optical coherence tomography system. *Ophthalmic Surgery, Lasers and Imaging Retina*. 2015;**46**(10):1001-1008. DOI: 10.3928/23258160-20151027-03
- [39] Ramírez-Estudillo JA, Sánchez-Ramos JA, Pérez-Montaña CR, González-Cortés JH. Utilidad transquirúrgica de la tomografía de coherencia óptica en cirugía vítreo-retiniana. *Cirugía y Cirujanos*. 2017;**85**(1):21-26. DOI: 10.1016/j.circir.2016.04.002
- [40] Ehlers JP, Khan M, Petkovsek D, et al. Outcomes of intraoperative OCT-assisted epiretinal membrane surgery from the PIONEER study. *Ophthalmology Retina*. 2018;**2**(4):263-267. DOI: 10.1016/j.oret.2017.05.006
- [41] Ehlers JP, Han J, Petkovsek D, Kaiser PK, Singh RP, Srivastava SK. Membrane peeling-induced retinal alterations on intraoperative OCT in vitreomacular interface disorders from the PIONEER study. *Investigative Ophthalmology and Visual Science*. 2015;**56**(12):7324-7330. DOI: 10.1167/iops.15-17526
- [42] Nam DH, Desouza PJ, Hahn P, et al. Intraoperative spectral domain optical coherence tomography imaging after internal limiting membrane peeling in idiopathic epiretinal membrane with connecting strands. *Retina*. 2015;**35**(8):1622-1630. DOI: 10.1097/IAE.0000000000000534

- [43] Farah ME, Maia M, Penha FM, Rodrigues EB. The use of vital dyes during vitreoretinal surgery-chromovitrectomy. *Developments in Ophthalmology*. 2015;**55**:365-375. DOI: 10.1159/000438963
- [44] Salvetti AP, Patrício MI, Barnard AR, Orlans HO, Hickey DG, MacLaren RE. Impact of vital dyes on cell viability and transduction efficiency of AAV vectors used in retinal gene therapy surgery: An in vitro and In vivo analysis. *Translational Vision Science & Technology*. 2017;**6**(4):4. DOI: 10.1167/tvst.6.4.4
- [45] Penha FM, Pons M, Costa Ede P, et al. Effect of vital dyes on retinal pigmented epithelial cell viability and apoptosis: Implications for chromovitrectomy. *Ophthalmologica*. 2013;**230**(2):41-50. DOI: 10.1159/000354251
- [46] Gonzalez-Cortes JH, Estudillo AR, Sanchez-Ramos JA, Bages-Rousselon Y, Fernandez-Mar M, Mohamed-Hamsho J. Anatomical changes of full-thickness macular hole documented by microscope-integrated spectral-domain optical coherence tomography. *Ophthalmic Surgery, Lasers and Imaging Retina*. 2018;**49**(9):e105-e111. DOI: 10.3928/23258160-20180907-17
- [47] Ehlers JP, Xu D, Kaiser PK, Singh RP, Srivastava SK. Intrasurgical dynamics of macular hole surgery: An assessment of surgery-induced ultrastructural alterations with intraoperative optical coherence tomography. *Retina*. 2014;**34**(2):213-221. DOI: 10.1097/IAE.0b013e318297daf3
- [48] Hahn P, Migacz J, O'Connell R, Izatt JA, Toth CA. Unprocessed real-time imaging of vitreoretinal surgical maneuvers using a microscope-integrated spectral-domain optical coherence tomography system. *Graefes' Archive for Clinical and Experimental Ophthalmology*. 2013;**251**(1):213-220. DOI: 10.1007/s00417-012-2052-2
- [49] Hahn P, Carrasco-Zevallos O, Cunefare D, et al. Intrasurgical human retinal imaging with manual instrument tracking using a microscope-integrated spectral-domain optical coherence tomography device. *Translational Vision Science & Technology*. 2015;**4**(4):1. DOI: 10.1167/tvst.4.4.1
- [50] Xu D, Yuan A, Kaiser PK, et al. A novel segmentation algorithm for volumetric analysis of macular hole boundaries identified with optical coherence tomography. *Investigative Ophthalmology and Visual Science*. 2013;**54**:163-169. DOI: 10.1167/iovs.12-10246
- [51] Ehlers JP, Itoh Y, Xu LT, Kaiser PK, Singh RP, Srivastava SK. Factors associated with persistent subfoveal fluid and complete macular hole closure in the PIONEER study. *Investigative Ophthalmology and Visual Science*. 2015;**56**(2):1141-1146. DOI: 10.1167/iovs.14-15765
- [52] Itoh Y, Vasanji A, Ehlers JP. Volumetric ellipsoid zone mapping for enhanced visualisation of outer retinal integrity with optical coherence tomography. *The British Journal of Ophthalmology*. 2016;**100**(3):295-299. DOI: 10.1136/bjophthalmol-2015-307105
- [53] Smith AG, Cost BM, Ehlers JP, Intraoperative OCT-assisted subretinal perfluorocarbon liquid removal in the DISCOVER study. *Ophthalmic Surgery, Lasers and Imaging Retina*. 2015;**49**(9):964-966. DOI: 10.3928/23258160-20151008-10
- [54] Oellers P, Mahmoud TH. Surgery for proliferative diabetic retinopathy: New tips and tricks. *Journal of Ophthalmic and Vision Research*. 2016;**11**(1):93-99. DOI: 10.4103/2008-322X.180697

- [55] Bhagat N, Grigorian RA, Tutela A, Zarbin MA. Diabetic macular edema: Pathogenesis and treatment. *Survey of Ophthalmology*. 2009;**54**(1):1-32. DOI: 10.1016/j.survophthal.2008.10.001
- [56] Dehghan MH, Salehipour M, Naghib J, Babaeian M, Karimi S, Yaseri M. Pars plana vitrectomy with internal limiting membrane peeling for refractory diffuse diabetic macular edema. *Journal of Ophthalmic and Vision Research*. 2010;**5**(3):162-167. DOI: 10.1097/IAE.0b013e31816102f2
- [57] Patel JI, Hykin PG, Schadt M, Luong VY, Fitzke F, Gregor ZJ. Pars plana vitrectomy with and without peeling of the inner limiting membrane for diabetic macular edema. *Retina*. 2006;**26**(1):5-13. DOI: 10.1097/00006982-200601000-00002
- [58] Gandorfer A, Messmer EM, Ulbig MW, Kampik A. Resolution of diabetic macular edema after surgical removal of the posterior hyaloid and the inner limiting membrane. *Retina*. 2000;**20**(2):126-133. DOI: 10.1097/00006982-200002000-00004
- [59] Rachitskaya AV, Yuan A, Marino MJ, Reese J, Ehlers JP. Intraoperative OCT imaging of the Argus II retinal prosthesis system. *Ophthalmic Surgery, Lasers and Imaging Retina*. 2016;**47**(11):999-1003. DOI: 10.3928/23258160-20161031-03
- [60] Browne AW, Ehlers JP, Sharma S, Srivastava SK. Intraoperative optical coherence tomography-assisted chorioretinal biopsy in the DISCOVER study. *Retina*. 2017;**37**(11):2183-2187. DOI: 10.1097/IAE.0000000000001522
- [61] Seider MI, Tran-Viet D, Toth CA. Macular pseudo-hole in shaken baby syndrome: Underscoring the utility of optical coherence tomography under anesthesia. *Retinal Cases and Brief Reports*. 2016;**10**(3):283-285. DOI: 10.1097/ICB.0000000000000251
- [62] Rootman DB, Gonzalez E, Mallipatna A, et al. Hand-held high-resolution spectral domain optical coherence tomography in retinoblastoma: Clinical and morphologic considerations. *The British Journal of Ophthalmology*. 2013;**97**(1):59-65. DOI: 10.1136/bjophthalmol-2012-302133
- [63] Cao C, Markovitz M, Ferenczy S, Shields CL. Hand-held spectral-domain optical coherence tomography of small macular retinoblastoma in infants before and after chemotherapy. *Journal of Pediatric Ophthalmology and Strabismus*. 2014;**51**(4):230-234. DOI: 10.3928/01913913-20140603-01
- [64] Campbell JP, Nudleman E, Yang J, et al. Handheld optical coherence tomography angiography and ultra-wide-field optical coherence tomography in retinopathy of prematurity. *JAMA Ophthalmology*. 2017;**135**(9):977-981. DOI: 10.1001/jamaophthalmol.2017.2481
- [65] Ehlers JP, Uchida A, Srivastava SK. The integrative surgical theater: Combining intraoperative optical coherence tomography and 3D digital visualization for Vitreoretinal surgery in THE DISCOVER study. *Retina*. 2018;**38**(Suppl 1):S88-S96. DOI: 10.1097/IAE.0000000000001999