

We are IntechOpen, the world's leading publisher of Open Access books Built by scientists, for scientists

4,800

Open access books available

122,000

International authors and editors

135M

Downloads

Our authors are among the

154

Countries delivered to

TOP 1%

most cited scientists

12.2%

Contributors from top 500 universities



WEB OF SCIENCE™

Selection of our books indexed in the Book Citation Index
in Web of Science™ Core Collection (BKCI)

Interested in publishing with us?
Contact book.department@intechopen.com

Numbers displayed above are based on latest data collected.

For more information visit www.intechopen.com



The Established and Evolving Role of Nailfold Capillaroscopy in Connective-Tissue Disease

Matthew J.S. Parker and Neil W. McGill

Abstract

Nailfold capillaroscopy (NFC) is a low-cost, non-invasive, rapid, highly specific and reproducible investigation well established in the diagnosis of systemic sclerosis and related conditions. This chapter will detail the relevant underlying scientific principles that underpin the investigation, the methods for performing NFC, the range of abnormalities that can be present and the currently available classification criteria before moving on to discuss the various established and emerging applications as relevant to the connective tissue diseases. In addition to its role in the diagnosis of SSc, highlighted by its inclusion in the most recent ACR/EULAR consensus classification criteria, NFC has been shown to predict disease activity, many organ-specific complications such as digital ulcers, pulmonary hypertension and interstitial lung disease, and even mortality. It is emerging as a useful investigation in other CTDs characterised by microvasculopathy, such as in the idiopathic inflammatory myopathies and mixed connective tissue disease, as well as being studied as a serial investigation in patients to act as a potential biomarker and measure of treatment efficacy. NFC can contribute to the earlier identification of patients with CTDs with clinically important complications and if applied accurately, therefore, can help improve outcomes in these often challenging diseases.

Keywords: nailfold capillaroscopy, systemic sclerosis, polymyositis, dermatomyositis

1. Introduction

The technique of nailfold capillaroscopy (NFC) was first described almost 100 years ago by Brown and O'Leary, but its utility in connective tissue disease was first truly recognised and demonstrated through the work of Maricq et al. in the 1970s and 1980s [1–3]. It is now established as a low-cost, non-invasive, highly specific, reproducible, and rapid investigation in the diagnostic workup of scleroderma-spectrum disorders and, tellingly, was included in the most recent ACR/EULAR systemic sclerosis classification criteria [4]. As a consequence, there has never been more interest in capillaroscopy and contemporary research is actively evaluating both the additional utility of NFC within scleroderma-spectrum disorders as well as in other diseases characterised by microvasculopathy. This chapter will summarise the techniques and principles of NFC, its established role, and explore the emerging roles for NFC with a focus on connective-tissue diseases.

2. What is nailfold capillaroscopy?

As the name implies, NFC involves visualising the nailfold capillaries. Capillaries are the smallest blood vessels, with a size that normally allows the passage of a single red blood cell at a time. They form a complex network of “loops” (U-shaped structures commonly compared to hairpins) with an afferent (arterial) and efferent (venous) limb and an apex connecting the two (see **Figure 1**). These small vessels aid the diffusion of gases and the movement of substrates for and non-essential by-products of cellular respiration. The skin has a rich network of capillaries which are usually orientated vertically, distributing blood from the deep cutaneous arterioles to the surface skin and then back down again to the venous plexus. In contrast, at the nailfolds, these capillary loops lie horizontally which allows a visualisation along the length of their course. To be strictly accurate, we are not able to visualise the capillaries themselves, the thin walls of which are essentially transparent, but instead the column of red blood cells. Over many years researchers have identified abnormalities in the structure and arrangement of these capillaries present in certain diseases characterised by microvasculopathy. These abnormalities are discussed in more detail later.

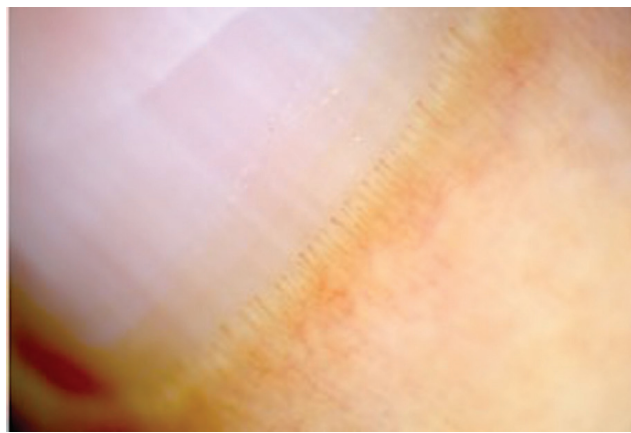


Figure 1.
Normal nailfold capillaries. The typical appearance of capillary “loops”.

3. Nailfold capillaroscopy techniques

NFC consists of two interrelated elements, image acquisition and image interpretation, and these will be discussed in turn in this and the following sections.

3.1 General principles

For all techniques, there are a number of general principles that should be observed. Firstly, to minimise the potential for variability in findings due to vasoconstriction and altered digital perfusion, capillaroscopy should be performed in a warm environment, with most studies suggesting a 15–30 minute period of acclimatisation to “room temperature”, usually around 20°C. Subjects should be advised to avoid smoking, caffeine or medications (where possible) that could cause peripheral vasoconstriction immediately prior to the investigation. Secondly, visualisation of the nailfold capillaries is aided by the use of a gel or oil interface to reduce surface reflection from the device light source. The more commonly used substances are clear or lightly coloured oils (such as paraffin or light olive oil) or lubricant jellies, applied in the region of the nailbed and cuticle immediately prior to visualisation. There are an increasing number of differing techniques for acquiring images and we will discuss the most frequently employed.

3.2 Widefield stereomicroscopy

Widefield stereomicroscopy (WSM; see **Figure 2a**) is the original technique pioneered by Maricq et al. and is still considered one of the two “gold-standard” techniques [2, 3, 5]. Each nailfold (usually of just the index-little finger of each hand, as thumbs can be difficult to orientate under the microscope) is examined at around 20-fold magnification which allows for a panoramic view of the entire nailfold. The microscope allows close control of depth of focus. The microscope can be combined with a camera and other digital equipment to allow recording of images and assist real-time explanation of investigation findings. The technique typically takes around 5 minutes to complete.

3.3 High-magnification videocapillaroscopy

Nailfold videocapillaroscopy (NVC; see **Figure 2b**) is the other “gold-standard” technique and is now the most frequent technique used in capillaroscopy research. Either a fixed or handheld imaging device is used which, when combined with computer software, affords a highly magnified view of the nailfold at 200–300-fold. This technique allows for very detailed images but an important consequence is that not all the nailfold can be visualised at the same time. The impact of this can be particularly relevant to studies looking at longitudinal nailfold changes (see later), as it can be difficult at subsequent study visits to visualise the exact same region of the nailfold. There is software that can ‘stitch’ together images using digital picture recognition and therefore produce a panoramic nailfold image made up of smaller high magnification images, first used by Herrick et al., which can mitigate this issue [6]. NVC can take substantially longer than other techniques if all fingers are studied (20–30 minutes), and consequently many studies restrict image acquisition to a single finger in both hands (most commonly the ring finger). An important potential downside of this compromise is that nailfold changes can vary markedly between even adjacent fingers. NVC has been shown in multiple studies to have good intra- and inter-observer variability and/or concordance and correlates well with WSM [6–9].

3.4 Handheld devices—ophthalmoscopes, dermatoscopes, USB microscopes etc.

Two important factors that have limited accessibility to NFC and its use in the broader rheumatology community are the relative (expensive) cost and the lack of portability of the two gold-standard techniques. There are clear advantages to being able to take a test to the “bedside” rather than having to bring a patient to the test, which is often only currently available at a small number of specialist institutions. Fortunately, there are a number of low cost and handheld devices such as dermatoscopes and ophthalmoscopes which achieve a good visualisation of the nailfolds at around 10–20-fold magnification (see **Figure 2c**). A number of studies directly comparing these techniques with WSM and NVC have found a reassuring concordance [10–12]. In particular, although the rate of “unclassifiable” images is higher, ample diagnostically relevant findings can be elicited, even if more subtle changes can be missed. Rapidly improving technology, particularly with the availability of USB microscopes or attachments for smartphones, can already achieve similar magnification to NVC and record images. This infers that these devices are going to become more commonplace [11]. An additional advantage with the handheld devices is that they can be easier to use in patients with finger deformities and in thumbs (or even toes) which are often not visualised in other techniques, although the additional information gleaned from these is not yet of clear clinical utility.

4. Nailfold capillary abnormalities

Before proceeding to discuss nailfold capillary abnormalities, it is important to note that there is a surprisingly broad range of capillary appearances between or even within ‘normal’ subjects and the disease controls used in research settings [13]. It can sometimes be difficult to be certain whether subtle changes are of significance or not but with increasing experience this distinction becomes somewhat easier. In practice, most examinations will clearly fall into a normal or definitely abnormal category and for those that do not there is usually extra information from a history, examination and additional diagnostic tests that can help contextualise the capillaroscopy results.

The abnormal features that originally defined Maricq’s “scleroderma-dermatomyositis pattern (SD-pattern) remain the most important to examine for [2]. These consist of giant (significantly enlarged) capillaries, avascular areas (also referred to as capillary “drop-out”), and microhaemorrhages. Other abnormalities are recognised and include excessively tortuous capillaries, unusually shaped capillaries (“bushy” or “arborized” capillaries) and cuticular hypertrophy, but their clinical significance especially in isolation is less well established.

4.1 Giant capillaries

There is no universally agreed definition of a “giant capillary” but one is by and large accepted as a capillary that is that is enlarged over four-fold normal diameter (and often >ten-fold) (see **Figure 3**). A normal adult capillary is somewhere between 25-50um and therefore generally anything over 150um is considered pathologic. Enlarged capillaries are somewhere in between giant capillaries and normal. A useful clinical tip is to compare capillaries within the same patient to first establish the appearances and dimensions of their “normal” capillaries and use these to compare the enlarged capillaries against, if present. The presence of even a single giant capillary is very suggestive of an underlying connective tissue disease.

4.2 Avascular areas

Avascular areas or areas of capillary “drop-out” are regions where there are no capillaries and in the absence of local nailfold trauma are highly specific for




Figure 2. The different techniques for performing nailfold capillaroscopy. (a) Widefield microscopy; (b) videocapillaroscopy; (c) dermoscopy (with a smartphone attachment).

systemic sclerosis in particular (see **Figure 4**). Again, there is no internationally ratified definition but a working definition is a 1 mm region of the distal nailfold with no capillaries present. Another definition is the absence of two or more sequential capillary loops [14]. It can be difficult if there is not adequate visualisation of the nailfold for technical reasons or if it is difficult to get the appropriate depth of focus to bring all capillaries in to view. A simple tip is to compare within the same patients nailfolds to see if the usual density of capillaries (number within a defined width or area) is regionally varied.

4.3 Microhaemorrhages

These are evidenced by reddish-brown punctate lesions (haemosiderin staining) in the cuticle (see **Figure 5**). They are often associated with regional capillary architectural abnormalities (such as a giant capillary) and sometimes recurrent haemorrhage can be deduced from lesions “growing-out” along the cuticle over time.

4.4 Other abnormal capillary shapes

It is difficult to define “bushy”, “arborized” or excessively tortuous capillaries as these are qualitative judgements and experience dependent (see **Figure 6**). In addition, although cuticle hypertrophy is well recognised (although not that prevalent) there is no established definition for it and it is based upon a subjective assessment.

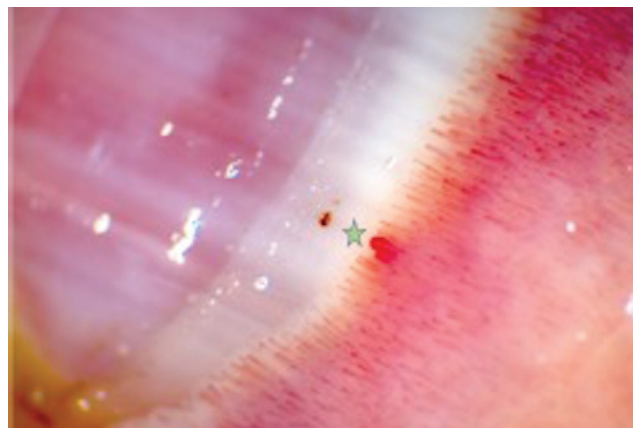


Figure 3.
A single giant capillary, in this example associated with a microhaemorrhage in the distal cuticle.

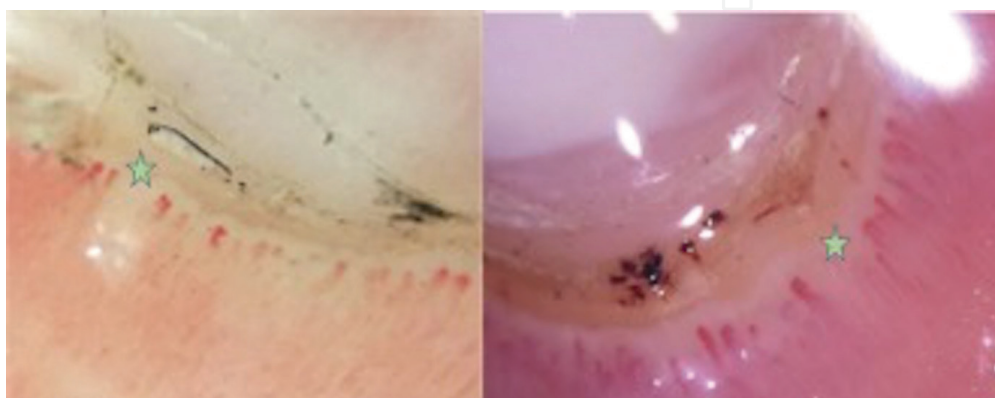

Figure 4.
Avascular areas, demonstrating areas of capillary “drop-out”. Note in the right-hand image the extensive associated microhaemorrhages and cuticle hypertrophy.

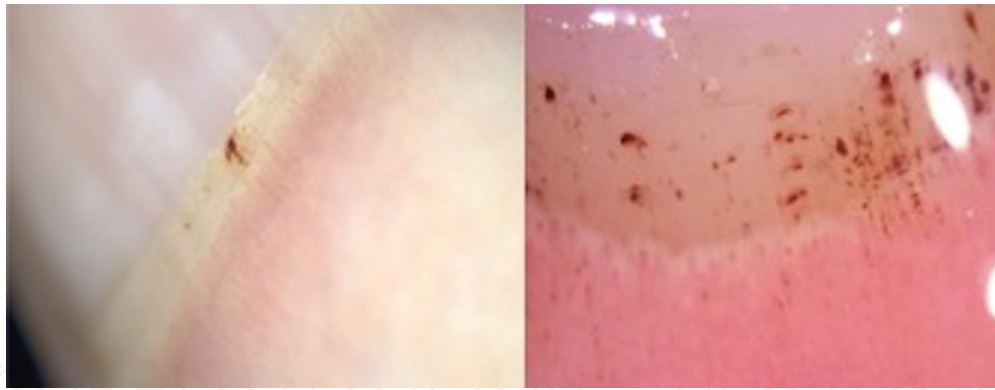


Figure 5.
Nailfold microhaemorrhages.

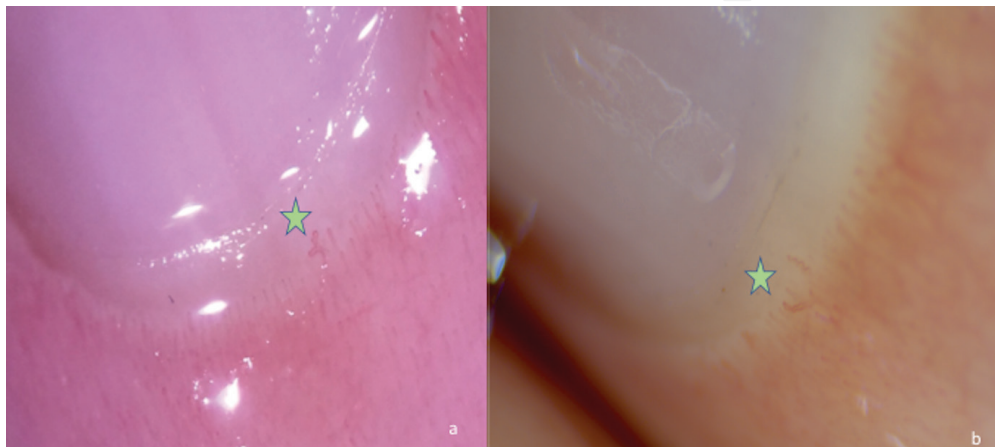


Figure 6.
Other abnormal capillary shapes. (a) A tortuous capillary; (b) elongated capillaries.

Recently, the reliability of simple capillaroscopic definitions to describe the different morphologies that can be seen in rheumatic diseases has been published and widely accepted [15]. Although there are a range of potential abnormalities which may seem relatively complex, there is actually very good intra- and inter-observer concordance in most studies and even only a short amount of training (for example an hour) can help complete novices make accurate assessments [16]. There has been encouraging results when capillaroscopy has been used in a primary care setting as well [17]. Two prospective studies in particular have elegantly demonstrated the prognostic significance of these abnormalities in patients with Raynaud's phenomenon. Koenig et al. showed that giant capillaries and capillary loss strongly predict the evolution to a diagnosis of systemic sclerosis (then using the 1980 ACR criteria) and, when combined with a relevant positive autoantibody, had a positive predictive value of 79% and negative predictive value of 93% [18]. A second study, by Ingegnoli et al., found that the three capillary abnormalities that correlated with a later diagnosis of systemic sclerosis were giant capillaries, capillary density and microhaemorrhages [19].

5. Classification

There is no universally adopted consensus on exactly how the varying combination of above potential capillary abnormalities should be classified and this is an ongoing research priority. Classification criteria have many discrete purposes from diagnostic criteria and we will cover only a few illustrative examples as our intended focus is on the use of capillaroscopy in the clinical rather than research setting.

5.1 Qualitative criteria

The first proposed classification criteria was that of Maricq et al. who classified patient's nailfold capillaries as having either "normal" appearances, "non-specific" abnormalities or the "Scleroderma-Dermatomyositis (or SD-) pattern" [2, 5]. This latter category was defined by the presence of giant capillaries or avascular areas and could include the other capillary abnormalities described above. It is this pattern that has now been shown in numerous publications to help differentiate primary from secondary Raynaud's syndrome and as the pattern present in around 90% of systemic sclerosis patients, often very early in the course of their disease [20]. In essence, therefore, it is these features that are of primary clinical significance as they strongly suggest an associated underlying connective-tissue disease. The "non-specific" group consists of individuals who have some definite capillary abnormalities (such as microhaemorrhages, enlarged or tortuous capillaries), but neither of the more specific features of giant capillaries or avascular areas. From a clinical perspective, the significance of an investigation with these findings should usually be interpreted as normal but it may have some suggestive relevance when considered in the context of a patient's history, examination and other investigations as supportive of a scleroderma-spectrum disorder.

5.2 Semi-quantitative criteria

Because of the intrinsic issues with purely qualitative classification systems, especially when trying to compare or reproduce different study methodologies and research findings, there have been many efforts to develop a more structured and systematic approach into criteria. A Brazilian group developed the Maricq scoring system and incorporated a count of the total number of enlarged or giant capillaries as well as a measure of mean capillary density (capillaries per mm) [21]. Other early efforts at moving towards a more quantitative classification included those by the research group of Lee et al. [14]. More recently, the most widely adopted criteria is that of Cutolo et al. who described "early", "active" and "late" categories (see **Table 1**) for individuals with definite capillary abnormal features [23]. Several studies have shown that the Cutolo criteria are associated with disease activity and severity. The "early" and "active" patterns are more common in limited SSc, whereas the "late" category is present more frequently in patients with diffuse SSc [24]. In the same study, the severity of organ involvement progressively increased across groups from "early" towards "late". Other studies have reported the "late" pattern in older patients, in those with a longer disease duration, and in those with diffuse disease [15, 16]. Several studies have shown that the "late" pattern in particular predicts digital ulcers as well as more severe cutaneous, cardiac and pulmonary disease [24–27]. The initial Cutolo criteria was later simplified into a score ranging from 0 to 9, correlating to the average score for each of three variables in each of eight examined nailfolds [28].

Classification	Description
Early	Few giant capillaries, few haemorrhages and no capillary loss
Active	Numerous giant capillaries and microhaemorrhages, mild capillary architecture disturbance and moderate capillary loss
Late	Severe capillary loss with extensive avascular areas, disorganised capillaries and ramified capillaries.

Table 1.
The Cutolo classification criteria [22].

5.3 Quantitative criteria

Certain components of the capillaroscopic assessment are well suited to quantitative assessment. Capillary density (by convention the number of capillaries within a 1 mm region of the distal nailfold) is the best example of this, with anything less than 6 per mm being pathologically abnormal. A quantitative method was employed in a recent multicentre study and involved counting all the microhaemorrhages, normal capillaries, enlarged capillaries, giant capillaries and other abnormal capillary shapes in the distal row within two 1 mm fields per finger [29]. The study concluded that the simple count of capillaries (i.e. capillary density) was sufficient to monitor the progression of scleroderma. Recently, some groups have used computer technology to count capillaries and automate this quantitative process with good reproducibility and obvious potential advantages for future work [30, 31]. Reduced capillary density has been associated with disease complications such as pulmonary hypertension, interstitial lung disease and digital ulcers. Many other capillary features have been measured and investigated including, for example, capillary length, angle and loop diameter, but the clinical relevance of these measurements is not well established.

6. The established role

6.1 Distinguishing primary from secondary Raynaud's syndrome

The first clearly established clinically relevant role for capillaroscopy was in the assessment of patients with Raynaud's symptoms. Abnormal nailfold capillaroscopy is strongly predictive of an underlying connective tissue disease (synonymous with "secondary" Raynaud's syndrome) and, conversely, normal nailfold capillaroscopy is reassuring that an underlying connective tissue disease is unlikely ("primary" Raynaud's syndrome). The early work into the importance of nailfold capillary changes in identifying patients with secondary Raynaud's syndrome is well summarised in a systematic review from 1998, where abnormal capillaries had the highest odds ratio (OR) of any variable studied for progression to secondary diseases [32]. These findings have been replicated and enhanced in the prospective study of Koenig et al. over 3000 patient years, who found abnormal capillaries and systemic sclerosis-specific autoantibodies were both independent predictors of an underlying connective tissue disease [18]. Twenty-six percent of patients with capillary abnormalities at baseline (and 36% with a specific autoantibody) developed systemic sclerosis within follow up, which increased to 80% in subjects with both features. Conversely, only 1.8% of patients with neither present at baseline developed a connective tissue disease during follow up. Similarly, a study from Pavlov-Dolijanovic et al. found 45% of their 3029 consecutive patients with Raynaud's syndrome and abnormal NFC went on to develop a connective tissue disease. The OR for being diagnosed with systemic sclerosis in patients with abnormal NFC compared to those with Raynaud's syndrome without capillary abnormalities was 183 (95% confidence intervals 97.9–271.5) [33].

6.2 Diagnosing systemic sclerosis

Abnormal capillaroscopy features are particularly useful in the diagnosis of systemic sclerosis (SSc) and are present in up to 90% of patients [34]. The work of Leroy and Medsger highlighted the importance of NFC in detecting early SSc in particular and much subsequent work has helped include capillaroscopy in the

most recent SSc classification criteria (see **Table 2**) [4, 35]. Abnormal capillaroscopic findings contribute 2 points towards the 9 points necessary to establish a diagnosis of SSc. If combined with Raynaud's symptoms, a common indication for the investigation, it contributes a total of 4 points towards the diagnosis. The addition of capillaroscopy to the new criteria have helped improve their sensitivity for early and very early SSc which is an area of great interest to researchers seeking to find interventions and treatments to improve long-term outcomes [36, 37]. It could be argued on the basis of these criteria that access to NFC should be a pre-requisite for all clinicians and researchers evaluating patients with potential SSc.

6.3 A predictor of organ-specific manifestations in systemic sclerosis

There is an accumulating literature on the association between capillaroscopic findings and certain organ-specific complications of SSc. In general, the more severe morphological changes correlate with more severe disease [34, 38]. The converse is also true, where patients with less marked NFC abnormalities have less severe cutaneous and pulmonary involvement [39].

6.3.1 Digital ulcers

Digital ulcers (DU) are a visible representation of peripheral vasculopathy, occurring in up to 50% of patients at some point in their illness [40]. It stands to reason that capillaroscopic abnormalities would correlate with their presence and there has been considerable interest in applying capillaroscopy as a predictor of digital ulcers in systemic sclerosis. The association of capillary loss and digital ischaemia was first established almost a decade ago with work by Herrick et al. and Ennis et al. [37, 41]. The more recent video CAPillaroscopy (CAP) study showed the

Item	Sub-item	Weight/score
Skin thickening of fingers of both hands extending proximal to the MCPs	–	9
Skin thickening (only count the higher score)	Puffy fingers	2
	Sclerodactyly	4
Finger tip lesions (only count the higher score)	Digital tip ulcers	2
	Finger tip pitting scars	3
Telangiectasia	–	2
Abnormal nailfolds	–	2
Pulmonary arterial hypertension and/or interstitial lung disease (maximum of 2)	Pulmonary arterial hypertension	2
	Interstitial lung disease	2
Raynaud's phenomenon	–	2
SSc-related autoantibodies (maximum score is 3)	Anti-Scl70 (anti-topoisomerase I)	3
	Anti-centromere	
	Anti-RNA polymerase III	

Patients with a score of ≥ 9 are classified as having definite systemic sclerosis.

Table 2.
 The 2013 classification criteria for systemic sclerosis [4].

mean number of capillaries in the dominant hand middle finger (per mm) was one of three predictors of DU (the two others being number of DUs at enrolment and critical digital ischaemia at enrolment) [29]. The “late” NFC pattern (see **Table 1**) has been shown in a prospective longitudinal study to be an independent predictor for DU in patients both with and without a history of DUs [42]. NFC findings may help in future target high risk patients for vascular remodelling and protective strategies. Indeed, a prognostic tool, the capillaroscopic skin ulcer risk index (CSURI), has been developed and demonstrated to help predict ulcers in the 3 months following assessment [43]. Another similar tool to predict digital trophic lesions intended for day-to-day clinical use based upon a simple capillary count has also been described [44].

6.3.2 Pulmonary hypertension

Pulmonary hypertension affects around 15% of patients with systemic sclerosis and despite advances in therapy still accounts for substantial morbidity and mortality [45]. Because of its relatively lower prevalence than other organ specific manifestations, it is more difficult to explore the role of NFC in predicting its presence or severity but some studies have already shown some intriguing results. In a recent Dutch cohort of over 200 patients, NFC changes were independently predictive of cardio-respiratory complications and, notably, all patients with pulmonary hypertension had abnormal NFC [46]. The “late” pattern and reduced capillary density have both been associated with the presence and severity of pulmonary hypertension in SSc [47, 48].

6.3.3 Interstitial lung disease

Interstitial lung disease (ILD) is present in up to 80% of patients with systemic sclerosis and, although only around 25% develop progressive disease, this again contributes to substantial morbidity and mortality [35]. In a retrospective observational study an association was found between abnormal NFC and the presence of ILD [49]. Capillaroscopic abnormalities were associated with a mean 15% reduction in forced vital capacity and DLCO compared to participants with normal capillaroscopy findings. Multiple other studies have also found an association between abnormal capillaroscopy and the presence or severity of ILD [27, 34, 46].

6.3.4 Mortality

Abnormal NFC has been associated with an increased mortality. A study of almost 3000 patients with Raynaud’s symptoms but without an established diagnosis of a CTD was conducted for a mean of 9.3 years. An increased all-cause mortality rate was found for females (HR 1.10; 1.07–1.77) but this association was interestingly not found for males, although the substantially fewer males with Raynaud’s syndrome and relatively short follow up for this outcome measure may have impacted [50]. A more recent study also found an association between capillary loss and mortality, although this did not remain significant after multi-variant adjustment [51].

7. The emerging role

There has never been more activity and interest in capillaroscopy and its applications are only likely to expand over time. Although its role in the diagnosis of SSc

is well established, it is emerging as having a role in a variety of other CTDs such as the idiopathic inflammatory myopathies (IIM) and mixed connective tissue disease (MCTD). Even within SSc there is much ongoing work into further understanding the potential role for capillaroscopy in more accurately screening and monitoring for disease complications and as a putative biomarker. Others are evaluating the potential role of capillaroscopy in monitoring the efficacy of new therapies and as a trial outcome measure. Finally, it is likely that capillaroscopy can be combined with complementary technologies or investigations to better serve the need for progress in the understanding and management of CTDs.

7.1 Use in other connective tissue diseases

7.1.1 Idiopathic inflammatory myopathies

Implicit in Maricq's initial qualitative classification of the "scleroderma-dermatomyositis" pattern was a recognition that dermatomyositis (DM) had similar nailfold capillary changes to SSc. This perhaps is not surprising given, like SSc, DM is a condition characterised by microvasculopathy and, along with other IIM subtypes such as the anti-synthetase syndrome and overlap myositis, it shares many clinical manifestations such as Raynaud's syndrome, myositis and cutaneous involvement [52]. NFC has not been as thoroughly evaluated in this patient group as in SSc but there are some interesting findings. An Italian study of 52 patients with IIM found nailfold changes were significantly more common in patients with DM versus polymyositis (PM) and that disease duration seemed to have an impact on the features, as patients with longer disease duration had less of the "late" features [53]. This may seem counter-intuitive and the opposite of the findings in SSc where there is a trend towards more "late" pattern changes with increasing disease duration, but the study was not controlled for the impact of treatment on the capillary features. In an earlier study from Spain, the combination of microhaemorrhages and capillary enlargement was found more frequently in patients with DM *versus* PM (OR 8.9) and overall in their cohort of 53 patients with IIM, found the prevalence of abnormal NFC to be 43% [54]. This study also found an association between NFC abnormalities and both disease activity and damage. There was a low incidence of capillary loss (in 20% of DM patients and 0% of PM patients) and the authors concluded that the pathogenesis of the disease is therefore likely different from that of systemic sclerosis, where avascular areas are far more prominent. The authors also concluded that abnormal NFC contributed to an earlier diagnosis of IIM and likely marks out patients for a poorer prognosis. There is limited information on longitudinal changes over time in patients with IIM but one study of quantitative capillaroscopy in these patients *versus* healthy controls found a progressive reduction in capillary density in patients with anti-Jo-1 positive anti-synthetase syndrome [55]. Another recent study has reported some relatively subtle longitudinal differences in the nailfolds of patients with IIM compared to SSc [56].

7.1.2 Mixed connective tissue disease

Many patients with MCTD, which again shares considerable clinical manifestation overlap with SSc, will have NFC abnormalities although this has not been studied in isolation [33]. The recent study by Markusse et al. found that the "early" pattern was associated with a positive anti-RNP antibody, a hint that, similar to NFC in the IIM, MCTD may have differing underlying microvascular pathophysiology with less avascular areas or capillary drop-out compared to patients with SSc [46].

7.1.3 Systemic lupus erythematosus

In a recent systematic review, Cutolo et al. have helped summarise the limited existing literature of NFC in systemic lupus erythematosus (SLE) [57]. Although differences in the prevalence of capillary abnormalities in patients with SLE compared to normal controls have been found (especially with increased capillary tortuosity, prominent venous plexus and elongated capillaries), these are usually subtle compared to the more marked findings in SSc and IIM. An increased NFC score did correlate with disease activity in the majority of the few studies that reported on this, especially with the frequency of Raynaud's symptoms or digital gangrene.

7.2 Capillaroscopy as a putative biomarker

Although the role of NFC in diagnosis is well established, its role, if any, in established disease is less clear – could serial examinations be used to screen for complications in much the same way as an annual echocardiogram and pulmonary function tests would do? Prospective longitudinal studies are required to properly address this question, and some are already completed or underway. A recent study by Avouac et al. followed patients prospectively over three years and found that changes in NFC over time (in particular a loss of capillary density to <4 per mm), which occurred in almost half of patients, was a strong marker of organ progression [58]. As mentioned above numerous studies have linked the “late” NFC pattern with SSc disease activity, digital ulcers, cutaneous, cardiac and pulmonary involvement, which suggests an evolution of NFC changes over time [24, 26, 27]. A study from Brazil looked at overall mortality within a group of patients with SSc and found an increased mortality in those with more marked capillary loss [59]. Longitudinal NFC assessments in patients with systemic sclerosis could feasibly become a part of routine care [60]. The comprehensive review by Ingegnoli & Gualtierotti also summarises the literature to date on the association between abnormalities of NFC and other serum biomarkers such as endothelin-1 and VEGF, which offers an insight into a potential future where biomarkers could be combined to stratify patients and personalise management [9].

7.3 Nailfold capillaroscopy and therapeutics

Another area that is being researched intensively is in the arena of monitoring effects of drugs on nailfold changes. If, as has been largely established, the structural microvascular changes in CTDs can associate with disease activity, it would also make sense that a successful treatment may reverse the microvascular changes. NFC could therefore be used as a measure of treatment efficacy or even a trial outcome measure. There have been reports of significant improvements in microangiopathy paralleling the substantial clinical improvement in patients after autologous haematopoietic stem cell transplant (HSCT) for SSc as well as in a patient with anti-synthetase syndrome [61–63]. In one report (of two patients with SSc and MCTD respectively), progressive improvements in NFC were seen with the cyclophosphamide used for stem cell mobilisation and then the subsequent HSCT [63]. Despite the evidence that endothelin-1 inhibitors reduce the incidence of digital ulcer recurrence and Raynaud's symptoms [64–66], two studies have failed to find significant changes in structural microvascular changes [67, 68]. However, the follow up of these studies was relatively short and it has been argued that the true impact of endothelin-1 antagonists on structural microvascular change may take longer to establish. Similarly, intravenous prostanoid therapy was not associated with NFC improvements at 12 months despite a statistically significant

improvement in Raynaud's symptoms [69]. Some researchers are already postulating that making an early diagnosis of SSc in patients with NFC abnormalities may allow for the early instigation of preventative therapies (e.g. endothelin-1 antagonists to prevent pulmonary hypertension, antifibrotic therapies to prevent ILD) and therefore help change the natural history of the disease [70].

7.4 Combining NFC with other technologies

As technology rapidly advances there may become available a variety of novel techniques that allow for image acquisition. Inexpensive USB microscopes are already available as are accessory equipment allowing the digital camera of a smart phone to take diagnostically useful images [11]. Technology could also be harnessed to allow for quicker and more reproducible image assessment, as in the case of the recent publication of automated capillary counting [30]. NFC is an excellent measure of structural microvascular changes in disease, but the role and assessment of functional changes may also add clinically useful information. Thermography, where the skin surface temperature is measured using thermal cameras, is already well established at some expert centres [20]. The equipment is relatively expensive and requires regular calibration but technology is advancing and soon thermal cameras may be available as smartphone attachments. Several studies have shown thermography to be able to differentiate between healthy controls and primary Raynaud's and between primary Raynaud's and Raynaud's secondary to systemic sclerosis based upon an abnormal pattern (a persistent "distal-dorsal difference") of rewarming [71, 72]. Although thermography as a stand-alone test has some utility, further work may help establish that, in time, assessments of patients with potential CTD may include both a structural assessment in the form of NFC and a functional assessment. Developing a standardised protocol for thermography with a plan to validate the protocol to assist ongoing research in thermography is already underway [39]. Another novel strategy for functional perfusion assessment is to use Laser technology. Techniques such as laser Doppler flowmetry and laser speckle contrast analysis (LASCA) have shown good reliability in patients with SSc [73–77]. Advances are occurring in parallel with advances in other non-invasive imaging techniques such as optical coherence tomography and photoacoustic imaging which allow the opportunity to view the skin and cutaneous vessels in three dimensions [20].

8. Future directions

Despite the great progress made by research into NFC over the last 50 years there is much work that is still required to be done. There is a great need for a widely-accepted consensus classification criteria. Work needs to continue to improve awareness of and access to the investigation which will be aided by more convenient and cheaper technologies. Prospective longitudinal studies will allow for a better understanding of certain nailfold capillary abnormalities and their link with organ-specific complications, disease severity, disease activity and hopefully, in time, the efficacy of certain treatments. Further work will also target other related CTDs.

9. Conclusions

Nailfold capillaroscopy is a simple, non-invasive, and non-expensive investigation with established roles in the diagnosis of scleroderma-spectrum disorders as

well as being linked to the presence and severity of a variety of serious organ-specific manifestations which account for substantial morbidity and mortality. Access to the investigation is likely to increase as technology makes equipment more user friendly, reproducible and inexpensive. Demand for the investigation is similarly going to increase substantially as it has been included in recent classification criteria for SSc and the potential clinical applications are only increasing in a wide range of conditions characterised by microangiopathy. Because microvascular change is often present very early in the clinical disease course, nailfold capillaroscopy may be a tool to identify a “window of opportunity”, in conditions which to date have proven largely refractory to the therapies employed with much greater success in other rheumatic and autoimmune disease. It may usher in a new era of preventative rather than reactionary therapy and may become a part of disease management decisions, perhaps in a similar way to the use of clinical ultrasound in patients with rheumatoid arthritis. It is of relevance to all clinicians seeing patients with suspected connective tissue diseases to stay abreast of the progress being made in nailfold capillaroscopy and the related investigations.

Acknowledgements

The authors would like to thank the patients of Royal Prince Alfred Hospital.

Conflict of interests

The authors declare no conflict of interests.

Author details


Matthew J.S. Parker^{1,2*} and Neil W. McGill^{1,2}

1 Department of Rheumatology, Royal Prince Alfred Hospital, Sydney, NSW, Australia

2 University of Sydney, Sydney, NSW, Australia

*Address all correspondence to: mjsparker24@gmail.com

IntechOpen

© 2018 The Author(s). Licensee IntechOpen. This chapter is distributed under the terms of the Creative Commons Attribution License (<http://creativecommons.org/licenses/by/3.0>), which permits unrestricted use, distribution, and reproduction in any medium, provided the original work is properly cited. 

References

- [1] Brown G, O'Leary P. Skin capillaries in scleroderma. *Archives of Internal Medicine*. 1926;**36**:73-88
- [2] Maricq H, LeRoy E. Patterns of finger capillary abnormalities in connective tissue disease by "wide-field" microscopy. *Arthritis and Rheumatism*. 1973;**16**(5):619-628
- [3] Maricq HR, LeRoy EC, D'Angelo WA, Medsger TA Jr, Rodnan GP, Sharp GCWJ. Diagnostic potential of in vivo capillary microscopy in scleroderma and related disorders. *Arthritis and Rheumatism*. 1980;**23**(2):183-189
- [4] Van Den Hoogen F, Khanna D, Fransen J, Johnson SR, Baron M, Tyndall A, et al. 2013 Classification criteria for systemic sclerosis: An american college of rheumatology/European league against rheumatism collaborative initiative. *Annals of the Rheumatic Diseases*. 2013;**72**:1747-1755
- [5] Maricq HR. Widefield capillary microscopy. Technique and rating scale for abnormalities seen in scleroderma and related disorders. *Arthritis and Rheumatism*. 1981;**24**(9):1159-1165
- [6] Anderson ME, Allen PD, Moore T, Hillier V, Taylor CJ, Ariane L, et al. Computerized nailfold video capillaroscopy—A new tool for assessment of Raynaud's phenomenon. *Journal of Rheumatology*. 2005;**32**(5):841-848
- [7] Sekiyama JY, Camargo CZ, Andrade LEC, Kayser C. Reliability of widefield nailfold capillaroscopy and videocapillaroscopy in the assessment of patients with Raynaud's phenomenon. *Arthritis Care and Research*. 2013;**65**(11):1853-1861
- [8] Dinsdale G, Moore T, O'Leary N, Tresadern P, Berks M, Roberts C, et al. Intra-and inter-observer reliability of nailfold videocapillaroscopy—A possible outcome measure for systemic sclerosis-related microangiopathy. *Microvascular Research*. 2017;**112**:1-6
- [9] Ingegnoli F, Gualtierotti R. A systematic overview on the use and relevance of capillaroscopy in systemic sclerosis. *Expert Review of Clinical Immunology*. 2013;**9**(11):1091-1097
- [10] Hughes M, Moore T, O'Leary N, Tracey A, Ennis H, Dinsdale G, et al. A study comparing videocapillaroscopy and dermoscopy in the assessment of nailfold capillaries in patients with systemic sclerosis-spectrum disorders. *Rheumatology (Oxford, England)*. 2015;**54**(8):1435-1442
- [11] Parker MJS, Oliffe MT, McGill NW. An evaluation of two novel capillaroscopy techniques in suspected scleroderma-spectrum disorders: A single-Centre cross-sectional study. *Modern Rheumatology*. 2018;**28**(4):676-680
- [12] Dogan S, Akdogan A, Atakan N. Nailfold capillaroscopy in systemic sclerosis: Is there any difference between videocapillaroscopy and dermatoscopy? *Skin Research and Technology*. 2013;**19**(4):446-449
- [13] Ingegnoli F, Gualtierotti R, Lubatti C, Bertolazzi C, Gutierrez M, Boracchi P, et al. Nailfold capillary patterns in healthy subjects: A real issue in capillaroscopy. *Microvascular Research*. 2013;**90**:90-95
- [14] Lee P, Leung F, Alderdice C, Armstrong S. Nailfold capillary microscopy in the connective tissue diseases: A semi-quantitative assessment. *The Journal of Rheumatology*. 1983;**10**(6):930-938
- [15] Cutolo M, Melsens K, Herrick AL, Foeldvari I, Deschepper E,

- De Keyser F, et al. Reliability of simple capillaroscopic definitions in describing capillary morphology in rheumatic diseases. *Rheumatology (United Kingdom)*. 2018;**57**(4):757-759
- [16] Smith V, Beeckman S, Herrick AL, Decuman S, Deschepper E, De Keyser F, et al. An EULAR study group pilot study on reliability of simple capillaroscopic definitions to describe capillary morphology in rheumatic diseases. *Rheumatology (Oxford, England)*. 2016;**55**(5):883-890
- [17] Overbury R, Murtaugh MA, Fischer A, Frech TM. Primary care assessment of capillaroscopy abnormalities in patients with Raynauds phenomenon. *Clinical Rheumatology*. 2015;**34**(12):2135-2140
- [18] Koenig M, Joyal F, Fritzler MJ, Roussin A, Abrahamowicz M, Boire G, et al. Autoantibodies and microvascular damage are independent predictive factors for the progression of Raynaud's phenomenon to systemic sclerosis: A twenty-year prospective study of 586 patients, with validation of proposed criteria for early systemic sclerosis. *Arthritis and Rheumatism*. 2008;**58**(12):3902-3912
- [19] Ingegnoli F, Boracchi P, Gualtierotti R, Lubatti C, Meani L, Zahalkova L, et al. Prognostic model based on nailfold capillaroscopy for identifying Raynaud's phenomenon patients at high risk for the development of a scleroderma spectrum disorder: PRINCE (Prognostic Index for Nailfold Capillaroscopic Examination). *Arthritis and Rheumatism*. 2008;**58**(7):2174-2182
- [20] Herrick AL, Murray A. The role of capillaroscopy and thermography in the assessment and management of Raynaud's phenomenon. *Autoimmunity Reviews*. 2018;**17**(5):465-472
- [21] Correa MJU, Andrade LEC, Kayser C. Comparison of laser Doppler imaging, fingertip lacticemy test, and nailfold capillaroscopy for assessment of digital microcirculation in systemic sclerosis. *Arthritis Research & Therapy*. 2010;**12**:R157
- [22] Cutolo M, Sulli A, Pizzorni C, Accardo S. Nailfold capillaroscopy assessment of microvascular damage in systemic sclerosis. *The Journal of Rheumatology*. 2000;**27**:155-160
- [23] Cutolo M, Pizzorni C, Tuccio M, Burrioni A, Craviotto C, Basso M, et al. Nailfold videocapillaroscopic patterns and serum autoantibodies in systemic sclerosis. *Rheumatology*. 2004;**43**(6):719-726
- [24] Caramaschi P, Canestrini S, Martinelli N, Volpe A, Pieropan S, Ferrari M, et al. Scleroderma patients nailfold videocapillaroscopic patterns are associated with disease subset and disease severity. *Rheumatology*. 2007;**46**(10):1566-1569
- [25] Marino Claveri L, Knobel E, Takashima L, Techera L, Oliver M, Gonzalez P, et al. Organ involvement in Argentinian systemic sclerosis patients with "late" pattern as compared to patients with "early/active" pattern by nailfold capillaroscopy. *Clinical Rheumatology*. 2013;**32**(6):839-843
- [26] Smith V, Decuman S, Sulli A, Bonroy C, Piette Y, Deschepper E, et al. Do worsening scleroderma capillaroscopic patterns predict future severe organ involvement? A pilot study. *Annals of the Rheumatic Diseases*. 2012;**71**(10):1636-1639
- [27] Smith V, Ricciari V, Pizzorni C, Decuman S, Deschepper E, Bonroy C, et al. Nailfold capillaroscopy for prediction of novel future severe organ involvement in systemic sclerosis. *The Journal of Rheumatology*. 2013;**40**(12):2023-2028

- [28] Sulli A, Secchi ME, C Pizzorni MC. Scoring the nailfold microvascular changes during the capillaroscopic analysis in systemic sclerosis patients. *Annals of the Rheumatic Diseases*. 2008;**67**(6):885-887
- [29] Cutolo M, Herrick AL, Distler O, Becker MO, Beltran E, Carpentier P, et al. Nailfold Videocapillaroscopic features and other clinical risk factors for digital ulcers in systemic sclerosis: A multicenter, prospective cohort study. *Arthritis Rheumatol*. 2016;**68**(10):2527-2539
- [30] Cheng C, Lee CW, Daskalakis C. A reproducible computerized method for quantitation of capillary density using nailfold capillaroscopy. *Journal of Visualized Experiments*. 2015;**104**:1-8
- [31] Cutolo M, Trombetta AC, Melsens K, Pizzorni C, Sulli A, Ruaro B, et al. Automated assessment of absolute nailfold capillary number on videocapillaroscopic images: Proof of principle and validation in systemic sclerosis. *Microcirculation*. 2018;**25**(4):16-18
- [32] Spencer-Green G. Outcomes in primary Raynaud phenomenon. *Archives of Internal Medicine*. 1998;**158**:595-600
- [33] Pavlov-Dolijanovic S, Damjanov NS, Stojanovic RM, Vujasinovic Stupar NZ, Stanisavljevic DM. Scleroderma pattern of nailfold capillary changes as predictive value for the development of a connective tissue disease: A follow-up study of 3029 patients with primary Raynaud's phenomenon. *Rheumatology International*. 2012;**32**(10):3039-3045
- [34] Ghizzoni C, Sebastiani M, Manfredi A, Campomori F, Colaci M, Giuggioli D, et al. Prevalence and evolution of scleroderma pattern at nailfold videocapillaroscopy in systemic sclerosis patients: Clinical and prognostic implications. *Microvascular Research*. 2015;**99**:92-95
- [35] Khanna D, Nagaraja V, Tseng C hong, Abtin F, Suh R, Kim G, et al. Predictors of lung function decline in scleroderma-related interstitial lung disease based on high-resolution computed tomography: Implications for cohort enrichment in systemic sclerosis-associated interstitial lung disease trials. *Arthritis Research & Therapy*. 2015;**17**(1):1-10
- [36] Jordan S, Maurer B, Toniolo M, Michel B, Distler O. Performance of the new ACR/EULAR classification criteria for systemic sclerosis in clinical practice. *Rheumatology (Oxford, England)*. 2015;**54**(8):1454-1458
- [37] Cutolo M, Smith V, Distler O, Kowal-Bielecka O, Allanore Y, Matucci-Cerinic M. OP0035 preliminary analysis of nailfold capillaroscopy in the very early diagnosis of systemic sclerosis (VEDOSS): The capi-vedoss experience. *Annals of the Rheumatic Diseases*. 2017;**76**:65-66
- [38] Fichel F, Baudot N, Gaitz JP, Trad S, Barbe C, Francès C, et al. Systemic sclerosis with normal or nonspecific nailfold capillaroscopy. *Dermatology*. 2014;**228**(4):360-367
- [39] Vayssairat M, Hidouche D, Abdoucheli-Baudot N, Gaitz JP. Clinical significance of subcutaneous calcinosis in patients with systemic sclerosis. Does diltiazem induce its regression? *Annals of the Rheumatic Diseases*. 1998;**57**(4):252-254
- [40] Walker UA, Tyndall A, Czirják L, Denton C, Farge-Bancel D, Kowal-Bielecka O, et al. Clinical risk assessment of organ manifestations in systemic sclerosis: A report from the EULAR scleroderma trials and research group database. *Annals of the Rheumatic Diseases*. 2007;**66**(6):754-763

- [41] Ennis H, Moore T, Murray A, Vail A, Herrick AL. Further confirmation that digital ulcers are associated with the severity of abnormality on nailfold capillaroscopy in patients with systemic sclerosis. *Rheumatology (United Kingdom)*. 2014;**53**(2):376-377
- [42] Silva I, Teixeira A, Oliveira J, Almeida I, Almeida R, Águas A, et al. Endothelial dysfunction and nailfold videocapillaroscopy pattern as predictors of digital ulcers in systemic sclerosis: A cohort study and review of the literature. *Clinical Reviews in Allergy and Immunology*. 2015;**49**(2):240-252
- [43] Sebastiani M, Manfredi A, Colaci M, Damico R, Malagoli V, Giuggioli D, et al. Capillaroscopic skin ulcer risk index: A new prognostic tool for digital skin ulcer development in systemic sclerosis patients. *Arthritis Care and Research*. 2009;**61**(5):688-694
- [44] Smith V, De Keyser F, Pizzorni C, Van Praet ET, Decuman S, Sulli A, et al. Nailfold capillaroscopy for day-to-day clinical use: Construction of a simple scoring modality as a clinical prognostic index for digital trophic lesions. *Annals of the Rheumatic Diseases*. 2011;**70**(1):180-183
- [45] Denton CP, Khanna D. Systemic sclerosis. *Lancet*. 2017;**6736**(17):1-15
- [46] Markusse IM, Meijs J, De BB, Bakker JA, Schippers HPC, Schouffoer AA, et al. Predicting cardiopulmonary involvement in patients with systemic sclerosis: Complementary value of nailfold videocapillaroscopy patterns and disease-specific autoantibodies. *Rheumatology*. 2017;**56**:1081-1088
- [47] Hofstee HMA, Serné EH, Roberts C, Hesselstrand R, Scheja A, Moore TL, et al. A multicentre study on the reliability of qualitative and quantitative nail-fold videocapillaroscopy assessment. *Rheumatology*. 2012;**51**(4):749-755
- [48] Ricciari V, Vasile M, Iannace N, Stefanantoni K, Sciarra I, Vizza CD, et al. Systemic sclerosis patients with and without pulmonary arterial hypertension: A nailfold capillaroscopy study. *Rheumatology*. 2013;**52**(8):1525-1528
- [49] Castellví I, Simeón-Aznar CP, Sarmiento M, Fortuna A, Mayos M, Geli C, et al. Association between nailfold capillaroscopy findings and pulmonary function tests in patients with systemic sclerosis. *The Journal of Rheumatology*. 2015;**42**(2):222-227
- [50] Mueller M, Gschwandtner ME, Gamper J, Giurgea GA, Charwat-Resl S, Kiener HP, et al. Relation of nailfold capillaries and autoantibodies to mortality in patients with raynaud phenomenon. *Circulation*. 2016;**133**(5):509-517
- [51] Pavan TR, Bredemeier M, Hax V, Capobianco KG, da Silva Mendonça Chakr R, Xavier RM. Capillary loss on nailfold capillary microscopy is associated with mortality in systemic sclerosis. *Clinical Rheumatology*. 2018;**37**(2):475-481
- [52] Parker MJS, Lilleker JB, Roberts ME, Chinoy H. Idiopathic inflammatory myopathies. *Medicine (United Kingdom)*. 2018;**46**(2):140-145
- [53] Manfredi A, Sebastiani M, Cassone G, Pipitone N, Giuggioli D, Colaci M, et al. Nailfold capillaroscopic changes in dermatomyositis and polymyositis. *Clinical Rheumatology*. 2015;**34**(2):279-284
- [54] Selva-O'Callaghan A, Fonollosa-Pla V, Trallero-Araguás E, Martínez-Gómez X, Simeon-Aznar CP, Labrador-Horrillo M, et al. Nailfold capillary microscopy in adults with inflammatory myopathy.

Seminars in Arthritis and Rheumatism. 2010;**39**(5):398-404

[55] Mercer LK, Moore TL, Chinoy H, Murray AK, Vail A, Cooper RG, et al. Quantitative nailfold video capillaroscopy in patients with idiopathic inflammatory myopathy. *Rheumatology*. 2010;**49**(9):1699-1705

[56] Pizzorni C, Cutolo M, Sulli A, Ruaro B, Trombetta AC, Ferrari G, et al. Long-term follow-up of nailfold videocapillaroscopic changes in dermatomyositis versus systemic sclerosis patients. *Clinical Rheumatology*. 2018;**37**(10):2723-2729

[57] Cutolo M, Melsens K, Wijnant S, Ingegnoli F, Thevissen K, De Keyser F, et al. Nailfold capillaroscopy in systemic lupus erythematosus: A systematic review and critical appraisal. *Autoimmunity Reviews*. 2018;**17**(4):344-352

[58] Avouac J, Lepri G, Smith V, Toniolo E, Hurabielle C, Vallet A, et al. Sequential nailfold videocapillaroscopy examinations have responsiveness to detect organ progression in systemic sclerosis. *Seminars in Arthritis and Rheumatism*. 2017;**47**(1):86-94

[59] Kayser C, Sekiyama JY, Próspero LC, Camargo CZ, Andrade LEC, Próspero LC, et al. Nailfold capillaroscopy abnormalities as predictors of mortality in patients with systemic sclerosis. *Clinical and Experimental Rheumatology*. 2013;**31**:S103-S108

[60] Pauling JD. Could nailfold videocapillaroscopy usher in a new era of preventative disease-modifying therapeutic intervention in systemic sclerosis? *Rheumatology*. 2017;**56**(7):1053-1055

[61] Miniati I, Guiducci S, Conforti ML, Rogai V, Fiori G, Cinelli M, et al. Autologous stem cell transplantation improves microcirculation in systemic

sclerosis. *Annals of the Rheumatic Diseases*. 2009;**68**(1):94-98

[62] Chojnowski MM, Nałęcz-Janik J. Regression of microangiopathy in antisynthetase syndrome. *Rheumatology*. 2017;**56**:724

[63] Aschwanden M, Daikeler T, Jaeger K, Thalhammer C, Gratwohl A, Matucci-Cerinic M, et al. Rapid improvement of nailfold capillaroscopy after intense immunosuppression for systemic sclerosis and mixed connective tissue disease. *Annals of the Rheumatic Diseases*. 2008;**67**(7):1057-1059

[64] Cutolo M, Zampogna G, Vremis L, Smith V, Pizzorni C, Sulli A. Longterm effects of endothelin receptor antagonism on microvascular damage evaluated by nailfold capillaroscopic analysis in systemic sclerosis. *The Journal of Rheumatology*. 2013;**40**(1):40-45

[65] Cutolo M, Ruaro B, Pizzorni C, Ravera F, Smith V, Zampogna G, et al. Longterm treatment with endothelin receptor antagonist bosentan and iloprost improves fingertip blood perfusion in systemic sclerosis. *The Journal of Rheumatology*. 2014;**41**(5):881-886

[66] Trombetta AC, Pizzorni C, Ruaro B, Paolino S, Sulli A, Smith V, et al. Effects of longterm treatment with bosentan and iloprost on nailfold absolute capillary number, fingertip blood perfusion, and clinical status in systemic sclerosis. *The Journal of Rheumatology*. 2016;**43**(11):2033-2041

[67] Hetteema ME, Zhang D, Bootsma H, Kallenberg CGM. Bosentan therapy for patients with severe Raynaud's phenomenon in systemic sclerosis. *Annals of the Rheumatic Diseases*. 2007;**66**:1398-1399

[68] Moore TL, Vail A, Herrick AL. Assessment of digital vascular structure

and function in response to bosentan in patients with systemic sclerosis-related Raynaud's phenomenon (1). *Rheumatology*. 2007;**46**(2):363-364

[69] Shah P, Murray AK, Moore TL, Herrick AL. Effects of iloprost on microvascular structure assessed by nailfold videocapillaroscopy: A pilot study. *Journal of Rheumatology*. 2011;**38**(9):14-16

[70] Pauling JD. Could nailfold videocapillaroscopy usher in a new era of preventative disease-modifying therapeutic intervention in systemic sclerosis? *Rheumatology*. 2017;**56**:1053-1055

[71] Anderson ME, Moore TL, Lunt M, Herrick AL. The "distal-dorsal difference": A thermographic parameter by which to differentiate between primary and secondary Raynaud's phenomenon. *Rheumatology*. 2007;**46**(3):533-538

[72] Horikoshi M, Inokuma S, Kijima Y, Kobuna M, Miura Y, Okada R, et al. Thermal disparity between fingers after cold-water immersion of hands: A useful Indicator of disturbed peripheral circulation in Raynaud phenomenon patients. *Internal Medicine*. 2016;**55**(5):461-466

[73] Lambrecht V, Cutolo M, De Keyser F, Decuman S, Ruaro B, Sulli A, et al. Reliability of the quantitative assessment of peripheral blood perfusion by laser speckle contrast analysis in a systemic sclerosis cohort. *Annals of the Rheumatic Diseases*. 2016;**75**(6):1263-1264

[74] Ruaro B, Sulli A, Pizzorni C, Paolino S, Smith V, Cutolo M. Correlations between skin blood perfusion values and nailfold capillaroscopy scores in systemic sclerosis patients. *Microvascular Research*. 2016;**105**:119-124

[75] Ruaro B, Sulli A, Alessandri E, Pizzorni C, Ferrari G, Cutolo M. Laser speckle contrast analysis: A new method to evaluate peripheral blood perfusion in systemic sclerosis patients. *Annals of the Rheumatic Diseases*. 2014;**73**(6):1181-1185

[76] Ruaro B, Sulli A, Pizzorni C, Paolino S, Smith V, Alessandri E, et al. Correlations between blood perfusion and dermal thickness in different skin areas of systemic sclerosis patients. *Microvascular Research*. 2018;**115**(8):28-33

[77] Cutolo M, Vanhaecke A, Ruaro B, Deschepper E, Ickinger C, Melsens K, et al. Is laser speckle contrast analysis (LASCA) the new kid on the block in systemic sclerosis? A systematic literature review and pilot study to evaluate reliability of LASCA to measure peripheral blood perfusion in scleroderma patients. *Autoimmunity Reviews*. 2018;**17**(8):775-780