

# We are IntechOpen, the world's leading publisher of Open Access books Built by scientists, for scientists

**4,800**

Open access books available

**122,000**

International authors and editors

**135M**

Downloads

Our authors are among the

**154**

Countries delivered to

**TOP 1%**

most cited scientists

**12.2%**

Contributors from top 500 universities



**WEB OF SCIENCE™**

Selection of our books indexed in the Book Citation Index  
in Web of Science™ Core Collection (BKCI)

Interested in publishing with us?  
Contact [book.department@intechopen.com](mailto:book.department@intechopen.com)

Numbers displayed above are based on latest data collected.

For more information visit [www.intechopen.com](http://www.intechopen.com)



# Neuropathology of Traumatic Brain Injury and Its Role in the Development of Alzheimer's Disease

*Sonia Villapol*

## Abstract

The devastating deficiencies that result from brain injury stem from multiple overlapping mechanisms, exacerbated by the fact that there are no effective treatments. Traumatic brain injury (TBI) is recognized as the most influential environmental risk factor for neurodegenerative disease later in life, including dementia of Alzheimer's disease (AD)-type. However, exactly how TBI triggers and strengthens the neurodegenerative cascade of events in AD remains controversial. Amyloid deposits and fibril precursor protein are extracellular in systemic amyloid A (AA) amyloidosis. In this chapter, I will discuss the neuropathology following TBI connected to AD. Additionally, I critically review recent animal and human studies regarding how brain trauma affects the potential risks factors for AD progression. Furthermore, it will be shown investigate the principal pathological features of dementia or AD, specifically focusing on axonal damage and consequent cleavage of the amyloid precursor protein (APP), amyloid  $\beta$  plaque formation, or phosphorylation and aggregation of tau, neurofibrillary tangles formation, and TDP-43 accumulation. In summary, despite recent progress more studies are required to (1) further understanding of the basic mechanisms and pathophysiology of TBI, (2) elucidate the precise association between TBI and neurodegenerative disease, and (3) to identify treatments and therapies that can mitigate long-term consequences.

**Keywords:** tau, TDP-43, neurodegenerative, dementia, amyloid beta, plaques, amyloid beta deposition

## 1. Introduction

Traumatic brain injury (TBI) affects millions of individuals worldwide, with 1.7 million new cases in the US each year [1]. Although many patients survive the initial lesion, TBI initiates a wide variety of pathologies such as neurological deficits, short and long-term brain damage, neuroinflammation, cognitive and emotional impairments, all of which depend on the severity of the injury and other various factors [2, 3]. Brain injuries are most frequently caused by motor vehicle crashes, sports injuries, or simple falls; males are about twice as likely as females to experience a brain trauma [4]. At least 5.3 million Americans, or approximately 2% of the total US population, currently are burdened with disabilities resulting from TBI [5].

Functional deficits caused by TBI result from an initial impact and secondary damage that continue to develop over time and provide a therapeutic window for treatment to prevent or ameliorate many of the damaging consequences of injury [6]. While single compounds have been reported to be effective for short periods in standardized rodent models of TBI, therapeutic tools currently available to clinicians to treat patients with TBI are minimal.

The neuroinflammatory cascade following TBI contributes to neurodegeneration and death through the cumulative action of multiple damaging processes [7]. TBI is one of the most consistent candidates for initiating the molecular cascades that result in neurodegenerative diseases, such as Parkinson's disease (PD) or amyotrophic lateral sclerosis (ALS) [8–11]. Notably, there exists a strong epidemiological relationship between the occurrence of TBI and the development of Alzheimer's disease (AD) later in life [12–15]. The link between TBI and AD is strengthened through the identification of acute and chronic AD-like pathologies in the brain in both TBI survivors and animal models of brain injury.

AD is a progressive neurodegenerative disease, which can only be fully diagnosed at autopsy. It is characterized, histologically, by the presence of amyloid plaques and intracellular neurofibrillary tangles (NFT) in the brain [16]. The amyloid plaques consist of aggregated proteinaceous material, a significant component of amyloid  $\beta$  ( $A\beta$ ). The tangles are composed of paired helical filaments (PHF) of the microtubule-associated phosphoprotein tau [16, 17]. In this chapter, I will describe the main pathological similarities, and differences, between TBI and AD. Although the evidence suggests that TBI is a risk factor for dementia, very little is known about what type, frequency, or severity of trauma is necessary to induce dementia [18].

A chronic disease process is initiated after TBI, known as the secondary injury cascade, and as part of this process, neuroinflammation, neuronal loss, or the production, aggregation and clearance of  $A\beta$  peptides occurs [19]. Several of these pathophysiological features have been characterized in patients with AD with similar neuropathology. Furthermore, epidemiological studies have shown how repetitive injury, or a single mild, moderate, or severe TBI, can cause a wide range of proteinopathies [20], and likely contribute to the later onset of debilitating neurodegenerative diseases. Indeed, the human pathology of survival from TBI is best described as a “poly pathology”, featuring  $A\beta$ , tau, and TDP-43 pathologies, together with white matter degradation, neuronal loss, and neuroinflammation [21]. There exist many pathological features common to both acute brain injury and AD, including  $A\beta$  deposition, tau phosphorylation, neurite degeneration, synapse loss and microgliosis [22]. Besides, the susceptibility of the patient may be predetermined by multiple factors such as age, sex and the interplay of several genetic factors [23–25].

The purpose of this chapter is to discuss the neuropathology and genetic risk factors associated with TBI that may collectively shed some light on the risk of developing dementia or AD following head trauma, as well as possible treatments in animal models and human studies.

## **2. Traumatic brain injury, neuroinflammation, and its link with Alzheimer's disease**

Postmortem studies in human populations have shown microglia activation many years after TBI. Innate activation of microglia generally leads to amyloidogenic APP processing and the generation of  $A\beta$  plaques.  $A\beta$  plaques formed during the initial weeks after injury may regress with time. In this case, a continuously

renewed store of A $\beta$  in degenerating axons can be kept in check through degeneration by endogenous mediators or anti-inflammatory phagocytic microglia, or macrophages. A deficiency in microglia clearance of A $\beta$  could possibly account for this balance shift, especially since aging microglia are known to have a reduction in phagocytic capacity and this is also observed in AD, the most common age-related dementia [13].

Compelling epidemiological evidence indicates that moderate and severe TBI is associated with increased risk of development of progressive disorders of cognitive impairment leading to dementia or AD [15, 26–28]. Therefore, TBI is considered as a strong epigenetic risk factor for AD [29, 30]. A $\beta$  plaques, a hallmark of AD, are found in 30% of patients who do not survive TBI [13]. A history of TBI is a strong risk factor for AD, although there remains a lack of clear consensus around this topic since a few epidemiological studies have not uncovered such an association [31]. However, there exists strong evidence linking TBI to AD-related pathologies [32, 33]. Moderate and severe head injury increased the risk of AD for 2.3 and 4.5 times, respectively [30]. Although there is clinical evidence linking TBI and AD pathologies, there is an important lack of knowledge specific to the mechanisms driving this link.

In follow up studies, an increased incidence of head trauma in those with AD has been found only in males, not in females, and the risk of developing AD after TBI focused on injury severity [4, 25]. In studies where these criteria are more broadly defined, we can analyze the relative risk from head trauma of differing severity; it has been suggested [8] that a prior history of TBI accelerates the onset of AD and that the higher the incidence of severe the injury, the higher the risk of developing AD. Roberts et al. provided one of the first studies to closely examine A $\beta$  deposition after TBI [34] (**Table 1**). Data from subsequent studies have suggested that even a single moderate to severe TBI event is a significant risk factor for the later onset of dementia or AD [35, 36].

However, it remains unknown whether patients with prior brain damage instead develop a distinct clinical phenotype of dementia, different from that of the typical AD. Examination of human brain samples confirmed that TBI

Patients (N)	Category of TBI	Pathology associated, postmortem tissue	Time after injury	References
16	Severe TBI	38% A $\beta$ deposits, diffuse plaques	18 days of TBI	[34]
152	Severe TBI	30% A $\beta$ diffuse deposits 20% (under 40) A $\beta$ plaques 70% (60–80 age) A $\beta$ plaques (50% controls)	Several times	[96]
7	TBI	A $\beta$ 42 peptide 30% A $\beta$ diffuse deposits	Several times	[97]
18	Severe TBI	33% A $\beta$ deposits, A $\beta$ 42 peptide, diffuse plaques 80% neuronal/glial intracellular A $\beta$ peptides tau (PHF-1) axons	2–19 h	[36]
18	TBI	A $\beta$ 42 peptide, axonal damage, APP deposits, neurofilament, $\beta$ -secretase, g-secretase Tau-positive astrocytes	4 h–5 days	[22]
11	TBI	Tau-positive oligodendrocytes	2 h	[107]

**Table 1.**  
*Patients with TBI and associated AD pathology.*

<b>Animals</b>	<b>Animal injury model</b>	<b>Pathology associated to AD</b>	<b>Time post-injury</b>	<b>Brain regions</b>	<b>References</b>
Mouse (Tg2576)	Controlled cortical impact	Increase A $\beta$ 40 and A $\beta$ 42 levels	9–16 weeks	Cortex	[92]
Mouse (wild-type)	Controlled cortical impact	Increase A $\beta$ 40 oligomers and A $\beta$ 42 levels Increase pTau	3 days	Hippocampus	[37]
Mouse (3xTg-AD)	Repetitive mild TBI	Increase pTau	1 day	Fimbria	[93]
Mouse (3xTg-AD)	Controlled cortical impact	Increase A $\beta$ 40 levels Increase total Tau and pTau	1–24 h and 7 days	Cortex	[76, 108]
Mouse (h-Tau)	Repetitive mTBI	Increase pTau	21 d	Cortex	[77]
Mouse (APP-YAC)	Controlled cortical impact	Decrease A $\beta$ 40 levels, but not A $\beta$ 42	1 week	Cortex	[109]
Mouse (APPNLh/NLh)	Controlled cortical impact	Decrease of caspase-3 by administration of a pan-caspase inhibitor Reduction of caspase-cleaved APP, A $\beta$ 40 and A $\beta$ 40 Improved histological outcome	24 h 14 days	Cortex	[43]
	Controlled cortical impact	Administration of simvastatin resulted in decreased A $\beta$ levels Decreased hippocampal tissue loss Behavioural outcome improved	3 h	Hippocampus	[110]
Mouse (BACE knock-out)	Controlled cortical impact	Increase A $\beta$ 40 Improved histological, behavioural outcomes following injury Administration of a $\gamma$ -secretase inhibitor (DAPT) in non-transgenic mice improved outcomes	1–7 days	Cortex and hippocampus	[19]
	Controlled cortical impact	Increase A $\beta$ 40	23 days	Hippocampus	[111]
Mouse (PDAPP)	Controlled cortical impact	Increase A $\beta$ 40 and A $\beta$ 42 levels Increase neuronal death and memory impairment No A $\beta$ plaques	2 h–2 months	Cortex and hippocampus	[90]
	Controlled cortical impact	Decrease in A $\beta$ plaques	2, 5 and 8 months	Cortex and Hippocampus	[91]
	Controlled cortical impact	Decrease in A $\beta$ plaques	16 weeks	Hippocampus	[103]

Animals	Animal injury model	Pathology associated to AD	Time post-injury	Brain regions	References
Mouse (PDAPP) and Tg2576	Controlled cortical impact	Increase A $\beta$ baseline in transgenic and decrease A $\beta$ after injury	2–24 h	Interstitial fluid	[112]
Mouse (PDAPP) crossed with apoE3 and apoE4	Controlled cortical impact	56% apoE4:PDAPP: increase A $\beta$ deposition and amyloid plaques 20% apoE3:PDAPP: increase A $\beta$ deposition and amyloid plaques	3 months	Hippocampus	[100]
Mouse (ApoE3/ApoE4), or ApoE null mice	Closed head injury	ApoE4 Die or poorer outcomes than apoE3	11 days	Cortex	[113]
Rat (Sprague Dawley)	Weight drop (open skull)	APP accumulation in damaged axons No accumulating A $\beta$ observed intracellularly or in plaques	1, 3 and 21 days	Cortex and thalamus	[94]
	Lateral fluid percussion	APP accumulation in damaged axons No accumulating A $\beta$ observed intracellularly or in plaques	1 h, 2 h, 48 h, 1 week, or 2 weeks	Cortex, striatum, cingulum, and hippocampus	[95]
	Lateral fluid percussion	Reduction of A $\beta$ accumulated in damage axons according with severity of injury	2 days–1 year	White matter, cortex and thalamus	[114]
	Lateral fluid percussion	Increase pTau	6 months	White matter, cortex	[115]
	Weight drop (open skull)	APP and A $\beta$ identified in damaged axons No A $\beta$ plaques observed	6 h–10 days	White matter	[44]
	Controlled cortical impact	Increase cleaved Tau	6–168 h	Cortex	[116]
Swine	Rotational acceleration (model of DAI)	APP and A $\beta$ accumulation Diffuse A $\beta$ plaques Increase total Tau	3–10 days	White matter and cortex	[117]
	Rotational acceleration (model of DAI)	A $\beta$ , APP, BACE and presenilin-1 accumulation in damaged axons Diffuse A $\beta$ plaques	3h, 3 days, 6 months	Subcortical white matter	[65]

**Table 2.**  
*Animal studies on TBI and associated AD pathology.*

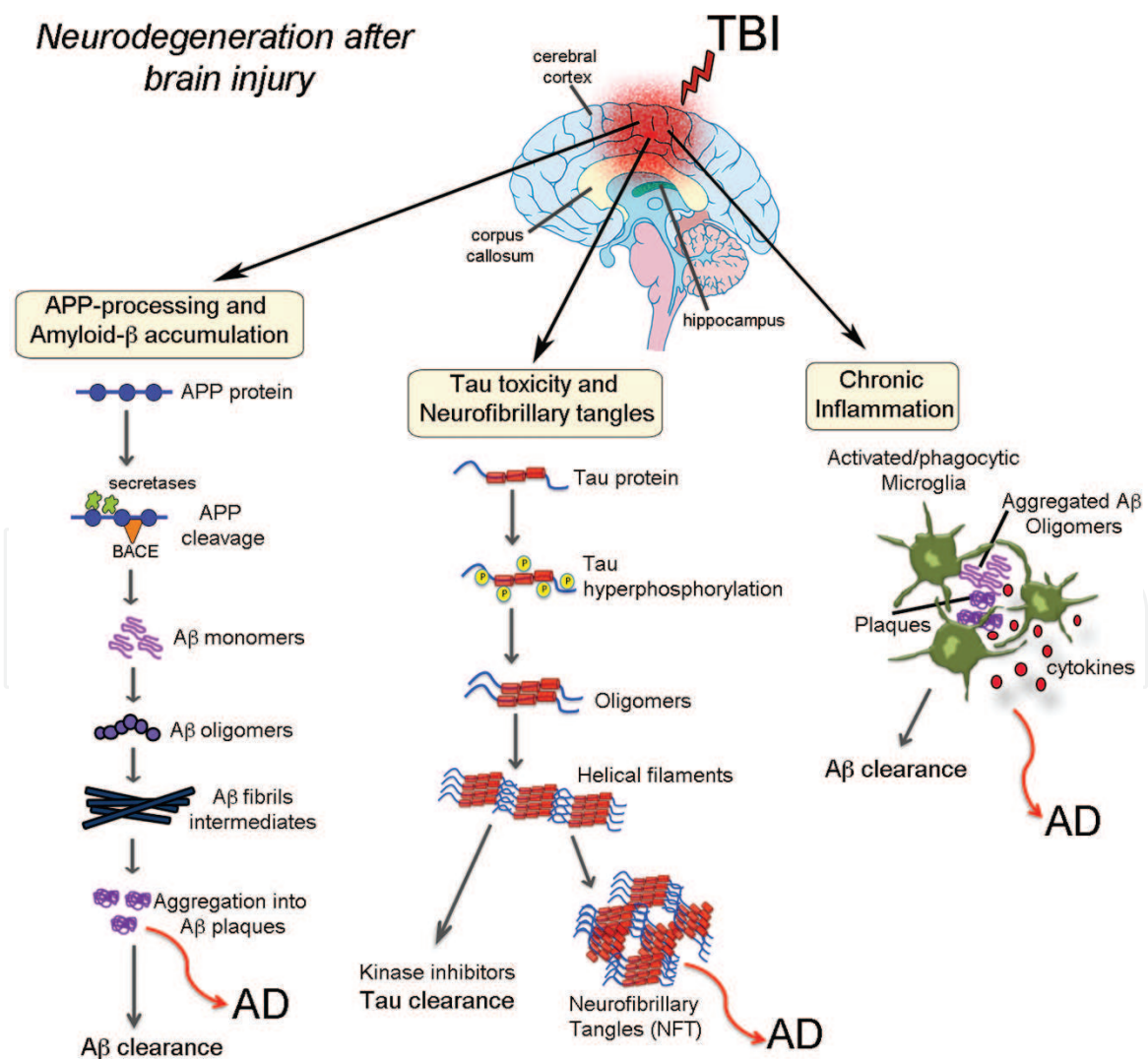
processes were the principal driver of accumulation of A $\beta$  peptides in swollen axons shortly after TBI, which persisted for years following the initial trauma [13]. In addition to such clinical studies, there exist multiple types of brain injuries in different animal models of AD. These animal models have been used to examine the formation, aggregation, and accumulation of A $\beta$  after injury; almost all of these are demonstrated an elevation in A $\beta$  levels after TBI (**Table 2**).

### 3. Neuropathology of TBI: related proteins

TBI regulates the expression patterns of several proteins commonly associated with neurodegenerative diseases, such as  $\alpha$ -synuclein, amyloid precursor protein,  $A\beta$ , TDP-43, and tau [37–40] (**Figure 1**). Besides, the ApoE4 gene and their cleaved products are implicated in neurodegenerative disorders, axonal pathology, and apoptosis following TBI [41, 42]. TBI also induces caspase-3, which is involved in APP processing, contributing to AD [43, 44]. This increase in APP expression and neuroinflammatory response following injury may contribute to a cycle of  $A\beta$  deposition and microglial activation that ultimately result in chronic neuropathology [45, 46]. In this section, I will summarize the principal proteins involved in TBI and AD and their associated factors in the neurodegenerative process.

#### 3.1 Amyloid precursor protein (APP)

APP and its proteolytic derivatives are important mediators of neuronal synaptogenesis and synapse maintenance [47]. APP functions in the axonal transport of vesicles and presenilin (PS) regulate intracellular protein trafficking, highlighting the role of APP as a synaptic vesicle protein [47]. TBI leads to overexpression



**Figure 1.** Relationship between neuropathological proteins induced after brain injury and the onset of Alzheimer's disease. Schematic diagram showing that traumatic brain injury (TBI) and Alzheimer's disease (AD) share similar pathological pathways (such as  $A\beta$  pathologies and TDP-43 proteinopathy) and neuroinflammatory responses that potentially could explain the vulnerability of TBI patients to the onset of dementia/AD.

of APP within neuronal cell bodies and APP accumulation within injured axons [48] (**Figure 2C**). Postmortem studies on human brain tissue samples from patients who have sustained mild TBI, but died due to other causes, have shown that APP accumulation occurs very rapidly (within a few hours) after brain [49]. Once mature, APP can be processed by two mutually exclusive complex pathways, either the non-amyloidogenic or the amyloidogenic pathway [50]. The non-amyloidogenic pathway accounts for the majority of APP processing and results in the secreted APP (sAPP $\alpha$ ) via  $\alpha$ -secretase cleavage [51]. The  $\beta$ - and  $\gamma$ -secretase pathway is responsible for producing secreted APP $\beta$  (sAPP $\beta$ ) and the toxic A $\beta$ , which is found within amyloid plaques in AD [52]. Both axonal APP accumulation and long-term accumulation of A $\beta$  has been reported in injured axons following TBI [53]. This large reservoir of APP in axons might be aberrantly cleaved to form A $\beta$  [49]. Evidence for the role of caspase-3 in APP cleavage and A $\beta$  production has come from recent studies examining the effects of caspase inhibition following trauma [43]. APP undergoes sequential proteolysis to produce plaque-forming A $\beta$  peptides.

## 3.2 Amyloid $\beta$ formation and amyloid plaques

### 3.2.1 Protein amyloid- $\beta$

Amyloid is a highly-ordered filamentous protein aggregate generally regarded as a misfolding event in which proteins that are soluble accumulate into fibrous structures [54]. However, determinants of amyloid formation and toxicity are largely unknown.

Edema, inflammatory response, vasculature changes, and deposition of A $\beta$  have all been found to be localized pathological changes after TBI [55]. As such, an understanding of the mechanism promoting AD risk is important. Although TBI is typically believed to be a static pathological insult from a single event, new clinical unrecognized clinical symptoms can arise many years after the initial injury. In human studies, TBI has been shown to result in amyloid deposits reminiscent of AD pathology.

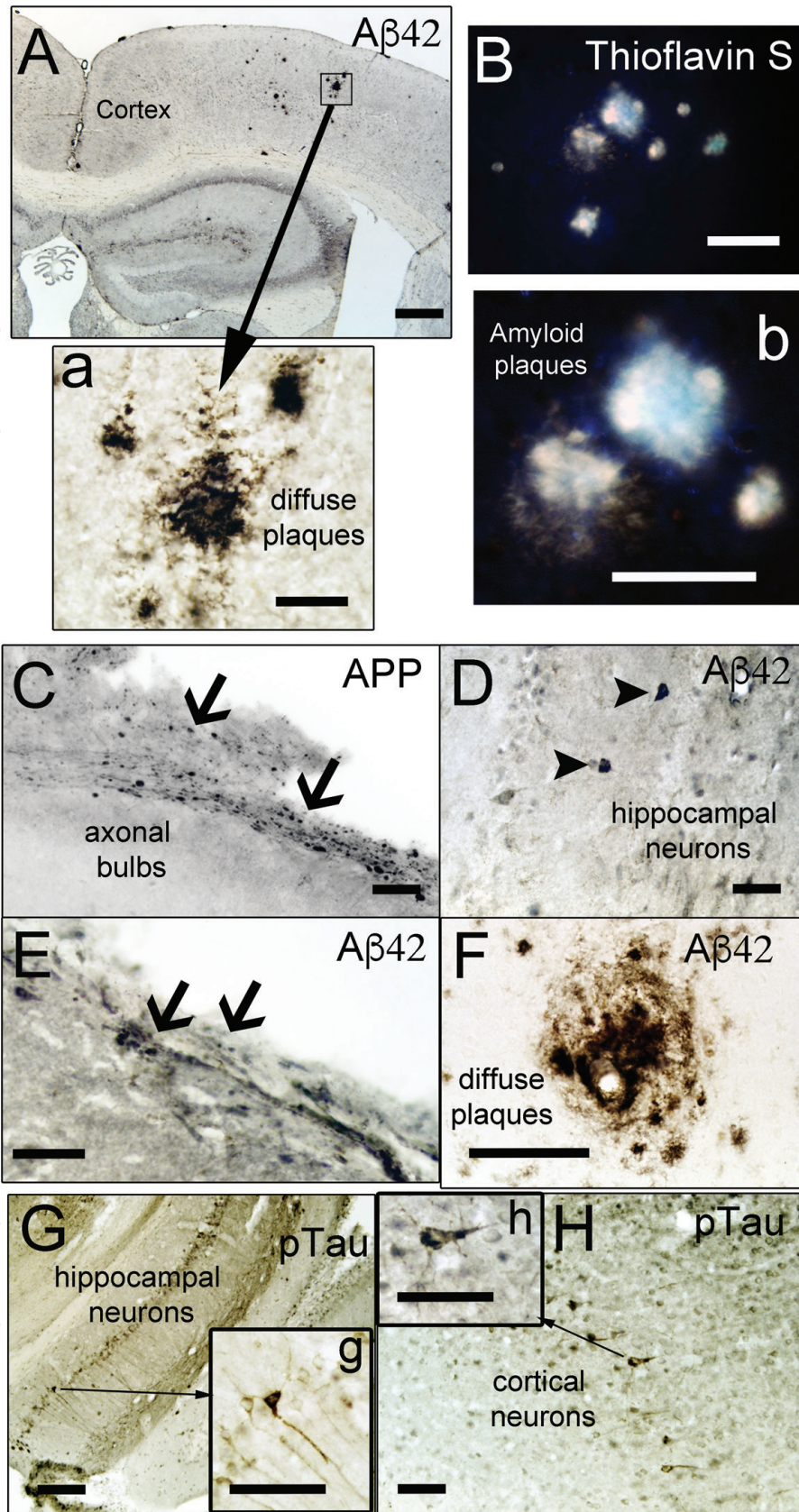
A $\beta$  immunoreactivity and protein expression increase for as long as a year after injury, indicating that A $\beta$  aggregation and plaques formation may continue long after APP gene expression returns to normal. Plaques found in TBI patients are strikingly similar to those observed in the early stages of AD [13, 14]. However, TBI-associated plaques can appear rapidly (within hours) after injury, whereas plaques in AD develop slowly and are found predominantly in the elderly [13].

Monomeric forms of A $\beta$  can aggregate to form oligomers, protofibrils; these fibrils deposit as amyloid plaque (**Figure 1**), unaggregated oligomeric forms of A $\beta$  may contribute to toxicity after TBI [56]. A $\beta$  causes apoptotic cell death of neuronal cells in culture by the induction of caspases, known instigators of apoptotic cell death [57]. Accumulation of A $\beta$  deposits, hippocampal damage, and chronic inflammation were found mainly in subcortical regions [18]. Early microglial accumulation in AD delays disease progression by promoting clearance of neurotoxic A $\beta$  peptides before the formation of senile plaques. However, as AD mice age, microglia become dysfunctional, producing proinflammatory cytokines in response to A $\beta$  aggregation downregulate genes involved in A $\beta$  clearance [58].

### 3.2.2 Mechanisms of post-traumatic amyloid- $\beta$ formation

The intracellular accumulation of A $\beta$ , extracellular deposition of soluble A $\beta$  plaques, and aggregation of tau protein have all been observed in patients, sometimes within hours after severe brain injury [59, 60]. A $\beta$  accumulation and amyloid





**Figure 2.** Representative immunohistochemical images showing neurodegenerative markers in a mouse model of Alzheimer's disease after brain injury. (A) A $\beta$  plaques detected using A $\beta$ 42 antibody in the cortex of AD model mice (3xTg-AD, 9 months old mice) (inset in A, high magnification in a). (B) A $\beta$  plaques detected using Thioflavin-S staining in the cortex of old 3xTg-AD (B, high magnification in b). (C) Representative broken axons stained with APP showing axonal bulbs found acutely following TBI in wild-type mice. (D–F) A $\beta$ 42 diffuse plaques were identified using an antibody specific for A $\beta$ 42 and were not detected by Thioflavin-S staining, in the CA1 hippocampal region (D), in the corpus callosum (E), and in the cortex (F) of wild-type mice. (G–H) Hippocampal neurons were stained using an antibody for phosphorylated tau in the CA1 hippocampus (G, high magnification in g) and cortical pyramidal layer (H, high magnification in h) after TBI in old 3xTg-AD mice. Scale bars: 200  $\mu$ m (A), 50  $\mu$ m (B–H), and 20  $\mu$ m (a, b, f, g, and h).

deposition precede the cognitive decline in Alzheimer's disease, with the pathology arriving later, and is associated with non-Alzheimer's disease dementia. Deposition of amyloid plaques from A $\beta$  peptide in Alzheimer's disease or acute phase of TBI have previously been reported to involve either mononuclear phagocytes, endocytic uptake, or proteolytic processing of the APP during fibril formation [61, 62]. Levels of A $\beta$  were found to be high days after TBI and then declined towards control levels in the subsequent 2 weeks. It has been suggested that a long-term process of A $\beta$  metabolism is initiated by TBI, which can be cleaved to form A $\beta$ . Both species of A $\beta$ , A $\beta$ 40, and A $\beta$ 42, are increased in the first week after injury in the CSF of TBI patients; other studies have shown comparatively lower A $\beta$ 40 levels compared to high levels of A $\beta$ 42 [63]. Intracellular A $\beta$  accumulation of non-plaque species of A $\beta$  is more common than plaque deposition after TBI. A $\beta$  is produced by sequential cleavage of the amyloid precursor protein APP via two enzymes,  $\beta$ - and  $\gamma$ -secretase. Depending on the cleavage point of  $\gamma$ -secretase, A $\beta$  peptides of different amino acid length are produced. The two most closely linked to AD are A $\beta$ 40 and A $\beta$ 42 [64]. The accumulation of A $\beta$  peptides is thought to be a major initiator event in AD pathogenesis (**Figure 1**). TBI leading to impaired axonal transport induces a long-term pathological co-accumulation of APP with  $\beta$ -site APP-cleavage enzyme 1 (BACE1), presenilin 1 and activated caspases, thus providing a possible mechanism for APP cleavage and production of A $\beta$  within axons following TBI [65]. The release of A $\beta$  (especially A $\beta$ 42) into tissue and plaque formation around damaged axons occurs after APP accumulation and A $\beta$  production in damaged axons. Both presenilin-1 (PS1) and BACE were found in swollen axons in the swine model and in humans (**Table 2**). Targeting the APP secretase enzymes can prevent the increase in A $\beta$  after TBI [19], specifically, A $\beta$ 42 was found to accumulate in the axonal bulbs of injured brains [22]. BACE1 and PS1 were increased in the damaged axons of TBI patients, and our previous studies have also shown that BACE1 and PS1 are considered the promising targets for the treatment of TBI [19].

Plaques have also been observed in pericontusional tissue surgically excised from survivors of TBI. Nevertheless, the key pathological similarity between TBI with AD is the observation that A $\beta$  plaques are found in up to 30% of patients who die of acute TBI [14]. While TBI-associated plaques largely appear in the gray matter, they have also been identified in white matter. Amyloid plaques consist primarily of aggregated A $\beta$  peptides, which are surrounded by dystrophic neurites, microglia, and reactive astrocytes [66, 67].

### 3.3 Tau protein and neurofibrillary tangles

The tau protein is associated with microtubules and plays a role in the outgrowth of neuronal processes and the development of neuronal polarity [68]. Misfolded and aggregated tau causes a gain of toxic function by hindering normal and axonal processes; axonal neurodegeneration due to the loss of tau is caused by a decrease in tau microtubule binding capabilities [69, 70]. Tau oligomerization is known as a critical mechanism in the development of NFTs, consisting of hyperphosphorylated tau proteins with pathological function [71]. AD is also characterized by intracellular hyperphosphorylated tau that constitutes the NFTs and senile plaques and is one of the most common tauopathies [72]. Furthermore, toxic tau proteins increase within hours after clinical brain injury [22], and their release and spreading effect may also contribute to the development of tauopathy following TBI [73]. It was described that the spatial pattern of the tau-immunoreactive pathology observed in chronic traumatic encephalopathy (CTE) is typical of the tauopathies [74]. The tau from both TBI and AD brains is phosphorylated at the same amino acids, resulting in the proteolytic cleavage of six isoforms known as

cleaved tau (c-tau), including the AT8 epitope [75]. Hyperphosphorylated Tau has been shown to increase between 1 and 7 days after moderate TBI in triple transgenic AD mice [76] and at 3 weeks after repetitive mild TBI in the human Tau (hTau) tauopathy mouse model [77] (**Table 2**). Experimental studies in animal models suggest that intra-axonal tau accumulation and tau phosphorylation may be in fact the consequences of repeated brain trauma or dementia pugilistica/CTE [78]. Today, CTE is used to define the neurological sequelae and neuropathological changes that occur as a result of repeat concussive or subconcussive blows to the head. Besides, the pathology of CTE is also characterized as a tauopathy, a class of neurodegenerative disease caused by the pathological aggregation of tau protein [78]. In CTE, NFTs also consist of hyperphosphorylated and ubiquitinated tau [79, 80]. Tau degradation in boxers with CTE are structurally and chemically similar to those seen in AD and frontotemporal lobar degeneration (FTLD) [80]. Treatment with  $\gamma$ -secretase inhibitors diminishes amyloid pathology but does not affect TBI-induced tangle formation, suggesting that TBI-induced tau pathology is not a downstream event of A $\beta$  and plaque formation [81].

### 3.4 TDP-43 pathology

TAR DNA-binding protein (TDP-43) protein has been identified as a regulator of gene expression and exon splicing with DNA and RNA binding capabilities. Hence, though TDP-43 is synthesized in the cytoplasm and resides in the nucleus of neurons and glia, under pathological conditions TDP-43 is accumulated in the cytoplasm in the form of ubiquitinated and hyperphosphorylated inclusions [82] (**Figure 1**). Pathological TDP-43 has been identified as the main disease-associated protein in ALS and FTLD. It has also been recognized as a secondary feature in many other neurodegenerative diseases, including Huntington disease, AD and PD [83]. Axonal damage results in an upregulation of TDP-43 expression, together with a redistribution of TDP-43 from the nuclear compartment to the cytoplasm [33, 84]. TBI induces TDP-43 abnormalities that can contribute to the neurological consequences of TBI, such as worse cell death, and cognitive deficits [85]. TDP-43 proteinopathy is also part of the acute or delayed pathological sequelae of repetitive mild, concussive TBI or CTE pathogenesis [86, 87]. The TDP-43 proteinopathy associated with CTE is similar to that found in FTLD with TDP-43 inclusions [87]. Intraneuronal accumulation of non-phosphorylated TDP-43 after a single TBI has also been reported [88]. Contrarily, related studies failed to demonstrate an association between single TBI and TDP-43 proteinopathy, only with repetitive TBI, indicating that just many insults reinforcing acute upregulation are sufficient to cause TDP-43 aggregation. Importantly, aggregates of phospho-TDP-43 were not increased long-term following TBI [88]. To the best of our knowledge, a clear functional role of altered TDP-43 expression levels after TBI has not been demonstrated, though this might disrupt signaling pathways involved in neuronal dysfunction, as some authors have suggested [89].

## 4. AD pathology in animal models of brain trauma

Several experimental animal models of TBI have been utilized in the attempt to replicate amyloid and tau pathologies, as well as other proteinopathies associated to AD. Some of these have been summarized in **Table 2**. Animal models of TBI show elevated A $\beta$  levels, A $\beta$  production, and A $\beta$  deposition, specific to the brain region and anatomy and varying with the type of injury. Observed in mice

that overexpress normal human APP, there is an increase in tissue concentrations of A $\beta$  after injury, associated with an increase in hippocampal neuronal death and memory impairment [43]. However, TBI alone does not seem to induce acute plaque formation systematically. Controlled cerebral impact (CCI) injury in an APP transgenic mouse model (PDAPP) has been shown to result in a spike in A $\beta$ 40 and A $\beta$ 42, peaking at 2 h post-injury and returning to baseline by 6 h [90]. Studies in PDAPP mice over greater intervals have shown that CCI can decrease the deposition of A $\beta$  in the ipsilateral cortex and hippocampus, up to 4–8 months after injury, compared to the uninjured side of the brain [91]. Additionally, CCI injuries, using in a different APP transgenic mouse model (Tg2576), have been shown cause elevated soluble and insoluble cortical A $\beta$ 40 and A $\beta$ 42 levels as well as amyloid plaque deposition [92]. Finally, studies in APP<sup>NLh/NLh</sup> mice, a gene-targeted mouse model that expresses normal levels of human APP, yielded elevated A $\beta$ 40 levels via inhibition of caspase-3 activity, only for the first 24 h after CCI, while A $\beta$ 42 levels remain elevated through 14 days [43]. Repetitive TBI is known to cause cumulative damage. After mild TBI in mice, during two consecutive days, studies have reported delayed recovery from fine motor coordination deficits as well as evidence of enhanced blood-brain barrier breakdown accompanied by axonal injury [21]. A recent study in an animal model using a triple-transgenic mouse model of Alzheimer's disease (3xTg-AD), the effect of repetitive mild TBI caused an increase of tau hyperphosphorylation and activation of asparaginyl endopeptidase (AEP), a cysteine proteinase which is known to be involved in tau phosphorylation [93].

In contrast, repetitive TBI in a Tg2576 APP-transgenic mice model did result in greater A $\beta$  deposition as well as an increase in the production of both soluble and insoluble cortical A $\beta$ 40 and A $\beta$ 42, which may be a result of the higher levels of oxidative stress after repetitive TBI [92]. However, TBI does not lead to early amyloid plaque formation in transgenic mice, and at later times there is a reduction in amyloid plaques in ipsilateral injury regions [90, 91]. Also, A $\beta$  accumulation was identified in damaged axons shortly after brain injury, albeit still in the absence of A $\beta$  plaques [94, 95]. However, the lack of evidence of A $\beta$  deposition in non-transgenic animals was attributed, in part, to differences in the A $\beta$  peptides found in different species. Experimental results of moderate and severe TBI studies in transgenic models of AD are also contrasted with that seen in human TBI (**Table 1**). First, rapid A $\beta$  deposition has not been demonstrated in any of the described transgenic models, unlike human studies [34, 36, 96, 97]. Second, increased severity of the injury does not result in increased A $\beta$  deposition; instead, it seems to correlate with reduced A $\beta$  deposition or possibly resolution of previously established plaques, as reported by [98]. In summary, all the animal models mentioned above provide important information regarding the potentially detrimental consequences of elevated A $\beta$  levels following TBI. However, post-traumatic A $\beta$  deposition has not been observed in the majority of non-transgenic animal studies; most failed to identify plaque pathology that is commonly observed following human TBI. To better understand the effects of repeat trauma on the brain, an animal model that can model the disease after repetitive trauma is required. Unfortunately, such an experimental model does not yet exist and will be challenging to generate.

## 5. Apolipoprotein E4 allele and TBI increase the risk of developing AD

The epidemiology of both AD and TBI are dominated by a single genetic risk factor, the APOE genotype. In humans, there are three distinct isoforms of

the protein: apoE2, apoE3, and apoE4, distinguished by three alleles [99]. The apoE  $\epsilon$ 4 allele confers strong susceptibility for AD and is also the factor for the development of amyloid plaques after TBI. Furthermore, the apoE  $\epsilon$ 4 allele has been associated with increased A $\beta$  in the cerebral cortex and unfavorable outcome after TBI [100]. ApoE4 individuals were over 10 times more likely to develop AD after severe TBI than those who did not possess the allele [101], and the presence of an apoE4 allele is linked to poor recovery from extended coma. Professional boxers containing the apoE  $\epsilon$ 4 allele were at increased risk of CTE compared to boxers without the apoE  $\epsilon$ 4 allele [102]. This finding suggests that genetic factors may strongly influence the risk of CTE after brain injury. However, the possibility remains that certain boxers may be innately 'resistant' to developing AD or dementia following CTE; definitely, not all boxers go on to develop AD, despite repetitive injury and having the higher risk genotype. Consistent with a role of ApoE protein in amyloid deposition in humans, apoE4 also increases amyloid plaque formation in mice. A $\beta$  deposition is also significantly increased following head trauma in PDAPP (platelet-derived growth factor promoter expressing amyloid precursor protein) mice carrying the human apoE  $\epsilon$ 4 allele versus those carrying apoE  $\epsilon$ 3 or no apoE (**Table 2**) [103]. Finally, transgenic APOE  $\epsilon$ 4 mice, which also overexpress APP, show accelerated deposition of A $\beta$  following injury, suggesting apoE  $\epsilon$ 4 may reduce the clearance of A $\beta$ , thereby favoring its deposition [100] (**Table 2**). Some recent reports are controversial clinical and preclinical studies about the link between poor outcome after severe and mild TBI and the APOE4 gene [11, 16, 30, 104, 105].

## 6. Similarities and differences in the neuropathology of TBI and AD

The similarities and differences in the neuropathology associated to TBI and AD are complex. A $\beta$  formation and aggregation, tau phosphorylation, including other proteins found in the brain and CSF following TBI, share a lot of similarities with AD, but also several evident differences. Principally, the localization and distribution of proteins in TBI patients are fundamentally distinct from the characteristic pattern commonly observed in AD [13]. However, one strong similarity between TBI and AD is in the A $\beta$  plaque formation; both are primarily composed of A $\beta$  41–42, furthermore, CSF levels of A $\beta$  are increased similarly for both [106]. However, in AD there are numerous, compact, core A $\beta$  aggregates in addition to neurofibrillary tangles and neuropil threads, this in contrast to TBI where there appears to be a higher prevalence of diffuse A $\beta$  plaques [34, 36]. Notably, A $\beta$  plaques in TBI are typically described as diffuse and do not display the histochemical or morphological features of the senile plaques that are characteristic of AD [35]. A $\beta$  toxicity only emerges when levels exceed a certain threshold, and unaggregated oligomeric forms of A $\beta$  may contribute to toxicity. As such, rapid aggregation of A $\beta$  into plaques may be a protective event following TBI [73]. In CTE, the tau inclusions are morphologically most similar to those found in AD, with pyramidal neurons maintaining their shape, and tangles consisting of hyperphosphorylated and ubiquitinated tau [84]. This phospho-tau staining was also observed in axons and clusters of neuronal cell bodies in the cerebral cortex and hippocampus (**Figure 2G and H**). Such studies have also noted the existence of tau-positive reactive astrocytes in AD, a pathology that is not usually associated with AD. Finally, the tau immunoreactive profile of CTE is characteristically very patchy and irregular, with preferential deposition in the superficial neocortical layers, while tangles in AD are found in deep and in superficial layers [33]. In summary, while there are certain important differences between mild, moderate, and severe TBI and dementia or AD, given the significant overlap

in neuropathology, there is still much that can be gleaned by closely comparing the molecular and cellular mechanisms involved in both of these neuropathological processes.

## **7. Conclusions**

The association between trauma and the onset of neurodegenerative diseases, such as AD, is extremely convoluted, further complicated by the absence of appropriate animal models able to reproduce human pathologies. Elucidation of this nature of this link remains in its infancy, requiring extensive further research to chip away at the underlying relationship. Moreover, quantification of the relative contributions of various risk factors for developing these pathologies, such as cellular and molecular mechanisms, frequency and severity of the injury, age, sex, and potential genetic predisposition, remain mostly imprecise. Although we do not know how TBI fundamentally impacts the long-term outcome and affects the risk of dementia, it remains clear that amyloid pathways play an important role in secondary injury and acute cell death after trauma. Continued efforts to investigate why TBI, and repeat concussions, may lead to AD and other associated dementias are required. Further understanding of the molecular mechanism underlying these events is required, achievable via better designed animal models able to more closely and accurately mimic the observed behavioral and pathological changes. Only then will we be well equipped to precisely evaluate novel therapeutic agents that may intervene in the disease process. Future research will be required to uncover the mechanisms through which TBI increases the risk of AD, opening the door to designer treatment strategies for the full scope of post-traumatic injuries.

## **Acknowledgements**

This work was supported by R21NS106640 (SV) and R03NS09503 (SV) from the National Institute for Neurological Disorders and Stroke (NINDS).

## **Conflict of interest**

There are no conflicts of interest to disclose.

IntechOpen

## **Author details**

Sonia Villapol<sup>1,2</sup>

1 Center for Neuroregeneration and Department of Neurosurgery, Institute for Academic Medicine, Houston Methodist Research Institute, Houston, TX, USA

2 Department of Neuroscience in Neurological Surgery, Weill Cornell Medical College, NY, USA

\*Address all correspondence to: [svillapol@houstonmethodist.org](mailto:svillapol@houstonmethodist.org)

## **IntechOpen**

---

© 2018 The Author(s). Licensee IntechOpen. This chapter is distributed under the terms of the Creative Commons Attribution License (<http://creativecommons.org/licenses/by/3.0>), which permits unrestricted use, distribution, and reproduction in any medium, provided the original work is properly cited. 

## References

- [1] Zitnay GA. Lessons from national and international TBI societies and funds like NBIRTT. *Acta Neurochirurgica. Supplement.* 2005;**93**:131-133
- [2] Chua KS, Ng YS, Yap SG, Bok CW. A brief review of traumatic brain injury rehabilitation. *Annals of the Academy of Medicine, Singapore.* 2007;**36**(1):31-42
- [3] Kibby MY, Long CJ. Minor head injury: Attempts at clarifying the confusion. *Brain Injury.* 1996;**10**(3):159-186
- [4] Taylor CA, Bell JM, Breiding MJ, Xu L. Traumatic brain injury-related emergency department visits, hospitalizations, and deaths—United States, 2007 and 2013. *MMWR Surveillance Summaries.* 2017;**66**(9):1-16
- [5] Langlois JA, Rutland-Brown W, Wald MM. The epidemiology and impact of traumatic brain injury: A brief overview. *The Journal of Head Trauma Rehabilitation.* 2006;**21**(5):375-378
- [6] Clausen T, Bullock R. Medical treatment and neuroprotection in traumatic brain injury. *Current Pharmaceutical Design.* 2001;**7**(15):1517-1532
- [7] Mendez MF. What is the relationship of traumatic brain injury to dementia? *Journal of Alzheimer's Disease.* 2017;**57**(3):667-681
- [8] Little DM, Geary EK, Moynihan M, Alexander A, Pennington M, Glang P, et al. Imaging chronic traumatic brain injury as a risk factor for neurodegeneration. *Alzheimer's & Dementia.* 2014;**10**(3 Suppl):S188-S195
- [9] Mouzon BC, Bachmeier C, Ferro A, Ojo JO, Crynen G, Acker CM, et al. Chronic neuropathological and neurobehavioral changes in a repetitive mild traumatic brain injury model. *Annals of Neurology.* 2014;**75**(2):241-254
- [10] Gavett BE, Stern RA, Cantu RC, Nowinski CJ, McKee AC. Mild traumatic brain injury: A risk factor for neurodegeneration. *Alzheimer's Research & Therapy.* 2010;**2**(3):18
- [11] Jellinger KA. Head injury and dementia. *Current Opinion in Neurology.* 2004;**17**(6):719-723
- [12] Breunig JJ, Guillot-Sestier MV, Town T. Brain injury, neuroinflammation and Alzheimer's disease. *Frontiers in Aging Neuroscience.* 2013;**5**:26
- [13] Johnson VE, Stewart W, Smith DH. Traumatic brain injury and amyloid-beta pathology: A link to Alzheimer's disease? *Nature Reviews. Neuroscience.* 2010;**11**(5):361-370
- [14] Sivanandam TM, Thakur MK. Traumatic brain injury: A risk factor for Alzheimer's disease. *Neuroscience and Biobehavioral Reviews.* 2012;**36**(5):1376-1381
- [15] Van Den Heuvel C, Thornton E, Vink R. Traumatic brain injury and Alzheimer's disease: A review. *Progress in Brain Research.* 2007;**161**:303-316
- [16] Jellinger KA, Bancher C. Neuropathology of Alzheimer's disease: A critical update. *Journal of Neural Transmission. Supplementum.* 1998;**54**:77-95
- [17] Dickson DW. Neuropathological diagnosis of Alzheimer's disease: A perspective from longitudinal clinicopathological studies. *Neurobiology of Aging.* 1997;**18**(4 Suppl):S21-S26



- [18] Wang HK, Lin SH, Sung PS, Wu MH, Hung KW, Wang LC, et al. Population based study on patients with traumatic brain injury suggests increased risk of dementia. *Journal of Neurology, Neurosurgery, and Psychiatry*. 2012;**83**(11):1080-1085
- [19] Loane DJ, Pocivavsek A, Moussa CE, Thompson R, Matsuoka Y, Faden AI, et al. Amyloid precursor protein secretases as therapeutic targets for traumatic brain injury. *Nature Medicine*. 2009;**15**(4):377-379
- [20] Kenney K, Iacono D, Edlow BL, Katz DI, Diaz-Arrastia R, Dams-O'Connor K, et al. Dementia after moderate-severe traumatic brain injury: Coexistence of multiple proteinopathies. *Journal of Neuropathology and Experimental Neurology*. 2018;**77**(1):50-63
- [21] Zakaria N, Kallakuri S, Bandaru S, Cavanaugh JM. Temporal assessment of traumatic axonal injury in the rat corpus callosum and optic chiasm. *Brain Research*. 2012;**1467**:81-90
- [22] Uryu K, Chen XH, Martinez D, Browne KD, Johnson VE, Graham DI, et al. Multiple proteins implicated in neurodegenerative diseases accumulate in axons after brain trauma in humans. *Experimental Neurology*. 2007;**208**(2):185-192
- [23] Sundman MH, Hall EE, Chen NK. Examining the relationship between head trauma and neurodegenerative disease: A review of epidemiology, pathology and neuroimaging techniques. *Journal of Alzheimers Disease & Parkinsonism*. 2014;**4**:137. DOI: 10.4172/2161-0460.1000137
- [24] Zandi PP, Carlson MC, Plassman BL, Welsh-Bohmer KA, Mayer LS, Steffens DC, et al. Hormone replacement therapy and incidence of Alzheimer disease in older women: The Cache County Study. *Journal of the American Medical Association*. 2002;**288**(17):2123-2129
- [25] O'Meara ES, Kukull WA, Sheppard L, Bowen JD, McCormick WC, Teri L, et al. Head injury and risk of Alzheimer's disease by apolipoprotein E genotype. *American Journal of Epidemiology*. 1997;**146**(5):373-384
- [26] Julien J, Joubert S, Ferland MC, Frenette LC, Boudreau-Duhaime MM, Malo-Veronneau L, et al. Association of traumatic brain injury and Alzheimer disease onset: A systematic review. *Annals of Physical and Rehabilitation Medicine*. 2017;**60**(5):347-356
- [27] Plassman BL, Grafman J. Traumatic brain injury and late-life dementia. *Handbook of Clinical Neurology*. 2015;**128**:711-722
- [28] Lye TC, Shores EA. Traumatic brain injury as a risk factor for Alzheimer's disease: A review. *Neuropsychology Review*. 2000;**10**(2):115-129
- [29] Magnoni S, Brody DL. New perspectives on amyloid-beta dynamics after acute brain injury: Moving between experimental approaches and studies in the human brain. *Archives of Neurology*. 2010;**67**(9):1068-1073
- [30] Plassman BL, Havlik RJ, Steffens DC, Helms MJ, Newman TN, Drosdick D, et al. Documented head injury in early adulthood and risk of Alzheimer's disease and other dementias. *Neurology*. 2000;**55**(8):1158-1166
- [31] Washington PM, Villapol S, Burns MP. Polypathology and dementia after brain trauma: Does brain injury trigger distinct neurodegenerative diseases, or should they be classified together as traumatic encephalopathy? *Experimental Neurology*. 2016;**275**(Pt 3):381-388
- [32] Shively S, Scher AI, Perl DP, Diaz-Arrastia R. Dementia resulting from traumatic brain injury: What is the

pathology? *Archives of Neurology*. 2012;**69**(10):1245-1251

[33] Blennow K, Hardy J, Zetterberg H. The neuropathology and neurobiology of traumatic brain injury. *Neuron*. 2012;**76**(5):886-899

[34] Roberts GW, Gentleman SM, Lynch A, Graham DI. Beta A4 amyloid protein deposition in brain after head trauma. *Lancet*. 1991;**338**(8780):1422-1423

[35] DeKosky ST, Abrahamson EE, Ciallella JR, Paljug WR, Wisniewski SR, Clark RS, et al. Association of increased cortical soluble abeta42 levels with diffuse plaques after severe brain injury in humans. *Archives of Neurology*. 2007;**64**(4):541-544

[36] Ikonovic MD, Uryu K, Abrahamson EE, Ciallella JR, Trojanowski JQ, Lee VM, et al. Alzheimer's pathology in human temporal cortex surgically excised after severe brain injury. *Experimental Neurology*. 2004;**190**(1):192-203

[37] Yu F, Zhang Y, Chuang DM. Lithium reduces BACE1 overexpression, beta amyloid accumulation, and spatial learning deficits in mice with traumatic brain injury. *Journal of Neurotrauma*. 2012;**29**(13):2342-2351

[38] Su E, Bell MJ, Wisniewski SR, Adelson PD, Janesko-Feldman KL, Salonia R, et al. Alpha-Synuclein levels are elevated in cerebrospinal fluid following traumatic brain injury in infants and children: The effect of therapeutic hypothermia. *Developmental Neuroscience*. 2010;**32**(5-6):385-395

[39] Surgucheva I, He S, Rich MC, Sharma R, Ninkina NN, Stahel PF, et al. Role of synucleins in traumatic brain injury—An experimental in vitro and in vivo study in mice. *Molecular and Cellular Neurosciences*. 2014;**63C**:114-123

[40] Laskowitz DT, Song P, Wang H, Mace B, Sullivan PM, Vitek MP, et al. Traumatic brain injury exacerbates neurodegenerative pathology: Improvement with an apolipoprotein E-based therapeutic. *Journal of Neurotrauma*. 2010;**27**(11):1983-1995

[41] Chauhan NB. Chronic neurodegenerative consequences of traumatic brain injury. *Restorative Neurology and Neuroscience*. 2014;**32**(2):337-365

[42] Sun XC, Jiang Y. Genetic susceptibility to traumatic brain injury and apolipoprotein E gene. *Chinese Journal of Traumatology*. 2008;**11**(4):247-252

[43] Abrahamson EE, Ikonovic MD, Ciallella JR, Hope CE, Paljug WR, Isanski BA, et al. Caspase inhibition therapy abolishes brain trauma-induced increases in Abeta peptide: Implications for clinical outcome. *Experimental Neurology*. 2006;**197**(2):437-450

[44] Stone JR, Okonkwo DO, Singleton RH, Mutlu LK, Helm GA, Povlishock JT. Caspase-3-mediated cleavage of amyloid precursor protein and formation of amyloid Beta peptide in traumatic axonal injury. *Journal of Neurotrauma*. 2002;**19**(5):601-614

[45] Hellewell SC, Yan EB, Agyapomaa DA, Bye N, Morganti-Kossmann MC. Post-traumatic hypoxia exacerbates brain tissue damage: Analysis of axonal injury and glial responses. *Journal of Neurotrauma*. 2010;**27**(11):1997-2010

[46] Chen XH, Johnson VE, Uryu K, Trojanowski JQ, Smith DH. A lack of amyloid beta plaques despite persistent accumulation of amyloid beta in axons of long-term survivors of traumatic brain injury. *Brain Pathology*. 2009;**19**(2):214-223

- [47] Groemer TW, Thiel CS, Holt M, Riedel D, Hua Y, Huve J, et al. Amyloid precursor protein is trafficked and secreted via synaptic vesicles. *PLoS One*. 2011;**6**(4):e18754
- [48] Itoh T, Satou T, Nishida S, Tsubaki M, Hashimoto S, Ito H. Expression of amyloid precursor protein after rat traumatic brain injury. *Neurological Research*. 2009;**31**(1):103-109
- [49] Marklund N, Farrokhnia N, Hanell A, Vanmechelen E, Enblad P, Zetterberg H, et al. Monitoring of beta-amyloid dynamics after human traumatic brain injury. *Journal of Neurotrauma*. 2014;**31**(1):42-55
- [50] Kowalska A. The beta-amyloid cascade hypothesis: A sequence of events leading to neurodegeneration in Alzheimer's disease. *Neurologia i Neurochirurgia Polska*. 2004;**38**(5):405-411
- [51] Kojro E, Fahrenholz F. The non-amyloidogenic pathway: Structure and function of alpha-secretases. *Sub-Cellular Biochemistry*. 2005;**38**:105-127
- [52] Mattson MP, Barger SW, Furukawa K, Bruce AJ, Wyss-Coray T, Mark RJ, et al. Cellular signaling roles of TGF beta, TNF alpha and beta APP in brain injury responses and Alzheimer's disease. *Brain Research. Brain Research Reviews*. 1997;**23**(1-2):47-61
- [53] Smith DH, Chen XH, Iwata A, Graham DI. Amyloid beta accumulation in axons after traumatic brain injury in humans. *Journal of Neurosurgery*. 2003;**98**(5):1072-1077
- [54] Harrison RS, Sharpe PC, Singh Y, Fairlie DP. Amyloid peptides and proteins in review. *Reviews of Physiology, Biochemistry and Pharmacology*. 2007;**159**:1-77
- [55] Muller UC, Deller T, Korte M. Not just amyloid: Physiological functions of the amyloid precursor protein family. *Nature Reviews. Neuroscience*. 2017;**18**(5):281-298
- [56] Hardy J, Selkoe DJ. The amyloid hypothesis of Alzheimer's disease: Progress and problems on the road to therapeutics. *Science*. 2002;**297**(5580):353-356
- [57] Tweedie D, Milman A, Holloway HW, Li Y, Harvey BK, Shen H, et al. Apoptotic and behavioral sequelae of mild brain trauma in mice. *Journal of Neuroscience Research*. 2007;**85**(4):805-815
- [58] Hickman SE, Allison EK, El Khoury J. Microglial dysfunction and defective beta-amyloid clearance pathways in aging Alzheimer's disease mice. *The Journal of Neuroscience*. 2008;**28**(33):8354-8360
- [59] Davies NM, Kehoe PG, Ben-Shlomo Y, Martin RM. Associations of anti-hypertensive treatments with Alzheimer's disease, vascular dementia, and other dementias. *Journal of Alzheimer's Disease*. 2011;**26**(4):699-708
- [60] An J, Nakajima T, Kuba K, Kimura A. Losartan inhibits LPS-induced inflammatory signaling through a PPARgamma-dependent mechanism in human THP-1 macrophages. *Hypertension Research*. 2010;**33**(8):831-835
- [61] Harper JD, Lansbury PT Jr. Models of amyloid seeding in Alzheimer's disease and scrapie: Mechanistic truths and physiological consequences of the time-dependent solubility of amyloid proteins. *Annual Review of Biochemistry*. 1997;**66**:385-407
- [62] Peters PJ, Mironov A Jr, Peretz D, van Donselaar E, Leclerc E, Erpel S, et al. Trafficking of prion proteins through a caveolae-mediated endosomal pathway. *The Journal of Cell Biology*. 2003;**162**(4):703-717

- [63] Olsson A, Csajbok L, Ost M, Hoglund K, Nylen K, Rosengren L, et al. Marked increase of beta-amyloid(1-42) and amyloid precursor protein in ventricular cerebrospinal fluid after severe traumatic brain injury. *Journal of Neurology*. 2004;**251**(7):870-876
- [64] Morishima-Kawashima M. Molecular mechanism of the intramembrane cleavage of the beta-carboxyl terminal fragment of amyloid precursor protein by gamma-secretase. *Frontiers in Physiology*. 2014;**5**:463
- [65] Chen XH, Siman R, Iwata A, Meaney DF, Trojanowski JQ, Smith DH. Long-term accumulation of amyloid-beta, beta-secretase, presenilin-1, and caspase-3 in damaged axons following brain trauma. *The American Journal of Pathology*. 2004;**165**(2):357-371
- [66] von Bernhardt R, Eugenin J. Microglial reactivity to beta-amyloid is modulated by astrocytes and proinflammatory factors. *Brain Research*. 2004;**1025**(1-2):186-193
- [67] Mannix RC, Whalen MJ. Traumatic brain injury, microglia, and beta amyloid. *International Journal of Alzheimer's Disease*. 2012;**2012**:608732
- [68] Ginzburg I. Neuronal polarity: Targeting of microtubule components into axons and dendrites. *Trends in Biochemical Sciences*. 1991;**16**(7):257-261
- [69] Johnson GV, Stoothoff WH. Tau phosphorylation in neuronal cell function and dysfunction. *Journal of Cell Science*. 2004;**117**(Pt 24):5721-5729
- [70] Drewes G. MARKing tau for tangles and toxicity. *Trends in Biochemical Sciences*. 2004;**29**(10):548-555
- [71] Cowan CM, Quraishe S, Mudher A. What is the pathological significance of tau oligomers? *Biochemical Society Transactions*. 2012;**40**(4):693-697
- [72] Lukiw WJ, Bazan NG. Neuroinflammatory signaling upregulation in Alzheimer's disease. *Neurochemical Research*. 2000;**25**(9-10):1173-1184
- [73] Hawkins BE, Krishnamurthy S, Castillo-Carranza DL, Sengupta U, Prough DS, Jackson GR, et al. Rapid accumulation of endogenous tau oligomers in a rat model of traumatic brain injury: Possible link between traumatic brain injury and sporadic tauopathies. *The Journal of Biological Chemistry*. 2013;**288**(23):17042-17050
- [74] Armstrong RA, McKee AC, Alvarez VE, Cairns NJ. Clustering of tau-immunoreactive pathology in chronic traumatic encephalopathy. *Journal of Neural Transmission (Vienna)*. 2017;**124**(2):185-192
- [75] Gordon-Krajcer W, Kozniowska E, Lazarewicz JW, Ksiezak-Reding H. Differential changes in phosphorylation of tau at PHF-1 and 12E8 epitopes during brain ischemia and reperfusion in gerbils. *Neurochemical Research*. 2007;**32**(4-5):729-737
- [76] Tran HT, Sanchez L, Esparza TJ, Brody DL. Distinct temporal and anatomical distributions of amyloid-beta and tau abnormalities following controlled cortical impact in transgenic mice. *PLoS One*. 2011;**6**(9):e25475
- [77] Ojo JO, Mouzon B, Greenberg MB, Bachmeier C, Mullan M, Crawford F. Repetitive mild traumatic brain injury augments tau pathology and glial activation in aged hTau mice. *Journal of Neuropathology and Experimental Neurology*. 2013;**72**(2):137-151
- [78] Mitsis EM, Riggio S, Kostakoglu L, Dickstein DL, Machac J, Delman B, et al. Tauopathy PET and amyloid PET in the diagnosis of chronic traumatic

encephalopathies: Studies of a retired NFL player and of a man with FTD and a severe head injury. *Translational Psychiatry*. 2014;**4**:e441

[79] Kokjohn TA, Maarouf CL, Dausgs ID, Hunter JM, Whiteside CM, Malek-Ahmadi M, et al. Neurochemical profile of dementia pugilistica. *Journal of Neurotrauma*. 2013;**30**(11):981-997

[80] Tartaglia MC, Hazrati LN, Davis KD, Green RE, Wennberg R, Mikulis D, et al. Chronic traumatic encephalopathy and other neurodegenerative proteinopathies. *Frontiers in Human Neuroscience*. 2014;**8**:30

[81] Tran HT, LaFerla FM, Holtzman DM, Brody DL. Controlled cortical impact traumatic brain injury in 3xTg-AD mice causes acute intra-axonal amyloid-beta accumulation and independently accelerates the development of tau abnormalities. *The Journal of Neuroscience*. 2011;**31**(26):9513-9525

[82] Neumann M, Sampathu DM, Kwong LK, Truax AC, Micsenyi MC, Chou TT, et al. Ubiquitinated TDP-43 in frontotemporal lobar degeneration and amyotrophic lateral sclerosis. *Science*. 2006;**314**(5796):130-133

[83] Chen-Plotkin AS, Lee VM, Trojanowski JQ. TAR DNA-binding protein 43 in neurodegenerative disease. *Nature Reviews. Neurology*. 2010;**6**(4):211-220

[84] McKee AC, Daneshvar DH, Alvarez VE, Stein TD. The neuropathology of sport. *Acta Neuropathologica*. 2014;**127**(1):29-51

[85] Tan XL, Sun M, Brady RD, Liu S, Llanos R, Cheung S, et al. Transactive response DNA-binding protein 43 abnormalities after traumatic brain injury. *Journal of Neurotrauma*. 2018. DOI: 10.1089/neu.2017.5491

[86] King A, Sweeney F, Bodi I, Troakes C, Maekawa S, Al-Sarraj S. Abnormal

TDP-43 expression is identified in the neocortex in cases of dementia pugilistica, but is mainly confined to the limbic system when identified in high and moderate stages of Alzheimer's disease. *Neuropathology*. 2010;**30**(4):408-419

[87] McKee AC, Gavett BE, Stern RA, Nowinski CJ, Cantu RC, Kowall NW, et al. TDP-43 proteinopathy and motor neuron disease in chronic traumatic encephalopathy. *Journal of Neuropathology and Experimental Neurology*. 2010;**69**(9):918-929

[88] Johnson VE, Stewart W, Trojanowski JQ, Smith DH. Acute and chronically increased immunoreactivity to phosphorylation-independent but not pathological TDP-43 after a single traumatic brain injury in humans. *Acta Neuropathologica*. 2011;**122**(6):715-726

[89] Kwong LK, Neumann M, Sampathu DM, Lee VM, Trojanowski JQ. TDP-43 proteinopathy: The neuropathology underlying major forms of sporadic and familial frontotemporal lobar degeneration and motor neuron disease. *Acta Neuropathologica*. 2007;**114**(1):63-70

[90] Smith DH, Nakamura M, McIntosh TK, Wang J, Rodriguez A, Chen XH, et al. Brain trauma induces massive hippocampal neuron death linked to a surge in beta-amyloid levels in mice overexpressing mutant amyloid precursor protein. *The American Journal of Pathology*. 1998;**153**(3):1005-1010

[91] Nakagawa Y, Nakamura M, McIntosh TK, Rodriguez A, Berlin JA, Smith DH, et al. Traumatic brain injury in young, amyloid-beta peptide overexpressing transgenic mice induces marked ipsilateral hippocampal atrophy and diminished Abeta deposition during aging. *The Journal of Comparative Neurology*. 1999;**411**(3):390-398

- [92] Uryu K, Laurer H, McIntosh T, Pratico D, Martinez D, Leight S, et al. Repetitive mild brain trauma accelerates Abeta deposition, lipid peroxidation, and cognitive impairment in a transgenic mouse model of Alzheimer amyloidosis. *The Journal of Neuroscience*. 2002;22(2):446-454
- [93] Hu W, Tung YC, Zhang Y, Liu F, Iqbal K. Involvement of activation of asparaginyl endopeptidase in tau hyperphosphorylation in repetitive mild traumatic brain injury. *Journal of Alzheimer's Disease*. 2018;64(3):709-722
- [94] Lewen A, Li GL, Nilsson P, Olsson Y, Hillered L. Traumatic brain injury in rat produces changes of beta-amyloid precursor protein immunoreactivity. *Neuroreport*. 1995;6(2):357-360
- [95] Pierce JE, Trojanowski JQ, Graham DI, Smith DH, McIntosh TK. Immunohistochemical characterization of alterations in the distribution of amyloid precursor proteins and beta-amyloid peptide after experimental brain injury in the rat. *The Journal of Neuroscience*. 1996;16(3):1083-1090
- [96] Roberts GW, Gentleman SM, Lynch A, Murray L, Landon M, Graham DI. Beta amyloid protein deposition in the brain after severe head injury: Implications for the pathogenesis of Alzheimer's disease. *Journal of Neurology, Neurosurgery, and Psychiatry*. 1994;57(4):419-425
- [97] Gentleman SM, Greenberg BD, Savage MJ, Noori M, Newman SJ, Roberts GW, et al. A beta 42 is the predominant form of amyloid beta-protein in the brains of short-term survivors of head injury. *Neuroreport*. 1997;8(6):1519-1522
- [98] Szczygielski J, Mautes A, Steudel WI, Falkai P, Bayer TA, Wirths O. Traumatic brain injury: Cause or risk of Alzheimer's disease? A review of experimental studies. *Journal of Neural Transmission*. 2005;112(11):1547-1564
- [99] Wang H, Durham L, Dawson H, Song P, Warner DS, Sullivan PM, et al. An apolipoprotein E-based therapeutic improves outcome and reduces Alzheimer's disease pathology following closed head injury: Evidence of pharmacogenomic interaction. *Neuroscience*. 2007;144(4):1324-1333
- [100] Hartman RE, Laurer H, Longhi L, Bales KR, Paul SM, McIntosh TK, et al. Apolipoprotein E4 influences amyloid deposition but not cell loss after traumatic brain injury in a mouse model of Alzheimer's disease. *The Journal of Neuroscience*. 2002;22(23):10083-10087
- [101] Maestre G, Ottman R, Stern Y, Gurland B, Chun M, Tang MX, et al. Apolipoprotein E and Alzheimer's disease: Ethnic variation in genotypic risks. *Annals of Neurology*. 1995;37(2):254-259
- [102] Jordan BD, Relkin NR, Ravdin LD, Jacobs AR, Bennett A, Gandy S. Apolipoprotein E epsilon4 associated with chronic traumatic brain injury in boxing. *Journal of the American Medical Association*. 1997;278(2):136-140
- [103] Nakagawa Y, Reed L, Nakamura M, McIntosh TK, Smith DH, Saatman KE, et al. Brain trauma in aged transgenic mice induces regression of established abeta deposits. *Experimental Neurology*. 2000;163(1):244-252
- [104] Han SD, Suzuki H, Drake AI, Jak AJ, Houston WS, Bondi MW. Clinical, cognitive, and genetic predictors of change in job status following traumatic brain injury in a military population. *The Journal of Head Trauma Rehabilitation*. 2009;24(1):57-64
- [105] Han SD, Drake AI, Cessante LM, Jak AJ, Houston WS, Delis DC, et al. Apolipoprotein E and traumatic brain

- injury in a military population: Evidence of a neuropsychological compensatory mechanism? *Journal of Neurology, Neurosurgery, and Psychiatry*. 2007;**78**(10):1103-1108
- [106] Raby CA, Morganti-Kossmann MC, Kossmann T, Stahel PF, Watson MD, Evans LM, et al. Traumatic brain injury increases beta-amyloid peptide 1-42 in cerebrospinal fluid. *Journal of Neurochemistry*. 1998;**71**(6):2505-2509
- [107] Irving EA, Nicoll J, Graham DI, Dewar D. Increased tau immunoreactivity in oligodendrocytes following human stroke and head injury. *Neuroscience Letters*. 1996;**213**(3):189-192
- [108] Tran HT, Sanchez L, Brody DL. Inhibition of JNK by a peptide inhibitor reduces traumatic brain injury-induced tauopathy in transgenic mice. *Journal of Neuropathology and Experimental Neurology*. 2012;**71**(2):116-129
- [109] Murai H, Pierce JE, Raghupathi R, Smith DH, Saatman KE, Trojanowski JQ, et al. Twofold overexpression of human beta-amyloid precursor proteins in transgenic mice does not affect the neuromotor, cognitive, or neurodegenerative sequelae following experimental brain injury. *The Journal of Comparative Neurology*. 1998;**392**(4):428-438
- [110] Abrahamson EE, Ikonomic MD, Dixon CE, DeKosky ST. Simvastatin therapy prevents brain trauma-induced increases in beta-amyloid peptide levels. *Annals of Neurology*. 2009;**66**(3):407-414
- [111] Mannix RC, Zhang J, Park J, Lee C, Whalen MJ. Detrimental effect of genetic inhibition of B-site APP-cleaving enzyme 1 on functional outcome after controlled cortical impact in young adult mice. *Journal of Neurotrauma*. 2011;**28**(9):1855-1861
- [112] Schwetye KE, Cirrito JR, Esparza TJ, Mac Donald CL, Holtzman DM, Brody DL. Traumatic brain injury reduces soluble extracellular amyloid-beta in mice: A methodologically novel combined microdialysis-controlled cortical impact study. *Neurobiology of Disease*. 2010;**40**(3):555-564
- [113] Sabo T, Lomnitski L, Nyska A, Beni S, Maronpot RR, Shohami E, et al. Susceptibility of transgenic mice expressing human apolipoprotein E to closed head injury: The allele E3 is neuroprotective whereas E4 increases fatalities. *Neuroscience*. 2000;**101**(4):879-884
- [114] Iwata A, Chen XH, McIntosh TK, Browne KD, Smith DH. Long-term accumulation of amyloid-beta in axons following brain trauma without persistent upregulation of amyloid precursor protein genes. *Journal of Neuropathology and Experimental Neurology*. 2002;**61**(12):1056-1068
- [115] Hoshino S, Tamaoka A, Takahashi M, Kobayashi S, Furukawa T, Oaki Y, et al. Emergence of immunoreactivities for phosphorylated tau and amyloid-beta protein in chronic stage of fluid percussion injury in rat brain. *Neuroreport*. 1998;**9**(8):1879-1883
- [116] Gabbita SP, Srivastava MK, Eslami P, Johnson MF, Kobritz NK, Tweedie D, et al. Early intervention with a small molecule inhibitor for tumor necrosis factor-alpha prevents cognitive deficits in a triple transgenic mouse model of Alzheimer's disease. *Journal of Neuroinflammation*. 2012;**9**:99
- [117] Smith DH, Chen XH, Nonaka M, Trojanowski JQ, Lee VM, Saatman KE, et al. Accumulation of amyloid beta and tau and the formation of neurofilament inclusions following diffuse brain injury in the pig. *Journal of Neuropathology and Experimental Neurology*. 1999;**58**(9):982-992