

# We are IntechOpen, the world's leading publisher of Open Access books Built by scientists, for scientists

4,800

Open access books available

122,000

International authors and editors

135M

Downloads

Our authors are among the

154

Countries delivered to

TOP 1%

most cited scientists

12.2%

Contributors from top 500 universities



WEB OF SCIENCE™

Selection of our books indexed in the Book Citation Index  
in Web of Science™ Core Collection (BKCI)

Interested in publishing with us?  
Contact [book.department@intechopen.com](mailto:book.department@intechopen.com)

Numbers displayed above are based on latest data collected.  
For more information visit [www.intechopen.com](http://www.intechopen.com)



---

# Musculoskeletal Injuries: Types and Management Protocols for Emergency Care

---

Ahmad Subhy Alsheikhly and  
Mazin Subhy Alsheikhly

Additional information is available at the end of the chapter

<http://dx.doi.org/10.5772/intechopen.81939>

---

## Abstract

These are a common type of human injuries which can result from the damage of muscular or skeletal systems (i.e., bones, muscles, tendons, ligaments, nerves, blood vessels, etc.); they usually occur due to a strenuous and/or repetitive activity and can result into variety of complaints, complications, and deformities causing a big burden on the financial and health system in all societies. They are among the largest category of work-related injuries and are responsible for almost 30% of all worker's compensation costs worldwide. Injuries to the musculoskeletal system occur in 85% of patients who sustain blunt trauma; they often appear dramatic, but rarely cause an immediate life-threatening situation, although these injuries must be assessed and managed accurately so life or limb are not jeopardized. The doctor must be familiar with the anatomy and the injury site to protect his patients from further disability and prevent complications. Major musculoskeletal trauma such as crushed injuries that can cause release of myoglobin resulting in renal tubular injury (acute kidney injury), or can be associated with internal torso injuries like acute compartment syndrome. soft tissue and skeletal system traumas may not be initially recognized, so continued reassessment and evaluation are necessary to identify all injuries.

**Keywords:** trauma, musculoskeletal, management

---

## 1. Introduction

The musculoskeletal system consists of bones, muscles, tendons, ligaments, and intervertebral discs, as well as their associated nerves and blood vessels [1], and is powered by the complex interrelationship between these separate structures, each of which depends on the other to function properly. Musculoskeletal injuries are common and, hence, are routinely

seen in the emergency department. This requires the attending physician to have a thorough understanding of human anatomy and to be familiar with the subtypes of these injuries in order to prevent life- or limb-threatening damage, anticipate possible complications, and avoid further disability, any of which might not be clear from the immediate presentation of the injury. Patients may come to the emergency department with a variety of complaints and be in pain, but on examination are found to have a strain (tendon) or sprain (ligament). Many musculoskeletal injuries are overuse injuries resulting from strenuous and/or repetitive activity.

Barring major complications and the potential for long-term deformities, most musculoskeletal injuries are relatively minor and rarely require an immediate life-threatening intervention. However, in patients who sustain blunt trauma, 85% incur musculoskeletal injuries that can be more serious. These patients need to be assessed and managed quickly and correctly. In cases of major musculoskeletal trauma when there are extraordinary forces that cause crushing injuries, the emergency physician may be confronted with more pressing challenges. When major muscle damage occurs, large amounts of myoglobin (a heme protein) are released into the bloodstream. When the myoglobin reaches the kidneys, it breaks down into harmful substances that can damage kidney cells, leading to precipitation in the renal tubules and acute kidney injury (AKI). Major musculoskeletal trauma can also result in internal torso injuries; in some cases, the pooling of fluids can form into an intact musculofascial layer with swelling in the space. This can cause complications such as acute compartment syndrome, which can lead to dire consequences if misdiagnosed. Continuous and careful assessment and correct recognition and management of musculoskeletal injuries in the emergency department are the key to successfully preventing further morbidity and reducing mortality.

## 2. Anatomy of the musculoskeletal system

The human musculoskeletal system (also known as the locomotor system) is a multiple organ system that gives human the ability to move using their muscles, tendons, and bones; it provides form, support, stability, and flexibility to the body as well as protecting vital organs [2]. Also, the skeletal portion of the system serves as the main storage system for calcium and phosphorus and contains critical components of the hematopoietic system [3].

Within the system, bones are connected to muscle fibers via connective tissue like tendons and ligaments. Muscles keep bones in place and also play a role in the movement of bones allowing overall motion; different bones are connected to by joints and cartilage prevents the bone ends from rubbing directly into each other.

There are, however, specific diseases and disorders, which will not be discussed in this chapter, that may adversely affect the function and overall effectiveness of the system. Some of which can be difficult to diagnose and treat in the emergency setting and may require a specialist to handle like an orthopedic surgeon; other issues may require physical rehabilitation which is handled by a physiotherapist.

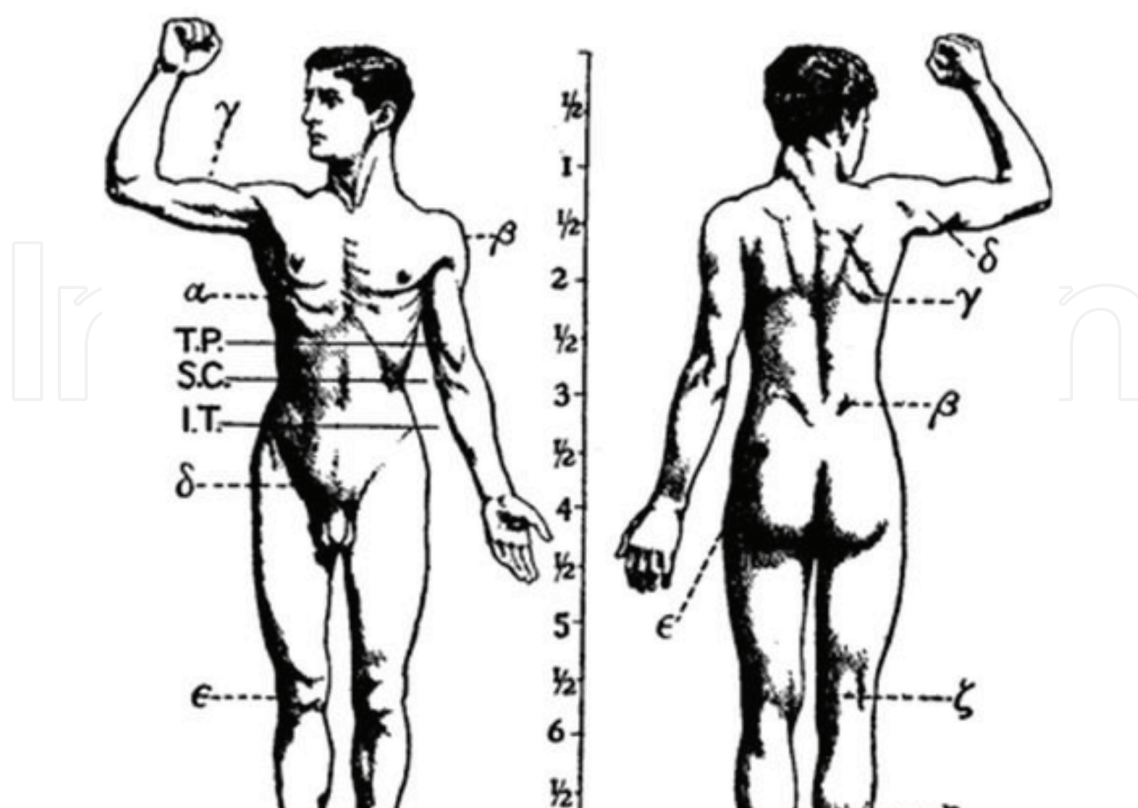


Figure 1. Features of the human activity system from the 1911.

It is of worth to note that previously, the musculoskeletal system used to be called the activity system (Figure 1).

## 2.1. The skeleton

This system serves many important functions; it aids in the shape and morphology of the whole body; it provides support and protection as well as allowing movement. It plays a major role in producing blood for the body and in storage of minerals [4]. The number of bones in the human skeleton is estimated to be around 270 at birth; however, many bones fuse together between birth and maturity. As a result, an average adult skeleton consists of 206 bones. The number of bones varies according to the method used to derive the count. While some consider certain structures to be a single bone with multiple parts, others may see it as a single part with multiple bones [5]. There are five general types of bones: long bones, short bones, flat bones, irregular bones, and sesamoid bones. The human skeleton is composed of both fused and individual bones. It is a complex structure with two distinct divisions; the axial skeleton, which includes the vertebral column, and the appendicular skeleton [2].

The skeletal system serves as a framework for tissues and organs to attach themselves to. This system acts as a protective structure for all vital organs. Major examples of this are the brain being protected by the skull and the heart with the lungs being protected by the rib cage.

Within the long bones are two distinctions of bone marrow (yellow and red). The yellow marrow has fatty connective tissue and is found in the marrow cavity. During starvation, the body uses the fat in yellow marrow for energy [2]. The red marrow of some bones is an important site for blood cell production; here, all erythrocytes, platelets, and most leukocytes form in adults. From the red marrow, erythrocytes, platelets, and leukocytes migrate to the peripheral blood to do their special tasks approximately 2.6 million red blood cells per second in order to replace existing cells that have been destroyed by the spleen [2].

Another function of bones is the storage of certain minerals. Calcium and phosphorus are among the main minerals being stored. The value of this storage “device” helps to regulate mineral balance in the bloodstream. When the fluctuation of minerals is high, these minerals are stored in bone; when it is low, it will be withdrawn from the bone.

## 2.2. Muscles

There are three types of muscles (smooth, skeletal, and cardiac). Smooth muscles are nonstriated muscles used to control the flow of substances within the lumens of hollow organs like vessels and bowels and are involuntarily controlled [3]. Skeletal and cardiac muscles have striations that are visible under a microscope due to the components within their cells. Only skeletal and smooth muscles are part of the musculoskeletal system and only the skeletal muscles can move the body skeleton. Skeletal muscles are attached to bones and arranged in opposing groups around joints. Cardiac muscles are found in the heart only and used to pump blood; they are like the smooth muscles, involuntarily controlled. Muscles are innervated by nerves which conduct electrical currents from the central nervous system and cause the muscles to contract.

The body contains three types of muscle tissue seen under microscope as shown in (**Figure 2**): (a) skeletal muscle, (b) smooth muscle, and (c) cardiac muscle.

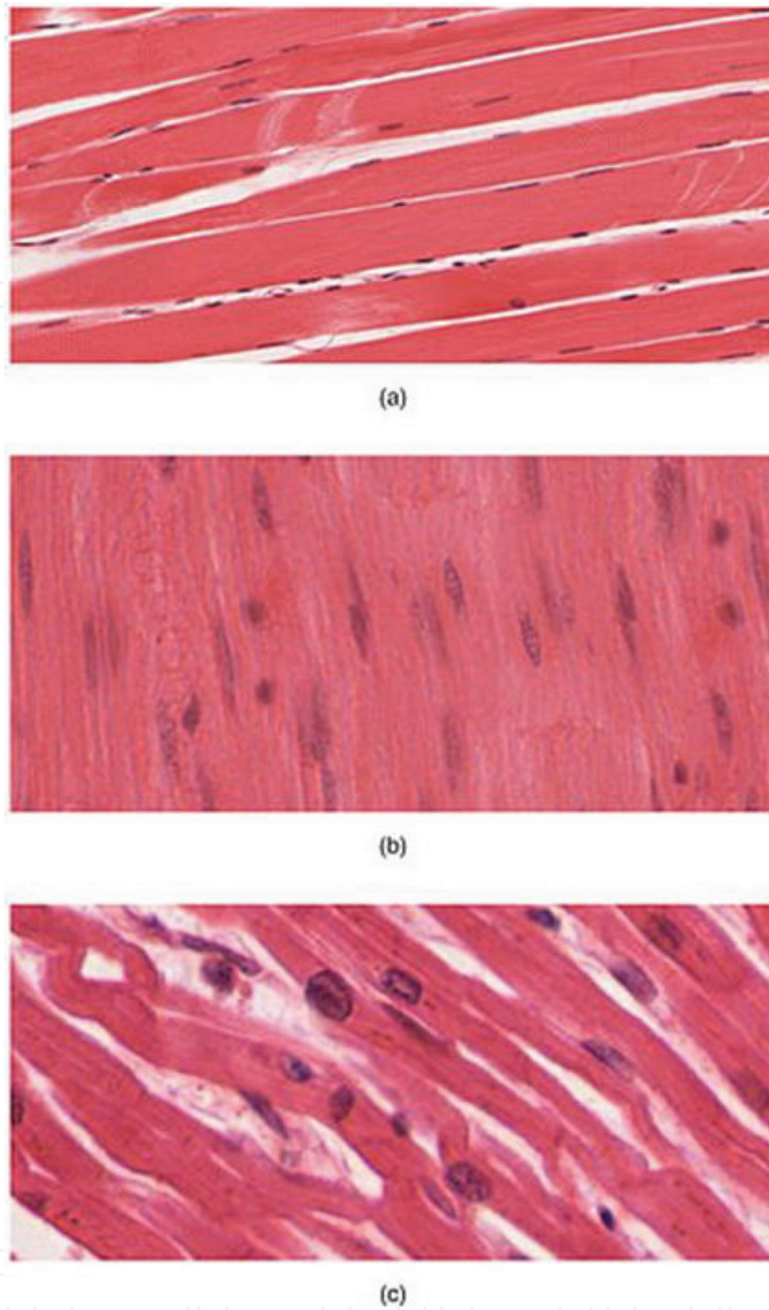
## 2.3. Joints

Joints, also called articulations, serve two important functions in the human body: holding the skeleton together and allowing it to be mobile. Simply defined as the site where two or more bones meet [2].

There are three types of joints according to its functional classification which measures the amount of movement the joint provides: diarthrosis joints which allow extensive mobility between two or more articular heads; synarthrosis or false joints which are joints that do not provide mobility and amphiarthrosis joints which allow little or very minimal movement.

Structural classification is based on the type of the material binding the bones together. Synovial joints (**Figure 3**) are the joints where the bones are lubricated by a solution called synovial fluid that is produced by the synovial membranes. This fluid lowers the friction between the articular surfaces and is kept within an articular capsule allowing maximum mobility.



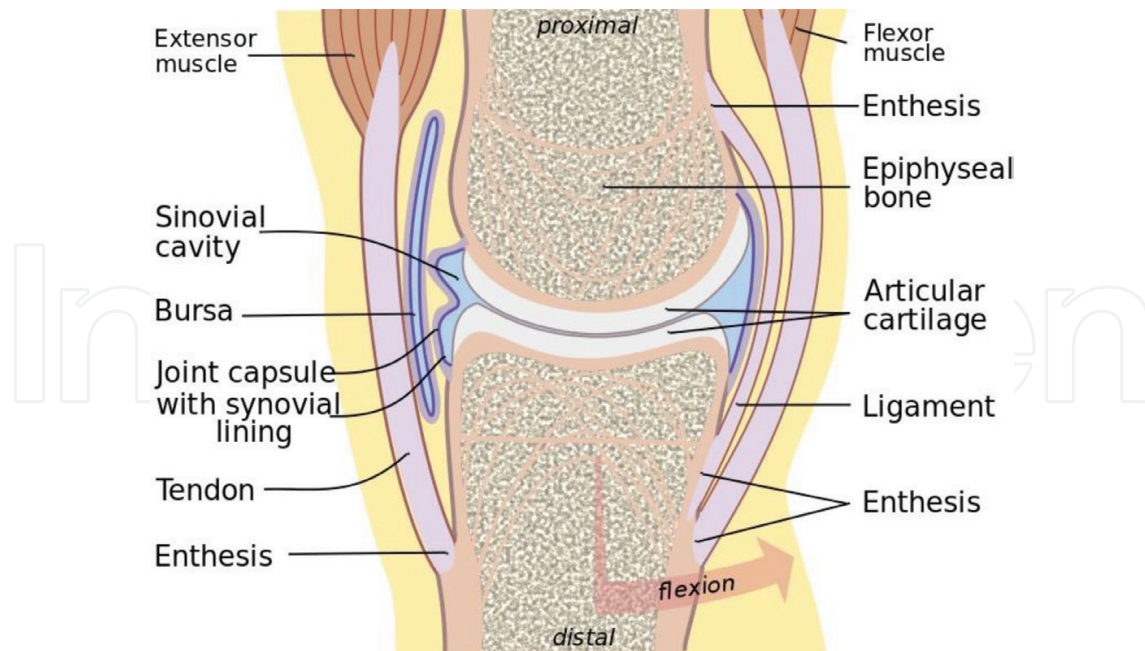


**Figure 2.** Muscle tissue under microscope.

Cartilaginous joints are the joints where bone ends are tied by cartilage, and fibrous joints are the joints where the bone ends are united by fibrous tissue; the latter two types vary in mobility according to their subclassifications and position in the body [2].

#### **2.4. Tendons**

A tendon is a tough, flexible band of fibrous connective tissue that connects muscles to bones [4]. The extracellular connective tissue between muscle fibers binds to tendons at the distal



**Figure 3.** Anatomy of synovial joint.

and proximal ends, and the tendon binds to the periosteum of individual bones at the muscle's origin and insertion. As muscles contract, tendons transmit the forces to the relatively rigid bones, pulling on them and causing movement. Tendons can stretch substantially, allowing them to function as springs during locomotion, thereby saving energy.

## 2.5. Ligaments

A ligament is a small band of dense, white, fibrous elastic connective tissue [2] that connects both ends of bones together in order to form a joint and they transfer force from one bone to the other allowing movement [6]. Most ligaments limit dislocation or prevent certain movements that can cause injury or tears. Since they are elastic tissue, they increasingly lengthen when under pressure; when the force exceeds the limit of elasticity, the ligament can handle; it becomes susceptible to damage which can result in severe injuries and tears or in an unstable joint movement. Ligaments may also restrict some actions and movements such as hyperextension or hyperflexion that is limited by the ligament ability to prevent this movement to an extent [7].

## 2.6. Bursa

A bursa is a small synovial fluid-filled sac contained within white fibrous connective tissue which is lined internally with synovial membrane. It provides a cushion between bones and tendons and/or muscles around a joint. The fluid-filled sac can be found in multiple regions in the body mostly around joints [2].

### 3. Addressing musculoskeletal injuries

It is valuable to have as much insight as possible about the incident, even the site of the incident, as any information may aid in weighing the level of trauma, things like the patient position, causative mechanism of injury (penetrating, blunt, crushing...), bleeding at the scene, exposed bone or fracture ends, open wounds, any deformity or dislocation, motor and/or sensory deficits, delays in transportation, limb function, perfusion, and neurological changes. Other things to keep in mind are to pay special attention to excessive pressure over prominences as they may result in a peripheral nerve compression, compartment syndromes, or crush syndromes.

A thorough history is the first step; always ask about the mechanism of the trauma, it is very essential in the management of musculoskeletal injuries and then past medical history to assess any morbidities, history of medications, any previous injuries, and the last meal the patient had and the timing of it.

Second in line is physical examination. The physical examination in the emergency department for these injuries is based on simple four steps:

1. Inspection (discoloration, swelling, or deformity).
2. Palpation (looking for tenderness and deformity).
3. Assess range of motion (both active and passive) with consideration to the joint above and below the injured part.
4. Neurovascular examination.

This should cover the basic general approach of these injuries.

### 4. Classification and management of musculoskeletal injuries

#### 4.1. Soft tissue injuries<sup>1</sup>

The soft tissue is a term that encompasses all body tissue except the bones. It includes skin, muscles, vessels, ligaments, tendons, and nerves. Their injuries can range from the trivial, such as a scraped knee, to the critical that includes internal bleeding; those which involve the skin and underlying musculature are commonly divided either as closed or open wounds.

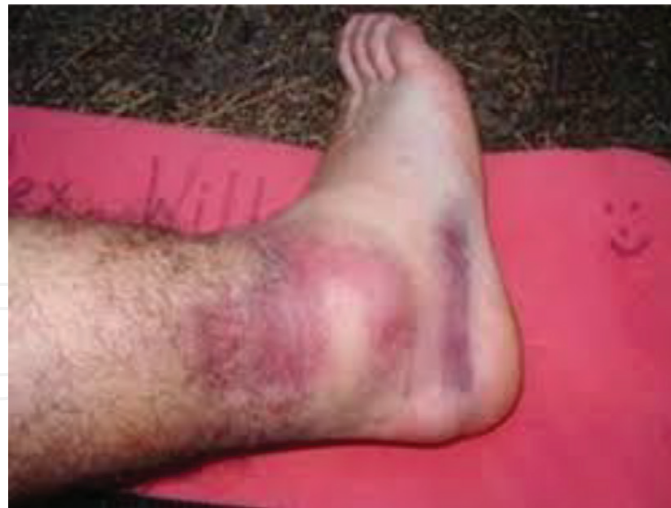##### 4.1.1. Closed wounds

An injury where there is no open pathway from the outside to the injured site (**Figure 4**) and can be divided into:

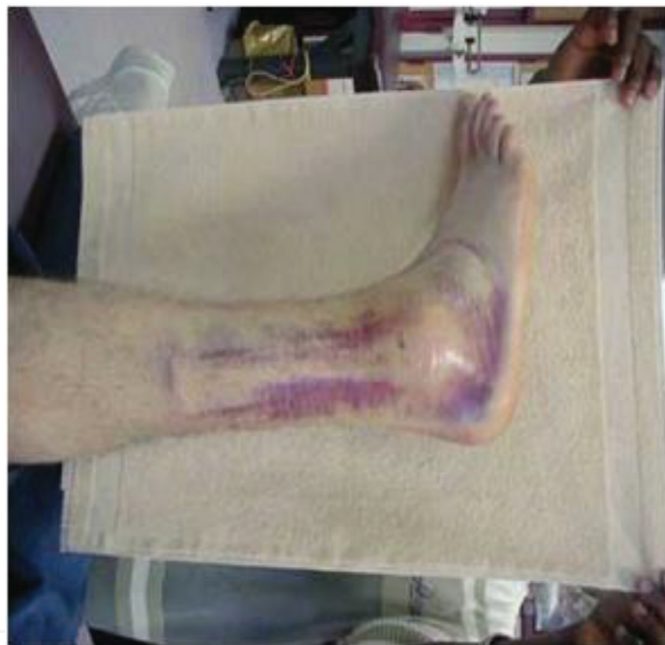---

<sup>1</sup> This will include soft tissue and connective tissue injuries for the sake of simplification.





**Figure 4.** Closed wound.



**Figure 5.** Ankle ligament sprain.

1. Contusion: a traumatic injury to the tissues beneath the skin without a break in the skin.
2. Ecchymosis: discoloration under the skin that is caused when blood leaks out into the surrounding soft tissues causing the skin to turn different colors.
3. Edema: swelling as a result of inflammation or abnormal fluid under the skin.
4. Strain: stretching or tearing of a muscle resulting from overstretching or overexertion. Also known as a pulled muscle or torn muscle [8].
5. Sprain: a joint injury involving damage to supporting ligaments and partial or temporary dislocation of bone ends, partial tearing or stretching of supporting ligaments (**Figure 5**). Also known as a torn ligament [8].

#### 4.1.1.1. Managements of closed injuries

Closed injuries can be managed effectively by applying the **R.I.C.E.R.** regime [4]. This involves the application of (**R**) rest, (**I**) ice, (**C**) compression, (**E**) elevation, and obtaining a (**R**) referral for appropriate medical treatment.

##### 4.1.1.1.1. Strains and sprains

A patient with strain and/or sprain usually has pain and edema, a point of tenderness or burning sensation with or without ecchymosis. There may be a mild deformity of the injured joint in addition to complete or near complete loss of movement of joint; treatment consists of pain control, supportive strapping or bandaging, and immobilization by splinting so that affected muscle is in relaxed position. If injury is severe, R.I.C.E.R must be followed [9, 10].

Also, make sure to cover the following:

1. Reassure the patient.
2. Gently support the site.
3. Check circulation, motor, and sensation before and after splinting.
4. Apply ice pack.
5. Splint and immobilize injured limb.
6. Elevate injured limb.
7. Arrange for transport to appropriate care center.

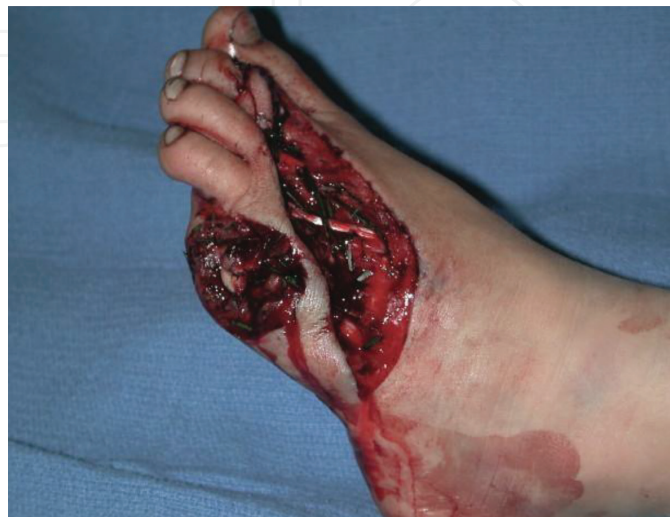

Figure 6. Open wound.

#### 4.1.2. Open wounds

An injury in which the skin is interrupted or broken, exposing the tissues underneath (**Figure 6**) and can be divided into:

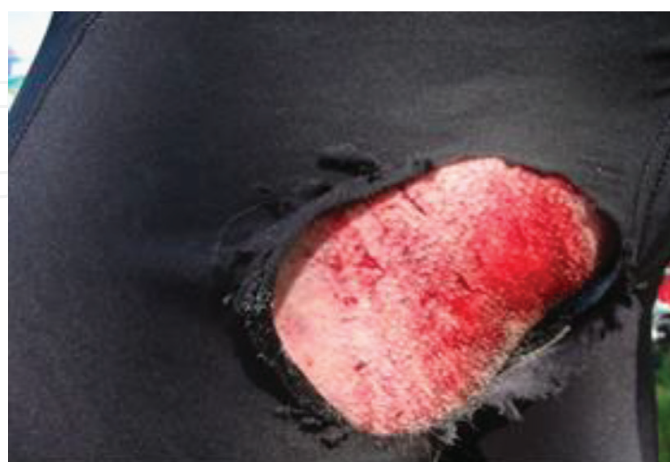1. Abrasions: where the top layer of the skin is removed.
2. Lacerations: these are cuts of the skin with jagged edges.
3. Incisions: which are characterized by smooth edges and resemble a paper cut.
4. Punctures: usually deep, narrow wounds such as a stab wound from a nail or knife.
5. Avulsions: where a flap of skin is forcefully torn from its attachment.
6. Amputations: partial or full detachment of a limb or other appendage of the body which may be iatrogenic or due to trauma.

##### 4.1.2.1. Management of open injuries

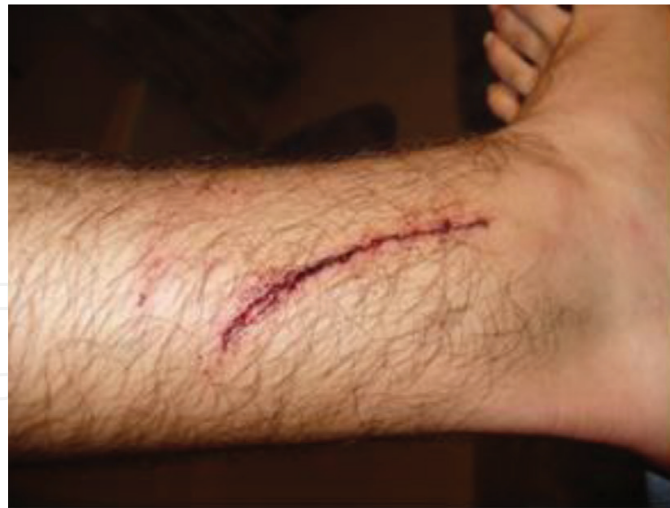###### 4.1.2.1.1. Abrasions

Also called “brush burns,” “mat burns,” and “road rash” in which some bleeding may result, but usually oozes from injured capillaries. Extremely painful because nerve endings are involved (**Figure 7**).

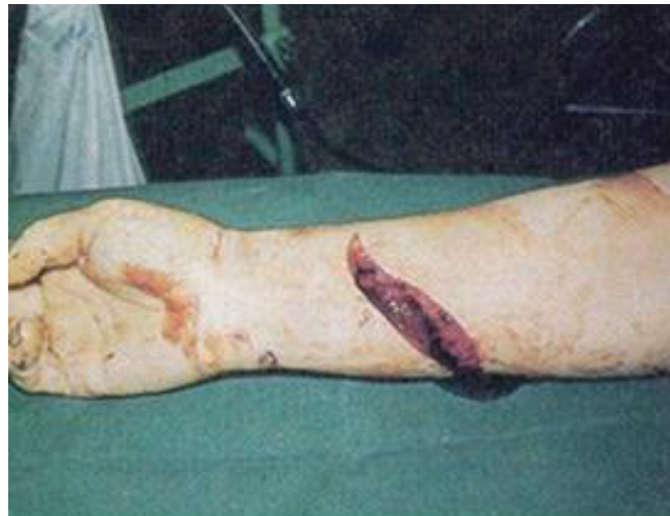The management is usually so minimal requiring cleansing of the wound; small bandages may be applied but tactical situations will usually preclude applying field dressings that are needed for more serious injuries. A large amount of dirt may be ground into the wound; therefore, secondary treatment measures should focus on preventing or stopping infections.



**Figure 7.** Abrasion post road accident.



**Figure 8.** Simple laceration.

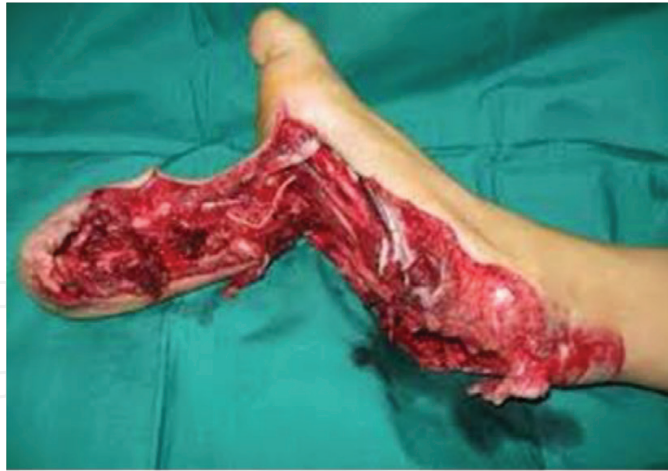

**Figure 9.** More severe laceration of the forearm.

#### 4.1.2.1.2. *Lacerations and incisions*

May be smooth or jagged and can be caused by an object with a sharp edge (**Figures 8 and 9**) or may result from a severe blow or impact with a blunt object. Treatment is generally the same as for abrasions. It is very important to remember protecting yourself from disease by using medical gloves, wash or irrigate the injury with warm saline, remove all foreign bodies, control bleeding by applying local compression and dressing, start intravenous fluids when necessary (e.g., in cases of severe bleeding and possible hemodynamic compromise). Insure to keep the patient warm, elevate the injured part of the body. If major tendons and muscles are completely cut, immobilize the limb to prevent further damage.

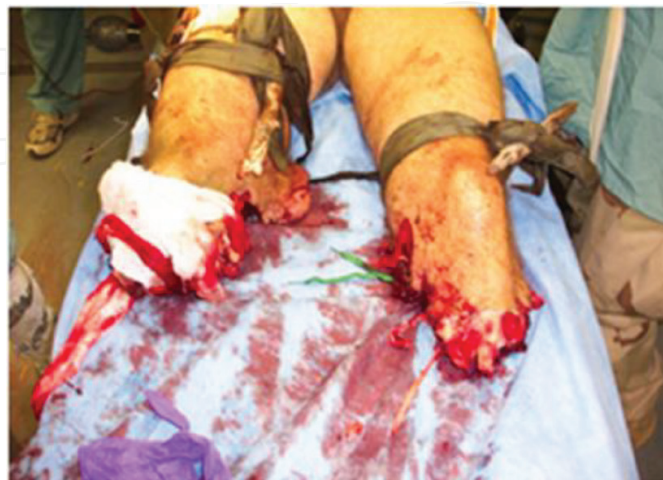



**Figure 10.** Avulsion.

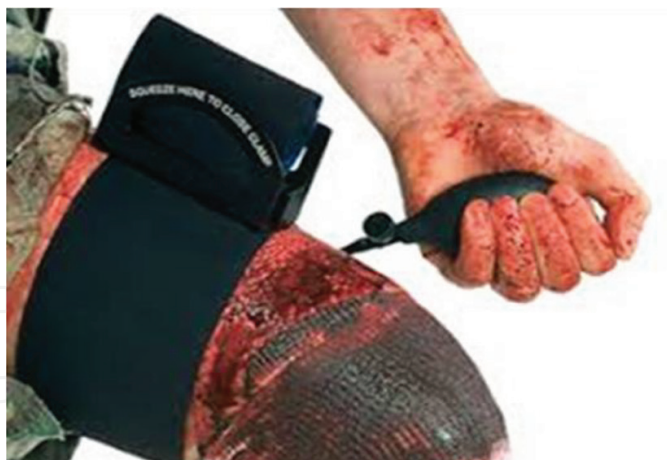#### 4.1.2.1.3. Avulsions

These should be assessed carefully to rule out vascular and/or neurological injury (**Figure 10**). Bleeding should be controlled by direct pressure on the bleeding site; the avulsed part should be managed by applying several pressure dressings or an air splint and followed by regular dressing. Contamination should be avoided; ensure avulsed flap is lying flat and that it is aligned in its normal position. If the avulsed part is completely pulled off, make every effort to preserve it. Wrap that part in a saline or water-soaked field dressing, pack wrapped part in ice, and whenever possible be careful to avoid direct contact between the tissue and ice. Transport the avulsed part with the patient but keep it well-protected from further damage and out of view of the patient [4].



**Figure 11.** Severe bilateral amputation of the lower limbs.





**Figure 12.** Pneumatic tourniquet in place.

#### *4.1.2.1.4. Amputations*

Amputation is a very traumatic event for the patient both physically and psychologically (**Figure 11**). With complete amputations, there is less bleeding than with partial or degloving cases. This is due to elastic nature of blood vessels as they are tended to spaz and retract into the surrounding tissue. It is very important to notice that replantation is performed only with an injury of isolated finger or extremity and should be performed by a skilled surgical team.

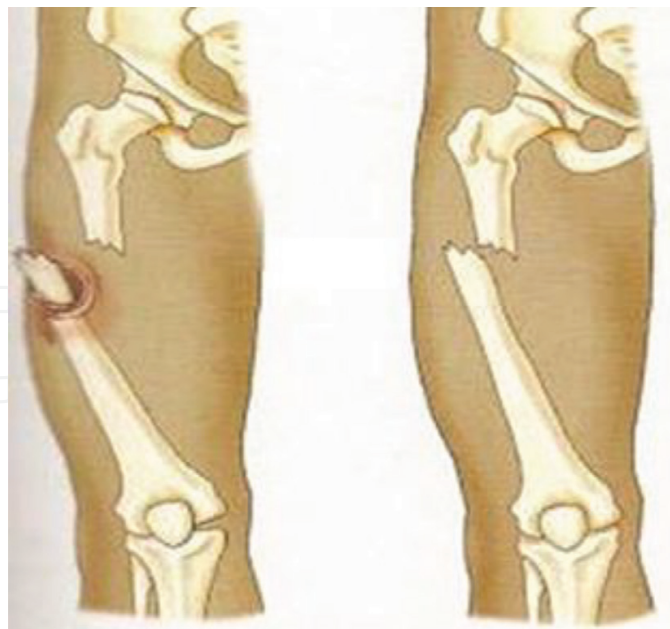Treatment should always be started by ABCDE, which is the management of airway, breathing, circulation, disabilities, and environment in addition to warmth of the patient and control of hemorrhage by direct pressure or application of a tourniquet (**Figure 12**). If a tourniquet is applied, it must occlude arterial inflow, as occluding only venous system can increase bleeding. In severe cases where the patient's life might be at compromise, a tourniquet may remain in place for a prolonged period in order to save the patient's life. The physician must be able to make such decision and be aware that this choice is for life and against limb.

It is helpful to mark the patient's forehead with a "T" (indicating the time it was applied) using a marker to be able to track time of which the tourniquet was applied. Place the patient in shock position (head down, feet elevated). Continue the management by treatment of shock via IV fluids and/or blood transfusion, vasopressors if necessary, pain control, and continuous monitoring of the patient's vitals. Make every effort to preserve the amputated part and transfer the patient to the theater as soon as possible after stabilization of the ABCDE. Wrap the amputated part in a sterile dressing, place in ice and send with patient, and prevent direct contact between tissue and ice as possible [7].

## **4.2. Fracture and dislocation injuries**

### *4.2.1. Fractures*

A break in the continuity of bone which may result in partial or complete disruption of the bone. Fractures are further classified as open or closed.



**Figure 13.** Open versus closed fracture.



**Figure 14.** Inside-out open fracture.

**Open fractures:** in which there is a break through the overlying skin and connective tissue with exposure of the broken bone (**Figure 13**).

It can be **inside-out** (**Figure 14**) where the broken end of the bone breaks through or pierces the skin, or **outside-in** where the external force causes laceration and breaks the layers till the bone. The latter has a higher likelihood of contamination.

**Closed fracture:** the bone is broken with no skin penetration or connection with the exterior surface (**Figure 13**).

Alternative classification to fractures can be applied in relation to the size of the wound and causative force:

Type I: Small wound (<1 cm), usually clean; low energy.

Type II: Moderate wound (>1 cm), minimal soft tissue damage or loss; low energy.

Type III: Severe skin wound, with extensive soft tissue damage; high velocity impact.

#### 4.2.1.1. Management of fractures

The following guidelines can be applied to any type of fracture, regardless of location:

- Treat as any case of trauma by starting management of airway, breathing, circulation, disabilities, and patients' environment (ABCDE).
- Control hemorrhage.
- Treatment for shock.
- Relieve pain (can include opioids).
- Treat any associated injuries and cover the injured area with sterile dressing.
- Check distal pulses before and after splinting.
- Immobilize the fracture using splints.
- Check pulse, motor, and sensation (PMS).
- Initiate IV antibiotics (usually broad-spectrum type to cover both Gram-positive and Gram-negative bacteria), in addition to tetanus prophylaxis.
- DO NOT re-place protruding bone or explore the wound nor clamp any vessel at the emergency setting and wait for the orthopedic physician.

In general, during clinical examination for suspected fractures, look for the following signs:

- Discoloration.
- Deformity.
- Edema.
- Crepitus.
- Point tenderness.
- Limited range of motion.
- Direct or indirect pain.
- Exposed bone fragments (open fractures).

- Any open wounds over or near a joint should be assumed to extend to the joint till proven otherwise.

**Serious complications** of open fractures are:

1. Soft tissue infection.
2. Osteomyelitis.
3. Gas gangrene.
4. Tetanus.
5. Crush syndrome.
6. Skin loss.
7. Malunion or Nonunion.

#### *4.2.1.1.1. Splints and splinting*

An appliance made of wood, metal, or plaster used for the fixation and protection of an injured part of the body aiming to:

- immobilize the injured body part.
- prevent further damage to muscles, nerves, or blood vessels caused by broken ends of bones.
- prevent a closed fracture from converting into an open fracture.
- decrease and control pain.

#### *4.2.1.1.1.1. General rules for splinting*

- Control hemorrhage. Direct pressure and/or pressure dressings will control virtually all external hemorrhage.
- Expose fracture site. Remove jewelry and watches.
- Before splinting, check for distal pulses.
- Splint in the position found unless limb is pulse-less.
- An attempt should be made to straighten a severely deformed limb with gentle traction only if there are no distal pulses, if resistance is felt, stop and splint as it lies.
- Move the fractured part as little as possible while applying the splint.

- DO NOT retract the exposed bone of an open fracture back into the body.
- Pad splint at bony prominence points (elbow, wrist, and ankle).
- Splint the joints above and below the fracture site.
- Reassess circulation and neurological status after splinting.

**Common complications** that can be seen with splinting include abrasions, sores, neurovascular compromise due to tight fitting splints, contact dermatitis, pressure ulcers, and thermal burns. Splints should be applied by skilled and trained professional, applied splint correctly followed by neurovascular status checkup.

#### 4.2.1.1.1.2. Common types of splints

1. Volar short splint which is used for wrist fractures, fractures of the second to fifth metacarpal bones, carpal tunnel syndrome, and soft tissue injuries (**Figure 15**).
2. Finger splints which are used for phalangeal fractures (**Figure 16**).

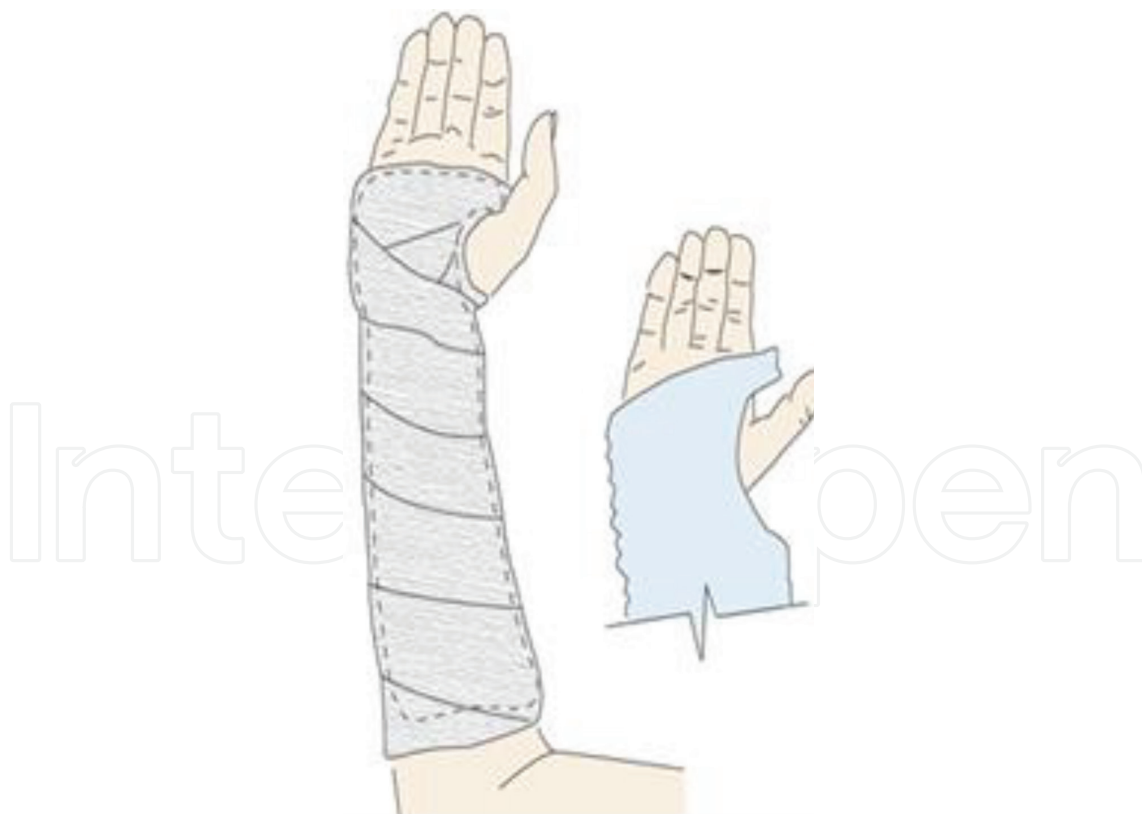

Figure 15.



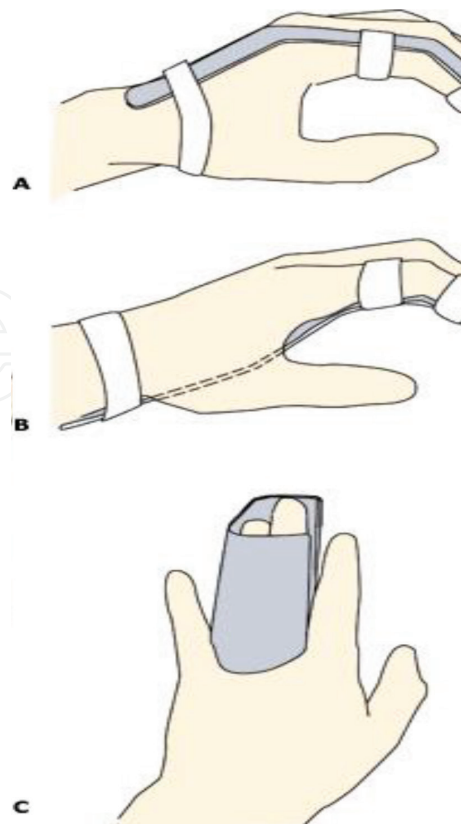


Figure 16.

3. Gutter splint which can be used for phalangeal fractures and metacarpal fractures; these are two types: radial and ulnar (**Figure 17**).
4. Buddy taping of toes used to secure the fractured toe to the adjacent one with adhesive strips; it is necessary to apply a small pad or sheet between toes to prevent maceration (**Figure 18**).
5. Thumb spica splint used for scaphoid fractures, extraarticular fractures of the thumb and ulnar collateral ligament injuries (**Figure 19**).
6. Stirrup splint is a below knee splint wrapping around the ankle to immobilize ankle fractures (**Figure 20**).
7. Posterior leg splint is used for distal leg fractures, ankle fractures, tarsal fractures, and metatarsal fractures (**Figure 21**).

#### 4.2.2. Dislocations

A displacement of bone ends at the joints (**Figures 22–24**) resulting in an abnormal stretching of the ligaments around the joints. Also called luxation, occurs when there is an abnormal separation in the joint where two or more bones meet [9, 10]. Sometimes causes tearing or complete ligament separation; a partial dislocation is referred to as subluxation. They are easily recognized and diagnosed; the impact area may be swollen or look bruised with associated redness

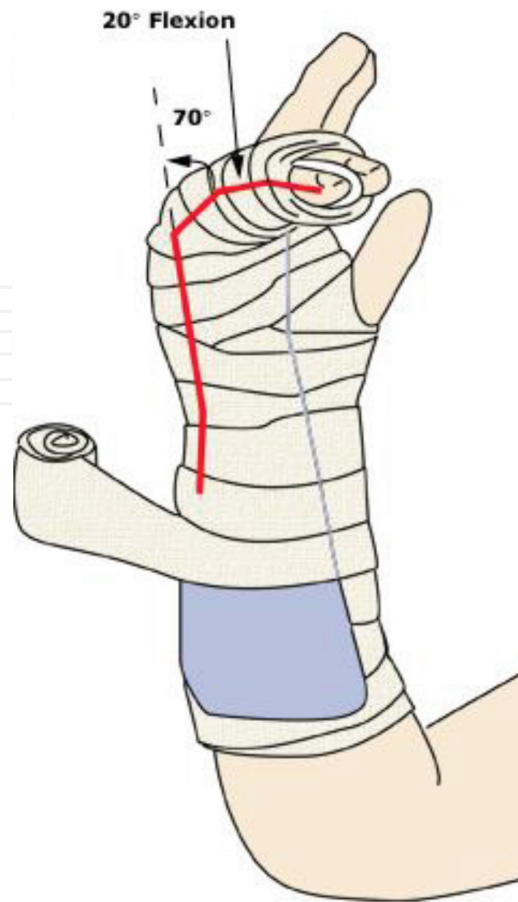


Figure 17.

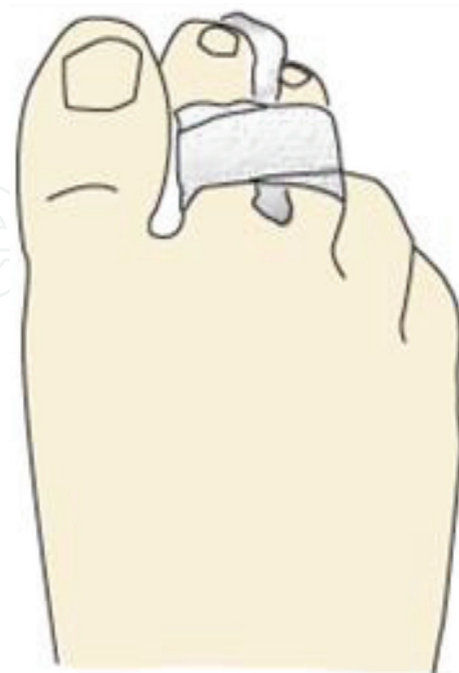

Figure 18.

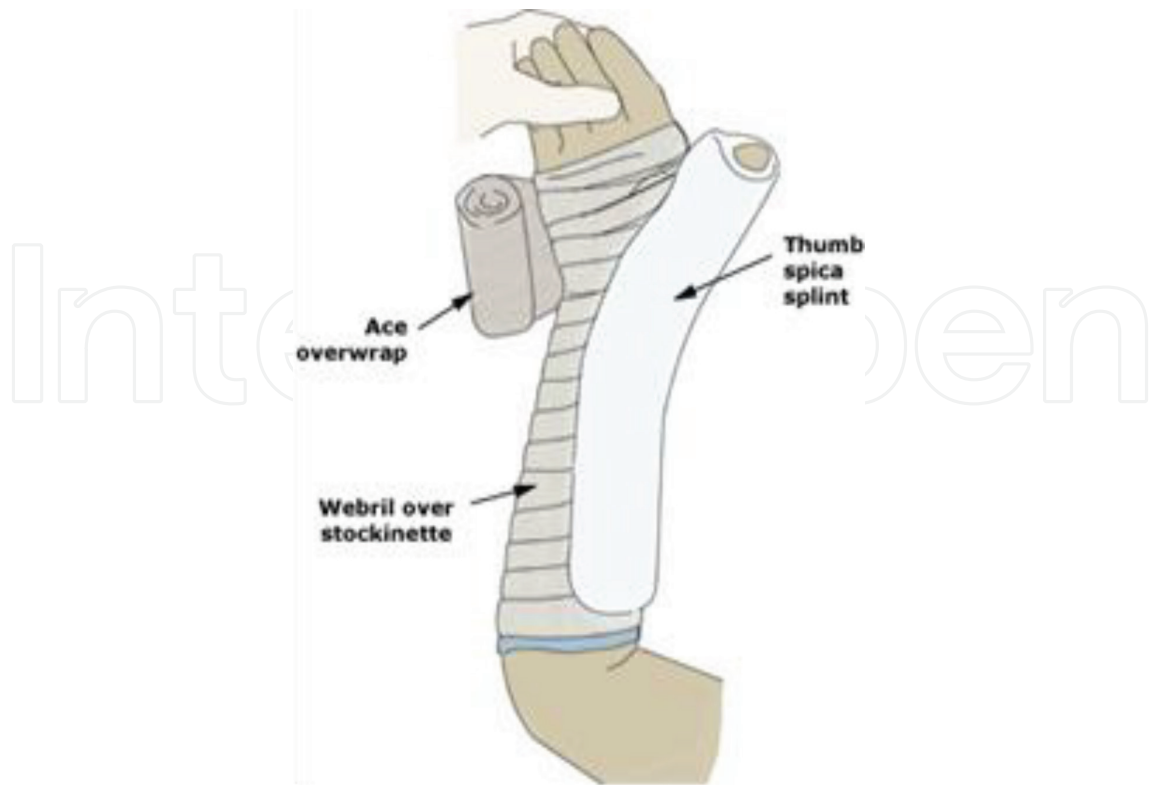


Figure 19.

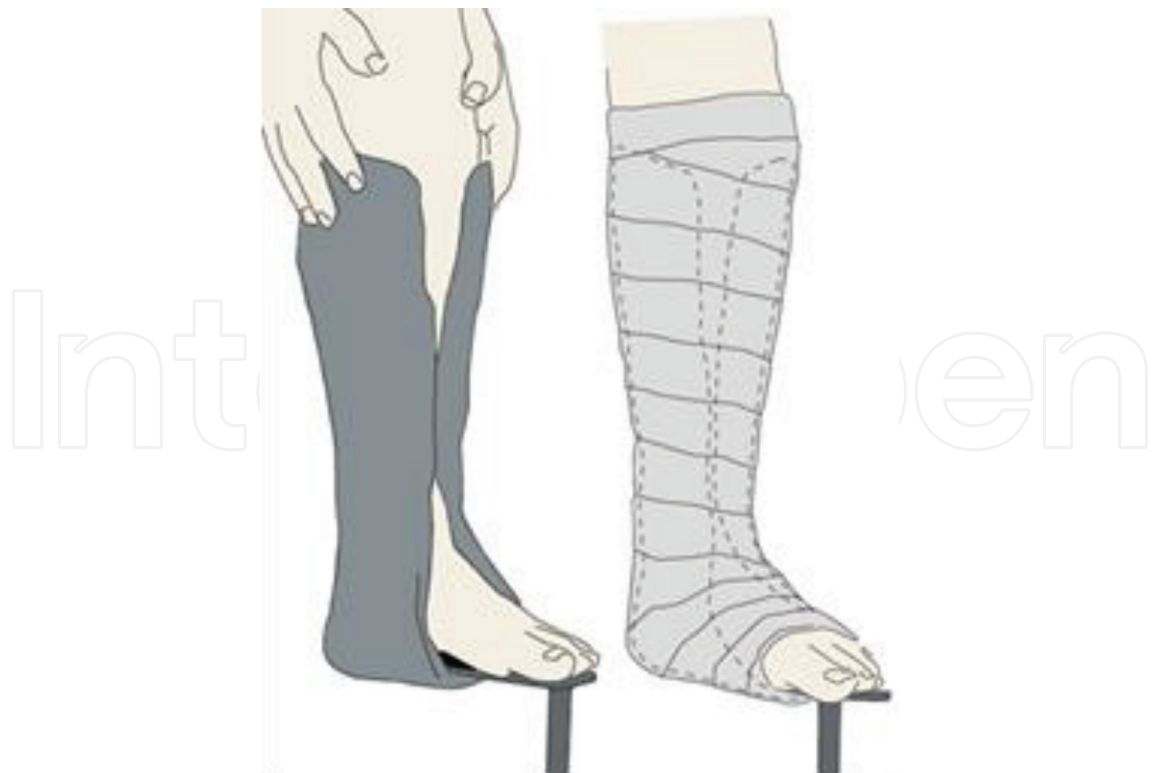

Figure 20.

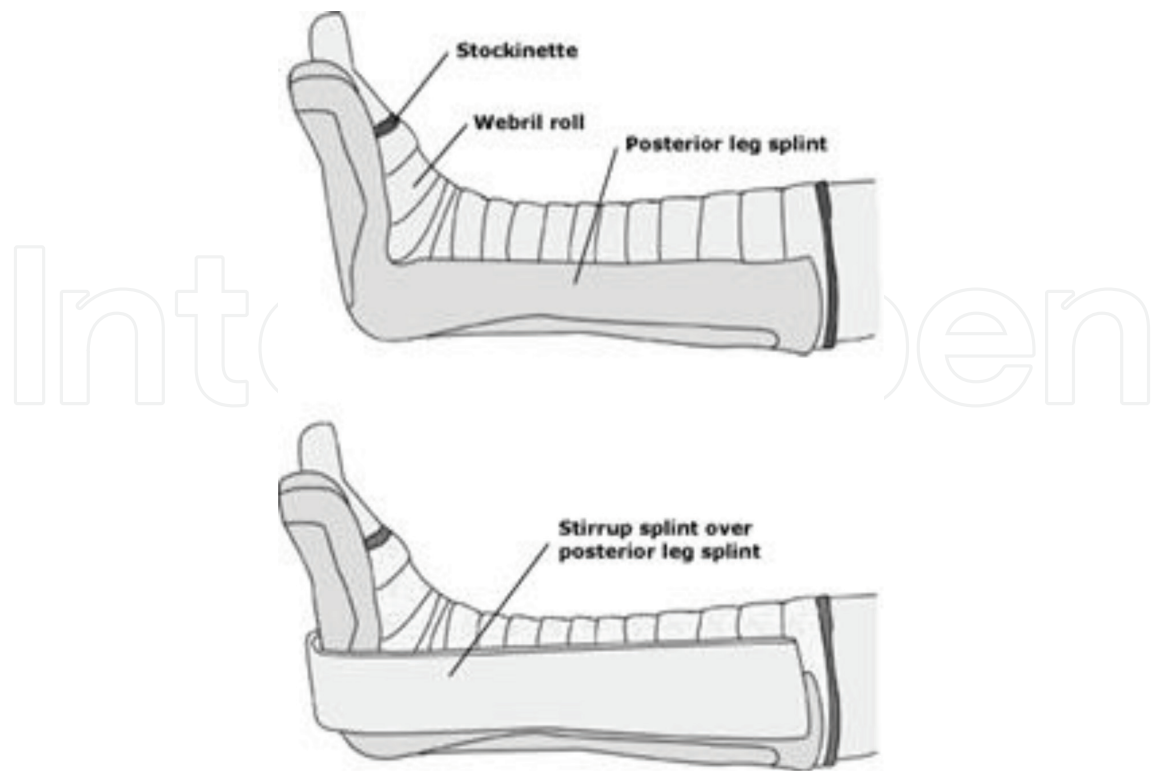


Figure 21.

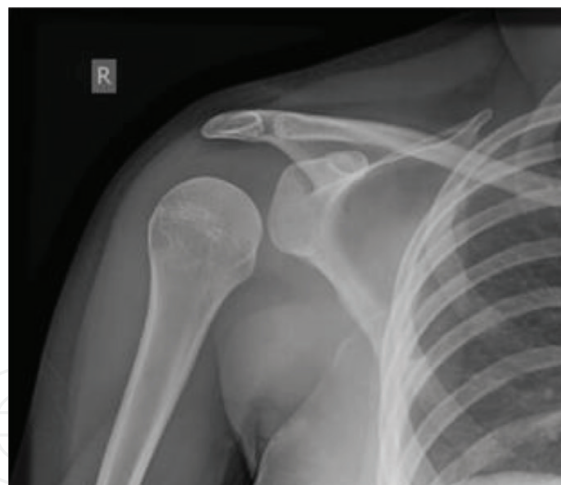

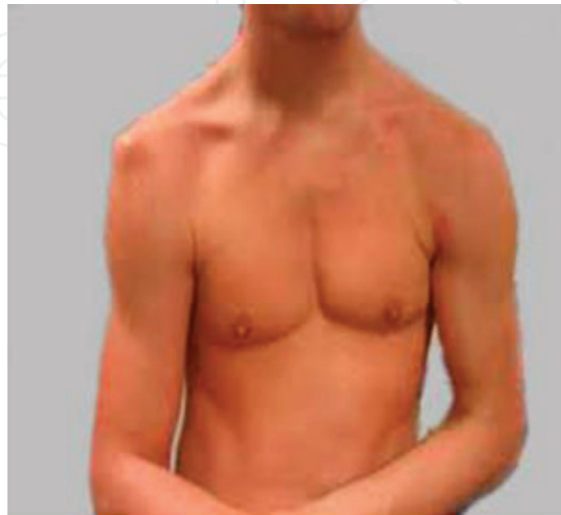Figure 22. Posterior shoulder dislocation on X-ray.

or discoloration. It may also have a strange shape or be deformed as a result of the unexpected or unbalanced trauma. Some of the other symptoms associated with dislocated joints include:

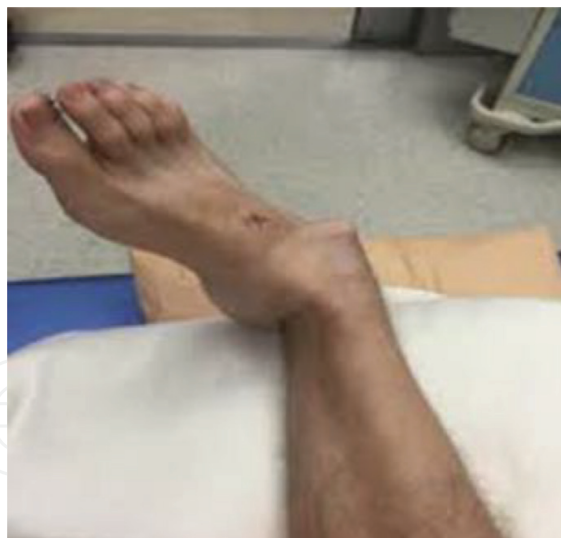1. Limited or lost motion.
2. Pain during movement.
3. Numbness around the area.

#### 4. Paresthesia and tingling feeling in the limb.

X-ray is usually the preferred method of imaging in the emergency department, on occasion, special imaging such as an MRI may be required for diagnosis to roll out associated fractures or tear in muscles and ligaments.



**Figure 23.** Shoulder dislocation.

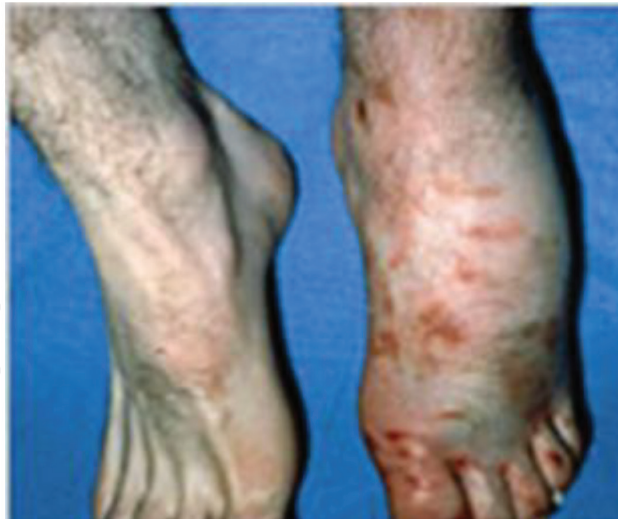

**Figure 24.** Ankle dislocation.

##### 4.2.2.1. Management of dislocation

Treatment of dislocations and/or subluxations will depend on the site of joint; it may also depend on the severity of injury. According to Johns Hopkins University, initial treatment for any dislocation involves R.I.C.E: rest, ice, compression, and elevation. In some cases, the dislocated/subluxated joint might go back into place naturally after this treatment [11–13].

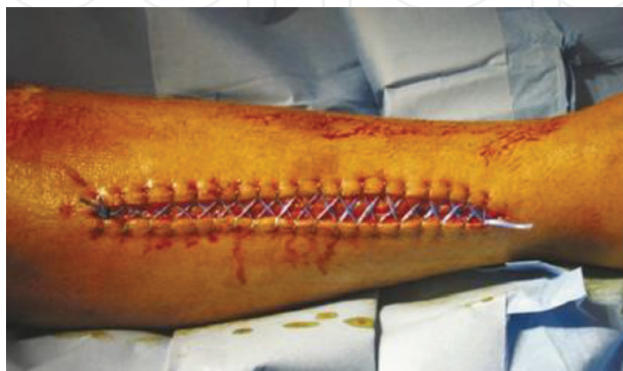



**Figure 25.** Acute compartment syndrome of the left foot.

If the joint does not return to normal naturally, treatment options should be one or more of the following:

1. Manipulation or repositioning (sedatives or anesthetics are necessary to keep the patient comfortable and also to allow muscles near to the injured joint to relax, which eases the procedure).
2. Immobilization (a sling, splint, or cast for several weeks to prevent recurrence).
3. Medication (a pain reliever or a muscle relaxant).
4. Rehabilitation (to increase the joint's strength and restore its range of motion).
5. Surgery is usually indicated only if there are damaged nerves or blood vessels, or if the doctor is unable to return bones to their anatomical position. Surgery may also be necessary for those who often dislocate the same joints, such as recurrent shoulder dislocations.



**Figure 26.** Fasciotomy.

## 5. Complications of musculoskeletal injury

### 5.1. Acute compartment syndrome (ACS)

A prolonged elevation of interstitial tissue pressure within an enclosed fascial compartment leading to impaired tissue perfusion and damage. Associated with increased vessel permeability and plasma leak into the intercellular space causing further pressure on muscles and nerves (**Figure 25**); it might result in death if not treated before 8–12 h [14–18].

This serious and critical musculoskeletal complication can be caused by direct blow or contusion, crush injury, burns, snake bites, fractures, hematoma, and prolonged pressure from splinting.

It is characterized by severe pain especially with stretching, tense compartment, tight and shiny skin. Late findings can be paresthesia, loss of pulses, and pain out of proportion.

#### 5.1.1. Management of ACS

Treatment of ACS is urgent surgical exploration with fasciotomy (**Figure 26**).

It should be noted that any case with prolonged ACS of more than 8–12 h can have permanent deformity and limb viability may possibly be lost.

During management, every effort should be used to release all compartments; the main focus is on reducing the dangerous pressure in the body compartment. Dressings, casts, or splints that are constricting the affected body part must be removed. Early recognition and diagnosis, pain control, keeping the body part with ACS below the level of the heart (to improve blood flow into the compartment), treatment of shock, prevention of metabolic acidosis and acute kidney injury (AKI) are all mandatory and crucial to save the patient limb [18–20].

## 6. Conclusion

The incidence and socioeconomic impact of musculoskeletal diseases globally is increasing due to multiple factors. Prevention of these injuries can be achieved by providing an environment in which the worker has a safe surrounding, improved awareness about what possible danger injuries might occur, a clear path to elevation of such danger in the time of need. Occupational safety measures should always be optimal with nearby kits to aid in on-site management. With the increased demand for building and aiming to touch the clouds with sky-high skyscrapers comes great responsibility to care more about providing a healthy working environment. The frequency of musculoskeletal injury and its concomitant burden on the healthcare system is expected to increase greatly in the coming decades. Physicians are required to keep up with this leap. A well-established basic knowledge of such injuries is very crucial and can be lifesaving and cost-effective especially in the emergency department.

The previous injuries we discussed are not by any chance everything in the musculoskeletal system; we chose the most common and the most essential ones, discussed briefly. We

strongly encourage every physician to take this chapter and consider it as a base and build upon it with further reading and practice.

## Author details

Ahmad Subhy Alsheikhly<sup>1\*</sup> and Mazin Subhy Alsheikhly<sup>2</sup>

\*Address all correspondence to: [ahmadmomz@yahoo.com](mailto:ahmadmomz@yahoo.com)

1 Weill Cornell Medical College, Qatar

2 Hamad Medical Corporation, Doha, Qatar

## References

- [1] Rogers F. Musculoskeletal System [Internet]. National Library of Medicine. PubMed Health. 2017 [cited May 13, 2017]. Available from: <https://www.ncbi.nlm.nih.gov/pubmedhealth/PMHT0027058/>
- [2] Marieb E. Human Anatomy & Physiology. 3rd ed. Redwood City: Benjamin Cummings; 1995
- [3] Villa-Forte A. Muscles—Bone, Joint, and Muscle Disorders [Internet]. MSD Manual Consumer Version. 2018 [cited June 14, 2018]. Available from: <https://www.merckmanuals.com/home/bone-joint-and-muscle-disorders/biology-of-the-musculoskeletal-system/muscles>
- [4] Beekley A, Starnes B, Sebesta J. Lessons learned from modern military surgery. *Surgical Clinics of North America*. 2007;**87**(1):157-184
- [5] Mammal Anatomy. New York: Marshall Cavendish Corporation; 2010
- [6] Buschmann J, Bürgisser G. Biomechanics of Tendons and Ligaments. Duxford: Matthew Deans; 6 February 2017. pp. 1-22
- [7] King RB et al. Evaluation of possible tourniquet systems for use in the Canadian forces. *The Journal of Trauma*. 2006;**60**(5):1061-1071
- [8] Brumitt J, Cuddeford T. Current concepts of muscle and tendon adaptation to strength and conditioning. *International Journal of Sports Physical Therapy*. 2015;**10**(6):748-759
- [9] Warby SA et al. The effect of exercise-based management for multidirectional instability of the glenohumeral joint: A systematic review. *Journal of Shoulder and Elbow Surgery*. 2014;**23**(1):128-142
- [10] Doherty C, Bleakley C, Delahunt E, Holden S. Treatment and prevention of acute and recurrent ankle sprain: An overview of systematic reviews with meta-analysis. *British Journal of Sports Medicine*. 2017;**51**:113

- [11] Simon R, Sherman S, Koenigsknecht S. *Emergency Orthopedics: The Extremities*. 5th ed. New York: McGraw-Hill; 2006
- [12] Schaidler J, Simon RR. *Clinical Practice of Emergency Medicine*. Philadelphia: Lippincott Williams & Wilkins; 2005. p. 1033
- [13] Agel J, Rockwood T, Barber R, Marsh J. Potential predictive ability of the orthopedic trauma association open fracture classification. *Journal of Orthopaedic Trauma*. 2014;**28**(5):300-306
- [14] Bagley C, Hunter A, Bacarese-Hamilton I. Patients' misunderstanding of common orthopedic terminology: The need for clarity. *Annals of the Royal College of Surgeons of England*. 2011;**93**(5):401-404
- [15] Chudnofsky C, Byers S. Splinting techniques. In: Roberts J, Hedges J, Chanmugam A, editors. *Clinical Procedures in Emergency Medicine*. 4th ed. Philadelphia, Pa: Saunders; 2004. p. 989
- [16] Boyd AS et al. Principles of Casting and Splinting [Internet]. PubMed-NCBI. Ncbi.nlm.nih.gov. 2018 [cited May 14, 2017]. Available from: <https://www.ncbi.nlm.nih.gov/pubmed/19145960>
- [17] Crespo A, Manoli A, Konda S, Egol K. Development of Compartment Syndrome Negatively Impacts Length of Stay and Cost After Tibia Fracture [Internet]. pubmed. 2018 [cited July 28, 2017]. Available from: <https://www.ncbi.nlm.nih.gov/pubmed/25463427>
- [18] Alessio Gai Via N. Acute Compartment Syndrome [Internet]. PubMed Central (PMC). 2015. Available at: <https://www.ncbi.nlm.nih.gov/pmc/articles/PMC4396671/> [Accessed: July 25, 2017]
- [19] Dries D. Trauma manual: Trauma and acute care surgery, 3rd edition. *Journal of the American College of Surgeons*. 2008;**206**(5):200-208
- [20] Frink M, Hildebrand F, Krettek C, Brand J, Hankemeier S. Compartment syndrome of the lower leg and foot. *Clinical Orthopaedics and Related Research*. 2009;**468**(4):940-950