

We are IntechOpen, the world's leading publisher of Open Access books Built by scientists, for scientists

4,800

Open access books available

122,000

International authors and editors

135M

Downloads

Our authors are among the

154

Countries delivered to

TOP 1%

most cited scientists

12.2%

Contributors from top 500 universities



WEB OF SCIENCE™

Selection of our books indexed in the Book Citation Index
in Web of Science™ Core Collection (BKCI)

Interested in publishing with us?
Contact book.department@intechopen.com

Numbers displayed above are based on latest data collected.

For more information visit www.intechopen.com



Cholangiocarcinoma

*Samuel Romeo Obiekwe, Nathaly Suzett De La Roca
and Jean Saric*

Abstract

Cholangiocarcinoma is a malignant disease of the biliary ductal system which consists of intrahepatic (periphery) 5–10% and extrahepatic, which is further divided into proximal (perihilar) 60–70% and distal 20–30%. The etiology of this grave disease is unknown although many causative factors, including infectious, congenital, and genetic factors, causing chronic inflammation, which results in dysplastic changes of the biliary epithelium and eventual malignancy, have been implicated. The prognosis is poor except when discovered early. The treatment of intrahepatic (CCA) is partial hepatectomy, while radical bile duct resection with or without hepatectomy or pancreaticoduodenectomy is considered for extrahepatic cancer. Liver transplantation is considered in advanced diseases, without extrahepatic lymph node involvement. Palliation including endoscopic drainage or surgical bypass which is an option for unresectable diseases. Adjuvant therapy in the form of chemotherapy, immunotherapy, and photodynamic therapy is a consideration in patients with advanced disease. Many advances have been made in the treatment of cholangiocarcinoma, and hopefully long-term survival may be improved.

Keywords: bile duct cancer, etiology, treatment, resection, palliation, prognosis

1. Introduction

This grave illness was first described in 1840 by Durand-Fardel, as a malignant neoplasia arising from the epithelial cells of the extrahepatic and intrahepatic bile ducts, excluding the papilla of Vater and gallbladder. In 1965, Gerald Klatskin, a Yale University pathologist, described the adenocarcinoma of porta hepatis. Adenocarcinoma of the bile duct epithelium or cholangiocarcinoma within the confluence of the right and left hepatic duct has since then been known as “Klatskin tumor.” The majority of this disease arises at the hepatic duct bifurcation. Surgical resection offers the only chance for cure of this disease. Unfortunately, many patients present with advanced locoregional and distant metastasis at the time of diagnosis, making palliative procedures aimed at biliary drainage with intent to prevent progressive liver failure and cholangitis, which is the only option for unresectable tumors [1–4].

Cholangiocarcinoma (CC) is classified into proximal, perihilar or Klatskin’s (60–70%), distal (20–30%), and intrahepatic or periphery (5–10%). They all have different pathophysiological, epidemiological, and clinical presentations. The most important modality of treatment for hilar cholangiocarcinoma is radical bile duct resection with partial hepatectomy and maintenance of bilioenteric continuity. For intrahepatic cholangiocarcinoma, partial hepatectomy is the treatment of choice,

whereas distal cholangiocarcinoma may require pancreaticoduodenectomy. Surgical outcome after resection for distal cholangiocarcinoma is superior to the rest. Some subset of highly selected patients with unresectable hilar cholangiocarcinoma (HCCA) or intrahepatic cholangiocarcinoma (ICCA) orthotopic liver transplantation (OLT) may be a viable option and has been reported to provide survival benefits [5, 6].

2. Incidence

Statistics of autopsy report shows that the incidence of bile duct carcinoma is 0.01–0.5%. In the United States, it is 1–100,000 per year, with 3000 new cases diagnosed yearly. Worldwide incidence is 0.5–2.0/100,000. Complete resection of early stage tumors can be curative. When the disease is unresectable, prognosis is generally poor with 1-year survival of 53% and 5-year survival of less than 5%. Bile duct cancer is rare in Western countries, resulting in less than 2% in all human cancers. It varies widely in different parts of the world. For example, in Thailand the incidence is 113/100,000 in men and 50/100,000 in women, whereas in France it is 1.7 and 0.5 per 100,000. In Australia, the incidence is low 0.2/100,000 in men and 0.1/100,000 in women. In the United States, studies have shown a decline from 0.85 per 100,000 in 1995 to 0.58 per 100,000 in 2005. The frequency of bile duct cancer increases with age, the majority of these patients are above 65 years old, with peak incidence at seventh decade of life. Cholangiocarcinoma rarely occurs before the age of 40 except in patients with congenital bile duct cysts. The incidence is higher in men than women with a ratio of 1:(1.2–1.5). In the past three decades, most studies have shown a worldwide increase in the mortality from intrahepatic cholangiocarcinoma, whereas there is a decrease in mortality for extrahepatic and gallbladder cancer [7–9].

3. Causative factors

The etiology of cholangiocarcinoma is unknown; however, several risk factors proven and unproven have been attributed as a causative factor for this grave illness. The cause of cholangiocarcinoma is associated with chronic biliary inflammation; malignant transformation may occur in the background of chronic inflammation and cholestasis. The production of some cytokines and reactive oxygen species may cause permanent damage to the DNA.

4. Risk factors

The established risk factors for cholangiocarcinoma include bile duct cysts, parasitic infection, primary sclerosing cholangitis (PSC), hepatolithiasis, and toxins. Other potential established risk factors include inflammatory bowel disease (IBD), hepatitis B and hepatitis C, liver cirrhosis, diabetes, obesity, alcohol, smoking, and host genetic polymorphisms. Thorotrast, a contrast medium which is no longer in use, although used between 1930 and 1960, was associated with several tumors including primary liver tumor, angiosarcomas, gallbladder carcinomas, and tumors of the extrahepatic bile duct. Several large studies from Japan, Germany, and Denmark showed that 45.6% of the patients exposed to Thorotrast developed liver cancer 15–20 years after exposure, compared to 0.3% of control. This is because biological half-life of Thorotrast is 400 years. As with other tumors, dietary

nitrosamines are also implicated [10, 11]. Primary sclerosing cholangitis, an autoimmune disease that results in stricturing of extra- and intrahepatic bile ducts, is an established risk factor for CC. Chronic inflammation, proliferation of biliary epithelium, production of endogenous bile mutagens, and bile stasis are postulated mechanisms of carcinogenesis. About 70% of patients with PSC also suffer from ulcerative colitis, but only a minority of patients with ulcerative colitis develops PSC, so that patients with ulcerative colitis who do not have symptoms of PSC may have increased risk of cholangiocarcinoma. It is interesting that surgical or medical treatment of ulcerative colitis does not decrease the risk of developing cholangiocarcinoma in patients with ulcerative colitis [12]. Hepatobiliary flukes *Opisthorchis viverrini* (*O. viverrini*) and *Clonorchis sinensis* (*C. sinensis*) are associated with cholangiocarcinoma irrespective of site, especially in Southeast Asia. They are trematodes that inhabit in the bile ducts, occasionally the gallbladder, and the pancreatic duct of mammals. Infestation of humans occurs via ingestion of raw, pickled, or undercooked fish. Both parasites increase the susceptibility of cholangiocytes to carcinogens causing chronic irritation and inflammation. Typhoid organisms have been implicated in patients with cholangiocarcinoma, as well as chronic recurrent pyogenic bacterial cholangitis [13, 14].

Hepatolithiasis are stone or gravel located in the intrahepatic biliary tree. Hepatolithiasis is rare in the Western Hemisphere but more common in Southeast Asia notably in Taiwan. These parasitic infestations, such as *Clonorchis sinensis* and *Ascaris lumbricoides*, have been implicated in most patients with hepatolithiasis. Because it is common in Asian countries, it is considered an important risk factor for cholangiocarcinoma. The relationship between hepatolithiasis and cholangiocarcinoma is not well established in the Western Hemisphere, except an Italian study which showed a significant association between hepatolithiasis and ICCA [15, 16]. Patients with congenital biliary disease have an increased risk of developing CC, compared to general population. The risk is highest in patients who did not undergo surgical treatment, who have complete cysts excision before the age of 20, and in those treated with cyst drainage alone, instead of complete cysts excision. There are different types of bile duct cysts, such as extrahepatic biliary cysts and intrahepatic biliary cysts. The etiology of cancer in patients with biliary cysts is as a result of chronic irritation from the reflux of pancreatic enzymes, cholestasis, and damaging effect of bile acids to biliary epithelium, resulting in the formation of malignant cells in patients with bile duct cysts. The average age of cancer formation is around 32, which is younger than the age of presentation of CC in the general population. The risk of malignancy decreases in patients undergoing complete choledochal cyst excision; surprisingly, these patients are still at an increased risk of developing CC than the general population. Patients with an anomalous pancreaticobiliary ductal junction (APBDJ) have a higher incidence of developing bile duct cancer. Ohta showed dysplastic mucosa in this group of patients [17–22].

Tocchi et al. did a retrospective review in patients with biliary-enteric drainage for benign disease and found a high incidence of CC in this population, 5.8% in those who underwent transduodenal sphincteroplasty, 7.6% in choledochoduodenostomy patients, and 1.9% in patients who had undergone hepaticojejunostomy [23].

Bile duct adenomas and multiple biliary papillomatosis have been shown to have malignant transformation potential [24, 25]. Hepatitis C (HCV), hepatitis B (HBV), and liver cirrhosis, regardless of etiology, have been shown as a risk factor for ICCA [26].

There is an association between hepatitis C and cholangiocarcinoma in the United States as reported in Japan. This association is not well studied, but cirrhosis is implicated here [27]. Some studies from the Western countries, such as Denmark,

examined a large population of patients with liver cirrhosis over a mean follow-up period of 6 years and showed an increase risk of cholangiocarcinoma in patients with cirrhosis than general population. An Italian study also demonstrated an association between HCV and ICCA [16, 28]. As mentioned above, the Japanese study showed an association between hepatitis C and cholangiocarcinoma. This is not represented in the study from Korea and Thailand, where the association of hepatitis B and cholangiocarcinoma was shown because of the endemicity of hepatitis B in both countries [26].

The association between diabetes, heavy alcohol drinking, smoking, and cholangiocarcinoma is not well established. Although some studies have shown a relationship between heavy alcohol drinking and cholangiocarcinoma, the risk factor may still be related to the presence of cirrhosis as a result of heavy alcohol drinking [16, 29, 30].

4.1 Genetic implications

Genetic studies showed that polymorphism in genes, which codes for enzymes implicated in the metabolism of carcinogens, DNA repair, and inflammation, can be either pro-carcinogenic or anticarcinogenic. Mutations in oncogenes such as tumor-suppressing genes, p53, APC, and Bcl-2, have been found in biliary duct tumors, which include amplification and overexpression of c-erbB-2 seen in cancers of the biliary tract. Mutations in K-ras, c-myc, c-neu, c-erbB-2, and c-met oncogenes have also been implicated, although mutations of RAS and TP53 genes are the most common abnormalities identified. Studies have shown that intrahepatic cholangiocarcinoma expresses CK7, CK19, and BerEP4 with cytoplasmic staining for CEA, unlike hepatocellular carcinoma. HER2/neu overexpression and high Ki-67 proliferation index are seen frequently in patients with nodal metastasis, as well as patients with reduced immunoexpression of E-cadherin. The suppressor p53 protein is involved in transcription, DNA repair, cell cycling, and genomic integrity. Three types of mechanisms of p16 inactivation have been reported in biliary neoplasms: deletion and point mutations of the p16INK4A gene and hypermethylation of 5' regulatory regions of p16INK4A. It appears that the vascular endothelium growth factor expression is more in patients with extrahepatic cholangiocarcinoma [31–37].

4.2 Clinical presentation

Patients with hilar CC present with progressive obstructive jaundice earlier because of the location of the bile duct confluence; jaundice occurs even when the tumor is comparably small. Symptoms include malaise, weight loss, anorexia, nausea, vomiting, pruritus, and right upper quadrant pain. In patients with hilar CC, intrahepatic bile ducts are dilated, the gallbladder is usually not palpable, and the common duct is often collapsed on cholangiogram or ultrasound. In contrast, patients with carcinoma in the distal common bile duct or cystic duct present usually with a distended gallbladder and significant dilatation of the proximal bile duct system.

The symptoms are often obscure and many times ignored, making it difficult for early detection. As the tumor grows and obstructs the common hepatic duct and biliary confluence, jaundice gradually develops. Most patients with hilar cholangiocarcinoma seek medical advice because of progressive painless jaundice, accompanied with pruritus with multiple skin excoriations, clay-colored stool, and dark urine. Only patients with acute cholangitis present with fever, and this is seen only in 10% of the cases. On physical examination the liver is enlarged and firm. The

gallbladder is usually impalpable, except in cases of distal biliary obstruction unlike hepatic biliary confluence obstruction where the gallbladder is not palpable [38, 39, 97].

4.3 Differential diagnosis

Biliary tumors are accompanied with painless jaundice which is suggestive of biliary obstruction. Although in the clinical findings, laboratory values such as tumor markers are non-specific and cannot specifically identify the exact cause of the stricture, differentiating extrahepatic biliary tumor from other causes of obstructive jaundice is important since the treatment is different.

4.4 Benign and malignant lesions masquerading as cholangiocarcinoma

Because of the close anatomic relationship of the biliary confluence to the gallbladder, carcinoma of the gallbladder may in some cases involve the hepatic hilum. Systemic dissemination of malignant melanoma can involve the biliary tract mimicking bile duct tumor. Neuroendocrine tumors can also involve the biliary tree. Lymph node metastatic cancers of the GI tract can also invade the bile duct as well as primary hematolymphoid malignancies which can affect the hepatic hilum [40–56]. Other lesions include primary sclerosing cholangitis, secondary sclerosing cholangitis syndromes (portal biliopathy and AIDS cholangiopathy), inflammatory pseudotumor (autoimmune pancreatocholangitis), recurrent pyogenic cholangitis, Mirizzi syndrome (Type I–IV), biliary adenomas, hepatobiliary sarcoidosis, xanthogranulomatous cholecystitis and cholangitis, chemotherapy-induced sclerosing cholangitis [40–56].

5. Pathology

5.1 Gross appearance

Macroscopic appearance of CC of the extrahepatic bile ducts can be grouped into three types, sclerosing/scirrhous, nodular, or papillary. Sclerosing/scirrhous tumors are the most common. They may also be a combination “nodular sclerosing.” Papillary variant accounts for 10% of all CC, most commonly seen in the distal bile duct but may also be present in hilus [57].

5.2 Pre-malignant lesions

Biliary adenoma: Although these are benign tumors, a small proportion may progress to carcinoma. **Papillomatosis:** Because of its multicentricity, it has a greater malignant potential and, whenever it is encountered, complete excision. Although difficult it is highly recommended.

Biliary cyst adenoma: Dysplastic changes leading to malignant transformation can occur with cysto-adenocarcinoma [24, 25].

5.3 Variants

Adenocarcinoma is the most common accounting for 90%, about two-third of all such tumors; it shows some focal intestinal differentiation with goblet and neuroendocrine cells. Variants include intestinal type, papillary adenocarcinoma, and mucinous adenocarcinoma. Overall, papillary adenocarcinoma has better prognosis even with lymph node metastasis. The mucinous adenocarcinoma produces an abundance

of mucin secretion. Perineural and neural invasion is common. Clear cell carcinoma, hepatic carcinoma, and signet ring carcinoma are all variants of cholangiocarcinoma. Carcinosarcoma can be differentiated from squamous carcinoma because of the presence of spindle cell in the sarcoma variant. Some of these tumors can be keratinizing, while others are not. Small-cell carcinomas are endocrine tumors with varying degrees of differentiation; synaptophysin and chromogranin are necessary to confirm their endocrine nature [57].

6. Staging

In accordance with the American Joint Committee on Cancer (AJCC), the staging of extrahepatic cholangiocarcinoma is based on the extent of the primary tumor (T stage), extent of regional lymph node involvement (N stage), and presence of distant metastasis (M stage) (**Table 1**). An alternative to staging system proposed by Bismuth and Corlette classifies cholangiocarcinoma, based on the location of the tumor with respect to the hilum and on the extent of ductal involvement (**Figure 1**). AJCC staging is based largely on pathologic criteria and has little clinical significance since most patients present with T3 (stage IVA) tumors based on invasion of the liver. This neither says much about its resectability nor does it correlate with survival. In the AJCC system, patients with involved N1 and N2 lymph nodes are

Anatomic stage/prognostic groups			
Stage 0	Tis	N0	M0
Stage I	T1	N0	M0
Stage II	T2a-b	N0	M0
Stage IIIA	T3	N0	M0
Stage IIIB	T1-3	N1	M0
Stage IVA	T4	N0-1	M0
Stage IVB	AnyT	N2	M0
	AnyT	Any N	M1
Primary tumor (T)			
TX	Primary tumor cannot be assessed		
T0	No evidence of primary tumor		
Tis	Carcinoma in situ		
T1	Tumor confined to the bile duct, with extension up to the bile duct, with extension up to the muscle layer or fibrous tissue		
T2a	Tumor invades beyond the wall of the bile duct to surrounding adipose tissue		
T2b	Tumor invades adjacent hepatic parenchyma		
T3	Tumor invades unilateral branches of the portal vein or hepatic artery		
T4	Tumor invades main portal vein or its branches bilaterally or the common hepatic artery or the second-order biliary radicals bilaterally or unilateral second-order biliary radicals with contralateral portal vein or hepatic artery involvement		
Primary tumor (T)			
NX	Regional lymph nodes cannot be assessed		
N0	No regional lymph node metastasis		

N1	Regional lymph node metastasis (including nodes along the cystic duct, common bile duct, hepatic artery, and portal vein)
N2	Metastasis to periaortic, pericaval, superior mesenteric artery, and celiac artery lymph nodes
Distant metastasis (M)	
M0	No distant metastasis
M1	Distant metastasis

Table 1.
 American Joint Committee on Cancer Seventh edition TNM staging for perihilar bile duct cancer. Anatomic stage/prognostic groups

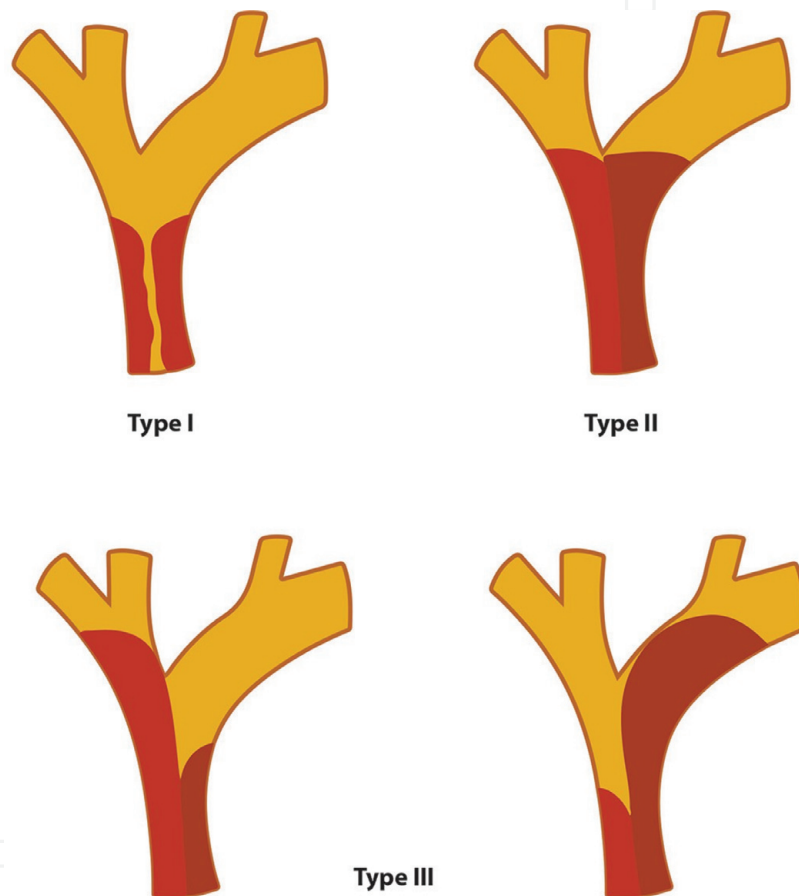


Figure 1.
 Original Bismuth-Corlette classification.

inappropriately staged the same, since patients with metastatic disease to N2 lymph nodes (celiac, periduodenal, or retroperitoneal) are not candidates for resection and should be considered to have M1 disease. The Bismuth-Corlette system is more clinically relevant if not too simplified, but it also correlates poorly with resectability and survival. The Japanese Society of Biliary Surgery (**Table 2**) established a separate pathological staging system. In this system, the T classification is meticulously divided into categories of invasion because of its histological landmarks such as mucosa, serosa, and subserosa and its depth of invasion to adjacent structures such as the liver or pancreas which is classified into less than 5 mm, between 5 and 20 mm, and greater than 20 mm. Vascular invasion is distinguished between portal and hepatic artery, with each type having three depths (adventitial, tunica medial, and tunica intimal with stenosis or obstruction) numbered 1–3, respectively. This

pT classification						
pT	Contents					
pT1	m, fm, hinf0, panc0, pv0, a0					
pT2	ss, hinf1, panc1, pv0, a0					
pT3	se, hinf2, panc2, pv1, a1					
pT4	si, hinf3, panc3, pv2, pv3, a2, a3					
Lymph node grouping						
Lymph node (site number)	Group					
	Hilar and proximal	Middle	Distal			
Infrapyloric LN (6)	pN3	pN3	pN3			
LN around the common hepatic artery (8)	pN2	pN2	pN2			
LN at the splenic hilum (10)	pN3	pN3	pN3			
LN along the splenic artery (11)	pN3	pN3	pN3			
LN at the hepatic hilum (12 h)	pN1	pN2	pN2			
LN along the hepatic artery (12a)	pN1	pN2	pN2			
Periportal LN (12p)	pN1	pN2	pN2			
Pericholedochal LN (12b)	pN1	pN1	pN1			
LN around the cystic duct (12c)	pN1	pN1	pN1			
Posterior superior pancreaticoduodenal LN (13a)	pN2	pN2	pN2			
Posterior inferior pancreaticoduodenal LN (13b)	pN3	pN3	pN3			
LN along the superior mesenteric artery (14)	pN3	pN3	pN2			
Para-aortic LN (16)	pN3	pN3	pN3			
Anterior superior pancreaticoduodenal LN (17a)	pN3	pN3	pN3			
Anterior inferior pancreaticoduodenal LN (17b)	pN3	pN3	pN3			
Stage grouping	H(-) and P(-) and M(-)				H(+) and/or P(+)	
	pN0	pN1	pN2	pN3	M(+) and any N and/or	
pT1	I	II	III	IVa	IVb	
pT2	II	III	III	IVa	IVb	
pT3	III	III	IVa	IVb	IVb	
pT4	IVa	IVa	IVb	IVb	IVb	

Table 2.
Japanese Society of Biliary Surgery classification for cholangiocarcinoma.

classification is not popular outside of Japan due to its lack of complexity and authenticity. The Bismuth-Corlette system has since then modified its classifications (**Figure 2**) from its original: Type I, non-obstructed primary confluence; Type

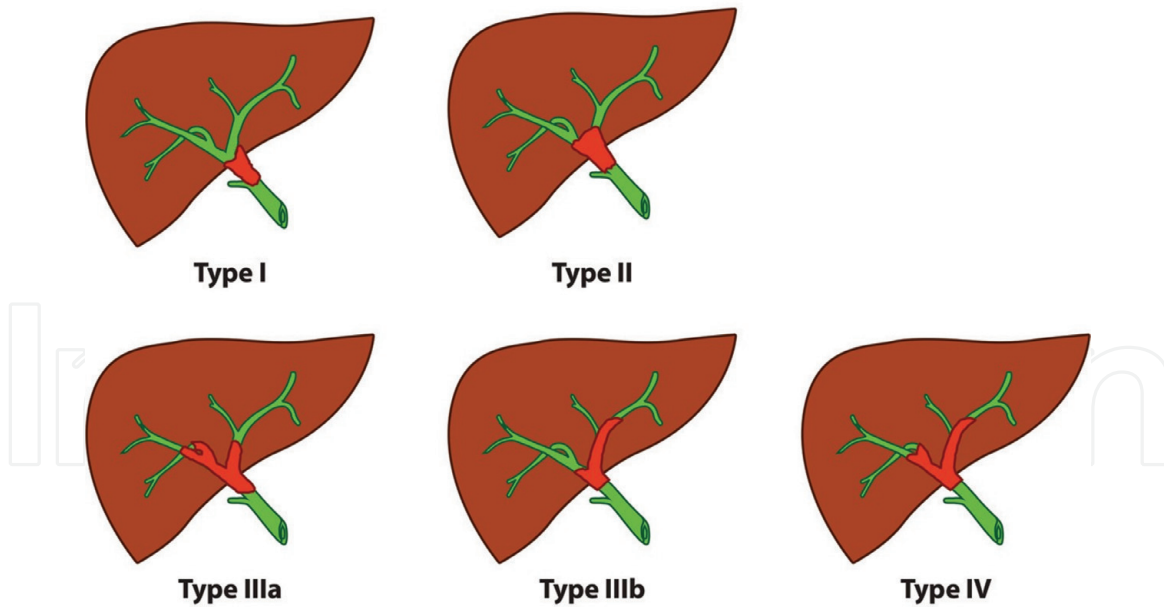


Figure 2. Modified Bismuth-Corlette classification. Type I, tumor entirely below the confluence; Type II, tumors affecting the confluence; Type III, tumors occluding the confluence extending to the first-order right (IIIa) or left (IIIb) intrahepatic ducts; Type IV, involving both hepatic ducts or are multicentric.

II, obstruction limited to primary confluence; Type III, primary confluence with extension to the right or left secondary confluence; and Type IV, extension involving bilateral biliary ductal systems.

6.1 Bismuth-Corlette classification

None of the current staging systems takes into account local factors such as vascular invasion and hepatic lobar atrophy, which are important determinants for resectability and surgical outcome.

The TNM system can only be determined postoperatively and on final pathological specimen. A modified preoperative T staging was proposed by Jarnagin/Blumgart (**Table 3**). In this staging, the nodal and distal metastases are not considered. Going from T1 to T3, the nodal and distal metastasis increases. In their series, resectability was 59% with T1 and 0% with T3. Negative resection margin, concomitant hepatic resection, and well-differentiated tumor are independent predictors of long-term survival. With the Jarnagin/Blumgart system, a more in-depth framework was utilized to base preoperative decisions by predicting not only resectability but also the likelihood of R0 resection and subsequent survival.

Stage	Criteria
T1	Tumor involving biliary confluence ± unilateral extension to second-order biliary radicles
T2	Tumor involving biliary confluence ± unilateral extension to second-order biliary and ipsilateral portal vein involvement ± ipsilateral hepatic atrophy
T3	Tumor involving biliary confluence ± bilateral extension to second-order biliary radicles or unilateral extension to second-order biliary radicles with contralateral portal vein involvement or unilateral extension to second-order biliary radicles with contralateral hepatic lobar atrophy or main or bilateral portal venous involvement

Table 3. Blumgart preoperative T staging system

7. Investigation and diagnosis

7.1 Evaluation of liver functional status

Liver function test and Child-Pugh score (MELD score).

Radiological: computer tomography volumetric analysis, hepatic steatosis measurement.

Some centers have taken into consideration the bioenergetics which includes the redox state of hepatocyte mitochondrial by quantifying the amount of ketone bodies in the serum of the patient, as well as the measurement of cellular energy charge through the measurement of AMP, ADP, ATP which can correlate with the phosphorylation ability of the hepatocytes. An abnormal functioning hepatocyte will have an alteration in energy level. Another emerging technique is the magnetic resonance spectroscopy which is an in vivo non-invasive measurement of intracellular metabolism in relationship to phosphorylation. Other tests, such as dynamic studies (clearance tests, e.g., indocyanine green, aminopyrine, MEGX, hexose sugar handling capacity, hepatic scintigraphy, and portal vein embolization) [58].

7.2 Role of tumor markers

There seems to be no specific screening for Cholangiocarcinoma that is effective accept the laboratory values which may indicate obstructive cholestasis with hyper bilirubinemia and elevated alkaline phosphatase. The levels of CA 19-9, CEA, and CA-125 may be elevated, but only CA 19-9 is sensitive and specific 79% and 98% at the cut off value of 129 units/ml. Tumor markers are helpful when used together with other diagnostic tests. CA 19-9, CEA, and CA-125, may be elevated in patients with cholangiocarcinoma. CA 19-9 is less sensitive in patients with PSC, 53% at a cut off of greater than 100 units/L and usually would be undetectable in some patients lacking blood type Lewis antigen who usually do not produce CA 19-9. Patients lacking blood-type Lewis antigen (10%) do not produce CA 19-9. CA 19-9 are non-specific because they are also elevated in other gastrointestinal tumors. CEA alone has a low sensitivity and specificity for the diagnosis of cholangiocarcinoma. Siquiera and his associates demonstrated in their study that CEA > 5.2 ng/mL in combination with CA 19-9 > 180 U/ml had a sensitivity of 100% and a specificity of 78.4% for the detection of cholangiocarcinoma in patients with PSC.

However, Patel et al. compared the levels of CA 19-9 in 36 patients with cholangiocarcinoma without PSC. They found a cutoff value of CA 19-9 > 100 units/ml with a sensitivity of 53% for the diagnosis of cholangiocarcinoma and a true negative rate of 76% for nonmalignant liver diseases and 92% for benign biliary stricture. All the studies show, in patients with PSC, CA 19-9 has a cutoff value of >100 U/ml and a sensitivity of 75–89% while a specificity of 80–86% for the detection of cholangiocarcinoma. Newer markers, such as the human mucin subtypes A and C (mucin-5 AC), trypsinogen, and soluble fragment of cytokeratin 19, are currently being investigated, although Bamrungphon et al. reported that mucin-5 AC at a cutoff value of 0.074 had a sensitivity of 71% and a specificity of 90% for the diagnosis of CC. In another study of tumor stage resectability, CA 19-9 and CEA levels increased significantly with rising tumor stages. Patients with preoperative serum levels of CA 19-9 (> 1000 U/ml) and CEA (>14.4 ng/ml) showed a significant poorer resectability rate [59, 60].

8. Imaging

The most commonly used imaging modalities are ultrasound, CT scan, MRI/MRCP, direct cholangiogram, and PET scan.

Ultrasound usually shows dilatation of the biliary tree either intra- or extrahepatic biliary tree. Distal obstruction is associated with both extra- and intrahepatic dilatation, whereas proximal obstruction is associated with intrahepatic dilatation. It can show the extent of the tumor involvement as well as encroachment to the portal vein. Contrast-enhanced ultrasound is currently being used in the diagnosis of hilar cholangiocarcinoma. Endoscopic ultrasound is valuable in assessing patients with cholangiocarcinoma and its involvement with neighboring structures, especially the middle and distal part of the bile duct, but it cannot distinguish between benign and malignant lesions [61, 62]. CT scan with intravenous contrast scanning plays an important role in the diagnosis and staging of hilar cholangiocarcinoma, since it can provide information regarding the location of biliary obstruction, tumor extension, vascular invasion, hepatic lobar atrophy, lymph node involvement, distant metastases, and encroachment of the portal vein. It is even more accurate when high-resolution multidetector-row CT scanners are used [63]. The combination of MRI with MRCP is another effective imaging modality for staging of hilar cholangiocarcinoma. Like CT scanning, MRI provides reliable information regarding the level of biliary obstruction, vascular invasion, hepatic lobar atrophy, lymph node involvement, as well as distant metastases. Unlike PTC, MRCP is not invasive. It has an accuracy of 72–83% [64, 65]. ERCP and PTC involve injection of contrast into the biliary tree. They are commonly used in the preoperative diagnosis. It is unreliable in patients with complete bile duct obstruction. It seems to be a simple procedure but could be met with some complications, which include bile leakage, cholangitis, bleeding, pancreatitis, and duodenal perforation. Mortality rate ranges between 0.6 and 5.6%. Because of its limitation it has been replaced with MRCP [64]. FDG-PET is not superior to conventional triple-phase CT scanning in the detection of primary lesion of hilar cholangiocarcinoma. However, it is more accurate than conventional CT scan in detecting distant metastases with a sensitivity between 56 and 100% and a specificity of 88% [66].

9. Tissue analysis

Endoscopic-guided fine-needle aspiration is useful when the results of brush cytology and forceps biopsy are inconclusive; EUS-guided FNA can be done. Its negative predictive value is 29%, which means that a negative EUS-guided FNA does not necessarily exclude the possibility of hilar CC [62].

Although the diagnosis of hilar cholangiocarcinoma is primarily based on imaging, it has its limitation because of its inability to differentiate between benign and malignant strictures. Brush cytology and forceps biopsy via ERCP or PTC are the most frequently used modality for pathological diagnosis. With brush cytology most of the time the tissue obtained may not be sufficient to make a good pathological assessment because the tumor may be hidden within fibrous stroma allowing for a lower sensitivity as opposed to forceps biopsy [67]. The FISH assay can identify malignant cells by its fluorescent probes as well as detecting abnormal chromosomes in the biliary cells obtained by brush cytology. It is a very advanced technique and when complemented with DIA which identifies malignant cells by the use of special stains that quantify nuclear DNA as well as demonstrate aneuploidy

are both promising [68]. The exfoliative cells found in the bile can further be analyzed in the context of its DNA methylation status, thereby demonstrating evidence of malignancy in patients with equivocal findings, such as biliary stricture. The most well studied are P16 and APC gene [69].

10. Treatment of cholangiocarcinoma

Only surgical excision of all detectable tumors is associated with an improvement in 5-year survival. However, surgery can only cure a minority of patients, with a 20–30% 5-year survival for distal lesion and a 9–18% 5-year survival for proximal lesions. The management of patients with CC should be a multidisciplinary approach. Patients' general physical condition must be assessed, including pulmonary and cardiovascular function, nutritional, extent of cholestasis, and a proper assessment of resectability as well as future liver remnant. Preoperative staging must have been done and resectability is assessed. The following criteria would suggest an irresectable tumor: involvement of bilateral second-order intrahepatic or extra hepatic ducts, or multifocal tumor on cholangiography, extensive involvement of the main portal vein, involvement of major vessels or ducts on the contralateral side of the liver, liver atrophy, and nodal metastasis to N2 lymph nodes (peripancreatic, periduodenal, celiac, superior mesenteric, or posterior pancreaticoduodenal lymph nodes). Lymph node involvement and peritoneal seeding may be difficult to detect preoperatively. In this case, laparoscopy and laparoscopic ultrasound offer additional benefit. Laparoscopy includes likelihood of visualizing small metastatic tumor deposits on the surface of the liver and peritoneum, which would otherwise go undetected. Laparoscopic staging avoids extensive preparation for inoperable patients. Cytological analysis of peritoneal washings can be done during laparoscopy.

11. Is there a role of preoperative optimization of the liver prior to surgical resection?

Jaundice is usually the presenting symptom in patients with hilar cholangiocarcinoma, even when the tumor is small. Complete tumor clearance may require extensive liver resection to obtain long-term survival. Having said that, extensive liver resection has a mortality rate of up to 20% and morbidity rates of up to 67%. Parenchymal transection in a jaundiced and cholestatic liver may result in increased bleeding, biliary fistula, sepsis, and impaired liver regeneration. In attempting to improve preoperative outcome, many centers have advocated preoperative biliary drainage and ipsilateral portal vein embolization of the hemiliver to be resected, to improve the future of the liver remnant. In a recent French national study, serum bilirubin was found to be correlated with mortality, which ranged from 9 to 27% when serum bilirubin was more than 300 units (French International Value). The choice of the route for biliary drainage is controversial. Endoscopic approach is often difficult in patients with complete obstruction, especially when the left duct requires drainage. Percutaneous transbiliary drainage can be done either unilateral or bilateral. But most centers prefer a unilateral PTBD on the side of the future liver remnant. It takes about 4–6 weeks prior to surgery and normalization of serum bilirubin. Note that preoperative biliary drainage resulted in an increase of postoperative infectious complication rates [70, 71]. Although there is no randomized study to show the benefit of portal vein embolization in hilar cholangiocarcinoma, some people argue in favor of PVE, especially when extended right lobe resection

and vascular reconstruction are anticipated since resection of more than 60% of the total liver volume may result in postoperative liver failure [72].

12. Surgical treatment

It is important to determine whether an R0 resection is achievable. Is the future liver remnant sufficient for patient survival? Is there distant metastasis and involvement of level 3 lymph nodes, celiac, SMA, and aortocaval, which precludes curative resection [73, 74]? In the last 20 years, extended liver and bile duct resection has become the standard of care for hilar cholangiocarcinoma. In general, a remnant liver consistent of 20–30% of the total liver mass is sufficient to prevent liver failure following resection as long as this remaining portion is not compromised. To accomplish this, it might be necessary to employ volumetric studies performed by radiologists of the total and future remnant liver. Some centers advocate the use of (ICG) 15-min retention rate and ICG clearance (K-value).

Peritoneal carcinomatosis and small intrahepatic metastasis are often not detectable by conventional preoperative investigations. This has motivated the use of staging laparoscopy and an analysis of peritoneal washing for patients with HCCA [75].

12.1 Is there a role of local resection in biliary cholangiocarcinoma?

Local resection is not an adequate curative operation for HCCA, except perhaps for small papillary Klatskin tumor without bile duct confluence involvement (Type I Bismuth-Corlette classification, T1s and T1 AJCC staging) [76].

The goal of the surgical principle in the management of HCCA is to accomplish a R0 resection, not only cancer-free proximal and distal margin but also cancer-free margins around the hepatoduodenal ligament. Patients should undergo a thorough surgical exploration, especially if they have no preoperative signs of metastasis or locally unresectable disease, because despite the selectivity and specificity of ultrasonography, CT scan, and MRI, almost 45% of patients who are explored are found to have peritoneal tumor seedings, lymph node involvement, liver metastasis, or advanced disease, all of which preclude resection. These patients may benefit with biliary bypass and cholecystectomy to prevent future occurrence of acute cholecystitis.

At laparotomy, a generous Kocher maneuver is performed to mobilize the pancreatic head. During this procedure, hepatoduodenal ligament, retropancreatic and celiac arteries are also exposed. Distal bile duct is isolated and resected at its intrapancreatic portion. Distal margin should be submitted for intraoperative frozen section examination. If the frozen section is negative, the distal stump is closed. If the distal margin is positive for cancer, then a concomitant pancreaticoduodenectomy is indicated. This applies to resectable tumors. For unresectable perihilar malignant lesions, Roux-en-Y choledocojejunostomy to either segment II or III bile ducts or the right hepatic duct can be performed.

For curative lesions, the location and local tumor involvement determine the extent of resection. Perihilar tumors involving the bifurcation or above the common hepatic duct (BC Type I or II) without any vascular involvement may be a candidate for local resection with portal lymphadenectomy, cholecystectomy, common bile duct excision, and bilateral Roux-en-Y hepaticojejunostomy. For lesions involving the right or left duct (Bismuth-Corlette IIIa and IIIb), right or left hepatic lobectomy can be performed. Distal bile duct tumors are frequently resectable, and if resectable they are treated with pylorus-preserving pancreaticoduodenectomy, whereas in unresectable distal bile duct tumors, Roux-en-Y hepaticojejunostomy,

cholecystectomy, and gastrojejunostomy should be performed to prevent gastric outlet obstruction as the tumor progresses. The principal caudate lobe duct drains into the left hepatic duct. Tumors extending into the left hepatic duct almost always involve the caudate duct and will usually necessitate caudate resection. Also, a dilated caudate duct may be suggestive of tumor involvement. The lobe is involved by HCCA in 40–98% of patients. Retrospective studies have shown a decrease in local recurrence and improvement in 5-year survival with concomitant caudate resection. Tsao et al. stated that combining hilar resection and partial hepatectomy with complete caudate lobe resection can be performed safely. Others consider removing the caudate lobe, only when the left hepatic duct is involved.

Depending on the level of ductal involvement with surrounding structures the following procedures can be performed:

Left or right hepatectomy with caudate lobectomy is performed for tumor involving the left or right secondary biliary duct. Resection of the caudate lobe along with left or right hepatectomy or sectionectomy is no more controversial in our center. We recommend mandatory caudectomy irrespective of the type of procedure to be carried on. Extended left or right hepatectomy with caudate lobectomy can be considered depending on the extent of biliary and parenchymal involvement. For B/C, Type IV tumors which involve bilateral secondary biliary radicles are considered unresectable. These patients are candidates for palliative treatment or liver transplantations. In various series of Klatskin tumors, portal vein involvement has been found in 16–22% of patients. In addition, its propensity to spread along the bile duct and nerves, that accompany the hepatic and celiac arteries, as well as its direct spread to lymph nodes (53%) and adjacent liver parenchyma, has made it difficult to achieve an R0 resection with removal of the duct alone [73].

Central hepatectomy is indicated for tumors located at the confluence of the three segments deep within the liver substance in patients with good hepatic reserve. This involves removal of segment 4a, 4b, 5, and 8 [77, 78].

Ex situ ex vivo autotransplantation. This highly skilled bench surgery which involves total hepatectomy under hypothermic perfusion and complex reconstruction and reimplantation should only be attempted in experienced centers on carefully selected patients [79]. Bilioenteric continuity is essential to restore the continuity of bilioenteric flow. Mucosal to mucosal anastomosis is made between a Roux-en-Y loop of jejunum.

The role of lymphadenectomy in the staging is important, but its role in treatment is debatable. Although earlier studies showed its advantage, clinical evidence of the survival benefits of lymphadenectomy during extended resection remains low [80, 81]. Portal vein resection can be done in cases where the tumor is adherent to the portal vein. It is evident that combined portal vein resection offers improved survival when compared to no resection or a resection with positive margins. Portal vein resection for HCCA in experienced hands is not debatable and can be done, and sometimes the resected portal vein is replaced with autologous vein or interposition graft. However, hepatic artery involvement by the tumor previously was considered contraindication to resection but recently, some centers are resecting and reconstructing the hepatic artery for tumors involving secondary biliary radicles and hepatic artery. Hepatic artery reconstruction is an evolving technique, in which more studies must be done before it becomes a standard [82, 83].

12.2 Transplantation

Surgical R0 resection is clearly the definitive choice for patients with HCCA/ICCA and should be considered in all patients who are surgical candidates presenting with resectable tumors. Earlier studies of long-term survival outcome

with the radical resection of early stage hilar tumor report a 5-year survival rate of 34%; the outcome for CCA with aggressive features such as tumor size more than 2 cm multifocality remains poor because of limitation of resection as treatment modality in achieving clear margins. For ICCA, the 5-year survival rate with negative surgical margins approached 31%; there are no survivors with residual disease. The median time for recurrence ranges from 9 to 20 months, with the most common site being the liver remnant, occurring in 38–70% of cases and metastasis to the regional lymph node, lung, and bones. Unfortunately many HCCA and ICCA tumors are considered unresectable because of tumor extension to the hepatic parenchyma, major hepatic artery, and vein of both right and left hemilivers and metastasis to regional lymph nodes. Considering these circumstances for locally advanced HCCA/ICCA in the absence of distant metastasis, a total hepatectomy followed with regional lymphadenectomy followed by orthotopic liver transplantation offers a viable treatment option because it will address all relevant resection margins, as well as liver disease. Liver transplantation offers the advantage of removing all structures that may be involved by hilar cholangiocarcinoma including portal vein, bilateral hepatic duct, atrophic liver lobes, and hepatic artery. Total hepatectomy will permit R0 resection for locally advanced tumors which are beyond the ordinary criteria for resection using partial hepatectomy. Unfortunately early reports of transplantation in patients with cholangiocarcinoma were not successful, the 5-year survival was 20–30%, and it was considered a relative contraindication to liver transplantation. It was not until the group from the Mayo Clinic developed a protocol with the intent of treating a highly selected group of patients with CC.

The inclusion criteria involves a strict selection of patients with early stage HCCA either deemed locally unresectable or arising in the setting of underlying PSC. Patients with HCCA were included only if there was no mass lesion below the level of the cystic duct. The upper limit of tumor size was 3 cm. When the mass was visible in cross-sectional imaging studies, and there must be no evidence of intrahepatic or extrahepatic metastasis by any imaging studies, the initial protocol excluded patients with intrahepatic CC or gallbladder cancer (**Table 4**). Surgical intervention and percutaneous biopsy were avoided to minimize percutaneous seeding; candidates must have no active infection or medical condition to preclude neoadjuvant therapy or liver transplantation. The candidates underwent endoscopic ultrasound-guided regional lymph node aspiration before neoadjuvant therapy. Any patient with positive lymph node metastases are disqualified from subsequent liver transplantation. In the Mayo Clinic protocol, patients received external beam radiotherapy and transcatheter radiation with iridium (Ir) 192 through a wire placed endoscopically. Systemic 5-FU is given during radiation followed by oral capecitabine after radiation until the day of surgery. Before transplantation all

Variables	Mayo Clinic	UCLA
Hilar CC	Yes	Yes
Hilar CC size	<3 cm	<3 cm
Intrahepatic CC	No	Yes
Intrahepatic CC size	—	≤8 cm
Metastasis to hepatic parenchyma	Absent	Present or absent
Metastasis to regional lymph node	Absent	Present or absent
Metastasis to distant organ	Absent	Absent

Table 4.

Comparison of inclusion criteria for Mayo Clinic and UCLA treatment protocol of cholangiocarcinoma.

patients undergo a staging laparotomy, including a biopsy of at least one lymph node along the proper hepatic artery and another along the common bile duct, as well as any suspicious lymph node. Only those with negative lymph nodes will proceed with transplantation. The results of transplantation showed 1- and 5-year survival rates of 91 and 76%, respectively, and 5 year recurrence-free survival rate of 60%. Predictors for tumor recurrence in older patients include CA 19-9 levels over 100 units/mL on the day of transplantation, prior cholecystectomy, tumor grade, and residual greater than 2 cm, as well as perineural invasion in explant. A multicenter study showed a 2- and 5-year recurrence-free survival of 78 and 65%, respectively. There is a significant morbidity associated with this, such as cholangitis, intrahepatic abscess and sepsis, infection, and tumor necrosis from chemoradiation. The greatest concern is vascular complication after transplantation. The overall vascular complication rate after transplantation was 41%; 21% of patients developed hepatic arterial complications, whereas 20% experienced portal venous complications. To avoid using irradiated native hepatic artery, an infrarenal interposition arterial graft was routinely used to reconstruct arterial inflow in all deceased donor grafts, whereas the native hepatic artery was used in live donor grafts. Although the Mayo Clinic protocol has resulted in excellent long-term recurrence-free survival, proponents for expansion of OLT criteria argue that patient inclusion guideline restricted to hilar tumors based only on size may exclude patients with locally advanced hilar CC stage IIA, IIB, and III (AJCC). Despite absence of metastatic disease, Hong et al. have recently reported that survival benefits can also be achieved in patients with locally advanced CC (>3 cm in size, tumor extension to hepatic parenchyma, branches of portal vein or hepatic artery, presence of perineural and lymphovascular invasion). Using a neoadjuvant and adjuvant protocol, they had a 5-year disease recurrence-free survival of 47% in patients who received OLT in combination with neoadjuvant and adjuvant therapies than 0% in the resection group [84–86].

12.3 Is there a role of adjuvant therapy in the treatment of cholangiocarcinoma?

Some centers reported the use of intraoperative radiotherapy, Busse et al. These results are rather conflicting with no significant difference in mean survival. Although Kamada et al. suggested that radiotherapy may increase survival in patients with positive hepatic duct resection margins. If this modality is to be used postoperatively, metal clips should be placed to mark the area of the anastomosis after resection or areas of known or suspected residual tumors. Despite significant advances in the surgical management of perihilar cholangiocarcinoma, the only chance for long-term survival remains complete resection with negative margins. Radiation therapy alone has no significant impact in prolonging survival in these patients. Some centers are using gemcitabine in combination with cisplatin along with radiation, although anecdotal but rather promising. Both gemcitabine and cisplatin have been demonstrated in recent years to have activity against hilar CC, and a recent phase 3 trial suggests that the best results can be achieved with a combination of these two agents [87–91].

12.4 Palliative therapy

Most patients with HCCA may not be suitable for surgical resection. If a patient is considered irresectable after histological or cytological tissue is confirmed to be cancerous, palliative measures can be an option. The palliative measures include biliary decompression either surgical, endoscopic, or percutaneous techniques which can be applied in unresectable tumors as well as chemotherapy, radiation

therapy, and photodynamic therapy. Palliative biliary bypass can be performed by exposing the left hepatic duct; this involves (1) opening the umbilical fissure, elevating the base of the segment 4 lobe, while lowering the left hepatic ductal system from the undersurface of the quadrate lobe, (2) exposing branches of the left duct by dissection at the base of the ligamentum teres, (3) by partial excision of the left lateral segment and performing a biliary-enteric anastomosis to the opening in branches of the left hepatic duct (Longmire procedure), and (4) Cahow's intrahepatic cholangiojejunostomy. If the left hepatic duct is not accessible, the right drainage system (V or VI) can be exposed by a hepatotomy at the base of the gallbladder fossa, but in general, segment III bypass is performed, unless the left liver is atrophic or is heavily involved with tumors or in cases of the primary lesion extending to the umbilical fissure of the liver [92, 93].

12.5 What are the importance of endoscopic and percutaneous methods and when is it indicated?

The use of these modalities differs from center to center. Routine biliary drainage is not recommended before assessing resectability, except in patients with suppurative cholangitis or patients with severe renal dysfunction and malnutrition. Endoscopic palliation of jaundice in patients with HCCA is best achieved in patients in whom preoperative drainage was achieved endoscopically. At the present time, percutaneous drainage of the biliary system is a useful tool in patients in whom endoscopic drainage cannot be achieved due to technical difficulties and in non-availability of advanced endoscopic facilities. Endoscopic stent insertion can also be used to deliver other forms of palliative adjuvant therapy, such as brachytherapy and photodynamic therapy. The development of newer stents and techniques for deployment as well as the rapidly emerging applications of EUS could widen the scope of endoscopy as a palliative tool in HCCA. It is technically easier to place endoscopically or percutaneously in patients with distal lesions than proximal lesions. The patency for metallic stents at the hilar region is less than those placed in the distal duct. Endoscopic, percutaneous, and operative approaches to biliary decompression are effective. The patency for distal stent is higher than the proximal stents. It might be technically difficult to place a stent to the proximal lesion endoscopically. In this scenario, percutaneous approach may be better for proximal lesions. Stents can be placed unilateral or bilateral and sometimes unilateral stent placement may be adequate. The patency of self-expanding bare metal stents is higher than polyethylene plastic stents. Covered stents have a comparable patency rate to bare metal stents, but they are associated with an increased rate of complication which involves stent migration. Photodynamic therapy is emerging as a promising option for palliative therapy, while brachytherapy is still evolving. Both approaches remain, at this time, investigational for CC palliation. It is important that the optimal management of patients with CC requires a multidisciplinary team of clinicians, including surgeons, interventional and diagnostic radiologists, gastroenterologist, and hepatologists [94, 95].

12.6 Photodynamic therapy and immunotherapy

This approach has been used as a palliative measure for tumors of the esophagus, colon, and stomach. It is promising as a means of providing biliary decompression without stents or another means of treating those with microscopically involved bile duct margins. It uses two nontoxic components, a photosensitizing chemical called photosensitizer and light which is applied in sequence. The wavelength of the photosensitizer corresponds to the absorption spectra of the photosensitizer, and it is activated by several wavelengths. To achieve tumor necrosis, it is better to use the

photosensitizer with the longest wavelength. With oxygen molecules present, this results in the release of various cytotoxic species, like singlet oxygen and other reactive oxygen species. Photodynamic therapy is both anti-angiogenic which damages tumor endothelial cells as well as dose-dependent immune responses. At high doses, it causes damage to the cellular membranes and the blood vessel which leads to recruitment of neutrophils and monocytes/macrophages and activation of pro-inflammatory cytokines like interleukin IL-1beta, IL-2, and tumor necrosis factor TNF-alpha. This results in the enhancement of the host immune system which plays an important role in secondary cytotoxicity and tumor control. Serum IL-6, a bile duct epithelium growth factor correlating with tumor burden in CC, decreases after PDT. The side effect of PDT is cutaneous photosensitivity [96]. Although not conclusive, but at its preliminary stage as discussed earlier, biliary cancers that express epidermal growth factor and angiogenesis have been correlated with poor prognosis. Erlotinib and EGFR tyrosine kinase inhibitor and bevacizumab, a vascular endothelial growth factor (VEGF) inhibitor, have been shown to have activity in biliary cancer. Inhibitors of epidermal growth factor receptor family, such as erlotinib, cetuximab, and lapatinib, were recently investigated. Furthermore, bortezomib (an inhibitor of proteasome), imatinib mesylate (an inhibitor of c-kit-R), bevacizumab (an inhibitor of VEGF), and sorafenib (a multiple kinase inhibitor), that blocks not only tyrosine kinase but also serine/threonine kinases along the RAS/RAF/MEK/ERK pathway, have been used. Early evidence of antitumor activity was seen, but the results are still too early and require further investigation [36].

13. Summary

Cholangiocarcinoma is a very deadly disease, which if diagnosed early and if the patient is subjected to a complete surgical resection may have an impact in long-term survival. Having said that, much progress has been made with multidisciplinary services, transplantation, aggressive surgical approach, and hopefully with new developments in technology and research; we hope to improve the survival rate.

Author details

Samuel Romeo Obiekwe^{1*}, Nathaly Suzett De La Roca² and Jean Saric³


1 Huntington Park Hospital, Los Angeles, USA

2 University of California, San Diego, USA

3 Department of Surgery, University of Bordeaux, France

*Address all correspondence to: sobiekwe@yahoo.com

IntechOpen

© 2018 The Author(s). Licensee IntechOpen. This chapter is distributed under the terms of the Creative Commons Attribution License (<http://creativecommons.org/licenses/by/3.0>), which permits unrestricted use, distribution, and reproduction in any medium, provided the original work is properly cited. 

References

- [1] Taylor-Robinson SD, Foster GR, Arora S, et al. Increase in primary liver cancer in the UK, 1979–94. *Lancet*. 1997; **350**:1142-1143
- [2] Patel T. Increasing incidence and mortality of primary intrahepatic cholangiocarcinoma in the United States. *Hepatology*. 2001; **33**:1353-1357
- [3] Klatskin G. Adenocarcinoma of the hepatic duct at its bifurcation within the porta hepatis: An unusual tumor with distinctive clinical and pathological features. *The American Journal of Medicine*. 1965; **38**:241-256
- [4] Strasberg SM. Resection of hilar cholangiocarcinoma. *HPB Surgery*. 1998; **10**:415
- [5] Zimmerman A. Tumors of the bile ducts-pathological aspects. In: Blumgart LH, editor. *Surgery of the Liver and Biliary Tract*. 3rd ed. Vol. 200. London: W.B. Saunders. pp. 953-975
- [6] Renard P, Boutron MC, Faivre J, et al. Biliary tract cancers in Cote d'Or (France): Incidence and natural history. *Journal of Epidemiology and Community Health*. 1987; **41**:344-348
- [7] Shahip Y, El-Sharag HB. The epidemiology of cholangiocarcinoma. *Seminars in Liver Disease*. 2004; **24**: 115-124
- [8] Khan SA, Taylor-Robinson SD, Toledano MD, et al. Changing international trends in mortality rates for liver, biliary and pancreatic tumors. *Journal of Hepatology*. 2002; **37**:806-813
- [9] Shaib YB, Davila JA, McGlynn K, et al. Rising incidence of intrahepatic cholangiocarcinoma in the United States: A true increase? *Journal of Hepatology*. 2004; **40**:472-477
- [10] Blechacz BR, Gores GJ. Cholangiocarcinoma. *Clinics in Liver Disease*. 2008; **12**(1):131-150
- [11] van Kaick G, Wesch H, Luhrs H, et al. Neoplastic diseases induced by chronic alpha-irradiation—Epidemiological, biophysical, and clinical results of the German Thorotrast Study. *Journal of Radiation Research (Tokyo)*. 1991; **32**(Suppl. 2):20-33
- [12] LaRusso NF, Shneider BL, Black D, et al. Primary sclerosing cholangitis: Summary of a workshop. *Hepatology*. 2006; **44**(3):746-764
- [13] Kaewpitoon N, Kaewpitoon SJ, Pengsaa P, et al. *Opisthorchis viverrini*: The carcinogenic human liver fluke. *World Journal of Gastroenterology*. 2008; **14**(5):666-674
- [14] Upatham ES, Vivyant V. *Opisthorchis viverrini* and opisthorchiasis: A historical review and future perspective. *Acta Tropica*. 2003; **88**(3):171-176
- [15] Lee CC, Wu CY, Chen GH. What is the impact of coexistence of hepatolithiasis on cholangiocarcinoma? *Journal of Gastroenterology and Hepatology*. 2002; **17**:1015-1020
- [16] Donato F, Gelatti U, Tagger A, et al. Intrahepatic cholangiocarcinoma and hepatitis C and B virus infection, alcohol intake, and hepatolithiasis: A case-control study in Italy. *Cancer Causes & Control*. 2001; **12**(10):959-964
- [17] Kobayashi S, Asano T, Yamaski M, et al. Risk of bile duct carcinogenesis after excision of extrahepatic bile ducts in pancreaticobiliary maljunction. *Surgery*. 1999; **126**(5):939-944
- [18] Watanabe Y, Toki A, Todani T. Bile duct cancer developed after cyst

- excision for choledochal cyst. *Journal of Hepato-Biliary-Pancreatic Surgery*. 1999;**6**(3):207-212
- [19] Soreide K, Korner H, Havnen J, et al. Bile duct cysts in adults. *The British Journal of Surgery*. 2004;**91**(12):1538-1548
- [20] Edil BH, Cameron JL, Reddy S, et al. Choledochal cyst disease in children and adults: A 30-year single institution experience. *Journal of the American College of Surgeons*. 2008;**206**(5):1000-1005
- [21] Mabrut JY, Bozio G, Hubert C, et al. Management of congenital bile duct cysts. *Digestive Surgery*. 2010;**27**(1):12-18
- [22] Ohta T, Nagakawa T, Ueno K, et al. Clinical experience of biliary tract carcinoma associated with anomalous union of the pancreatic ductal system. *The Japanese Journal of Surgery*. 1990;**20**:36-43
- [23] Tocchi A, Mazzoni G, Liotta G, et al. Late development of bile duct cancer in patients who had biliary-enteric drainage for benign disease: A follow-up study of more than 1,000 patients. *Annals of Surgery*. 2001;**234**:210-214
- [24] Callea F, Sergi C, Fabbretti G, et al. Precancerous lesions of the biliary tree. *Journal of Surgical Oncology*. Supplement. 1993;**3**:131-133
- [25] O'Shea M, Fletcher HS, Lara JF. Villous adenoma of the extrahepatic biliary tract: A rare entity. *The American Surgeon*. 2002;**68**:889-891
- [26] Yamamoto S, Kubo S, Hai S, et al. Hepatitis C virus infection as a likely etiology of intrahepatic cholangiocarcinoma. *Cancer Science*. 2004;**95**(7):592-595
- [27] El-Serag HB, Engels EA, Landgren O, et al. Risk of hepatobiliary and pancreatic cancers after hepatitis C virus infection: A population-based study of U.S. Veterans. *Hepatology*. 2009;**49**(1):116-123
- [28] Sorensen HT, Friis S, Olsen JH, et al. Risk of liver and other types of cancer in patients with cirrhosis: A nationwide cohort study in Denmark. *Hepatology*. 1998;**28**(4):921-925
- [29] Shaib YH, El-Serag HB, Nooka AK, et al. Risk factors for intrahepatic and extrahepatic cholangiocarcinoma: A hospital-based case-control study. *The American Journal of Gastroenterology*. 2007;**102**(5):1016-1021
- [30] Shaib YH, El-Serag HB, Davila JA, et al. Risk factors for intrahepatic cholangiocarcinoma in the United States: A case-control study. *Gastroenterology*. 2005;**128**(3):620-626
- [31] Grainge MJ, West J, Solaymani-Dodaran M, et al. The antecedents of biliary cancer: A primary care case-control study in the United Kingdom. *British Journal of Cancer*. 2009;**100**(1):178-180
- [32] Prawan A, Kukongviriyapan V, Tassaneeyakul W, et al. Association between genetic polymorphisms of CYP1A2, arylamine N-acetyltransferase 1 and 2 and susceptibility to cholangiocarcinoma. *European Journal of Cancer Prevention*. 2005;**14**(3):245-250
- [33] Khan SA, Thomas HC, Toledano MB, et al. p53 mutations in human cholangiocarcinoma: A review. *Liver International*. 2005;**25**:704-716
- [34] Liu XF, Zhang H, Zhu SG, et al. Correlation of p53 gene mutation and expression of p53 protein in cholangiocarcinoma. *World Journal of Gastroenterology*. 2006;**12**:4706-4709
- [35] Zheng J, Zhu YM. Expression of c-erbB-2 proto-oncogene in extrahepatic

cholangiocarcinoma and its clinical significance. *Hepatobiliary & Pancreatic Diseases International*. 2007;**6**:412-415

[36] Yoshikawa D, Ojima H, Iwasaki M, et al. Clinicopathological and prognostic significance of EGFR, VEGF, and HER2 expression in cholangiocarcinoma. *British Journal of Cancer*. 2008;**98**: 418-425

[37] Guedj N, Zhan Q, Perigny M, et al. Comparative protein expression profiles of hilar and peripheral hepatic cholangiocarcinomas. *Journal of Hepatology*. 2009;**51**:93-101

[38] Sitzmann J, Greene P. Perioperative predictors of morbidity following hepatic resection for neoplasm. *Annals of Surgery*. 1994;**219**:13-17

[39] Noun R, Jagot P, Farges O, et al. High preoperative serum alanine transferase levels: Effect on the risk of liver resection in child grade A cirrhotic patients. *World Journal of Surgery*. 1997;**21**:390-395

[40] Are C, Gonen M, DAngelica M, et al. Differential diagnosis of proximal biliary obstruction. *Surgery*. 2006;**140**: 756-763

[41] Dasgupta T, Brasfield R. Metastatic melanoma: A clinicopathologic study. *Cancer*. 1964;**15**:1323-1339

[42] El Rassi ZS, Mohsine RM, Berger F, et al. Endocrine tumors of the extrahepatic bile ducts: Pathological and clinical aspects, surgical management and outcome. *Hepato-Gastroenterology*. 2004;**51**:1295-1300

[43] Riopel MA, Klimstra DS, Godellas CV, et al. Intrabiliary growth of metastatic colonic adenocarcinoma: A pattern of intrahepatic spread easily confused with primary neoplasia of the biliary tract. *The American Journal of Surgical Pathology*. 1997;**21**:1030-1036

[44] Van Slyck EJ, Schuman BM. Lymphocytic lymphosarcoma of the gallbladder. *Cancer*. 1972;**30**:810-816

[45] Broome U, Olsson R, Loof L, et al. Natural history and prognostic factors in 305 Swedish patients with primary sclerosing cholangitis. *Gut*. 1996;**38**: 610-615

[46] Abdalian R, Heathcote EJ. Sclerosing cholangitis: A focus on secondary causes. *Hepatology*. 2006;**44**: 1063-1074

[47] Sasahira N, Kawabe T, Nakamura A, et al. Inflammatory pseudotumor of the liver and peripheral eosinophilia in autoimmune pancreatitis. *World Journal of Gastroenterology*. 2005;**11**:922-925

[48] Sperling RM, Koch J, Sandhu JS, et al. Recurrent pyogenic cholangitis in Asian immigrants to the United States: Natural history and role of therapeutic ERCP. *Digestive Diseases and Sciences*. 1997;**42**:865-871

[49] Nash JA, Cohen SA. Gallbladder and biliary tract disease in AIDS. *Gastroenterology Clinics of North America*. 1997;**26**:323-335

[50] Kim KP, Kim MH, Song MH, et al. Autoimmune chronic pancreatitis. *The American Journal of Gastroenterology*. 2004;**99**:1605-1616

[51] Sarin SK, Bhatia MU. Portal biliopathy in extrahepatic portal vein obstruction. *Indian Journal of Gastroenterology*. 1992;**2**:A82

[52] Johnson LW, Sehon JK, Lee WC, et al. Mirizzi's syndrome: Experience from a multi-institutional review. *The American Surgeon*. 2001;**67**:11-14

[53] Kawakatsu M, Vilgrain V, Zins M, et al. Radiological features of papillary adenoma and papillomatosis of the biliary tract. *Abdominal Imaging*. 1997;**22**:87-90

- [54] Cox CE, Davis-Allen A, Judson MA. Sarcoidosis. *The Medical Clinics of North America*. 2005;**89**:817-828
- [55] Howard TJ, Bennion RS, Thompson JE Jr. *Xanthogranulomatous cholecystitis*: A chronic inflammatory pseudotumor of the gallbladder. *The American Surgeon*. 1991;**57**:821-824
- [56] Batts KP. Ischemic cholangitis. *Mayo Clinic Proceedings*. 1998;**73**: 380-385
- [57] Albore-Saavedra J, Scoazec JC, Wittekind C, et al. Carcinoma of the gallbladder and extrahepatic bile ducts. In: Hamilton SR, Aaltonen LA, editors. *World Health Organization Classification of Tumours. Tumors of the Digestive System*. Lyon: International Agency for Research on Cancer Press; 2000. pp. 206-214
- [58] Jiao L, El-Desoky A, Seifalian A, et al. Effect of liver blood flow and function on hepatic indocyanine green clearance measured directly in a cirrhotic animal model. *The British Journal of Surgery*. 2000;**87**:568-574
- [59] Alvaro D. Serum and bile biomarkers for cholangiocarcinoma. *Current Opinion in Gastroenterology*. 2009;**25**:279-284
- [60] Bamrungphon W, Prempracha N, Bunchu N, et al. A new mucin antibody/enzyme-linked lectin sandwich assay of serum MUC5AC mucin for the diagnosis of cholangiocarcinoma. *Cancer Letters*. 2007;**247**:301-308
- [61] Sharma MP, Ahuja V. Aetiological spectrum of obstructive jaundice and diagnostic ability of ultrasonography: A clinician's perspective. *Tropical Gastroenterology*. 1999;**20**:167-169
- [62] Fritscher-Ravens A, Broering DC, Knoefel WT, et al. EUS-guided fine-needle aspiration of suspected hilar cholangiocarcinoma in potentially operable patients with negative brush cytology. *The American Journal of Gastroenterology*. 2004;**99**:45-51
- [63] Akamatsu N, Sugawara Y, Osada H, et al. Diagnostic accuracy of multidetector-row computed tomography for hilar cholangiocarcinoma. *Journal of Gastroenterology and Hepatology*. 2010;**25**:731-737
- [64] Park HS, Lee JM, Choi JY, et al. Preoperative evaluation of bile duct cancer: MRI combined with MR cholangiopancreatography versus MDCT with direct cholangiography. *AJR. American Journal of Roentgenology*. 2008;**190**:396-405
- [65] Park MS, Kim TK, Kim KW, et al. Differentiation of extrahepatic bile duct cholangiocarcinoma from benign stricture: Findings at MRCP versus ERCP. *Radiology*. 2004;**233**:234-240
- [66] Fritscher-Ravens A, Bohuslavizki KH, Broering DC, et al. FDG PET in the diagnosis of hilar cholangiocarcinoma. *Nuclear Medicine Communications*. 2001;**22**:1277-1285
- [67] Weber A, von Weyhern C, Fend F, et al. Endoscopic transpapillary brush cytology and forceps biopsy in patients with hilar cholangiocarcinoma. *World Journal of Gastroenterology*. 2008;**14**: 1097-1101
- [68] Baron TH, Harewood GC, Rumalla A, et al. A prospective comparison of digital image analysis and routine cytology for the identification of malignancy in biliary tract strictures. *Clinical Gastroenterology and Hepatology*. 2004;**2**:214-219
- [69] Yin XY, Yan G, Peng JX, et al. The clinical values of methylation status of P16, APC genes in bile in diagnosis of malignant obstructive jaundice. In: *Gastrointestinal Cancer Symposium*

Proceedings; San Francisco, California, USA; 2011. p. 91

[70] Grandadam S, Compagnon P, Arnaud A, et al. Role of preoperative optimization of the liver for resection in patients with hilar cholangiocarcinoma type II. *Annals of Surgical Oncology*. 2010;**17**:3155-3161

[71] Nagino M, Takada T, Miyazaki M, et al. Preoperative biliary drainage for biliary tract and ampullary carcinomas. *Journal of Hepato-Biliary-Pancreatic Surgery*. 2008;**15**:25-30

[72] Hwang S, Lee SG, Ko GY, et al. Sequential preoperative ipsilateral hepatic vein embolization after portal vein embolization to induce further liver regeneration in patients with hepatobiliary malignancy. *Annals of Surgery*. 2009; **249**:608-616

[73] Nagino M, Nimura Y, Hayakawa N, et al. Logistic regression and discriminant analyses of hepatic failure after liver resection for carcinoma of the biliary tract. *World Journal of Surgery*. 1993;**17**:250-255

[74] Jarnagin WR, Fong Y, DeMatteo RP, et al. Staging resectability, and outcome in 225 patients with hilar cholangiocarcinoma. *Annals of Surgery*. 2001;**234**:507-519

[75] Weber SM, DeMatteo RP, Fong Y, et al. Staging laparoscopy in patients with extrahepatic biliary carcinoma. Analysis of 100 patients. *Annals of Surgery*. 2002;**235**:392-399

[76] Capussotti L, Vigano L, Ferrero A, et al. Local surgical resection of hilar cholangiocarcinoma: Is there still a place? *HPB: The Official Journal of the International Hepato Pancreato Biliary Association*. 2008;**10**(3):174-178

[77] Hadjis NS, Blenkarn JI, Alexander N, et al. Outcome of radical surgery in

hilar cholangiocarcinoma. *Surgery*. 1990;**107**(6):597-604

[78] Neuhaus P, Jonas S, Bechstein WO, et al. Extended resections for hilar cholangiocarcinoma. *Annals of Surgery*. 1999;**230**(6):808-818; discussion 19

[79] Pichlmayr R, Bretschneider HJ, Kircchner E, et al. Ex-situ operation an der Leber. Eine neue Moeglichkeit in der Leber chirurgie. *Langenbecks Archiv für Chirurgie*. 1988;**373**(2):122-126

[80] Bismuth H, Nakache R, Diamond T. Management strategies in resection for hilar cholangiocarcinoma. *Annals of Surgery*. 1992;**215**:31-38

[81] Kitagawa Y, Nagino M, Kamiya J, et al. Lymph node metastasis from hilar cholangiocarcinoma: Audit of 110 patients who underwent regional and paraaortic node dissection. *Annals of Surgery*. 2001;**233**:385-392

[82] Nagino M, Nimura Y, Nishio H, et al. Hepatectomy with simultaneous resection of the portal vein and hepatic artery for advanced perihilar cholangiocarcinoma: An audit of 50 consecutive cases. *Annals of Surgery*. 2010;**252**:115-123

[83] Hemming AW, Mekeel K, Khanna A, et al. Portal vein resection in the management of hilar cholangiocarcinoma. *Journal of the American College of Surgeons*. 2011; **212**(4):604-613; discussion 613-6

[84] Mantel HT, Rosen CB, Heimbach JK, et al. Vascular complications after orthotopic liver transplantation after neoadjuvant therapy for hilar cholangiocarcinoma. *Liver Transplantation*. 2007;**13**:1372-1381

[85] Rea DJ, Heimbach JK, Rosen CB, et al. Liver transplantation with neoadjuvant chemoradiation is more effective than resection for hilar

- cholangiocarcinoma. *Annals of Surgery*. 2005;**242**:451-458; discussion 8-61
- [86] Hong JC, Jones CM, Duffy JP, et al. Comparative analysis of resection and liver transplantation for intrahepatic and hilar cholangiocarcinoma: A 24-year experience in a single center. *Archives of Surgery*. 2011;**146**:683-689
- [87] Deziel DJ, Kiel KD, Kramer TS, et al. Intraoperative radiation therapy in biliary tract cancer. *American Journal of Surgery*. 1988;**54**:402-407
- [88] McMasters KM, Tuttle TM, Leach SD, et al. Neoadjuvant chemoradiation for extrahepatic cholangiocarcinoma. *American Journal of Surgery*. 1997;**174**:605-609
- [89] Pitt HA, Nakeeb A, Abrams RA, et al. Perihilar cholangiocarcinoma. Postoperative radiotherapy does not improve survival. *Annals of Surgery*. 1995;**221**:788-797; discussion 797-8
- [90] Busse PM, Stone MD, Sheldon TA, et al. Intraoperative radiation therapy for biliary tract carcinoma: Results of a 5-year experience. *Surgery*. 1989;**105**:724-733
- [91] Kamada T, Saitou H, Takamura A, et al. The role of radiotherapy in the management of extrahepatic bile duct cancer: An analysis of 145 consecutive patients treated with intraluminal and/or external beam radiotherapy. *International Journal of Radiation Oncology, Biology, Physics*. 1996;**34**:767-774
- [92] Traynor O, Castaing D, Bismuth H. Left intrahepatic cholangio-enteric anastomosis (round ligament approach): An effective palliative treatment for hilar cancer. *The British Journal of Surgery*. 1987;**74**:952-954
- [93] Jagannath P, Bhansali MS, Desouza LJ, et al. Palliative segment III biliary bypass (left cholangio-jejunostomy) in malignant block at porta hepatis. *Indian Journal of Gastroenterology*. 1992;**11**:71-72
- [94] Abraham NS, Barkun JS, Barkun AN. Palliation of malignant biliary obstruction: A prospective trial examining impact on quality of life. *Gastrointestinal Endoscopy*. 2002;**56**(6):835-841
- [95] Nordback IH, Pitt HA, Coleman J, et al. Unresectable hilar cholangiocarcinoma: Percutaneous versus operative palliation. *Surgery*. 1994;**115**:597-603
- [96] Huang Z, Xu H, Meyers AD, et al. Photodynamic therapy for treatment of solid tumor potential and technical challenges. *Technology in Cancer Research & Treatment*. 2008;**7**:309-320
- [97] Tsao J, Nimura Y, et al. Management of hilar cholangiocarcinoma. *Annals of Surgery*. 2000;**323**(2):166-174