

We are IntechOpen, the world's leading publisher of Open Access books Built by scientists, for scientists

4,800

Open access books available

122,000

International authors and editors

135M

Downloads

Our authors are among the

154

Countries delivered to

TOP 1%

most cited scientists

12.2%

Contributors from top 500 universities



WEB OF SCIENCE™

Selection of our books indexed in the Book Citation Index
in Web of Science™ Core Collection (BKCI)

Interested in publishing with us?
Contact book.department@intechopen.com

Numbers displayed above are based on latest data collected.
For more information visit www.intechopen.com



Open Conversion after EVAR: Indications and Technical Details

Andrea Siani, Federico Accrocca,
Tommaso Castrucci, Gianluca Smedile, Giulia Ianni,
Stefano Corona, Gennaro De Vivo and
Stefano Bartoli

Additional information is available at the end of the chapter

<http://dx.doi.org/10.5772/intechopen.78017>

Abstract

Endovascular aortic aneurysm repair (EVAR) is widely used for the treatment of abdominal aortic aneurysms. Complications secondary to EVAR are also treated with endovascular techniques. When this is not applicable, open surgical repair is mandatory. Surgical re-intervention following EVAR is considered to be more demanding compared with primary open repair and it is related to the type of endograft implanted (infra renal vs. suprarenal fixation), to the indications for surgical conversion (infection vs. non infection), to the setting of presentation (elective vs. emergency) and type of conversion (total vs. partial). While technically challenging, delayed open conversion of EVAR can be accomplished with low morbidity and mortality in both the elective and emergent settings. These results reinforce the justification for long-term surveillance of endografts following EVAR.

Keywords: late conversion, EVAR, open conversion

1. Introduction

Despite endovascular aortic aneurysm repair (EVAR) has changed the management of abdominal aortic aneurysms (AAA), reducing the perioperative morbidity and mortality, it seems to be associated with an increased rate of late secondary re-interventions. Proportions of patients with postoperative complications in need for secondary interventions range from 12.5 to 43% and secondary endovascular approach are generally considered as the first line treatment. Stent graft failure secondary to endoleaks, stent graft migration, endotension

and/or sac enlargement, infection or stent graft tear and fracture, continue to be a persistent problem that can result in aneurysm rupture. Indeed large cohorts of studies have reported rupture rates between 0.5 and 1.2% per patient per year after EVAR.

Open conversion is considered the last line therapy for several EVAR complications as endoleaks unfit for endovascular management, stent graft infection, and aneurysm rupture and stent graft thrombosis.

Surgical re-intervention following EVAR is considered to be more demanding compared with primary open repair and it is related to the type of endograft implanted (infra renal vs. suprarenal fixation), to the indications for surgical conversion (infection vs. non infection), to the setting of presentation (elective vs. emergency) and type of conversion (total vs. partial) [1, 2].

2. Indications to open conversion

The need for conversion from endovascular repair to open results from:

- Procedural and technical errors
- Unsuitable aortic morphology and device failures

Predictors of clinical failure or need for re-intervention seem to be due to some anatomical features of AAA as:

- Large aneurysm size
- Diffuse neck thrombus or calcification
- Neck angulation $>45-70^\circ$
- Conical aortic neck and an aortic neck with diameter > 28 mm
- Short infra renal neck (<10 mm)
- Common iliac artery diameter > 20 mm
- Persistent type II endoleak
- Age > 80 years and female gender

Despite narrow aortic bifurcation (<20 mm) or small iliac diameter are currently considered as no contraindications for EVAR and are treated by means of the use of low-profile device, the high incidence of late and persistent Type II endoleaks could be affect an increase of sac enlargement in the future and need for redo-endovascular treatment or late open conversion.

Some specifically anatomic situation can be associated with high incidence of late conversion:

- Chimney endovascular procedure used to increase the sealing zone in cases of insufficient neck for endovascular approach, especially when distance between the target vessel which needs chimney graft implantation and first aortic side branch above the covered stent is <15 mm, in emergent conditions to treat type IA endoleak or when three visceral vessels are covered.
- Distal complex procedure to achieve a safe landing zone for sealing as iliac side branch (common iliac artery <50 mm in length, iliac diameter bifurcation <15 mm)
- Fenestrated and branched endografts

During follow up the significant risk for rupture were proximal type I endoleak, type III endoleak, migration with kinking of the endograft, in contrast with distal type I endoleak or limb thrombosis that were present but statistically not significant. Many authors reported increased rupture risk in patients with persistent type II endoleak. Regarding the correlation between endotension and device, in experimental model e-PTFE reduces sac pressure more effectively than Dacron, but some clinical studies observed that endograft with PTFE produced a high rate of sac enlargement, probably due to inflammatory reaction with cytokine production (post inflammatory syndrome).

Currently the surgical indications for conversion to open repair are:

- Aneurysmal rupture unfit for endovascular treatment
- Sac enlargement due to migration and endoleak (type I, II, III or endotension) unfit for endovascular approach
- Infection with or without aortoenteric fistula
- Late graft or graft limb thrombosis

3. Clinical presentation

The clinical findings are determined by the cause of failure. These may be:

- No symptoms (sac enlargement)
- Abdominal pain with radiation to the back and flanks, hypotension and shock in cases of rupture
- Leg ischemia due graft/limb thrombosis
- Fever, leukocytosis and gastrointestinal bleeding in case of infection

3.1. Diagnostic tests

Include Duplex ultrasound, and angio CT scan. Leukocyte scintigraphy, FDG-PET or SPECT plays an important role in the evaluation of patients with suspected infection.

Product name	Fixation location	Stent expansion	Stent material	Graft material
Treo	Suprarenal, infrarenal	Self-expanding	Nitinol	Tightly woven polyester
Zenith alpha abdominal	Suprarenal	Self-expanding	Nitinol	Woven polyester
Zenith fenestrated AAA endovascular graft (distal bifurcated body)	—	Self-expanding	Stainless steel	Woven polyester
Zenith fenestrated AAA endovascular graft (one proximal seal stents)	Suprarenal	Self-expanding	Stainless steel	Woven polyester
Zenith fenestrated AAA endovascular graft (two proximal seal stents)	Suprarenal	Self-expanding	Stainless steel and nitinol	Woven polyester
Zenith flex with Z-Trak	Suprarenal	Self-expanding	Stainless steel and nitinol	Woven polyester
Incraft AAA stent graft system	Suprarenal	Self-expanding	Nitinol	Woven polyester
AFX endovascular AAA system—AFX2 bifurcated endograft system	Fixation at bifurcation, infrarenal, or suprarenal configurations for seal	Self-expanding	Cobalt chromium alloy	Duraply multilayer ePTFE
Ovation iX abdominal stent graft system	Suprarenal	Nonexpansive polymer-filled ring*	Nitinol	PTFE
Gore excluder AAA endoprosthesis featuring C3 delivery system	Infrarenal	Self-expanding	Nitinol	ePTFE
E-tegra stent graft system	Suprarenal	Self-expanding	Nitinol	Woven polyester
E-vita abdominal XT stent graft system	Suprarenal	Self-expanding	Nitinol	Woven polyester
Altura endograft system	Suprarenal	Delivery system controlled	Nitinol	Polyester
Aorfix AAA endovascular stent graft	Infrarenal, transrenal	Self-expanding	Nitinol	Polyester
Endurant AAA stent graft system	Suprarenal	Self-expanding	Nitinol	Woven polyester
Endurant II AAA stent graft system	Suprarenal	Self-expanding	Nitinol	Woven polyester
Endurant II AUI stent graft system	Suprarenal	Self-expanding	Nitinol	Woven polyester
Endurant IIs AAA stent graft system	Suprarenal	Self-expanding	Nitinol	Woven polyester
Anaconda	Infrarenal	Self-expanding	Nitinol	Woven polyester
Fenestrated anaconda	Suprarenal	Self-expanding	Nitinol	Woven polyester

Table 1. Currently available endografts on the market.

3.2. Treatment

3.2.1. Type of grafts

The type of endoprosthesis and its relationship with aortic neck and renal arteries and its proximal attachment, infra renal or suprarenal, significantly affects the surgical strategy (**Table 1**). We can basically define four clinical scenarios:

1. Endograft with infrarenal fixation
2. Endograft with suprarenal fixation
3. Endograft with visceral vessel involvement (Chimney, F-EVAR, B-EVAR)
4. Sealing technology endograft explant

4. Operative procedure

4.1. Infra renal fixation

In cases of endoprosthesis with internal fixation, the surgical removal is relatively easy. The results mainly depend on the indication of conversion. In cases of total conversion, the abdominal aorta can be approached with standard trans peritoneal approach. After mobilization of the 3rd and 4th duodenal portion and Treitz ligament dissection the posterior peritoneum is prepared and the aneurysm neck carefully dissected. In selected cases, the total conversion can be due to type IA endoleak. In this setting a more proximal dissection and suprarenal aortic control can be advocate. The periaortic inflammation of aortic wall due to endoprosthesis needs of a minimal but sometimes carefully dissection. The distal control depends to the aneurysm extension. Although the presence of iliac limb inside the iliac arteries seems to suggest the placement of iliac clamp only after removing of the same iliac limbs to avoid any damage on the iliac wall. In some cases the use of endoclamping with Foley or Fogarty catheters could be useful.

The sac was opened longitudinally, the thrombus or hygromas or both removed and then all the lumbar arteries were sutured. The inferior mesenteric artery can be ligated or re-implanted on the basis of back bleeding. The final step is the restoration of aortic flow with tube or bifurcated graft. When the iliac limb is too difficult to remove, some authors suggest the insertion of the vascular graft on the iliac limb.

In cases of semi conversion (**Figure 1**), to treat a type II endoleak, the infrarenal aorta was prepared. A preventive banding and reshaping of the neck with a Teflon band to consolidate the graft to the aortic neck with four or five stitches binding together the Teflon, the aortic wall, and the endograft was carried out. When the proximal neck was secured, the sac was opened longitudinally and all the lumbar arteries were ligated. The sac was sutured leaving some fenestrations to avoid repressurization with the consequent risk of expansion and rupture. In some cases the proximal neck can be approached by means of less aggressive

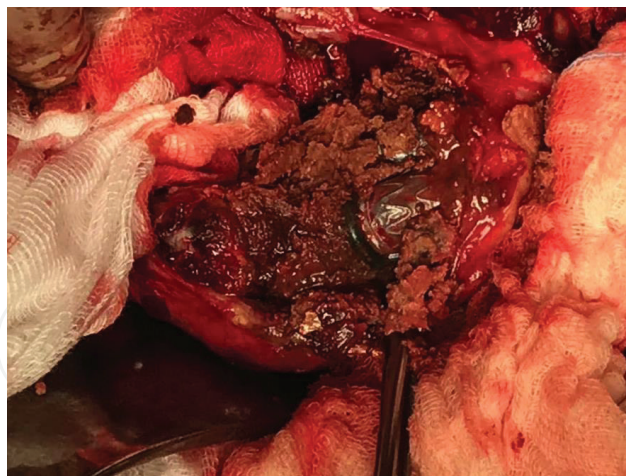


Figure 1. Type II EL with sac enlargement in patient treated 4 years early with 26 mm ovation prime endograft the sac was opened longitudinally, and the thrombus removed.

standard retroperitoneal approach through the 11th intercostal space, without rib resection or reflection of the left kidney. In cases of iliac artery involvement the standard laparotomy is mandatory. In all the cases, drainage is left in place from 3 days and until only traces of chyle are present.

4.2. Suprarenal fixation

In cases of suprarenal fixation, the presence of anchoring metal barbs, generally extended over the superior mesenteric artery lead to complete control of supra celiac aorta. The supra celiac aorta can be controlled by means of classical surgical approach or with endovascular aortic balloon placed from trans axillary or trans femoral approach.

In case of supra celiac control, the aorta was approached by means of trans peritoneal route. After resection of left triangular ligament and retraction of the left lobe of the liver, the gastrohepatic omentum is opened. After splitting of the diaphragms crura and identification of nasogastric tube with the finger, the aorta can be clamped. Medial visceral mobilization by standard full-length midline incision extended to the left towards the top of 7th rib to allow an anterior thoracotomy of 8–10 cm with short radial phrenotomy lead to excellent exposure and safe dissection of the entire visceral aorta.

To reduce the morbidity and mortality, an endovascular control of proximal aorta seems to be better. Through axillary approach an aortic balloon (**Table 2**) can be placed at renal level. In our experience trans femoral approach seems to be better, avoid the problem due to large sheets placed in subclavian artery (vertebral occlusion, embolism to posterior cerebral circulation, arm ischemia) (**Figure 2**). In cases of small diameter of axillary artery, surgical approach to proximal axillary artery below the clavicle must be carried out to place a large introducer sheath without problems (**Figure 3**). After proximal balloon was inflated, the aneurysm was open, back bleeding from iliac arteries and lumbar /IMA stopped by means of ligature and iliac clamping or endoclamping. The free flow is normally fixed in aorta due to re epithelization. The infolding of the endoprosthesis, as suggest by some authors with transacted syringe

Product name	Size (F)	Recommended introducer size (F)	Guidewire diameter (inch)	Maximum inflated balloon diameter (mm)
Berenstein occlusion balloon catheter	6	8	0.038	8.5, 11.5
Equalizer balloon catheter	7	14–16, 40-mm via cut down only	0.038	20, 27, 33, 40
Standard occlusion balloon catheter	7	9	0.038	11.5
Coda balloon catheter	10	14	0.035	46
Coda LP balloon catheter	9	12	0.035	32
Q50 plus stent graft balloon catheter	8	12	0.038 or smaller	50
Reliant stent graft balloon catheter	8	12	0.038 or smaller	

Table 2. Aortic occlusion balloons.

is speculative and hazardous. We prefer to perform a cut below the anchoring barbs, leaving the free flow in place. A Dacron graft is sutured in an end-to-end fashion, passing the stitches through the aorta and the first covered stent in order to minimize the risk of late complications. In case of necessary total endograft excision (infection), a thoracoabdominal approach must be planned. Some new generation endoprosthesis, as Ovation prime, have a very long

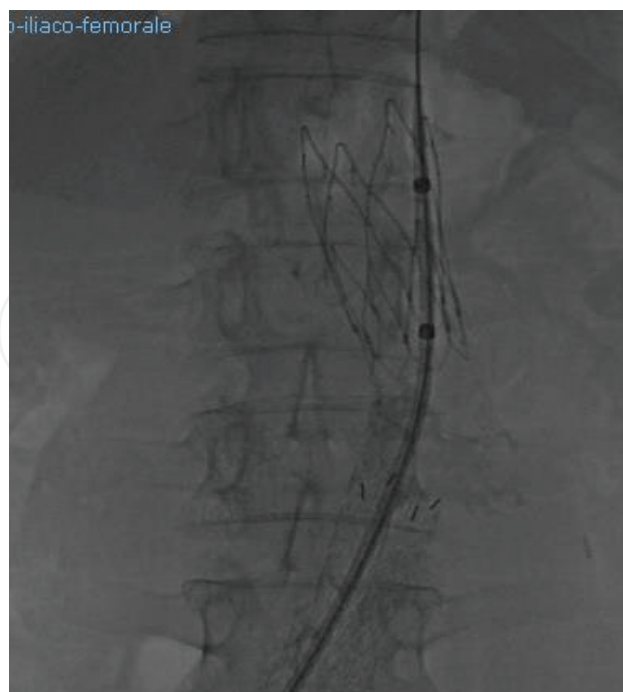

Figure 2. Aortic occlusion balloon (coda 32 mm) at level of Freeflow of ovation 26 mm through femoral approach by means of 12 Fr dry seal sheath.

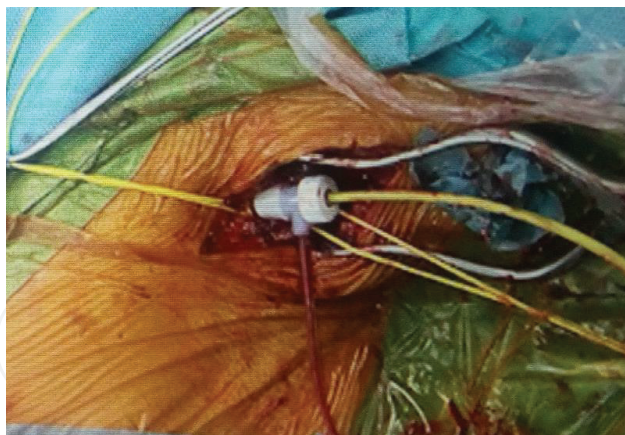

Figure 3. Axillary approach (12 FR introducer sheath-coda LP balloon catheter).

free flow. In this case a partial salvage of the graft can be performed anastomosing the surgical graft with the proximal part of endograft, between two polymer rings or above the first.

In cases of more proximal endograft procedure as chimney, F-EVAR or B-EVAR, or in presence of endoanchor, thoracoabdominal approach or medial visceral rotation must be performed [3–6].

Medial visceral rotation has been developed to obtain adequate exposure of para renal and suprarenal aorta avoiding the thoracic approach. The preferred route for medial visceral rotation is a standard midline trans-abdominal incision. Incising the left lateral peritoneal reflection allows mobilization of the descending and, if necessary, sigmoid colon. The peritoneal incision is carried cephalad through the phrenocolic and lineorenal ligaments. A plane is developed between the pancreas and Gerota's fascia. The descending colon, pancreas, spleen, and stomach are then rotated anteriorly and medially, leaving the left renal vein, ureter, left kidney, and adrenal gland in situ. The triangular ligament and left lobe of liver are freed. All of abdominal aorta is now exposed from the diaphragm to the bifurcation. Resection of median arcuate ligament and separation of the muscle fibers of the diaphragm expose the distal thoracic aorta within the lower mediastinum. The origin of celiac trunk and superior mesenteric arteries may be freed from the surrounding autonomic ganglia tissue. The aortic cross clamping is performed above the superior mesenteric artery or celiac trunk, according to the extension of the free flow. A longitudinal arteriotomy is then performed into the anterolateral wall of the aorta, starting from the origin of renal arteries for a sufficient length to allow a safe free flow remove avoid any intimal lesion. After free-flow extraction, the longitudinal aortotomy is closed with 4/0 running polypropylene suture, the visceral arteries and aorta flushed and the clamp placed in infrarenal position to perform a standard aorto-aortic substitution. In cases in which a long renal or visceral ischemic time is expected, a renal protection by means of cold perfusion (4°C lactated Ringer's solution).

In cases of thoracoabdominal approach an incision through the four to eight intercostal spaces is employed according to the extension of Chimney, F/B-EVAR. Generally a thoracophrenolaparotomy in the seventh or eighth intercostal spaces is carried out. After posterior section of the rib, the pleural space I entered after single right-lung ventilation is initiated. After careful

isolation of thoracic aorta, avoiding lesion on vagus nerve or esophageous wall, a limited circumferential section of the diaphragm is carried out, sparing the phrenic center to avoid paralysis of the left hemi-diaphragm and respiratory failure in the postoperative period. The upper abdomen is approached via trans peritoneal approach. The retro peritoneum entered lateral to the colon. A medial visceral rotation is carried out. The spleen, left colon and left kidney can be retracted anteriorly and to the right. Special care must be taken when isolating the left renal artery (retro aortic renal vein). After the section of left diaphragmatic pillars, and peritoneal ganglia division, the aorta is exposed from thoracic to abdominal bifurcation.

At this point, surgical cannulation of femoral artery (14 FR) and intrapericardial cannulation of left superior pulmonary vein (20 FR) are carried out to start a left heart bypass pump. The LHBP is started at 1500–2500 ml/min with an ACT > 200", with 35°C until the clamp was removed and LHBP stopped. After aortic clamping and incision, the endoprosthesis and components were removed. The backflow from intercostal arteries are temporarily stopped with 3 or 4 F occlusion balloon catheters. To prevent paraplegia, an aggressive policy of intercostal arteries reimplantation must be carried out. The visceral arteries (renal, superior mesenteric and celiac trunk) are perfused by means of 9 F Pruitt occlusion-perfusion catheters with oxygenated isotherm blood at 500 ml/h or 4°C lactated Ringer's solution.

4.3. Sealing explant technology

Regarding explanation of polymer sealing based technology endografts, few cases have been described, mostly for infection. After opening the aneurysm sac, the graft has been easily removed without extensive dissection of aortic neck. After removal of endobag, the clamp is placed in infrarenal position and perfusion is restored with interposition of Dacron graft. The Nellix explant seems to be a straightforward procedure compared to the removal of a conventional endograft with suprarenal fixation (temporary suprarenal clamping, lack of penetrating components in the juxta and infrarenal aorta).

4.4. Emergency conversion

Rupture after EVAR has been estimated to be 0.9–1.2% with a mortality rate of 30% in emergency situation. Patients submit to open conversion appeared to be older, with severe comorbidities (coronary disease, chronic renal failure). In emergency patients received more frequently a supra mesenteric endovascular or surgical control, renal and visceral cross clamp times were longer and the blood loss greater. So despite good results in literature, emergency surgical conversion due to AAA rupture especially in cases of endograft with suprarenal fixation or infection are associated with low results and high morbidity and mortality rate [7, 8].

4.5. Special situation

4.5.1. Open conversion after EVAR for graft infection

The endograft infection is rare, with an incidence of 0.2–0.7%. Predominant microorganism is *Staphylococcus* and *Streptococcus* species, and is often associated with aortoenteric fistula or erosion. Generally it is observed in emergency conditions. Currently, graft infections are

classified as low-grade and high-grade infections. Low-grade infections occur later and are caused by less virulent bacteria (coagulase negative staphylococci, CNS) and clinical symptoms are generally non-specific. High-grade infections occur earlier, are caused by more aggressive bacteria and associated with signs of sepsis, graft thrombosis, septic embolism or GIT erosion with bleeding. In elective condition current imaging modalities to diagnose infection are angioCT scan. Relatively new techniques are fluorodeoxyglucose-positron emission tomography (FDG-PET) or SPECT. After proximal control (surgical or endovascular) and duodenum mobilization by means of intestinal derotation, vascular reconstruction options include:

- Extra-anatomic bypass and aortic stump: after endograft explanation, an axillo-byfemoral bypass graft is performed. Results of extra atomic approach were disappointing because of high mortality rates, mostly due to aortic stump blowout and failure of the extra-anatomic graft due to thrombosis and reinfection. Adequate closure of aortic stump is essential, but can raise quite a challenge because of the inflamed tissue and fragile aortic wall. Several techniques have been proposed to ensure stump integrity such as double plane sutures, use of paravertebral fascia, use of epiplon or omental wrapping.

Extra-anatomic approach seems to be preferable in case of high-grade infection, with massive contamination of retroperitoneal space.

- In situ reconstruction:
 1. Allografts
 2. Autologous vein grafts (NAIS) with femoropopliteal vein in various configuration.
 3. Antimicrobial grafts (rifampin-soaked polyester)

Many authors suggest to place a cuff or endoprosthesis as bridge therapy to achieve a bleeding control and to perform a surgical conversion in semi-elective condition, especially in cases of a reconstruction performed with superficial femoral veins. Literature review evidence such as stent graft infection with graft excision has a mortality rate ranging between 36 and 56% [9–11].

4.5.2. *Graft or limb thrombosis*

Severe iliac artery angulation, narrow aortic bifurcation (<20 mm) and small graft limb diameter can predispose to endograft limb stenosis. In some cases limb graft occlusion seems due to complications at the femoral artery level due to thrombosis or dissection after percutaneous approach (Prostar XL or Proglide System). It is more frequent in tortuous iliac anatomy, in presence of pre-existing iliac stenosis and in unsupported endograft. For endograft limb occlusion treatment depends on the clinical manifestations. In case of mild or absent symptoms, a conservative approach could be desirable. However in most cases an endovascular approach or surgical reintervention is required. If occlusion has occurred in recent period (<48 h), the thrombolysis/thromboaspiration and endovascular treatment of the cause of limb occlusion (stenosis, kinking) seems to be the best treatment. In cases of late symptomatic occlusion a surgical approach by means of extra atomic bypass graft (femoro-femoral or axillo-femoral) seems to be the best treatment.

In cases of acute aortic thrombosis bilateral embolectomy with Fogarty catheters and relining with new endoprosthesis (aorto-uni-iliac and femoro-femoral bypass or use of two iliac leg graft) seems to be the treatment of choice.

Direct aortic reconstruction (graft excision or semi conversion and aortobifemoral bypass graft) or extra-anatomic approach with femoro-femoral or axillo-femoral bypass grafts seems to be feasible only in selected cases [12].

4.6. Complications

Because most operations for conversion of endovascular to open repair require suprarenal clamping in high-risk patients, the complication rate is higher as compared to open repair and include:

Cardiac complications, hemorrhage, iatrogenic injuries, renal failure, distal embolization, gastrointestinal and respiratory complications. Moreover the incidence of late complications as pseudo aneurysms as well infection of the graft was observed with an incidence of 1.4% [13–18].

5. Summary

Open conversion after EVAR for AAA are feasible but carry out an high risk of complications. With a large numbers of endografts implanted worldwide, the issue of late conversion to open repair will increase significantly in the near future. The future incidence of late conversion of endografts is changing. With increasing off label use, the limitations of graft design are being stretched and redefined. As interventionalists become more comfortable with EVAR devices and use devices in anatomy that is outside the instructions for use, we can expect to have inferior outcomes compared with data from IDE trials that may predispose some patients to late conversion. Mortality for elective late EVAR AAA-related conversion is not significantly different than primary open repair but is technically more challenging. Endovascular surveillance may identify late complications that require removal and justifies continued monitoring. Early elective conversion of EVAR for type I and type III endoleak or migration that cannot be treated with endovascular procedures may improve outcomes. The mortality rate for conversion in the setting of rupture or infection remains very high [19-23].

Author details

Andrea Siani*, Federico Accrocca, Tommaso Castrucci, Gianluca Smedile, Giulia Ianni, Stefano Corona, Gennaro De Vivo and Stefano Bartoli

*Address all correspondence to: andreasiani@yahoo.it

Vascular, Endovascular and Emergency Vascular Surgery Unit, "S.Eugenio" Hospital, Rome, Italy

References

- [1] Klonaris C, Lioudaki S, Katsargyris A, Psathas E, Kouvelos G, Doulaptsis M, et al. Late open conversion after failed endovascular aortic aneurysm repair. *Journal of Vascular Surgery*. 2014 Feb;**59**(2):291-297
- [2] Mangialardi N, Ronchey S, Orrico M, Serrao E, Alberti V, Fazzini S, et al. Surgical conversion with graft salvage as a definitive treatment for persistent type II endoleak causing sac enlargement. *Journal of Vascular Surgery*. 2015 Dec;**62**(6):1437-1441
- [3] Brinster CJ, Fairman RM, Woo EY, Wang GJ, Carpenter JP, Jackson BM. Late open conversion and explantation of abdominal aortic stent grafts. *Journal of Vascular Surgery*. 2011 Jul;**54**(1):42-46
- [4] Harris PL, Vallabhaneni SR, Desgranges P, Becquemin JP, van Marrewijk C, Laheij RJ. Incidence and risk factors of late rupture, conversion, and death after endovascular repair of infrarenal aortic aneurysms: The EUROSTAR experience. European collaborators on stent/graft techniques for aortic aneurysm repair. *Journal of Vascular Surgery*. 2000 Oct;**32**(4):739-749
- [5] Lipsitz EC, Ohki T, Veith FJ, Suggs WD, Wain RA, Rhee SJ, et al. Delayed open conversion following endovascular aortoiliac aneurysm repair: Partial (or complete) endograft preservation as a useful adjunct. *Journal of Vascular Surgery*. 2003 Dec;**38**(6):1191-1198
- [6] Chaar CI, Eid R, Park T, Rhee RY, Abu-Hamad G, Tzeng E, et al. Delayed open conversions after endovascular abdominal aortic aneurysm repair. *Journal of Vascular Surgery*. 2012 Jun;**55**(6):1562-1569
- [7] Coppi G, Gennai S, Saitta G. Treatment of ruptured abdominal aorta aneurysm after endovascular abdominal aortic repair. A comparison with patients without prior treatment. *Journal of Vascular Surgery*. 2009;**49**(3):582-588
- [8] Metha M, Paty PS, Roddy SP. Treatment options for delayed AAA rupture following endovascular repair. *Journal of Vascular Surgery*. 2011;**53**(1):14-20
- [9] Menna D, Capoccia L, Sirignano P, Esposito A, Rossi M, Speziale F. Infective etiology affects outcomes of late open conversion after failed endovascular aneurysm repair. *Journal of Endovascular Therapy*. 2015 Feb;**22**(1):110-115
- [10] Kelso RL, Lyden SP, Butler B, Greenberg RK, Eagleton MJ, Clair DG. Late conversion of aortic stent grafts. *Journal of Vascular Surgery*. 2009;**49**(3):589-595
- [11] Speziale F, Sbarigia E, Capoccia L, Menna D, Esposito A. Graft infection after EVAR. In: Pratesi C, Pulli R, editors. *Management of Complications after EVAR and TEVAR*. Torino: Edizioni Minerva Medica; 2012. pp. 224-236
- [12] Cochennec F, Bacquemin JP, Desgranges P, et al. Limb graft occlusion following EVAR: Clinical pattern, outcomes and predictive factors of occurrence. *European Journal of Vascular and Endovascular Surgery*. 2007;**34**:59

- [13] Turney EJ, Steenberge SP, Lyden SP, Eagleton MJ, Srivastava SD, Sarac TP, et al. Late graft explants in endovascular aneurysm repair. *Journal of Vascular Surgery*. 2014 Apr;**59**(4):886-893
- [14] Ferrero E, Ferri M, Viazzo A, Pecchio A, Berardi G, Piazza S, et al. Open conversion after endovascular aortic aneurysm repair: A single-center experience. *Annals of Vascular Surgery*. 2013 Oct;**27**(7):856-864
- [15] Perini P, de Troia A, Tecchio T, Azzarone M, Bianchini Massoni C, Salcuni P, et al. Infra-renal endograft clamping in late open conversions after endovascular abdominal aneurysm repair. *Journal of Vascular Surgery*. 2017 Oct;**66**(4):1048-1055
- [16] Maitrias P, Kaladji A, Plissonnier D, Amiot S, Sabatier J, Coggia M, et al. Treatment of sac expansion after endovascular aneurysm repair with obliterating endoaneurysmorrhaphy and stent graft preservation. *Journal of Vascular Surgery*. 2016 Apr;**63**(4):902-908. DOI: 10.1016/j.jvs.2015.10.059
- [17] Botsios S, Bausback Y, Piorkowski M, Werner M, Branzan D, Scheinert D, et al. Late open conversion after endovascular aneurysm repair. *Interactive Cardiovascular and Thoracic Surgery*. 2014 Oct;**19**(4):622-626. DOI: 10.1093/icvts/ivu203
- [18] Moulakakis KG, Dalainas I, Mylonas S, Giannakopoulos TG, Avgerinos ED, Liapis CD. Conversion to open repair after endografting for abdominal aortic aneurysm: A review of causes, incidence, results, and surgical techniques of reconstruction. *Journal of Endovascular Therapy*. 2010 Dec;**17**(6):694-702. DOI: 10.1583/1545-1550-17.6.694. Review
- [19] Ouriel K, Clair DG, Greenberg RK, Lyden SP, Hara PJ, Sarac TP, et al. Endovascular repair of abdominal aortic aneurysms: Device-specific outcome. *Journal of Vascular Surgery*. 2003;**37**:991-998
- [20] Mac Millan DP, Chaikof EL. Surgical conversion after endovascular aortic repair. In: Pierce WH, Matsumura JS, Yao JST, editors. *Trends in Vascular Surgery*. Evanston, IL: Greenwood Academic; 2004. pp. 317-324
- [21] White GH, May J, Waugh RC, Chaufour X, Yu W. Type III and type IV endoleak: Toward a complete definition of blood flow in the sac after endoluminal AAA repair. *Journal of Endovascular Surgery*. 1998;**5**:305-309
- [22] Verzini F, Cao P, De Rango G, Parlani G, Xanthopoulos D, Iacono G, et al. Conversion to open repair after endografting for abdominal aortic aneurysm: Causes, incidence and results. *European Journal of Vascular Surgery*. 2006;**31**:136-142
- [23] Fransen GA, Vallabhaneni SR Sr, van Marrewijk CJ, Laheij RJ, Harris PL, Buth J. Rupture of infra-renal aortic aneurysm after endovascular repair: A series from EUROSTAR registry. *European Journal of Vascular and Endovascular Surgery*. 2003;**26**:487-493

