

We are IntechOpen, the world's leading publisher of Open Access books Built by scientists, for scientists

4,800

Open access books available

122,000

International authors and editors

135M

Downloads

Our authors are among the

154

Countries delivered to

TOP 1%

most cited scientists

12.2%

Contributors from top 500 universities



WEB OF SCIENCE™

Selection of our books indexed in the Book Citation Index
in Web of Science™ Core Collection (BKCI)

Interested in publishing with us?
Contact book.department@intechopen.com

Numbers displayed above are based on latest data collected.
For more information visit www.intechopen.com



Trapeziometacarpal Joint: A Mechanical Explanation of Total Prosthesis Failures

Victoria Spartacus

Abstract

Total prosthesis, which preserves strength and respects trapeziometacarpal (TMC) joint range of motion, is a surgical option considered for the TMC joint replacement. With the usual ball-and-socket design, patients obtain faster pain relief, stronger grip function, and shorter convalescence than with trapeziectomy. However, prostheses currently used have led to various early complications, especially in active and young patients. Revisions are most often due to the loosening of the trapezium cup and of the metacarpal stem and to the luxation of the first metacarpal bone. The short lifespan of these devices suggests the difficulty of designing a prosthesis that respects the complex anatomy and motions of the TMC joint. Early implant failure may reflect the fact that the current devices do not exactly replicate the true kinematics. The aim of this chapter will be to shed light mechanical explanations for TMC prosthesis failures in regard to the complex kinematics of the joint.

Keywords: trapeziometacarpal joint, total prosthesis, failures

1. Introduction

The thumb column is composed of three bones: the scaphoid, trapezium, and first metacarpal (M1) (**Figure 1**).

The trapeziometacarpal (TMC) joint, composed of the trapezium and the M1, plays a capital role in strength and movement orientation of this column. This joint allows the opposition of the thumb and thus is highly solicited.

Arthrosis of the TMC joint, called rhizarthrosis, is the second most frequent arthritis of the hand [1]. It is prevalent among middle-aged and postmenopausal women [2]; one third of women over 55 are radiographically affected by rhizarthrosis [3]. This painful and disabling pathology limits the range of motion and the strength of the thumb. It not only occurs mainly on the cartilage of the trapezium and the first metacarpal joint but can also affects the whole cartilaginous surface of the trapezium as defined by Dell [4] and Eaton and Littler [5] (**Figure 2**).

Its natural progression typically results in less pain, but hand function is reduced because of the Z-deformity of the thumb column. The base of the first metacarpal (M1) dislocates into adduction, in combination with hyperextension of the metacarpophalangeal (MCP) joint and contracture of the first web space. This natural progression toward pain relief often results in patients and surgeons taking in a wait-and-see approach. When conservative treatments fail, surgical options can be considered. The numerous surgical solutions proposed include trapeziectomy

with ligament interposition and arthrodesis [6]. Arthrodesis involves fusion of the trapezium and M1, to reduce pain by restraining movement. In trapeziectomy, the trapezium bone is removed and all the ligaments are sectioned. Trapeziectomy yields good pain results, but patients lack strength during movements [7]. These treatments do not respect the original anatomy of the joint and modify the kinematics of the TMC joint.

Another and more recent surgical option is total prosthesis, which preserves strength and respects TMC joint kinematics. With the usual ball-and-socket design, patients obtain faster and better pain relief, stronger grip function, and shorter convalescence than with trapeziectomy [8, 9]. However, there are also many reports of poor results [10]. Revisions are most often due to the loosening of the trapezium cup [11, 12] and of the metacarpal stem and to the luxation of the first metacarpal bone [13] (**Figure 3**).

The prostheses currently used have thus led to various early complications, especially in active young patients. The short lifespan of these devices suggests the difficulty of designing a prosthesis that respects the complex anatomy and motions of the TMC joint. Early implant failure may reflect the fact that current devices do not exactly replicate the true kinematics. Improved knowledge of TMC kinematics with implant could also enhance the design and consequently the lifespan of implants.

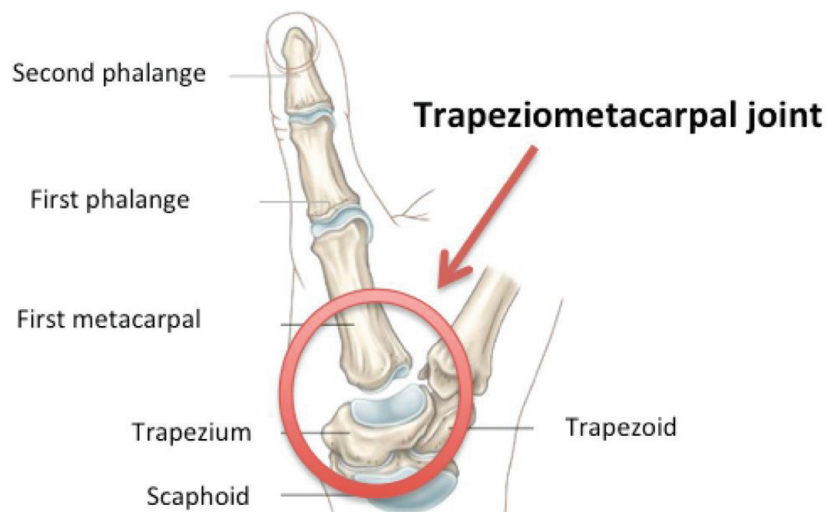


Figure 1.
Thumb column.

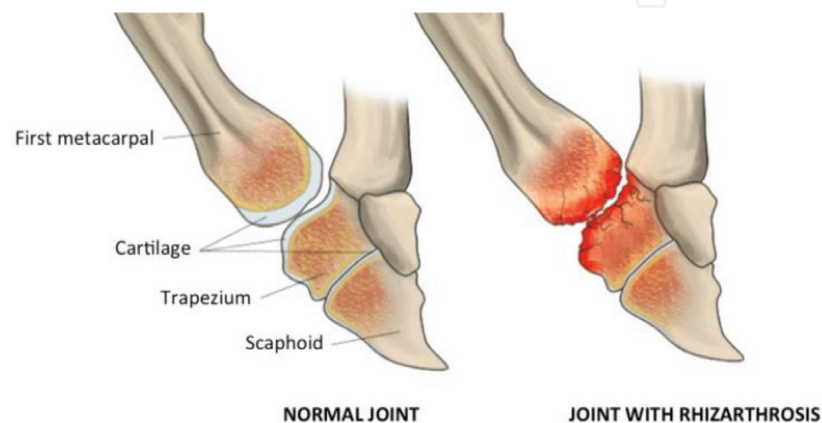


Figure 2.
Rhizarthrosis of the trapeziometacarpal joint.

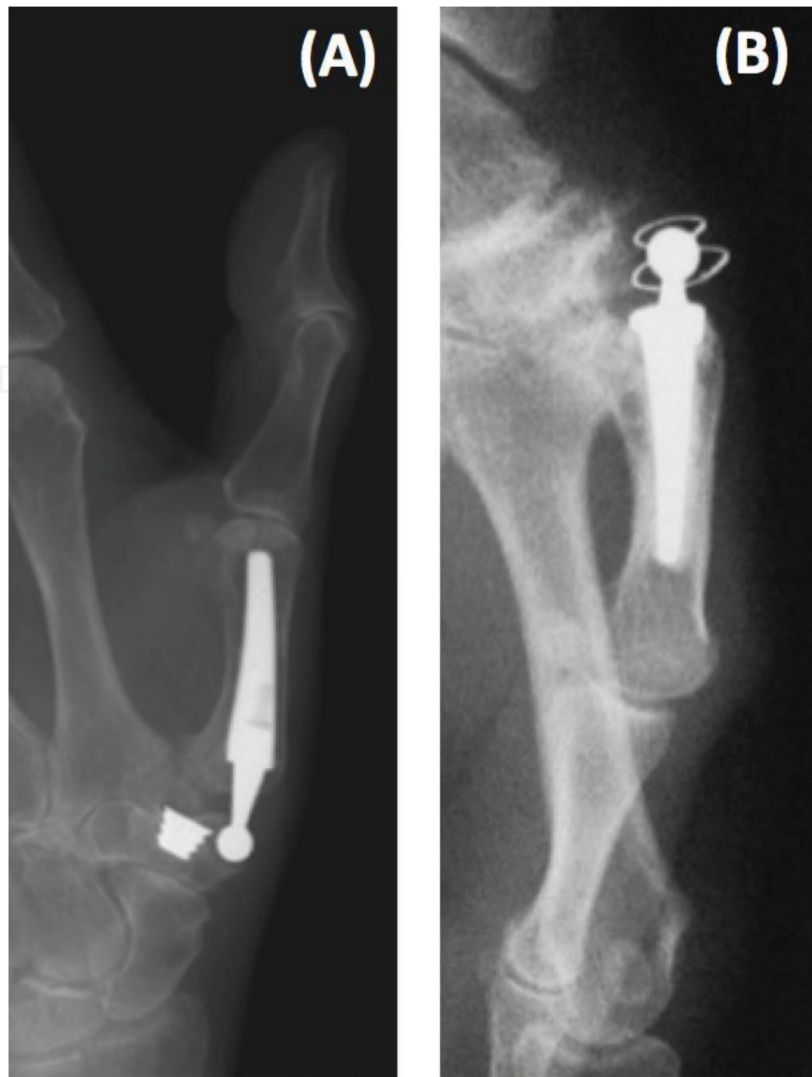

Figure 3.
(A) Luxation of the first metacarpal bone by Klahn et al. [14] and (B) loosening of the trapezium cup by Lemoine et al. [15].

2. Trapeziometacarpal joint kinematics

A precise description of the TMC joint in an anatomic plane is complicated by the complexity of the joint anatomy. The TMC joint is 40° orientated with respect to the three anatomic planes (**Figure 4**). This joint is described according to four principal views:

- Palmar view: anterior view, observation of the palm of the hand

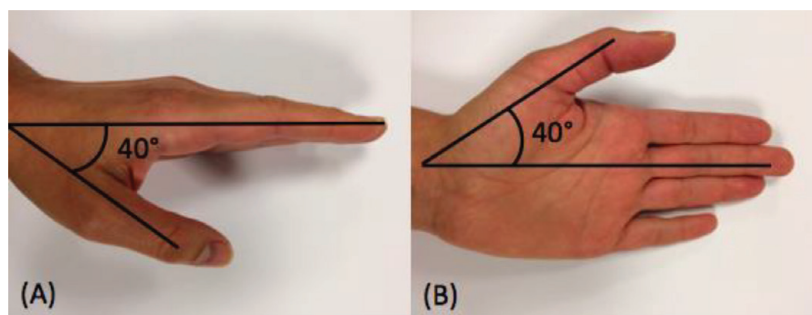


Figure 4.
Thumb in resting position of a left hand. (A) Frontal plane and (B) sagittal plane.

- Dorsal view: posterior view, observation in the dorsal face of the hand
- Ulnar view: a medial viewing angle (ulna side)
- Radial view: a lateral viewing angle (radius side)

In order to well understand the hand anatomy descriptive documents, certain criteria have to be taken into account. From the general view, the body is divided into two parts by vertical column. Then in anatomic study, the more the part of the body is close to the column, the more this part is medial. The more distant it is becoming from the column, the more lateral it is becoming from it. However, a difficulty arises with the human hand. The prono-supination movement gives to the thumb both possibilities according to the articular position of the wrist and the elbow. Thus a reference position has been established also called resting position. This position corresponds to the forearm in supination with the thumb in the lateral side, outwardly directed.

As it was mentioned previously, the TMC joint plays a fundamental role in the opposition mechanism of the thumb. It imparts a very high mobility, in regard to the M1 movement related to the trapezium. The TMC joint increasingly used, particularly with the appearance of the new technology, was a subject of interest.

The TMC joint is considered as a saddle-shape joint with two degrees of freedom (DOF) with nonorthogonal and nonintersected axes. This joint allows the thumb's different movements: flexion/extension, abduction/adduction, axial rotation, and circumduction (**Figure 5**):

- Flexion: thumb movement in medial direction. The thumb fingertip draws near the palm of the hand.
- Extension: thumb movement in posterolateral direction. Opposite side of flexion.
- Abduction: thumb movement in anterolateral direction, perpendicular to the palm of the hand.
- Adduction: thumb movement in posteromedial direction, in the palm of the hand plane.
- Circumduction: combination of the flexion/extension and the abduction/adduction movements.
- Axial rotation: rotation of the first metacarpal around his longitudinal axis.

The TMC joint is also a noncongruent joint with articular surface of the trapezium bigger than the M1 (**Figure 6**). This noncongruence of the articular surfaces implies translation of the M1 relatively to the trapezium.

Chèze et al. [16, 17] reported in their study values of M1 displacements in regard to the trapezium (**Table 1**).

Translations are considered to be negligible. Nevertheless, in regard to articular surface measurements, this conclusion is questionable [18, 19]. A study [18] realized measures on trapezium diameter. The results showed that the average diameter of the trapezium is 11.96 ± 1.32 mm. From these measurements it can be deduced that the M1 diameter is 34% larger than the trapezium diameter. In more recent study [19], the results show that the mean length of the trapezium

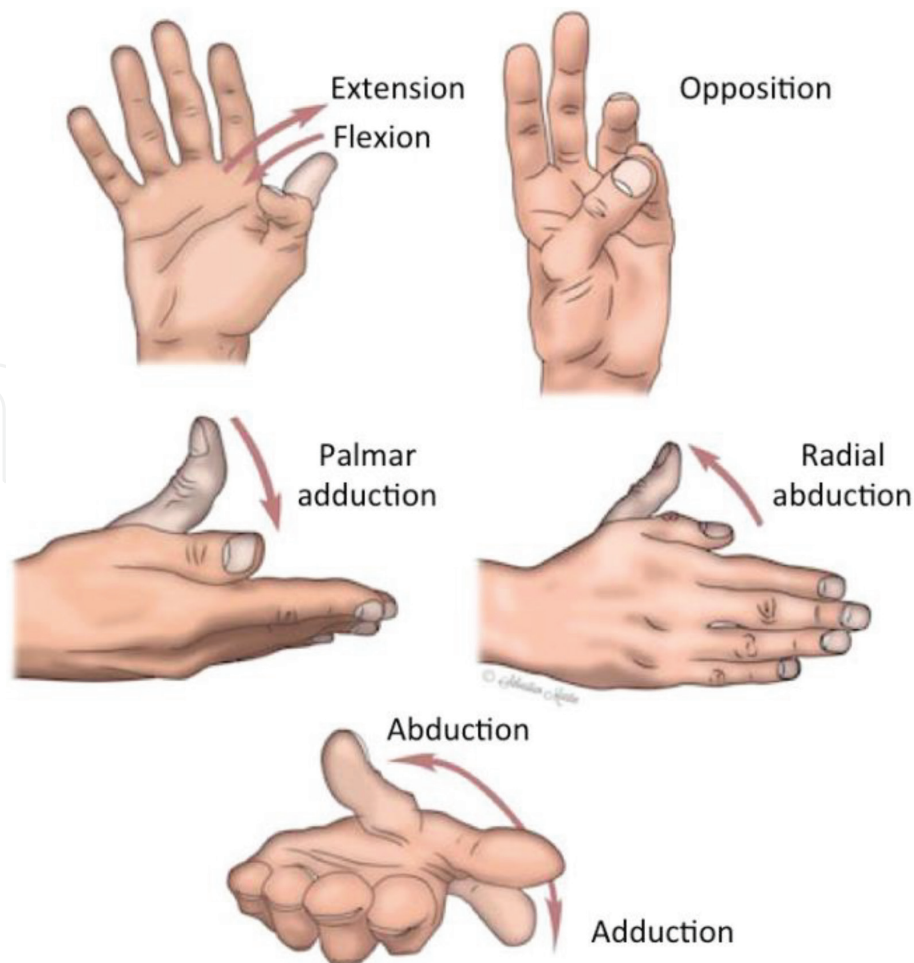


Figure 5.
 Thumb movements by Dr Grégoire Chick.

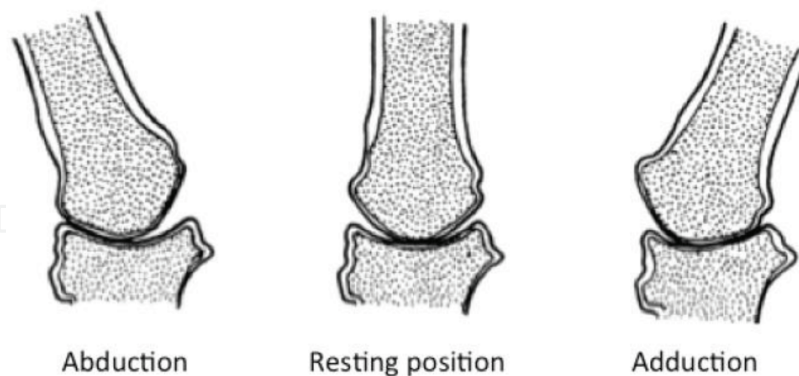


Figure 6.
 Noncongruence of the TMC joint by Napier et al. [14].

is 19.2 mm. From this value the M1 lateral displacement represents 25.5% of the trapezium surface that could not be negligible. In addition, in more recent study [20], displacement of the M1 was measured for different functional tasks as key pinch, jar grasp, and jar twist. In this study, the maximum radial/ulnar displacement of the M1 is 5.7 mm. With this value the M1 displacement represents 47.7% of the trapezium diameter.

Moreover, the two DOF models are not precise enough. The dispersion in range of motion in the literature shows the difficulties to analyze with accuracy the kinematic of the TMC joint (Table 2).

Medial/lateral displacement	1.7 mm, maximum 4.9 mm
Proximal/distal displacement	2.0 mm, maximum 5.9 mm
Anterior/posterior displacement	3.0 mm, maximum 6.3 mm

Table 1.
Average displacement of the M1 by Chèze et al. [15]

	Kaplan [19]	Cooney et al. [20]	Chèze et al. (2001)[17]	Coert et al. [21]	Li et al. (2007) [24]	Cheema et al. (2006) [25]
Axial rotation	17.5°	16.5°	38°	90°	45°	89°

Average range of movement of axial rotation.

Table 2.
Example of disparity in range of movement of the thumb.

Several methods of thumb movement quantification have been established. These methods, including video technics [22, 23, 26], reflective markers [27, 28], and electromagnetic design [17, 29, 30], used different external markers as reference point. In 2001, Chèze et al. [17] elaborated an experimental protocol with a motion analysis system that allows to obtain the range of motion. In 2009, Goubier et al. [29] studied the movement with an optoelectronic system. These protocols used external markers to analyze the thumb kinematics. Then interference of soft tissue could influence the movements.

Tomographic imaging is an emerging method in thumb kinematics analysis. In vivo measurement has been established to evaluate axial rotation [25]. This rotation has been measured drawing reference lines in CT scan images. This study allows to measure the axial orientation of the M1.

In vivo studies, using CT scan methodology, based on TMC joint movement have been performed [31–34]. They described nonorthogonal and nonperpendicular axes, but they did not particularly described translations and axial rotation.

All previous studies aimed to characterize the thumb movement with different specific methods. However, they only considered the movement of healthy joint and not on pathologic one. Furthermore these studies did not focus on movement of the TMC prosthesis.

2.1 Material and methods

In order to analyze the movement of the TMC prosthesis, CT scans of the TMC joint under various postures of the thumb were performed with a general electric scanner light speed VCT64. The scan acquisition parameters were mAs 90, kV 120, slice thickness 0.625, and FOV small. Eight hands were obtained from six embalmed Caucasian cadaveric subjects, two males (three hands) and four females (five hands) with different degrees of rhizarthrosis according to the Dell classification [4] (**Table 3**). The subjects were divided into three groups: group 1, subjects with either no or stage 1 arthrosis; group 2, subjects with stage 2 and stage 3 arthrosis; and group 3, subjects with stage 4 arthrosis.

Three postures were chosen to cover the full range of thumb motion: commissural closing (**Figure 7(A)**), grip (**Figure 7(B)**), and opposition (**Figure 7(C)**). Using Mimics[®] (Materialize 3D, Belgium), the DICOM data from the CT scans were used to develop 3D reconstructions of the TMC joint.

Subject	1.R	2.R	3.R	4.R	5.R	5.L	6.R	6.L
Gender	M	M	F	F	F	F	F	F
Age	82	90	92	84	94	94	94	94
Side	Right	Right	Right	Right	Right	Left	Right	Left
Stage of arthrosis	3	1	3	4	NA	4	2	2

NA, no arthrosis; Stage 1, subchondral sclerosis with no osteophytes or subluxation; Stage 2, small subluxation and small internal osteophytes; Stage 4, no remaining space between the bones.

Table 3.
 Summary of cadaveric subjects.

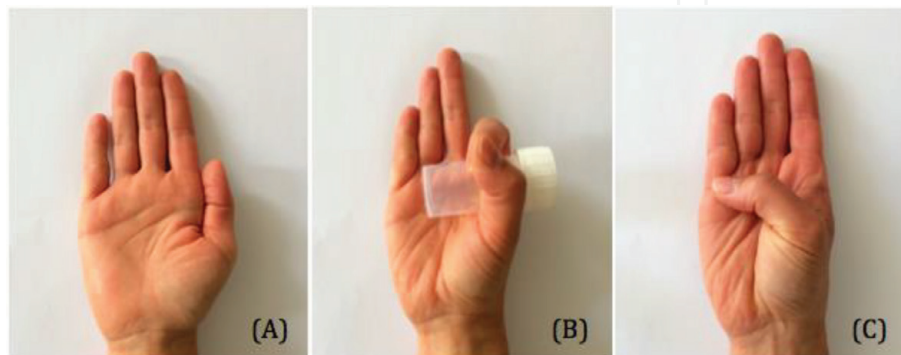


Figure 7.
 (A) Thumb in commissural closing posture, (B) thumb in grip posture and (C) thumb in opposition posture.

CAD models of a currently used prosthesis (**Figure 8**) were coupled with the 3D reconstructions of the joint to provide numerical models of the TMC joint with a ball-and-socket implant. The CAD model, composed of three elements (stem, neck, and trapezium cup), was placed in the ATM using 3-Matic[®] (Materialize, Belgium).

Working from the 3D models, the commissural closing posture was the reference posture for the complex trapezium/cup and the complex M1/stem/neck. These complexes were superposed to the M1 and the trapezium in opposition and in grip posture, using a surface-based registration procedure based on the iterative closest point (ICP) [35] (**Figure 9**).

Thus for each posture, we determined the position of the complex M1/stem/neck relative to the complex trapezium/cup. Then, for each hand, considering the complex trapezium/cup as fixed, the different postures were superposed using the same surface-based registration procedure. The method of superposition was previously described by Cerveri et al. [31] (**Figure 10**).

Potential translations of the head relative to the cup were determined by the distance between the center of the cup and the center of the head. This distance was calculated for grip and opposition posture (**Figure 11**). Zero distance is being taken as indicating none translation. A distance other than zero was taken as a sign of translation, with the head of the neck penetrating the cup. In this case, the intersection volume between the cup and the head was calculated in order to evaluate the percentage of the cup volume occupied by the head.

2.2 Results

Regarding the straight neck, the smallest distances between the cup and the head of the prosthesis in grip posture or in opposition posture are 1.3 and 0.8 mm, respectively. Regarding the angled neck, the smallest distances between the cup

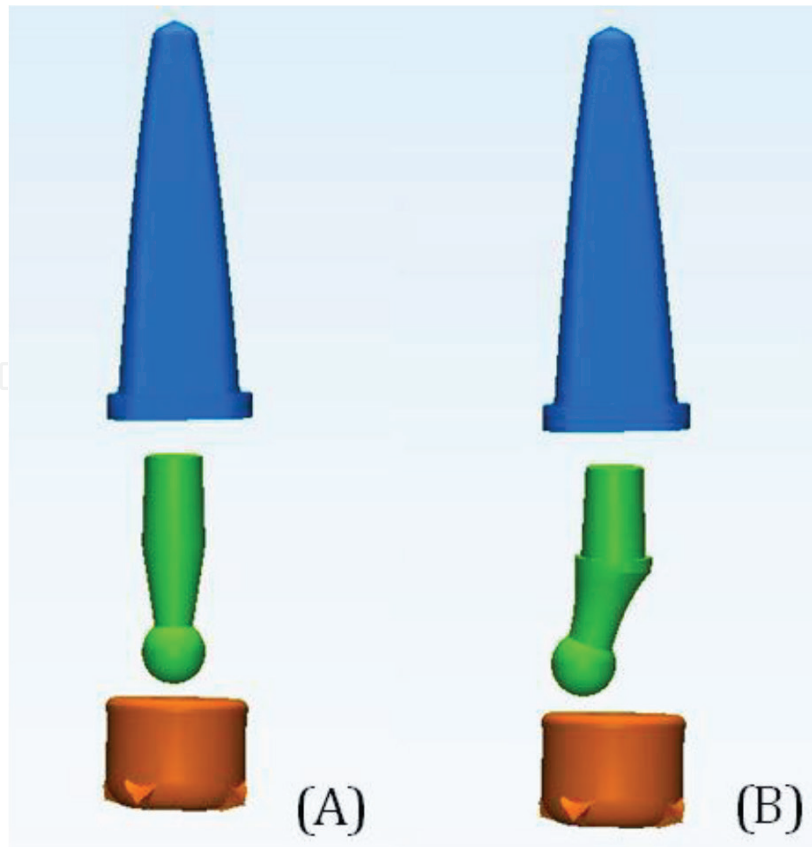


Figure 8.
 CAD models of current prosthesis used in this study: cup in orange, neck in green, and stem in blue.
 (A) Prosthesis with a straight neck and (B) prosthesis with an angle neck.

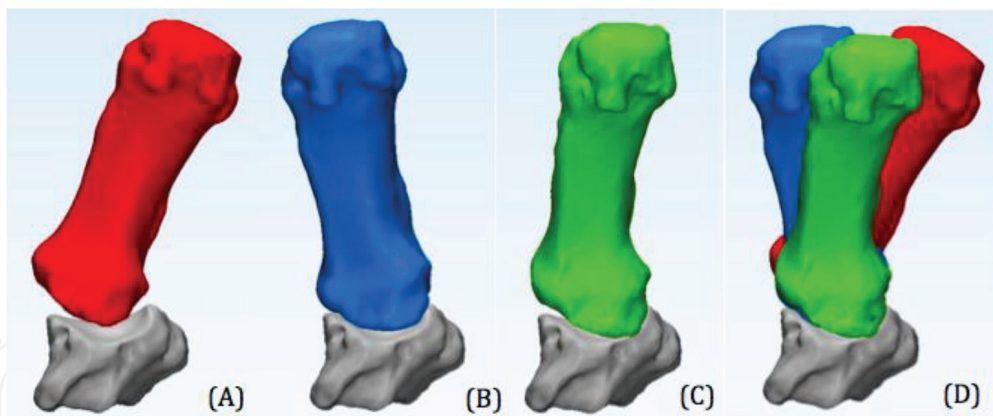


Figure 9.
 Superposition procedure.

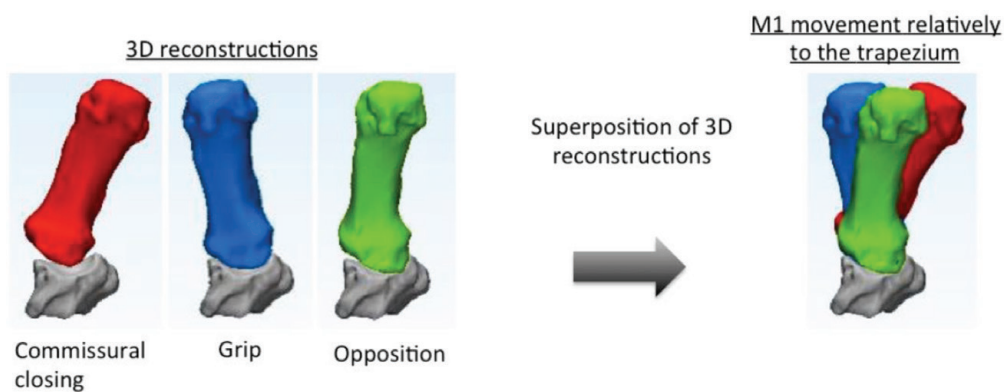


Figure 10.
 Superposition procedure for complex trapezium/cup and complex M1/stem/neck.

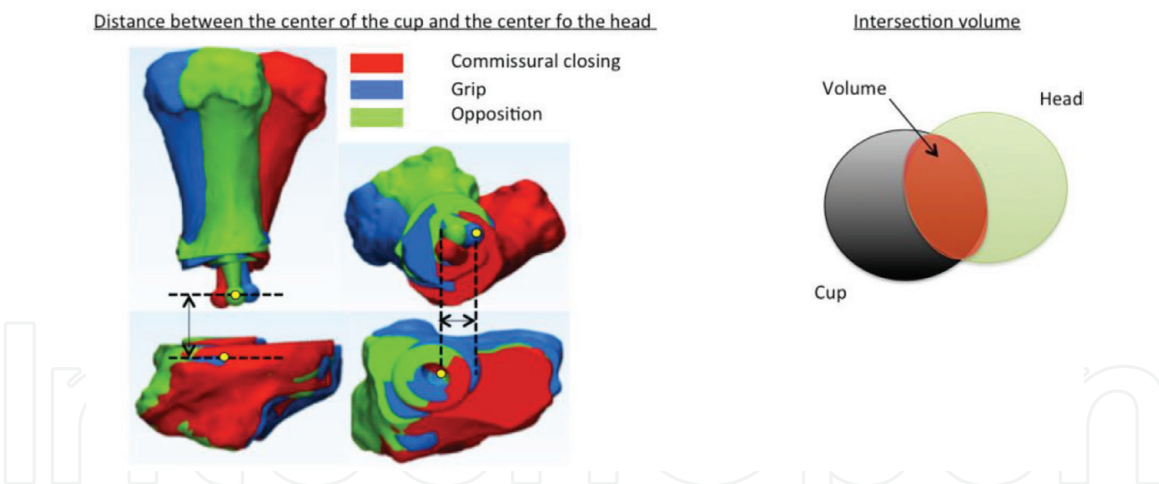


Figure 11. Right: distance between cup and head center. Left: intersection volume between the cup and the head.

	D1 (mm)	V1 (mm ³)	D2 (mm)	V2 (mm ³)	D3 (mm)	V3 (mm ³)	D4 (mm)	V4 (mm ³)
5.R G1	5.2	0.0	2.5	6.3	3.5	0.8	4.9	0.0
2.R G1	5.3	0.0	3.8	0.2	3.4	1.0	5.4	0.0
6.R G2	2.3	9.0	0.8	24.4	1.4	16.6	2.9	3.6
6.L G2	3.2	2.6	1.6	15.3	1.5	15.7	3.6	0.5
3.R G2	4.3	0.0	3.1	2.8	3.2	1.9	5.1	0.0
1.R G2	4.9	0.0	2.0	11.1	1.8	12.4	4.0	0.0
4.R G3	1.5	16.2	0.8	24.4	0.6	25.5	1.2	19.3
5.L G3	1.3	17.9	1.4	18.0	0.7	25.1	1.5	15.7

Table 4. For each subject, distances between the head gravity center of the straight neck and the center of the cup in grip posture (D1) and in opposition posture (D2). V1 is the theoretical intersection volume between the cup and the head of the straight neck in grip posture and V2 in opposition posture. Same results are observed for angled neck in D3, D4, V3, and V4.

and the head of the prosthesis in grip posture or in opposition posture are 0.6 and 1.2 mm, respectively.

Thus, for both types of the neck, for each posture, distances are superior to zero. Thus for each of the three groups, the head of the prosthesis translates during movements and penetrates into the cup.

Regarding prosthesis with a straight neck, the intersection volume between cup and head varied from 0 to 24.4 mm³ (Table 4). When the volume is 0, the elements do not intersect. In this case, the head is completely out of the cup. When the volume is 24.4 mm³, the elements intersect. The intersecting volume represents 67.6% of the cup volume.

Regarding prosthesis with an angled neck, the intersection volume between cup and head varied from 0 to 25.5 mm³ (Table 4). When the volume is 0, the elements do not intersect. In this case, the head is completely out of the cup. When

the volume is 25.5 mm^3 , the elements intersect. The intersecting volume represents 70.8% of the cup volume.

2.3 Conclusion

The current total prosthesis, with the usual ball-and-socket design, preserves strength and respects TMC range of motion. However, they have led to various early complications, especially in active young patients. This study focused on the origin of the TMC prostheses failures to elucidate their mechanical explanation.

The CAD model of a ball-and-socket design prosthesis implanted in each different postures of each subject shows that the original kinematics of the joint is disturbed by the prosthetic elements. The displacements of the head of the prosthesis between each posture are greater than those of the cup. We observe numerical penetration by the head of the prosthesis into the cup. This phenomenon could in vivo correspond to an overstress of prosthetic elements. This penetration supports the fact that the most frequent prosthesis revision is due to the loosening of the trapezium cup [11, 36]. Chakrabarti et al. [36] showed that 91% of prosthesis revisions are due to loosening of the cup.

Thus, the movement of the prosthesis does not fully respect the anatomical kinematics. The TMC joint is known to have nonintersecting and nonorthogonal rotation axes [31, 32]. Moreover, this joint allowed translations of the M1 over the trapezium [32, 37]. Then simplifying the TMC joint to a ball-and-socket articulation could in vivo lead to an overstress of the prosthesis. The overstressing produced by this design could partly explain the short lifespan of current prostheses. In the light of this study's findings, a review of the design of these prostheses appears warranted.

IntechOpen

Author details

Victoria Spartacus

University of Valenciennes and Hainaut-Cambrésis, Valenciennes, France

*Address all correspondence to: victoria.spartacus@wanadoo.fr

IntechOpen

© 2018 The Author(s). Licensee IntechOpen. This chapter is distributed under the terms of the Creative Commons Attribution License (<http://creativecommons.org/licenses/by/3.0>), which permits unrestricted use, distribution, and reproduction in any medium, provided the original work is properly cited. 

References

- [1] Batra S, Kanvinde R. Osteoarthritis of the thumb trapeziometacarpal joint. *Current Orthopaedics*. 2007;**21**:135-144
- [2] Stussi JD, Dap F, Merle M. A retrospective study of 69 primary rhizarthrosis surgically treated by total trapeziectomy followed in 34 cases by interpositional tendinoplasty and in 35 cases by suspensioplasty. *Chirurgie de la main*. 2000;**19**:116-127. PMID: 10904830
- [3] Armstrong A, Hunter J, Davis T. The prevalence of degenerative arthritis of the base of the thumb in post-menopausal women. *The Journal of Hand Surgery: Journal of the British Society for Surgery of the Hand*. 1994;**19**:340-341. PMID: 8077824
- [4] Dell PC, Brushart TM, Smith RJ. Treatment of trapeziometacarpal arthritis: Results of resection arthroplasty. *Journal of Hand Surgery*. 1978;**3**:243-249. PMID: 659819
- [5] Eaton RG, Littler JW. Ligament reconstruction for the painful carpometacarpal joint. *Clinical Orthopaedics*. 1987;**220**:14-26
- [6] Gay AM, Celier A, Iniesta A, Legré R. Surgery for trapeziometacarpal osteoarthritis. *Hand Surgery & Rehabilitation*. 2016;**35**(4):238-249. DOI: 10.1016/j.hansur.2016.06.002
- [7] Degeorge B, Dagneaux L, Andrin J, Lazerges C, Coulet B, Chammas M. Do trapeziometacarpal prosthesis provide better metacarpophalangeal stability than trapeziectomy and ligamentoplasty? *Orthopaedics & Traumatology: Surgery & Research*. 2018;**104**(7):1095-1100. DOI: 10.1016/j.otsr.2018.07.008
- [8] Dehl M, Chelli M, Lippmann S, Benaissa S, Rotari V, Moughabghab M. Results of 115 Rubis II reverse thumb carpometacarpal joint prostheses with a mean follow-up of 10 years. *Journal of Hand Surgery (European Volume)*. 2017;**42**(6):592-598. DOI: 10.1177/1753193416687508
- [9] Semere A, Vuillerme N, Corcella D, Forli A, Moutet F. Results with the Roseland HAC trapeziometacarpal prosthesis after more than 10 years. *Chirurgie de la Main*. 2015;**34**:59-66. DOI: 10.1016/j.main.2015.01.004
- [10] Robles-Molina MJ, Lopez-Caba F, Gomez-Sanchez RC, Cardenas-Grande E, Pajares-Lopez M, Hernandez-Cortes P. Trapeziectomy with ligament reconstruction and tendon interposition versus a trapeziometacarpal prosthesis for the treatment of thumb basal joint osteoarthritis. *Orthopedics*. 2017;**40**(4):e681-e686. DOI: 10.3928/01477447-20170503-03
- [11] Toffoli A, Teissier J. MAÏA trapeziometacarpal joint arthroplasty: Clinical and radiological outcomes of 80 patients with more than 6 years of follow-up. *Journal of Hand Surgery (American Volume)*. 2017;**42**(10):838.e1-838.e8. DOI: 10.1016/j.jhsa.2017.06.008
- [12] Caekebeke P, Duerinckx J. Can surgical guidelines minimize complications after Maïa® trapeziometacarpal joint arthroplasty with unconstrained cups? *Journal of Hand Surgery (European Volume)*. 2018;**43**(4):420-425. DOI: 10.1177/1753193417741237
- [13] Bricout M, Rezzouk J. Complications and failures of the trapeziometacarpal Maïa® prosthesis: A series of 156 cases. *Hand Surgery & Rehabilitation*. 2016;**35**(3):190-198. DOI: 10.1016/j.hansur.2016.02.005
- [14] Klahn A, Nygaard M, Gvozdenovic R, Boeckstyns MEH. Elektra prosthesis

for trapeziometacarpal osteoarthritis: A follow-up of 39 consecutive cases. *Journal of Hand Surgery*. 2012;**37E**:605-609. DOI: 10.1177/1753193412443501

[15] Lemoine S, Wavreille G, Alnot JY, Fontaine C, Chantelot C, le groupe GUEPAR. Second generation guepar total arthroplasty of the thumb basal joint: 50 months follow-up in 84 cases. *Orthopaedics & traumatology: Surgery & research*. 2008;**95**:63-69. DOI: 10.1016/j.otsr.2008.06.001

[16] Napier JR. The form and the function of the carpo-metacarpal joint of the thumb. *Journal of Anatomy*. 1955;**89**:362-369. PMID: 13251966

[17] Chèze L, Doriot N, Eckert M, Rumelhart C, Comtet JJ. In vivo cinematic study of the trapezometacarpal joint. *Chirurgie de la main*. 2001;**20**:23-30. PMID: 11291316

[18] Bettinger P, Berger R. Functional ligamentous anatomy of the trapezium and trapeziometacarpal joint (gross and arthroscopic). *Hand Clinics*. 2001;**17**(2):151-168. PMID: 11478038

[19] Loisel F, Chapuy S, Rey PB, Obert L, Parratte B, Tatu L, Lepage D. Dimensions of the trapezium bone: A cadaver and CT study. *Surgical and Radiologic Anatomy*. 2015;**37**(7):787-792. DOI: 10.1007/s00276-015-1418-7

[20] Halilaj E, Rainbow MJ, Got C, Schwartz JB, Moore DC, Weiss AP, Ladd AL, Crisco JJ. In vivo kinematics of the thumb carpometacarpal joint during three isometric functional tasks. *Clinical Orthopaedics and Related Research*. 2014;**472**(4):1114-1122. DOI: 10.1007/s11999-013-3063-y

[21] Kaplan EB. *Functional and Surgical Anatomy of the Hand*. 2nd ed. Philadelphia: J.B. Lippincott; 1965

[22] Cooney WP 3rd, Lucca MJ, Chao EY, Linscheid RL. The kinesiology of the

thumb trapeziometacarpal joint. *Journal of Bone and Joint Surgery (American)*. 1981;**63**(9):1371-1381. PMID: 7320028

[23] Coert JH, Hoek van Dijke GA, Hovius SER, Snijders CJ, Meek MF. Quantifying thumb rotation during circumduction utilizing a video technique. *Journal of Orthopaedic Research*. 2003;**21**:1151-1155. DOI: 10.1016/S0736-0266(03)00114-1

[24] Li Z-M, Tang J. Coordination of the thumb joint during opposition. *Journal of Biomechanics*. 2007;**40**:502-510. PMID: 16643926

[25] Cheema TA, Cheema NI, Tayyab R, Firoozbakhsh K. Microstructural adaptation in trapezium bone due to subluxation of the thumb. *Journal of Hand Surgery*. 2009;**31**:76-79. DOI: 10.1002/jor.20500

[26] Kuo L-C, Su F-C, Chiu H-Y, Yu C-Y. Feasibility of using a video-based motion analysis system for measuring thumb kinematics. *Journal of Biomechanics*. 2002;**35**:1499-1506. PMID: 12413969

[27] Lin H-T, Kuo L-C, Liu H-Y, Wu W-L, Su F-C. The three-dimensional analysis of three thumb joints coordination in activities of daily living. *Clinical Biomechanics*. 2011;**28**:371-376. DOI: 10.1016/j.clinbiomech.2010.11.009

[28] Chèze L, Dumas R, Comtet J-J, Rumelhart C, Fayet M. Determination of the number of degrees of freedom of the trapeziometacarpal joint-an in vitro study. *IRBM*. 2012;**33**:271-276

[29] Goubier JN, Devun L, Mitton D, Lavaste F, Papadogeorgou E. Normal range of motion of trapeziometacarpal joint. *Chirurgie de la main*. 2009;**28**:297-300. PMID: 19762264

[30] Kuo L-C, Cooney WP, An K-N, Lai K-Y, Wang S-M, Su F-C. Effects of age and gender on the movement workspace

of the trapeziometacarpal joint. *Journal of Engineering in Medicine. Part H.* 2009;**223**:133-142. PMID: 19278191

[31] Cerveri P, De Momi E, Marchente M, Baud-Bovy G, Scifo P, Barros RML, Ferrigno G. Method for the estimation of double hinge kinematic model for the trapeziometacarpal joint using MR imaging. *Computer Methods in Biomechanics and Biomedical Engineering.* 2010;**13**(3):387-396. PMID: 19802754

[32] Crisco J, Halilaj E, Douglas CM, Patel T, Weiss A-P, Ladd L. In vivo kinematics of the trapeziometacarpal joint during thumb extension-flexion and abduction-adduction. *Journal of Hand Surgery American.* 2015;**40**(2):289-296. DOI: 10.1016/j.jhssa.2014.10.062

[33] D'Agostino P, Dourthe B, Kerkhof F, Stockmans F, Vereecke EE. In vivo kinematics of the thumb during flexion and adduction motion: Evidence for screw-home mechanism. *Journal of Orthopaedic Research.* 2017;**35**(7): 1556-1564. DOI: 10.1002/jor.23421

[34] Wang KK, Zang X, McCombe D, Ackland DC, Ek ET, Tham SK. Quantitative analysis of in-vivo thumb carpometacarpal joint kinematics using four-dimensional computed tomography. *Journal of Hand Surgery (European Volume).* 2018; 1753193418789828;**0**(0):1-10. DOI: 10.1177/1753193418789828

[35] Besl PJ, McKay ND. A method for registration of 3-D shapes. *IEEE Transactions on pattern analysis and machine intelligence.* 1992;**14**(2):239-256

[36] Chakrabarti AJ, Robinson AHN, Gallagher P. De La Caffinière thumb carpometacarpal replacements: 93 cases at 6 to 16 years follow-up. *Journal of Hand Surgery (British).* 1997;**22**: 695-698. PMID: 9457567

[37] Crisco JJ, Patel T, Halilaj E, Moore DC. The envelope of physiological motion of the first carpometacarpal joint. *Journal of Biomechanical Engineering.* 2015;**137**(10):101002. DOI: 10.1115/1.4031117