

We are IntechOpen, the world's leading publisher of Open Access books Built by scientists, for scientists

4,800

Open access books available

122,000

International authors and editors

135M

Downloads

Our authors are among the

154

Countries delivered to

TOP 1%

most cited scientists

12.2%

Contributors from top 500 universities



WEB OF SCIENCE™

Selection of our books indexed in the Book Citation Index
in Web of Science™ Core Collection (BKCI)

Interested in publishing with us?
Contact book.department@intechopen.com

Numbers displayed above are based on latest data collected.
For more information visit www.intechopen.com



Liver Transplantation in China

Yingzi Ming, Quan Zhuang, Baoren Tu, Gangcheng Kong, Hao Li, Ying Niu, Bo Peng, Junhui Li, Meng Yu and Min Yang

Abstract

Liver transplantation has been developed in Mainland China for about 40 years, from clinical trials to maturity. Its number has become the second in the world, its quality is also in line with the international level, and the source of donors has gradually transitioned to donation after citizen's death (DCD). This chapter is aimed to elaborate the liver transplant work in China from the history and current status of liver transplantation, the main operating methods, major indications, donor maintenance and donor quality assessment, postoperative major complications, and application of immunosuppressive agents to the postoperative follow-up. Liver transplantation is a meaningful and challenging work currently in China; all the Chinese transplant surgeons and scholars are devoting themselves to this work in order to give more effective help to the patients.

Keywords: liver transplantation, Mainland China, DCD, piggyback liver transplantation, donor quality assessment, liver transplant indications, HBV, liver transplant complications, immunosuppressant, follow-up

1. The developing history and current status of liver transplantation in China

Since the first clinical trial of liver transplantation in Mainland China in 1977, it has been more than 40 years. During this period, China's liver transplantation has experienced ups and downs and finally developed from immature to mature. Liver transplantation has been recognized as the only effective treatment for various end-stage liver diseases. The number of liver transplant cases in China ranks second in the world, ranking behind the United States. Its rapid development has attracted the attention of the world, and it has also exposed many problems that need to be solved [1].

The development of liver transplantation in China has gone through the following stages:

- (1) The initial trial stage (1977–1983). In 1977, Shanghai Ruijin Hospital and Wuhan Tongji Hospital started the clinical liver transplantation in China. From 1977 to 1983, 57 liver transplants were carried out nationwide, but because the liver transplantation indications at that time were mainly advanced primary liver cancer, the curative effect was poor, and most patients died 3 months after surgery. Ten years later (1983–1993), China's liver transplantation was basically at a standstill.
- (2) Re-development stage (1993–1997). With the continuous entry of new immunosuppressants into China, the continuous improvement of surgical

techniques and perioperative management, and the continuous strengthening of international exchanges and cooperation, China's liver transplantation finally re-emerged in the 1990s.

- (3) Rapid development stage (1997–2005). This is the main stage of liver transplantation development in China, and the main performance is as follows: (1) the number of liver transplants in mainland China has increased year by year. From 16 cases in 1997 to 100 cases in 1999, there were 200 cases of liver transplantation in 2000. By 2005, 3300 cases of liver transplantation were implemented. (2) The units and regions for liver transplantation have also increased year by year. More than 300 hospitals across the country have carried out liver transplantation. (3) Liver transplantation is diversified, from traditional classic liver transplantation to piggyback liver transplantation, ectopic liver transplantation, partial liver transplantation, split liver transplantation, and living donor liver transplantation. (4) The postoperative management level is continuously improved, the application of immunosuppressive agents is more individualized and diverse, and the survival rate of recipients is significantly improved. The 1-year survival rate after liver transplantation was 80.5%, and the 5-year survival rate was 65.9%. Liver transplantation technology and clinical efficacy are close to international standards [2]. In 2006, the Ministry of Health conducted an access work for organ transplant medical institutions, and China's liver transplantation entered the stage of clinical normative development. Liver transplantation is gradually incorporated into the legal management. The medical institutions that are admitted are mainly strong medical institutions that have mature liver transplantation technology and talented echelons. Taking the service area and scope into account, the admitted liver transplant medical institutions are mainly concentrated in the affiliated hospitals of the provincial capital universities in the big cities, which further guarantee the quality, safety, and management of transplants [3]. In 2007, China's first "Human Organ Transplantation Regulations" was officially implemented, and the Ministry of Health also issued relevant supporting regulations, marking a crucial step in the legalization and standardization of China's organ transplantation [4]. In February 2005, the China Liver Transplant Registration Network was established. The system was supported by the University of Hong Kong with the support of the Ministry of Health. In May 2008, the China Liver Transplant Registration Network was officially authorized by the Ministry of Health to further cover the 80 admitted liver transplantation centers [5]. China Liver Transplant Registration Network has been upgraded from scientific voluntary registration to administrative mandatory registration, becoming the standardized management system for liver transplantation in China. China Liver Transplant Network has collected more than 12,000 cases of domestic liver transplant patients. By the end of 2008, China had implemented 14,600 liver transplants. By August 10, 2009, China had implemented 16,158 liver transplants until July 22, 2010. The Chinese transplant network registered 18,180 liver transplants [6].
- (4) DCD (organ donation after citizen's death) Liver transplantation stage (2010–present) in 2010. China gradually began trial of DCD for liver transplantation, with 11 provinces including Zhejiang, Yunnan, Hubei, and Hunan as the first batch of pilots. The DCD was vigorously promoted and achieved good results. Summary after the completion of the pilot work: as of July 1, 2013, a total of 906 DCD donors donated nationwide, and 2469 organs were donated, including 746 livers. The above data show that although the Chinese DCD work

started late, in the future it is the most potential source of organs [7]. Under the vigorous promotion of the Ministry of Health and the Red Cross Society, DCD work began to be promoted nationwide in 2012, and the construction of relevant laws and regulations also steadily advanced. In October 2012, in order to better implement the “Human Organ Transplant Regulations” and actively promote the Chinese organ donation work, the Ministry of Health formulated the “Management Methods for the Acquisition and Distribution of Human Organs in China” and established the “China Organ transplant response system” (OTRS). Through the application of this system, we wish to improve the matching degree of organs, reduce or prevent waste of resources, strive to achieve the traceability of each distributed organ, and eliminate the interference of human and subjective factors to ensure the principle of “fairness, openness, and justice” [8]. In 2010, DCD liver transplantation accounted for only 1.38% of the total, and in 2013, it has increased significantly to 26.02% [9], and by 2015, it has exceeded 80% [10]. China has completely banned the use of organs in the judicial channel since 2015. DCD donor China has become the main source of donors for organ transplantation in China. In 2017, 4732 cases of liver transplantation were performed in China, including 4138 cases of DCD liver transplantation, which was 26.43% higher than that of 2016 (3273 cases). The data show that the survival rates of liver transplantation in China at 1, 3, and 5 years are 84, 75, and 71%, respectively. The Chinese organ transplantation has entered the DCD era [11].

Although China’s organ transplants have developed rapidly, they have also achieved many achievements and showed the characteristics of China, but they also exposed some problems.

(1) Problems faced by liver transplantation for liver cancer.

China is a big country with hepatitis B. The HBV carrying rate is about 10% in the national population. As the terminal end of the development chain of hepatitis-cirrhosis-hepatocarcinoma, the high incidence of liver cancer in China is inevitable. China’s liver cancer patients account for more than half of the world’s liver cancer patients, and 318,000 new liver cancer patients occur in China each year. With the continuous improvement of the medical insurance system, China has the world’s largest transplant recipient group, liver cancer liver transplantation once accounted for about 44% of China’s total liver transplant [5]. It is urgent to formulate the staging criteria and surgical adaptation of liver cancer liver transplantation in accordance with China’s national conditions as soon as possible. At the same time, how to combine immunosuppressive agents with antiliver disease and antihepatitis virus treatment is the main problem faced by Chinese transplant experts [12].

(2) Problems faced by the DCD era.

The development of DCD donors has effectively alleviated the problem of donor shortages in China, and has also led to the complete abolition of judicial source donors. However, the current organ donation rate in China is still very low. In 2010, it was only 0.03 cases/million population. In 2015, it was 2.03 cases/million population, and in 2016, it was 2.98 cases/million population [13]. Although the growth is relatively fast, there is still a huge growth potential. This requires all levels of government in China to increase the propaganda of donations, and at the same time increase the staff of organ donation to find and report the information of potential donors in a timely manner. At the

same time, a complete organ donation process must be developed to ensure the smooth implementation of the donation.

- (3) Basic and clinical research related to transplantation needs to be strengthened.

Organ transplantation is a multidisciplinary and interdisciplinary profession. Only by strengthening relevant basic and clinical research, can we better protect organ quality and provide better postoperative management and monitoring of patients [14].

- (4) The relevant laws and regulations on transplantation have yet to be perfected.

The current regulations on organ transplantation in China are mainly based on “the Interim Provisions on the Clinical Application Management of Human Organs Technology” issued in July 2006 and the “Human Organ Transplantation Regulations” promulgated by the State Council in March 2017. However, with the development of transplantation and the advent of the DCD era, more completed legal and ethical systems and management norms are needed to provide legal protection and policy support for the healthy and orderly development of organ transplantation in China.

China’s clinical liver transplantation has entered a critical period of simultaneous hopes and challenges, and Chinese liver transplant experts are constantly working hard to make liver transplantation a better way for patients with liver disease.

2. Quality assessment of liver grafts

In China, liver grafts used for transplantation are mainly from DCD (organ donation after citizen’s death), which includes DBD, DCD, DBCD, and living related donor. Here, we discuss the quality assessment of liver grafts from DCD. The quality of transplant liver is an important factor affecting the short-term and long-term effects of transplantation. Donated liver assessment mainly includes donor’s general information, medical history, general condition and intervention, laboratory results, etc. and specific items are listed in **Table 1** [15]. Every case is evaluated dynamically, including at least one preliminary evaluation and final assessment prior to liver harvest. Donor age, hepatic steatosis, warm and cold ischemia time, the risk of infection and tumor, hypernatremia, etc. are risk factors affecting the quality of liver grafts.

2.1 Donor age

It is generally believed that elderly donors often have higher opportunity of getting arteriosclerosis, hepatic steatosis, and tumor, which are risk factors affecting the quality of liver. Therefore, age is an important factor in the evaluation of liver grafts, and usually, donor age > 50 years is considered a contraindication to the use for transplantation. However, as the progression of liver transplantation and the relatively expanded need for liver grafts, liver grafts from these elderly donors can also be used with rigorous assessment, especially in the case of ensuring a short warm and cold ischemia time [16–18].

2.2 Hepatic steatosis

Hepatic steatosis is an important factor affecting liver function after transplantation; hence, the classification and the grading of hepatic steatosis are extremely

Category	Item	Category	Item
General information of donor	Gender	Laboratory tests	Blood routine
	Age		Urine routine
	Blood type		Fecal routine
	Height		Liver function
	BMI		Blood lipids
Medical history	Primary disease (cause of death)		Blood sugar
	ICU stay days		Blood electrolytes
	Past history		Coagulation function
	Family history		HIV
General condition and intervention	Vital signs		Hepatitis virus
	Urine volume		Syphilis tests
	Mechanical ventilation		Tumor markers
	Vasoactive drugs and other related drugs		Infection-related indicators
Other	Judgment during harvesting operation		
	Warm and cold ischemia time		
	Pretransplant biopsies of livers		

Table 1.
Assessment content of liver grafts.

pivotal. According to the histology classification, hepatic steatosis is mainly divided into macrovesicular steatosis, which is considered to be a more dangerous one, and microvesicular steatosis, which is generally regarded as being reversible. For microvesicular steatosis liver grafts, even though the lesion is severe, they can still be used. For macrovesicular steatosis liver grafts, if the lesion is more than 50%, it is considered to be a taboo for transplantation [19, 20]. At present, the methods for evaluating fatty liver graft mainly relies on the judgment of organ harvesting surgeon, and rapid frozen biopsy of liver grafts [21, 22]. The research toward the use of imaging methods such as ultrasound, CT, MRI, and metabonomics in the assessment of liver steatosis is launched and their efficiency still need to be verified [23].

2.3 Warm and cold ischemia injury

Warm ischemic injury caused by hypotensive and hypoxic perfusion process is one of the most important features of liver grafts. Long-term ischemia can increase the risk of primary nonfunction and biliary complications; thus, the time of warm ischemia is an important factor in evaluating the quality of liver. In addition, cold ischemia time > 8 hours is also a risk factor of liver transplantation. It has been reported that the incidence of liver failure after transplantation increases by 8% for every 1 hour after cold ischemia time > 6 hours. Therefore, during the process of liver acquisition, in order to improve the quality of grafts, the operation and transportation time should be shortened as much as possible [18].

2.4 Hepatitis virus infection

It is mainly hepatitis B virus prevailing in China. The main route of HBV infection in liver transplant recipients is through liver grafts. Liver graft from the donor who is in active period of hepatitis virus infection or has developed hepatitis virus-related liver fibrosis should not be used. For HBV-positive grafts, they can still be used to recipients who are selected rationally, get prophylactic antiviral therapy and the treatment of HBV immunoglobulin [18, 19]. HCV infection is not common in China. HCV-positive liver grafts can be used to recipients who need transplantation urgently, and they need anti-HCV therapy after surgery.

2.5 Tumor

For donors who have malignant tumors or tumor history, whether the liver can be used for transplantation remains controversial, and the transfer risk of tumor cannot be properly assessed. It is generally believed that the incidence of donor-related tumor and the resulting mortality are very low. However, the current view is that the liver from donors who have malignant tumor history should be selected carefully because some malignant tumors have unpredictable possibilities of recurrence and metastasis [19].

2.6 Hypernatremia

Hypernatremia (serum sodium >155 mmol/L) in donors is an important factor affecting the prognosis of liver transplantation. Studies have shown that hypernatremia affects the function of transplant organs and increases the risk of liver failure after transplantation, whose mechanism may be related to cell swelling, increased osmotic pressure, and reperfusion injury caused by hypernatremia. This adverse effect can be reduced by effectively correcting the blood sodium concentration [18].

2.7 Liver preservation

The effect of liver preservation affects the quality of grafts. At present, there are two methods of liver storage, which are static cold storage (SCS) and mechanical perfusion (MP). SCS is the most widely used method, and UW liquid, HTK liquid and Celsior liquid are the most popular preservation liquids. The ideal time for cold storage is less than 8 hours, and in clinical practice, the preservation time generally does not exceed 12–15 hours. MP can continuously infuse the organ's intrinsic vascular system to deliver nutrient, achieve organ preservation, and repair simultaneously, having great value in prolonging the time of liver preservation and improving organ quality. Besides, MP can monitor liver function, bile secretion and other indicators dynamically during storage and transportation, and evaluate the quality of donated liver, showing important clinical application prospects [24, 25].

3. Donor liver procurement and benchwork surgery

3.1 Donor liver procurement

Since there is still no law about brain death, at the present stage in China, the sources of liver are DCD and living-related donation. Here, we only talk about the DCD donor liver procurement.

It is recommended in most centers the “rapid cold perfusion and en-bloc liver-kidney procurement” technique [26]. Core temperature of the liver can be decreased rapidly to 0–4°C by double perfusion from the hepatic artery (aortic cannulation) and the portal vein (superior mesenteric vein cannulation). This technique also prevents accidental injuries to the hepatic hilar structures.

Following administration of 30,000 IU or 300 IU/Kg of heparin, expeditious access to the abdominal cavity is obtained through a midline incision from the xiphoid to the pubic symphysis. The abdominal aorta and inferior vena cava (IVC) are dissected and cannulated, and the cold flush (0–4°C normal saline) is initiated immediately. Superior mesenteric vein is isolated and cannulated at the root of small bowel mesentery followed with perfusion. Ice and slush are packed around the liver and kidneys, and subsequent dissection is carried out after completion of cold perfusion (**Figure 1**).

The liver is mobilized by dividing the round ligament, falciform, left triangular, and gastrohepatic ligaments. The hepatoduodenal ligament, posterior peritoneum nearby and the adhesions between the head of pancreas and duodenum are dissected with modified Kocher maneuver; the common bile duct is exposed and transected at the inferior margin of pancreas. The whole colon, stomach, and duodenum are isolated successively; then the bilateral peritoneum are cut open and the peritoneal attachments in the retroperitoneal space are divided until the spine. The ureters are isolated and transected at the common iliac artery level. After the procedure, only the liver, spleen, kidneys, and most part of pancreas are still left in the abdominal cavity. The pericardium and diaphragm are incised bilaterally: on the left, extending to the esophagus, and on the right, extending posterior the right lobe of the liver, adrenal gland, and IVC. The thoracic aorta and IVC are transected

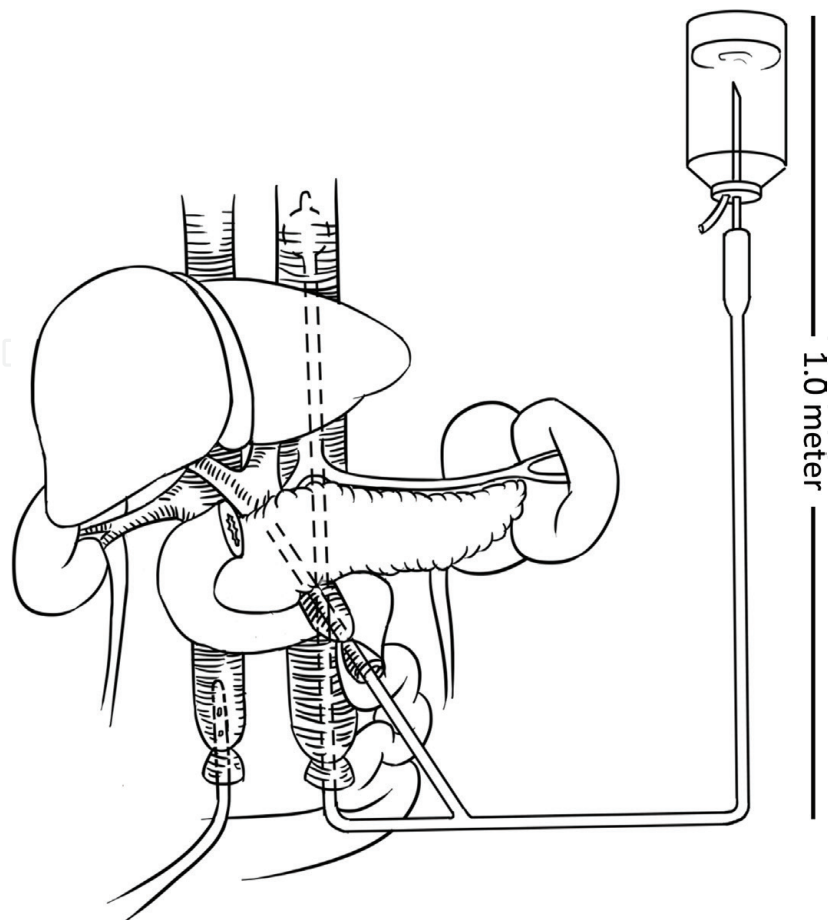


Figure 1.
The intubation perfusion of aorta and portal vein.

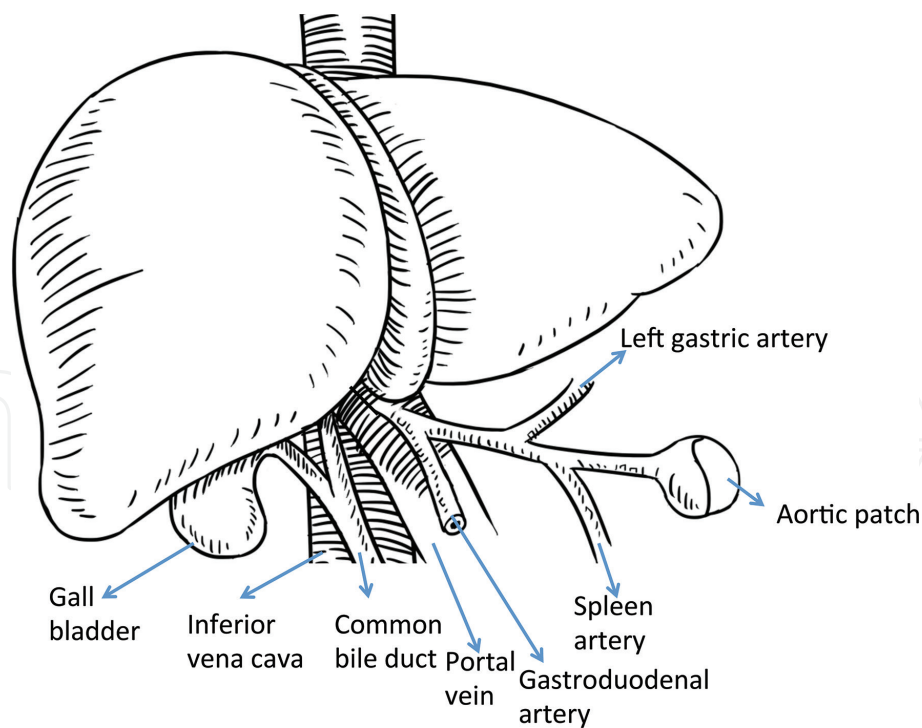


Figure 2.
The trimmed and shaped donor liver.

and the adhesions with the spine are divided until the common iliac artery level. The en-bloc liver-kidney-spleen organs cluster can be harvested with the aorta and IVC transection just below the cannulas.

Once the multiple-organs cluster is taken out, it must be put into the sterile basin filled with 0–4°C organ preservation solution (usually UW solution) immediately. Additional perfusion usually is needed in order to eliminate the residual blood and sustain the low core temperature of the organs. The posterior wall of the aorta is longitudinal cut out, and the origins of celiac trunk, superior mesenteric artery (SMA) and bilateral kidney arteries are exposed. The adhesions between the right kidney, adrenal gland, and the hepatic right lobe are divided until the inferior IVC exposed. IVC is transected just above the kidney veins level, and aorta is transected below the origin of SMA level; the liver and kidneys are separated and packaged respectively.

3.2 Bench surgery

The aim of bench surgery is to remove the unnecessary tissues attached to the liver and trim the main vessels and bile duct for a convenient anastomosis. The bench should be set up with a suitable sized bowl in which the graft is kept in sterile slush ice and UW at 4°C for the duration of the procedure to avoid rewarming.

Firstly, the diaphragm and remaining cardiac muscle are removed from the bare area of the liver and the vena cava. Then, the supra- and intrahepatic vena cava are skeletonized and all small branches are ligated with silk. The adrenal vein and the phrenic veins are tied or over sewn to prevent bleeding upon recirculation.

The skeletonization of the hepatic artery is the most critical step in the bench surgery procedure. The dissection starts from the aorta and ends until the gastro duodenal artery (GDA) in order not to injure the hepatic lobar vessels. Care is taken to identify any aberrant arterial anatomy, which can be present in up to 20% of the population [27]. So, every artery and its branches should be isolated until it is identified that not entering the liver. The most common two variants are a replaced right hepatic artery emanating from superior mesenteric artery or a replaced left hepatic

artery originating from the left gastric artery. Often the aberrant liver arteries need to be reconstructed for anastomosis.

The portal vein is skeletonized up to 1–2 cm below the bifurcation point. Surrounding lymphatic tissue is removed, and care is taken not to injure the hepatic artery or bile duct.

The pancreas tissues around the lower segment of the common bile duct are removed. Do not dissect excessively the tissues between the bile duct and the hepatic artery in order to preserve the blood supply of the bile duct.

A perfusion-giving set with cold UW should be set up to perfuse the liver and also to check the integrity of the portal vein and arterial tree, once the graft has been prepared for implantation (**Figure 2**).

4. Surgical methods of recipient liver transplantation

Surgical methods of recipient liver transplantation include two main categories: orthotopic liver transplantation and ectopic liver transplantation [28]. At present, transplant centers in China basically use orthotopic liver transplantation. Orthotopic liver transplantation is divided into classic orthotopic liver transplantation, piggy-back orthotopic liver transplantation, reduced-size liver transplantation, split liver transplantation, and auxiliary liver transplantation according to different surgical methods. The above procedures are applied in the Chinese transplant centers.

4.1 Classical orthotopic liver transplantation

4.1.1 Diseased liver resection

A curved cut under the regular costal edge or “Mercedes-Benz” logo shape incision has been made firstly, then dissecting the first hepatic portal dissecting the hepatic artery, separating the common bile duct, and finally separating the portal vein [29]. The inferior vena cava is then exposed. The posterior inferior vena cava can be quickly and safely separated from the posterior peritoneum [30].

4.1.2 Extracorporeal portal

The nonhepatic venous bypass technique can reduce the congestion of the portal system and can solve the problem of blood return in the intestine and inferior vena cava during the nonhepatic period [31, 32]. As the surgical techniques become more and more skilled, the anastomosis time is shortened. At present, most transplant centers in China have adopted nontransfer liver transplantation technology [33]. However, for patients with severe hepatorenal syndrome, gastrointestinal bleeding, and cardiac insufficiency before surgery, extracorporeal portal bypass technology will still benefit.

4.1.3 Graft implantation

The portal vein and two inferior vena cava were clamped in turn, to avoid vascular torsion, and the blood vessels were cut off near the liver to remove the diseased liver. The suprahepatic inferior vena cava the infrahepatic inferior vena cava and the portal vein were sequentially anastomosed with 3-0, 4-0, and 5-0 Prolene sutures. The anastomosis was performed by two-point continuous valvulus suture. Precautions of inferior vena cava anastomosis: A. The inferior vena cava of the recipient and the donor cannot be kept too long or too short; otherwise,

the inferior vena cava will be folded or stretched, and the inferior vena cava hypertension or bleeding will be caused. B. The recipient's suprahepatic inferior vena cava cannot be reversed; otherwise, it will cause poor blood flow in the inferior vena cava. C. The suture cannot be pulled too tightly to avoid damage to the intima form artificial stenosis, and even lead to Budd-Chiari syndrome. Precautions of hepatic portal vein anastomosis: A. Donor and recipient's portal vein should be kept proper. B. The difference between the size of the portal vein of the donor and the recipient should not be too large, otherwise. C. The tension of the anastomosis needs to be appropriate. When the suture is completed, the "widening factor" of the portal vein should also be retained. The transplanted liver blood flow is then opened. The hepatic artery was reconstructed with a 7-0 Prolene suture, and the hepatic artery was opened. Successful hepatic artery reconstruction is critical to the function of the transplanted liver and the influence of bile duct. There is a variety of suturing methods: A. Separate the hepatic artery, the gastro duodenal artery and the common hepatic artery, and the three confluences were trimmed as a hornline, which was anastomosed with the donor's common hepatic artery. B. When the gastroduodenal artery is relatively large, the donor's celiac trunk artery can be anastomosed at the junction of the recipient's gastroduodenal artery and the proper hepatic artery. C. If there is an anatomic abnormality in the hepatic artery of the donor, the hepatic artery should be trimmed, shaped, and then anastomosed with the recipient's hepatic artery. D. When the recipient's hepatic artery has an anatomic abnormality, the donor's celiac trunk artery can be directly anastomosed to the abdominal aorta above the recipient's celiac trunk artery. Finally, the bile duct was reconstructed with a 6-0 or 7-0 Prolene suture. T tube is drawn through the recipient's common bile duct. If the recipient's common bile duct is very small, it is recommended to perform bile duct jejunum Roux-en-Y anastomosis. The graft gallbladder was then removed [34–36] (**Figure 3**).

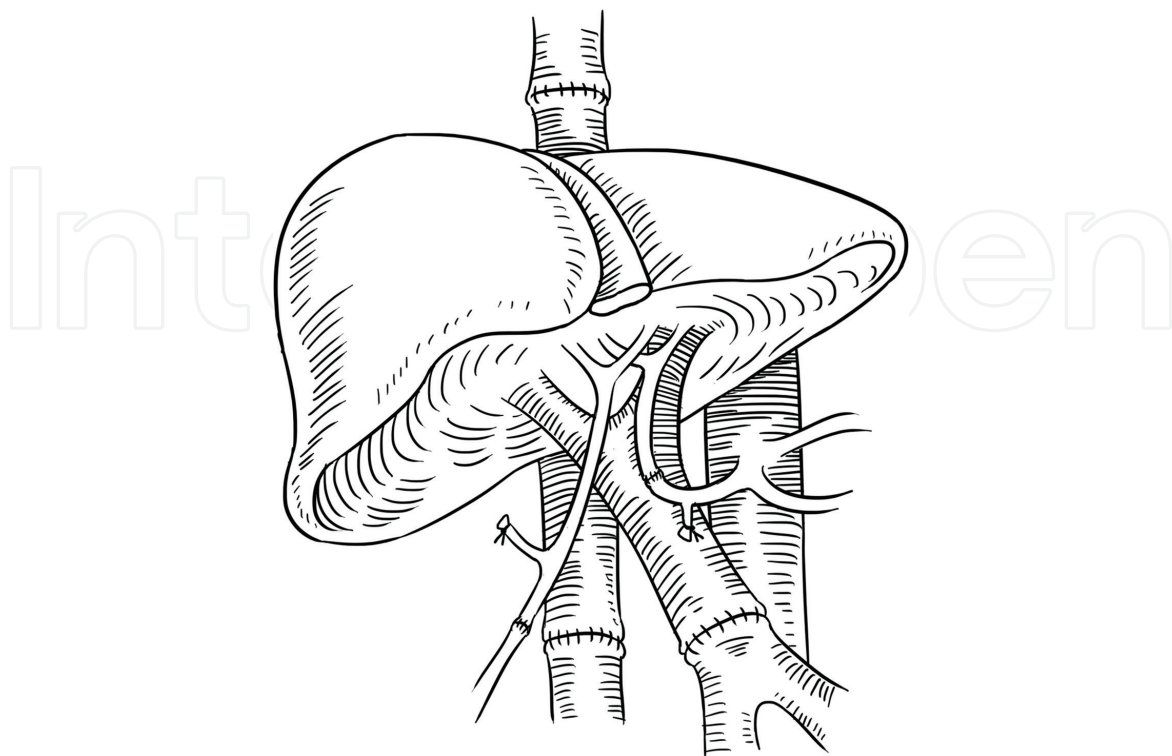


Figure 3.
The classical orthotopic liver transplantation.

4.2 Piggyback liver transplantation

Piggyback liver transplantation, different from the classical liver transplantation, is that the infrahepatic inferior vena cava is not necessary to be anastomosed, which thereby is clamped, and the suprahepatic inferior vena cava of the donor liver is anastomosed directly to the recipient's hepatic vein or laterally to the recipient's inferior vena cava [37, 38]. This procedure simplifies the operation of donor liver implantation, and only partially blocks the inferior vena cava during operation. It has little effect on hemodynamics in patients in nonhepatic phase, does not require venous bypass, and has less renal damage. However, this traditional piggyback liver transplantation procedure has a problem that the graft liver would swing in the abdominal cavity and cause vascular torsion, and the circulation return will be affected. At present, the modified piggyback procedure used in most mature transplant centers in China is below: inferior vena cava (VC) shaping: (1) recipient VC: according to the patient's hepatic vein anatomy, the hepatic veins (left, middle and right) are split from the middle and trimmed into a continuous opening, and the front wall of inferior vena cava is also trimmed longitudinally, and all these together form an inverted triangular incision. (2) Donor VC: the posterior wall of the donor superior inferior vena cava was cut longitudinally with the two up angles of hepatic superior VC, also trimmed into an inverted triangular incision. Finally, these two inverted triangular incisions are anastomosed (**Figure 4**). The main purpose of this piggyback procedure is to enlarge the anastomosis of the outflow tract, avoid the anastomotic torsion, and reduce the incidence of postoperative outflow obstruction [39, 40].

4.3 Reduced-size liver transplantation and split liver transplantation

In our clinical work, the whole liver transplantation cannot meet the needs of liver transplantation in children and some small-weight adults, because these patients cannot accommodate the large-size liver in the abdominal cavity, which is why the reduced-size liver transplantation came into being [41]. Reduced-size liver transplantation actually includes reduced-size cadaveric liver transplantation, split liver transplantation, and partial living liver transplantation. By 2010, 86 transplant centers in 30 provinces of Mainland China had undergone reduced-size liver transplantation. The donor liver for children with reduced-size liver transplantation

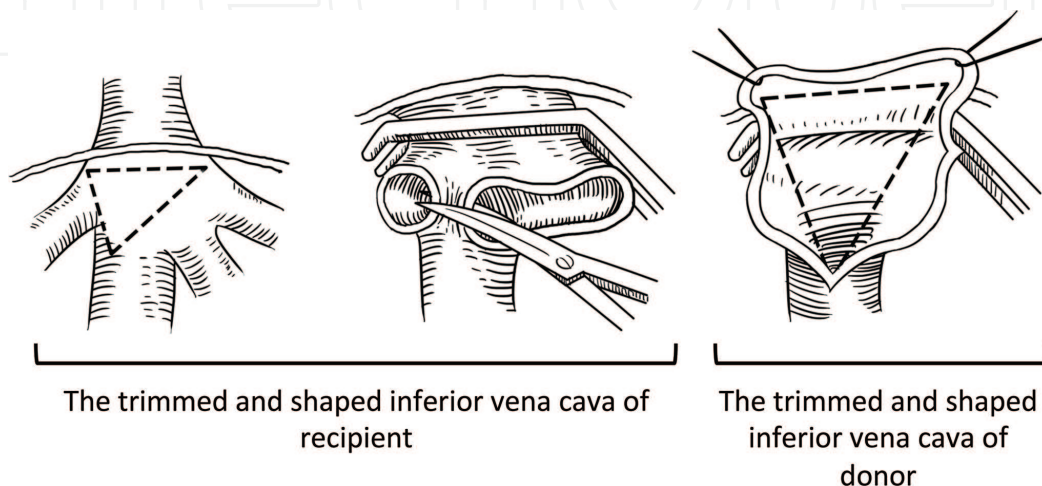


Figure 4.
The two “inverted triangular” incisions of donor and recipient’s inferior CV.

is mainly the left liver. Split liver transplantation refers to the separation of an adult cadaveric donor liver into two transplanted livers with independent structures and functions by two-way technique, which is transplanted to two recipients. The conventional method is to detach the liver along the Cantlie line and obtain the intact right and left hepatic livers, respectively [42, 43].

4.4 Auxiliary liver transplantation

Auxiliary liver transplantation refers to retaining the recipient's liver or part of the liver, implanting the donor's whole liver or part of the liver into the recipient, so that patients with liver failure can receive life support or compensate for the metabolism, detoxification, and other functions of the original liver deficiency [44]. It is divided into auxiliary ectopic liver transplantation and auxiliary orthotopic liver transplantation. The auxiliary liver transplantation has the following advantages: (1) patients with acute liver failure can pass the dangerous period, and (2) for congenital metabolic liver disease, implantation of a small amount of liver can meet the patient's metabolic needs, (3) under surgical trauma, the recipient has no nonhepatic period, (4) the required liver volume is small, increase the donor liver source, and (5) for some patients within inability to tolerate the orthotopic whole liver transplantation, auxiliary liver transplantation should be performed first, and then the orthotopic liver transplantation should be considered after the recovery of the body function.

4.5 Living donor liver transplantation

Living donor liver transplantation has developed rapidly due to the severe lack of cadaver donor livers. In early years, the left half liver was used as the donor liver for living donor liver transplantation between adults, but for large-size recipients, the left half liver could not meet the demand of the recipient, so the right half liver was gradually used as the donor liver. The procedure of living donor liver transplantation is basically the same as that of orthotopic liver transplantation, but there are many differences in the reconstruction of hepatic vein, portal vein, hepatic artery, and bile duct.

4.5.1 Hepatic vein reconstruction

In living donor liver transplantation, the right half liver as donor liver is divided into two types, including the hepatic middle vein and not including the hepatic middle vein. Whether the branches of the hepatic middle vein in hepatic segment V and VIII should be reconstructed in living donor liver transplantation of right half liver is controversial. Different liver transplantation centers have proposed different reconstruction criteria.

In the literature, B ultrasonography was used to assess congestion in the right half liver donation after temporary occlusion of the hepatic artery and the hepatic middle vein. Criteria for reconstruction of hepatic middle vein include: (1) after removing the area of the congestion, the remaining transplanted liver volume was less than 40% of recipient's standard liver volume. (2) When hepatic artery and hepatic middle vein branches are blocked, the area of the donor liver congestion is more than half of the area of the right anterior lobe. (3) Noncongestive graft-to-recipient weight ratio (ncGRWR) < 0.65%.

The diameter of the branches of the hepatic middle vein is also one of the criteria for reconstruction. The diameter of the branch of the hepatic middle vein in hepatic segments V and VIII was more than 7 mm, which was considered as the boundary of whether to reconstruct the branch of the hepatic middle vein. Kim et al. suggested

that when the hepatic middle vein branches of segments V and VIII were larger than 5 mm in diameter, the hepatic middle vein branches needed to be reconstructed, and they tried to make the area of congestion less than 10% of the total graft volume [45].

In living liver transplantation without hepatic middle vein, the grafts used for reconstruction of hepatic middle vein include the recipient's own great saphenous vein, superficial femoral vein, umbilical vein, portal vein, artificial blood vessel, iliac vein or iliac artery cryopreserved from allogeneic tissue, and also venous patch to reconstruct the branch of hepatic umbilical vein. Liver transplantation center of the first Hospital of Zhejiang University carried out a preliminary study on 131 cases of living right donor liver transplantation without hepatic middle vein. The graft vessels were reconstructed by autologous portal vein, hepatic vein, great saphenous vein, or cryopreserved iliac artery to reconstruct the right hepatic vein branches V and VIII without hepatic middle vein [5].

4.5.2 Portal vein construction

After the portal veins of donor liver and recipient were in line with their caliber and length, they were performed with an end-to-end anastomosis. When the recipient of living donor liver transplantation has portal vein sclerosis or narrow problems, we anastomose the donor portal vein directly to the confluence of the recipient's splenic vein and superior mesenteric vein. If the donor portal vein does not have enough length, portal vein transplantation can be performed.

4.5.3 Hepatic artery reconstruction

The reconstruction of hepatic artery in living donor liver transplantation is directly related to the success or failure of transplantation. The diameter of donor hepatic artery is only 2–3 mm. Arterial anastomosis under direct vision has been a difficult problem for many surgeons. Until the application of microsurgical vascular anastomosis under microscope, the incidence of hepatic artery thrombosis decreased from 25 to 0–3.8%. However, this technique is difficult to master and is influenced by arterial variations, donor-recipient caliber matching, and recipient hemodynamics. Therefore, it is important to establish a stable microsurgical team and mature arterial anastomosis methods in various transplantation centers.

4.5.4 Bile duct reconstruction

- (1) Bile duct shaping: within 3 mm, the combination of adjacent hepatic duct opening can be considered.
- (2) The principle of one-time suture insertion: in the so-called one-time suture process, the noninvasive suture needle from the recipient of the bile duct to the donor of the hepatic duct needle, must be completed at one time
- (3) The basic bile duct end to end anastomosis technique: the posterior wall is continuously sutured, and the anterior wall is discontinuously sutured.

With the improvement of liver transplantation anesthesia, surgical techniques and perioperative management, the efficacy and survival rate of liver transplant patients have been significantly improved. With the accumulation of surgical experience, we need promotion of our surgical techniques. However, in view of the current situation of organ shortage in China, how to choose the most suitable

liver transplantation for different indications, preoperative status, and physiological and anatomical features still needs to continuously explore and summarize the experience.

5. Complications after liver transplantation

5.1 Early complications after liver transplantation

5.1.1 Postliver transplant hemorrhage

Intraabdominal hemorrhage postliver transplantation is an early serious complication, and continues to be a prognostic factor for transplant success. Statistically, intraabdominal hemorrhage postliver transplantation occurs in 5–21% of recipients [46], while incidence rate of this complication in China is 5–15.3% [47, 48]. Reasons for intraabdominal bleeding after liver transplantation include coagulopathy, portal hypertension, massive transfusion of stored blood, primary graft non-function/poor graft function, anastomotic leakage, as well as blood vessel damage by abdominal infection. Coagulopathy is one of the most important risk factors for postoperative early hemorrhage. Diffuse hemorrhage postreperfusion often occurs in recipients with coagulopathy, especially in those with poor liver function or lack of clotting factors. In addition, massive transfusion of stored blood leads to circulatory overload, abnormal coagulation and acid-base imbalance, resulted with aggravated hemorrhage symptoms. Surgical bleeding is related with operation of liver resection or graft harvesting. Furthermore, early hemorrhage may also occur as a result of blood vessel damage caused by anastomotic leakage or abdominal infection. Therefore, keeping normal coagulation function perioperatively, reducing bleeding and achieving effective hemostasis during operation, accurate anastomosis of blood vessels with vascular patency, as well as preventing and controlling infection, can contribute to prevention of this complication.

Therapeutically, correcting the clotting problem via giving blood products and coagulants is usually effective. However, patients with persistent hemodynamic instability, which indicates active hemorrhage, usually require emergency exploratory laparotomy for hemostasis.

5.1.2 Vascular complications

Vascular complications represent one of the most critical complications, and contribute to a major source of morbidity and mortality after liver transplantation. Vascular complications, including hepatic arterial complications, portal vein complications and vena cava complications, threaten outcomes for liver transplant recipients and graft survival. Among the vascular complications, hepatic arterial complications following liver transplantation are the most threatening conditions, including hepatic arterial thrombosis (HAT), hepatic artery stenosis, hepatic artery aneurysm, and hepatic artery rupture.

HAT is a life-threatening complication, as it interrupts blood supply of the allograft and induces early graft loss, long-term graft dysfunction, or recipient death. As the most common hepatic arterial complication, HAT occurs in 2–9% of adult transplants with a higher incidence in pediatric recipients [49, 50]. Risk factors for the development of HAT include technical imperfection with the anastomosis, dissection of the hepatic arterial wall, celiac stenosis or compression by median arcuate ligament, aberrant arterial anatomy, complex back-table arterial reconstruction of the allograft, as well as high-resistance microvascular arterial outflow mediated by rejection or severe ischemic-reperfusion injury. According

to the time of onset, HAT is divided into early HAT and late HAT. Early HAT, diagnosed less than 4 weeks after liver transplantation, shows various clinical manifestations, ranging from fulminant hepatic failure, recurrent biliary sepsis, or delayed biliary leaks to an asymptomatic presentation with abnormal liver function. Compared with early HAT, clinical presentation of late HAT is relatively reduced, varied from increased serum transaminase level with or without cholestasis to liver abscess and biliary complications such as ischemic biliary lesions, cholangitis, bile duct stenosis, or necrosis. Early diagnosis with emergent surgical intervention is lifesaving and contributes to graft survival. Diagnosis of HAT depends on imaging examinations, while surgical exploration can confirm diagnosis. In clinical setting, arteriography is recognized as gold standard for diagnosis of HAT following liver transplantation. Patients with early HAT and fulminant hepatic failure require resuscitation, broad-spectrum antibiotics, artificial liver, and expeditious retransplantation.

Hepatic artery stenosis is one of the most common complications postliver transplantation, with incidence rate ranging from 4 to 11% [51, 52]. This stenosis most commonly occurs in anastomosis site or the kinking of reconstructed artery. Factors associated with hepatic artery stenosis include surgical injury, vasospasm, anastomotic stenosis, high-resistance hepatic artery blood flow mediated by rejection, and cold preservation injury. Clinical presentation varies from abnormal liver function to severe biliary complications. If unrecognized and managed appropriately, hepatic artery stenosis will lead to complete occlusion of hepatic artery or thrombosis, resulting in ischemic infarction and graft failure. Angiography is the gold standard for diagnosis of hepatic artery stenosis. Therapeutically, interventional vascular procedures are current major treatment.

Hepatic artery aneurysm and hepatic artery rupture are rare complications after liver transplantation, with an incidence of 0.3–1% [53, 54]. However, these complications can also threaten patients and grafts.

5.1.3 Biliary complications

The incidence of biliary complications has decreased dramatically because of advances in liver transplantation; however, biliary complication remains the most frequent complications postliver transplantation, with an incidence of 26.92–53.8% [55, 56]. Biliary complication is no longer a major cause of mortality in experienced liver transplantation center, as these complications can be recognized early and revive timely effective management. But biliary complication exhibits impact on patients' life quality, and sometimes it enables development of graft dysfunction. Therefore, biliary complication remains a challenging complication.

Biliary complications include bile leakage, anastomosis stenosis, bile duct ischemic injury, gall-stone formation, and sphincter dysfunction. Bile leakage, either anastomosis leakage or bile leakage after removal of T-tubes, usually occurs early postliver transplantation. Anastomosis stenosis is frequent. Endoscopic therapy and interventional radiology treatment are proven to be effective in treatment of anastomosis stenosis. Bile duct ischemic injury is a major cause of bile leakage, bile duct stenosis, or dilatation, followed by biliary sludge and cholelithiasis. Gall-stone formation is mainly found in donor liver bile duct, but can also be observed in recipient's bile duct. Sphincter dysfunction is a complication hard to diagnose. Among the biliary complications after liver transplantation, bile duct ischemic injury is the most dangerous disease with high mortality. Patients with serious bile duct ischemic injury finally will need retransplantation. Surgical imperfection and bile duct ischemia are the major causes of biliary complication. Accurate bile duct anastomosis without distortion of the bile duct, proper use of T-tube, avoiding excessive trimming of vessels, and protecting blood supply of bile duct will promote

reconstruction of bile duct and reduce bile duct complications after liver transplantation. Immunosuppressants can also contribute to this complication, such as CsA promotes cholestasis and gall-stone formation.

Clinical presentation of biliary complication varies. Patients with bile leakage usually have mild or moderate abdominal pain, with bile drained out from drainage tube or biliary spillage from umbilical incision. Symptoms of serious bile duct stenosis include jaundice in a short time. Early symptoms of patients with bile duct ischemic injury are atypical, sometimes similar to bile leakage, but late symptoms of bile duct ischemic injury like bile duct stenosis. Gallstones may occur secondary to bile duct stenosis, and patients with serious bile duct obstruction usually will have abdominal pain and jaundice.

With advances in imaging and endoscopic therapy, biliary complications can be diagnosed early and interventional treatment has become the first choice for patients with biliary complications after liver transplantation.

5.2 Late complications

With advances in transplant technique, liver transplant recipients achieve a longer life longevity and prolonged graft survival. Meanwhile, late complications postliver transplantation gradually become critical factors of their life quality and graft long-term survival.

5.2.1 Metabolic complications

5.2.1.1 De novo diabetes

De novo diabetes after liver transplantation is critical for outcomes of patients, correlated with a higher incidence of infection or cardiovascular diseases postliver transplantation. And it contributes to graft dysfunction and lower recipients' survival. According to definition of diabetes mellitus from WHO and ADA, de novo diabetes occurs in 9–63.3% patients with liver transplantation [57, 58]. Immunosuppressants, such as corticosteroid use and calcineurin inhibition, are risk factors for de novo diabetes. Appropriate use of immunosuppressant, including dose and duration, is of significance for preventing de novo diabetes postliver transplantation.

5.2.1.2 Hyperlipidemia

Hyperlipidemia is a common complication is solid organ transplantation, which can significantly promote incidence of chronic cardiac diseases in organ recipients. The incidence rate of hyperlipidemia in liver recipients is 45–66% [48, 58, 59]. Elevations of serum cholesterol and triglyceride are common consequences of use of immunosuppressants. Particularly, steroids and cyclosporine are closely associated with higher levels of cholesterol and triglyceride, while sirolimus exerts a stronger impact on triglyceride levels. Life style modifications with diet, exercise, and weight loss are preferred treatments. Besides, HMG-CoA reductase inhibition requires caution, as it may cause hepatotoxicity.

5.2.1.3 Hyperuricemia

Hyperuricemia is common in patients with liver transplantation, which usually occurs in 17–60 months postliver transplantation. The incidence rate of hyperuricemia in patients received liver transplantation is 14–47% [60, 61]. Mechanically,

long-term use of calcineurin inhibitors leads to kidney injury and impairs the capability to clear uric acid, resulted with elevated uric acid levels or gout.

5.2.2 Biliary complications

Although huge advances have been made in liver transplantation, including biliary reconstruction, organ preservation and perioperative management, the incidence of biliary complications after liver transplantation remains high, up to 53.8% [56]. Biliary complications include biliary stenosis, bile leakage, ampulla dysfunction, biliary silt, and gallstone formation. However, biliary stenosis and gallstone formation are major late complications. As biliary reconstruction is recognized as Achilles' heel of liver transplantation, biliary reconstruction technique is strongly correlated with biliary complications. Besides, poor blood supply of hepatic artery and injury caused by donor liver harvest, cold preservation, or reperfusion. Furthermore, infection is also an important cause of biliary complication.

5.2.3 Recurrent disease

Recurrent liver diseases after liver transplantation is a common late complication, including hepatitis B, nonalcoholic fatty liver disease, autoimmune hepatitis, primary biliary cirrhosis as well as primary sclerosing cholangitis; however, the risk and timing of recurrent liver diseases are variable. Of note, recurrent hepatitis B virus (HBV) infection can be prevented in compliant patients with hepatitis B immunoglobulin and anti-HBV drugs. However, poor therapy compliance with irregular immunosuppressants application allows recurrence of HBV infection. In addition, recurrent autoimmune hepatitis or primary biliary cirrhosis rarely cause graft dysfunction or require retransplantation, though there are no proven effective therapies for the treatment of these late complications.

6. Indications for liver transplantation

Liver transplantation is an important option to treat the end-stage liver diseases and aims to prolong the life survival and to improve the quality of life for the patients. In principle, any acute or chronic liver disease, which has no other effective treatment or would cause the death of the patient in a short time, should be the indication to liver transplantation. With the increasing advance of liver transplantation, it can also be performed to improve the quality of life, although the primary liver disease might not be cured. The detail indications include the following:

- (a) Acute liver failure: infections, drug- or toxin-induced liver injury, circulatory disturbance, etc.
- (b) Liver cirrhosis: hepatitis cirrhosis, alcoholic cirrhosis, cholestatic cirrhosis, etc.
- (c) Liver neoplasms: hepatocellular carcinoma, cholangiocarcinoma, etc.
- (d) Metabolic disorders: Wilson disease, alpha-1 antitrypsin deficiency, hereditary tyrosinemia, glycogen storage disease, etc.
- (e) Others: autoimmune hepatitis, polycystic liver, trauma, etc.

The contraindications, although decreasing with the development of liver transplantation, generally include the following:

- (a) Malignancy outside of the liver and cannot be radical cured
- (b) Uncontrolled sepsis
- (c) Excessive drinking or drug abuse
- (d) Severe cardiopulmonary, encephalic or renal complications
- (e) Acquired immunodeficiency syndrome (AIDS)
- (f) Persistent nonadherence with medical care
- (g) Uncontrolled psychological or mental diseases

According to the China Liver Transplant Registry (CLTR), the most common disease leading to liver transplantation from DCD was liver neoplasms (42.98%), following by liver cirrhosis (41.05%) and acute liver failure (9.07%) from 2010 to 2017. The model for end-stage liver disease (MELD) or MELDNa score is applied to evaluate the status of the patients and to determine the priority of recipients and the allocation of organs by the CLTR.

6.1 Liver transplantation for hepatocellular carcinoma

It was estimated that more than 300,000 patients died of hepatocellular carcinoma (HCC) in China, which accounted for half of the total deaths all over the world [62]. The main reason was the high rate of hepatitis B virus (HBV) infection. In recent years, liver transplantation has become an effective treatment to HCC, in which the en bloc resection of the tumor can be achieved and the cirrhotic liver can be replaced. According to the CLTR, HCC was one of the most common causes leading to liver transplantation from DCD in China, with the 1- and 5-year survival rate of 82.77 and 59.18%, respectively (CLTR, 2010–2017). With the large number of practices, the Chinese experience was summarized.

6.1.1 Indications

The Milan criteria (a single lesion ≤ 5 cm, or up to three lesions, all ≤ 5 cm; no macrovascular invasion; no regional nodal or extrahepatic distant metastases) are the benchmark for selection of appropriate candidates for liver transplantation due to HCC. However, few patients in clinical practice could fully meet these strict criteria so that they might lose the opportunity of transplantation. Even expanded to the University of California at San Francisco (UCSF) criteria or Pittsburgh criteria, the number of candidates meeting the criteria is still limited in China. During the past decades, many Chinese scholars tried to expand the boundary of the indication, and concluded the criteria suitable for the Chinese situation.

(1) Hangzhou Criteria.

The Hangzhou Criteria were proposed by Prof. Shu-Sen Zheng, etc. in 2008 [63]. The criteria contained one of the two following items: (a) total tumor diameter ≤ 8 cm; (b) total tumor diameter > 8 cm, with histopathologic grade I or II and preoperative alpha fetoprotein (AFP) level ≤ 400 ng/mL, simultaneously.

Obviously, Hangzhou Criteria significantly expanded the candidate pool, and the reported 5-year survival rate was comparable to that of patients fulfilling Milan criteria (72.3 versus 78.3%, $P > 0.05$). More importantly, these criteria not only considered the tumor size, but also included the histopathologic grading and serum AFP level, which better reflected the biological characteristics of the tumor and predicted the prognosis. In Chinese guidelines of liver transplantation to HCC 2014, Hangzhou criteria were recommended [62].

(2) Shanghai Fudan Criteria.

Compared to Milan criteria, Shanghai Fudan Criteria expanded the indications on the tumor size: single lesion ≤ 9 cm in diameter, or no more than three lesions, the largest ≤ 5 cm, with a total tumor diameter ≤ 9 cm. There was no significant difference in 1, 2, 3-year survival rates and recurrence-free survival rates between Milan criteria and Shanghai Fudan Criteria [64].

6.1.2 Downgrade treatment of HCC before transplantation

The early diagnosis of HCC in China is limited so that a large number of patients are diagnosed with advanced HCC. Even if the expanded criteria were applied, many patients still lose the opportunity of transplantation. For patients without macrovascular invasion or extrahepatic distant metastases but beyond the current indications, downgrade treatments are proved effective to make part of the patients available to liver transplantation [65, 66]. The main downgrade treatments include transcatheter hepatic arterial chemoembolization (TACE), and local ablation therapy (radio-frequency ablation, microwave ablation, cryoablation and percutaneous ethanol injection) [62]. The combination of multiple therapies may achieve better efficacy.

6.1.3 Antivirus treatment

It was reported that over 90% of the HCC patients in China were related to the HBV infection. The high HBV load would increase the risk of tumor recurrence so that antivirus treatment is recommended pre-, intra- and posttransplantation. Before transplantation, the candidate should receive the nucleotide analogues (NAs) like entecavir and tenofovir as soon as possible to reduce the HBV load. During the nonhepatic phase in operation, the hepatitis B immunoglobulin (HBIG) is administered to block the viral transmission. After transplantation, the combination of NAs and low-dose of HBIG is recommended. HBV vaccines are given to some recipients posttransplantation, but the effects are still controversial.

6.1.4 Immunosuppression and prevention of tumor recurrence

The triple immunosuppressive regimens (CNI + MMF + corticosteroids) still consist the footstone of immunosuppression for HCC liver transplantation. Although CNI is reported as an independent risk factor for tumor recurrence, complete drug withdraw is not recommended. The mammalian target of rapamycin (mTOR) inhibitor like sirolimus or everolimus, which has the potential for the inhibition of tumor growth, has been applied with the induction of IL-2 receptor antagonist (IL-2RA) in some centers in China. What is advocated currently is the individualized regimen based on the individual's immune status. The main regimens used in clinic include the followings: (1) CNI + MMF + corticosteroids, (2) IL-2RA + sirolimus/everolimus + MMF + corticosteroids, and (3) IL-2RA + sirolimus/everolimus + MMF [62].

The recurrence of HCC is the main hinder for the long-term survival of these patients. Reportedly, the recurrence rate reached 20.0–57.8%; thus, it is critical to prevent the recurrence posttransplantation [67, 68]. The effective treatments include 131I-labeled metuximab, sorafenib, and chemotherapy. The choice depends on the morphological features, neoplasm staging, gene typing, histological grade, and biological characteristics of the tumor.

6.2 Liver transplantation for viral hepatitis

In China, viral hepatitis is mostly caused by HBV infection, and the prevalence of HCV is low. National Hepatitis Serum Epidemiology Survey [69, 70] showed that the HBsAg carrier rate in China's general population aged 1–59 years was 7.18%, while the anti-HCV prevalence rate was about 0.43% [71]. Based on this, there are about 93 million people with chronic HBV infection [72], and for HCV infection, this data are 5.6–10 million [73]. Patients with end-stage chronic hepatitis B have become the main population of liver transplant recipients in China. According to the China Liver Transplant Registry (CLTR) 2015 statistics, patients with viral hepatitis-associated liver disease accounted for 74.79%, and hepatitis B virus (HBV)-related liver disease patients accounted for 71.25%. Therefore, the following mainly describes the problems faced by liver transplantation in the treatment of hepatitis B virus-associated liver disease.

6.2.1 Indications

Similar to other indications for liver transplantation in chronic liver disease, liver transplantation should be considered when the following conditions occur:

- (a) Patients undergoing systemic medical treatment, but the expected survival time is shorter than 2 years
- (b) Recurrent esophageal varices bleeding after endoscopic treatment
- (c) Refractory ascites
- (d) Chronic hepatic encephalopathy
- (e) Occasional bacterial peritonitis
- (f) Liver cancer that occurs on the basis of hepatitis B

6.2.2 Prevention of hepatitis B virus recurrence after transplantation

The choice of patients with viral liver disease as recipients of liver transplantation was once controversial. The main reason is the high recurrence rate of viral hepatitis after transplantation. Although the liver transplantation completely removes the diseased liver, the extrahepatic tissue and blood are inevitably left with a small amount of residual virus, which causes the reinfection of HBV in liver. It was reported that the recurrence rate of hepatitis B after liver transplantation for hepatitis B-related liver disease is up to 70–80% in China [74, 75].

The recurrence of hepatitis B is affected by a variety of factors. The use of immunosuppressive agents, preoperative HBV at high replication levels, and without other viral coinfections will increase the rate of postoperative hepatitis B recurrence. In addition, HBV genotypes can also affect the recurrence of hepatitis B after transplantation [76]. Among them, the gene D has the highest recurrence rate.

The study found that patients with HBV reactivation after liver transplantation have more serious hepatocyte damage and faster fibrosis progression [77]. In the short term, it can rapidly develop into fibrous cholestatic hepatitis, cirrhosis, or acute liver failure, resulting in the death of the recipient. Therefore, prevention and treatment of recurrent hepatitis is particularly important.

The practice guideline on prophylaxis and treatment of hepatitis B for liver transplantation in China recommended that HBV DNA should not be detected as much as possible or the HBV DNA level should be minimized before transplantation [78]. Therefore, antiviral drugs such as high-resistance gene barrier NAs (ETV or TDF) should be routinely applied before transplantation. In the liver transplantation, the fully use of HBIG to neutralize HBsAg is a key measure to prevent HBV infected the new liver. After transplantation, the “NAs combined with low-dose HBIG” regimen should be used, which could significantly reduce the risk of hepatitis B recurrence.

HBsAg, HBV DNA, and anti-HBs titers should be frequently detected within 6 months after HBV-related liver transplantation to monitor HBV replication and reinfection, and to determine the dose and frequency of HBIG use. During follow-up, the recipient's anti-HBV titer, which suddenly decreased or wore off, often indicates the recurrence of HBV, so that the therapeutic regimen should be adjusted.

6.2.3 Treatment of HBV reinfection/emerging infection after liver transplantation

HBV reinfection/emerging infection after liver transplantation progresses relatively rapidly, which can lead to liver failure and even death of patients. It is necessary to carry out targeted evaluation and treatment as soon as possible, aiming to rapidly inhibit HBV replication in the short term and to avoid serious liver injury. After the HBV reinfection/emerging infection, HBIG should be discontinued and treated with high-resistance gene barrier NAs, and HBV-resistant mutant genes and regulatory drugs should be tested. Intensive monitoring of HBV DNA levels and liver injury indicators should be performed. When the liver injury indicators are abnormal, the pathological examination of the liver tissue should be considered, and the degree of liver injury and disease progression comprehensively determines whether the liver transplantation should be evaluated again.

In the selection of NAs drugs, in addition to the resistance mutation factors, some scholars believe that HBV genotype should also be a reference factor. According to the difference of HBV gene sequence, it can be divided into 10 genotypes of A-J [79]. In China, HBV infection is mainly B/C type [70]. Numerous studies have shown that the antiviral efficacy of NAs is affected by the HBV genotype. Among them, Chinese literature reports that the antiviral efficacy of NAs is significantly different between HBV gene type B and type C [80–83]. It is summarized in the following table.

At present, the mechanism by which different genotypes of HBV react differently to antiviral drugs is still unclear. Moreover, some scholars have found that the genotype does not affect the antiviral efficacy of the drug, and may be related to the different genotype detection methods used by different researchers and the sample size. In conclusion, there is no consensus on the effect of HBV genotype on the antiviral efficacy of NAs. The specific mechanism and its correlation require further clinical observation and basic experimental research to guide clinical antiviral drug treatment and efficacy judgment (**Table 2**).

6.3 Liver transplantation for alcoholic liver disease

Alcoholic liver disease is caused by long-term heavy drinking. In the early stage, it usually manifests as fatty liver, which in turn can develop into alcoholic hepatitis,

NA species	The difference of the curative effect
ETV/entecavir	B > C
LAM/lamivudine	B > C
ADV/adefovir dipivoxil	No significant difference
TDF/tenofovir disoproxil fumarate	No significant difference
LdT/telbivudine	B > C

Table 2.
NAs make a different curative effect in different HBV genotypes.

liver fibrosis, and cirrhosis. In severe alcohol abuse, extensive hepatocyte necrosis can be induced and even cause liver failure.

According to the 2014 World Health Organization report, the per capita alcohol consumption of Chinese people over the age of 15 is about 6.7 L/year, and 4.8% of the population has alcohol use disorders, including 9.1 and 0.2% for men and women, respectively. Overall, the proportion of Chinese drinkers and the prevalence of alcohol-related liver diseases are on the rise. According to epidemiological survey data of alcohol related liver disease in some provinces, the prevalence of alcohol-related liver disease is 0.50–8.55% [84–86]. From 2000 to 2004, the proportion of alcohol-related liver disease in hospitalized patients with liver disease had increased from 2.4 to 4.3% [87]. The proportion of patients with alcoholic cirrhosis in all patients with cirrhosis increased from 10.8% in 1999 to 24.0% in 2003 [88, 89]. Alcohol-related liver disease has become one of the most important chronic liver disease in China [90].

6.3.1 Indications

It is generally believed that liver transplantation should be considered when patients with alcoholic liver disease meet the following conditions:

- (a) Fail to respond to medications.
- (b) Liver lesions are severe or end-stage liver disease manifests.
- (c) Suspected small liver cancer is present (single nodule <5 cm, 1–3 nodules <3 cm).
- (d) No serious alcohol damage in other organs.
- (e) After comprehensive factor evaluation, it is determined that there is a lower post-operative recovery of alcohol abuse.

6.3.2 Assess the risk of relapse after transplantation

Studies have shown that the 3-year survival rate of alcoholic patients after liver transplantation is significantly lower than that of nonalcoholic groups [91]. Therefore, in patients with alcoholic liver disease, whether or not successful alcohol withdrawal after liver transplantation becomes the key. Predictors of longer postoperative alcohol withdrawal include: (1) the patient recognizes the severity of alcoholism. (2) The patient has a stable residence. (3) The patient has a stable occupation. (4) The patient has at least one closely related patient to provide spiritual support.

The following factors represent a higher risk of restocking. (1) The patient has had psychological or mental disorders. (2) The patient has unstable personality characteristics. (3) The patient has repeatedly failed to stop drinking. (4) The patient has the

habit of drug abuse. (5) The patient's social relationship is isolated. In practice, effective preventive education measures can significantly reduce the patient's redinking after surgery. At present, the Chinese guidelines are feasible for liver transplantation in patients with alcoholic liver disease who require alcohol withdrawal for 3–6 months before liver transplantation and no serious alcohol damage in liver.

6.4 Liver transplantation for metabolic diseases

Liver is an important metabolic organ of the human body. Therefore, congenital metabolic diseases caused by defects in certain key metabolic steps are often associated with the liver damage. Some genetic metabolic diseases are manifested in liver disease in infants or children. As the disease progresses, nerves, kidneys, heart, bones, vision, hearing, and skin mucosa are damaged. Liver diseases can also aggravated, leading to cirrhosis and liver failure. These diseases are collectively referred to as hereditary metabolic liver disease.

There are many kinds of genetic metabolic diseases, and the etiology is complicated, 50–60% in childhood. At present, there are more than 600 kinds of hereditary metabolic liver diseases, including carbohydrate metabolism disease, amino acid metabolism disease, fatty acid metabolism disease, organic acid metabolism disease, mitochondrial liver disease, lysosomal disease, peroxisome disease, and metal. There are nine categories of metabolic disorders and 1-antitrypsin deficiency.

Liver disease progresses to advanced cirrhosis or liver failure and requires liver transplantation. According to CLTR, 0.69% of the liver transplantation from DCD is caused by hereditary metabolic liver diseases. In living donor liver transplantation, the rate is 4.13%.

The clinical manifestations of genetic metabolic diseases are diverse, and the symptoms are often not limited to the liver. Since some hereditary metabolic liver diseases often involve multiple organ systems, liver transplantation cannot solve the lesions outside the liver, leading to a poor prognosis. There are certain limitations in liver transplantation in this respect. For example, the effect of simple liver transplantation on patients with progressive familial intrahepatic cholestasis type 1 is not ideal. For these diseases, it is often necessary to cooperate with other treatments. For example, for hyperglycemia, liver transplantation can only improve the clinical symptoms, and patients can continue to excrete succinylacetone in the urine after surgery. Therefore, some cases need to be combined with liver and kidney transplantation to correct metabolic abnormalities.

7. Immunosuppressants for liver transplantation

With the rapid development of liver transplantation technology, immunosuppressive drugs and drug regimens have emerged in endlessly, playing an increasingly important role. Looking back, medical pioneers had to use crude technical means such as whole-body x irradiation. Until the advent of cyclosporine, liver transplantation has gradually become the main stream of treatment for liver failure. Today, drugs like azathioprine have almost withdrawn from the stage of history. More and more novel immunosuppressants and different strategies are coming into view. Understanding each agent's potency and deficiencies is an essential part of clinical practice. No immunosuppressant is universally applicable yet. Patients with renal impairment, malignancy, or autoimmune diseases may need specific agent or regimen. Therefore, individualized treatment is essential. Here, some commonly used immunosuppressants will be briefly introduced and discussed. Emphasis will be placed on the clinical application, rather than the mechanism of agents (**Table 3** and **Figure 5**).

7.1 Calcineurin inhibitors

Cyclosporine and tacrolimus are two well-known calcineurin inhibitors (CNIs). Both of them are discovered from the soil fungus and are mechanistically similar. They can suppress the immune system by inhibiting interleukin 2 (IL2) gene transcription. Cyclosporine's effect is mediated by cyclosporine's association with cyclophilin, while the tacrolimus's effect is mediated by a specific interaction with FK-binding protein-12 (FKBP12), both of which can result in inhibition of the calcium/calmodulin-dependent phosphatase complex calcineurin, hence the designation "calcineurin inhibitor" (or CNI). An important distinction is that the immunosuppressive potency of tacrolimus is estimated to be 100-fold greater on a molar level. Due to their powerful capacity in reducing acute rejection, the CNIs have been playing an important role in immunosuppression regimens postliver transplantation. As it should be noted that most recent trials use tacrolimus monotherapy or tacrolimus-based therapy as the control group, suggesting that tacrolimus is considered the standard against, which other immunosuppressants are compared.

Despite the potency of CNIs, some serious problems remain. The CNIs may have close relationship with renal toxicity, HCV reinfection, hepatocellular carcinoma recurrence, and some other negative effects [92–94]. So how to use CNIs properly in liver transplantation is a conundrum. At present, to perform therapeutic drug monitoring to reduce the chance of overdosing is necessary, but not enough. The only reasonable step when facing those complicated cases is to minimize or eliminate CNI use.

7.2 Antimetabolites

As for antimetabolites, what is popular now is mycophenolate mofetil (MMF; Hoffmann La Roche, Basel, Switzerland), which is a prodrug of mycophenolic acid (MPA). It takes effect through inhibiting inosine-59-monophosphate dehydrogenase (IMPDH), an important enzyme for de novo synthesis of guanosine nucleotides. Thanks to Sollinger, MMF was brought to the clinic in the early 1990s and used as an immunosuppressant from then on.

Another prodrug of MPA being used clinically is referred to as enteric-coated mycophenolate sodium (ECMPS; Novartis, Basel, Switzerland). Different from MMF, EC-MPS is not rapidly absorbed in the stomach; it is a delayed-release drug formulation that allows release of MPA in the small intestine via a pH-dependent dissolution. The research and development of EC-MPS was trying to solve the well-known gastrointestinal side effects of MMF. However, things are not as smooth as imagined. Studies have not demonstrated fewer side effects with EC-MPS [95].

Due to the renal toxicity of CNI, MMF and EC-MPS are playing an increasing potential role in liver transplantation as they basically have no nephrotoxicity. Several studies have now shown that MMF and EC-MPS are superior to CNIs in terms of renal function, at the cost of a higher rejection rate [96]. For now, compromise is inevitable in such situation. Regimens like "MMF/EC-MPS + low dose CNIs" are acceptable [97].

As mentioned above, MMF and EC-MPS are not without side effects. Both gastrointestinal disorders and hematological suppression are concerns that cannot be ignored.

By the way, azathioprine (AZA) is another antimetabolite that has left an important part in the history of liver transplantation. Though its role for preventing rejection has been almost completely replaced by MMF/EC-MPS, some researches demonstrated that AZA may have some kind of anti-HCV effects [98, 99].

Immunosuppressants		Action	Merits	Demerits
T cell activation inhibitors	Cyclosporine	Inhibits calcineurin via cyclophilin, blocking IL2 transcription	<ul style="list-style-type: none"> • Reliable antirejection effect • Rich experience in using 	<ul style="list-style-type: none"> • Renal toxicity • Malignancy • Diabetes, fibrosis...
	Tacrolimus	Inhibits calcineurin via FKBP12, blocking IL2 transcription		
T cell proliferation inhibitors	MPA prodrugs	IMPDH inhibitor: enzyme required for de novo synthesis of guanosine nucleotides, required for lymphocyte proliferation	• Low renal toxicity	<ul style="list-style-type: none"> • Acute rejection • Gastrointestinal side effects
	mTOR inhibitors	mTOR blockade prevents IL2-induced T cell proliferation	• Less renal toxicity	<ul style="list-style-type: none"> • Wound healing↓, mouth ulcers, hyperlipidemia
	Azathioprine	Inhibits purine synthesis, thereby blocking immune cell proliferation	<ul style="list-style-type: none"> • Cheap • Possible anti-HCV effects 	<ul style="list-style-type: none"> • Relative weak immunosuppression

Note: AZA: azathioprine.

Table 3.
Comparison of common immunosuppressive agents.

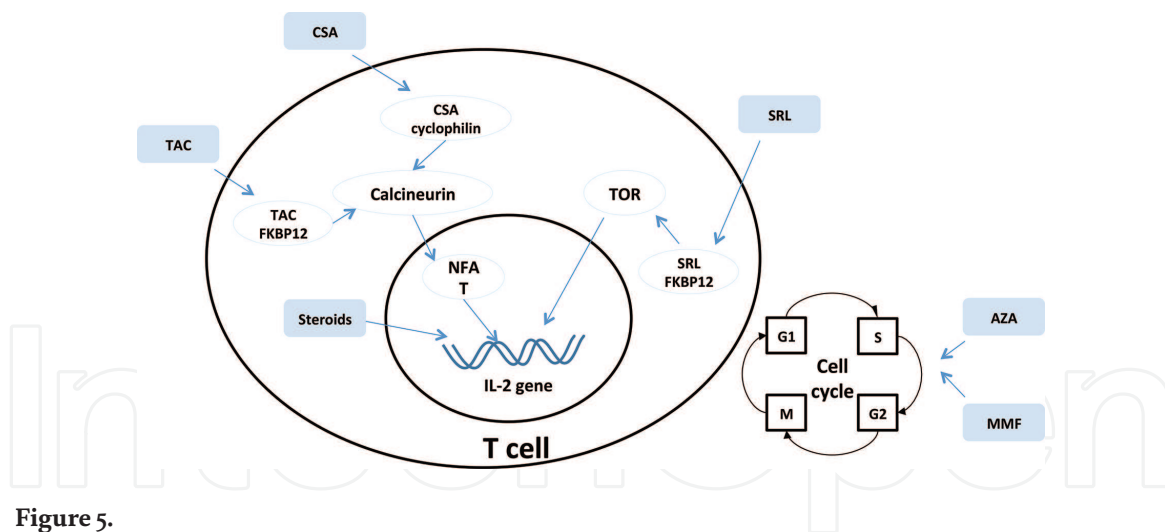


Figure 5.
The mechanism of common immunosuppressive agents.

7.3 mTOR inhibitors

Mammalian target of rapamycin (mTOR) inhibitors include sirolimus (rapamycin; Wyeth) and everolimus (a rapamycin derivative; Novartis). Rapamycin was first discovered in soil from Easter Island (Rapa Nui). Researchers were trying to find its fungi inhibiting ability while accidentally found its immunosuppressive effect. Rapamycin can bind to FKBP12 and form FKBP12 immunosuppressive complex, which can bind to and inhibit the activity of mTOR, thus inhibiting the development of G1 to S phase in cell cycle. Unlike the CNI effects, rapamycin allows T cell activation, but prevents cells from proliferating in response to IL2.

mTOR inhibitors have been approved for use in renal and heart transplantation in combination with CNIs, but not in liver transplantation so far. The use of mTOR inhibitors may cause several adverse reactions:

- (a) It may be related to the development of early posttransplant hepatic artery thrombosis, though not confirmed [100, 101].
- (b) It may elevate blood lipids (cholesterol).
- (c) It may cause wound-healing delays, leg edema and mouth ulcers.
- (d) However, this is not to say that mTOR inhibitors have no advantage in liver transplantation.
- (e) It may reduce early renal dysfunction compared to CNIs.
- (f) It may promote liver allograft tolerance compared to CNIs [102, 103].
- (g) It has antitumor effects compared to CNIs [104, 105].
- (h) It may have antifibrosis effect [106].

All in all, although mTOR inhibitors are not approved for use in liver transplantation yet, they have good reasons for further investigation.

7.4 Steroids

No doubt, steroids have made great contributions through the development of liver transplantation. For many years, they have been fighting against rejection.

While as always the case, their utilization today is controversial. On one hand, corticosteroids have a wide range of immunosuppressive properties:

- (a) Inhibit arachidonic acid metabolism
- (b) Affect antigen presentation by dendritic cells
- (c) Inhibit IL1-dependent lymphocyte activation by decreasing IL1 transcription

Their broad spectrum of effects provides excellent anti-inflammatory activity that often reverses ongoing allograft rejection.

Of course, their side effects are also well known such as diabetes, hypertension, osteoporosis, obesity, etc. Besides, researches also suggested that high-dose steroids may exacerbate HCV infection and fibrosis, especially when used as pulse therapy for antirejection treatment [107]. Thus, how to use steroids in a proper way is still a pending problem. A variety of steroid-free/minimization immunosuppressive protocols in liver transplantation are under evaluation [108].

7.5 Other promising immunosuppressants or therapy

Due to space limitations, we did not talk about biologic agents like ATG and basiliximab, and will not discuss those promising agents such as belatacept, alemtuzumab and efalizumab, or cellular-based therapy, which may be widely used in liver transplantation in the future. For details, readers can refer to [109].

7.6 Common solutions and suggestions

Tacrolimus-based therapy: “Tac + MMF + steroids” or “Tac + steroids.”

Day 0 (the day of the operation): methylprednisolone 500 mg, intravenous, intraoperative; no Tac.

Postoperation: Tac 0.05 mg/(kg*d), twice, later adjust the dose according to blood concentration; methylprednisolone, gradually decrease the dosage, and on day 7 changed to prednisone 20 mg, oral administration; MMF 1.5–2 mg/d, twice.

About 24–48 hours after Tac administration, blood concentration should be tested, and together with other clinical results adjust the Tac dosage.

Steroids withdrawal strategy: day 0, methylprednisolone 500 mg, intravenous, intraoperative; day 1, 240 mg; then decrease 40 mg every day; day 7, change to prednisone 20 mg, oral administration. 1 month postoperation, start to decrease prednisone dosage, decrease 2.5 mg every 2 weeks. For hepatic cancer and hepatitis C recipients, the process of reducing the dosage should be fast. While for the primary biliary cirrhosis and combined liver kidney transplantation recipients, the process should be slower. In addition, gastric protective drugs should be used when steroids are used.

For better-individualized medication, we have to understand the merits and demerits of each immunosuppressant available for liver transplantation, along with each patient's condition. On this individualized basis, our ultimate goal is to minimize or even eliminate long-term pharmacological immunosuppression in liver transplantation recipients. Though difficult, it is worth the effort.

8. Postoperative follow-up of liver transplantation

Nowadays, with the improvement of the surgical techniques of liver transplantation and the update of immunosuppressive agents, liver transplantation in china

is getting more and more mature, which has already been in line with the international standards, approximately 95% of patients can safely get through the perioperative period and discharge from hospital [110, 111]. With the increasing of cases of liver transplantation and the prolongation of life span, the patients' long-term treatment and follow-up work have been paid more and more attention by experts and related scholars.

The follow-up of liver transplantation is a long and complex work, which is mainly characterized by large data volume, individual differences, and long follow-up period (generally, lifelong follow-up). An efficient and reasonable follow-up system can not only improve the efficiency of the transplant center, but can also increase the rate of survival of patients. With the gradual standardization of liver transplantation, an ideal postoperative follow-up system has become an important indicator of a mature liver transplantation center.

8.1 Meaning of regular follow-up

Through regular follow-up, the clinicians can dynamically observe the rehabilitation, mental state and medication situation of liver transplant recipients, and give necessary guidance and health education. In the follow-up, the clinicians can detect and deal with the complications after liver transplantation in time, improve the quality of life, prolong the survival period after the operation. Because the incidence of tumor after transplantation is higher than that of the general population, especially liver transplantation of HCC patients may lead to tumor recurrence and metastasis, follow-up regularly can promptly detect the tumor and give appropriate treatment. Moreover, follow-up is the need of medical model transformation, which makes up for the shortage of medical resources, is a tracking service and also an active service. In today's China acute contradiction between doctors and patients, follow-up is a very good way of communication, which can make the relationship between doctors and patients more harmonious and understand each other more. Meanwhile, collection of information of the regular follow-up can accumulate valuable experience for clinical and scientific research [112].

8.2 Development and method of follow-up in China

Liver transplantation centers in China are in different stages of development, and each center should choose a suitable follow-up method according to its outpatient follow-up volume and staffing. With the increase of liver transplantation cases, our center has established the database for recipients' management and follow-up since 2002, which is constantly updated and improved. In the early stage of liver transplantation, many centers in China lack a sound follow-up system, which is passive and sporadic. In 2008, China Liver Transplantation Registry (CLTR) came into use, the first liver transplantation scientific registration system in China, which is an intelligent data collection and management system in line with the characteristics of organ transplantation in China [48]. It sets up a good platform for clinical evidence-based medicine and the scientific research and provides patients with high-quality medical service at the same time. In our center, we set specialized transplant clinic and establish a complete follow-up procedure (**Figure 6**). The patients should follow the standard follow-up program in the absence of complications, including outpatient frequency and inspection items of follow-up (see **Table 4**) [113, 114]. Because exceeding or insufficient immunosuppressive agent has a negative effect on graft function, its concentration must be monitored regularly (see **Table 5**). In addition, there is a big problem in China now that all the candidates and recipients are lack of health education related with organ

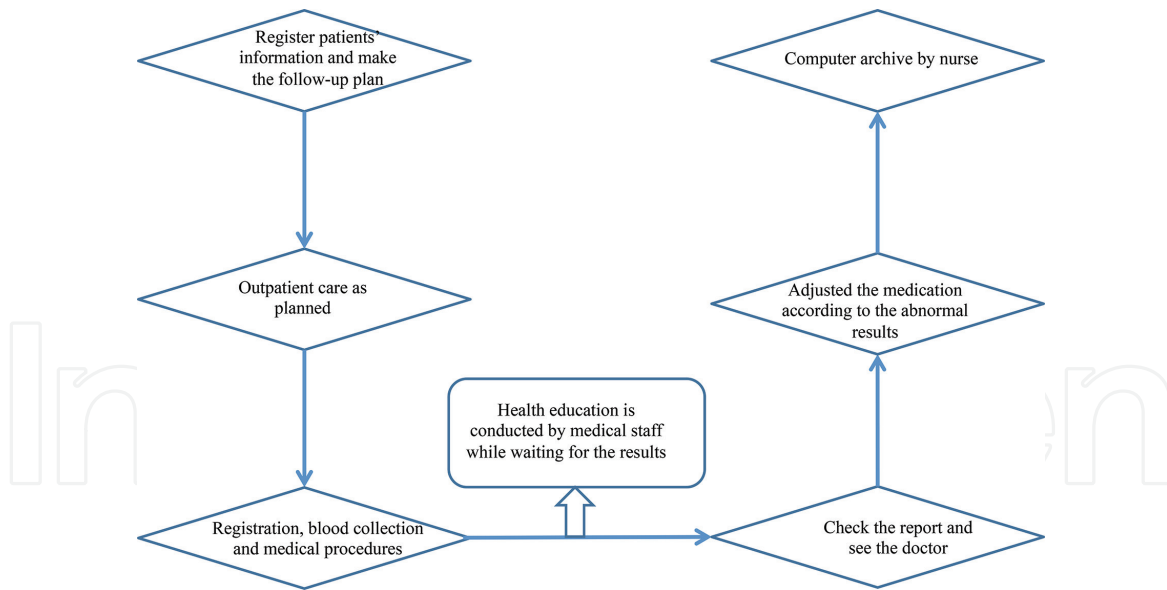


Figure 6.
 Follow-up procedure after liver transplantation.

transplantation, which lead to many problems of long survival and better quality of life. Our center is aware of it and gives the patients regular health education during follow-up through PPT, video and handbook, etc. [115, 116].

Inspection items	1–3 m post-LT	3–6 m post-LT	6–12 m post-LT	>12 m post-LT
Blood routine	Once a week	Once 2 weeks	Once a month	Once half year
Liver function	Once a week	Once 2 weeks	Once a month	Once half year
Renal function	Once a week	Once 2 weeks	Once a month	Once half year
Blood glucose and lipids levels	Once a week	Once 2 weeks	Once a month	Once half year
Blood coagulation function	Once a week	Once 2 weeks	Once a month	Once half year
Immunosuppressive agent concentration	Once a week	Once 2 weeks	Once a month	Once half year
HBsAg (for chronic hepatitis B patients)	Once a month		Once half year	
HBV-DNA (for chronic hepatitis B patients)	Once a month		Once half year	
HCV-DNA	Once a month		Once half year	
AFP (for hepatocellular carcinoma patients)	Once a month		Once half year	
Color ultrasound of transplanted liver	Once a month		Once half year	
Chest film or lung CT	Once a month		Once half year	
CT and MRCP	Once 3 months		Once half year	

Abbreviation: m, month; post-LT, post liver transplantation.

Table 4.
 Frequency and inspection items of follow-up.

	1 D-1 Mpost-LT	1-3 Mpost-LT	3-12 Mpost-LT	>12 Mpost-LT
Fk506 C ₀ (ng/mL)	8-10	6-8	6-8	5-7
CSA C ₀ (ng/mL)	200-350	150-300	100-250	>50
CSA C ₂ (ng/mL)	1000-1500	800-1200	600-1000	>400
SIR C ₀ (ng/mL)	5-8	4-8	4-8	3-6

Abbreviation: C₀, the minimal concentration; C₂, peak plasma concentration.

Table 5.
Immunosuppressive agents concentration based on postoperative time.

As is well known, the success of liver transplant surgery only means the beginning of a new life for patients. The long-term survival of liver transplant recipients depends not only on the surgical skills of surgeons, but also on the high quality and efficient follow-up after liver transplantation. With the increase in the number of liver transplantation and the application of CLTR, the experts and scholars in China will have more experience to help the patients benefit from liver transplantation.

9. Conclusion and future perspectives

After decades of efforts, the liver transplantation in Mainland China has made many achievements. The number of cases has ranked second in the world, and the quality and survival rate are no different from those of advanced countries; since 2010, China's organ donation work has been gradually carried out, and the source of liver transplant donors has transitioned from relying on judicial channels to DCDs and relative living donors. Before 2015, DCD work has not been widely carried out in the country. For some time, due to the shortage of donors, the proportion of living relatives has increased significantly (**Figures 7 and 8**), but with the development of DCD work, DCD has become the main source of liver, which better alleviated the problem of organ shortage, meanwhile many shortcoming and problems have been exposed in the DCD era.

- (1) The main primary disease of liver transplantation in current China is still HBV-related disease. China is a large HBV country, and patients requiring liver transplantation are increasing year by year. Although DCD donors alleviate the shortage of donors to a certain extent, it is necessary for Chinese health management departments to pay more attention to the prevention and treatment of HBV and related research work. For transplant experts, more work and research is needed on HBV treatment and prevention of recurrence before and after transplantation.
- (2) The proportion of liver cancer liver transplants in China is high (**Figures 9 and 10**). How to develop a liver transplantation standard suitable for liver cancer in China, how to reduce the recurrence of liver cancer after transplantation, prolong the survival time, and how to effectively combine with immunosuppressant are also problems faced by Chinese physicians.
- (3) Legal regulations are not yet complete. China has not established a brain death law, and the relevant transplant laws and regulations are also quite lacking.

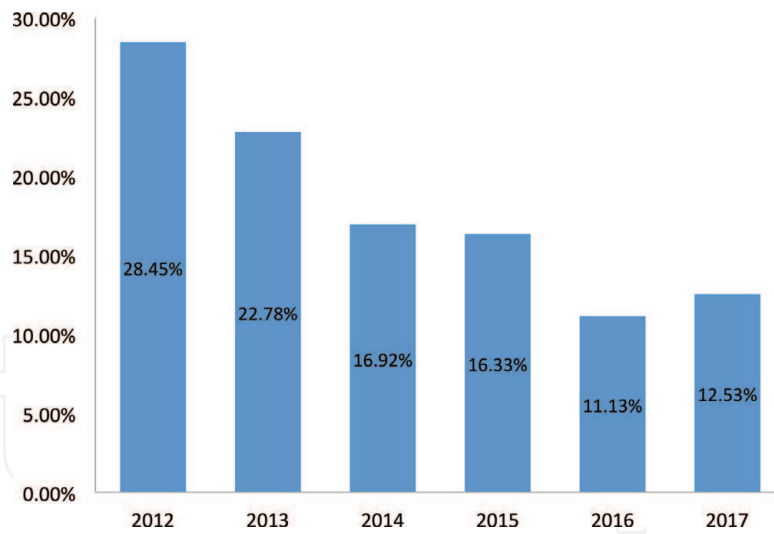


Figure 7.
 Proportion of living donor liver transplantation (data from CLTR).

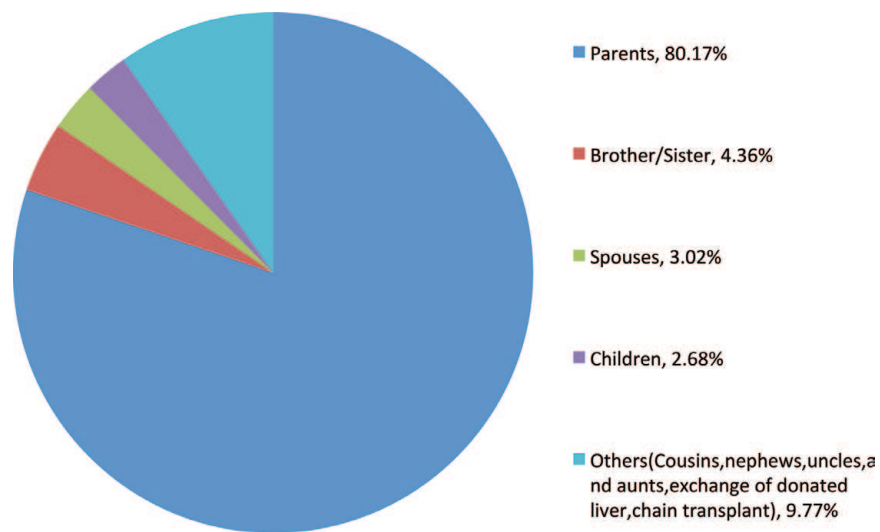


Figure 8.
 The categories of living donors (data from CLTR).

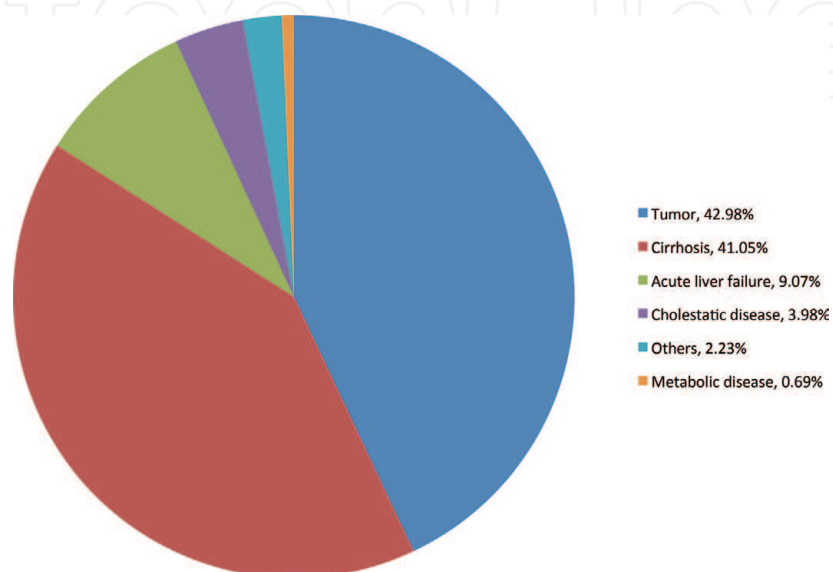


Figure 9.
 2010–2017 Primary disease statistics of DCD liver transplant recipients (data from CLTR).

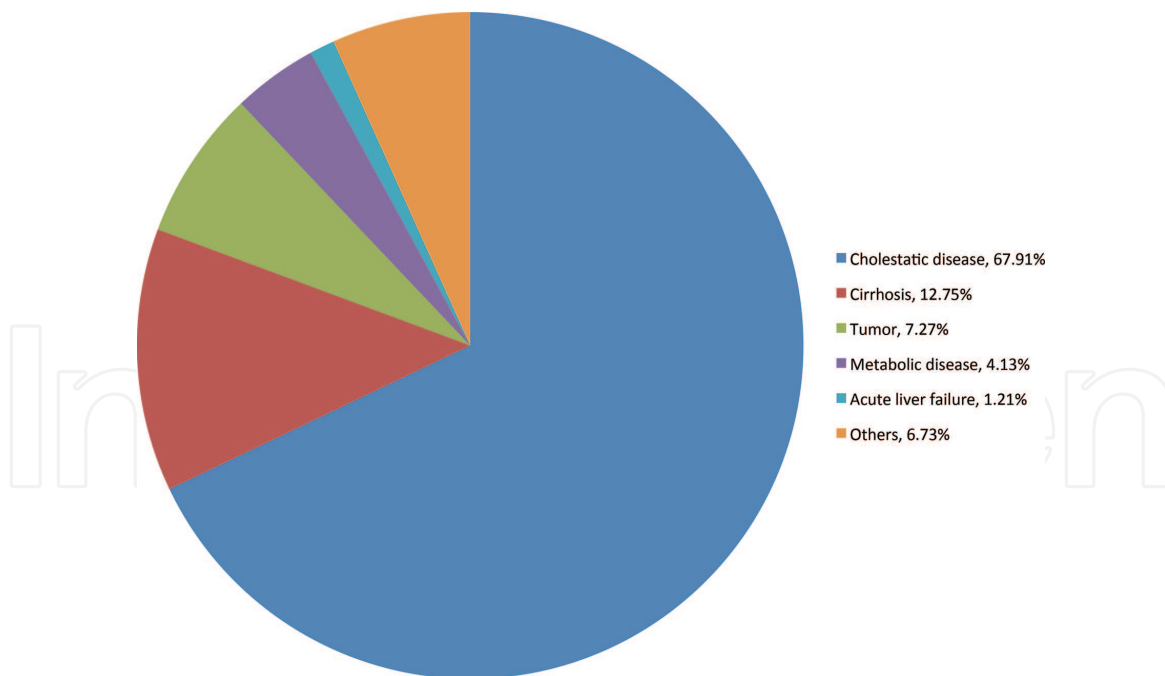


Figure 10. 2010–2017 Primary disease statistics of living donor liver transplant recipients (data from CLTR).

The corresponding management system is still not perfect. The Chinese government and transplant experts are also constantly exploring and working hard on these issues.

- (4) DCD-related work needs to be strengthened. China's contribution rate per million populations is very low, only about three cases per million people. In order to better carry out DCD work, it is necessary to increase the positive publicity of organ donation, further improve the donation, acquisition and distribution system, and establish effective services for transplant-related institutions. These are issues that China still needs to solve.

China's liver transplantation is facing enormous challenges and opportunities. It not only faces legal issues, sociology, ethics, and many other issues in donor donation, but also requires surgeons to refine and continuously improve surgical methods. More related researches needed to be done by transplant scholars. The entry criteria for liver transplant recipients and the induction of human immune tolerance in accordance with China's national conditions also depend on further research by domestic transplant workers, and the solution to these problems will be tortuous and difficult. We believe that through the long-term joint efforts of the Chinese transplanting colleagues, China's liver transplantation will have a brighter future.

Acknowledgements

We thank Prof. Zheng Shu-sen from liver transplantation center of the first hospital of Zhejiang University and workers from China Liver Transplantation Register (CLTR) for their technique support and data providing. This work was supported by grants from the National Natural Science Foundation of China (no. 81771722) to YZM and (no. 81700658) to QZ, and the Natural Science Foundation of Hunan Province (no. 2016JJ4105) to QZ.

Conflict of interest

No conflict of interest.

IntechOpen

Author details

Yingzi Ming*, Quan Zhuang, Baoren Tu, Gangcheng Kong, Hao Li, Ying Niu, Bo Peng, Junhui Li, Meng Yu and Min Yang
Transplantation Center of the 3rd Xiangya Hospital, Central South University, Engineering and Technology Research Center for Transplantation Medicine of National Ministry of Health, Changsha, Hunan, China

*Address all correspondence to: myz_china@aliyun.com

IntechOpen

© 2018 The Author(s). Licensee IntechOpen. This chapter is distributed under the terms of the Creative Commons Attribution License (<http://creativecommons.org/licenses/by/3.0>), which permits unrestricted use, distribution, and reproduction in any medium, provided the original work is properly cited. 

References

- [1] Chen GH. Liver transplantation in Mainland China: Past, present and future. *Organ Transplantation*. 2010;**1**(1):5-6
- [2] Chen H, Zang YJ, Zhu XW, Shen ZY. A brief history of liver transplantation. *Chinese Journal of Medical History*. 2006;**36**(4):227-230
- [3] Notice of the General Office of the Ministry of Health on Doing a Good Job in the Registration of Subjects for Human Organ Transplantation. Issued by General Office of the Ministry of Health. Vol. 87. 2007
- [4] Regulations on Organ Transplantation. State Council Order No. 491
- [5] Zheng SS, Yu J, Zhang W. Current development of liver transplantation in China. *Journal of Clinical hepatology*. 2014;**30**(1):2-4
- [6] Huo F, Li P. The past, current situation, and future of DCD Liver transplantation. *Journal of Hepatobiliary Surgery*. 2014;**22**(2):84-86
- [7] Organ Donation after Cardiac Death Classification Standard of the Ministry of Health of the People's Republic China. Available from: <http://www.moh.gov.cn/publicfiles/business/cmsresources/mohy/fwjgs/cmsrsdocument/doc11852.doc> [Accessed: Oct 15, 2011]
- [8] Zhu JY, Gao PJ. The current situation of organ donation after citizen death liver transplantation. *Chinese Journal of Hepatobiliary Surgery (Electronic Edition)*. 2016;**5**(5):273-276
- [9] Huang JF. The development path and expectation of China organ donation. *Medical Journal of Wuhan University*. 2016;**37**(4):517-522
- [10] Rao W. A Brief Introduction of Liver Transplantation Development Path in China. Available from: www.haodf.com
- [11] Guo YH. The number of liver transplantation in China last year. *Chinese Family News*. June 28, 2018
- [12] Wang XH, Li GQ. The current situation and challenges facing by liver transplantation in China. *Chinese Journal of Digestive Surgery*. 2013;**12**(9):641-643
- [13] China Organ Donation Administrative Center. December 31, 2016
- [14] Huang JF, Li ZH, Guo ZY, HeXS. The development path of organ donation in China. *Chinese Journal of Critical Care and Intensive Care Medicine*. 2017;**3**(2):81-84
- [15] Fu B, Yi S, Tang H, Yi M, Meng W, Zhang T, et al. Experience of quality evaluation and function maintenance of donor liver from organ donation after citizen's death. *Organ Transplantation*. 2016;**7**:215-218. DOI: 10.3969/j.issn.1674-7445.2016.03.011
- [16] Li D, Xu C, Li Z, Guan G, Zhang B. Multifactor analysis on the quality of DCD donor liver. *Practical Journal of Organ Transplantation (Electronic Version)*. 2018;**6**:25-29. DOI: 10.3969/j.issn.2095-5332.2018.01.007
- [17] Shu Z, Xiang P, Zheng S. Quality assessment and protection of liver donated by cardiac death donor. *Chinese Journal of Organ Transplantation*. 2014;**35**:698-700. DOI: 10.3760/cma.j.issn.0254-1785.2014.11.016
- [18] Duan X, Zheng S. Quality assessment of donation after cardiac death liver. *Chinese Journal of Transplantation (Electronic Edition)*. 2015;**9**:38-41. DOI: 10.3877/cma.j.issn.1674-3903.2015.01.009
- [19] Xia L. The problems in DCD donor liver preoperative evaluation. *Journal of Hepatobiliary Surgery*.

2017;25:241-243. DOI: 10.3969/j.issn.1006-4761.2017.04.001

[20] Xia W, Ke Q, Wang Y, Feng X, Guo H, Wang W, et al. Donation after cardiac death liver transplantation: Graft quality evaluation based on pretransplant liver biopsy. *Liver Transplantation*. 2015;21:838-846. DOI: 10.1002/lt.24123

[21] Liu Z, Zhao H, Geng X. Progress in rapid pathological examination in liver grafts selection. *Chinese Journal of Organ Transplantation*. 2014;35:760-762. DOI: 10.3760/cma.j.issn.0254-1785.2014.12.014

[22] Shi X, Fu Z, Ding G, Ni Z, Wang Z, Guo W, et al. Rapid evaluation of quality of liver and perfusion at the liver graft harvesting. *Journal of Hepatobiliary Surgery*. 2005;13:184-186. DOI: 10.3969/j.issn.1006-4761.2005.03.009

[23] Zhang Y, Yang Q, Lv H, Fu B, Liu W. Application of metabolomics in the evaluation of liver grafts from cardiac dead donors. *Organ Transplantation*. 2017;8:472-475. DOI: 10.3969/j.issn.1674-7445.2017.06.012

[24] Zheng SS, Ye QF, Li JH, Xu X, Xie HY, Wang YF. Chinese expert consensus on organ protection in transplantation. *Chinese Archives of General Surgery (Electronic Edition)*. 2016;10(5):315-323. DOI: 10.3760/cma.j.issn.1007-8118.2016.09.001

[25] Cheng Y. Application of mechanical perfusion in liver transplantation. *Organ Transplantation*. 2016;7:390-393. DOI: 10.3969/j.issn.1674-7445.2016.05.012

[26] Reich DJ, Mulligan DC, Abt PL, et al. ASTS recommended practice guidelines for controlled donation after cardiac death organ procurement and transplantation. *American Journal of Transplantation*. 2009;9(9):2004-2011

[27] Ye SJ, Ming YZ, Ye QF, et al. Experience of bench preparation of

donor liver in liver transplantation. *Chinese Journal of General Surgery*. 2007;16(3):261-264

[28] Starzl TE, Iwatsuki S, Van Thiel DH. Evolution of liver transplantation. *Hepatology*. 1982;2(5):614-636

[29] Özgün G, Haberal Reyhan N, Özdemir BH, Haberal M. Liver transplant for hepatocellular carcinoma: Pathologic point of view. *Experimental and Clinical Transplantation*. 2017;15(Suppl 2):50-54

[30] Zheng SS, Liang TB. Experience in classical orthotopic liver transplantation. *Surgical Theory and Practice*. 2002;7(2):91-93

[31] Yassen AM, Elsarraf WR, Elmorshedi MA. Short-term effects of extracorporeal graft rinse versus circulatory graft rinse in living donor liver transplantation. A prospective randomized controlled trial. *Transplant International*. 2017;30(7):725-733

[32] Zheng SS, Liang TB. Discussion on venous bypass and non-flow problems in orthotopic liver transplantation. *Chinese Journal of Basic and Clinical Medicine*. 2002;9(4):217-218

[33] Zheng SS, Huang DS, Wu J. Classical orthotopic liver transplantation without extracorporeal venous-venous bypass. *Chinese Journal of Surgery*. 2002;40(5):326-328

[34] Xia Q. The surgical essentials of classic orthotopic liver transplantation. *Journal of Hepatobiliary Surgery*. 2007;15(5):326-327

[35] Zheng SS, Bai XL, Liang TB, Yan S, Wang WL, Shen Y, et al. Microsurgical reconstruction of hepatic artery variability in liver transplantation. *Chinese Journal of General Surgery*. 2004;19(1):7-9

[36] Ma Y, He XS, Zhu XF, Wang GD, Wang D, Ping W, et al. Techniques for orthotopic liver transplantation

for biliary reconstruction. *Chinese Journal of Practical Surgery*. 2008;**28**(3):200-202

[37] Ye QF. The evolution of piggyback liver transplantation and the development status of international piggyback liver transplantation. *Chinese Journal of Modern Medicine*. 2004;**14**(13):6-9

[38] Nishida S, Nakamura N, Vaidya A, Levi DM, Kato T, Nery JR, et al. Piggyback technique in adult orthotopic liver transplantation: An analysis of 1067 liver transplants at a single center. *Hepato Pancreato Biliary*. 2006;**8**(3):182-188

[39] Schembri V, Cassinotto C, Panaro F. Challenging TIPS in liver transplant recipients: The pull-through technique to address piggyback anastomosis. *Cardiovascular and Interventional Radiology*. 2018;**41**(5):804-810

[40] Lauro A, Vaidya A. Role of “reduced-size” liver/bowel grafts in the “abdominal wall transplantation” era. *World Journal of Gastrointestinal Surgery*. 2017;**9**(9):186-192

[41] Ji HF, Wang WL, Shen Y. Reduced-size liver transplantation for glycogen storage disease. *Hepatobiliary & Pancreatic Diseases International*. 2009;**8**(1):106-108

[42] Oswari H, Lynch SV, Fawcett J, Strong RW, Ee LC. Outcomes of split versus reduced-size grafts in pediatric liver transplantation. *Journal of Gastroenterology and Hepatology*. 2005;**20**(12):1850-1854

[43] Zhu ZJ, Zeng ZG. Research progress in assisted liver transplantation. *Journal of Clinical Hepatology*. 2015;**31**(12):2020-2022

[44] Yang YX, Dou KF. Selection and implementation of assisted liver transplantation. *Journal of Hepatobiliary Surgery*. 2013;**21**(4):247-250

[45] Kim SH, Hwang S, Ha TY, Song GW, Jung DH, Ahn CS, et al. Usability of cryopreserved aortic allografts for middle hepatic vein reconstruction during living-donor liver transplantation. *Journal of Gastrointestinal Surgery*. 2016;**20**(5):1049-1055. DOI: 10.1007/s11605-015-3048-0

[46] Figiel W, Grat M, Wronka KM, Patkowski W, Krasnodebski M, Masiar L, et al. Reoperations for intraabdominal bleeding following deceased donor liver transplantation. *Polski Przegląd Chirurgiczny*. 2016;**88**(4):196-201. DOI: 10.1515/pjs-2016-0051

[47] Li C, Wen TF, Yan LN, Li B. Risk factors for abdominal bleeding after living-donor liver transplant. *Experimental and Clinical Transplantation*. 2014;**12**(5):424-428. DOI: 10.6002/ect.2013.0223

[48] Wei Q, Gao F, Zhuang R, Ling Q, Ke Q, Wu J, et al. A national report from China liver transplant registry: Steroid avoidance after liver transplantation for hepatocellular carcinoma. *Chinese Journal of Cancer Research*. 2017;**29**(5):426-437. DOI: 10.21147/j.issn.1000-9604.2017.05.07

[49] Lui SK, Garcia CR, Mei X, Gedaly R. Re-transplantation for hepatic artery thrombosis: A national perspective. *World Journal of Surgery*. 2018;**42**(10):3357-3363. DOI: 10.1007/s00268-018-4609-7

[50] Mourad MM, Liossis C, Gunson BK, Mergental H, Isaac J, Muiesan P, et al. Etiology and management of hepatic artery thrombosis after adult liver transplantation. *Liver Transplantation*. 2014;**20**(6):713-723. DOI: 10.1002/lt.23874

[51] Pulitano C, Joseph D, Sandroussi C, Verran D, Strasser SI, Shackel NA, et al. Hepatic artery stenosis after liver transplantation: Is endovascular

treatment always necessary? *Liver Transplantation*. 2015;**21**(2):162-168. DOI: 10.1002/lt.24043

[52] Ma L, Lu Q, Luo Y. Vascular complications after adult living donor liver transplantation: Evaluation with ultrasonography. *World Journal of Gastroenterology*. 2016;**22**(4):1617-1626. DOI: 10.3748/wjg.v22.i4.1617

[53] Boleslawski E, Bouras AF, Truant S, Liddo G, Herrero A, Badic B, et al. Hepatic artery ligation for arterial rupture following liver transplantation: A reasonable option. *American Journal of Transplantation*. 2013;**13**(4):1055-1062. DOI: 10.1111/ajt.12135

[54] Senter-Zapata M, Khan AS, Subramanian T, Vachharajani N, Dageforde LA, Wellen JR, et al. Patient and graft survival: Biliary complications after liver transplantation. *Journal of the American College of Surgeons*. 2018;**226**(4):484-494. DOI: 10.1016/j.jamcollsurg.2017.12.039

[55] Coelho JCU, Leite LO, Molena A, Freitas ACT, Matias JEF. Biliary complications after liver transplantation. *Arquivos Brasileiros de Cirurgia Digestiva*. 2017;**30**(2):127-131. DOI: 10.1590/0102-6720201700020011

[56] Ye S, Dong JH, Duan WD, Ji WB, Liang YR. The preliminary study on procurement biliary convergence from donors with complicated bile duct variant in emergency right lobe living donor liver transplantation. *Journal of Clinical and Experimental Hepatology*. 2017;**7**(1):33-41. DOI: 10.1016/j.jceh.2016.09.016

[57] Li DW, Lu TF, Hua XW, Dai HJ, Cui XL, Zhang JJ, et al. Risk factors for new onset diabetes mellitus after liver transplantation: A meta-analysis. *World Journal of Gastroenterology*. 2015;**21**(20):6329-6340. DOI: 10.3748/wjg.v21.i20.6329

[58] Watt KD, Charlton MR. Metabolic syndrome and liver transplantation: A review and guide to management. *Journal of Hepatology*. 2010;**53**(1):199-206. DOI: 10.1016/j.jhep.2010.01.040

[59] Zheng J, Wang WL. Risk factors of metabolic syndrome after liver transplantation. *Hepatobiliary & Pancreatic Diseases International*. 2015;**14**(6):582-587

[60] Longenecker JC, Waheed S, Bandak G, Murakami CA, McMahan BA, Gelber AC, et al. Hyperuricemia after orthotopic liver transplantation: Divergent associations with progression of renal disease, incident end-stage renal disease, and mortality. *BMC Nephrology*. 2017;**18**(1):103. DOI: 10.1186/s12882-017-0518-5

[61] Neal DA, Tom BD, Gimson AE, Gibbs P, Alexander GJ. Hyperuricemia, gout, and renal function after liver transplantation. *Transplantation*. 2001;**72**(10):1689-1691

[62] Transplantation Chinese Society of Organ, Section of Organ Transplantation Chinese Society of Surgery, Doctors Chinese College of Transplant. The Chinese clinical practice guideline on liver transplantation for hepatocellular carcinoma (2014 edition). *Practical Journal of Organ Transplantation (Electronic Version)*. 2015;**3**:66-71

[63] Zheng SS, Xu X, Wu J, Chen J, Wang WL, Zhang M, et al. Liver transplantation for hepatocellular carcinoma: Hangzhou experiences. *Transplantation*. 2008;**85**(12):1726-1732. DOI: 10.1097/TP.0b013e31816b67e4

[64] Fan J, Zhou J, Xu Y, Qiu SJ, Wu ZQ, Yu Y, et al. Indication of liver transplantation for hepatocellular carcinoma: Shanghai Fudan criteria. *Zhonghua Yi Xue Za Zhi*. 2006;**86**(18):1227-1231

- [65] Clavien PA, Lesurtel M, Bossuyt PM, Gores GJ, Langer B, Perrier A, et al. Recommendations for liver transplantation for hepatocellular carcinoma: An international consensus conference report. *The Lancet Oncology*. 2012;**13**(1):e11-e22. DOI: 10.1016/S1470-2045(11)70175-9
- [66] European Association for the Study of the Liver, European Organisation for Research, Treatment of Cancer. EASL-EORTC clinical practice guidelines: Management of hepatocellular carcinoma. *Journal of Hepatology*. 2012;**56**(4):908-943. DOI: 10.1016/j.jhep.2011.12.001
- [67] Mazzaferro V, Llovet JM, Miceli R, Bhoori S, Schiavo M, Mariani L, et al. Predicting survival after liver transplantation in patients with hepatocellular carcinoma beyond the Milan criteria: A retrospective, exploratory analysis. *The Lancet Oncology*. 2009;**10**(1):35-43. DOI: 10.1016/S1470-2045(08)70284-5
- [68] Zimmerman MA, Ghobrial RM, Tong MJ, Hiatt JR, Cameron AM, Hong J, et al. Recurrence of hepatocellular carcinoma following liver transplantation: A review of preoperative and postoperative prognostic indicators. *Archives of Surgery*. 2008;**143**(2):182-188; discussion 8. DOI: 10.1001/archsurg.2007.39
- [69] Liang X, Bi S, Yang W, Wang L, Cui G, Cui F, et al. Evaluation of the impact of hepatitis B vaccination among children born during 1992-2005 in China. *The Journal of Infectious Diseases*. 2009;**200**(1):39-47. DOI: 10.1086/599332
- [70] Liang X, Bi S, Yang W, Wang L, Cui G, Cui F, et al. Epidemiological serosurvey of hepatitis B in China--declining HBV prevalence due to hepatitis B vaccination. *Vaccine*. 2009;**27**(47):6550-6557. DOI: 10.1016/j.vaccine.2009.08.048
- [71] Yuan-Sheng C, Li LI, Fu-Qiang CUI, Wen-Ge X, Lu W, Zhi-Yuan JIA, et al. A sero-epidemiological study on hepatitis C in China. *Chinese Journal of Epidemiology*. 2011;**9**:888-891. DOI: 10.3760/cma.j.issn.0254-6450.2011.09.009
- [72] Chinese Society of Hepatology, Chinese Medical Asso., Chinese Society of Infectious Diseases, Chinese Med. The guideline of prevention and treatment for chronic hepatitis B: A 2015 update. *Journal of Clinical Hepatology*. 2015;**12**:1941-1960. DOI: 10.3969/j.issn.1001-5256.2015.12.002
- [73] Hepatology Chinese Society of Diseases Chinese Society of Infectious. The guideline of prevention and treatment for hepatitis C: A 2015 update. *Chinese Hepatology*. 2015;**49**(12):933-1006. DOI: 10.3969/j.issn.1008-1704.2015.12.002
- [74] Yuan G, Wentao W, Ziqiang L, Gendong T, Lei R, Kai S, et al. Hepatitis B vaccination: A new strategy to prevent hepatitis B recurrence after liver transplantation for hepatitis B virus-related recipients. *Chinese Journal of Hepatobiliary Surgery*. 2015;**10**:668-670. DOI: 10.3760/cma.j.issn.1007-8118.2015.10.006
- [75] Liu G, Chen G, Sun J, Tang G, Wang W, Zhu S. Analysis of lamivudine combined with low-dose hepatitis B immunoglobulin for prevention and treatment of hepatitis B recurrence after liver transplantation. *China Practical Medical*. 2014;**36**:117-118
- [76] Jurim O, Martin P, Shaked A, Goldstein L, Millis JM, Calquhoun SD, et al. Liver transplantation for chronic hepatitis B in Asians. *Transplantation*. 1994;**57**(9):1393-1395
- [77] Yin-Jie GAO, Han-Wei LI, Jing-Min Z, Min Z, Bo JIN, Fan-Ping M. Clinicopathological analysis of HBV recurrence in post-liver transplantation patients. *Chinese*

Journal of Organ Transplantation.
2011;**8**:477-480. DOI: 10.3760/cma.j.issn.0254-1785.2011.08.008

[78] Chinese Society of Organ Transplantation, Chinese, Chinese Society of Hepatology, Chinese Medical Ass. The practice guideline on prophylaxis and treatment of hepatitis B for liver transplantation in China (2016 edition). Journal of Clinical Hepatology. 2017;**2**:213-220. DOI: 10.3969/j.issn.1001-5256.2017.02.002

[79] Liu CJ, Kao JH. Global perspective on the natural history of chronic hepatitis B: Role of hepatitis B virus genotypes A to J. Seminars in Liver Disease. 2013;**33**(2):97-102. DOI: 10.1055/s-0033-1345716

[80] Xian Y, Cheng S. Progress in research and application of hepatitis B virus genotyping. International Journal of Virology. 2016;**4**:285-288. DOI: 10.3760/cma.j.issn.1673-4092.2016.04.021

[81] Yang L, Peng X, Zhao Y, Zhao P, Ma Y, Yang F. Relationship of HBV genotypes to changes of liver biopsies and to responses to antiviral therapy of nucleoside analogs. Journal of Clinical Hepatology. 2012;**2**:120-122. DOI: 10.3969/j.issn.1672-5069.2012.02.013

[82] Lu D, Zhao L. Relationship between hepatitis B virus genotype and antiviral drug efficacy. Medical Journal of West China. 2005;**4**:389-391. DOI: 10.3969/j.issn.1672-3511.2005.04.064

[83] Lin T, Chen L, Kong J. Different effects of tenofovir treatment with different HBV genotypes in HBeAg positive chronic hepatitis B. China Foreign Medical Treatment. 2017;**23**:38-40. DOI: 10.16662/j.cnki.1674-0742.2017.23.038

[84] Wang H, Ma L, Yin Q, Zhang X, Zhang C. Prevalence of alcoholic liver disease and its association

with socioeconomic status in North-Eastern China. Alcoholism, Clinical and Experimental Research. 2014;**38**(4):1035-1041. DOI: 10.1111/acer.12321

[85] Huang S, Dai S, Zhang X, Yu Y, Tan M, Yi C. Survey of epidemiological investigation of alcoholic liver disease in Hunan Province. Journal of Chinese Physician. 2005;**3**:426-427. DOI: 10.3760/cma.j.issn.1008-1372.2005.03.080

[86] Zhou YJ, Li YY, Nie YQ, Ma JX, Lu LG, Shi SL, et al. Prevalence of fatty liver disease and its risk factors in the population of South China. World Journal of Gastroenterology. 2007;**13**(47):6419-6424

[87] Group Chinese Alcoholic Liver Disease Investigation Collaboration. Management of malignant biliary hilar obstruction with multiple stents. Chinese Journal of Digestion. 2007;**4**:231-234. DOI: 10.3760/j.issn:0254-1432.2007.04.005

[88] Liu Y, Chi B. Clinical analysis on 237 cases with alcoholic liver cirrhosis. Jilin Medical Journal. 2004;**2**:40-42. DOI: 10.3969/j.issn.1004-0412.2004.02.016

[89] Wang H, Wang J. Study on the association of hepatitis virus infection and alcoholic liver cirrhosis (a clinic study on 182 patients with alcoholic liver disease). Journal of Norman Bethune University of Medical Science. 1998;**6**:652-653

[90] Wang FS, Fan JG, Zhang Z, Gao B, Wang HY. The global burden of liver disease: The major impact of China. Hepatology (Baltimore, MD). 2014;**60**(6):2099-2108. DOI: 10.1002/hep.27406

[91] Pfitzmann R, Schwenzer J, Rayes N, Seehofer D, Neuhaus R, Nussler NC. Long-term survival and predictors of relapse after orthotopic

liver transplantation for alcoholic liver disease. *Liver Transplantation*. 2007;**13**(2):197-205. DOI: 10.1002/lt.20934

[92] Firpi RJ, Zhu H, Morelli G, et al. Cyclosporine suppresses hepatitis C virus in vitro and increases the chance of a sustained virological response after liver transplantation. *Liver Transplantation*. 2006;**12**:51-57. DOI: 10.1002/lt.20532

[93] Guba M, von BP, Steinbauer M, et al. Rapamycin inhibits primary and metastatic tumor growth by antiangiogenesis: Involvement of vascular endothelial growth factor. *Nature Medicine*. 2002;**8**:128-135. DOI: 10.1038/nm0202-128

[94] Koehl GE, Andrassy J, Guba M, et al. Rapamycin protects allografts from rejection while simultaneously attacking tumors in immunosuppressed mice. *Transplantation*. 2004;**77**:1319-1326

[95] Schmidt H, Brockmann J. MMF to EC-MPS conversion: What makes the difference. *Liver Transplantation*. 2007;**13**:773-774; author reply 775. DOI: 10.1002/lt.21101

[96] Schlitt HJ, Barkmann A, Böker KH, et al. Replacement of calcineurin inhibitors with mycophenolate mofetil in liver-transplant patients with renal dysfunction: A randomised controlled study. *Lancet*. 2001;**357**:587-591

[97] Fisher RA, Ham JM, Marcos A, et al. A prospective randomized trial of mycophenolate mofetil with neoral or tacrolimus after orthotopic liver transplantation. *Transplantation*. 1998;**66**:1616-1621

[98] Stangl JR, Carroll KL, Illichmann M, Striker R. Effect of antimetabolite immunosuppressants on flaviviridae, including hepatitis C virus. *Transplantation*. 2004;**77**:562-567

[99] Nebbia G, Mattes FM, Sabin CA, et al. Differential effects of prednisolone and azathioprine on the development of human cytomegalovirus replication post liver transplantation. *Transplantation*. 2007;**84**:605610. DOI: 10.1097/01.tp.0000280555.08651.11

[100] Kneteman NM, Oberholzer J, Al SM, et al. Sirolimus-based immunosuppression for liver transplantation in the presence of extended criteria for hepatocellular carcinoma. *Liver Transplantation*. 2004;**10**:1301-1311. DOI: 10.1002/lt.20237

[101] Dunkelberg JC, Trotter JF, Wachs M, et al. Sirolimus as primary immunosuppression in liver transplantation is not associated with hepatic artery or wound complications. *Liver Transplantation*. 2003;**9**:463-468. DOI: 10.1053/jlts.2003.50079

[102] Li Y, Zheng XX, Li XC, Zand MS, Strom TB. Combined costimulation blockade plus rapamycin but not cyclosporine produces permanent engraftment. *Transplantation*. 1998;**66**:1387-1388

[103] Li Y, Li XC, Zheng XX, Wells AD, Turka LA, Strom TB. Blocking both signal 1 and signal 2 of T-cell activation prevents apoptosis of alloreactive T cells and induction of peripheral allograft tolerance. *Nature Medicine*. 1999;**5**:1298-1302. DOI: 10.1038/15256

[104] Luan FL, Hojo M, Maluccio M, Yamaji K, Suthanthiran M. Rapamycin blocks tumor progression: Unlinking immunosuppression from antitumor efficacy. *Transplantation*. 2002;**73**:1565-1572

[105] Guertin DA, Sabatini DM. Defining the role of mTOR in cancer. *Cancer Cell*. 2007;**12**:9-22. DOI: 10.1016/j.ccr.2007.05.008

- [106] Neef M, Ledermann M, Saegesser H, Schneider V, Reichen J. Low-dose oral rapamycin treatment reduces fibrogenesis, improves liver function, and prolongs survival in rats with established liver cirrhosis. *Journal of Hepatology*. 2006;**45**:786-796. DOI: 10.1016/j.jhep.2006.07.030
- [107] Henry SD, Metselaar HJ, Van Dijck J, Tilanus HW, Van Der Laan LJ. Impact of steroids on hepatitis C virus replication in vivo and in vitro. *Annals of the New York Academy of Sciences*. 2007;**1110**:439-447. DOI: 10.1196/annals.1423.046
- [108] Segev DL, Sozio SM, Shin EJ, et al. Steroid avoidance in liver transplantation: Meta-analysis and meta-regression of randomized trials. *Liver Transplantation*. 2008;**14**:512-525. DOI: 10.1002/lt.21396
- [109] Geissler EK, Schlitt HJ. Immunosuppression for liver transplantation. *Gut*. 2009;**58**:452-463. DOI: 10.1136/gut.2008.163527
- [110] Peng S. Improving the level of liver transplantation in China. *Zhonghua Yi Xue Za Zhi*. 2001;**81**:1089-1090
- [111] Huang J, He X, Chen G, Zhu X, Lu M, Wang G, et al. Liver transplantation at the Sun Yat-Sen University of Medical Sciences in China. *Chinese Medical Journal*. 2002;**115**:543-548
- [112] Wang GS, Yang Y, Li H, Jiang N, Fu BS, Jin H, et al. Health-related quality of life after liver transplantation: The experience from a single Chinese center. *Hepatobiliary & Pancreatic Diseases International*. 2012;**11**:262-266
- [113] Xie M, Rao W, Yang T, Deng Y, Zheng H, Pan C, et al. Occult hepatitis B virus infection predicts de novo hepatitis B infection in patients with alcoholic cirrhosis after liver transplantation. *Liver International*. 2015;**35**:897-904
- [114] Jiang W, Li J, Guo Q, Sun J, Chen C, Shen Z. Liver transplantation for hepatocellular carcinoma. *Drug Discoveries & Therapeutics*. 2015;**9**:331-334
- [115] Zheng H, Zhang HM, Zheng WP. Insight and judgment on recurrence of hepatocellular carcinoma after liver transplantation. *Zhonghua Gan Zang Bing Za Zhi*. 2018;**26**:88-92
- [116] Wei L, Chen D, Zhang B, Zhao Y, Liu B, Shi H, et al. Long-term outcome and recurrence of hepatitis B virus following liver transplantation from hepatitis B surface antigen-positive donors in a Chinese population. *Journal of Viral Hepatitis*. 2018;**00**:1-6