

We are IntechOpen, the world's leading publisher of Open Access books Built by scientists, for scientists

4,800

Open access books available

122,000

International authors and editors

135M

Downloads

Our authors are among the

154

Countries delivered to

TOP 1%

most cited scientists

12.2%

Contributors from top 500 universities



WEB OF SCIENCE™

Selection of our books indexed in the Book Citation Index
in Web of Science™ Core Collection (BKCI)

Interested in publishing with us?
Contact book.department@intechopen.com

Numbers displayed above are based on latest data collected.
For more information visit www.intechopen.com



Management Strategies for Oral Cancer Subsites

Neeti Kapre Gupta, Monica Mahajan and
Apeksha Hore

Additional information is available at the end of the chapter

<http://dx.doi.org/10.5772/intechopen.81555>

Abstract

Oral cancers are the most common cancers in India, especially in males. This can be attributed primarily to consumption of tobacco and areca related products. Surgery is the mainstay of treatment for oral cancers with subtle subsite-specific nuances. The oral cavity starts at the mucocutaneous junction of the lips (the vermilion border) extending posteriorly to the junction of the hard and soft palate superiorly, anterior fauces laterally and the junction of the anterior two-thirds and posterior third of the tongue inferiorly. The oral cavity is lined by stratified squamous epithelium of varying degrees of keratinization. Primary tumors of the oral cavity may be derived from the mucosa, salivary glands, neurovascular tissues, bone or dental tissues. Over 90% of malignant tumors of the oral cavity are squamous cell carcinomas. There are certain basic principles of oncology, those hold true, despite the disease subsite and pathology. Stage I and II disease should be dealt with single modality treatment, whereas Stage III and IV warrant combined modality approach. Choice of modality (surgical versus non-surgical), depends on intent of treatment, chances of cure, accessibility and resectability of disease, impact on quality of life and patient's general health profile.

Keywords: oral cancer, oral oncosurgery, radiotherapy, chemotherapy

1. Introduction

Oral cancers are the most common cancers in India, especially in males. This can be attributed primarily to consumption of tobacco and areca related products. Surgery is the mainstay of treatment for oral cancers with subtle subsite-specific nuances.

The oral cavity starts at the mucocutaneous junction of the lips (the vermilion border) extending posteriorly to the junction of the hard and soft palate superiorly, anterior fauces laterally and the junction of the anterior two-thirds and posterior third of the tongue inferiorly. The

oral cavity is lined by stratified squamous epithelium of varying degrees of keratinization. Primary tumors of the oral cavity may be derived from the mucosa, salivary glands, neurovascular tissues, bone or dental tissues. Over 90% of malignant tumors of the oral cavity are squamous cell carcinomas.

There are certain basic principles of oncology, those hold true, despite the disease subsite and pathology. Stage I and II disease should be dealt with single modality treatment, whereas Stage III and IV warrant combined modality approach. Choice of modality (surgical versus non-surgical), depends on intent of treatment, chances of cure, accessibility and resectability of disease, impact on quality of life and patient's general health profile.

The following chapter attempts to succinctly highlight subtle differences in management of oral cancer at individual subsites.

1.1. Diagnosis: imaging

Contrast enhanced multi-detector computed tomography (CECT) scan is the workhorse for head and neck imaging. Magnetic resonance imaging (MRI) is preferred for better soft tissue delineation. **Table 1** summarizes preferred imaging modality in individual subsite.

A distant metastatic work-up is indicated in oral cancers in the following scenarios-

- Patients presenting with obvious symptoms pointing to distant metastatic sites
- Recurrent disease, especially with short disease-free interval
- Extensive nodal burden/lower level (root of the neck) cervical nodes
- Primary resection is expected to be excessively morbid

Whole body contrast enhanced PETCT is the investigation of choice for these patients since it offers the combined advantage of functional and structural imaging.

| Sr. no. | Site | Imaging modalities |
|---------|--|---|
| 1 | Lip, buccal mucosa, gingivobuccal sulcus, mandible, retromolar trigone | Primarily: CECT (a puffed cheek technique is preferred) |
| 2 | Tongue, floor of the mouth | Primarily: MRI Other preferred modalities: CECT (especially if mandibular bone involvement is suspected) |
| 3 | Maxilla | Primarily: CT Other preferred modalities: MRI (helpful for detection of perineural invasion) |
| 4 | Hard palate | Primarily: CT Other preferred modalities: MRI |

Table 1. Choice of imaging modality for individual subsites in oral cavity.

1.2. Diagnosis: pathology

Biopsy and subsequent histological examination is the gold standard for diagnosing head and neck malignancies. The most representative part of the lesion should be chosen for taking punch biopsies. It is certainly not necessary to take biopsy from margin of diseased and normal tissue as was previously advocated. Verrucous proliferative lesions may harbor foci of invasive cancer in 20% cases, therefore it is essential to include reasonable depth of tissue while performing biopsy. A wedge incision or knife biopsy is often recommended in these situations. Fine needle aspiration cytology (FNAC) aids for ascertaining positive nodal metastases. Sometimes imaging guided biopsy or FNAC are useful for targeting disease in difficult to access areas. Certain specific viral antibodies testing (human papilloma virus (HPV) for oropharynx) may be supplemented as deemed necessary.

2. Treatment

Definitive treatment modalities: The management for cancer mainly includes three treatment modalities—surgery, radiotherapy and chemotherapy. These modalities can be used individually or in combination with each other. The factors that influence choice of initial treatment for primary carcinomas of the oral cavity are dependent on the characteristics of the primary tumor (tumor factors), those related to the patient—site of the primary tumor, size (T-stage), location (anterior vs. posterior), proximity to bone (mandible or maxilla), status of cervical lymph nodes, histology (type, grade, and depth of invasion), and previous treatment, and those related to the treatment team providing care to the patient (physician factors). The ultimate goals in treatment of cancer of the oral cavity are to eradicate the cancer, preserve or restore form and function, minimize the sequelae of treatment, and prevent subsequent new primary tumors [1].

2.1. Surgery

Surgery is the mainstay of treatment for oral cancers. The goal of any oncological surgery is complete removal of the primary tumor and appropriate clearance of regional lymph nodes, while preserving the integrity of uninvolved structures.

2.1.1. Management of primary lesion

The surgical plan should involve wide excision of the tumor in all three dimensions with adequate margins (**Table 2**). This should account for histopathological shrinkage (approximately 25%) [2]. Due attention must be given specially to the third dimension which is the soft tissue/depth and generally the site of surgical failures. An examination under anesthesia should ideally always precede the excision.

Intraoperative frozen section evaluation is a very effective modality to assess the complete removal of the malignant lesion. Frozen section provides instant pathological information that can guide intra-operative surgical decision making such as adequacy of margins, identification of nodal metastases [3, 4]. However, we have literature from high volume centers

| | |
|-----------------|-------------------------|
| Negative margin | >5 mm |
| Close margin | 1–5 mm |
| Positive margin | <1 mm/tumor cut through |

Table 2. Adequacy of margins for resection of oral primary.

in India to suggest that the incremental value of frozen section analysis of margins over surgeon's gross assessment is limited when the margin is >7 mm [5]. The authors have original research work in role of crush imprint cytology for identification of nodal metastases from oral cancers with reasonable sensitivity (92%) and accuracy (88%) [6].

2.1.1.1. Approaches to the oral cavity

Per-oral: This approach has the following prerequisites (**Figure 1**)

1. Adequate mouth opening
2. Small size
3. Anteriorly located lesions
4. All resection margins accessible
5. Noncontiguous lymph nodal spread

Upper cheek flap: This approach allows access to the maxilla, upper alveolus, hard palate. Care should be exercised while raising the flap superolaterally to avoid injury to the infra-orbital nerve and to anticipate subcutaneous/cutaneous soft tissue extent of the tumor while deciding the thickness of the flap. Extensions of the flap such as the lateral rhinotomy, Weber Ferguson with or without Dieffenbach extension can be used to excise sinonasal tumors. Lateral subciliary or supra-orbital incisions can be combined to perform orbital exenteration depending upon the extent of the tumor.

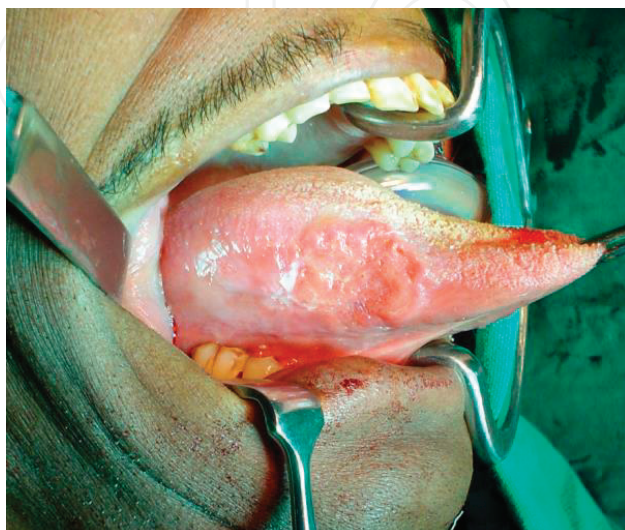

Figure 1. Resection of squamous cell carcinoma of right lateral border of tongue by per oral approach.

Lower cheek flap: This approach allows access to the mandible, lower gingiva-buccal complex, retro-molar trigone and tonsil. Depending upon the location and extent of the tumor, the decision to preserve the mental nerve and the lateral mandibular periosteum is made.

Mandibulotomy: This approach allows access to the posterior tongue, tonsil and soft palate. A paramedian mandibulotomy is preferred between the lateral incisor and canine since these teeth roots are maximally divergent. Care should be taken to remain anterior to the mental nerve. A step ladder osteotomy offers a better mechanical advantage.

Pull through: This approach is often employed for large volume tongue cancers with extension into the hyoglossus muscle provided gingivolingual mucosa and alveolus are free.

Commando approach: This terminology has fallen out of favor and the term composite resections are used to denote excision of tongue, tonsil and mandible.

2.1.1.2. Subsite specific salient features

Tongue/floor of mouth:

- Aggressive biological behavior
- Notorious for neural and lymphovascular invasion
- Tendency for submucosal spread
- Propensity for nodal and distant metastases
- Depth of invasion and extrinsic tongue muscle involvement bad prognosticators
- Compartmental excisions are recommended for deep invasion of extrinsic tongue musculature to ensure removal of the tumor along with the in-transit lymphatics and contiguous lymph nodal station [7].
- Since reconstruction has direct impact on speech and swallow, following principles must be borne in mind
 - Preserve tip
 - Maintain bulk posteriorly to prevent aspiration
 - Palatal contact to promote better consonant pronunciation
 - Prevent tethering to mandible/inter-dental stitches that will hamper with mobility

Buccal mucosa/gingivobuccal sulcus/mandible:

- High prevalence in Indian subcontinent due to habit of chewed tobacco consumption
- Extent of disease into the masticator space and infra-temporal fossa must be assessed on pre-operative imaging
- Caution should be exercised in estimating deeper soft tissue extent in the setting of trismus and posteriorly located tumors particularly with involvement of the retro-molar trigone area.
- Proximity to and involvement of mandible determines bony resection

- Reconstruction of middle third should be necessarily with free osteocutaneous flaps
- Reconstruction of posterior segment can be with osteocutaneous or soft tissue flaps depending upon age of the patient, disease extent and amount of remnant mandibular segment.
- Placement of the incision (midline or commissure split incision) should be based on anterior extent of the resection margin.

2.1.1.3. Management of mandible

Indications for marginal mandibulectomy:

1. For achieving adequate margin (tumor close to but not involving mandible)
2. Superficial bony erosion
3. Superficial periosteal invasion

However, a mandibular height of minimum 1 cm is essential for bony support after marginal mandibulectomy. In situations where inferior soft tissue or bony margin does not allow this, a segmental mandibulectomy should be contemplated. Soft tissue margins are often used as surrogates to decide bony margins. Frozen section analysis of the bone marrow can alternatively be used to decide adequacy of the same [8].

Indications for segmental mandibulectomy:

1. Gross bony erosion
2. Prior radiation
3. Edentulous mandible
4. Gross paramandibular disease

2.1.1.3.1. Lip

- Squamous cancers are the most common histology
- Involvement of oral commissure has direct bearing on its esthetic and functional performance
- While reconstruction it is important to remember that the lip should have sensation, motion, prevent drooling, permit speech and have a reasonable cosmetic appearance (**Figure 2**).

2.1.1.3.2. Hard palate

- Salivary gland malignancies are common although squamous cancers still remain the most common histology
- Nasal endoscopy should be performed to determine extension into the nasopharyngeal surface of the soft palate.

- For maxillary cancers extending onto hard palate, a hypothetical line extending from the medial canthus to the angle of mandible differentiates inferomedial and superolateral tumors. The former is said to have a significantly better prognosis than the later.

2.1.2. Management of neck nodes

An elective neck dissection is now standard of care for all oral cancers [9]. The risk of regional metastases has been correlated to thickness of the tumor, site, size and histological features of the primary [10]. The dissemination of metastatic cancer to regional lymph nodes from primary cancers in the oral cavity occurs in a predictable and sequential fashion [11]. The initial spread from oral cancer occurs at Levels I, II, III. Involvement of Level IV is often implicated in tongue cancers. Isolated skip metastases to Level V are exceedingly uncommon. Some authors propose level IIa positivity as a guide to proceed for level IIB/V clearance [12]. A selective (supraomohyoid) neck dissection clearing Levels I, II, III, and IV is considered appropriate for most primary oral cancers with clinico-radiologically N0 neck [13]. The extent and of neck dissection varies according to the clinico-radiological staging of nodal disease (Table 3). Sentinel node biopsy has gained much interest as a reliable and oncologically safe, less morbid alternative to elective neck dissection [14]. However, requirement of resources and expertise and a reasonably steep learning curve for accurate interpretation of results has limited its wider applicability.

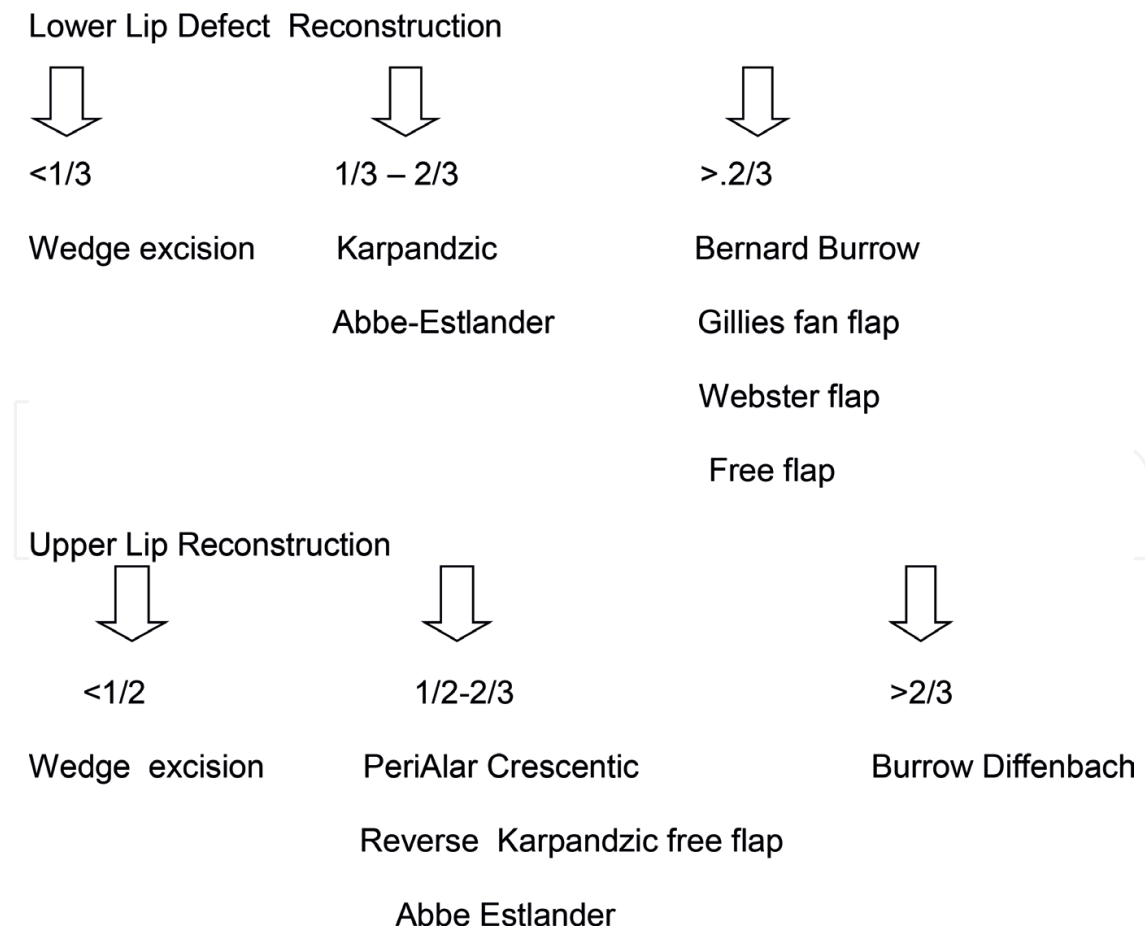


Figure 2. Techniques for reconstruction of upper and lower lip defects.

2.1.2.1. Incisions for neck dissection

The exact location and type of skin incision will depend on the site of the primary tumor and whether a unilateral or bilateral neck dissection is planned. Caution should be exercised to avoid tri-pointer suturing over the great vessels to safeguard from a dreaded complication of carotid blow-out. Triangular edges in the flaps are liable to undergo ischemic necrosis and should be similarly avoided. The vertical limbs in the incision should be avoided as they produce unsightly scars and contractures which produce neck morbidity.

The following are the various routinely employed incisions used for neck dissection [15, 16].

- I. Macfee incision
- II. Crile's incision
- III. Hay-Martin's incision
- IV. Schobinger's incision
- V. Modified Conley's incision
- VI. Apron incision
- VII. Modified Macfee incision

2.1.3. Reconstruction

Reconstruction after oral cancer surgery should aim at restoration of both form and function. The principle of "like for like" is a good rationale for deciding the type of reconstruction. This can be accomplished by the following: (1) primary closure, (2) split thickness skin graft, (3) vascularized cutaneous free flap, (4) regional myocutaneous flap, or (5) microvascular free

| | |
|--|---|
| N_0 | <ol style="list-style-type: none"> 1. Selective neck dissection (Figure 3) 2. Frozen section/crush imprint cytology for clinically suspicious nodes-SOS modified neck dissection |
| $N+$ | Modified neck dissection (Figure 4) |
| Classical radical neck dissection [13, 14] | <ol style="list-style-type: none"> 1. N3 disease 2. Gross invasion of the spinal accessory nerve/internal jugular vein/sternocleidomastoid 3. Recurrent or persistent metastatic carcinoma after previous radiation therapy, chemoradiation therapy, or previous selective neck dissection |
| Extended radical neck dissection | <ol style="list-style-type: none"> 1. Gross extranodal disease. 2. Involvement of the skin or platysma. 3. Involvement of other nonlymphatic structures like great vessels (carotid), nerves (vagus, phrenic, sympathetic plexus, etc.) muscles of neck, mandible, maxilla, infratemporal fossa, sinuses, etc. |

Table 3. Extent of neck dissection for oral cancers.

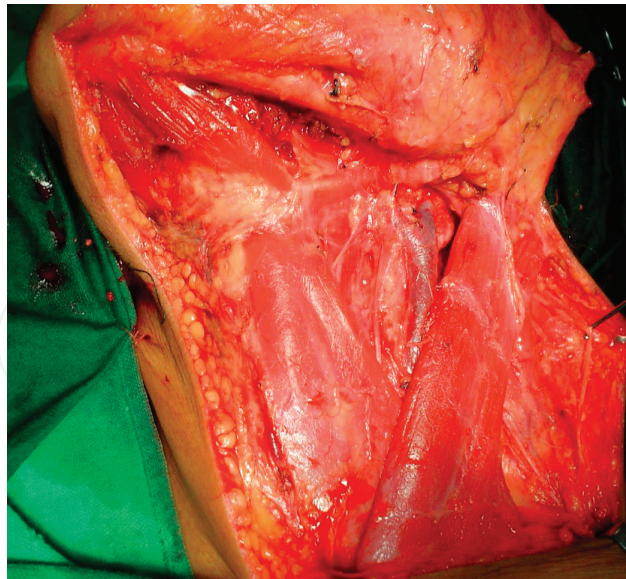


Figure 3. Selective neck dissection preserving greater auricular nerve, sternocleidomastoid muscle (SCM), internal jugular vein (IJV), spinal accessory nerve (SAN).

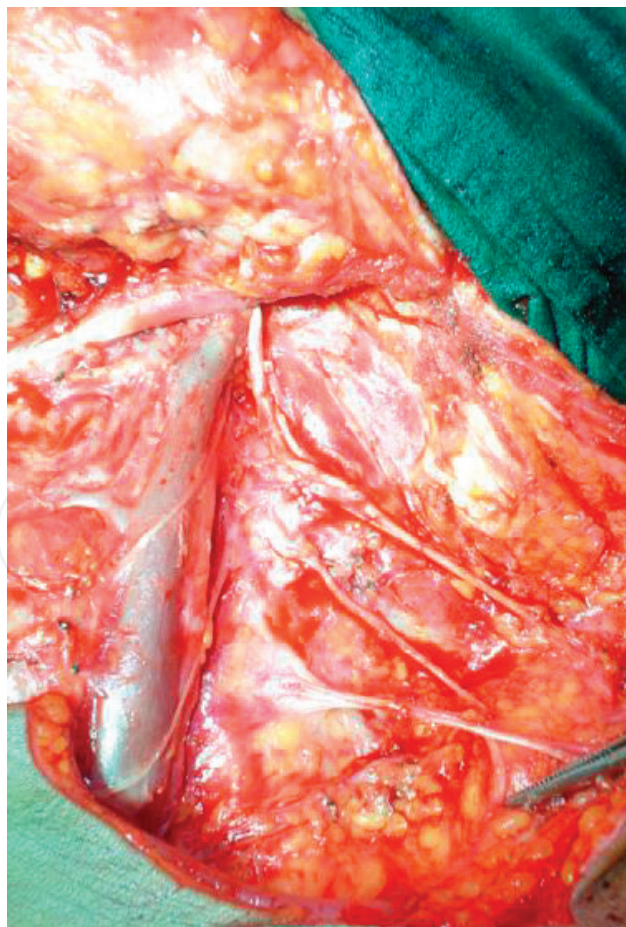


Figure 4. Modified radical neck dissection preserving IJV, SAN and sacrificing SCM.

flap. A variety of free flaps consisting of skin, muscle, bone, or any combination of these tissues are available for reconstruction in the oral cavity. There is an increasing inclination towards microvascular reconstructions for oral resections in light of better functional and cosmetic outcomes [17]. To summarize, the choice of reconstruction should be guided by the anticipated postoperative morbidity, extent of resection and the available infrastructure, resources and expertise.

2.1.3.1. Tongue

Being a very mobile organ and of paramount importance in deglutition and prevention of aspiration, reconstruction of tongue defects is a challenge (**Table 4**).

2.1.3.2. Gingivobuccal-alveolus complex

Smaller defects can be closed with local flaps such as palatal, buccal fat pad, posterior tongue flap, nasolabial flap, etc. Larger soft tissue defects should be reconstructed with FRAFF, FALT or PMMC and deltopectoral flaps depending on defect, disease and patient factors and the expertise available. Segmental mandibular defects should ideally be reconstructed with free osteocutaneous flaps like the fibular, iliac crest, scapular flap, etc. Posterior mandibular defects in old age patients can be considered for PMMC flap reconstruction. Hard palate defects can be reconstructed with dental obturators or osteocutaneous flaps.

2.2. Radiotherapy

Radiotherapy has undergone remarkable advances in the past few decades. With the advent of intensity modulated radiotherapy and image guided radiotherapy, radiation treatment delivery has become very precise with minimum damage of surrounding areas at risk [18]. Tumors of the tongue require bilateral face and neck radiation whereas buccal complex tumors warrant unilateral face and neck radiation. The primary role of radiotherapy in oral cancers is in the adjuvant setting. Upfront radiation is offered in very select cases of early small size accessible tumors (generally brachytherapy) or as a non-surgical treatment for locally advanced cancers where either surgery is contra-indicated on medical grounds.

| | |
|---------------------|---|
| <30% substance loss | Primary closure (some surgeons also consider leaving behind a raw surface for very superficial small size defects) |
| >30% tissue loss | <ol style="list-style-type: none"> 1. Free radial artery forearm flap (FRAFF) Supple, sensate 2. Pectoralis major myocutaneous flap (PMMC)/ Free anterolateral thigh flap (FALT)/ Rectus abdominis flap Provide good bulk |

Table 4. Reconstruction of tongue defects.

Indications for adjuvant radiation:

- T₃/T₄ disease
- Positive nodal metastases/multiple positive lymph nodes (>2 lymph nodes)/bilateral positive lymph nodes
- Extranodal invasion
- Poor differentiation
- Adverse pathological factors such as lymphovascular or perineural invasion
- Positive surgical margins
- Recurrent tumors

Indications for adjuvant chemoradiation [19]:

- Positive surgical margins
- Perinodal extension

Some oncologists practice concurrent chemoradiation for bulky or level IV/V nodal disease or T₃/T₄ tumors, lymphovascular or perineural invasion also [20, 21].

2.2.1. Brachytherapy

Interstitial brachytherapy represents a traditional approach for OSCC and is an alternative to external beam radiotherapy (EBRT). Brachytherapy delivers radiotherapy by positioning radioactive sources in direct proximity to the tumor target area. Brachytherapy is a feasible treatment option restricted to following conditions in oral malignancies:

- Superficial lesions (especially over lip, tip of nose where surgical resection will lead to considerable cosmetic deformity)
- Small tumors
- Tumors away from bone
- N0 nodal status

2.3. Chemotherapy

Chemotherapy has no curative potential in oral cancers.

2.3.1. Neo-adjuvant chemotherapy (NACT)

For selected T4 tumors where morbidity of resection is extremely high, NACT can be administered. Induction chemotherapy has been used as a biological decider for locally advanced borderline operable disease [22].

However, in candidates that undergo surgery, it must be borne in mind that resection margins must be planned taking into account the initial extent of the tumor and not the measurements of the shrunken tumor after NACT.

2.3.2. Palliative chemotherapy

Combination palliative chemotherapy has been documented to prolong progression free survival by few months. However, the risk benefit ratio of the disease response and systemic side effects of the chemotherapy must be critically evaluated at each stage to decide regarding continual treatment.

3. Conclusions

Oral cancer is primarily a surgically managed disease. However, treatment needs to be personalized based on subsite, stage and biology of tumor, patient health profile and the infrastructure and expertise available. Appropriate management of cervical nodal metastases has a direct bearing on prognosis. Reconstructive options must be tailored to suit patient needs in order to regain as much as possible form and function. Adjuvant treatment adherence and regular follow-up in the surveillance period should be adhered to.

4. Future prospects

PDL1 (programmed death ligand) antagonists are gaining promise as an alternative for recurrent and metastatic head and neck cancers [23]. Targeting the m TOR pathway for exploring resistance to Cetuximab is established [24]. Research and interest in Immunotherapy is also increasing however, it is still only in an experimental phase.

Author details

Neeti Kapre Gupta^{1,2,3*}, Monica Mahajan^{1,2,4} and Apeksha Hore^{1,5}

*Address all correspondence to: hi.neeti@gmail.com

1 Neeti Clinics, Nagpur, India

2 Tata Memorial Hospital, Mumbai, India

3 International Federation of Head and Neck Oncologic Societies, UK

4 SDKS Dental College, Nagpur, India

5 VSPM Dental College, Nagpur, India

References

- [1] Shah J. *Head and Neck Surgery and Oncology*. 3rd ed. St. Louis, MO: Mosby; 2003
- [2] Mohiyuddin SMA, Padiyar BV, Suresh TN, et al. Clinicopathological study of surgical margins in squamous cell carcinoma of buccal mucosa. *World Journal of Otorhinolaryngology – Head and Neck Surgery*. 2016;**2**(1):17-21
- [3] Byers RM, Bland KI, Borlase B, Luna M. The prognostic and therapeutic value of frozen section determinations in the surgical treatment of squamous carcinoma of the head and neck. *American Journal of Surgery*. 1978;**136**(4):525-528
- [4] van den Hoogen FJ, Manni JJ. Value of the supraomohyoid neck dissection with frozen section analysis as a staging procedure in the clinically negative neck in squamous cell carcinoma of the oral cavity. *European Archives of Oto-Rhino-Laryngology*. 1992;**249**(3):144-148
- [5] Chaturvedi P, Datta S, Nair S, Nair D, Pawar P, Vaishampayan S, et al. Gross examination by the surgeon as an alternative to frozen section for assessment of adequacy of surgical margin in head and neck squamous cell carcinoma. *Head & Neck*. 2014;**36**(4):557-563
- [6] <http://www.jhnps.org>. IP: 49.248.194.11
- [7] Calabrese L, Bruschini R, Giugliano G, Ostuni A, Maffini F, Massaro MA, et al. Compartmental tongue surgery: Long term oncologic results in the treatment of tongue cancer. *Oral Oncology*. 2011;**47**(3):174-179
- [8] Namin AW, Bruggers SD, Panuganti BA, Christopher KM, Walker RJ, Varvares MA. Efficacy of bone marrow cytologic evaluations in detecting occult cancellous invasion. *The Laryngoscope*. 2015;**125**(5):E173-E179
- [9] D'Cruz AK, Vaish R, Kapre N, et al. Elective versus therapeutic neck dissection in node-negative oral cancer. *The New England Journal of Medicine*. 2015;**373**(6):521-529
- [10] Spiro RH, Huvos AG, Gy W, et al. Predictive value of tumor thickness in squamous cancer confined to the tongue and floor of mouth. *American Journal of Surgery*. 1986;**152**:345-350
- [11] Shah JP. Patterns of nodal metastasis from squamous cell carcinomas of the upper aerodigestive tract. *American Journal of Surgery*. 1990;**160**:405-409
- [12] Pantvaidya GH, Pal P, Vaidya AD, Pai PS, D'Cruz AK. Prospective study of 583 neck dissections in oral cancers: Implications for clinical practice. *Head and Neck*. 2014;**36**(10):1503-1507
- [13] Brazilian Head and Neck Cancer Study Group. Results of a prospective trial of elective modified radical classical versus supraomohyoid neck dissection in the management of oral squamous cell carcinoma. *American Journal of Surgery*. 1996;**176**:422-427
- [14] Schilling C, Stoeckli SJ, Haerle SK, et al. Sentinel European Node Trial (SENT): 3-year results of sentinel node biopsy in oral cancer. *European Journal of Cancer*. 2015;**51**(18):2777-2784

- [15] Shah J. Surgical approaches to the oral cavity primary and neck. *International Journal of Radiation Oncology, Biology, Physics*. 2007;**69**(2(Suppl)):S15-S18
- [16] Susan D et al. Radical neck dissection. *Operative Techniques in Otolaryngology*. 2004;**15**:152-159
- [17] Urken ML, Buchbinder D, Weinberg H, Vickery C, Sheiner A, Parker R, et al. Functional evaluation following microvascular oromandibular reconstruction of the oral cancer patient: A comparative study of reconstructed and nonreconstructed patients. *The Laryngoscope*. 2015;**125**(7):1512
- [18] Nutting CM, Morden JP, Harrington KJ, et al. Parotid-sparing intensity modulated versus conventional radiotherapy in head and neck cancer (PARSPORT): A phase 3 multi-centre randomised controlled trial. *The Lancet Oncology*. 2011;**12**(2):127-136
- [19] Bernier J, Cooper JS. Chemoradiation after surgery for high-risk head and neck cancer patients: How strong is the evidence? *The Oncologist*. 2005;**10**(3):215-224
- [20] Bernier J, Dommenege C, Ozsahin M, et al. Postoperative irradiation with or without concomitant chemotherapy for locally advanced head and neck cancer. *The New England Journal of Medicine*. 2004;**350**(19):1945-1952
- [21] Cooper JS, Pajak TF, Forastiere AA, et al. Postoperative concurrent radiotherapy and chemotherapy for high-risk squamous-cell carcinoma of the head and neck. *The New England Journal of Medicine*. 2004;**350**(19):1937-1944
- [22] Patil VM, Prabhash K, Noronha V, et al. Neoadjuvant chemotherapy followed by surgery in very locally advanced technically unresectable oral cavity cancers. *Oral Oncology*. 2014;**50**(10):1000-1004
- [23] Seiwert TY, Burtneess B, Mehra R, et al. Safety and clinical activity of pembrolizumab for treatment of recurrent or metastatic squamous cell carcinoma of the head and neck (KEYNOTE-012): An open-label, multicentre, phase 1b trial. *The Lancet Oncology*. 2016;**17**(7):956-965
- [24] Wang Z, Martin D, Molinolo AA, et al. mTOR co-targeting in cetuximab resistance in head and neck cancers harboring PIK3CA and RAS mutations. *Journal of the National Cancer Institute*. 2014;**106**(9):pii:dju215. DOI: 10.1093/jnci/dju215. Print Sep 2014