

We are IntechOpen, the world's leading publisher of Open Access books Built by scientists, for scientists

4,800

Open access books available

122,000

International authors and editors

135M

Downloads

Our authors are among the

154

Countries delivered to

TOP 1%

most cited scientists

12.2%

Contributors from top 500 universities



WEB OF SCIENCE™

Selection of our books indexed in the Book Citation Index
in Web of Science™ Core Collection (BKCI)

Interested in publishing with us?
Contact book.department@intechopen.com

Numbers displayed above are based on latest data collected.
For more information visit www.intechopen.com



Role of Radiotherapy in High Grade Glioma

Henrique Balloni

Abstract

The aim of this review is to explore the changing utility of radiotherapy in the treatment of patients with glioblastoma over the past decades. Surgery and radiotherapy has always been the cornerstone of treatment of glioblastoma, but techniques have significantly advanced over this time. We selected the main studies that support the advances of radiotherapy in the present day as well as controversies in several aspects of the treatment will be approached; definition of the target volume in the magnetic resonance imaging (MRI) planning, size of the margins around the target volume; prescribed dose (standard vs. hypofractionated); management of glioblastoma in elderly; review role of radiosurgery past and new potential use in recurrence and the evidence of reirradiation in patients with local recurrence. Finally, continued development on many fronts have allowed for modestly improved outcomes while at the same time limiting toxicity.

Keywords: glioblastoma, radiotherapy, target volume, hypofractionated, radiosurgery

1. Introduction

The benefit of radiation therapy in patients with newly diagnosed glioblastoma has been demonstrated in many randomized trials and has been the basis of treatment for decades. To make an effort to achieve and improve the very poor outcomes associated with this disease, numerous therapeutics have been added to radiation though with lack of success until the landmark study by Stupp et al. [1] established a standard of care of treatment, gross surgical excision followed by concurrent temozolomide and radiation.

The use of radiation in glioblastoma is constantly evolving as a result of advances in imaging methods and personalized medicine leading to continuous controversies over the delineations of tumor volume.

Multiple recent studies on personalized medicine, especially in elderly patients with glioblastoma suggest that the role and dose/fractionation of radiation delivery to this increasing population will continue to develop. This chapter will highlight the major historical studies that have resulted in radiation being the current standard of care; discuss the continuing controversies of volume delineation in radiation delivery planning; discuss dose evolution and fractionation of radiotherapy in the management of patients; and review studies and ongoing trials on the use of radiation in the salvage scenario.

2. Radiotherapy target volume definitions

In the 1970s, a randomized trial showed that 60 Gy of postoperative whole-brain RT (WBRT) could improve the survival for patients with high-grade glioma (HGG). Since then, postoperative RT was a standard treatment for newly diagnosed HGG. [2] However, other studies started to compare WBRT with partial-brain irradiation and concluded that there was no advantage of WBRT [3]. Tomography (CT) and magnetic resonance imaging (MRI) has contributed largely to improve the accuracy of tumor delineation and establish that partial-brain irradiation standard to treat HGG [4]. The three-dimensional (3D) conformal radiation technique makes partial-brain irradiation for glioma possible and reduces neurotoxicity [5]. The image fusion pre- and postoperative MRI with planning CT images is normally used to determine the RT treatment volume for GBM. However, the optimal treatment volume for GBM remains a controversial issue and varies among different institutions. The Radiation Therapy Oncology Group (RTOG) refers to a two-phase treatment at 60 Gy, where the initial clinical target volume (CTV) typically includes postoperative peritumoral edema plus a 2 cm margin, followed by a boost field defined as the residual tumor plus a 2 cm margin (as per RTOG 0525 and RTOG 0825 trials) [6]. Inversely, the European Organization for Research and Treatment of Cancer (EORTC) defines a single-phase treatment with 2–3 cm dosimetric margins around the tumor (as evaluated by MRI), because 80–90% of treatment failures occur within this margin [1]. The University of Texas MD Anderson Cancer Center uses a 2 cm margin around the gross tumor volume (GTV), which consists of the resection cavity and any residual contrast-enhancing tumor without regard to edema [7]. However, several studies have raised the hypothesis that the results are similar when using reduced margins as small as 5 mm to delineate the CTV in the treatment of GBM [8].

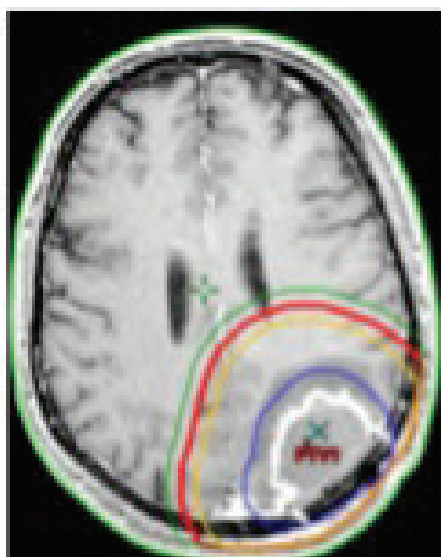
In daily clinical practice between different institutions, the margins of the planned target volume vary significantly. A survey of radiation oncologists in Canada showed that 32 and 14% followed the RTOG and EORTC guidelines, respectively, while 54% followed the center's specific guidelines. Biphasic treatments were reported by 37% and single-phase by 60% of clinicians. For clinicians treating in single phase, 61% treat the surgical cavity and enhancing tumor with a margin, and 33% treat an area that includes tumor edema in addition to the surgical cavity and enhancing tumor. The GTV margins to generate the planning treatment volume (PTV) also varied widely and included 0.5 cm (6%), 1 cm (6%), 1.5 cm (25%), 2 cm (56%), 2.5 cm (25%), and 3 cm (12.5%). For clinicians treating in multiple phases, 90% include peritumoral edema in Phase I of the treatment. In Phase II, respondents reported using total margins (from GTV to PTV) of 1 cm (10%), 2 cm (40%), 2.5 cm (30%), and 3 cm (20%) [9]. Examples of differences in guidelines are shown (Table 1 and Figures 1 and 2).

2.1 Peritumoral edema

It is discussed regarding the inclusion of edema in the treatment plan. The rationale for including peritumoral edema is that such areas are believed to contain high concentrations of tumor cells. A study compared the histopathologic distributions of neoplastic cells in GBM with the corresponding CT images and found that the vast majority of the neoplastic tissue was contained within the contrast-enhancing and low-density peritumoral areas; however, the CT low-density area was not always identical to the area infiltrated by tumor cells. No tumor cells were found in some areas of low density, whereas, in some instances, normal appearing brain tissue beyond the CT low-density area was also found to contain tumor cells [10]. Furthermore, Halperin et al. [11] compared preoperative CT scans with the postmortem topography of recurrent tumors and found that 9/11 (81.8%) tumor cells were found beyond the enhancement area plus a 1 cm margin on CT. Indeed,

Clinical Trial	CTV Margin	RT Dose
RTOG(9)	T2+ 2cm (pink)	46 Gy
	T1+2.5 cm (Red)	14 Gy
EORTC(4)	T1+2-3 cm (Green)	60 Gy
MD Anderson(10)	T1+ 2 cm (yellow)	60 Gy
Atlanta(11)	T2+0,7 cm	46Gy
	T1+0,5 cm (blue)	or 54Gy 60 Gy

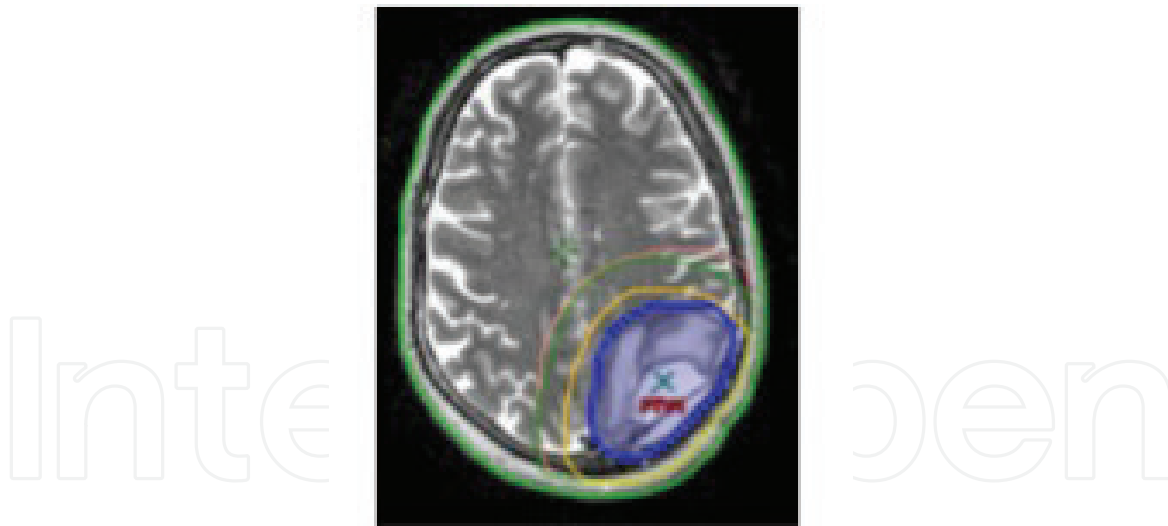
Table 1.
 The definition of radiation treatment volumes during the delineation of high-grade gliomas.



MRI T1 contrast enhanced .
 PTV(s) 60Gy volume by
 clinical trial (green EORTC,
 red RTOG, yellow MD
 anderson and Blue Atlanta)

Figure 1.
 Example planning treatment volumes (PTV) delineation of high grade. MRI T1 contrast enhanced showing in colors lines different protocol volumes.

only treatment plans that covered the contrast-enhancing tumor, the “edema” volume, plus an additional 3 cm margin would cover the entire histologically identified tumor. Kelly et al. [12] also reported on the correlation between histopathologic and MRI findings for 177 biopsy specimens from 39 patients with glial neoplasms. Pathologic evaluation of biopsy specimens obtained from various locations in the volumes defined by CT and MRI showed that contrast enhancement most



MRI T2. PTV(s) volume by clinical trial (PTV 60Gy green EORTC, PTV 46 pink RTOG, PTV 60 Gy yellow MD anderson and PTV 46Gy Blue Atlanta)

Figure 2.

Example planning treatment volumes (PTV) delineation of high grade. MRI T2 showing in colors lines different protocols volumes

often corresponded to tumor tissue without intervening parenchyma, whereas hypodensity corresponded to parenchyma infiltrated by isolated tumor cells or, in some instances, in low-HGGs, to tumor tissue or to edema. For the normal T1- and T2-weighted MRI regions that were biopsied, there was a false-negative rate of 69 and 40%, respectively [13]. A study conducted by Lu et al. [13] analyzed peritumoral edema using diffusion tensor MR imaging. This group divided gliomas associated with peritumoral edema into tumor-infiltrated edema and purely vasogenic edema.

It is controversial the prognostic of peritumoral edema. Some authors considered peritumoral edema on a preoperative MRI to be an independent prognostic factor, in addition to the postoperative Karnofsky performance score (KPS), age, and type of tumor resection [14]. Patients with major edema (>1 cm) had a significant shorter overall survival (OS) time, compared to patients with minor edema (<1 cm). Another study established that peritumoral edema, noncontrast-enhancing tumor, satellites, and multifocality were independent prognostic factors for survival in GBM, whereas preoperative tumor size, tumor location, and extent of necrosis had no significant impact on survival [15]. Conversely, there was no correlation between peritumoral edema, patient age, and tumor volume, but there was an association between edema, tumor location, and necrosis [16]. Similarly, Ramakrishna et al. [17] analyzed the predictive value of abnormal MRI features for the survival of patients with GBM. The result demonstrated that tumor burden and invasion characteristics indicated by the T1-weighted gadolinium-enhanced MRI were significant predictors of patient survival, but the total area of signal intensity abnormalities on the T2-weighted images and the T2/T1 ratio did not correlate with patient outcome.

In summary, for patients with GBM, the significance of peritumoral edema for the survival of a patient with GBM is not clear. A majority of tumor tissues are contained

within the contrast enhancement areas in T1-weighted MRI, but not always, and infiltrate into the peritumoral edema area. We believe that GTV in HGG for RT should be focus in T1-weighted MRI and surgical bed, regarding the peritumoral edema area. In addition, the ability to accurately distinguish tumor-infiltrated edema from vasogenic edema composed purely of extracellular water could be helpful for target delineation. It is hoped that advances in image techniques will enable this in the future.

2.2 Recurrent patterns of postoperative GBM

Several studies have studied the pattern of relapse in patients with glioblastoma. One of them [18] retrospectively analyzed the patterns of radiographic presentation of 80 adult patients with supratentorial GBM at four clinically relevant time points: presentation, first recurrence, second recurrence, and third recurrence. At diagnosis, 87.5% (70/80), 6.25% (5/80), 3.75%, and 2.5% of patients presented with unifocal disease and distant, multifocal, and diffuse MRI-defined radiographic patterns, respectively. After RT and temozolamide treatment local recurrence occurs in 80%, distant in 7.5% and multifocal in 6.25% (including one with cerebrospinal fluid dissemination), and 6.25% was diffuse. In the same way, Wallner et al. [19] found that 78% of unifocal anaplastic astrocytoma and GBM recurrences occurred within 2 cm of the presurgical original tumor extent, which is defined as the enhancing edge of the tumor on preoperative CT, and 56% (18/32) of tumors recurred within 1 cm of the initial tumor margin. Liang et al. [20] published the pattern of failure for 42 patients with grade III or IV astrocytoma treated with chemoradiotherapy to a total of 60 Gy. In all 42 patients, recurrence occurred within a 2 cm margin of the original CT-enhancing lesion, and 10% of the patients suffered from multifocal recurrence. In a retrospective series of 34 patients treated either with WBRT and conformal boost or entirely with 3D conformal RT, Oppitz et al. [21] revealed that all GBM recurrences occurred within the 90% isodose line when targets were contoured around the original preoperative contrast-enhancing tumor plus a 2 cm margin. More than 80% of the recurrences occur in 2 cm of the surgical bed dose-escalation studies analyzed 36 patients with HGGs treated with radiation alone to 70–80 Gy using the 3D conformal techniques [22]. In this study, recurrences were divided into several categories: (1) “central,” in which 95% or more of the recurrent tumor volume (V_{recur}) was within D95, the region treated to a high dose (95% of the prescription dose); (2) “infield,” in which 80% or more of V_{recur} was within the D95 isodose surface; (3) “marginal,” when between 20 and 80% of V_{recur} was inside the D95 surface; and (4) “outwith,” in which <20% of V_{recur} was inside the D95 surface. This study found that 89% of the recurrences were central or infield, 3/36 (8%) had a marginal recurrence pattern, and only one patient (3%) clearly failed outside of the high-dose region. Another trial [7] reported similar patterns of failure in a series of 48 patients with GBM, comparing treatment guidelines based on residual tumor and cavity plus 2 cm margin, as used at the MD Anderson Cancer Center, with RTOG guidelines that specified the inclusion of preoperative peritumoral edema. They showed that 90% (43/48) of patients failed in central and infield locations. The five remaining marginal and distal recurrences failed to be covered by the 46 Gy isodose line, even when overlaid by the RTOG plan incorporating edema volume, confirming them to be true marginal recurrences. Additionally, Minniti et al. [23] compared recurrence patterns in 105 patients whose surgical resections were delineated by the EORTC contouring technique, wherein the CTV includes the resection cavity, and any residual tumor seen on postoperative T1-weighted MRI, plus a 2 cm margin, and the PTV includes the CTV plus an additional 3 mm margin. After recurrence was confirmed, a theoretical plan, based on the addition of postoperative edema plus 2 cm margins, according to the current

RTOG guidelines, was created for each patient. The radiation coverage of the site of subsequent recurrences was compared for the different contouring techniques. The results revealed no significant differences in relapse patterns between the two target delineation techniques. Although, the median percent volume of normal brain irradiated to high doses was significantly smaller using the EORTC guideline. In our opinion, these data provide some evidence and reassurance to support treatment plans based on resection cavity and any residual tumor seen on postoperative T1-weighted MRI with a 2 cm margin, rather than specified inclusion of preoperative peritumoral edema plus a 2 cm margin. The use of this limited-margin RT can significantly decrease the volume of normal brain tissue that is irradiated, without a significant increase in the risk of marginal recurrences. A number of studies have been conducted to explore the feasibility of limited-margin RT in the context of a treatment paradigm involving RT with concurrent chemotherapy. Trying to reduce treatment volume, McDonald et al. [8] report the pattern of tumor failure in a series of 62 patients with GBM treated with postoperative limited-margin RT and concurrent chemotherapy. The initial CTV included the postoperative T2 abnormality, with a median margin of 0.7 cm. The boost CTV included the residual T1-enhancing tumor and resection cavity, with a median margin of 0.5 cm. The PTV margin varied from an additional 0.3 cm–0.5 cm. The initial dose was 46–54 Gy, followed by a boost to 60 Gy. In this study, the total boost PTV (PTV_{boost}) margin was 1 cm or less in 92% of the patients. Results showed that 38/41 patients (93%) had a central or infield failure, two (5%) had a marginal failure, and one (2%) had a distant failure, relative to the 60 Gy isodose line. The author concluded that a PTV_{boost} margin of 1 cm or less did not appear to increase the risk of marginal and/or distant tumor failure, compared with other published series. In the same direction, Dobelbower et al. [24] analyzed the patterns of failure in patients with GBM treated with concurrent radiation and TMZ. Patients generally received 46 Gy to the primary tumor, surrounding edema, plus a 1 cm margin and 60 Gy to the enhancing tumor plus a 1 cm margin. The result revealed that 18 patients (90%) had infield failures, 2 patients (10%) had marginal failures, and no regional failures were reported. Four patients (20%) suffered from distant failure, in which an independent satellite lesion was located completely outwith the 95% isodose curve. These studies also suggested that by delineating the GTV based on peritumoral edema, it is feasible to reduce the margin to 1 cm or less. Clinical studies showed that the volume of irradiated brain is important factor in the development of neurotoxicity and for the development of radiographic and pathologic surrogates for neurotoxicity [25–28].

Smaller RT fields may be more appropriate than larger RT fields, possibly reducing the risk of late neurological deterioration especially in patients with large peritumoral edema. The neurocognitive function would be likely to be affected by radiation therapy especially in long-term survivors [29].

The pattern of failure for GBM after radiation therapy has been studied previously; almost all tumors fail within a 2 cm margin of the resection cavity or residual tumor. The primary failure location was infield, but some patients had marginal failures, and few had a distant failure or an independent satellite lesion. Taking these data into consideration, we conclude that it is preferable to contour the GTV based on the T1-enhanced MRI, and regard the peritumoral edema as a subclinical lesion. We suggest that the CTV should be identified based on the residual T1-enhancing tumor and resection cavity (GTV) with a 2 cm margin or the postoperative T2 or FLAIR (fluid-attenuated inversion recovery) abnormality; however, in the case of a cone-down boost phase, the CTV should include the GTV with a 1 cm margin.

3. Dose

Standard therapy for HGG patients is a total dose of 60 Gy in 30–33 fractions [30]. Adequate doses of RT are required to maximize the survival benefit [31–33]. One important study conducted by Walker et al. evaluated the relationship between survival and increasing doses of RT in malign gliomas [33]. Doses ranged from <45 Gy to 60 Gy. They showed that there was a significant improvement in median survival from 28 to 42 weeks in the groups treated with doses of 50–60 Gy. There is no benefit for dose escalation of >60 Gy. In two randomized trials, there were no significant differences in tumor control or survival in patients treated with 60 Gy cranial radiation or 60 Gy followed by a 10 Gy tumor boost [34, 35]. Two series [35, 36] analyzed failure patterns for patients with HGG dose escalation levels 70, 80, and 90 Gy. The GTV was defined based on postoperative gadolinium-enhanced T1-weighted images. They defined three separate PTVs in three dimensions by 0.5 cm to make PTV1, 1.5 cm to make PTV2, and 2.5 cm to make PTV3 from GTV. At median follow-up of 11.7 months, median survival was found to be 11.7 months, and 1- and 2-year survivals were 47.1% and 12.9%, respectively. The authors concluded that despite dose escalation to 90 Gy, the predominant failure pattern in HGG remained local. This suggested that close margins used in highly conformal treatments did not increase the risk of marginal or distant recurrences. Since the majority of tumor recurrences were seen within the previous radiation therapy fields and the poor outcomes associated with standard regimen, the new therapy strategies were evaluated to deliver higher doses to the tumor bed. Higher doses for HGG have been attempted with a variety of methods, including altered fractionation [37, 38], stereotactic radio surgery [39], and brachytherapy [40].

The term “conventional RT” refers to giving daily radiation of 180–200 cGy per day. “Hypofractionated RT” refers to the use of a higher daily dose of radiation (> 200 cGy per day) which typically reduces the overall number of fractions and therefore the overall treatment time. “Hyperfractionated RT” defined as the use of a lower daily dose of radiation (< 180 cGy per day), a greater number of fractions and multiple fractions delivered per day in order to deliver a total dose at least equivalent to external beam daily conventionally fractionated RT in the same time frame. The aim of this approach is to reduce the potential for late toxicity [41, 42]. In this study, the authors compared hyperfractionated RT (with or without chemotherapy) vs. conventionally fractionated RT (without chemotherapy). The trial included 81 HGG patients randomized to conventional fractionation (5800 cGy in 30 daily fractions) or hyperfractionation (6141 cGy in 89 cGy fractions given 3 times a day every 2–4 hours for 4.5 weeks). Median survival in two groups was 39 and 27 weeks, respectively, and the 1-year survival rates were 41 and 20%, respectively. Others have failed to confirm these results. Therefore, there is insufficient data regarding hyperfractionation vs. conventionally fractionated radiation (without chemotherapy) and insufficient data regarding accelerated radiation vs. conventionally fractionated radiation (without chemotherapy) [43].

“Hypofractionated RT” refers to the delivery of higher daily dose to reduce the overall treatment time. Five studies that randomized participants to hypofractionated radiation therapy vs. conventionally fractionated RT [43]. Their results suggested that hypofractionated RT has similar efficacy for survival as compared to conventional radiotherapy, especially for individuals aged 60 and older with HGG. A randomized controlled trial (RCT) and several retrospective studies conducted in the elderly suggest that short course-radiation therapy (SCRT) of 34–40 Gy in 2.6–3.4 Gy fractions, with or without TMZ, may have similar results to LCRT [44–46]. Results from the Nordic trial suggested that SCRT may be superior to LCRT in patients aged ≥ 70 years [47]. An International Atomic Energy Agency Randomized Phase III Study of Radiation Therapy in Elderly and/or Frail Patients

with Newly Diagnosed Glioblastoma Multiforme showed no differences in overall survival time, progression-free survival time, and quality of life between patients receiving the two radiotherapy regimens (25 Gy in five daily fractions over 1 week vs. 40 Gy in 15 daily fractions over 3 weeks) [48].

There are no data comparing optimal dose and schedule in grade III gliomas vs. GBM. However, many radiation oncologists use a dose of 59.4 Gy in 1.8 Gy fractions for grade III tumors vs. 60 Gy in 2 Gy fractions for grade IV tumors with the expectation that dose reduction per fraction may lead to reduced late normal tissue effects for patients with probability longer-term survival [49].

4. Stereotactic radiotherapy and radiosurgery (SRS)

Stereotactic radiotherapy or radiosurgery (SRS) uses three-dimensional planning techniques to precisely deliver narrowly collimated beams of ionizing radiation in a single high-dose fraction to small lesions [50, 51]. This technique in primary treatment of HGG was used in some trials a boost (additional dose). The treatment was composed of 50 Gy conventional RT and four SRT boost fractions of either 5 or 7 Gy. SRT was administered once weekly during the final 4 weeks of therapy. The results suggested that while the regimen was safe, there was no survival benefit compared to the standard of care. Some retrospective studies suggest that it may be used in patients with recurrent HGG previously irradiated. A number of small prospective and retrospective series suggest that SRS may prolong survival in this setting, either alone or in combination with chemotherapy [52]. It is important to know the bias of these studies including the initial radiation dose, extent of initial and second surgical resections, tumor volume at the time of SRS, and timing and use of chemotherapy and the time between initial radiation therapy and retreatment have clear implications on patient outcomes but are variably reported [52, 53]. Patients newly diagnosed with progressive/recurrent gliomas, there is insufficient evidence in terms of the benefits/harms of using SRS/SRT. There is also insufficient evidence regarding the benefits/harms in the use of SRS/SRT at the time of progression or recurrence.

5. Reirradiation in recurrent high-grade gliomas

Tumor recurrence is inevitable in HGG patients, but diagnostic of progressive disease from radiation necrosis or other radiation-induced imaging changes could be a big challenge. Treatment decisions for patients with recurrent or progressive HGG must be individualized, since therapy is not curative and there are no randomized trials that directly compare active intervention vs. supportive care. Reoperation is an important treatment modality and may involve either biopsy (for diagnostic purposes) or repeat debulking of tumor, but only 20–30% of recurrent HGG patients are candidates for another surgery [54]. Focal RT approaches are often employed with limited volume recurrences; however, the role of reirradiation in patients with recurrent HGG is uncertain, and there is a lack of prospective data. Based on retrospective series, selected patients with small recurrent tumors and a good performance status may benefit from repeat radiation using modern high-precision techniques [55]. In a small series of 101 patients with recurrent HGG, the median survival was 12 months for patients with grade III tumors and 8 months for those with grade IV lesions. In this study SBRT was performed with a median dose of 36 Gy (range 15–62) [56].

6. Toxicity of radiotherapy

The toxicity of RT usually divided into acute and late effects, effects differentiated by time that occur, during radiation or up to 3 months afterward, early-delayed effects that appear up to 6 months after radiation, and late effects that can develop 6 months or more after the completion of radiation. Usually, acute reactions are reversible, and late reactions are generally irreversible. Most common acute radiation morbidity during cranial irradiation includes fatigue, erythema, alopecia, headache, and nausea with or without vomiting; these are usually not severe and are self-limiting [49]. The factors influencing the likelihood of developing complications include the volume of normal brain tissue treated and the total radiation dose. Fatigue is one of the most common side effects of cranial irradiation. In a prospective study with 70 consecutive patients receiving radical cranial irradiation, most of the patients were treated for GBM, and their results suggested that 90% of the patients experienced \geq grade 1 symptoms (disturbance with some tiredness, but activity not curtailed), and approximately half experienced mild to moderate symptoms like decreased activity and increased tiredness, sleeping much of the day or most activities curtailed. The symptoms typically began within 2 weeks of the start of RT, peaked at approximately 6–8 weeks, and then slowly resolved over the next several months. Corticosteroids or antiemetic are used to prevent or abbreviate the symptoms. Late effects including cognitive impairments and radiation necrosis are worrisome and may become manifest many years after RT [57]. Cranial irradiation can result in a spectrum of neurocognitive deficits in the years following treatment in children and in adults. The data of radiation-induced cognitive impairment is mostly learned from studies that are conducted in low-grade glioma patients. Cognitive functioning in patients with brain tumor was affected by the antiepileptic drug use, extent of surgery, tumor localization, and age [57]. Radiation necrosis is a serious and uncommon late toxicity that typically develops 1–3 years after radiation, but in rare cases it has been reported more than 10 years after radiation [58]. The probability of radiation necrosis is strict dependence on the dose. Focal brain radiation with doses around 70 Gy using conventional 2 Gy fractionation risk of focal radiation necrosis is usually estimated in 5% in 5 years [59]. The risk of radiation necrosis probably increases with concurrent chemotherapy or radio sensitizers [60].

7. Conclusion

The standard of care for HGG adults, up to age 70 with good performance status, is conformal fractionated radiotherapy (6000 cGy in 30 daily fractions) with the addition of concurrent and adjuvant temozolomide chemotherapy following maximal safe debulking of the tumor. Elderly patients, older than 70 years or with poor performance status, hypofractionated RT has similar efficacy for survival as compared to conventional radiotherapy.

The optimal treatment volume for HGG patients remains controversial and varies among cooperative groups; dose escalation above 60 Gy or stereotactic radiosurgery has not shown any survival benefits. Treatment decisions for patients with recurrent or progressive HGG must be individualized, since therapy is not curative and there are no randomized trials that directly compare active intervention vs. supportive care.

IntechOpen

IntechOpen


Author details

Henrique Balloni

Department of Radiation Oncology of Oncoville Oncoville, Curitiba PR, Brazil

*Address all correspondence to: henriqueballoni@gmail.com

IntechOpen

© 2019 The Author(s). Licensee IntechOpen. This chapter is distributed under the terms of the Creative Commons Attribution License (<http://creativecommons.org/licenses/by/3.0>), which permits unrestricted use, distribution, and reproduction in any medium, provided the original work is properly cited. 

References

- [1] Stupp R, Mason WP, van den Bent MJ, et al. Radiotherapy plus concomitant and adjuvant temozolomide for glioblastoma. *The New England Journal of Medicine*. 2005;**352**(10):987-996. DOI: 10.1056/NEJMoa043330
- [2] Walker MD, Alexander E Jr, Hunt WE, et al. Evaluation of BCNU and/or radiotherapy in the treatment of anaplastic gliomas. A cooperative clinical trial. *Journal of Neurosurgery*. 1978;**49**(3):333-343. DOI: 10.3171/jns.1978.49.3.0333
- [3] Shapiro WR, Green SB, Burger PC, et al. Randomized trial of three chemotherapy regimens and two radiotherapy regimens and two radiotherapy regimens in postoperative treatment of malignant glioma. Brain tumor cooperative group trial 8001. *Journal of Neurosurgery*. 1989;**71**(1):1-9. DOI: 10.3171/jns.1989.71.1.0001
- [4] Heesters MA, Wijrdeman HK, Struikmans H, Witkamp T, Moerland MA. Brain tumor delineation based on CT and MR imaging. Implications for radiotherapy treatment planning. *Strahlentherapie und Onkologie*. 1993;**169**(12):729-733. PMID 8284745
- [5] Leibel SA, Scott CB, Loeffler JS. Contemporary approaches to the treatment of malignant gliomas with radiation therapy. *Seminars in Oncology*. 1994;**21**(2):198-219. PMID: 8153665
- [6] Colman H, Berkey BA, Maor MH, et al. Phase II radiation therapy oncology group trial of conventional radiation therapy followed by treatment with recombinant interferon-beta for supratentorial glioblastoma: Results of RTOG 9710. *International Journal of Radiation Oncology, Biology, Physics*. 2006;**66**(3):818-824. DOI: 10.1016/j.ijrobp.2006.05.021
- [7] Chang EL, Akyurek S, Avalos T, et al. Evaluation of peritumoral edema in the delineation of radiotherapy clinical target volumes for glioblastoma. *International Journal of Radiation Oncology, Biology, Physics*. 2007;**68**(1):144-150. DOI: 10.1016/j.ijrobp.2006.12.009
- [8] McDonald MW, Shu HK, Curran WJ Jr, Crocker IR. Pattern of failure after limited margin radiotherapy and temozolomide for glioblastoma. *International Journal of Radiation Oncology, Biology, Physics*. 2011;**79**(1):130-136. DOI: 10.1016/j.ijrobp.2009.10.048
- [9] Ghose A, Lim G, Husain S. Treatment for glioblastoma multiforme: Current guidelines and Canadian practice. *Current Oncology*. 2010;**17**(6):52-58. PMID: 21151410
- [10] Burger PC, Dubois PJ, Schold SC Jr, et al. Computerized tomographic and pathologic studies of the untreated, quiescent, and recurrent glioblastoma multiforme. *Journal of Neurosurgery*. 1983;**58**(2):159-169. DOI: 10.3171/jns.1983.58.2.0159
- [11] Halperin EC, Bentel G, Heinz ER, Burger PC. Radiation therapy treatment planning in supratentorial glioblastoma multiforme: An analysis based on post mortem topographic anatomy with CT correlations. *International Journal of Radiation Oncology, Biology, Physics*. 1989;**17**(6):1347-1350. PMID:2557310
- [12] Kelly PJ, Daumas-Duport C, Kispert DB, Kall BA, Scheithauer BW, Illig JJ. Imaging-based stereotaxic serial biopsies in untreated intracranial glial neoplasms. *Journal of Neurosurgery*. 1987;**66**(6):865-874. DOI: 10.3171/jns.1987.66.6.0865
- [13] Lu S, Ahn D, Johnson G, Law M, Zagzag D, Grossman

- RI. Diffusion-tensor MR imaging of intracranial neoplasia and associated peritumoral edema: Introduction of the tumor infiltration index. *Radiology*. 2004;**232**(1):221-228. DOI: 10.1148/radiol.2321030653
- [14] Schoenegger K, Oberndorfer S, Wuschitz B, et al. Peritumoral edema on MRI at initial diagnosis: An independent prognostic factor for glioblastoma? *European Journal of Neurology*. 2009;**16**(7):874-878. DOI: 10.3171/jns.1987.66.6.0865
- [15] Pope WB, Sayre J, Perlina A, Villablanca JP, Mischel PS, Cloughesy TF. MR imaging correlates of survival in patients with high-grade gliomas. *AJNR. American Journal of Neuroradiology*. 2005;**26**(10):2466-2474. PMID:16286386
- [16] Iliadis G, Kotoula V, Chatzisotiriou A, et al. Volumetric and MGMT parameters in glioblastoma patients: Survival analysis. *BMC Cancer*. 2012;**12**:3. DOI: 10.1186/1471-2407-12-3
- [17] Ramakrishna R, Barber J, Kennedy G, et al. Imaging features of invasion and preoperative and postoperative tumor burden in previously untreated glioblastoma: Correlation with survival. *Surgical Neurology International*. 2010;**1**:40. DOI: 10.4103/2152-7806.68337
- [18] Chamberlain MC. Radiographic patterns of relapse in glioblastoma. *Journal of Neuro-Oncology*. 2011;**101**(2):319-323. DOI: 10.1007/s11060-010-0251-4
- [19] Wallner KE, Galicich JH, Krol G, Arbit E, Malkin MG. Patterns of failure following treatment for glioblastoma multiforme and anaplastic astrocytoma. *International Journal of Radiation Oncology, Biology, Physics*. 1989;**16**(6):1405-1409. PMID:2542195
- [20] Liang BC, Thornton AF Jr, Sandler HM, Greenberg HS. Malignant astrocytomas: Focal tumor recurrence after focal external beam radiation therapy. *Journal of Neurosurgery*. 1991;**75**(4):559-563. DOI: 10.3171/jns.1991.75.4.0559
- [21] Oppitz U, Maessen D, Zunterer H, Richter S, Flentje M. 3D-recurrence-patterns of glioblastomas after CT-planned postoperative irradiation. *Radiotherapy and Oncology*. 1999;**53**(1):53-57. DOI: 10.1186/s13014-016-0665-z
- [22] Lee SW, Fraass BA, Marsh LH, et al. Patterns of failure following high-dose 3-D conformal radiotherapy for high-grade astrocytomas: A quantitative dosimetric study. *International Journal of Radiation Oncology, Biology, Physics*. 1999;**43**(1):79-88. PMID:9989517
- [23] Minniti G, Amelio D, Amichetti M, et al. Patterns of failure and comparison of different target volume delineations in patients with glioblastoma treated with conformal radiotherapy plus concomitant and adjuvant temozolomide. *Radiotherapy and Oncology*. 2010;**97**(3):377-381. DOI: 10.1016/j.radonc.2010.08.020
- [24] Dobelbower MC, Burnett Iii OL, Nordal RA, et al. Patterns of failure for glioblastoma multiforme following concurrent radiation and temozolomide. *Journal of Medical Imaging and Radiation Oncology*. 2011;**55**(1):77-81. DOI: 10.1111/j.1754-9485.2010.02232.x
- [25] Klein M, Heimans JJ, Aaronson NK, et al. Effect of radiotherapy and other treatment-related factors on mid-term to long-term cognitive sequelae in low-grade gliomas: A comparative study. *Lancet*. 2002;**360**(9343):1361-1368. PMID:12423981
- [26] Kleinberg L, Wallner K, Malkin MG. Good performance status of

long-term disease-free survivors of intracranial gliomas. *International Journal of Radiation Oncology, Biology, Physics*. 1993;**26**(1):129-133. DOI: 10.1016/0360-3016(93)90183-V

[27] Marks JE, Baglan RJ, Prasad SC, Blank WF. Cerebral radionecrosis: Incidence and risk in relation to dose, time, fractionation and volume. *International Journal of Radiation Oncology, Biology, Physics*. 1981;**7**(2):243-252. PMC1014206

[28] Swennen MH, Bromberg JE, Witkamp TD, Terhaard CH, Postma TJ, Taphoorn MJ. Delayed radiation toxicity after focal or whole brain radiotherapy for low-grade glioma. *Journal of Neuro-Oncology*. 2004;**66**(3):333-339. DOI: 10.1120/jacmp.v8i2.2423

[29] Jalali R, Mallick I, Dutta D, et al. Factors influencing neurocognitive outcomes in young patients with benign and low-grade brain tumors treated with stereotactic conformal radiotherapy. *International Journal of Radiation Oncology, Biology, Physics*. 2010;**77**(4):974-979. DOI: 10.1016/j.ijrobp.2009.06.025

[30] Gondi V, Pugh SL, Tome WA, Caine C, Corn B, Kanner A, et al. Preservation of memory with conformal avoidance of the hippocampal neural stem-cell compartment during whole-brain radiotherapy for brain metastases (RTOG 0933): A phase II multi-institutional trial. *Journal of Clinical Oncology*. 2014;**32**:3810-3816

[31] Kirkpatrick JP, Laack NN, Shih HA, Gondi V. Management of GBM: A problem of local recurrence. *Adjuvant Radiation Therapy for High-Grade Gliomas. Journal of Neuro-Oncology*; 2017

[32] Coffey RJ, Lunsford LD, Taylor FH. Survival after stereotactic biopsy of malignant gliomas. *Neurosurgery*. 1988;**22**:465-473

[33] Walker MD, Strike TA, Sheline GE. An analysis of dose-effect relationship in the radiotherapy of malignant gliomas. *International Journal of Radiation Oncology, Biology, Physics*. 1979;**5**:1725-1731

[34] Nelson DF, Diener-West M, Horton J, Chang CH, Schoenfeld D, Nelson JS. Combined modality approach to treatment of malignant gliomas--re-evaluation of RTOG 7401/ECOG 1374 with long-term follow-up: A joint study of the radiation therapy oncology group and the eastern cooperative oncology group. *NCI Monographs*. 1988:279-284

[35] Lee SW, Fraass BA, Marsh LH, Herbort K, Gebarski SS, Martel MK, et al. Patterns of failure following high-dose 3-D conformal radiotherapy for high-grade astrocytomas: A quantitative dosimetric study. *International Journal of Radiation Oncology, Biology, Physics*. 1999;**43**:79-88

[36] Chan JL, Lee SW, Fraass BA, Normolle DP, Greenberg HS, Junck LR, et al. Survival and failure patterns of high-grade gliomas after three-dimensional conformal radiotherapy. *Journal of Clinical Oncology*. 2002;**20**:1635-1642

[37] Werner-Wasik M, Scott CB, Nelson DF, Gaspar LE, Murray KJ, Fischbach JA, et al. Final report of a phase I/II trial of hyperfractionated and accelerated hyperfractionated radiation therapy with carmustine for adults with supratentorial malignant gliomas: Radiation therapy oncology group study 83-02. *Cancer*. 1996;**77**:1535-1543

[38] Nieder C, Nestle U, Ketter R, Kolles H, Gentner SJ, Steudel WI, et al. Hyperfractionated and accelerated-hyperfractionated radiotherapy for glioblastoma multiforme. *Radiation Oncology Investigations*. 1999;**7**:36-41

- [39] Mehta MP, Masciopinto J, Rozental J, Levin A, Chappell R, Bastin K, et al. Stereotactic radiosurgery for glioblastoma multiforme: Report of a prospective study evaluating prognostic factors and analyzing long-term survival advantage. *International Journal of Radiation Oncology*. 1994;**30**:541-549
- [40] Sneed PK, Lamborn KR, Larson DA, Prados MD, Malec MK, McDermott MW, et al. Demonstration of brachytherapy boost dose-response relationships in glioblastoma multiforme. *International Journal of Radiation Oncology, Biology, Physics*. 1996;**35**:37-44
- [41] Shin KH, Muller PJ, Geggie PH. Superfractionation radiation therapy in the treatment of malignant astrocytoma. *Cancer*. 1983;**52**:2040-2043
- [42] Lorentini S, Amelio D, Giri MG, Fellin F, Meliado G, Rizzotti A, et al. IMRT or 3D-CRT in glioblastoma? A dosimetric criterion for patient selection. *Technology in Cancer Research & Treatment*. 2013;**12**:411-420
- [43] Khan L, Soliman H, Sahgal A, Perry J, Xu W, Tsao MN. External beam radiation dose escalation for high grade glioma. *Cochrane Database of Systematic Reviews*. 2016;**8**:011475
- [44] Roa W, Brasher PM, Bauman G, Anthes M, Bruera E, Chan A, et al. Abbreviated course of radiation therapy in older patients with glioblastoma multiforme: A prospective randomized clinical trial. *Journal of Clinical Oncology*. 2004;**22**:1583-1588
- [45] Arvold ND, Tanguturi SK, Aizer AA, Wen PY, Reardon DA, Lee EQ, et al. Hypofractionated versus standard radiation therapy with or without temozolomide for older glioblastoma patients. *International Journal of Radiation Oncology, Biology, Physics*. 2015;**92**:384-389
- [46] Minniti G, De Sanctis V, Muni R, Rasio D, Lanzetta G, Bozzao A, et al. Hypofractionated radiotherapy followed by adjuvant chemotherapy with temozolomide in elderly patients with glioblastoma. *Journal of Neuro-Oncology*. 2009;**91**:95-100
- [47] Malmstrom A, Gronberg BH, Marosi C, Stupp R, Frappaz D, Schultz H, et al. Temozolomide versus standard 6-week radiotherapy versus hypofractionated radiotherapy in patients older than 60 years with glioblastoma: The Nordic randomised, phase 3 trial. *The Lancet Oncology*. 2012;**13**:916-926
- [48] Roa W, Kepka L, Kumar N, Sinaika V, et al. International Atomic Energy Agency randomized phase III study of radiation therapy in elderly and/or frail patients with newly diagnosed glioblastoma multiforme. *Journal of Clinical Oncology*. 2015;**33**(35):4145-4150. DOI: 10.1200/JCO.2015.62.6606
- [49] Lassman AB, Matcyevesky D, Corn BW. High-grade gliomas. In: *Clinical Radiation Oncology*. 4th ed. USA: Elsevier; 2016
- [50] Ten Haken RK, Thornton AF, Sandler HM, LaVigne ML, Quint DJ, Fraass BA, et al. A quantitative assessment of the addition of MRI to CT-based, 3-D treatment planning of brain tumors. *Radiotherapy and Oncology*. 1992;**25**:121-133
- [51] Douglas JG, Stelzer KJ, Mankoff DA, Tralins KS, Krohn KA, Muzi M, et al. [F-18]-fluorodeoxyglucose positron emission tomography for targeting radiation dose escalation for patients with glioblastoma multiforme: Clinical outcomes and patterns of failure. *International Journal of Radiation Oncology*. 2006;**64**:886

- [52] Redmond KJ, Mehta M. Stereotactic radiosurgery for glioblastoma. *Cureus*. 2015;7(12):e413
- [53] Murovic JA, Chang SD. Outcomes after stereotactic radiosurgery and various adjuvant treatments for recurrent glioblastoma multiforme: A current literature review and comparison of multiple factors that impact outcome. *World Neurosurgery*. 2012;78:588-591
- [54] Weller M, van den Bent M, Tonn JC, Stupp R, Preusser M, CohenJonathan-Moyal E, et al. European Association for Neuro-Oncology(EANO) guideline on the diagnosis and treatment of adult astrocytic and oligodendroglial gliomas. *The Lancet Oncology*. 2017;18:315
- [55] National Comprehensive Cancer Network (NCCN). NCCN Clinical Practice Guidelines in Oncology
- [56] Combs SE, Thilmann C, Edler L, Debus J, Schulz-Ertner D. Efficacy of fractionated stereotactic reirradiation in recurrent gliomas: Long-term results in 172 patients treated in a single institution. *Journal of Clinical Oncology*. 2005;23:8863-8869
- [57] Douw L, Klein M, Fagel SS, Van den Heuvel J, Taphoorn MJ, Aaronson NK, et al. Cognitive and radiological effects of radiotherapy in patients with low-grade glioma: Long-term follow-up. *Lancet Neurology*. 2009;8(9):810-818
- [58] Strenger V, Lackner H, Mayer R, Sminia P, Sovinz P, Mokry M, et al. Incidence and clinical course of radionecrosis in children with brain tumors. A 20-year longitudinal observational study. *Strahlentherapie und Onkologie*. 2013;189:759-764
- [59] Leibel S, Sheline G. Tolerance of the brain and spinal cord to conventional therapeutic irradiation. In: Gutin P, Leibel S, Sheline G, editors. *Radiation Injury to the Nervous System*. Raven Press; 1991. p. 239
- [60] Ruben JD, Dally M, Bailey M, Smith R, Mc Lean CA, Fedele P. Cerebral radiation necrosis: Incidence, outcomes, and risk factors with emphasis on radiation parameters and chemotherapy. *International Journal of Radiation Oncology, Biology, Physics*. 2006;65:499-508