

We are IntechOpen, the world's leading publisher of Open Access books Built by scientists, for scientists

4,800

Open access books available

122,000

International authors and editors

135M

Downloads

Our authors are among the

154

Countries delivered to

TOP 1%

most cited scientists

12.2%

Contributors from top 500 universities



WEB OF SCIENCE™

Selection of our books indexed in the Book Citation Index
in Web of Science™ Core Collection (BKCI)

Interested in publishing with us?
Contact book.department@intechopen.com

Numbers displayed above are based on latest data collected.
For more information visit www.intechopen.com



Surgical Resection in HCC

Kevin Labadie, Kevin M. Sullivan and James O. Park

Additional information is available at the end of the chapter

<http://dx.doi.org/10.5772/intechopen.81345>

Abstract

Hepatocellular carcinoma (HCC) is a deadly disease. Its incidence is rising worldwide without significant improvement in survival in spite of improving therapies. A wide array of treatment options for HCC exist and include surgery, catheter-based therapies, radiation and systemic therapy. These modalities are often used in combination for optimal management in a multidisciplinary approach. Surgical resection remains one of the only curative therapeutic options for HCC, although it is indicated in select patients with localized disease. Herein, we cover the role of surgical resection in the management of HCC, reviewing the perioperative and operative considerations, in addition to highlighting the advances in minimally invasive surgery and novel navigation technologies.

Keywords: hepatocellular carcinoma, liver cancer, surgery, minimally invasive, multidisciplinary

1. Introduction

Hepatocellular carcinoma (HCC) is the second most lethal malignancy worldwide [1]. Despite the advent of effective antiviral drugs to eradicate hepatitis C infection, the prevalence of HCC is projected to increase secondary to increasing rates of fatty liver disease from diabetes and the obesity epidemic [2]. Unfortunately, there has been little to no change in the survivability of HCC over the last three decades [3] in spite of the increasing array of therapeutic options, leaving much room for improvement. The armamentarium for managing HCC is wide and includes surgical resection, orthotopic liver transplantation (OLT), ablative techniques using ethanol (percutaneous ethanol injection, PEI), microwave (MWA) or radiofrequency (RFA), catheter-directed transarterial chemoembolization (TACE) or radioembolization (TARE),

external beam radiation therapy in the form of stereotactic body radiation therapy (SBRT) or proton beam therapy (PBT), systemic targeted small molecule tyrosine kinase inhibitors, check-point inhibitor immunotherapy and investigational agents. These modalities are often used together in a multidisciplinary approach.

Surgical resection, or partial hepatectomy (PH), is a potentially curative surgical treatment option for up to 15–20% of patients with HCC. The primary objective of PH is to remove the HCC with an adequate margin, while preserving as much functional liver parenchyma to avoid post-resection hepatic failure. With improvements in preoperative assessment, patient selection, surgical and anesthetic techniques, intraoperative ultrasound, PH for HCC is now routine and safe. Operative mortality has been reduced to less than 5% with a 5-year overall survival of 60–75%.

2. Preoperative considerations

Several factors are considered in determining the eligibility for PH, including the patient's health status (e.g. age, ECOG PS), tumor-specific factors (e.g. extent and tumor biology), and the reserve of the liver remnant. Determined by the degree of liver dysfunction and the size of the postoperative liver remnant. While there is no strict age limit, one must consider the liver's regenerative capabilities in elderly patients, and the patient's ability to tolerate the physiologic consequences of portal pedicle clamping and acute hemorrhage on their cardiopulmonary system. In addition, patients undergoing a minimally invasive approach must also be able to endure the effects of the pneumoperitoneum and reverse Trendelenburg positioning on their physiology.

Several different clinical staging systems exist to stratify patients according to prognostic variables [4]. One of the most commonly used is the Barcelona Clinic Liver Cancer (BCLC) system which incorporates tumor size, number of nodules and hepatic function as classified by the Child-Pugh score [5]. The system classifies patients into early, intermediate, advanced and terminal stages and proposes recommended treatment strategy. According to this staging system, only stage 0 or early stage patients with small tumors are recommended for surgical resection or liver transplant.

However, many view the BCLC criterion for resection to be restrictive. For patients with large tumors (beyond any down-staging or expanded OLT criteria) who are ineligible for OLT, PH is the only potentially curative treatment. With improvements in perioperative management, preoperative morphological assessment and manipulation of the future liver remnant, PH for large HCC has been safely performed with good oncologic outcome [6, 7]. Therefore, large tumor size alone is not a contraindication to PH, rather factors such as multiple or bilobar tumors, extrahepatic metastasis, involvement of the main bile duct, portal venous or other macroscopic vascular invasion, and portal hypertension are all relative contraindications to PH. When clinically not evident, portal hypertension can be evaluated by measuring the transjugular intrahepatic portosystemic gradient (PSG). PSG values greater than 10 mmHg are indicative of significant portal hypertension and these patients must be approached with caution.

85–90% of patients with HCC have concomitant liver dysfunction. It is critical to account for the degree of liver dysfunction in addition to the patient's overall functional and nutritional status. Patients with liver disease are often malnourished with diminished performance status and comorbid conditions. To help stratify clinical liver dysfunction, patients are classified by the Child-Turcotte-Pugh (CTP) score and the Model for End-Stage Liver Disease (MELD) system. These two systems classify patients based on physical exam and laboratory data, with increasing scores associated with higher overall surgical risk. In general, patients with CTP score up to B7, MELD score <9 without significant portal hypertension can be considered for PH. Patients with more severe liver dysfunction and HCC can be considered for OLT if they meet specific criteria [8, 9].

Assessment of the hepatic function and future liver remnant (FLR) is important for patient selection prior to surgical resection [10]. The volume of the FLR and the regenerative capacity are key predictors of postoperative morbidity. Several laboratory tests have been used to evaluate hepatic reserve in cirrhotic patients including assessment of clearance of indocyanine green, sorbitol and ^{99m}Tc-galactosyl serum albumin scintigraphy [11]. Preoperative volumetric analysis can be performed with 3D computerized tomography volumetry [12]. To minimize the chance of post-hepatectomy liver failure, data suggest a liver remnant to be at minimum >20% of preoperative liver volume in a normal functioning liver, >30% for patients who have undergone >3 months systemic chemotherapy and >40% in those with advanced liver disease [13, 14].

Several techniques for preoperative optimization of the FLR exist including portal vein embolization (PVE) and the associated liver partition with portal vein ligation for staged hepatectomy (ALPPS) [15]. Initially developed in 1986, PVE results in atrophy of the embolized segments and compensatory hypertrophy of the perfused segments [16], within approximately 4–6 weeks, with at least >10% growth of the FLR predicting adequate regeneration post-PH. PVE has been shown to reduce the rate of postoperative complications in select patients with chronic liver disease [17], and can also be used safely in patients undergoing concurrent chemotherapy for colorectal metastases. One study demonstrated improved prognosis after PH in patients with impaired hepatic function [18].

ALPPS was developed in 2007 to induce liver hypertrophy in patients planned for extended liver resections with marginal FLR. A two-step operation, the initial data demonstrated it to be quite effective with rapid hypertrophy [15], however, it has not gained wide acceptance secondary to significant morbidity and mortality and the need for larger scale studies [19–21]. However, there are more recent reports of “mini-ALPPS” where the procedure is performed minimally invasively and with limited peripheral division of the parenchyma.

3. Surgical considerations

3.1. Surgical anatomy

The surgical anatomy of the liver is based on Claude Couinaud's classification system and further refined in the Brisbane 2000 Terminology of Liver Anatomy and Resections (**Figure 1**)

[22]. In this classification, the liver is divided into first, second and third order divisions based on internal anatomy rather than surface landmarks. First order division splits the liver into a right and left hemiliver along Cantlie's line, a plane extending from the middle of the gallbladder fossa to the center of the inferior vena cava. Second order divisions split the hemilivers into two respective sections or sectors, the medial and lateral sections/sectors on the left and anterior and posterior sections/sectors on the right. The third order division divides each section/sector into two segments, constituting the 9 individual hepatic segments defined by Couinaud. In general, each segment has a unique vascular inflow, outflow and biliary duct enabling segments to be removed without damage to other segments.

The proper hepatic artery and portal vein bifurcate prior to the hilum of the liver and form the right and left hepatic artery and portal vein which supply the right and left hemiliver. Joined by the biliary duct, the portal triad generally runs centrally within hepatic segments. The right hepatic artery enters the parenchyma soon after branching while the left has a longer extrahepatic course. In contrast, the three hepatic veins run between section/sectors in three portal scissurae. The right hepatic vein drains directly into the inferior vena cava (IVC) while the middle and left hepatic veins often form a common trunk prior to entering the IVC.

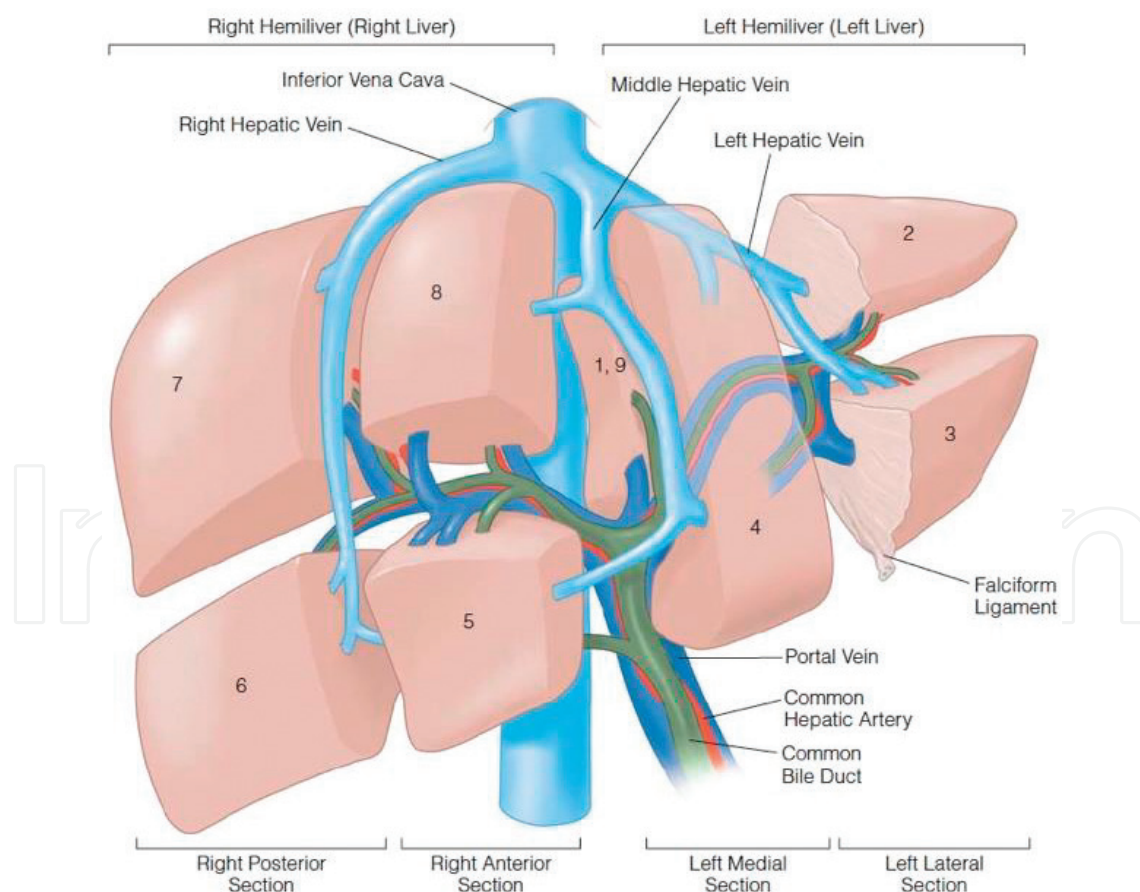


Figure 1. Schematic of liver anatomy separating the parenchyma into 9 anatomic segments. Each segment has unique blood supply and biliary drainage. Source: Cho, Fong. Hepatic Resection. In: Ashley SW, editor. Scientific American Surgery. Hamilton: Decker. 7th ed; 2014. pp. 1094–1114.

The liver is encapsulated by a fibrous capsule, known as Glisson's capsule. The capsule envelops the portal triads as they enter the liver parenchyma which makes it identifiable on intraoperative ultrasound. Furthermore, the dense capsule allows for control of the portal triad during dissection and enables pedicle ligation.

3.2. Anesthetic considerations

Some important perioperative anesthetic considerations should be accounted for to increase the safety of hepatectomy. To minimize the possibility of major intraoperative hemorrhage, the central venous pressure should be maintained at less than 5 mmHg to reduce the intrahepatic venous pressure. This is achieved using various anesthetic maneuvers and agents such as IVF restriction, and administration of isoflurane, fentanyl, mannitol, and cisatracurium. For open hepatectomy, the patient can be placed in slight reverse Trendelenburg position if pressures allow and switched to Trendelenburg position if there is significant hemorrhage with hemodynamic derangement to increase cardiac output and maintain end-organ perfusion. For laparoscopic/robotic hepatectomy, the patient is placed in reverse Trendelenburg position for a caudal approach which improves visualization of the vasculature, and the pneumoperitoneum creates a tamponade effect on the hepatic veins, which aids in limiting hemorrhage. Adequate vascular access should be obtained using large bore IVs, with appropriate invasive hemodynamic monitoring using A-line. Blood products should be readily available and resuscitation of operative blood loss should be with an appropriate combination of crystalloid, albumin and blood product as necessary. End-tidal CO₂ is measured to monitor for CO₂ embolism in the laparoscopic/robotic approach.

4. Operative technique

Resections are either "anatomic" or "non-anatomic". Anatomic resection defines a resection that obeys Brisbane divisions and is preferred for malignant disease because it has been found to lower rate of positive margins, decrease regional recurrences and improve surgical outcome. Non-anatomic resection refers to parenchymal transection that does not respect segmental planes and is typically used for debulking procedures, benign tumors or when trying to preserve remnant parenchyma. Achieving a microscopic margin negative (R0) resection is paramount to reducing local recurrence. 1 cm surgical margins have historically been considered standard, but narrower margins have been safely demonstrated [23].

There are six standard, anatomic hepatic resections as defined by the Brisbane classification (**Figure 2**). Right hemi-hepatectomy consists of surgical resection of segments V-VIII and left hepatectomy includes segments II-IV and occasionally segment I. In an extended right hepatectomy or a right trisectionectomy/trisectorectomy, segments IV-VIII, and in an extended left hepatectomy or a left trisectionectomy, segments II-IV, V and VIII are resected. A left lateral sectorectomy involves resection of segments II-III and a right posterior sectionectomy includes segments VI-VII. Segmentectomies denote resection of any individual segment.

The common principle of anatomic hepatectomies involves parenchymal transection after both vascular inflow and outflow have been controlled. Given that each hepatic segment has

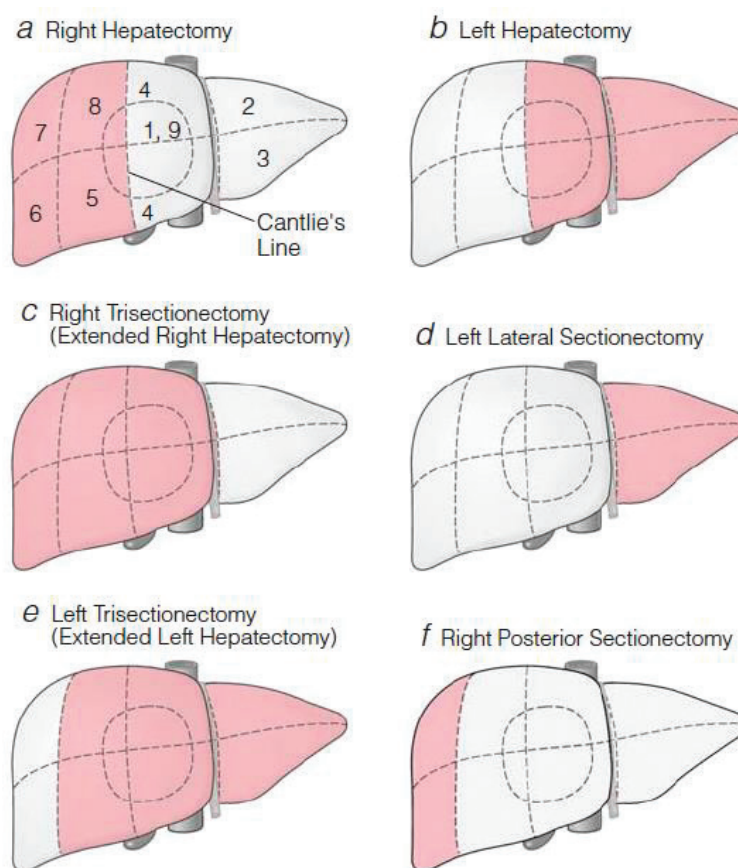


Figure 2. Schematic illustrations of the standard hepatic resections as labeled. Source: Cho, Fong. Hepatic Resection. In: Ashley SW, editor. Scientific American Surgery. Hamilton: Decker. 7th ed; 2014. pp. 1094–1114.

their unique vascular inflow and outflow, each segment can be safely excised without damage to surrounding hepatic segments. Intraoperative ultrasonography is used routinely for identification of the vascular structures, evaluation of tumor location, extent and relationship to the surrounding vasculature.

After initial laparoscopic inspection excludes unresectable disease (in selected cases), the incision is made. In an open conventional approach, appropriate incision and exposure is critical to safe hepatectomy. There are several incisions used including the bilateral subcostal (Chevron), right/left subcostal, J-type or the inverted Y (Mercedes) incision.

Once the liver is mobilized by dividing ligamentous attachments, careful inspection, palpation and ultrasound examination are performed to evaluate for any missed tumors. Arterial aberrancies are identified and portal triad inflow is controlled with sutures and clips or staple ligation. The corresponding hepatic vein is isolated and ligated. Parenchymal transection is performed along the line of devascularization. Different techniques for parenchymal transection exist, varying from clamp-crushing, waterjet, monopolar/bipolar cautery, radiofrequency ablative devices, bipolar vessel sealing devices, ultrasonic dissection devices to staplers. The clamp-crush technique is rapid and has been associated with lower rates of blood loss compared to other methods [24]. Once the resected segment is removed, hemostasis is obtained

with sutures, clips, argon beam coagulator and application of various hemostatic agents. Biliary leaks are controlled with clipping and suture ligation. Prior to abdominal closure, drains are placed if there is an infected operative field or if a biliary reconstruction is performed [25].

5. Minimally invasive hepatectomy

5.1. Laparoscopic-assisted partial hepatectomy

Although established as a safe and beneficial approach for numerous intra-abdominal operations, laparoscopic techniques were slow to be adopted for liver surgery for several reasons [26]. Concerns over technical feasibility of vascular dissection and control, organ mobilization, parenchymal dissection and management of intraoperative complications were prohibitive. Furthermore, it was unknown if port-site seeding, inadequate margins and poor oncologic outcomes would be more common in the minimally invasive approach.

The benefits of laparoscopic liver surgery are numerous. In addition to the generalized benefits of laparoscopic surgery including a more rapid functional recovery, smaller incisions which reduce the incidence of surgical site infections and postoperative pulmonary complications, there are additional advantages specific to laparoscopic liver surgery. Steep Trendelenburg positioning reduces intrahepatic venous pressure and the pneumoperitoneum exerts tamponade effect on vasculature leading to reduced intraoperative blood loss. Laparoscopy creates a caudal-cranial surgical view which affords improved visualization of major vascular structures compared to the ventral-dorsal angle of visualization of an open hepatectomy. For cirrhotic patients, small laparoscopic incisions avoid disruption of abdominal wall collaterals and the constraint on fluid shifts in a laparoscopic partial hepatectomy can decrease the incidence of liver-related complications. Minimally invasive hepatectomy also results in less adhesion formation which facilitates additional surgery in the future.

There have been numerous studies to date demonstrating the safety and efficacy of laparoscopic liver surgery. In 2009, a worldwide experience of 127 series including 2804 cases of laparoscopic partial hepatectomy demonstrated comparable 5-year overall survival and disease free survival compared to open hepatectomy [27]. Half of these cases were done for malignant disease with greater than 80% of resections boasting negative surgical margins. In 2015, a randomized control trial was published demonstrating safety and feasibility of laparoscopic liver resection with reduction in length of stay and intraoperative blood loss compared to open hepatectomy [28]. Numerous systematic analyses have substantiated these data, demonstrating that the laparoscopic partial hepatectomy is associated with decreased intraoperative blood loss, shorter length of hospital stay, and decreased number of positive resection margins. Overall, there were consistently fewer complications found in the laparoscopic group in these reviews [29]. A case-control propensity matched studies also found no difference in 1-, 3-, and 5-year overall survival and disease-free survival [30]. The National Surgical Quality Improvement Program database was evaluated to compare short-term outcomes among patients undergoing minimally invasive partial hepatectomy. Over 3000 patients were include in the study

and it demonstrated lower postoperative morbidity and shorter length of stay compared with patients undergoing open liver resection [31].

Specific to the treatment of HCC, the safety and efficacy of the laparoscopic approach has been evaluated in several meta-analyses and propensity score analyses. These studies demonstrated the equivalent or superior perioperative outcomes of laparoscopic compared to open resection [32, 33]. In a propensity score analysis, the overall and disease-free survival were similar and for the secondary outcomes, the laparoscopic group had shorter hospital stay, lower morbidity, with fewer transient liver failure and wound complications, and a larger tumor margin [34].

Multiple meta-analyses and case control series were reviewed and analyzed at the second international conference for laparoscopic liver resection in Morioka in 2014. Minor resections were validated as standard practice in the assessment stage, while major or complex resections were considered to be in the exploration stage, with incompletely defined risks. The Jury at Morioka made strong recommendations for higher quality studies including registries to define the role and benefits of laparoscopic major hepatectomy.

Patient selection is critical to ensuring safe laparoscopic partial hepatectomy. Although is technically feasible, resection of lesions in right posterior sections or the hepatic dome can be challenging and should be approached with caution. The patient is placed in the supine position and securely fastened to the table to allow for safe intraoperative repositioning. Generally, five ports are required for laparoscopic resection including two 12 mm and three 5 mm ports. Port placement is dependent upon laterality of the lesion as shown in **Figure 3**. Some surgeons advocate using a hand access port to assist with intraoperative manipulation, intra-corporeal suturing as well as serve as the specimen removal site.

5.2. Robotic-assisted partial hepatectomy

Further advances in surgical technology has created new opportunities in minimally invasive liver surgery. Robotic surgical systems offer unique advantages to the liver surgeon that enhances the minimally invasive approach. There are several key improvements on the robotic surgical system including a camera with optics providing a 3-dimensional stereotactic visual field. In addition, the instruments allow for seven degrees of freedom in their motion, providing easier suturing for hemorrhage control. There is no fulcrum effect on the body wall of the patient as in laparoscopic surgery, and it has been associated with reduction in surgeon fatigue compared to the laparoscopic approach.

Similar to laparoscopic partial hepatectomy, the patient is placed in the supine position and in steep reverse Trendelenburg position. The table is tilted with right side up approximately 25 degrees for right-sided resections. Five ports are placed including four robot-controlled ports and one assistant port (**Figure 4**). The ports are placed based on the laterality of the resection. In general, for a right-sided hepatectomy, the camera port is placed to the right-side of midline. Once the ports have been placed, the robot is docked from the cephalad position (**Figure 5**). Intraoperative ultrasound is critical to establishing vascular anatomy and defining oncologic planes of resection. After vascular control and establishing the line of transection, parenchymal transection is performed using one of many published techniques [35].

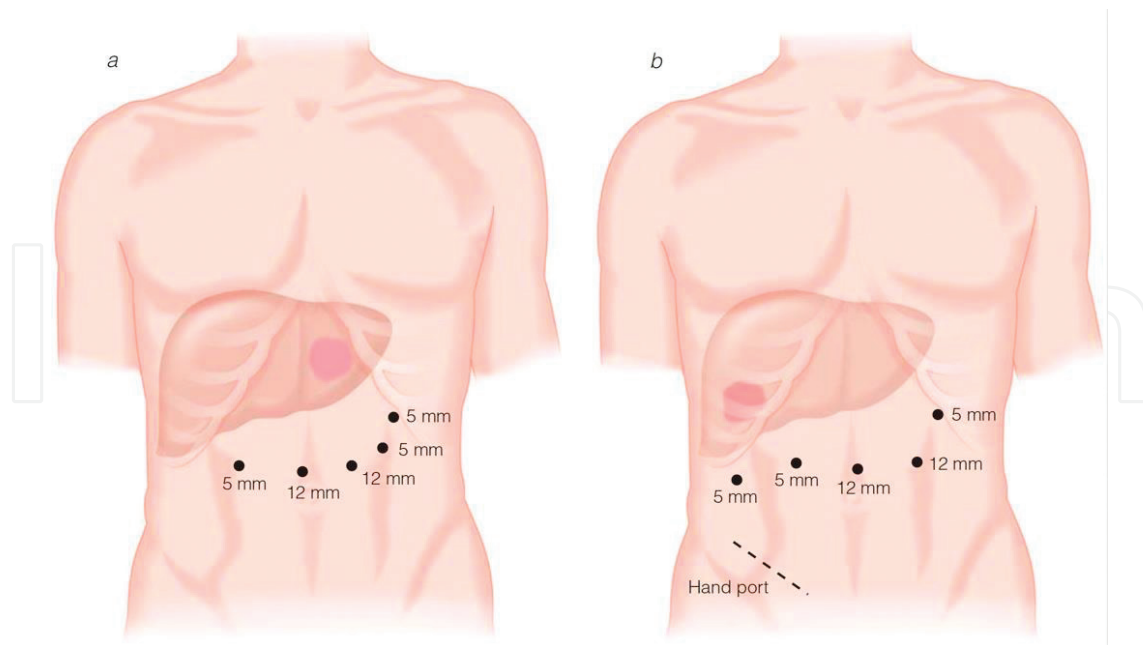


Figure 3. Suggested port placements for laparoscopic left lateral sectionectomy (a) and hand-assisted laparoscopic right hepatectomy (b). Source: Cho, Fong. Hepatic Resection. In: Ashley SW, editor. *Scientific American Surgery*. Hamilton: Decker. 7th ed; 2014. pp. 1094–1114.

Several large case series have been published demonstrating the success of robotic liver resection [36, 37]. The first large case series of 70 patients included 38.5% major liver resections without any mortalities [36]. An early systematic review of the literature demonstrated safety and feasibility of the robotic technique, with conversion to open rate of 4.6% and complication rate of 20.3% [38]. In 2018, an international, multicenter retrospective review of robotic liver surgery was published specifically evaluating long-term oncologic outcomes in patients with primary hepatobiliary malignancies after a median follow up of 75 months [39]. This study demonstrated comparable outcomes between robotic, open and laparoscopic liver surgery with 3-year overall survival of 90% for HCC. The majority of the cases were non-anatomic resections with an R0 resection achieved in 95% of HCC resections, 68% in cholangiocarcinoma and 82% in gallbladder cancer.

Minimally invasive approach to liver surgery, both laparoscopic and robotic-assisted, have their share of limitations. An important potential complication associated with the establishment of pneumoperitoneum and laparoscopic liver surgery is carbon dioxide gas embolism. Reports have demonstrated that this event rate is low, particularly if the pneumoperitoneal pressure is maintained below 12 mmHg [40]. Studies have published an event rate of as low as 0.5–1.5% [41]. There is a learning curve with gaining proficiency in the laparoscopic technique of liver resection with expert centers estimating the learning curve for laparoscopic liver resection at approximately 45–70 cases with senior partner proctoring [42]. Other limitations include the need for a skilled bedside assistant, and the diminished tactile sense when dealing with friable tissue such as steatotic liver parenchyma or thin venules within a cirrhotic liver can make the case challenging. And in the rare event when massive venous bleeding ensues, it can be difficult to control.

Cost is one major barrier to the wide adoption of the robotic approach. There is a significant initial capital investment in addition to maintenance fees and costs of staff training. However, one

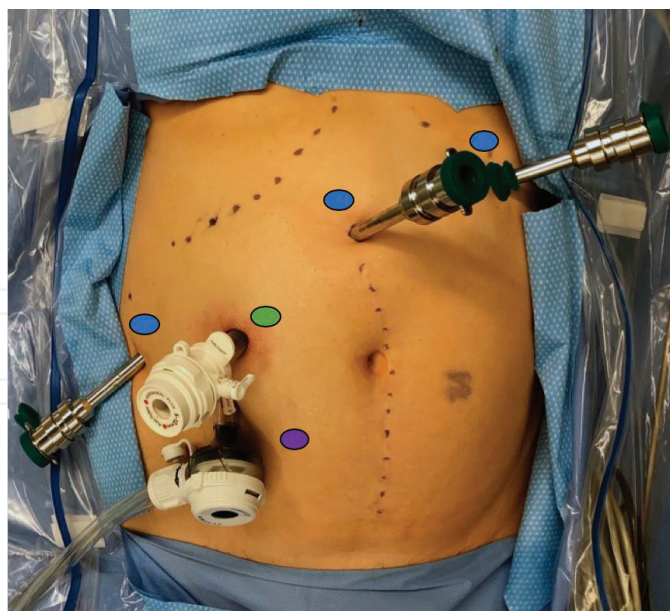


Figure 4. Image of port placement for a robot-assisted surgeries left lateral sectionectomy. Blue dots denote da Vinci 8-mm reusable cannulas (3). Green dot denotes 12-mm camera port. Purple dot denotes AirSeal® assistant port. Costal margin and midline marked in dotted pen.

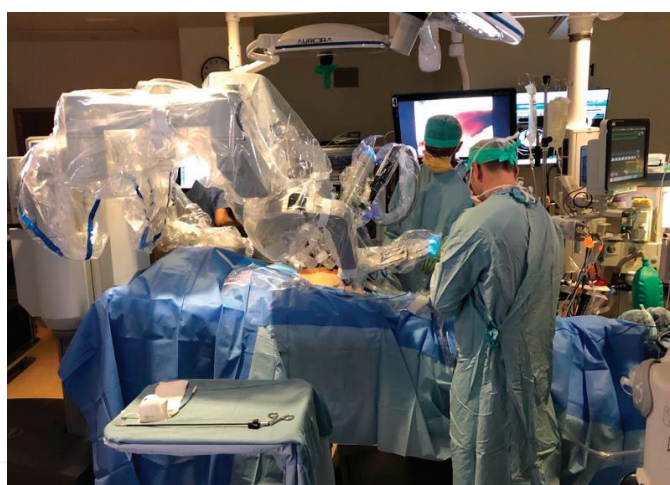


Figure 5. Standard operating room set up for robotic-assisted liver surgery. Head of bed is on left side of image, anesthesia equipment and personnel on right side of image.

study demonstrated that while perioperative costs are higher with the robot, the overall total direct hospital costs are lower at least in part due to the decrease length of stay with robotic minimally invasive resection [43]. There are several generations of the robot with older generation units best suited for an operation in a single work field, with cumbersome redocking steps to perform multi-quadrant operations. The majority of studies indicate a longer operating time secondary to robot set up and draping. Technically speaking, the robot does not provide haptic feedback challenging the surgeon to “feel with their eyes” and occasionally resulting in excessive tissue damage in inexperienced hands. Further studies are needed to examine the comparative effectiveness of robotic versus laparoscopic minimally invasive hepatectomy.

6. Postoperative complications

The main postoperative complications include postoperative hemorrhage, liver dysfunction, biliary leak and fluid collections. Postoperative hemorrhage is uncommon after liver resection if meticulous attention is given to confirmation of hemostasis at the conclusion of the case. Bleeding may occasionally occur from retroperitoneal structures, such as the adrenal gland, or diaphragmatic musculature. Argon beam coagulator and a variety of topical hemostatic applications are utilized to reduce liver surface related bleeding.

Post hepatectomy liver failure (PHLF) is a major postoperative complication with mortality of approximately 30%. The definition of post-hepatectomy liver is the impaired ability of the liver to maintain its synthetic, excretory and detoxifying functions, characterized by an increase in international normalized ratio and bilirubin on or after postoperative day 5 [44]. The most effective treatment of PHLF is liver transplantation but that is reserved for the most severe cases. Initial care is supportive and often includes mechanical ventilation, hemodynamic support and hemodialysis. Administration of colloid products and nutritional supplementation is also advocated.

The best way to treat post-hepatectomy liver failure is to prevent it. Preoperative weight loss, nutritional supplementation, careful preoperative selection and risk stratification are important to minimize the risk of PHLF [10]. Intra-operatively, minimizing blood loss and blood transfusion, close attention to hemostasis and minimizing skeletonization of the hepatoduodenal ligament will lower risk of PHLF. In the postoperative period, recognizing and aggressively treating postoperative hemorrhage, biliary obstructions or leaks and intra-abdominal infections will reduce the hepatic stress and likelihood of developing hepatic failure.

Postoperative fluid collections collect in the resected liver bed. These collections are varied in etiology but can include hematoma, seroma or biloma. They often do not result in symptoms, but occasionally they can cause pain or fullness requiring drainage. These collections also are at risk for infection and abscess formation. Biliary leakage from the raw surface of the resected liver can occur in up to 8% of patients after liver resection [45].

7. Emerging technologies

7.1. Near-infrared fluorescent imaging in hepatic surgery

New technologies continue to be developed to enhance minimally invasive liver surgery. One example is intra-operative near-infrared fluorescence (NIF) imaging. NIF imaging has become commonplace in many laparoscopic and robotic camera systems enabling the identification of various dyes, such as indocyanine green, injected preoperatively. Indocyanine green is a green dye that is preferentially metabolized by hepatocytes and excreted in the biliary tree. It lights up the biliary tree and has been utilized for robotic and laparoscopic assisted cholecystectomy. It has been more recently utilized to guide parenchymal dissection after vascular control by identifying perfused from poorly perfused hepatic parenchyma.

7.2. Intelligent imaging in robotic-assisted surgery

Future directions within the realm of robotic liver surgery include the application of preoperative planning with virtual reality (VR) models and real-time augmented reality (AR) intraoperative endoscopic overlays to aid with surgical navigation on *da Vinci*® surgical systems. The current practice standard for operative planning involves preoperative cross-sectional imaging using contrast-enhanced, multiphase liver protocol computed tomography (CT) or magnetic resonance imaging (MRI) scans to evaluate the tumor's extent (size and number) and location with respect to critical structures including the major vasculature and biliary architecture. Surgeons rely on years of training to develop the ability to mentally reconstruct 2D images into a mental 3D model in order to preoperatively plan for a surgery while referencing the 2D images intraoperatively.

Computer-based three-dimensional (3D) reconstructions of liver tumors have been shown to increase accuracy of tumor localization and precision of operative planning for liver surgery [46]. While useful for operative planning, intraoperative review of 2D images on a traditional PACS system requires diversion of attention away from the operative field. Intraoperative ultrasound is routinely used for real-time localization of liver tumors and

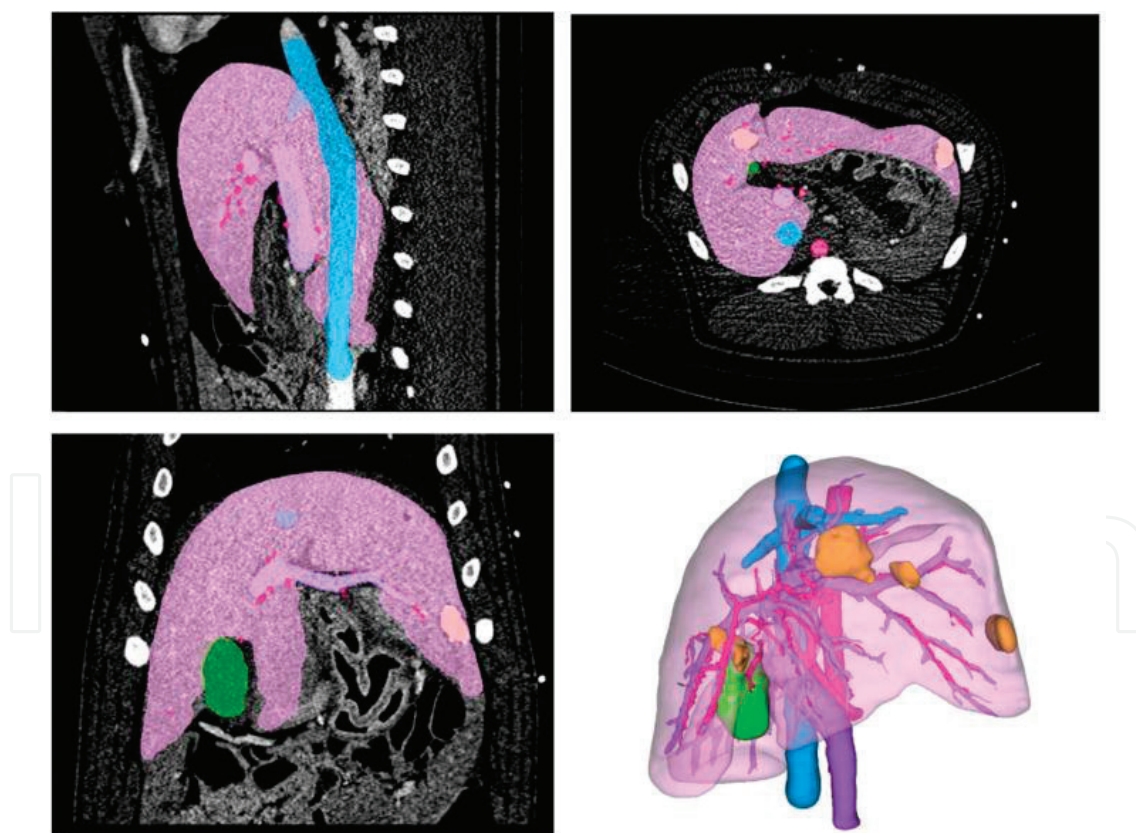


Figure 6. Virtual 3D model of the liver. Porcine experimental model with implanted radiopaque tumor within the liver parenchyma. Preoperatively, CT images were obtained of the porcine liver with 3D segmented reconstructions created from the DICOM images. The 3D reconstructions can be viewed for preoperative planning with intuitive Surgical's *da Vinci*® Surgical System.

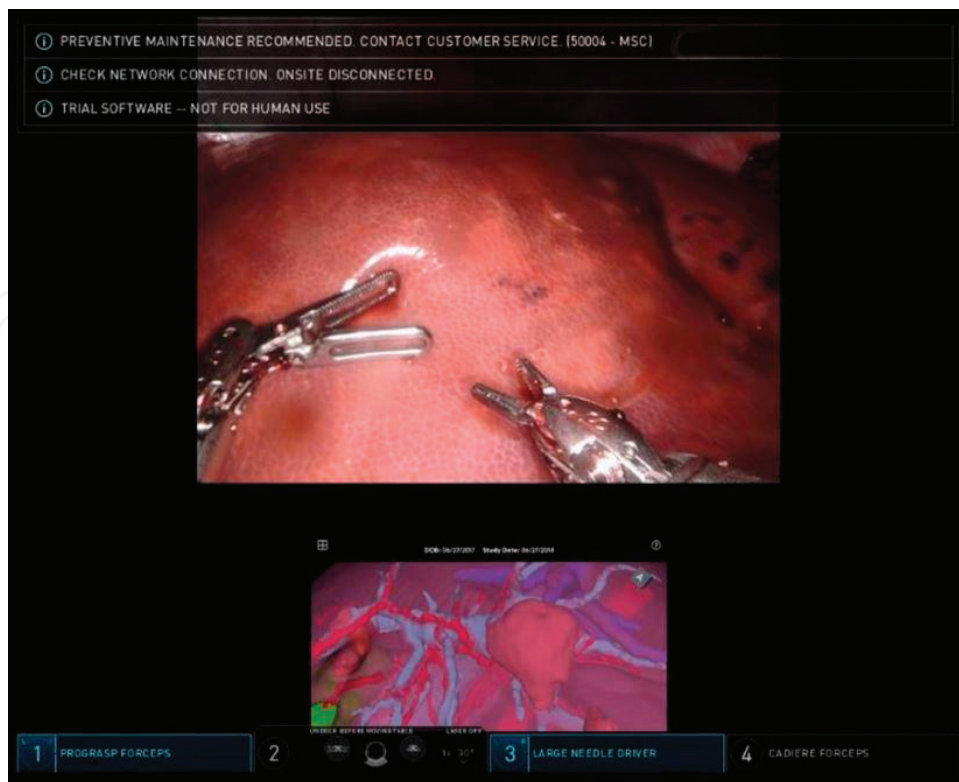


Figure 7. Real-time endoscopic overlay of 3D reconstruction over the surgical field on the *da Vinci*® Xi Surgical System. The relationship between the tumor (light pink) and adjacent vasculature including the hepatic veins (light blue), hepatic arteries (red) and portal veins (blue) is present on the overlay. After initial registration, the overlay is mapped onto the patient-specific anatomy changing in real-time with camera movement.

identification of vessels and biliary structures. However, its use is limited in minimally invasive liver surgery due to the need for an additional port site and the need to interpret the 2D ultrasound images and mentally reconstruct the 3D anatomy being projected based on the orientation of the ultrasound probe. Preoperative planning with a VR model (**Figure 6**) and the application of AR endoscopic overlay (**Figure 7**) of patient-specific anatomy into the robotic surgical system could potentially improve surgical efficiency in real-time with intelligent surgical navigation.

AR may be developed to overlay accurate 3D reconstruction data onto the operative field itself, thereby eliminating the need to divert the attention from the operative field and to translate the 2D images into a 3D construct. These advancements with planning and guidance can potentially reduce the cognitive load burden on the surgeon. Augmented reality for spatial recognition has been shown to improve localization accuracy in an experimental model of uterine myomectomy [47], and our recent experience has shown promise and feasibility in an experimental porcine liver model (**Figures 1 and 2**). Next steps in the application of VR and AR to hepatobiliary surgery include overcoming technical obstacles of continuous co-registration to a mobile liver with tissue deformation while continuing to define the utility of the technology with patient education, tumor board evaluations, preoperative planning and intraoperative navigation.

8. Conclusion

Hepatocellular carcinoma (HCC) is a deadly disease that represents major challenges for patients and healthcare providers alike. Numerous therapeutic options exist for the treatment of HCC that are often used in combination for local and regional control. Surgical resection remains an important intervention that can be curative. Minimally invasive surgical technologies continue to improve increasing its safety and applicability for oncologic liver surgery.

Acknowledgements

We would like to acknowledge Drs. Kyle Miller and Jonathan Sorger of Intuitive Surgical Inc. for their collaboration on the emerging robotic surgical technologies.

Conflict of interest

The authors have no conflict of interest to report.

Author details

Kevin Labadie, Kevin M. Sullivan and James O. Park*

*Address all correspondence to: jopark@uw.edu

University of Washington, Seattle, WA, USA

References

- [1] Ferlay J, Soerjomataram I, Dikshit R, et al. Cancer incidence and mortality worldwide: Sources, methods and major patterns in GLOBOCAN 2012. *International Journal of Cancer*. 2015;**136**(5):E359-E386. DOI: 10.1002/ijc.29210
- [2] Starley BQ, Calcagno CJ, Harrison SA. Nonalcoholic fatty liver disease and hepatocellular carcinoma: A weighty connection. *Hepatology*. 2010;**51**(5):1820-1832. DOI: 10.1002/hep.23594
- [3] Altekruse SF, McGlynn KA, Reichman ME. Hepatocellular carcinoma incidence, mortality, and survival trends in the United States from 1975 to 2005. *Journal of Clinical Oncology*. 2009;**27**(9):1485-1491. DOI: 10.1200/JCO.2008.20.7753
- [4] Pons F, Varela M, Llovet JM. Staging systems in hepatocellular carcinoma. *HPB: The Official Journal of the International Hepato Pancreato Biliary Association*. 2005;**7**(1):35-41. DOI: 10.1080/13651820410024058

- [5] Llovet J, Brú C, Bruix J. Prognosis of hepatocellular carcinoma: The BCLC staging classification. *Seminars in Liver Disease*. 1999;**19**(03):329-338. DOI: 10.1055/s-2007-1007122
- [6] Ng KK, Vauthey J-N, Pawlik TM, et al. Is hepatic resection for large or multinodular hepatocellular carcinoma justified? Results from a multi-institutional database. *Annals of Surgical Oncology*. 2005;**12**(5):364-373. DOI: 10.1245/ASO.2005.06.004
- [7] Régimbeau JM, Farges O, Shen BY, Sauvanet A, Belghiti J. Is surgery for large hepatocellular carcinoma justified? *Journal of Hepatology*. 1999;**31**(6):1062-1068
- [8] Mazzaferro V, Regalia E, Doci R, et al. Liver transplantation for the treatment of small hepatocellular carcinomas in patients with cirrhosis. *The New England Journal of Medicine*. 1996;**334**(11):693-700. DOI: 10.1056/NEJM199603143341104
- [9] Iwatsuki S, Starzl TE, Sheahan DG, Yokoyama I, Demetris AJ, Todo S, et al. Hepatic resection versus transplantation for hepatocellular carcinoma. *Annals of Surgery*. 1991;**214**(Table 1):221-228
- [10] Kauffmann R, Fong Y. Post-hepatectomy liver failure. *Hepatobiliary Surgery and Nutrition*. 2014;**3**(5):238-246. DOI: 10.3978/j.issn.2304-3881.2014.09.01
- [11] Ge P-L, Du S-D, Mao Y-L. Advances in preoperative assessment of liver function. *Hepatobiliary & Pancreatic Diseases International*. 2014;**13**(4):361-370
- [12] Okamoto E, Kyo A, Yamanaka N, Tanaka N, Kuwata K. Prediction of the safe limits of hepatectomy by combined volumetric and functional measurements in patients with impaired hepatic function. *Surgery*. 1984;**95**(5):586-592
- [13] Kishi Y, Abdalla EK, Chun YS, et al. Three hundred and one consecutive extended right Hepatectomies. *Transactions of the Meeting of the American Surgical Association*. 2009;**127**(4):171-179. DOI: 10.1097/SLA.0b013e3181b674df
- [14] Shindoh J, Tzeng C-WD, Aloia TA, et al. Optimal future liver remnant in patients treated with extensive preoperative chemotherapy for colorectal liver metastases. *Annals of Surgical Oncology*. 2013;**20**(8):2493-2500. DOI: 10.1245/s10434-012-2864-7
- [15] Schnitzbauer AA, Lang SA, Goessmann H, et al. Right portal vein ligation combined with In situ splitting induces rapid left lateral liver lobe hypertrophy enabling 2-staged extended right hepatic resection in small-for-size settings. *Annals of Surgery*. 2012;**255**(3):405-414. DOI: 10.1097/SLA.0b013e31824856f5
- [16] Kinoshita H, Sakai K, Hirohashi K, Igawa S, Yamasaki O, Kubo S. Preoperative portal vein embolization for hepatocellular carcinoma. *World Journal of Surgery*. 1986;**10**(5):803-808
- [17] Farges O, Belghiti J, Kianmanesh R, et al. Portal vein embolization before right hepatectomy. *Annals of Surgery*. 2003;**237**(2):208-217. DOI: 10.1097/01.SLA.0000048447.16651.7B
- [18] Tanaka H, Hirohashi K, Kubo S, Shuto T, Higaki I, Kinoshita H. Preoperative portal vein embolization improves prognosis after right hepatectomy for hepatocellular carcinoma in patients with impaired hepatic function. *The British Journal of Surgery*. 2000;**87**(7):879-882. DOI: 10.1046/j.1365-2168.2000.01438.x

- [19] Torres OJM, Fernandes ESM, Herman P. ALPPS: Past, present and future. *Arquivos Brasileiros de Cirurgia Digestiva*. 2015;**28**(3):155-156. DOI: 10.1590/S0102-67202015000300001
- [20] Torres OJM, Fernandes E de SM, Oliveira CVC, et al. Associating liver partition and portal vein ligation for staged hepatectomy (ALPPS): The Brazilian experience. *Arquivos Brasileiros de Cirurgia Digestiva*; **26**(1):40-43
- [21] Zhang G-Q, Zhang Z-W, Lau W-Y, Chen X-P. Associating liver partition and portal vein ligation for staged hepatectomy (ALPPS): A new strategy to increase resectability in liver surgery. *International Journal of Surgery*. 2014;**12**(5):437-441. DOI: 10.1016/j.ijssu.2014.03.009
- [22] Strasberg S, Belghiti J, Clavien P, et al. The Brisbane 2000 terminology of liver anatomy and resections. *HPB: The Official Journal of the International Hepato Pancreato Biliary Association*. 2000;**2**:333-339. DOI: 10.1016/S1365-182X(17)30755-4
- [23] Shi M, Guo R-P, Lin X-J, et al. Partial hepatectomy with wide versus narrow resection margin for solitary hepatocellular carcinoma. *Annals of Surgery*. 2007;**245**(1):36-43. DOI: 10.1097/01.sla.0000231758.07868.71
- [24] Pamecha V, Gurusamy KS, Sharma D, Davidson BR. Techniques for liver parenchymal transection: A meta-analysis of randomized controlled trials. *HPB: The Official Journal of the International Hepato Pancreato Biliary Association*. 2009;**11**(4):275-281. DOI: 10.1111/j.1477-2574.2009.00057.x
- [25] Cho, Park, Fong. Hepatic resection. In: Ashley SW, editor. *Scientific American Surgery*. 7th ed. Decker, Hamilton; 2014. pp. 1094-1114
- [26] Coelho FF, Kruger JAP, Fonseca GM, et al. Laparoscopic liver resection: Experience based guidelines. *World Journal of Gastrointestinal Surgery*. 2016;**8**(1):5-26. DOI: 10.4240/wjgs.v8.i1.5
- [27] Nguyen KT, Gamblin TC, Geller DA. World review of laparoscopic liver resection—2,804 patients. *Annals of Surgery*. 2009;**250**(5):831-841. DOI: 10.1097/SLA.0b013e3181b0c4df
- [28] Ding G, Cai W, Qin M. Pure laparoscopic versus open liver resection in treatment of Hepatolithiasis within the left lobes. *Surgical Laparoscopy, Endoscopy & Percutaneous Techniques*. 2015;**25**(5):392-394. DOI: 10.1097/SLE.0000000000000120
- [29] Viganò L, Tayar C, Laurent A, Cherqui D. Laparoscopic liver resection: A systematic review. *Journal of Hepato-Biliary-Pancreatic Surgery*. 2009;**16**(4):410-421. DOI: 10.1007/s00534-009-0120-8
- [30] Han H-S, Shehta A, Ahn S, Yoon Y-S, Cho JY, Choi Y. Laparoscopic versus open liver resection for hepatocellular carcinoma: Case-matched study with propensity score matching. *Journal of Hepatology*. 2015;**63**(3):643-650. DOI: 10.1016/j.jhep.2015.04.005
- [31] Bagante F, Spolverato G, Strasberg SM, et al. Minimally invasive vs. open hepatectomy: A comparative analysis of the National Surgical Quality Improvement Program Database. *Journal of Gastrointestinal Surgery*. 2016;**20**(9):1608-1617. DOI: 10.1007/s11605-016-3202-3

- [32] Jiang B, Yan X-F, Zhang J-H. Meta-analysis of laparoscopic versus open liver resection for hepatocellular carcinoma. *Hepatology Research*. 2018;**48**(8):635-663. DOI: 10.1111/hepr.13061
- [33] Chen K, Pan Y, Zhang B, Liu X-L, Maher H, Zheng X-Y. Laparoscopic versus open surgery for hepatocellular carcinoma: A meta-analysis of high-quality case-matched studies. *Canadian Journal of Gastroenterology and Hepatology*. 2018;**2018**:1746895. DOI: 10.1155/2018/1746895
- [34] Sposito C, Battiston C, Facciorusso A, et al. Propensity score analysis of outcomes following laparoscopic or open liver resection for hepatocellular carcinoma. *The British Journal of Surgery*. 2016;**103**(7):871-880. DOI: 10.1002/bjs.10137
- [35] Nota CL, Rinkes IHB, Hagendoorn J. Setting up a robotic hepatectomy program: A Western-European experience and perspective. *Hepatobiliary Surgery and Nutrition*. 2017;**6**(4):239-245. DOI: 10.21037/hbsn.2016.12.05
- [36] Giulianotti PC, Coratti A, Sbrana F, et al. Robotic liver surgery: Results for 70 resections. *Surgery*. 2011;**149**(1):29-39. DOI: 10.1016/j.surg.2010.04.002
- [37] Goh B, Lee S, Chan C, et al. Early experience with robot-assisted laparoscopic hepatobiliary and pancreatic surgery in Singapore: Single-institution experience with 20 consecutive patients. *Singapore Medical Journal*. 2018;**59**(3):133-138. DOI: 10.11622/smedj.2017092
- [38] Ho C-M, Wakabayashi G, Nitta H, Ito N, Hasegawa Y, Takahara T. Systematic review of robotic liver resection. *Surgical Endoscopy*. 2013;**27**(3):732-739. DOI: 10.1007/s00464-012-2547-2
- [39] Khan S, Beard RE, Kingham PT, et al. Long-term oncologic outcomes following robotic liver resections for primary Hepatobiliary malignancies: A multicenter study. *Annals of Surgical Oncology*. July 2018. DOI: 10.1245/s10434-018-6629-9
- [40] Otsuka Y, Katagiri T, Ishii J, et al. Gas embolism in laparoscopic hepatectomy: What is the optimal pneumoperitoneal pressure for laparoscopic major hepatectomy? *Journal of Hepato-Biliary-Pancreatic Sciences*. 2013;**20**(2):137-140. DOI: 10.1007/s00534-012-0556-0
- [41] Qiu J, Chen S, Chengyou D. A systematic review of robotic-assisted liver resection and meta-analysis of robotic versus laparoscopic hepatectomy for hepatic neoplasms. *Surgical Endoscopy*. 2016;**30**(3):862-875. DOI: 10.1007/s00464-015-4306-7
- [42] Komatsu S, Scatton O, Goumard C, et al. Development Process and Technical Aspects of Laparoscopic Hepatectomy: Learning Curve Based on 15 Years of Experience. *Journal of the American College of Surgeons*. 2017;**224**(5):841-850
- [43] Sham JG, Richards MK, Seo YD, Pillarisetty VG, Yeung RS, Park JO. Efficacy and cost of robotic hepatectomy: Is the robot cost-prohibitive? *Journal of Robotic Surgery*. 2016;**10**(4):307-313. DOI: 10.1007/s11701-016-0598-4
- [44] Rahbari NN, Garden OJ, Padbury R, et al. Posthepatectomy liver failure: A definition and grading by the International Study Group of Liver Surgery (ISGLS). *Surgery*. 2011;**149**(5):713-724. DOI: 10.1016/j.surg.2010.10.001

- [45] Zimmitti G, Roses RE, Andreou A, et al. Greater complexity of liver surgery is not associated with an increased incidence of liver-related complications except for bile leak: An experience with 2,628 consecutive resections. *Journal of Gastrointestinal Surgery*. 2013;**17**(1):57-65. DOI: 10.1007/s11605-012-2000-9
- [46] Lamadé W, Glombitza G, Fischer L, et al. The impact of 3-dimensional reconstructions on operation planning in liver surgery. *Archives of Surgery*. 2000;**135**(11):1256-1261
- [47] Bourdel N, Collins T, Pizarro D, et al. Augmented reality in gynecologic surgery: Evaluation of potential benefits for myomectomy in an experimental uterine model. *Surgical Endoscopy*. 2017;**31**(1):456-461. DOI: 10.1007/s00464-016-4932-8