

# We are IntechOpen, the world's leading publisher of Open Access books Built by scientists, for scientists

**4,800**

Open access books available

**122,000**

International authors and editors

**135M**

Downloads

Our authors are among the

**154**

Countries delivered to

**TOP 1%**

most cited scientists

**12.2%**

Contributors from top 500 universities



**WEB OF SCIENCE™**

Selection of our books indexed in the Book Citation Index  
in Web of Science™ Core Collection (BKCI)

Interested in publishing with us?  
Contact [book.department@intechopen.com](mailto:book.department@intechopen.com)

Numbers displayed above are based on latest data collected.

For more information visit [www.intechopen.com](http://www.intechopen.com)



# Cystic Artery Variations and Associated Vascular Complications in Laparoscopic Cholecystectomy

*Pankaj Prasoon, Tomohiro Katada, Kohei Miura, Yuki Hirose, Jun Sakata and Toshifumi Wakai*

## Abstract

Substantial knowledge of the arterial supply and its anatomical variations of the gall bladder and liver are important in all the hepatobiliary surgical procedures. The arterial supply of gallbladder called cystic artery (CA) is a vital structure required to get ligated or clipped in the path of laparoscopic cholecystectomy. The possible concerns like intra-operative bleeding or adjoining accidental injuries will almost always be focused on the research consisting of dissection and clipping with cystic artery. Pseudoaneurysm of the cystic artery has additionally been belonging to the presence of acute cholecystitis or pancreatitis. An original supply of CA is usually assessed depending on the existence of hepatic artery variants. Laparoscopic cholecystectomy is really a recent and arduous noninvasive procedure and might even result in substantial unintended effects possibly iatrogenic or in the form of post-procedural complications. The perfect knowledge of anatomy in addition to feasible variation of cystic artery is mandatory. An efficient operative strategy and consciousness are probably the key components with all the results and marginal likelihood of complications, which often can be ultimately attainable. Within this chapter, we have attempted to explore some variations of cystic artery, complications and management.

**Keywords:** cystic artery (CA), laparoscopic cholecystectomy (LC), proper hepatic artery (PHA), right hepatic artery (RHA), inferior mesenteric artery (IMA)

## 1. Introduction

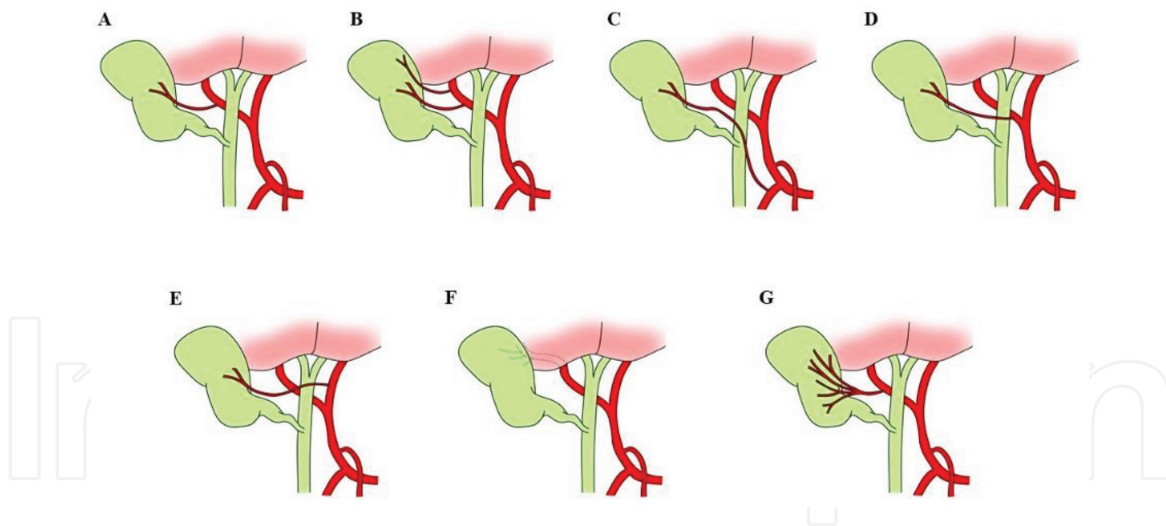
Laparoscopic cholecystectomy (LC) is commonly used nowadays to treat numerous conditions and diseases of the gallbladder and biliary tree. It is mandatory to specialists to get acquainted with all the technique, but additionally with anatomical variants of vascular supply in the extrahepatic biliary structures [1]. The cystic artery is often a solitary blood vessel that arises from the right branch from the proper hepatic artery (PHA). It constantly goes to the hepatobiliary triangle, which is encircled superiorly with the inferior surface of the liver, inferiorly with the cystic duct and, the common hepatic duct corresponds to medially [2]. According to Calot's triangle illustration, the superior border is made with the cystic artery [2]. While getting closer to the gallbladder, the cystic artery divides into two branches superficially and deeply running on the anterior and posterior

components of the gallbladder, correspondingly. Variants at the originations and course of CA are extremely typical. Uncontrolled arterial bleeding during LC is often a significant issue and might increase the likelihood of biliary duct injury. Consequently, appropriate recognition of the anatomy of the CA is essential. Cystic artery is excessively acknowledged to possess a highly diverse branching pattern. Therefore, given that LC had become the defacto standard to treat cholelithiasis, comprehension of anatomical vascular variations in hepatobiliary surgery has attained significance [3].

## 2. Types of cystic artery and its variation

### 2.1 Single cystic artery

The cystic artery commences within the Calot's triangle and most often starting from the right hepatic artery. When getting close to the gallbladder, it bifurcates into deep and superficial branches to the gallbladder neck. The exterior branch proceeds eventually left facet of the gallbladder. The deep branch goes throughout the connective tissues between gallbladder and liver parenchyma. The deep branch engenders really small offshoots to furnish the gallbladder, which anastomoses with all the superficial branches [4]. During open cholecystectomy, such type of CA is laterally located through the cystic duct within Calot's triangle. However in LC procedure, it is merely at the back and a bit much deeper contrary to cystic duct [4]. In a study, such type of variations were documented (73.3%) in 440 of 600 patients [4]. The intricate anatomical deviation among cystic arteries might increase the likelihood of injury throughout LC procedure [5]. Yet in another research, CT images had been analyzed prior to LC, were compared with intra-operative findings and postoperative results. It was witnessed that, cystic artery originating from the right hepatic artery were (76%) in most of the cases, while 55 (60%), CA originating from the right hepatic artery and it undergoes the Calot's triangle and reached the neck of the gallbladder in total of the 91 cases [5]. A single artery to cystic duct together with the conventional configuration of "H shaped" was revealed in 161 (91.47%) patients [6]. Within a current overview of 9800 patients, It is documented that the typical origination of cystic artery were from the RHA (79.02%), where as in 5427 patients (81.5%), origination was found in the hepatobiliary triangle [7]. Variations within cystic artery possessing clinical significance, located anterior to the common hepatic duct in 485 of 2704 patients (17.9%); whereas in 228 (5.4%), out of 4202 patients, located anterior to CBD, correspondingly [7]. A single CA was witnessed in 340 cases out of 740 patients. [8]. Single CA is present in 85% of sufferers out of 300 cases of LC [9]. On standard cholecystectomy, single CA sometimes appears within the hepatobiliary triangle and much more laterally positioned with the cystic duct, although while in laparoscopic view, it could be observed behind and marginally deeper compared to cystic duct [10]. In a recent study by Yang et al., the original source and variety of cystic arteries as well as their relationship together with the Calot's triangle was assessed by CT images and further it was compared with laparoscopic cholecystectomy results. They witnessed single CA was in 53 (73%) of the 73 patients [5]. In one study, normal origin of CA originating from the right hepatic artery was noticed in 72% of patients [11]. In accordance to the reported results, the conventional position of the cystic artery can be found in 70–80% of scenarios [4, 10–12] (**Figure 1A**). Within the study with Kenyan's populations, it had been stated that the CA stood a typical origin from the right hepatic artery in 92.2% of cases, although only one CA supplied the gallbladder within a comparable ratio [13]. With the laparoscopic point of view, a single or a



**Figure 1.**

*Schematic illustrations of various anatomic anomalies of cystic artery during LC. (A) Cystic artery origination from right hepatic artery; (B) double cystic artery origination from right hepatic artery; (C) cystic artery origination from gastroduodenal artery; (D) cystic artery origination from aberrant right hepatic artery; (E) cystic artery origination from left hepatic artery; (F) cystic artery origination from liver parenchyma; (G) cystic artery syndrome.*

bit larger CA in length necessitates gentle exploration, as it can really be an aberrant hepatic artery, which needs to be dissociated from the cystic duct or gallbladder by cautious dissection [10].

## 2.2 Double cystic artery

The double cystic artery shows scenarios in which the superficial and deep branches of the CA have independent origins [14] (**Figure 1B**). Double cystic artery could be divided up based upon the position with regards to the bile ducts and portal vein and the hepatobiliary triangle [1, 4, 10]. Concerning the origins of double cystic arteries, they sometimes seem to be with the right hepatic artery or its partitions [1, 15]. According to Loukas et al., double cystic arteries originating both from Right hepatic artery and the posterior superior pancreaticoduodenal artery coexists having an accessory left hepatic artery originating from the left gastric artery [16].

Ding et al.; defined a terminology called “compound cystic artery,” in which the cystic arteries endured not just in the hepatobiliary triangle, but additionally outside of it [4]. Congenital absence of the deep branch of CA indicates the presence of an additional CA, and that is often recognized by subsequent hemostasis following LC. The posterior CA is extremely fragile in some instances, and it is frequently cut by electrocoagulation while in dissection. According to one study, such types of likelihood of vessel occurrence in 73 patients (12.2%); i.e. (double cystic artery) right after LC [4]. Suzuki et al. revealed incidence of double cystic artery in 27 cases (11.1%) out from 244 Japanese patients who undergone LC [1]. Zubair et al. noted the most typical variant with double CA in the Pakistani patients during the LC procedure. He witnessed the CA passing over the Calot’s triangle, which had been observed in 26 (11.8%) scenarios out of 220 [17]. While in another research double cystic artery was present in only 3 of 300 cases (1%) [9]. In Western communities of Slovenians and Croatians, double cystic artery was documented in 13.6 and 5.5% of cases, correspondingly [10, 15]. In the recent research conducted by Yang et al., all patients experienced LC following the CT examinations [5]. The relationship between CA as well as the Calot’s triangle was compared by the interventional radiologist and surgeon. Double cystic arteries were witnessed in 20 (27%) patients [5].

### **2.3 Cystic artery origination from gastroduodenal artery (GDA)**

On few occasions, the CA emanate from the gastroduodenal artery or its branches, it is termed as “a low-lying cystic artery.” Its terminal segment getting close to the gallbladder is essential for laparoscopic visual image [10]. On standing point of laparoscopic view, it is actually identified much more superficially or anteriorly to the cystic duct. Therefore, to be the first structure stumbled upon on cholecystectomy. In this instance, there is a probability of its intersection on dissecting the peritoneal replication hooking up the hepatoduodenal ligament to Hartman’s pouch with the gall bladder or even the cystic duct. This anatomic deviation was discovered in 9 (4.5%) individuals [10]. The incidence with this anatomic discrepancy varies from 1 to 30% [2, 10, 18]. (**Figure 1C**). In a latest review, based on clinically important anatomical variations of the cystic artery, it was witnessed that the aberrant gastroduodenal origination of cystic artery was (1.94%) out of 6898 cases [7]. Ding et al., founded such anatomic variation in 45 patients (7.5%) out from 600 sufferers addressed with LC [4]. As a whole of these terminal branches of artery, the way it approaches the gallbladder is essential for laparoscopic surgeons [4]. Given that, it should not merely be altered at an initial course. However, it is also vulnerable to injuries and hemorrhage throughout the dissection, especially while dealing with peritoneal folds at the joining point of hepatoduodenal ligament to Hartman’s pouch on the gallbladder or the cystic duct [4].

### **2.4 Aberrant right hepatic artery (RHA)**

The right hepatic artery (RHA) typically yields several tiny divisions providing gallbladder in contrast to a solitary cystic artery (**Figure 1D**). When masked by the gallbladder in the gallbladder fossa, it is prone to get the injury by cautery directly or by thermal injuries [10]. With the laparoscopic standpoint, a single large cystic artery necessitates gentle exploration, as it might be an aberrant hepatic artery, which needs to be dissociated with the cystic duct or gallbladder which additionally needs meticulous exploration [10]. The biliary anatomy of the Calot’s triangle and extrahepatic vascular supply is widely known to become unpredictable and extremely diverse [19]. This allows a persistent obstacle to the surgeon carrying out LC. Cautious dissection of the cystic duct and artery is needed having consistent thoughts within the several anatomical chances to stay clear of either conversion necessitating postoperative bleeding or biliary leak. A replaced RHA is observed in 15–25% of patients, that the great majority disclose the RHA branching from the superior mesenteric artery [20, 21]. Inadvertent RHA ligation in cholecystectomy has become linked to liver ischemia, occasionally warranting resection of affected lobes of liver [22]. An aberrant RHA adherent to the cystic duct and gallbladder neck is referred to one of the most uncommon defects [19, 23]. Anatomical variants are frequent; in 6–16%, the right hepatic artery flows intently parallel to the cystic duct and could be mistakenly ligated during the LC, the structures within the triangle of Calot’s are usually not evidently recognized [24]. Andall et al.; noted aberrant RHA origination of (5.58%), 385 out from 6898 cases. An aberrant RHA originating from the celiac trunk is an extremely unusual anatomical variant. Nevertheless, it might be connected with an irregular path of the cystic artery. Specialists have to know anatomical variations of the extrahepatic biliary tree and arterial supply in order to avoid feasible injuries throughout LC [25]. According to recent publicized research, focusing on the patients with combined bile duct and hepatic artery injuries during LC revealed, formation of liver abscesses in three of four cases and stricture’s anastomotic site by 50% of four sufferers; on the other hand, these complications just weren’t recognized in cases with separated biliary duct injuries [26].

The earlier LC studies demonstrated an anomaly of right hepatic artery and were being disrupted during excessive hemorrhage throughout Calot's triangle dissection [27]. The outline with the surgery described the explanation for blood loss and also the intra-operative management with unspecified amounts of clips [27]. Ding et al., witnessed aberrant RHA in 18 (3%) of cases in their study [4]. The complicated structure of hepatic artery tends to make the hilar and perihilar area much more hazardous and vulnerable to a variety of traumas. The potential for biliary injuries might be of interest in patients who endure complicated or extended dissection with the Calot's triangle, accompanied by the roll-out of discomfort, fever and altered liver function assessments [28].

## **2.5 Aberrant left hepatic artery**

The cystic artery in some instances emanates from the left hepatic artery, heading for the tunnel or through the liver and attaining the center of the gallbladder body or within the gall bladder fossa where it bifurcates it into two branches, which are namely called ascending and descending branches [10] (**Figure 1E**). This CA variance is simply not observed on endoscopic visualization with the hepatobiliary triangle, consequently necessitating extreme caution when treatment of gall bladder with the fossa [10]. Within one study, this sort of CA variation with typical caliber was discovered in 2 (1%) patients [10]. In accordance with the literature, it possesses an occurrence of 4%, where it was acknowledged and clipped [29]. The findings of CA origin were being with the left hepatic artery (2.07%), 143 out from 6898 cases. An aberrant RHA originating from the celiac trunk is an extremely uncommon anatomical variant. Nevertheless, it could be connected with an irregular path of the CA. Specialists should always keep in mind about the extrahepatic biliary tree and arterial supply anatomical variations to counteract attainable injuries while performing LC [25].

## **2.6 Cystic artery origination from liver parenchyma**

As outlined by Ding et al. [4]; This CA pierces the hepatic parenchyma getting close to the gallbladder base (**Figure 1F**). It usually situates inside the right lateral to the edge of gallbladder body and bottom part. Even so, a few are found in the middle of the gallbladder bed or located left lateral of gallbladder base. Hardly any other arterial blood vessels are located inside Calot's triangle [4]. This anatomic variation with the cystic artery is just not witnessed right until hemorrhaging and is because of dissection of the gallbladder fundus. It is sometimes complicated to understand more about and needs cautious dissection. It was witnessed in 15 patients (2.5%) within one another study [4].

## **2.7 Cystic artery syndrome**

Suzuki et al.; referred to a condition known as "cystic artery syndrome", in which the CA originates from the right hepatic artery, but uncommonly has a course that wraps across the cystic duct [1] (**Figure 1G**). They suggested that this course could result in reduced blood flow in the cystic duct, which exhibits clinically within the patient as cholelithiasis [1]. According to Zubair et al., this syndrome was discovered within 2% of the patients who underwent LC procedure [17].

## **2.8 Abnormal origination of cystic artery**

Andall et al. lately have summarized the experiences of 55 experts, they analyzed 9800 cases and discovered only 20 instances where the CA arise straight

from the superior mesenteric artery (SMA) [7]. An uncommon scenario has been documented possessing CA arising from the SMA with abnormal branching in the CT and MRI within a Japanese woman cadaver [30]. The CA typically come across the ventral facet with the portal vein as well as the posterior side of the common bile duct. Additionally, in their case the CA have origination with the SMA and RHA and they leaped concurrent to Calot's triangle [30]. Consequently, in such instances, it is sometimes complicated for medical professionals to evaluate the origination of CA on account of the SMA [30]. The absence of congenital cystic artery was documented in 33 of 9836 (0.34%) cases [7]. While in another study, scholars mentioned the advantages of computed tomography angiography (CTA), and estimated that, it is quicker, much less intrusive and is through with considerably fewer irradiation exposure. CTA offers an appropriate and efficient depiction of cystic artery vessels in 924% of cases (95% CI, 87–98%) [7]. Nonetheless, variations, for instance, small or short CA, origins from aberrant hepatic artery or from an additional vessel completely results in the CA not passing throughout the cystohepatic triangle [7].

### **3. Complications associated with cystic artery injuries**

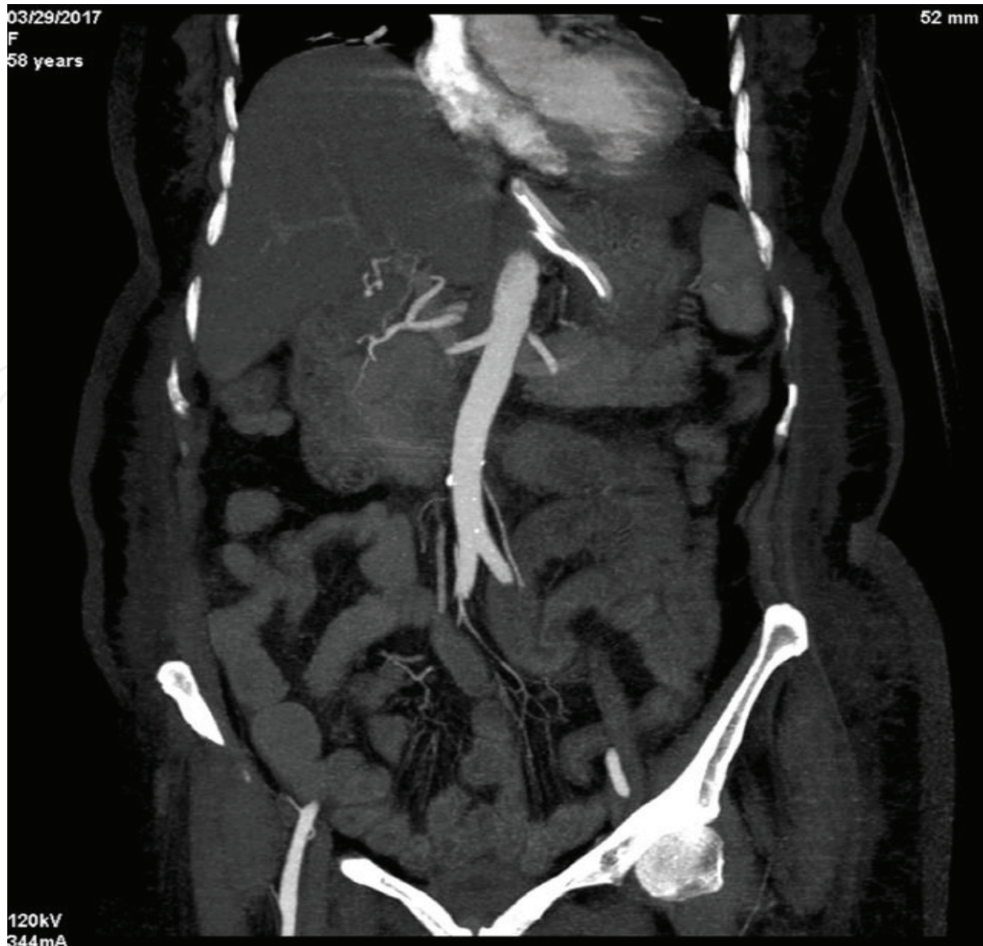
#### **3.1 Twisted cystic artery**

The signs and symptoms of torsion imitate acute cholecystitis, but various clinical attributes (slim person, older people, and spine problems) and image conclusions are helpful for differentiating it from standard acute cholecystitis [31]. Even so, preoperative recognition continues to be challenging to identify the anomalies of vessels. Considering torsion of CA, it was initially reported in 1898. There are almost 500 cases have been acknowledged inside the literary works, and many of them were diagnosed throughout the surgical procedure [32]. The ultrasonography, computed tomography (CT), and magnetic resonance imaging (MRI) have already been stated to be helpful for proper diagnosis of gallbladder torsion such as twisting of the pedicle of the cystic duct and gallbladder mesentery designated as “whirl sign” [33]. Variety of twisted CA by 3D CT, angiography signifies unique and primary verification with this concern that enables definitive medical diagnosis and obviates the entire overall performance of other assessments [32]. Whenever a patient is assumed of owning torsion with the gallbladder, 3D-CT angiography ought to be carried out for making an earlier significant and exact diagnosis [32].

#### **3.2 Cystic artery pseudoaneurysm (CAP)**

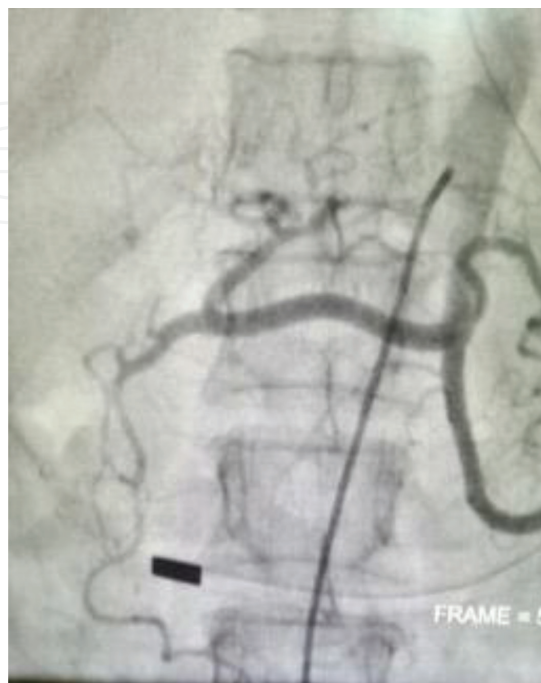Pseudoaneurysm of the cystic artery is actually an uncommon side-effect right after laparoscopic cholecystectomy (**Figure 2**). CA involvement is documented significantly less in the literature. Pseudoaneurysm formation is resulted in by vascular injuries. The important causes consist of arterial access procedures, accident trauma, and surgical trauma [34]. Cystic artery pseudoaneurysm which develops carrying out a cholecystectomy and leading to upper gastrointestinal bleeding are usually an unusual entity, with merely four instances referred to inside the literature [35]. Generally, in most patients (80%), the PSA typically presents roughly a month following LC surgery; on the other hand, delayed PSA presentation after 5 years following the surgical procedure had been documented in the literature [36, 37].

Emergency abdominal angiogram unveiled a CA stump pseudoaneurysm, without any proof of active contrast extravasation and it was managed by coiling



**Figure 2.**  
*Pseudoaneurysm in the hepatic artery after radical cholecystectomy.*

or embolization's technique, consequently the patient did not have any additional hemorrhagic episodes. In cases like this, an angiogram and embolization in contrast to surgical treatment are the most preferred method of management equally when



**Figure 3.**  
*After the post-embolization of the pseudo aneurysm.*



it comes to treatment and diagnosis (**Figure 3**). The existence of a dilated cystic artery stump on angiogram adhering to cholecystectomy is definitely the threatening indicator even without the active extravasation of contrast [35]. The signs and symptoms might appear during the early postoperative period or as late as 4 months following surgical procedure. One of the several attainable causes includes the unnecessary use of electrocautery throughout the dissection at the infundibulum of the gallbladder, leading to thermal damage to the vascular wall, and break down in the inner wall of the cystic artery. A result of exposure to the tip of the metal clip utilized to occlude the cystic duct [38]. The management of their patient incorporated several plans such as attaining hemostasis, managing the cystic duct stump leak, alleviating obstructive jaundice, managing the infections with antibiotics, and depleting the intra-abdominal collection [34].

### **3.3 Hemobilia due to cystic artery pseudoaneurysm**

The mixed injuries of bile ducts and vessels create the pathologic vascular-biliary interconnection and also the hemorrhage with the bile duct, which can be described as hemobilia [39]. Therefore, hemobilia has turned into a specific issue in the laparoscopic age. The likelihood of hemobilia right after an emergency LC for acute cholecystitis (within just 72 h) had been stated to be 0.001%, although it is been witnessed being 0.0003% for all those going through an elective LC [40]. Bile acids are potent solubilizers of lipid membrane for their cytotoxic and amphipathic qualities, leading to cell death in patients with bile leaks; it has been postulated to result in immediate deterioration and break down in the vascular walls, ultimately causing a PSA [41, 42]. Hemobilia has been considered to be the most prevalent presentation (90%), although abdominal pain (70%) and jaundices (60%) are also typical presentations [40, 43]. CAP is usually an unusual entity and therefore, there is absolutely no comprehensive agreement to the medical treatments for this problem. The potential risk of a PSA rupture relates to its dimensions, having a greater than 10 times risk in the event the aneurysm is much larger than 5 cm [44]. A hold off in presentation after thermal injuries could possibly be as a result of charring of the vessel which may get separate several days or weeks later, especially in the existence of bile [40]. The pathophysiology of aneurysmal dilatation of the cystic artery in the existence of calculus cholecystitis just isn't apparent. However, it is considered that the artery is eroded possibly by immediate tension of gallstones or swelling from the arterial wall [45]. This subsequently contributes to harm the adventitia with the localized weak point within the vessel wall and development of the pseudoaneurysm [45].

Hemobilia induced by non-iatrogenic injuries of the CA is really an intense uncommon but attainable etiology, and thus it has to be deemed. Pseudoaneurysm in the CA is an extremely unusual reason behind hemobilia, and its particular pathogenesis remains to be ambiguous [46]. Cholecystitis could produce arterial wall weakness and necrosis leading hemobilia [46]. Many experts have revealed that bleeding pseudoaneurysm of the cystic artery as a result of re-activation of the continual cholecystitis treated by endovascular embolization and subsequent cholecystectomy [47]. Whenever a sufferer presents with significant gastrointestinal internal bleeding, an ascending total bilirubin level and recent hepatobiliary treatment or intervention, a higher index of suspicions is definitely required [48]. Loizides et al.; evaluated altogether, 25 reported cases since 1983–2015 and found that pseudoaneurysm of CA is to be secondary to acute and chronic cholecystitis [45]. During its natural course, a PSA will steadily develop in its dimensions prior to rupture, seen in 21–80% of cases [49]. The rupture of a PSA in the peritoneal cavity may be possibly usual to hypovolemic shock or might be comprised quickly with

the encompassing tissue also known as “double rupture phenomenon,” since the preliminary comprised hemorrhage might be accompanied by additional blood loss, which can be more severe situation [36].

Unattended hemobilia presents an instantaneous risk to life. It can result in acute hemodynamic imbalances, requiring diagnosis, accessibility, and control over the pseudoaneurysm. Arterial-phase CT is an excellent initial noninvasive mode of detection of LC complication's [34]. This technology not only help to gauge intra-abdominal collection, biliary tree dilatation, and doable bile duct injury, but also to visualize pseudoaneurysms or hemorrhage [34]. Several different treatment methods have already been documented within the literature together with selective embolization and coiling, open cholecystectomy with ligation of the aneurysm, or perhaps a two-step approach involving radiological treatments for the pseudoaneurysm accompanied by an elective cholecystectomy [45]. Angiography is a significant restorative technique simply because it make possible for embolization of the cystic pseudoaneurysm, transforming an urgent scenario to a semi elective one [50]. It has a substantial proportion of good results attaining hemostasis in 75–100% of sufferers with hemobilia [50], with a reported of less than 2% [51].

Some patients having typical obstructive jaundice and hemophilia may additionally need endoscopic retrograde cholangiopancreatography, CBD exploration or transhepatic biliary drainage to vacate the clot in the event the jaundice doesn't get relieved [49, 52]. Natural or spontaneous rupture of normal cystic artery is undoubtedly an extremely exceptional reason behind hemoperitoneum [53]. Medical co-morbidity, for instance, arteriosclerosis, diabetes, arterial hypertension and long-term usage of corticosteroid are the most prevalent components liable for vascular fragility [53]. Selective embolization is an efficient and also a noninvasive treatment alternative, which can result in ischemic gallbladder necrosis few days following the treatment [53]. The patients having good hemodynamically status, cholecystectomy can be carried out averting biliary ischemic problems and also the related morbidity and mortality [53].

### **3.4 Hematemesis due to cystic artery pseudoaneurysm (CAP)**

Dependent upon the latency from surgery to presentation, the rate of bleeding differs from the minimum to enormous, with the increased amount of blood loss are much more likely in later presentations [39]. Some possible components of injury considered to play a role in CAP incorporate the unnecessary use of electrocautery when taking apart the infundibulum from the gallbladder, which might trigger thermal damage to the vascular wall and erosion of the tip of the metal clip utilized to ligate the cystic duct into the internal walls of the cystic artery [38]. In cases with repeated hematemesis and a medical history of earlier biliary interventions, upper endoscopy is undoubtedly a suitable first diagnostic step. Direct visualization of blood emanating from the ampulla of vater, diagnostic of hemobilia, is hardly ever experienced [54]. If recurring endoscopic and cholangiographic assessments are not able to uncover a possible bleeding point, angiography may be recommended as the next phase in assessment [54]. Surgical ligation via an open or laparoscopic approach is recognized as second-line treatments for pseudoaneurysm of hepatic artery and CAP, restricted to controls exactly where an angiographic approach isn't feasible or does not work out [54]. In another study, they assessed the importance of choledochoscopy within the evaluation of hemobilia, considering that several EGDs and ERCPs skipped diagnosing, contrary to choledochoscopic visual image of the clip, eroding into the cystic duct remnant by having an adjoining soft-tissue protuberance was the initial indication of potential vascular injury, resulting in the right examination and remedial assistance [55]. Gallbladder ischemia is an issue for

patients having an intact gallbladder that endure embolization of the cystic artery. Therefore, in such circumstances gall bladder removal is normally carried out right after embolization procedure [56].

CAPs are unusual but possibly despondent complications of LC procedures. Right upper quadrant pain, hemorrhaging, and jaundice after biliary intervention are an indication of hemobilia, a typical manifestation of pseudoaneurysm, even though introductory signs and symptoms can differ considerably. In the cases where the PSA continues to grow following preliminary management with TAE, following operative management had been documented through which an exploratory laparotomy and ligation of the nourishing vessel ended in an entire recuperation [57]. Infection might also result in a high-risk of vascular suture rupture right after ligation of the artery; within this report, the patient passed away 2 days following surgical repair of a PSA as a result of severe bleeding from GI tract [58]. Gastrointestinal internal bleeding may perhaps present as hematemesis or melena, depending on the rate of blood loss [59]. Erosion on the PSA in GI tract or into the cystic duct stump or forming a fistula between these two structures was earlier documented [58, 60–62]. An increased index chart of diagnostic doubts is really important for earlier acknowledgement and treating this additional unwanted effect. In combination with endoscopy, cholangiography, angiography, and choledochoscopy might be helpful diagnostic resources in order to evaluate of suspected hemobilia [55]. Lately, numerous scientific studies have documented the effective treatments for PSAs by injecting thrombin straight into the hepatic artery aneurysm [37, 63].

On the other hand, embolization employing this approach could possibly be not discerning. It could result in unwanted additional complications, for instance, infarctions of liver and bowel; adding small quantities of thrombin with real-time sonography and Doppler assistance may perhaps lessen this threat [37]. Alternatively, angiographic embolization might be related to considerable hazards, such as shatter in the PSA throughout coil's embolization, an expansion in the thrombosis within the RHA, necrosis, hemorrhage, abscess creation and CBD stricture resulting from poor vascular supply [64–66]. A current review discovered that post-embolization syndrome took place in 9 out from 14 sufferers, and it was linked to the ages of the patient as well as time period relating to the LC procedure and TAE therapy [67]. Some others have recommended usage of a protected stent when dealing with the PSA to be able to sustain blood circulation towards liver preventing additional complications relevant to diminished circulation [68]. Stents could also be used for individuals with accompanying hepatic artery stenosis and PSAs [68]. From a technical perspective, the positioning of the stent for the PSA in the RHA is recognized as complicated owing its far away position, more compact dimension and quite often intricate or transformed [68]. In one report, a patient presented with acute pancreatitis due to corrosion of TAE coils in the CBD subsequently 24 months after the LC [69].

Nevertheless, as a result of substantial advancements in catheter-based treatment plans now are generally given TAE by occluding the providing vascular supply with various embolic agents, which includes gel foam, coils, N-butyl cyanoacrylate and thrombin, ahead of preferably embolizing the vessel proximal and distal towards the PSA to avoid equity filling up in the PSA [37, 60, 65, 66, 70, 71]. In 82% of scenarios, embolization was documented typically effective while, surgical procedures needed in remainder 18% of the subjects [36]. When coils are utilized, they are able to the originator of thrombosis; consequently, in sufferers with considerable coagulopathies, the blood vessel might still continue to be distinct regardless of embolization plus the course of action could possibly be inadequate to managing

blood loss [72]. In modest PSAs, glue works extremely well as an alternative because the adhesive contours towards the type of PSA [73]. Additionally, coil's positioning could be tricky in individuals having a modest PSA [71]. In some instances, equally techniques could be implemented [71].

Failing to excise the PSA may bring about its burst since the aneurysm is usually inflamed and infected. An infection may also result in a high-risk of vascular suture split adhering to ligation of the artery; within a review, a person passed away 2 days following surgical repair of a PSA due to catastrophic gastrointestinal hemorrhage [58]. In the event wherein the PSA continues to be expanded following preliminary management with TAE, following operative management had been documented by which an exploratory laparotomy and ligation of the nourishing vessel ended in an entire recuperation [57]. Excision helps to ensure that a PSA won't expand resulting from continual arterial blood pressure; furthermore, failing to excise the PSA may bring about its burst because the aneurysm is frequently contaminated [72]. A number of people who typical to hemobilia and obstructive jaundice may additionally need endoscopic retrograde cholangiopancreatography and transhepatic biliary drainage while in some circumstances CBD exploration to vacate the blood clot in the event the jaundice won't get better [49, 52]. Operative control over to substantial hemobilia is apparently effective for 90% of patients, with rebleeding and fatality rates of lower than 5 and 10%, correspondingly [66].

#### **4. Summary**

Most often, vascular injuries and biliary duct injuries may occur concomitantly during the LC procedure. They arise more frequently than contemplated formerly, and it is witnessed much more proximal in LC contrast to those observed in open surgical procedure. Ultimately, it enhances the fatality rate. However, it could potentially cause greater morbidity and endanger the long-term functional outcomes of biliary reconstruction by triggering anastomotic strictures. When recognized earlier, there is certainly some space for restoration and reconstruction, even though this is contentious. Where as in delayed instances, it appears to be acceptable not to consider the vascular injuries by itself.

A hepatic or cystic artery PSA following the LC procedure is definitely infrequent. However, when it ensues occurs as life-threatening complications. The delayed presentation of the situation, which could take place weeks following the surgical procedure, and the typical symptoms with gastrointestinal internal bleeding can potentially lead to incorrect diagnosis or late treatment. Consequently, a higher index of clinical suspicions is needed for patients with inexplicable GI hemorrhage after having the LC procedure. A contrast CT scan or angiogram typically verifies the diagnosing, and trans arterial embolization is most likely the defacto standard of management, having a higher rate of success. On the other hand, operative treatment is essential for cases where TAE is unachievable or does not work out. Safety measures ought to be taken to prevent vascular injury while conducting the LC in order to prevent a PSA, especially when the cholecystectomy procedure is essentially problematic. An increased likelihood of symptomatic suspicion is needed for earlier recognition and management of this unwanted effect. In combination with endoscopy, cholangiography, angiography, and choledochoscopy could be efficient diagnostic tools while in the evaluation of assumed hemobilia. Specialist's consultation is mandatory while having any diagnostic and operative dilemma during the LC procedure in order to deter the unwanted complications and to attain the optimal consequences.

IntechOpen

IntechOpen

### **Author details**


Pankaj Prasoon, Tomohiro Katada, Kohei Miura, Yuki Hirose, Jun Sakata and Toshifumi Wakai\*

Division of Digestive and General Surgery, Niigata University Graduate School of Medical and Dental Sciences, Niigata, Japan

\*Address all correspondence to: [wakait@med.niigata-u.ac.jp](mailto:wakait@med.niigata-u.ac.jp)

### **IntechOpen**

---

© 2018 The Author(s). Licensee IntechOpen. This chapter is distributed under the terms of the Creative Commons Attribution License (<http://creativecommons.org/licenses/by/3.0>), which permits unrestricted use, distribution, and reproduction in any medium, provided the original work is properly cited. 

## References

- [1] Suzuki M, Akaishi S, Rikiyama T, Naitoh T, Rahman MM, Matsuno S. Laparoscopic cholecystectomy, Calot's triangle, and variations in cystic arterial supply. *Surgical Endoscopy*. 2000;**14**(2):141-144
- [2] Chen TH, Shyu JF, Chen CH, Ma KH, Wu CW, Lui WY, et al. Variations of the cystic artery in Chinese adults. *Surgical Laparoscopy, Endoscopy & Percutaneous Techniques*. 2000;**10**(3):154-157
- [3] Polgaj M, Podgorski M, Hogendorf P, Topol M. Variations of the hepatobiliary vasculature including coexistence of accessory right hepatic artery with unusually arising double cystic arteries: Case report and literature review. *Anatomical Science International*. 2014;**89**(3):195-198
- [4] Ding YM, Wang B, Wang WX, Wang P, Yan JS. New classification of the anatomic variations of cystic artery during laparoscopic cholecystectomy. *World Journal of Gastroenterology*. 2007;**13**(42):5629-5634
- [5] Xia J, Zhang Z, He Y, Qu J, Yang J. Assessment and classification of cystic arteries with 64-detector row computed tomography before laparoscopic cholecystectomy. *Surgical and Radiologic Anatomy*. 2015;**37**(9):1027-1034
- [6] Rashid A, Mushtaque M, Bali RS, Nazir S, Khuroo S, Ishaq S. Artery to cystic duct: A consistent branch of cystic artery seen in laparoscopic cholecystectomy. *Anatomy Research International*. 2015;**2015**:847812
- [7] Andall RG, Matusz P, du Plessis M, Ward R, Tubbs RS, Loukas M. The clinical anatomy of cystic artery variations: A review of over 9800 cases. *Surgical and Radiologic Anatomy*. 2016;**38**(5):529-539
- [8] Singh K, Singh R, Kaur M. Clinical reappraisal of vasculobiliary anatomy relevant to laparoscopic cholecystectomy. *Journal of Minimal Access Surgery*. 2017;**13**(4):273-279
- [9] Talpur KA, Laghari AA, Yousfani SA, Malik AM, Memon AI, Khan SA. Anatomical variations and congenital anomalies of extra hepatic biliary system encountered during laparoscopic cholecystectomy. *The Journal of the Pakistan Medical Association*. 2010;**60**(2):89-93
- [10] Balija M, Huis M, Nikolic V, Stulhofer M. Laparoscopic visualization of the cystic artery anatomy. *World Journal of Surgery*. 1999;**23**(7):703-707. discussion 7
- [11] Hugh TB, Kelly MD, Li B. Laparoscopic anatomy of the cystic artery. *American Journal of Surgery*. 1992;**163**(6):593-595
- [12] Daseler EH, Anson BJ, et al. The cystic artery and constituents of the hepatic pedicle; a study of 500 specimens. *Surgery, Gynecology & Obstetrics*. 1947;**85**(1):47-63
- [13] Saidi H, Karanja TM, Ogengo JA. Variant anatomy of the cystic artery in adult Kenyans. *Clinical Anatomy (New York, NY)*. 2007;**20**(8):943-945
- [14] Michels NA. Newer anatomy of the liver and its variant blood supply and collateral circulation. *American Journal of Surgery*. 1966;**112**(3):337-347
- [15] Mlakar B, Gadzijev EM, Ravnik D, Hribernik M. Anatomical variations of the cystic artery. *European Journal of Morphology*. 2003;**41**(1):31-34
- [16] Loukas M, Ferguson A, Louis RG, Colborn GL. Multiple variations of the hepatobiliary vasculature including double cystic arteries, accessory left

hepatic artery and hepatosplenic trunk: A case report. *Surgical and Radiologic Anatomy*. 2006;**28**(5):525-528

[17] Zubair M, Habib L, Mirza RM, Cnanna MA, Yousuf M, Quraishy MS. Anatomical variations of cystic artery: Telescopic facts. *The Medical Journal of Malaysia*. 2012;**67**(5):494-496

[18] Sarkar AK, Roy TS. Anatomy of the cystic artery arising from the gastroduodenal artery and its choledochal branch—A case report. *Journal of Anatomy*. 2000;**197**(Pt 3): 503-506

[19] Blecha MJ, Frank AR, Worley TA, Podbielski FJ. Aberrant right hepatic artery in laparoscopic cholecystectomy. *Journal of the Society of Laparoendoscopic Surgeons*. 2006;**10**(4):511-513

[20] Jones RM, Hardy KJ. The hepatic artery: A reminder of surgical anatomy. *Journal of the Royal College of Surgeons of Edinburgh*. 2001;**46**(3):168-170

[21] Hiatt JR, Gabbay J, Busuttil RW. Surgical anatomy of the hepatic arteries in 1000 cases. *Annals of Surgery*. 1994;**220**(1):50-52

[22] Uenishi T, Hirohashi K, Tanaka H, Fujio N, Kubo S, Kinoshita H. Right hepatic lobectomy for recurrent cholangitis after bile duct and hepatic artery injury during laparoscopic cholecystectomy: Report of a case. *Hepato-Gastroenterology*. 1999;**46**(28):2296-2298

[23] Covey AM, Brody LA, Maluccio MA, Getrajdman GI, Brown KT. Variant hepatic arterial anatomy revisited: Digital subtraction angiography performed in 600 patients. *Radiology*. 2002;**224**(2):542-547

[24] Scott-Conner CE, Hall TJ. Variant arterial anatomy in laparoscopic cholecystectomy. *American Journal of Surgery*. 1992;**163**(6):590-592

[25] Katagiri H, Sakamoto T, Okumura K, Lefor AK, Kubota T. Aberrant right hepatic artery arising from the celiac trunk: A potential pitfall during laparoscopic cholecystectomy. *Asian Journal of Endoscopic Surgery*. 2016;**9**(1):72-74

[26] Gupta N, Solomon H, Fairchild R, Kaminski DL. Management and outcome of patients with combined bile duct and hepatic artery injuries. *Archives of Surgery (Chicago, Ill: 1960)*. 1998;**133**(2):176-181

[27] Martino V, Ferrarese A, Bindi M, Marola S, Gentile V, Rivelli M, et al. Abnormal right hepatic artery injury resulting in right hepatic atrophy: Diagnosed by laparoscopic cholecystectomy. *Open Medicine (Warsaw, Poland)*. 2015;**10**(1):535-537

[28] Mirza DF, Narsimhan KL, Ferraz Neto BH, Mayer AD, McMaster P, Buckels JA. Bile duct injury following laparoscopic cholecystectomy: Referral pattern and management. *The British Journal of Surgery*. 1997;**84**(6):786-790

[29] Rocko JM, Di Gioia JM. Calot's triangle revisited. *Surgery, Gynecology & Obstetrics*. 1981;**153**(3):410-414

[30] Yakura T, Hayashi S, Terayama H, Miyaki T, Nakano T, Naito M. A case of a cystic artery arising from the superior mesenteric artery with abnormal branching of the celiac trunk. *BMC Research Notes*. 2017;**10**(1):526

[31] Lau WY, Fan ST, Wong SH. Acute torsion of the gall bladder in the aged: A re-emphasis on clinical diagnosis. *The Australian and New Zealand Journal of Surgery*. 1982;**52**(5):492-494

[32] Yokoi T, Miyata K, Yuasa N, Takeuchi E, Goto Y, Miyake H, et al. Twisted cystic artery disclosed by 3-dimensional computed tomography angiography for torsion of the gallbladder. *American Journal of Surgery*. 2011;**201**(5):e33-e34

- [33] Chou CT, Chen RC, Yang AD, Wu HK. Gallbladder torsion: Preoperative diagnosis by MDCT. *Abdominal Imaging*. 2007;**32**(5):657-659
- [34] To K, Lai EC, Chung DT, Chan OC, Tang CN. Cystic artery pseudoaneurysm with haemobilia after laparoscopic cholecystectomy. *Hong Kong Medical Journal [Xianggang yi xue za zhi]*. 2018;**24**(2):203-205
- [35] Moses V, Keshava SN, Wann VC, Joseph P, Sitaram V. Cystic artery pseudoaneurysm after laparoscopic cholecystectomy presenting as haemobilia: A case report. *Tropical Gastroenterology*. 2008;**29**(2):107-109
- [36] Bulut T, Yamaner S, Bugra D, Akyuz A, Acarli K, Poyanli A. False aneurysm of the hepatic artery after laparoscopic cholecystectomy. *Acta Chirurgica Belgica*. 2002;**102**(6):459-463
- [37] Kumar A, Sheikh A, Partyka L, Contractor S. Cystic artery pseudoaneurysm presenting as a complication of laparoscopic cholecystectomy treated with percutaneous thrombin injection. *Clinical Imaging*. 2014;**38**(4):522-525
- [38] De Molla Neto OL, Ribeiro MA, Saad WA. Pseudoaneurysm of cystic artery after laparoscopic cholecystectomy. *HPB: The Official Journal of the International Hepato Pancreato Biliary Association*. 2006;**8**(4):318-319
- [39] Wen F, Dong Y, Lu ZM, Liu ZY, Li W, Guo QY. Hemobilia after laparoscopic cholecystectomy: Imaging features and management of an unusual complication. *Surgical Laparoscopy, Endoscopy & Percutaneous Techniques*. 2016;**26**(1):e18-e24
- [40] Sansonna F, Boati S, Sguinzi R, Migliorisi C, Pugliese F, Pugliese R. Severe hemobilia from hepatic artery pseudoaneurysm. *Case Reports in Gastrointestinal Medicine*. 2011;**2011**:925142
- [41] Madanur MA, Battula N, Sethi H, Deshpande R, Heaton N, Rela M. Pseudoaneurysm following laparoscopic cholecystectomy. *Hepatobiliary & Pancreatic Diseases International*. 2007;**6**(3):294-298
- [42] Bin Traiki TA, Madkhali AA, Hassanain MM. Hemobilia post laparoscopic cholecystectomy. *Journal of Surgical Case Reports*. 2015;**2015**(2):rju159
- [43] Nicholson T, Travis S, Ettles D, Dyet J, Sedman P, Wedgewood K, et al. Hepatic artery angiography and embolization for hemobilia following laparoscopic cholecystectomy. *Cardio Vascular and Interventional Radiology*. 1999;**22**(1):20-24
- [44] Bulut T, Yamaner S, Bugra D, Akyuz A, Acarli K, Poyanli A. False aneurysm of the hepatic artery after laparoscopic cholecystectomy. *Acta Chirurgica Belgica*. 2002;**102**(6):459-463
- [45] Loizides S, Ali A, Newton R, Singh KK. Laparoscopic management of a cystic artery pseudoaneurysm in a patient with calculus cholecystitis. *International Journal of Surgery Case Reports*. 2015;**14**:182-185
- [46] Liang X, Lu JM, Meng N, Jin RA, Cai XJ. Hemorrhagic shock caused by rupture of cystic artery pseudoaneurysm secondary to calculous cholecystitis. *Chinese Medical Journal*. 2013;**126**(23):4590-4591
- [47] Trombatore C, Scilletta R, Bellavia N, Trombatore P, Magnano SLV, Petrillo G, et al. Acute hemobilia from a pseudoaneurysm of the cystic artery arising from the left hepatic artery: Case report and literature review. *International Journal of Surgery Case Reports*. 2017;**37**:60-64
- [48] Demyttenaere SV, Hassanain M, Halwani Y, Valenti D, Barkun JS. Massive hemobilia. *Canadian Journal*



of Surgery Journal [Canadien de Chirurgie]. 2009;52(4):E109-Ee10

[49] Hadj AK, Goodwin M, Schwalb H, Nikfarjam M. Pseudoaneurysm of the hepatic artery. *Journal of Gastrointestinal Surgery: Official Journal of the Society for Surgery of the Alimentary Tract*. 2011;15(10):1899-1901

[50] Green MH, Duell RM, Johnson CD, Jamieson NV. Haemobilia. *The British Journal of Surgery*. 2001;88(6):773-786

[51] Priya H, Anshul G, Alok T, Saurabh K, Ranjit N, Romesh L, et al. Emergency cholecystectomy and hepatic arterial repair in a patient presenting with haemobilia and massive gastrointestinal haemorrhage due to a spontaneous cystic artery gallbladder fistula masquerading as a pseudoaneurysm. *BMC Gastroenterology*. 2013;13:43

[52] Hsiao CY, Kuo TC, Lai HS, Yang CY, Tien YW. Obstructive jaundice as a complication of a right hepatic artery pseudoaneurysm after laparoscopic cholecystectomy. *Journal of Minimal Access Surgery*. 2015;11(2):163-164

[53] Ouazzani A, Bataille D, Boutkhil A, Guerin E, Lefebvre JC, Vaneukem P. Spontaneous cystic artery rupture: A rare cause of haemoperitoneum. *Acta Chirurgica Belgica*. 2009;109(1):106-108

[54] Tessier DJ, Fowl RJ, Stone WM, McKusick MA, Abbas MA, Sarr MG, et al. Iatrogenic hepatic artery pseudoaneurysms: An uncommon complication after hepatic, biliary, and pancreatic procedures. *Annals of Vascular Surgery*. 2003;17(6):663-669

[55] Choudhary A, Barakat MT, Higgins LJ, Banerjee S. Choledochoscopic identification of a hepatic/cystic artery pseudoaneurysm in a patient with hematemesis after laparoscopic

cholecystectomy. *Digestive Diseases and Sciences*. 2017;62(6):1439-1442

[56] Maeda A, Kunou T, Saeki S, Aono K, Murata T, Niinomi N, et al. Pseudoaneurysm of the cystic artery with hemobilia treated by arterial embolization and elective cholecystectomy. *Journal of Hepato-Biliary-Pancreatic Surgery*. 2002;9(6):755-758

[57] Roche-Nagle G, Maceneaney, Harte P. Pseudo-aneurysm of the hepatic artery after laparoscopic cholecystectomy: A case report. *Journal of Minimal Access Surgery*. 2006;2(2):73-75

[58] Sebastian JJ, Pena E, Blas JM, Cena G. Fatal upper gastrointestinal bleeding due to hepatic artery pseudoaneurysm diagnosed by endoscopy. *Digestive Diseases and Sciences*. 2008;53(4):1152-1153

[59] Deziel DJ, Millikan KW, Economou SG, Doolas A, Ko ST, Airan MC. Complications of laparoscopic cholecystectomy: A national survey of 4,292 hospitals and an analysis of 77,604 cases. *American Journal of Surgery*. 1993;165(1):9-14

[60] Genyk YS, Keller FS, Halpern NB. Hepatic artery pseudoaneurysm and hemobilia following laser laparoscopic cholecystectomy. A case report. *Surgical Endoscopy*. 1994;8(3):201-204

[61] Saldinger PF, Wang JY, Boyd C, Lang E. Cystic artery stump pseudoaneurysm following laparoscopic cholecystectomy. *Surgery*. 2002;131(5):585-586

[62] Chen CC, Chen BB, Wang HP. Upper gastrointestinal bleeding owing to right hepatic artery pseudoaneurysm after laparoscopic cholecystectomy. *Gastroenterology*. 2009;137(5):e5-e6

- [63] Boddy A, Macanovic M, Thompson J, Watkinson A. Use of an endovascular stent graft and percutaneous thrombin injection to treat an iatrogenic hepatic artery pseudoaneurysm. *Annals of the Royal College of Surgeons of England*. 2010;**pii**:952. DOI: 10.1308/147870810x12822015504806. ISSN: 0035-8843. <https://doi.org/10.1308/147870810X12822015504806>
- [64] Yao CA, Arnell TD. Hepatic artery pseudoaneurysm following laparoscopic cholecystectomy. *American Journal of Surgery*. 2010;**199**(1):e10-e11
- [65] Nakase Y, Takagi T, Fukumoto K, Kassai K, Yamagami T, Itani K, et al. Hemobilia and cystic artery stump pseudoaneurysm associated with liver abscess after a laparoscopic cholecystectomy: Report of a case. *Surgery Today*. 2008;**38**(6):567-571
- [66] Murugesan SD, Sathyanesan J, Lakshmanan A, Ramaswami S, Perumal S, Perumal SU, et al. Massive hemobilia: A diagnostic and therapeutic challenge. *World Journal of Surgery*. 2014;**38**(7):1755-1762
- [67] Feng W, Yue D, Zai Ming L, Zhao Yu L, Wei L, Qiyong G. Hemobilia following laparoscopic cholecystectomy: Computed tomography findings and clinical outcome of transcatheter arterial embolization. *Acta Radiologica (Stockholm, Sweden: 1987)*. 2017;**58**(1):46-52
- [68] Hylton JR, Pevac WC. Successful treatment of an iatrogenic right hepatic artery pseudoaneurysm and stenosis with a stent graft. *Journal of Vascular Surgery*. 2010;**51**(6):1510-1513
- [69] Halbe S, Ahmed NI, Sundar K, Sathyakumar C. Pseudoaneurysm in gall bladder fossa following laparoscopic cholecystectomy. *Indian Journal of Gastroenterology: Official Journal of the Indian Society of Gastroenterology*. 1999;**18**(3):122
- [70] Kirschberg O, Scheduling A, Saers T, Krakamp B. Detection and treatment of an aneurysma spurium of the arteria hepatica dextra after laparoscopic cholecystectomy. *BMC Gastroenterology*. 2013;**13**:121
- [71] Gandhi V, Doctor N, Marar S, Nagral A, Nagral S. Major hemobilia— Experience from a specialist unit in a developing country. *Tropical Gastroenterology: Official Journal of the Digestive Diseases Foundation*. 2011;**32**(3):214-218
- [72] Machado NO, Al-Zadjali A, Kakaria AK, Younus S, Rahim MA, Al-Sukaiti R. Hepatic or cystic artery pseudoaneurysms following a laparoscopic cholecystectomy: Literature review of aetiopathogenesis, presentation, diagnosis and management. *Sultan Qaboos University Medical Journal*. 2017;**17**(2):e135-ee46
- [73] Chigot V, Lallier M, Alvarez F, Dubois J. Hepatic artery pseudoaneurysm following laparoscopic cholecystectomy. *Pediatric Radiology*. 2003;**33**(1):24-26