

# We are IntechOpen, the world's leading publisher of Open Access books Built by scientists, for scientists

4,800

Open access books available

122,000

International authors and editors

135M

Downloads

Our authors are among the

154

Countries delivered to

TOP 1%

most cited scientists

12.2%

Contributors from top 500 universities



WEB OF SCIENCE™

Selection of our books indexed in the Book Citation Index  
in Web of Science™ Core Collection (BKCI)

Interested in publishing with us?  
Contact [book.department@intechopen.com](mailto:book.department@intechopen.com)

Numbers displayed above are based on latest data collected.  
For more information visit [www.intechopen.com](http://www.intechopen.com)



---

# Orthodontics in Relation with Alveolar Bone Grafting in CLP Patients

---

Aslıhan Uzel

Additional information is available at the end of the chapter

<http://dx.doi.org/10.5772/intechopen.80853>

---

## Abstract

Alveolar bone grafting is an essential step in the overall management of patients with cleft lip and palate (CLP). The numerous advantages of this procedure have been reported in the literature. Failure to rehabilitate the alveolar cleft may give rise to a variety of problems. Lack of investing alveolar bone often precludes the correction of anterior tooth irregularities and limits orthodontic treatment and/or prosthodontic rehabilitation. The success of the graft is multifactorial. The periodontal health of the surrounding graft tissues, the experience and ability of the surgeon, the timing of surgery, and orthodontic management of the cleft area before and after grafting are shown to be the most important factors in this issue. In this chapter, current orthodontic approaches in relation with alveolar bone grafting (ABG) in cleft patients will be discussed.

**Keywords:** cleft palate, alveolar bone grafting, orthodontics

---

## 1. Introduction

Cleft lip and palate (CLP) are among the most common of all congenital facial deformities which affect approximately 1 in every 600 newborn babies worldwide [1]. Congenital CL/P can arise in isolation or together with other syndromes. Alveolar cleft (osseous defect in the alveolus of upper jaw) affects approximately 75% of cleft lip and palate patients [2, 3].

The rehabilitation of individuals with CL/P requires interdisciplinary care by centralization of treatment [1, 4].

As the facial cleft affects the whole stomatognathic system, orthodontics is a core element of the overall treatment process. The orthodontist should aim to provide a dentition that

---

functions well and is capable of lifetime maintenance by routine oral hygiene and dental care. However, the underlying skeletal deformity that reflects intrinsic variation and the consequences of surgery severely restricts occlusal change [5].

There are two major factors which effect orthodontic treatment in patients with CLP:

### 1. Facial growth disruption

It is well known that facial growth in patient with CP is disturbed. Besides the intrinsic defect, surgery itself contributes to further disruption [3, 6]. A significant feature of facial growth in repaired CP patients is that the maxilla fails to grow at the same rate as the mandible during the adolescent growth spurt. Progressive midfacial retrusion is usually seen by the mid- to late teens. The results of the facial growth studies revealed the general characteristics of the individuals with UCLP: a short retrusive maxilla and vertical elongation of the anterior face, a retrusive mandible, and a reduction in posterior face height [6–9].

### 2. Alveolar bone deficiency

Lack of the alveolar bone may give rise to a variety of problems, including oronasal fistula, fluid reflux, speech pathology, impaired tooth eruption, lack of bone support for the anterior teeth, dental crowding, periodontal recession and eventual loss of teeth, and maxillary and facial asymmetry. Alveolar defect also limits orthodontic treatment and/or prosthodontic rehabilitation [10–12].

Thus, orthodontic treatment for children with cleft should aim to achieve an optimal occlusion and dentofacial esthetics within the constraints imposed by the underlying skeletal pattern [5].

The integration of orthodontics into the overall treatment of CLP starts any point between birth and end of the teens and highly related to surgical procedures, including lip repair, alveolar bone grafting, distraction, and orthognathic surgery [5].

This chapter reviews current orthodontic approaches in relation with alveolar bone grafting (ABG) in nonsyndromic cleft patients.

## 2. Alveolar bone grafting

Alveolar bony defect is the main limiting factor for orthodontic treatment. Elimination of the bony defect is provided by alveolar bone grafting (ABG). Since the introduction of secondary alveolar bone grafting (SABG) in 1972, this technique has become an essential step in the overall management of patients with cleft lip and palate (CLP). Providing bone tissue for cleft has following benefits: [10, 12–21]

1. To permit eruption of the permanent canine in the cleft site into sound bone.
2. To provide bony support for teeth on either side of the cleft site.
3. To permit orthodontic tooth movement.

4. To obviate or minimize the need for prosthetic replacement of teeth in the cleft site.
5. To permit placement of osseointegrated implants into the cleft area when indicated.
6. To stabilize maxillary dental arch.
7. To facilitate fistula closure.
8. To improve the contour of the alar base.

The long-term success of the alveolar graft is crucial for providing and lifetime maintaining optimal occlusion and dentofacial esthetics in patients with CLP.

Postgraft stimulation of maturation through remodeling of the graft is extremely important and is provided primarily by natural tooth eruption. Thus, it is generally agreed that the optimum timing for ABG is in the mixed dentition stage (8–11 years), just before the eruption of the permanent canine in line with the cleft side [10, 13, 16, 19, 22–29]. There is no precise recommended chronological age but, when one-half to two-thirds of the canine root is formed [10]. Canines are mostly the reference teeth because lateral incisors in patient with CLP are frequently absent. However, if lateral incisor is present, earlier bone grafting can be indicated at an age around 7–8 years. It has been found that the success rate is significantly reduced when ABG is performed after eruption of the canine. Resorption of the bone graft is a common situation, and the success of ABG depends on several factors. The periodontal health of the surrounding graft tissues, the experience and ability of the surgeon, and graft material are also shown to be the general factors determining success [13, 19, 20, 23, 30, 31].

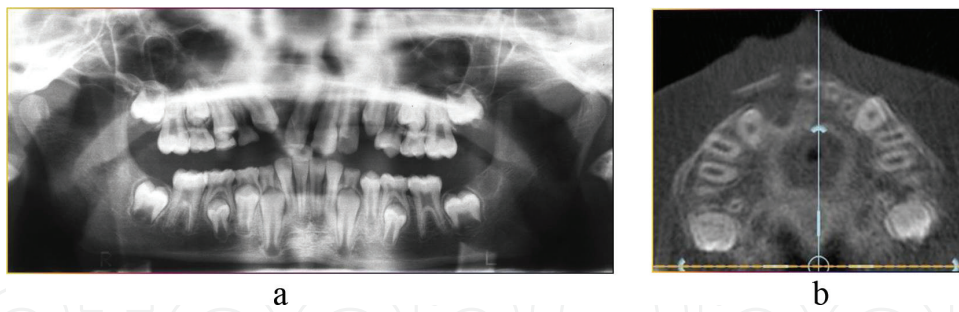The importance of the orthodontist in planning, preparations, and follow-up around ABG procedure is also widely recognized. Successful alveolar bone grafting necessitates a joint orthodontic and surgical involvement pre-, peri-, and postoperatively [10, 32, 33].

Before treatment, orthodontists should be able to explain the predicted outcome of bone grafting to patients and their parents [34].

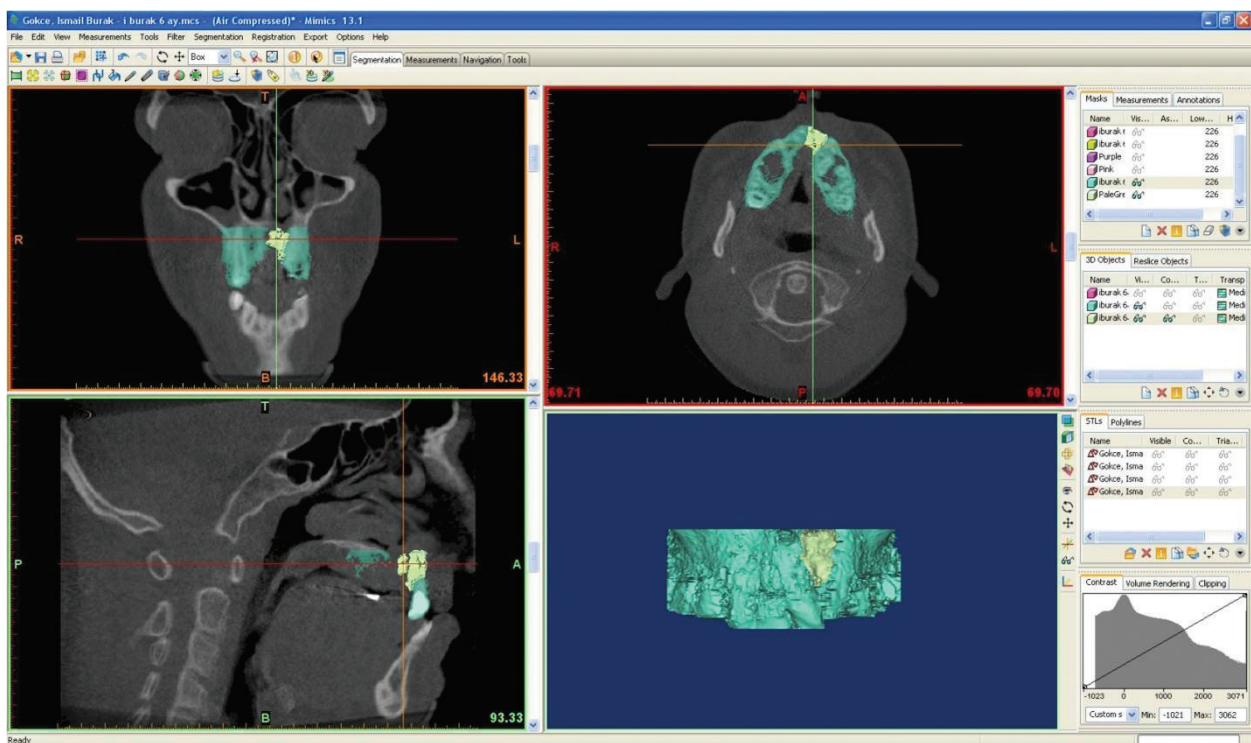
At that point, diagnostic information is very important for planning pre- and post-orthodontic management.

### **3. Advantages of CBCT in diagnosing and treatment planning of patients with CLP**

A bony bridge with sufficient height and width is important for successful bone grafting in the alveolar cleft and to guide eruption and movement of permanent teeth [15, 35–37]. The outcome of the procedure is considered satisfactory when a sufficient volume of remodeled bone tissue is obtained; otherwise, the surgery has to be repeated. Thus, volumetric measurements of CBCT images have been using to evaluate the success of alveolar graft outcomes in the current literature [38]. CBCT, an alternative approach to conventional CT that provides similar diagnostic information with much less radiation exposure, avoids the problems associated with traditional 2D imaging such as image enlargement and distortion, structure



**Figure 1.** Superimpositions on the 2D imaging might led to misdiagnosis. (a) Grafted area seems to be filled successfully on the pantomograph; (b) axial view of the CBCT image shows that graft is not successful as seen on the panoramic radiograph.

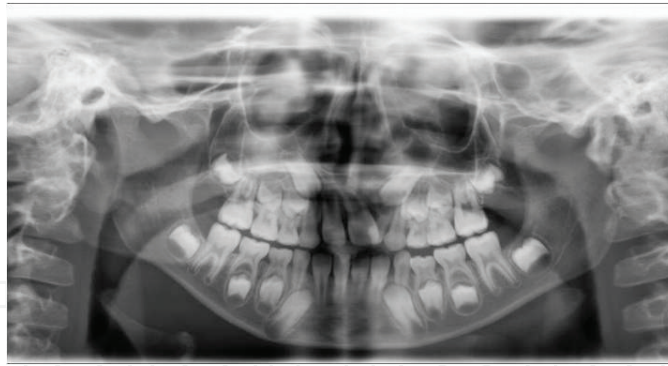

**Figure 2.** The precise volume and density can be measured by using various software.

overlap, positional problems, and limited number of identifiable landmarks (**Figure 1**). It has been used to quantify the average volume of the graft, location of the bone loss, and periodontal bone support of the cleft-adjacent teeth. CBCT-derived volumetric assessment of alveolar grafts has been reported as a reliable method [24, 29, 37, 39, 40] (**Figure 2**). The success rate of an alveolar graft has been found to be significantly lower with volumetric evaluation than that with conventional radiographic imaging [39, 41, 42].

#### 4. Mixed dentition stage (phase I orthodontic treatment)

Orthodontic treatment of patients with CLP takes much more time (is more extensive) than routine treatment because of the underlying skeletal pattern. There is no need to attempt



**Figure 3.** Malpositioned lateral incisor in the cleft area should be extracted 3–4 weeks before ABG.

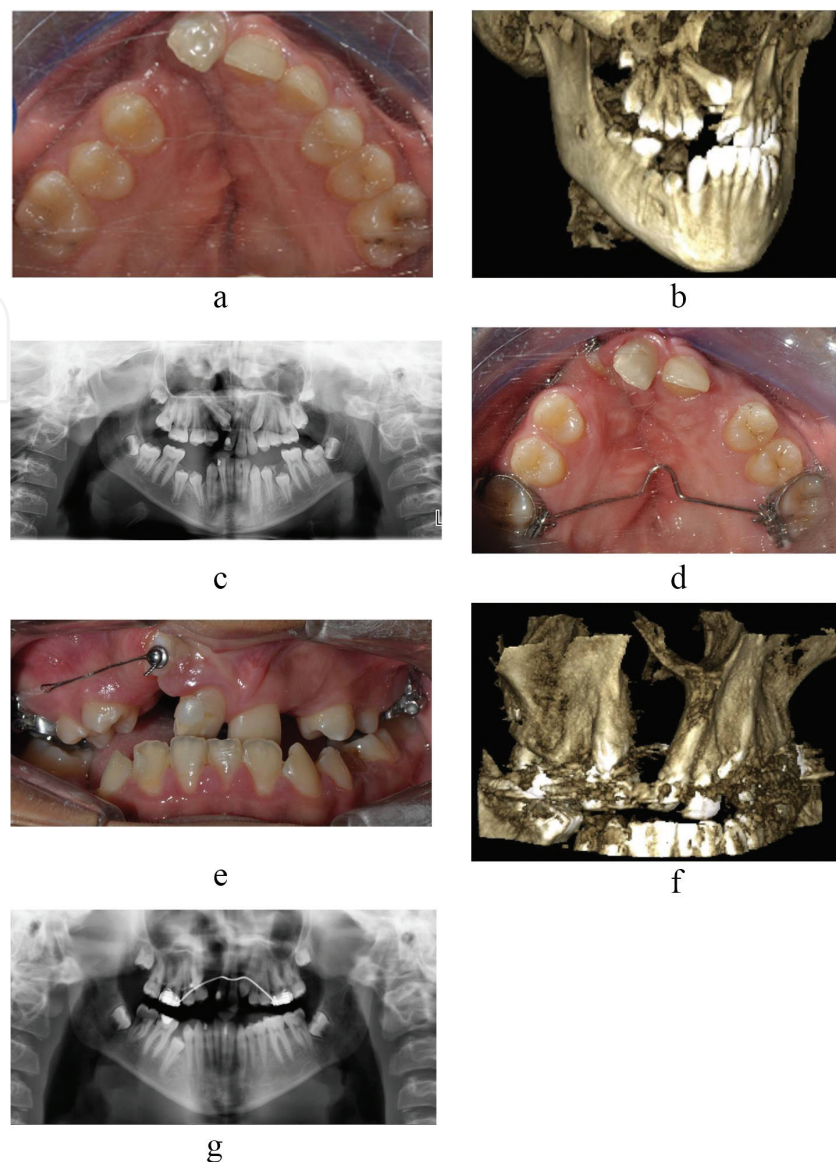
orthodontic treatment in deciduous dentition stage. This will need much more retention procedures and will impose unnecessary burden of care [5].

Monitoring eruption of the teeth is important by the age 6–7. Radiographic evaluation is needed at the age of 8–9 (after eruption of upper incisors) to detect any possible teeth positioned in the cleft area and to see if lateral incisor is missing or not. If lateral incisor is present, earlier bone grafting can be planned. It is often advisable that any supplemental, deciduous teeth and also malformed and/or malpositioned lateral incisors in the cleft area should be extracted 3–4 weeks before surgery that permits healing of the mucosa (**Figure 3**). Thus, CBCT 6–8 months before ABG is recommended for detailed evaluation of bony support and position of the cleft-related teeth. This time frame will provide enough time to accomplish all necessary pregraft preparations such as tooth extraction and/or orthodontic tooth movement on time and not to delay bone grafting. Sometimes an additional CBCT just before the grafting might be needed to assess the root position of the cleft-related teeth after orthodontic movement.

#### **4.1. Pre-graft orthodontics**

Presurgical orthodontics plays an important role in correcting misaligned incisors or repositioning displaced maxillary alveolar segments. Severe central or canine inclination toward the cleft defect can also interfere with cleft mucoperiosteal dissection. Presurgical orthodontics allows the surgeon better access for placement of the graft and closure of the soft tissue (**Figure 4**). Furthermore, correction of central incisor rotation and inclination prior to SABG enables patients to achieve better oral hygiene and prevents plaque formation. This can therefore prevent chronic, low-grade inflammation activating proteases that degrade grafted bone [5, 32, 33, 38].

One of the presenting problems which occurs early in both unilateral and bilateral clefts is the anteroposterior malpositioning of the incisors. If the anteroposterior malpositioning of the incisors is not corrected, lingual lock of the anterior teeth will further inhibit the development of the maxilla. The proper overjet relationship will allow appropriate growth of the maxilla [19]. By age 7–8, incisor alignment and correction of anterior crossbite can be provided to maximize the forward development of the maxillary dentoalveolar process. However, orthodontic movement of maxillary anterior teeth must be done with great caution because of the closeness of the roots to the bony defect. A very thin bony covering of the central incisor next to the cleft site is a common feature. Often there is just a lamina dura with no cancellous bone.



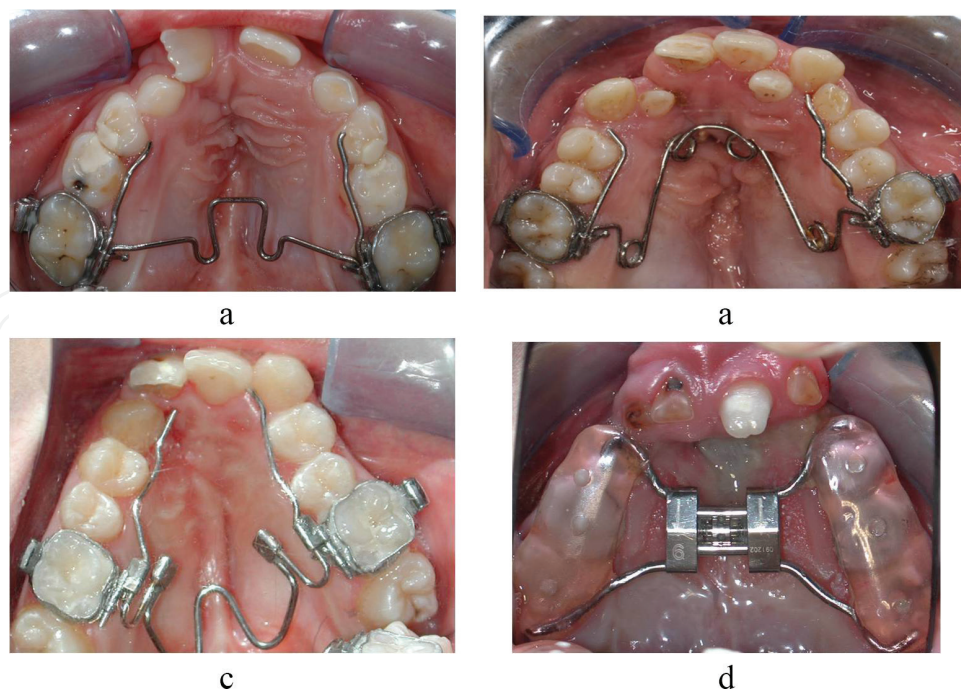
**Figure 4.** Severe canine inclination toward the cleft defect should be corrected before ABG. (a,b,c) initial views, a. intraoral, b. 3D image c. panoramic radiograph of the patient. (d,e) orthodontic traction of the cleft related canine. (f,g) pregraft 3D image and panoramic radiograph.

The incisor should not be bodily uprighted before successful ABG because of the possibility of bone loss and fenestration of the thin cortical lamina [10, 43].

#### 4.2. Transverse expansion

Constriction of maxillary segments is a very common situation in patients with cleft palate. As the individuals with complete cleft lip and palate do not have midpalatal suture, constriction occurs mostly by the rotation of the lateral segment(s) inward, toward bony defect. Both the absence of the midpalatal bone and the soft tissue traction produced by lip and palate repair promote arch constriction [5, 44, 45].

Significant segmental displacement requires pre-bone graft expansion to rotate the lateral segment(s) outward, facilitate placement of the graft, and provide the surgeon working



**Figure 5.** Various types of expanders for maxillary expansion. (a) TPA with lateral expansions, (b) quad helix, (c) NiTi expander, and (d) hyrax.

facility during surgery. If possible, transverse expansion can be combined with the correction of incisor irregularities. In the mixed dentition stage, arch expansion is very important because this process also normalizes the morphology and induces eruption of the canine into the symmetrical maxillary arch [10, 13, 19, 46].

Several types of expanders have been used, and there is no universal protocol for maxillary expansion prior to secondary alveolar bone grafting (Figure 5). Both slow maxillary expansion (SME) and rapid maxillary expansion (RME) have been advocated [5, 47, 48].

SME using the quad helix or its variations is frequently used for segmental repositioning as selective expansion anteriorly is required [5]. It has been shown that slow expansion forces are apparently already sufficient to allow a skeletal expansion of the maxilla in complete cleft palate patients [45, 47, 48]. There were *no differences* found between the dentoalveolar effects of SME and RME in patients with BCLP [45, 47].

RME with Haas type or hyrax expanders is also widely used for correcting the maxillary constriction. Asymmetric expansions were found by several authors [46, 48–53]. Isaacson and Murphy reported no correlation between the cleft location and the relative amount of lateral movement of each maxillary segment, emphasizing that RME laterally repositioned the maxillary segments in an unpredictable manner [49]. For greater amount of anterior displacement of the maxilla, fante type or double-hinged RPE expanders have been advocated [54].

According to our clinical experience, there is usually no need for RPE in patients with UCLP. Quad helix or TPA with lateral expansions can solve the problem. However, in some patients with BCLP, significant constriction of the segments necessitates RPE. Thus, patient selection is important in this issue.



## 5. Postgraft stabilization

The quad helix and/or stabilizing archwire used in BCLP may be removed during the bone grafting procedure for improved surgical access, but these appliances should be replaced before the patient leaves the operating room and left in place for 3 months.

As the bone grafting alone cannot be relied upon to maintain the expansion, a simple palatal arch would be advisable until the permanent dentition has erupted.

Stabilizing a mobile premaxilla with orthodontic arch wire is needed in patients with complete BCLP. Typically the arch wires will be removed during surgery and replaced at the end of the operation to provide retention [5, 10, 19].

## 6. Postgraft orthodontics

If the graft is done at proper time, before eruption of the cleft-related permanent canine, observation of the permanent dentition is generally all that is necessary. The status of cleft side unerupted teeth does need careful monitoring [5]. Physiologic eruption of the adjacent canine will provide enough stimulation for the alveolar graft. Sometimes orthodontic traction might be needed if the position of the canine is not appropriate for spontaneous eruption. High degrees of canine inclination indicate risk for altered eruption and impaction [5, 32].

If graft is done at age 7–8, correction of incisor irregularities provides also favorable stimulation to the graft.

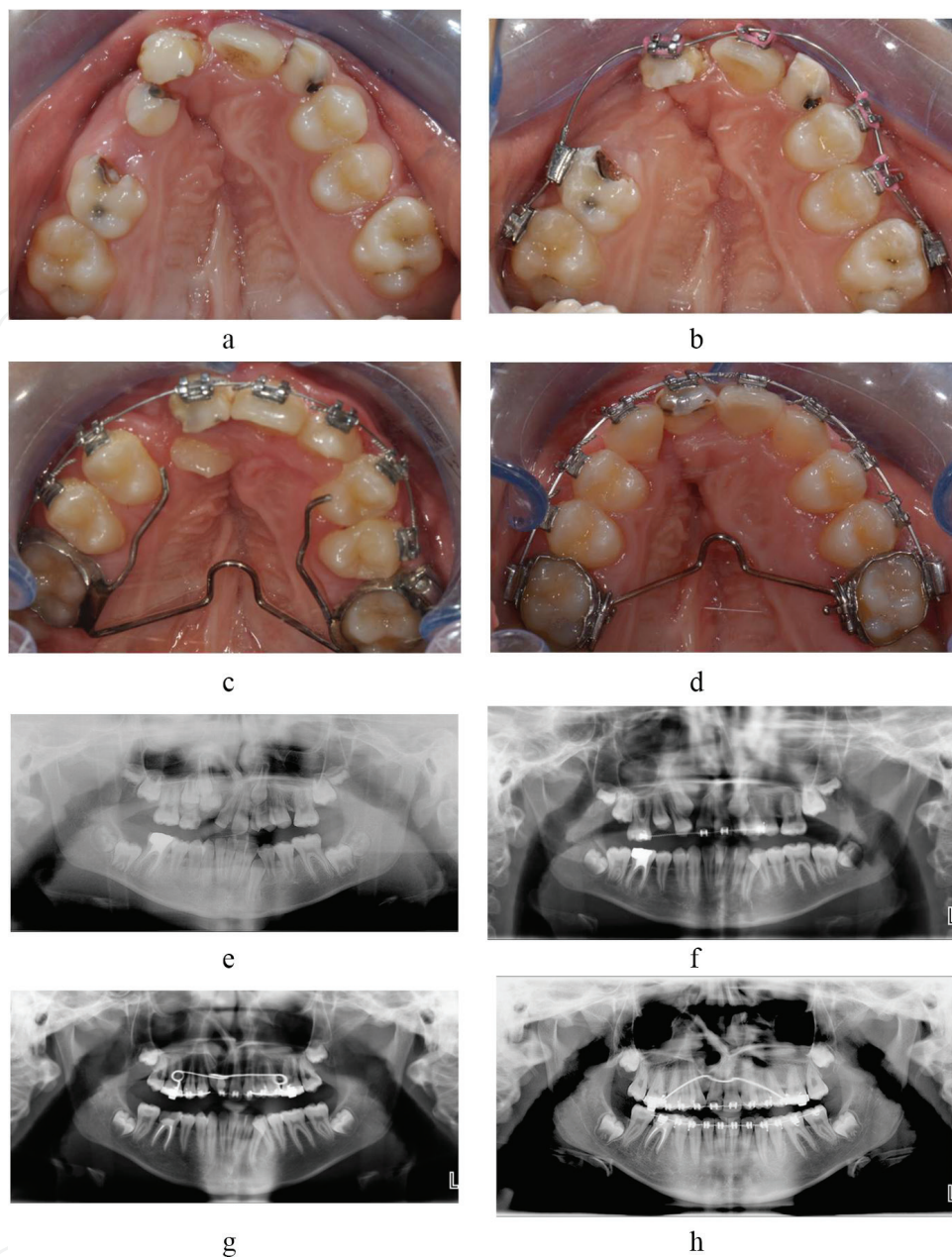
Orthodontic movement of the cleft-adjacent teeth in the direction of the grafted bone can be instituted at an average of 3 months after the bone grafting, if needed. Combined interceptive bone grafting and orthodontic treatment at an early age avoid more extensive prolonged treatment later in the patient's life [5, 13, 19, 34].

It has been recommended not to delay orthodontic treatment more than 6 months after grafting, in cases in which an a-p crossbite or a residual transverse posterior crossbite exists. One- to two year delay in stimulation of the ABG of the premaxilla (by orthodontic treatment) can lead to serious postoperative problems. Where there is no stimulation of the graft, there tends to be "locking" or lingual collapse of the maxillary central incisors and collapse of the premaxillary arch [19].

### 6.1. Maxillary space management choice

In patients with CLP, the lateral incisor is missing in about 50% of cases in the permanent dentition. There are two options when maxillary lateral incisors are absent: space closure or space preservation [5].

The success of the bone graft is the determinant factor for this choice. When bone graft is properly done before the eruption of the permanent canine, canine can simultaneously migrate



**Figure 6.** Space closure with canine substitution in patient with successful ABG. (a-d) intraoral occlusal views of the case. a. pre-graft, b. post-graft, c. after eruption of the canine, d. levelling of the upper dentition. (e-h) panoramic radiographs of the case. a. pre-graft, b. post-graft, c. eruption of the canine, h. levelling of the upper arch.

into the newly formed bone and increases its vertical height. Maintaining the alveolar bone height in the cleft area is important to prevent long-term complications, such as gingival retractions and periodontitis [32, 33].

Moreover, the natural dentition has the best prognosis for long-term health of the dentition. Thus, space closure with the canine substitution should be the first treatment choice for patients with CLP [5, 32, 33] (**Figure 6**). The functional stress imposed by orthodontic treatment influences the volume and prevents resorption of the grafted bone. Higher grafting success was found in the case of space closure than in the case of space openings [5, 33].

However, in patients with severely impaired maxillary growth, multiple missing teeth, and/or failure of bone graft, orthodontic space closure may not be feasible, and some form of prosthesis might be needed.

## 6.2. Extraction choice

Extraction of maxillary teeth may be required in UCLP in non-cleft quadrant, either because of crowding or to allow correction of the dental midline. As the second premolar is frequently malformed, it is the most commonly removed tooth. In some patients removal of the non-cleft lateral incisor allows the rapid restoration of the symmetry. However, this should be considered when compliance with space closure is assured [5].

In the lower arch, the absence of the second premolars is frequent and should be assessed carefully where extractions are necessary to relieve lower incisor crowding.

Extraction of the lower teeth to compensate class III skeletal pattern should be avoided in the early teens.

## 7. Management of maxillary deficiency in growing cleft patients

Hypoplastic maxilla and progressive midface retrusion are typical characteristics of patients with CLP.

Therefore, maxillary protraction (MP) has been frequently applied in the orthodontic treatment of growing patients with cleft lip and palate to improve the maxillomandibular relationship, occlusion, and facial esthetics. Optimal timing for initiating maxillary protraction for non-cleft children is shown as in the early mixed dentition before age 10. Early mixed dentition is favored over late, because of the closure of the sutures of the nasomaxillary complex [55].

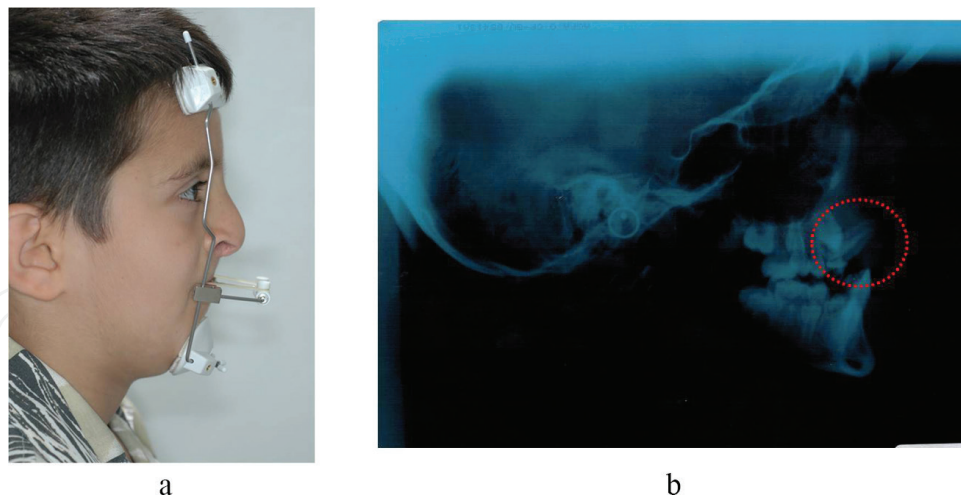
However, SABG is optimally carried out between 9 and 11 years, and there is no consensus on the treatment sequencing of maxillary protraction and SABG in patients with CLP.

Two studies of three-dimensional finite element analysis suggested the advantage of SABG before maxillary protraction [55–57].

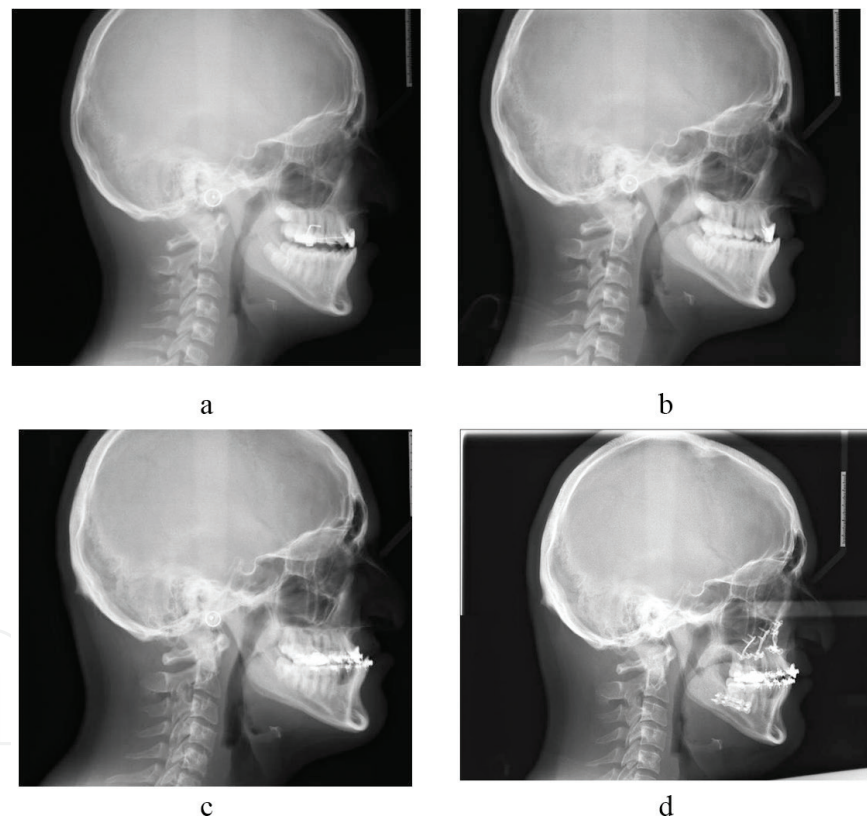
In a recent clinical study, short-term results showed that facemask therapy after alveolar bone grafting led to enhance maxillary skeletal advancement and minimize mandibular clockwise rotation more than those in the ungrafted group.

Maeda-lino found that the root lengths of U1 were comparatively short on the cleft side in patients with UCLP treated with MPA before SABG. Thus, they concluded that orthodontic force exerted by the MPA before SABG might result in short dental roots [58].

Moreover, it has been advocated that protraction of severely retruded cleft maxilla, even at an early stage, does not provide lasting skeletal benefit. Its effect in individual cases with CLP is difficult to predict, and many patients require orthognathic surgery after MP treatment [5, 59, 60] (**Figures 7 and 8**). Thus, explanation of the expected effects and associated problems should be given to the patients and parents before MP treatment.



**Figure 7.** Face mask application using bonded hyrax in patient with BCLP. (a) extraoral view of the patient. (b) initial lateral cephalogram.



**Figure 8.** Cephalometric radiographs of the patient after facemask therapy between 10 and 19 years of age and after orthognathic surgery. (a) age 10, after face mask therapy, (b) age 14, follow-up, (c) age 19, pre-orthognathic surgery, (d) after orthognathic surgery.

### 7.1. Patients with no to mild skeletal discrepancy

Providing proper overjet relationship at the early mixed dentition by correcting lingual lock of the anterior teeth using either removable or fixed appliances will be sufficient to maximize the forward development of the maxillary dentoalveolar process. Facemask can be a valuable source of anchorage for advancing posterior teeth during space closure after SABG [5, 19].

## 7.2. Patients with moderate to severe skeletal discrepancy

Early determination of the eventual need for maxillary osteotomy is a very important decision for the orthodontist.

Extracting lower premolar to correct anterior crossbite and trying to camouflage skeletal discrepancy are not appropriate in growing children. In that case, leveling only the upper arch, finishing with crossbite, and monitoring the growth are the best options. Early surgical options can be considered if needed [5].

## 7.3. Summary of treatment sequencing for mixed dentition stage

Evaluation CBCT–maxillary expansion and/or ortho-tooth movement–fistula closure and alveolar graft–maxillary protraction if needed.

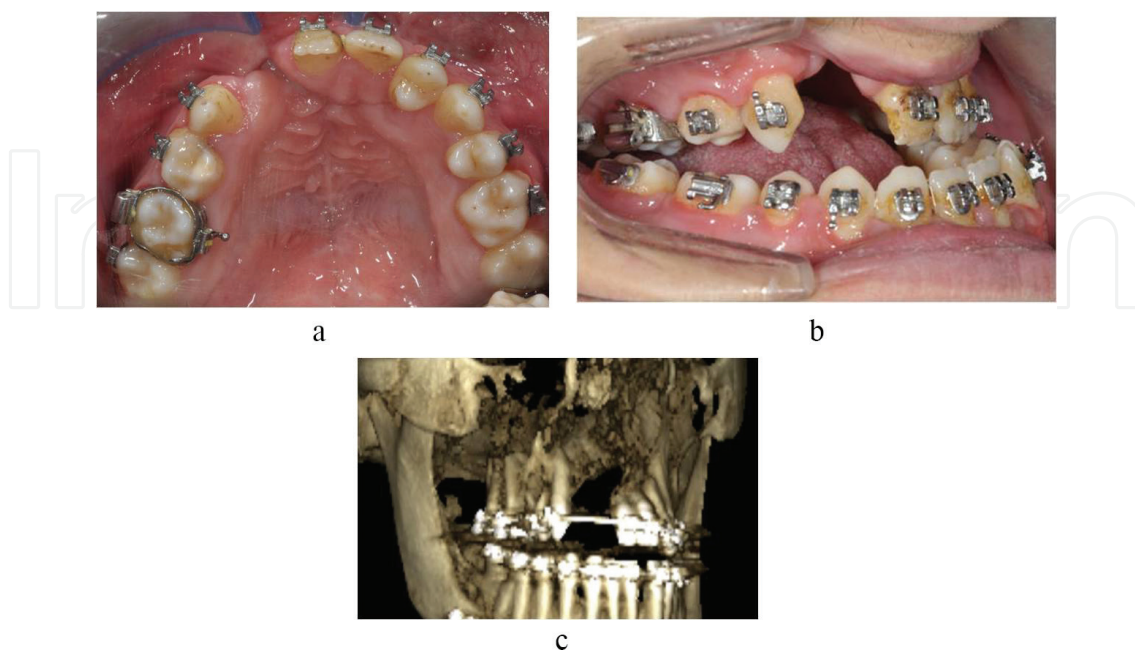
Maxillary protraction protocol: 350–450 gram per side protraction force is adequate 14–15 hours a day for 6–12 months. MP can be started 4–6 weeks after SABG.

Part of this force should be transmitted as intermittent force to the maxillary anterior teeth through oral appliances such as an arch wire and/or lingual arch.

## 7.4. Unfavorable conditions

If maxillary deficiency accompanies with a wide alveolar cleft and/or fistula, it will be more challenging for both orthodontist and surgeon to treat growing patients [54] (**Figure 9**).

Late bone grafting or prolonged orthodontic treatment prior to bone grafting leads to loss of orthodontic control, marked instability of the premaxilla, and difficulty in maintaining



**Figure 9.** Wide alveolar cleft limits both orthodontic treatment and maxillary osteotomy. (a, b) intraoral views of a wide cleft, (c) 3D image of the case.

anteroposterior growth. In patients with BCLP, the unstable premaxilla with the small amount of maxillary bone attached to the vomer is usually incapable of being maintained with good stability without grafting.

When the premaxilla has been effectively grafted, any need to forward the maxilla at a later date can be accomplished by Le Fort osteotomy with a much diminished possibility of relapse [19].

## 8. Summary

The success of the orthodontic treatment and SABG is strongly interrelated. Carefully coordinated orthodontic and surgical involvement is critical for the well-being of the patients with CLP.

## Author details

Aslihan Uzel

Address all correspondence to: [aslihanuzel@gmail.com](mailto:aslihanuzel@gmail.com)

Department of Orthodontics, Faculty of Dentistry, Cukurova University, Adana, Turkey

## References

- [1] WHO. Global strategies to reduce the health-care burden of craniofacial anomalies. In: Report of WHO Meetings on International Collaborative Research on Craniofacial Anomalies. Geneva, Switzerland: Human genetics programme; 2002
- [2] IPDTC Working Group. Prevalence at birth of cleft lip with or without cleft palate: Data from the international perinatal database of typical oral clefts. *The Cleft Palate-Craniofacial Journal*. 2011;**48**(1):66-81
- [3] ACH W, Sell DA, Grunwel P. Management of Cleft Lip and Palate. London, Philadelphia: Whurr Publishers; 2004
- [4] Shaw WC, Semb G. Choosing the best treatment for the child with a cleft. In: ACH W, Sell DA, Grunwel P, editors. Management of Cleft Lip and Palate. London, Philadelphia: Whurr Publishers; 2004. p. 400
- [5] Semb G, Shaw WC. Orthodontics. In: Watson ACH, Sell DA, Grunwel P, editors. Management of Cleft Lip and Palate. London, Philadelphia: Whurr Publishers; 2004. p. 299
- [6] Kreiborg S, Hermann NV, Darvann TA. Characteristics of facial morphology and growth in infants with clefts. In: Berkowitz S, editor. Cleft Lip and Palate. 2nd ed. Germany: Springer-Verlag Berlin Heidelberg; 2006. pp. 25-235

- [7] Semb G. A study of facial growth in patients with unilateral cleft lip and palate treated by the Oslo CLP team. *The Cleft Palate Journal*. 1991;**28**:1-21
- [8] Semb G. A study of facial growth in patients with bilateral cleft lip and palate treated by the Oslo CLP team. *The Cleft Palate Journal*. 1991;**28**:22-39
- [9] Mars M. Facial growth. In: Watson ACH, Sell DA, Grunwel P, editors. *Management of Cleft Lip and Palate*. London, Philadelphia: Whurr Publishers; 2004. pp. 44-67
- [10] Mars M. Alveolar bone grafting. In: Watson ACH, Sell DA, Grunwel P, editors. *Management of Cleft Lip and Palate*. London, Philadelphia: Whurr Publishers; 2004. pp. 326-337
- [11] Semb G. Alveolar bone grafting. *Frontiers of Oral Biology*. 2012;**16**:124-136
- [12] Goudy S, Lott DG, Burton R, Wheeler J, Canady J. Secondary alveolar bone grafting: Outcomes, revisions, and new applications. *The Cleft Palate-Craniofacial Journal*. 2009;**46**:610-612
- [13] Bergland O, Semb G, Abyholm F. Elimination of the residual alveolar cleft by secondary bone grafting and subsequent orthodontic treatment. *The Cleft Palate-Craniofacial Journal*. 1986;**23**:175-205
- [14] Daskalogiannakis J, Ross RB. Effect of alveolar bone grafting in the mixed dentition on maxillary growth in complete unilateral cleft lip and palate patients. *The Cleft Palate-Craniofacial Journal*. 1997;**34**:455-458
- [15] Kindelan JD, Roberts-Harry D. A 5 year post-operative review of secondary alveolar bone grafting in the Yorkshire region. *British Journal of Orthodontics*. 1999;**26**:211-217
- [16] Eppley BL, Sadove AM. Management of alveolar cleft bone grafting-state of art. *The Cleft Palate-Craniofacial Journal*. 2000;**37**:229-233
- [17] Kawakami S, Hura K, Yokozeki M, Takahashi T, Seike T, Nakanishi H, et al. Longitudinal evaluation of secondary bone grafting into the alveolar cleft. *The Cleft Palate-Craniofacial Journal*. 2003;**40**:569-576
- [18] Murthy AS, Lehman JA Jr. Evaluation of alveolar bone grafting: A survey of ACPA teams. *The Cleft Palate-Craniofacial Journal*. 2005;**42**:99-101
- [19] Boyne PJ, Herford AS, Stringer DE. Prevention of relapse following cleftal bone grafting and the future use of BMP cytokines to regenerate osseous clefts without grafting. In: Berkowitz S, editor. *Cleft Lip and Palate*. 2nd ed. Germany: Springer-Verlag Berlin Heidelberg; 2006. p. 587
- [20] Craven C, Cole P, Holier L Jr, Stal S. Ensuring success in alveolar bone grafting: A three-dimensional approach. *The Journal of Craniofacial Surgery*. 2007;**18**:855-859
- [21] Guo J, LI C, Zhang Q, Wu G, Deacon SA, Chen J, et al. Secondary bone grafting for alveolar cleft in children with cleft lip or cleft lip and palate (review). *The Cochrane Collaboration issue*. 2011;**6**:1-44

- [22] Boyne PJ, Sands NR. Secondary bone grafting of residual alveolar and palatal clefts. *Journal of Oral Surgery*. 1972;**30**:87-92
- [23] Boyne PJ, Sands NR. Combined orthodontic-surgical management of residual palato-alveolar cleft defects. *American Journal of Orthodontics*. 1976;**70**:20-37
- [24] Yoshida S, Suga K, Nakano Y, Sakamoto T, Takaki T, Uchiyama T. Postoperative evaluation of grafted bone in alveolar cleft using three-dimensional computed data. *The Cleft Palate-Craniofacial Journal*. 2013;**50**:671-677
- [25] Enemark H, Krantz-Simonsen E, Schramm JE. Secondary bone grafting in unilateral cleft lip palate patients: Indications and treatment procedure. *International Journal of Oral Surgery*. 1985;**14**:2-10
- [26] Feichtinger M, Mossböck R, Karcher H. Assessment of bone resorption after secondary alveolar bone grafting using three-dimensional computed tomography: A three-year study. *The Cleft Palate-Craniofacial Journal*. 2007;**44**:142-148
- [27] Ozawa T, Omura S, Fukuyama E, Matsui Y, Torikai K, Fujita K. Factors influencing secondary alveolar bone grafting in cleft lip and palate patients: Prospective analysis using CT image analyzer. *The Cleft Palate-Craniofacial Journal*. 2007;**44**:286-291
- [28] Sindet-Pedersen S, Enemark H. Comparative study of secondary and late secondary bone-grafting in patients with residual cleft defects. Short-term evaluation. *International Journal of Oral Surgery*. 1985;**14**:389-398
- [29] Tai C-CE, Sutherland IS, McFadden L. Prospective analysis of secondary alveolar bone grafting using computed tomography. *Journal of Oral and Maxillofacial Surgery*. 2000;**58**:1241-1249
- [30] Kalaaji A, Lilja J, Friede H, Elander A. Bone grafting in the mixed and permanent dentition in cleft lip and palate patients: Long-term results and the role of the surgeon's experience. *Journal of Cranio-Maxillo-Facial Surgery*. 1996;**24**:29-35
- [31] Uzel A. Computed tomographic evaluation of secondary alveolar bone grafting in patients with cleft lip and palate. *GÜ Diş Hek Fak Derg*. 2012;**29**:11-18
- [32] Jabbari F, Skoog V, et al. Optimization of dental status improves long-term outcome after alveolar bone grafting in unilateral cleft lip and palate. *The Cleft Palate-Craniofacial Journal*. 2015;**52**(2):210-218
- [33] Liao YF, Huang CS. Presurgical and postsurgical orthodontics are associated with superior secondary alveolar bone grafting outcomes. *Journal of Cranio-Maxillo-Facial Surgery*. 2015;**43**(5):717-723
- [34] Maeda A, Uehara S, Suga M, Nishihara K, Nakamura N, Miyawaki S. Changes in grafted autogenous bone during edgewise treatment in patients with unilateral cleft lip/palate or alveolus. *The Cleft Palate-Craniofacial Journal*. 2014;**51**(5):525-532
- [35] Feichtinger M, Mossböck R, Karcher H. Evaluation of bone volume following bone grafting in patients with unilateral clefts of lip, alveolus and palate using a CT-guided



- three-dimensional navigation system. *Journal of Cranio-Maxillofacial Surgery*. 2006; **34**:144-149
- [36] Hamada Y, Kondoh T, Noguchi K, Lino M, Isono H, Ishii H, et al. Application of limited cone beam computed tomography to clinical assessment of alveolar bone grafting: A preliminary report. *The Cleft Palate-Craniofacial Journal*. 2005; **42**:128-137
- [37] Honma K, Kobayashi T, Nakajima T, Hayasi T. Computed tomographic evaluation of bone formation after secondary bone grafting of alveolar clefts. *Journal of Oral and Maxillofacial Surgery*. 1999; **57**:1209-1213
- [38] Chang CS, Wallace CG, Hsiao YC, Chiu YT, et al. Difference in the surgical outcome of unilateral cleft lip and palate patients with and without pre-alveolar bone graft orthodontic treatment. *Scientific Reports*. 2016; **6**:23597. 1-7
- [39] Rosenstein SE, Ross EL Jr, Dado DV, Vinson B, Alder ME. Comparison of 2-D calculations from periapical and occlusal radiographs versus 3-D calculations from CAT scans in determining bone support for cleft-adjacent teeth following early alveolar bone grafts. *The Cleft Palate-Craniofacial Journal*. 1997; **34**:199-205
- [40] Nagashima H, Sakamoto Y, Ogata H, Miyamoto J, Yazawa M, Kishi K. Evaluation of bone volume after secondary bone grafting in unilateral alveolar cleft using computer-aided engineering. *The Cleft Palate-Craniofacial Journal*. 2014; **51**:665-668
- [41] Feichtinger M, Zemanna W, Mossbock R, Kärcher H. Three-dimensional evaluation of secondary alveolar bone grafting using a 3D-navigation system based on computed tomography: A two-year follow-up. *The British Journal of Oral & Maxillofacial Surgery*. 2008; **46**:278-282
- [42] Shirota T, Kurabayashi H, Ogura H, Seki K, Maki K, Shintani S. Analysis of bone volume using computer simulation system for secondary bone graft in alveolar cleft. *International Journal of Oral and Maxillofacial Surgery*. 2010; **39**:904-908
- [43] Long RE Jr, Semb G, Shaw WC, et al. *Cleft Palate-Craniofacial Journal*. 2000; **37**(6):533-546
- [44] Garib DG, Lauris RCMC, Calil LR, Medeiros Alves AC, Janson G, Almeida AM, et al. Dentoskeletal outcomes of a rapid maxillary expander with differential opening in patients with bilateral cleft lip and palate: A prospective clinical trial. *American Journal of Orthodontics and Dentofacial Orthopedics*. 2016; **150**(4):564-574
- [45] de Almeida AM, Ozawa TO, de Medeiros Alves AC, Janson G, Lauris JRP, Ioshida MSY, et al. Slow versus rapid maxillary expansion in bilateral cleft lip and palate: A CBCT randomized clinical trial. *Clinical Oral Investigations*. 2017; **21**:1789-1799
- [46] Ayub PV, Janson G, Gribel BF, Lara TS, Garib DG. Analysis of the maxillary dental arch after rapid maxillary expansion in patients with unilateral complete cleft lip and palate. *American Journal of Orthodontics and Dentofacial Orthopedics*. 2016; **149**:705-715
- [47] de Medeiros Alves AC, Garib DG, Janson G, de Almeida AM, Calil LR analysis of the dentoalveolar effects of slow and rapid maxillary expansion in complete bilateral cleft lip and palate patients: A randomized clinical trial. *Clinical Oral Investigations*. 2016; **20**:1837-1847

- [48] Holberg C, Holberg N, Schwenzer K, Wichelhaus A, Rudzki-Janson I. Biomechanical analysis of maxillary expansion in CLP patients. *The Angle Orthodontist*. 2007;**77**(2):280-287
- [49] Isaacson RJ, Murphy TD. Some effects of rapid maxillary expansion in cleft lip and palate patients. *The Angle Orthodontist*. 1964;**34**:143-154
- [50] Pan X, Qian Y, Yu J, Wang D, Tang Y, Shen G. Biomechanical effects of rapid palatal expansion on the craniofacial skeleton with cleft palate: A three-dimensional finite element analysis. *The Cleft Palate-Craniofacial Journal*. 2007;**44**:149-154
- [51] Wang D, Cheng L, Wang C, Qian Y, Pan X. Biomechanical analysis of rapid maxillary expansion in the UCLP patient. *Medical Engineering & Physics*. 2009;**31**:409-417
- [52] Gautam P, Zhao L, Patel P. Biomechanical response of the maxillofacial skeleton to transpalatal orthopedic force in a unilateral palatal cleft. *The Angle Orthodontist*. 2011;**81**:503-509
- [53] Façanha AJ, Lara TS, Garib DG, da Silva Filho OG. Transverse effect of Haas and hyrax appliances on the upper dental arch in patients with unilateral complete cleft lip and palate: A comparative study. *Dental Press Journal of Orthodontics*. 2014;**19**:39-45
- [54] Liou EJW, Chen PKT. Management of maxillary deformities in growing cleft patients. In: Berkowitz S, editor. *Cleft Lip and Palate*. 2nd ed. Germany: Springer-Verlag Berlin Heidelberg; 2006. pp. 535-554
- [55] Zhang Y, Jia H, Fu Z, Huang Y, Wang Z, Guo R, et al. Dentoskeletal effects of facemask therapy in skeletal class III cleft patients with or without bone graft. *American Journal of Orthodontics and Dentofacial Orthopedics*. 2018;**153**:542-549
- [56] Yang IH, Chang YI, Kim TW, Ahn SJ, Lim WH, Lee NK, et al. Effects of cleft type, facemask anchorage method, and alveolar bone graft on maxillary protraction: A three-dimensional finite element analysis. *The Cleft Palate-Craniofacial Journal*. 2012;**49**:221-229
- [57] Chen Z, Pan X, Shao Q, Chen Z. Biomechanical effects on maxillary protraction of the craniofacial skeleton with cleft lip and palate after alveolar bone graft. *The Journal of Craniofacial Surgery*. 2013;**24**:446-453
- [58] Maeda-Iino A, Marutani K, Furukawa M, Nakagawa S, Kwon S, Kibe T, et al. Evaluation of maxillary central incisors on the noncleft and cleft sides in patients with unilateral cleft lip and palate—Part 1: Relationship between root length and orthodontic tooth movement. *The Angle Orthodontist*. 2017;**87**:855-862
- [59] Kuijpers-Jagtman AM, Long RE Jr. The influence of surgery and orthodontic treatment on maxillofacial growth and maxillary arch development in patients treated for orofacial clefts. *The Cleft Palate-Craniofacial Journal*. 2000;**37**:1-12
- [60] Susami T, Okayasu M, Inokuchi T, Ohkubo K, Uchino N, Uwatoko K, et al. Maxillary protraction in patients with cleft lip and palate in mixed dentition: Cephalometric evaluation after completion of growth. *The Cleft Palate-Craniofacial Journal*. 2014;**51**(5):514-524

