

We are IntechOpen, the world's leading publisher of Open Access books Built by scientists, for scientists

4,800

Open access books available

122,000

International authors and editors

135M

Downloads

Our authors are among the

154

Countries delivered to

TOP 1%

most cited scientists

12.2%

Contributors from top 500 universities



WEB OF SCIENCE™

Selection of our books indexed in the Book Citation Index
in Web of Science™ Core Collection (BKCI)

Interested in publishing with us?
Contact book.department@intechopen.com

Numbers displayed above are based on latest data collected.
For more information visit www.intechopen.com



Radiation Therapy in Metastatic Neuroblastoma

Meenu Gupta and Anupam Dhasmana

Additional information is available at the end of the chapter

<http://dx.doi.org/10.5772/intechopen.80892>

Abstract

Neuroblastoma is the commonest extracranial solid tumor in children, and metastasis at presentation is seen in more than 50% of cases. The role of radiotherapy as a palliative modality in patients with advanced neuroblastoma provides better symptomatic relief. Palliative radiotherapy dose schedules can be given either in single hypofractionation from 4 to 8 Gy or fractionated radiotherapy that can range from 21 to 30.6 Gy. Dose-response relationship trend has been reported in the palliative setting of bone metastasis. Because of the proximity of tumor to critical organs, serious adverse effects can be avoided with conformal techniques. Although currently there is limited data available, new treatments with particle therapies are undergoing clinical evaluation and may offer new hope for good quality of life in these patients.

Keywords: neuroblastoma, radiotherapy, palliative, metastasis, dose

1. Introduction

Rudolf Virchow, a German physician, was the first person who described neuroblastoma in 1864. Through his research he called the tumors found in the abdomens of children as gliomas. In 1910, James Homer Wright made great efforts to map the origin and development of tumor cells, and he named the tumors neuroblasts, as “blastoma” refers to a collection of immature, undifferentiated cells [1]. His meticulous study showed that these tumors originated from an immature, primitive form of neural cell. The term *neuro* denotes to “nerves,” while *blastoma* denotes to a “cancer that affects immature or developing cells.” Neuroblasts which are formed during embryonic stages develop normally once fetus matures after birth. Sometimes due to uncontrolled cell divisions, they become cancerous, causing neuroblastoma (**Figure 1**).

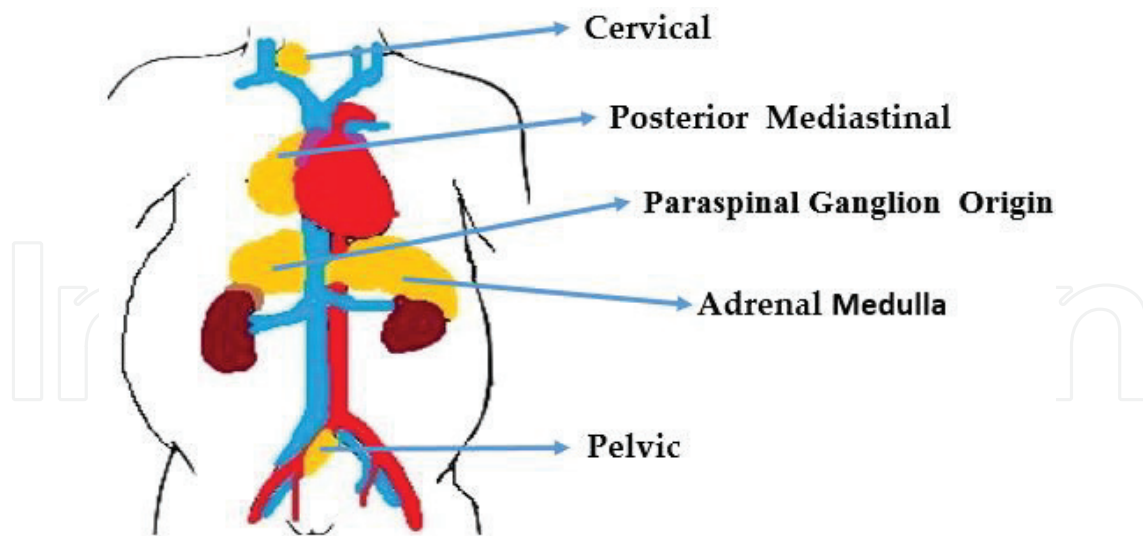


Figure 1. Primordial neural crest cells which develop into the adrenal medulla and sympathetic ganglia during specification and differentiation that lead to formation of neuroblastoma. Adrenal gland is the most common site of origin, but sympathetic nervous system chain from the neck to the pelvis can be other common site of origin.

2. Epidemiology

This set of tumors is considered almost exclusively a disease of pediatric population. Neuroblastoma is the most common solid extracranial tumor, accounting for third most common childhood cancer, after leukemia and brain tumors. Neuroblastoma accounts for approximately 15% of all pediatric cancer fatalities with almost 600 new cases are diagnosed in the United States each year. White race infants displayed more incidence of neuroblastoma than black infants (ratio of 1.7:1 for male and 1.9:1 for females), but little of any racial difference is apparent among older children. Males have higher incidence rate relative to females (male-to-female ratio of 1.3:1) [2]. Neuroblastoma is thought to occur sporadically, with 1–2% of cases are familial [3].

3. Clinical presentation

Patients with neuroblastoma present with a combination of signs and symptoms which are nonspecific and are variable. They depend on site of tumor, size, degree of metastatic spread, and catecholamine secretion.

3.1. Primary disease

Neuroblastomas in the abdomen are the most common form that arises in 65% of cases, approximately 50% arises from the adrenal glands (adrenal neuroblastoma), and one-third are from paravertebral ganglion (extra-adrenal neuroblastoma). Abdominal mass which is asymptomatic may be an incidental finding which is usually detected by parents [4].

Symptoms are abdominal pain or fullness and abdominal mass which is usually firm and fixed. Characteristic nodularity of abdominal neuroblastomas is similar to palpating a *bag of potatoes*

which differentiates it from a nephroblastoma. In some cases, enlarged liver, spleen, and intestinal obstruction may be seen. Rarely, scrotal and lower extremity edema results from the compression of venous and lymphatic drainage of the lower extremities due to size of primary or metastatic abdominal tumors. Renin-mediated hypertension is because of compromised renal vasculature. Epinephrine is rarely released from most neuroblastomas due to deficiency of enzyme necessary for synthesis. So hypertension, tachycardia, flushing, and sweating are uncommon symptoms. Hypertension and opsomyoclonus detected in less than 2% are part of paraneoplastic syndromes [5].

3.2. Metastatic disease

More than 50% of patients present with metastatic disease. Neuroblastoma is associated with lymphatic and hematogenous spread. Common hematogenous metastatic sites are the bone marrow (70.5%), bones (skull, long bones, ribs, vertebrae, 55.7%), liver (29.6%), and skin and rarely the brain or lungs. Thirty-five percent of patients had regional lymph node metastases with localized tumors [6].

3.2.1. Signs and symptoms of metastasis

Long bone involvement causes pain and limping with increasing risk of pathological fractures which is known as Hutchinson syndrome. Periorbital ecchymoses, swelling, and proptosis (raccoon eyes) occur due to sphenoid bone and retrobulbar tissue involvement. Painless proptosis, periorbital edema, and ecchymosis of the upper lid are akin with trauma or child abuse. Irritable and fussy infant needs attention. Bone marrow involvement may result in pancytopenia. Huge involvement of the liver in metastatic condition is common in infants with stage Ms/4S and may cause Pepper syndrome (PS), which induces the respiratory distress, quoted by W. Pepper [7]. PS was recognized as a localized primary tumor and metastatic condition restricted to the skin, bone marrow, and liver in infants. PS is usually known for better prognosis, as it is linked with spontaneous regression of disease. Some infants with stage 4S neuroblastoma die of massive hepatomegaly, respiratory failure, and overwhelming sepsis. Non-tender, bluish, and mobile skin and subcutaneous nodules are because of metastasis to these sites. This is known as "blueberry muffin sign." These nodules become

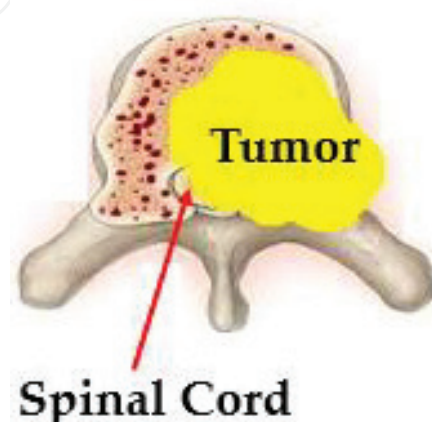


Figure 2. Spinal cord compression by vertebral body metastasis and extension of tumor posteriorly into the epidural space.

prominently red once provoked and thereafter blanch for some minutes, due to release of vasoconstrictive metabolic products. These nodules can be diagnostic of neuroblastoma and should be differentiated from metastatic skin leukemic infiltrates.

Paraspinal tumors in the thoracic, abdominal, and pelvic regions often present with spinal cord compression due to spinal canal invasion through the neural foramina causing symptoms related to compression of nerve roots and spinal cord. There may be subacute or acute paraplegia, bladder or bowel dysfunction, or less commonly radicular pain. Cervical neuroblastoma may present as Horner's syndrome [8] (**Figure 2**).

4. Prognosis according to MYCN amplification status

In infants, MYCN (neuroblastoma-derived, v-myc avian myelocytomatosis viral related oncogene) amplification and unfavorable Shimada histopathology correlated with increased frequencies of bone and intracranial or orbital metastases. In geriatric patients, MYCN amplification is associated with increased risk of intracranial or orbital and lung and liver metastases [6]. MYCN amplification status defines response rate to palliative radiotherapy. Median overall survival time is increased in patients without amplification. A French study showed response rate to palliative RT according to MYCN status was 47.6% in patients with amplified MYCN vs. 75.7% in patient without amplification of MYCN ($p = 0.04$) [6, 9].

5. Investigation

Medical history including family history and physical examination is needed before proceeding for any investigations.

- Laboratory studies: urine examination for catecholamine homovanillic acid (HVA) and vanillylmandelic acid (VMA)
- Imaging: abdominal ultrasound and computed tomography/MRI (calcification on imaging is a favorable sign)
- MIBG (metaiodobenzylguanidine) scan, bone scan, and positron emission tomography (PET) scan
- Biopsies and bilateral bone marrow biopsy

6. Staging

Most commonly used system is the International Neuroblastoma Staging System (INSS) based on clinical, radiographic, and surgical findings (see **Figure 3**).

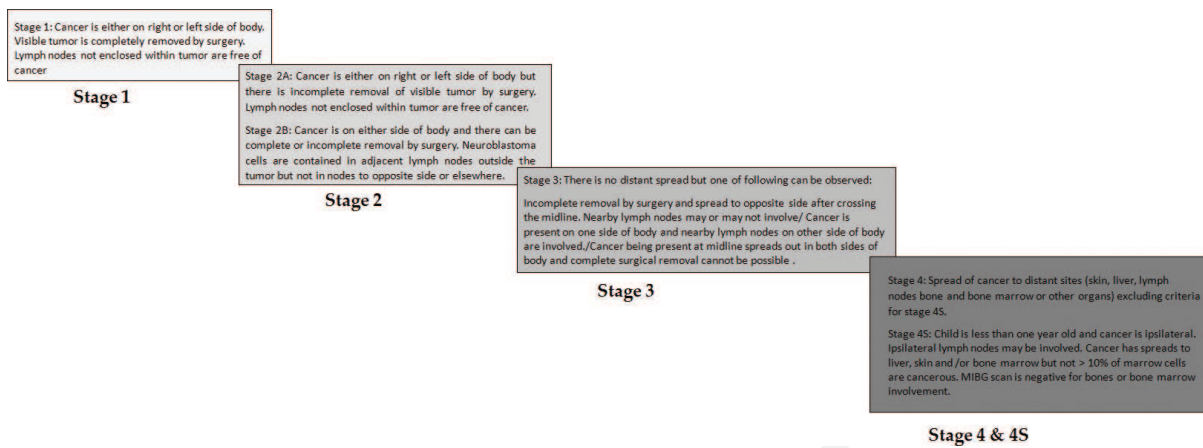


Figure 3. The International Neuroblastoma Staging System (INSS) [10, 11].

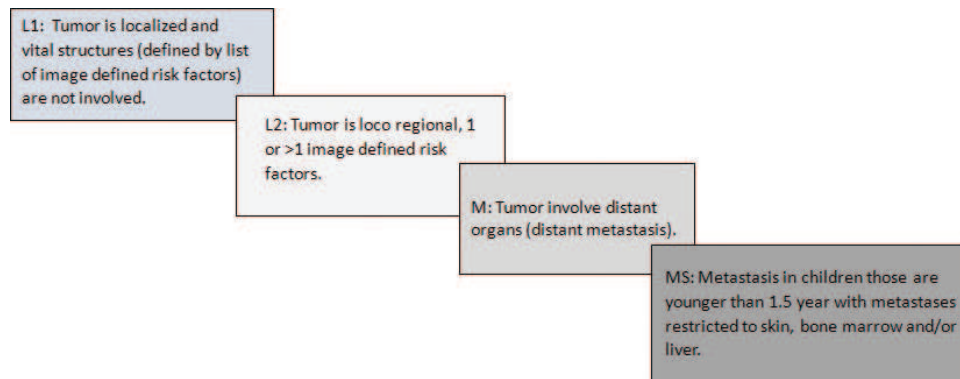


Figure 4. Showing the International Neuroblastoma Staging System (INRGSS) [10, 11].

Later, the International Neuroblastoma Risk Group Staging System (INRGSS) and International Neuroblastoma Risk Group Consensus Pretreatment Classification are released. INRGSS is using pretreatment tumor imaging rather than extent of surgical resection [10]. The INRGSS is explained in **Figure 4**.

7. Management

1. For stage I and II disease, the treatment is complete removal of both the primary tumor and its adjacent involved lymph nodes. Cytoreductive removal of the maximum tumor burden can be done in more advanced stage with expertise of oncosurgeons.
2. Surgical resection is not recommended in stage 4S disease where the neuroblastoma is prone to spontaneous regression.
3. Multidisciplinary approach with surgery, chemotherapy, and irradiation is a key for neuroblastoma treatment depending on patient age, disease stage, response to therapy, and tumor relapse. Local control, metastatic control, and the prevention of relapse are the goal of treatment

7.1. Radiotherapy

In high-risk neuroblastoma, radiation therapy (RT) can be recommended both to the primary site and to sites of metastatic disease as part of consolidative therapy. RT also plays an integral part in the palliation of symptoms from metastatic disease. RT can be used to treat emergencies such as:

- Cord compression
- Tracheal compression
- Expanding retro-orbital tumor
- Imminent bone fracture
- Rapidly enlarging liver

7.1.1. Radiation therapy techniques

7.1.1.1. Three-dimensional conformal radiation therapy

Three-dimensional conformal radiation therapy (3DCRT) is considered the gold standard practice to treat metastases. Conformal dose distribution to the target volume and dose reduction to the surrounding normal tissues is achieved by 3DCRT. In 3DCRT planning, after making the patient comfortable and in reproducible position, adequate immobilization is done by immobilization devices. Three-dimensional anatomic information is obtained on CT simulator or MRI. Three-dimensional conformal plans are generated to deliver high doses within the tumor which is the target and spare the adjacent normal structures at the same time. In the case of vertebral metastasis, radiation portals should include the involved vertebral body (and the soft tissue if involved by the tumor), plus a vertebral body below and above. Patients can be treated in either supine or prone position. If bony metastatic sites are very painful and there is difficulty in prone position, patient can be made comfortable in supine position, and this is also an acceptable reproducible position. A three-dimensional plan composed of one anteroposterior field and two posterior oblique wedged field is illustrated in **Figure 5**. The dose prescribed is 20 Gy at 4 Gy per fraction. Hypofractionated radiotherapy is minimally toxic and time efficient for palliation purpose.

7.1.2. Treatment volumes

Delineation of target volumes is done by CT-based planning. The gross tumor volume of the primary (GTVp) should include post-induction chemotherapy and presurgical disease. For abdominal primaries, the clinical target volume (CTVp) included the para-aortic lymph nodes in addition to the GTVp. Setup uncertainties are reduced by the generation of planning target volume (PTVp) through expansion of the CTVp approximately 0.5–1.0 cm. For metastatic sites irradiation, the GTVm consisted of the residual metastatic tumor (following induction chemotherapy) as defined by MIBG, CT, or MRI. An additional 1.0–1.5 cm CTVm margin for microscopic disease followed by a 0.5–1.0 cm PTVm margin will account for setup uncertainties.

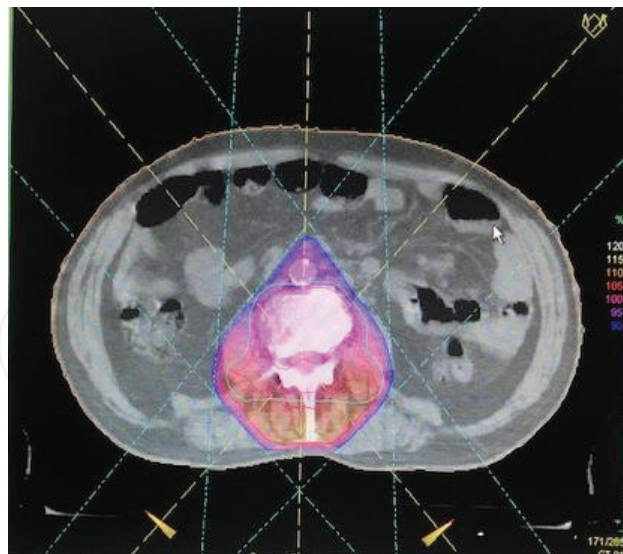


Figure 5. Isodose distribution for three-dimensional conformal radiotherapy (3DCRT) to vertebra.

The 6MV photon energy is delivered by linear accelerator. Wedges and compensators are used to make the dose distribution more uniform. Whole PTV should be included within the 95% isodose surface. Not >10% of the PTV should achieve >110% of the prescription dose (evaluated by DVH) [12].

If dose prescription is 21.6 or 36 Gy, then constraints defined by ANBL0532 AOR are the contralateral kidney in which V12 should be <20% and V8 < 50% and the liver in which V9 should be <50% and <25% to receive 18 Gy. With these conservative doses, Kandula et al. did not observed any hepatic or renal toxicity [12].

When treating a child with intensity-modulated radiotherapy (IMRT) techniques, the theoretical increase in secondary malignancies should be considered. For volumes exposed to low-dose RT, IMRT significantly increased the normal tissue volume receiving 50% or less of the prescribed dose for the volumes exposed to low-dose RT. The decision to irradiate a metastatic site should be made by the treating physician depending upon the evaluation based on post-induction response and posttransplant or preradiotherapy imaging.

7.1.3. Radiotherapy doses

Most of the studies recommend that the median RT dose to the primary site is 21.6 Gy (range 21.0–30.6 Gy). Metastatic sites can be irradiated concurrently with the primary site [13]. The median RT dose recommended to metastatic sites is 21.6 Gy (range 21.0–30.6 Gy) in 12 fractions [12]. Casey et al. reviewed results of RT to metastatic sites as a part of consolidative therapy at a single institution between 2000 and 2015. Among 159 patients, 229 metastases were irradiated. Median dose of 21 Gy (10.5–36 Gy) was given to 90% of irradiated metastasis. Out of 229 irradiated metastasis, 35(15%) had tumor recurrence. These irradiated metastatic sites had 81.3% 5-year local control. There was no difference in local control as far as number of metastatic sites is irradiated. Also the site of metastatic bone versus soft tissue irradiation had no impact on local control, but there was improved overall survival (OS) 59.5% seen in

cases who were controlled at metastatic site than those patients whose disease was persistent, and OS in these patients was 18.3% with $p = 0.0003$ [14].

7.1.3.1. Response rate in palliative radiotherapy

RT is effective in controlling metastatic deposits and in decreasing symptoms due to metastatic disease, with a response rate of 65.2% observed in various studies. Response rates varied with the type of metastases: 84.2% in soft tissue metastases and 63.2% in bone metastases [9].

7.1.4. Bone metastases

There are many established fears about the long-term impact of RT in children like growth disturbances or other skeletal abnormalities after irradiation of the musculoskeletal system. Radiotherapy is performed primarily in these patients with incurable or metastatic disease to relieve pain, definitely control a bone affected from metastases, and prevent pathologic fractures as well as spinal cord compression.

7.1.4.1. Radiotherapy doses for bone metastasis

Dose schedule ranges from 6 to 40 Gy [9]. Fraction regimens can be given from 1.8 to 4 Gy per fraction. The most commonly irradiated sites reported are the lower limb (34%) and spine (29%). An overall response rate of 65–77% is reported in various studies [9, 15, 16]. The Institut Curie, Paris, France, published a series of 23 children with neuroblastoma treated for 38 bony metastatic sites with doses ranging from 6 to 40 Gy. A trend toward improved response with higher doses was seen (**Tables 1 and 2**) [9].

7.1.5. Soft tissue metastasis

In soft tissue metastasis, mediastinum, supraclavicular, cervical, axillary, abdominal, and orbital sites are often involved.

7.1.5.1. Fractionation schedule

The optimal fractionation schedule is still an unresolved issue. Doses can be given as 20 Gy, with a range from 8 to 36 Gy [9]. Various fraction regimens, including 1.5–4 Gy per fraction, can be given in palliative setting. **Figure 6(a and b)** illustrates 3DCRT radiotherapy treatment of olfactory neuroblastoma with extension into maxillary sinus, ethmoid, orbital, and neck nodes metastasis.

Total dose	Response	p Value
<20 Gy	50%	0.088
≥20 Gy	81.2%	

Table 1. Response to radiotherapy according to dose delivered for bone metastases.

Myc status	Good response	P value
Myc amplified	26%	0.70
Myc nonamplified	56.5%	

Table 2. Response to radiotherapy in 23 patients with bone metastasis according to MYCN status.




Figure 6. (a and b) Isodose distribution for three-dimensional conformal radiotherapy (3DCRT) to the nose, orbit, right maxilla (**Figure 6a**), and ipsilateral neck (**Figure 6b**) with wedge for homogenous dose distribution. Blue represents 95% of the isodose line.

7.1.6. Radiotherapy for hepatomegaly (stage 4S)

Massive hepatomegaly causes respiratory distress. To prevent respiratory compromise, the liver is irradiated for symptomatic stage 4S disease. Doses can be given as 450–600 cGy in 2–4 fractions (450 cGy in 3 fractions, 1.5 Gy/fraction) [15]. Target volume can be treated by opposed lateral fields to avoid renal and ovarian exposure.

7.1.6.1. Radiotherapy borders

Radiotherapy box field should be gridded as anterior border 2 cm anterior to the liver, posterior border should be anterior to vertebral body, superior border 2 cm superior to the liver, and inferior border gridded at superior iliac crest to avoid ovarian exposure.

Although very rare but one study reported by Paulino showed survival of one patient stage 4S neuroblastoma with liver metastases who was alive 13 years after hepatic irradiation [15].

7.1.7. Intracranial metastasis of neuroblastoma (IMN)

CNS lesions are defined as leptomeningeal disease or metastatic deposits in the CNS parenchyma. Patients with radiographic evidence of bone involvement or with intracranial extension from the epidural, dura, or skull are not classified with CNS neuroblastoma. Patients who experience a disease recurrence incidence of leptomeningeal or CNS parenchymal disease range from 1 to 16%. The overall incidence rate for newly diagnosed patients is approximately 6.3%.

The incidence rate is >10% in cases who are treated with recent intensive chemotherapy and immunotherapy (N6 and N7, with which the expected cure rate is $\geq 38\%$) [17].

Symptoms of CNS involvement are listed in **Box 1**. Patients with neurologic symptoms should undergo physical examination and further neuroimaging with head/orbit CT and/or MRI scans. MIBG scan is not a reliable indicator of CNS disease as false-negative MIBG scans appear to be common for patients with CNS lesions. This is due to difficulty in discriminating CNS lesions from skull lesions without SPECT images.

- Headaches
- Nausea and emesis
- Seizures
- Motor weakness and paralysis
- Extremity or back pain
- Change in consciousness
- Cranial nerve symptoms
- Fever

Box 1. Clinical features of patients with central nervous system involvement.

7.1.7.1. Genetic associations in brain metastasis

Neuroblastoma tumors that exhibited MYCN amplification correlate with high-risk disease and poor prognosis as they developed CNS recurrence.

7.1.7.2. External beam radiotherapy in CNS metastasis

Prognosis is very poor even if multimodality treatment is given. Multiple brain metastasis can be treated by whole brain radiotherapy. In patients with oligometastasis in the brain, literature suggested that stereotactic radiosurgery (SRS) confers survival benefit [18].

7.1.8. Gamma knife radiosurgery

Nathan C. Rowland et al. described in literature two cases of the application of SRS to high-risk, recurrent IMN. Leksell Gamma Knife model 4C using Leksell GammaPlan 4C treatment planning software was used for radiotherapy. First patient 5-year-old male was treated case of neuroblastoma whose brain magnetic resonance imaging (MRI) showed a 4.0×3.3 cm mass in the right parietal lobe with a small amount of surrounding edema and midline shift. The dose prescription was 27.7 Gy to 47% isodose line. The 18 mm and 14 mm collimating helmets were used in 18 targets. Target volume was 29.2 cc and 100% target coverage was by prescribed isodose line. Conformity index of 1.34 was achieved. Radiological follow-up at 2 and 4 months revealed stable reduction of disease. Patient again received chemotherapy and 21.6 Gy dose given to craniospinal axis. Three-month post-radiotherapy intra-ommaya therapy along with complete surgical excision of mass was given. CNS relapse occurred 15 months after radiotherapy and

patient gave up to disease. The second case was 2 ½-year-old male treated case of neuroblastoma which showed solid mass in the left parieto-occipital lobe measuring 1.8×1.0 cm with a small anterior cystic component. Stereotactic biopsy of the intracranial mass diagnosed the neuroblastoma. A dose of 14 Gy was prescribed to the 50% isodose line and this was administered to five targets. The 18 mm collimating helmet was utilized. Although radiological follow-up at 2 and 3 months showed reduction in size of initial parieto-occipital lesion, 4-month follow-up CT scan showed slight progression in size of metastatic lesion with vasogenic edema. Finally after CNS relapse which occurred 7 ½-month post-radiotherapy, patient died of disease. Stereotactic radiosurgery is an acceptable palliative method in the treatment of IMN [19].

7.1.9. Proton beam therapy

Proton beam therapy (PBT) is a good alternative to photon therapy for pediatric patients where post-radiotherapy side effects are concerned. PBT delivers radiation within a defined radiation track length, with virtually no dose beyond the intended target due to Bragg peak (Figures 7 and 8). Proton beam provides superior target volume coverage and greater dose reductions for normal tissues or organs at risk by a factor of 1.5–3.0 than photon beam. This is due to additional benefit of no exit dose and low entrance dose [20]. Proton beam is considered safe for neuroblastoma pediatric patients with minimal risk of secondary cancer which is slightly higher with intensity-modulated radiotherapy (IMRT) due to peripheral doses. As discussed earlier, doses in path of proton beam are very minimal. There is homogenous dose distribution with large volume of neuroblastoma with less number of ports than IMRT [21].

7.1.10. Procedure

Before treatment, CT images for PBT planning are to be obtained at intervals of 2–5 mm in the treatment position. The interval depends on the age, height, and treatment site of the patient. The gross tumor volume (GTV) is defined as the tumor volume before PBT for a recurrent tumor. The clinical target volume (CTV) is defined as the GTV plus a 1.5 cm margin, and the PTV is defined as the CTV plus a 0.5–0.7 cm margin. Toxicity and treatment effect should be

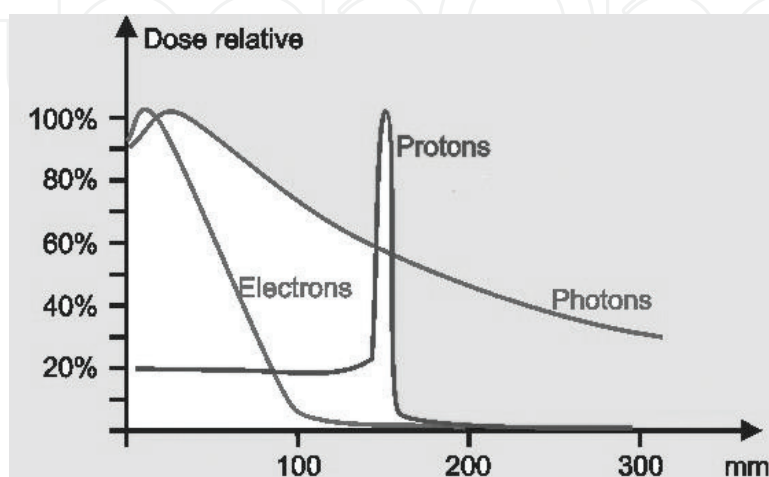


Figure 7. Bragg peak of proton is very sharp.

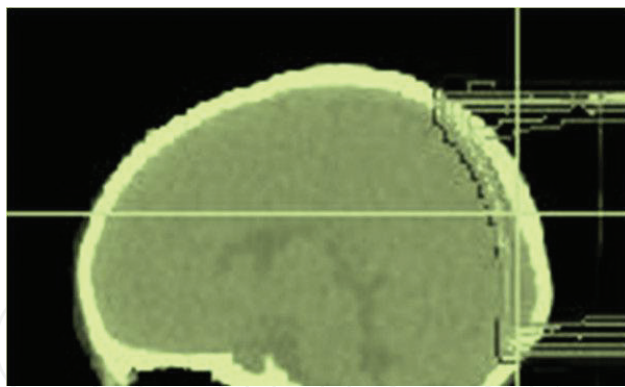


Figure 8. Sharp reduction of dose to brain tissue by proton irradiation.

balanced in determining the CTV. Sedatives can be administered for planning CT and treatment in pediatric patients.

The photon equivalent dose (GyE) = [Physical Dose (Gy)] × [Relative Biological Effectiveness of the proton beam]. This is assigned with a value of 1.1.

The PBT doses usually administered from 19.8 to 45.5 GyE (median: 30.6 GyE) [21].

8. Summary

- Radiotherapy can be considered to primary site or residual MIBG-positive metastatic site.
- Palliative radiotherapy is given on individual case to case basis.
- Abdominal and pelvic sites are commonly treated with AP fields or 3DCRT techniques. Plans should be with the use of multileaf collimators (MLC).
- Dose: 21.6 Gy in 12 fractions (1.8 Gy per fraction).
- GTV (primary tumor volume) = pre-surgery CT/MIGB scans.
- Bone metastatic site = volume positive on MIGB/bone scan after induction chemo.
- PTV = GTV + 2 cm.

Dose constraints for liver normal parenchyma are V9 Gy <50% and V18 Gy <25%; contralateral kidney constraints are V8 Gy <50% and V12 Gy <20%.

Acknowledgements

We gratefully acknowledge Dr Vijay Dhasmana, the Honorable Vice Chancellor of Swami Rama Himalayan University, Dehradun, India, for his support and for providing the necessary

facilities, and we are also thankful to Prof. (Dr) Sunil Saini, Director of Cancer Research Institute, Chairman Research Committee, Himalayan Institute of Medical Sciences, Swami Rama Himalayan University and Prof. (Dr) Mushtaq Ahmad, Dean, Himalayan Institute of Medical Sciences, Swami Rama Himalayan University, Dehradun.

Conflict of interest

We have no conflict of interest with anybody working in the area and among the authors in the book chapter.

Author details

Meenu Gupta^{1*} and Anupam Dhasmana²

*Address all correspondence to: meenugupta.786@rediffmail.com

1 Department of Radiation Oncology, Cancer Research Institute, Swami Rama Himalayan University, Dehradun, India

2 Department of Biosciences, Swami Rama Himalayan University, Dehradun, India

References

- [1] Kelly EB. Neuroblastoma: Cancer in Very Young Children. The 101 Most Unusual Diseases and Disorders. Vol. 1; Nov 2015. p. 253
- [2] Goodman MT, Gurney JG, Smith MA, Olshan AF. Sympathetic nervous system tumors. In: Cancer Incidence and Survival among Children and Adolescents: United States SEER Program, 1975-1995. Bethesda, MD: National Cancer Institute; 1999. p. 35
- [3] Maris JM. Recent advances in neuroblastoma. The New England Journal of Medicine. 2010;**10**:2202-2211. DOI: 10.1056/NEJMra0804577
- [4] Chu CM, Rasalkar DD, Hu YJ, Cheng FWT, Li CK, Chu WCW. Clinical presentations and imaging findings of neuroblastoma beyond abdominal mass and a review of imaging algorithm. The British Journal of Radiology. Jan 2011;**84**(997):81-91
- [5] Hadley L, Lakhoo K. Book Chapter 105. Neuroblastomas: Pediatric Surgery: A Comprehensive Text for Africa. Vol. 2; 2011. p. 610
- [6] DuBois SG, Kalika Y, Lukens JN, Brodeur GM, Seeger RC, Atkinson JB, et al. Metastatic sites in stage IV and IVS neuroblastoma correlate with age, tumor biology, and survival. Journal of Pediatric Hematology/Oncology. May-Jun 1999;**21**(3):181-189

- [7] Pepper WA. A study of congenital sarcoma of the liver and suprarenal with report of a case. *American Journal of the Medical Sciences*; (1827-1924). 1901;**121**:287-299
- [8] Malis J. Clinical Presentation of Neuroblastoma. Chapter 1, IntechOpen. 2013:3-12. <http://dx.doi.org/10.5772/55921>
- [9] Causa L, Hijal T, Michon J, Helfre S. Role of palliative radiotherapy in the management of metastatic pediatric neuroblastoma: A retrospective single-institution study. *International Journal of Radiation Oncology, Biology, Physics*. Jan 1, 2011;**79**(1):214-219
- [10] Monclair T, Brodeur GM, Ambros PF, Brisse HJ, Cecchetto G, Holmes K, et al. The international neuroblastoma risk group (INRG) staging system: An INRG task force report. *Journal of Clinical Oncology*. 10 Jan 2009;**27**(2):298-303
- [11] Katsanis E, Whitesell L. Neuroblastoma. Elsevier BV; 2002
- [12] Kandula S, Prabhu RS, Nanda R, Switchenko JM, Cash T, Qayed M, et al. Outcomes after radiation therapy to metastatic sites in patients with stage 4 neuroblastoma. *Journal of Pediatric Hematology/Oncology*. Apr 2015; **37**(3):175-180
- [13] Mazloom A, Louis CU, Nuchtern J, Kim E, Russell H, Allen-Rhoades W, et al. Radiation therapy to the primary and Postinduction chemotherapy MIBG-avid sites in high-risk neuroblastoma. *International Journal of Radiation Oncology, Biology, Physics*. Nov 15 2014; **90**(4):858-862
- [14] Casey DL, Kushner B, Cheung NK, Modak S, Wolden SL. Radiation therapy to sites of metastatic disease as part of consolidation in high-risk neuroblastoma: Can long-term control be achieved? *International Journal of Radiation Oncology, Biology, Physics*. Oct 1, 2017;**99**(Issue 2, Supplement):E565
- [15] Paulino AC. Palliative radiotherapy in children with neuroblastoma. *Pediatric Hematology and Oncology*. Mar 2003;**20**(2):111-117
- [16] Halperin EC, Cox EB. Radiation therapy in the management of neuroblastoma: The Duke University medical Center experience 1967-1984. *International Journal of Radiation Oncology, Biology, Physics*. 1986;**12**:1829-1837
- [17] Kramer K, Kushner B, Heller G, Nai-Kong VC. Neuroblastoma metastatic to the central nervous system. *Cancer*. April 15, 2001;**91**(8):1510-1518
- [18] Niibe Y, Karasawa K, Nakamura O, Shinoura N, Okamoto K, Yamada R, et al. Survival benefit of stereotactic radiosurgery for metastatic brain tumors in patients with controlled primary lesions and no other distant metastases. *Anticancer Research*. 2003 Sep-Oct;**23**(5b):4157-4159
- [19] Rowland NC, Andrews J, Patel D, LaBorde DV, Nowlan A, George B, et al. Intracranial metastatic neuroblastoma treated with gamma knife stereotactic radiosurgery: Report of two novel cases. *Case Reports in Neurological Medicine*. 2012;**2012**:690548

- [20] Main C, Dandapani M, Pritchard MG, Wilson J. The effectiveness and safety of proton beam radiation therapy in children with malignant central nervous system (CNS) tumours. *Systematic Reviews*. Dec 2016;**5**(1):1-7
- [21] Oshiro Y, Mizumoto M, Okumura T, Sugahara S, Fukushima T, Ishikawa H, et al. Clinical results of proton beam therapy for advanced neuroblastoma. *Radiation Oncology*. 2013;**8**:142

IntechOpen

IntechOpen

