

# We are IntechOpen, the world's leading publisher of Open Access books Built by scientists, for scientists

**4,800**

Open access books available

**122,000**

International authors and editors

**135M**

Downloads

Our authors are among the

**154**

Countries delivered to

**TOP 1%**

most cited scientists

**12.2%**

Contributors from top 500 universities



**WEB OF SCIENCE™**

Selection of our books indexed in the Book Citation Index  
in Web of Science™ Core Collection (BKCI)

Interested in publishing with us?  
Contact [book.department@intechopen.com](mailto:book.department@intechopen.com)

Numbers displayed above are based on latest data collected.

For more information visit [www.intechopen.com](http://www.intechopen.com)



---

## Graft Vascular Disease

---

Lucas Barbieri, Noedir Stolf, Mariane Manso and  
Wallace André Pedro da Silva

Additional information is available at the end of the chapter

<http://dx.doi.org/10.5772/intechopen.79631>

---

### Abstract

Cardiac transplantation (TxC) is considered the first therapeutic option in patients with congestive heart failure, refractory to clinical treatment and without the possibility of conventional surgical treatment. The pathophysiological status, as a consequence of severe cardiomyopathy, is represented by various degrees of systolic and diastolic dysfunction, reflecting low ejection volumes and high diastolic volumes and high filling diastolic pressures, respectively. Patients in this pathophysiological context also present, among other symptoms, neurohormonal alterations of the renin-angiotensin aldosterone system, decreased renal, visceral and splanchnic perfusion, and increased levels of catecholamines. Barnard et al., in 1967, performed the first orthotopic heart transplantation among humans with relative success, Zerbini (1969) being the first to perform it in Brazil. The presence of high rates of graft rejection and infection accounted for small survival and caused great disinterest and abandonment of the technique in the 70's. However, the experience accumulated by the groups that maintained TxC as a treatment, mainly after the introduction of cyclosporin A, first in kidney transplantation in 1978, and in 1980 in TxC, reinvigorated this therapeutic option, allowing the true development and the application of this treatment worldwide.

**Keywords:** nanoemulsions, methotrexate, paclitaxel, heart transplantation, allograftvasculopathy

---

### 1. Introduction

Cardiac transplantation (TxC) is currently considered the first therapeutic option in patients with congestive heart failure, refractory to clinical treatment and without the possibility of conventional surgical treatment [1].

The pathophysiological status, as a consequence of severe cardiomyopathy, is represented by various degrees of systolic and diastolic dysfunction, reflecting low ejection volumes and high diastolic volumes and high filling diastolic pressures, respectively [2].

Patients in this pathophysiological context also present, among other symptoms, neurohormonal alterations of the renin-angiotensin aldosterone system, decreased renal, visceral, and splanchnic perfusion, and increased levels of catecholamines.

The first reference for heart transplantation is from Carrel and Guthrie, who performed the transplantation of a young animal's heart on the neck of an adult animal [3]. It was, however, the work of Lower and Shumway in the 1950s and 1960s that standardized the technique—which provided a long survival for dogs with immunosuppression—and laid the foundations for the success of this surgical treatment. Barnard et al., in 1967, performed the first orthotopic heart transplantation among humans with relative success, Zerbini being the first to perform it in Brazil [4].

The presence of high rates of graft rejection and infection accounted for small survival and caused great disinterest and abandonment of the technique in the 70's [5, 6]. However, the experience accumulated by the groups that maintained TxC as a treatment, mainly after the introduction of cyclosporin A, first in kidney transplantation in 1978, and in 1980 in TxC, reinvigorated this therapeutic option, allowing the true development and the application of this treatment worldwide.

## 2. Type of rejection in cardiac transplantation

### 2.1. Acute cellular rejection

In acute cellular rejection, the antigen-presenting cells directly or indirectly carry the immune message of the graft to the T lymphocyte in a phenomenon known as allorecognition. In this process, the T lymphocyte membrane is bombarded by multiple immune stimuli that activate different effectors, especially calcineurin, which, through interleukin-2, promotes the clonal expansion of T lymphocytes, leading to the production of the following cell clones and enzymes [7, 8].

Auxiliary T lymphocytes (CD4—Helper T lymphocytes) identify antigens on the membrane of cells that have been phagocytosed by macrophages and thereby activate the body's specific immunity;

Cytotoxic T lymphocytes (CD8—Killer T lymphocytes) have the ability to induce lysis of target cells to the case in point the graft cells;

Lymphocytes B are responsible for humoral immunity due to the production of antibodies against foreign antigens, which may give rise to plasma cells (antibody producing cells) or memory cells.

Natural cytotoxic cells (natural killer cells) are granular lymphocytes that destroy target cells by adherence, similar to cytotoxic T lymphocytes (CD8); and the proliferation or rapamycin

target enzyme (mTOR—target of rapamycin) regulates the transcription of messenger RNA, acting on growth, proliferation, motility, survival, and protein synthesis of the lymphocyte.

Immunosuppression is generally based on regimens of induction, maintenance, and treatment of acute rejection, described below:

The induction regimen seeks to achieve and induce graft tolerance. This therapy has been reserved for patients at high risk of rejection or renal failure.

- Maintenance therapy usually consists of a therapy combination of corticosteroids, antiproliferative agents, and calcineurin inhibitors. Combination drug therapy seeks to achieve the activation of T cell lymphocytes at various stages, thus allowing lower doses of each drug.
- Rejection or rescue therapy refers to immunosuppressive therapy used to reverse an episode of acute rejection. Rejection is treated by increasing oral therapy with pulses of oral or intravenous corticosteroids with changes in oral therapy or with the use of monoclonal or polyclonal antilymphocytic agents.

## 2.2. Antibody-mediated rejection

Antibody-mediated rejection can be understood as another form of immune reaction that has a generally more severe course, since circulating preformed antibodies already exists against the alloantigens of the HLA (human leukocyte antigens) graft system. It is a catastrophic situation that leads to acute dysfunction of the organ, and immunosuppressors cannot exert any immediate effect [9–11]. As a preventive measure to curb this event, it has been advocated prior knowledge of the reactivity of the receptor potential to a panel of lymphocytes and the prospective knowledge of cross-lymphocyte testing. In this way, it becomes possible to allocate the donated hearts more rationally to the most suitable recipients.

## 3. Graft vascular disease

Graft vascular disease in cardiac transplantation is an insidious complication, characterized by persistent perivascular inflammation and intimal hyperplasia. It was first described by Thomson, 1969, and emerges as the most important factor affecting long-term survival after transplantation [12].

Graft vascular disease and coronary atherosclerosis are atheromatous diseases with some similarities and differences in macroscopic and microscopic presentation. Both diseases are characterized by increased cell adhesion and leukocyte infiltration, similar environment and cytokine profiles, aberrant extracellular matrix, and early and prolonged accumulation of extracellular and intracellular lipids, as well as migration of smooth muscle cells, endothelial dysfunction, and abnormality in cellular apoptosis.

It represents a type of rejection in which aggression immune to the coronary endothelium occurs persistently and constitutes the main late complication, limiting the survival of the patient and the graft itself in the long term [13].

Although acute graft failure after transplantation has improved over the last two decades, the same cannot be said in the long run where achievements have been less pronounced. Graft vascular disease appears as the main complication after the first year of transplantation and lacks specific and effective therapy. The importance of this entity can be observed in the comparative analysis of the survival curves presented by the International Society for Heart and Lung Transplantation, in which patients who developed vasculopathy had a higher mortality rate than the others.<sup>13</sup> The graft vascular disease is responsible for 17% of the deaths and can be detected as early as the first year after transplantation, reaching in the third year figures in the order of 42% by cinecoronariography and 75% by intravascular ultrasonography [13–17].

The “graft vascular disease” designation has received greater acceptance rather than the other ones—post-transplant atherosclerosis, chronic rejection, accelerated atherosclerosis, graft vasculopathy and others—because it expresses more appropriately the immunological phenomenon that is common to transplants of solid organs [9].

Graft vascular disease is a form of accelerated coronary vasculopathy of immune origin that has not yet been completely clarified, in which nonimmunological factors also take place. However, the most likely entrance door is the endothelial dysfunction, as it allows the aggression of the subintimal layer and stimulates the myointimal proliferation in the wall of the artery. The inflammatory process extends to the entire arterial bed and, occasionally, to the veins, sparing only the recipient’s native vessels [8, 18].

In the initial phase of the lesion, there is a discrete thickness of the intima, with little hyperplastic fibrosis and an increase in extracellular matrix proteins. At this stage, the internal elastic lamina is still intact, and the involvement is limited to the proximal arteries. Subsequently, the thickness proceeds diffusely through the coronary vasculature, with the appearance of plaques of fibroadiposal tissue and gradual deposition of calcium with the future formation of isolated plaques of atheroma [19, 20]. The first intimal changes can be observed as early as the sixth month after transplantation [15, 16, 19].

In the late phase of the disease, it is observed that the thickness of the intima is diffuse, with hyperplasia and concentric fibrosis. A detailed study of the coronary arteries has shown the incorporation of lipids and focal plaques of atheromas interspersed with diffuse arteritis [19, 20]. The arteries thickness occurs by the infiltration of mononuclear inflammatory cells in response to alloimmune stimuli or by infection, and in this last situation, the participation of the cytomegalovirus deserves special attention. In a more advanced stage, the medial layer may be totally or partially replaced by fibrous tissue. Only vessels with little or no muscle layer can be spared [21–23].

The participation of acute rejection is controversial in the development of graft vascular disease [24–26]. Among the nonimmunological factors considered to be at risk for graft vascular disease, we highlight those that may compromise the integrity of the endothelium, as classified below [24–29]:

The donor risk factors encephalic death etiology, age, sex, atherosclerotic disease, and his or her clinical characteristics.

As for the receptor: age, sex, cytomegalovirus infection, diabetes mellitus, hypertension, dyslipidemia, smoking, obesity, and hyperhomocysteinemia. Among these are hyperlipidemia and diabetes mellitus with incidence between 50 and 80%.

The first step in triggering graft vascular disease is the recognition that occurs after reperfusion of the graft, aggravated by postanoxic endothelial dysfunction. The major cytokines involved in the rejection process are interleukin-2 (IL-2), interferon-gamma (IFN- $\gamma$ ), and tumor necrosis factor alpha (TNF- $\alpha$ ). IL-2 induces proliferation and differentiation of T lymphocytes; IFN- $\gamma$  activates the macrophages; and TNF- $\alpha$  alone is cytotoxic to the transplanted heart. In addition, TNF- $\alpha$  increases the expression of MHC class I molecules, whereas IFN- $\gamma$  increases MHC expression of both classes I and II. In general, these cytokines may lead to chronic rejection of the graft. IFN- $\gamma$  and TNF- $\alpha$  induce the production of vascular cell adhesion molecule 1 (VCAM-1), promoting monocyte adhesion and passage through the endothelium and, consequently, vascular graft disease. Explosive encephalic death promotes greater release of cytokines and adhesion molecules and increases the expression of class I and II antigens of the MHC system, promoting an inflammatory reaction exacerbated in the heart of the potential donor and leading to endothelial dysfunction.

The clinical diagnosis of graft vascular disease is difficult, since myocardial ischemia presents a silent course because it is a denervated heart. In the advanced stage, the disease often manifests with signs of heart failure, arrhythmias or even sudden death [14, 21, 30–32].

Coronary angiography may not express the true severity of the graft vascular disease, since the examination allows only the analysis of the internal diameter of the artery and not of the wall [29, 31–33]. It has been proposed to complement the examination with intravascular ultrasonography, which allows to detect the coronary artery wall thickness even in the initial phase of the process. However, this method is not yet widely used, it is invasive and is limited to analysis only of the largest caliber arteries.

Regarding the noninvasive methods, the dobutamine stress echocardiogram has shown advantages as a non-invasive screening test with good sensitivity to select patients with a higher risk of graft vascular disease [13, 34–36].

Among the alternative surgical methods, direct myocardial revascularization or angioplasty deserves special mention, although both present serious restrictions due to the universal distribution of inflammation in the arteries; therefore, the prognosis of the disease is bleak, and few patients can benefit from retransplantation [31, 37, 38].

Ultimately, effective treatment of graft vascular disease in humans is nonexistent, simply limiting the use of prophylactic measures to reduce risk factors. In this way, the treatment of this terrible disease constitutes a fertile field of research but with multiple challenges.

#### **4. Nanotechnology and nanoscience**

Nanotechnology and nanoscience, ranging from 1 to 100 nanometers (nm), focus on materials of atomic size, molecular, and supramolecular, which point to the control and manipulation

of these new materials precisely by configuring atoms and molecules, producing new molecular aggregates and designing self-aggregation systems to create supramolecular devices at the cellular or minor scale.

The nanoscale is prevalent in natural systems, as several functional components of living cells fit into this anthropometric classification, but few drugs or diagnostic, therapeutic, and repair devices have been developed on this scale.

The properties of the nanoscale allow high density of function in small packages to minimize invasiveness and facilitate intelligent therapeutic interventions with increased specificity of release and action, decrease of side effects, and ability to respond to external stimuli and to refer to external receptors.

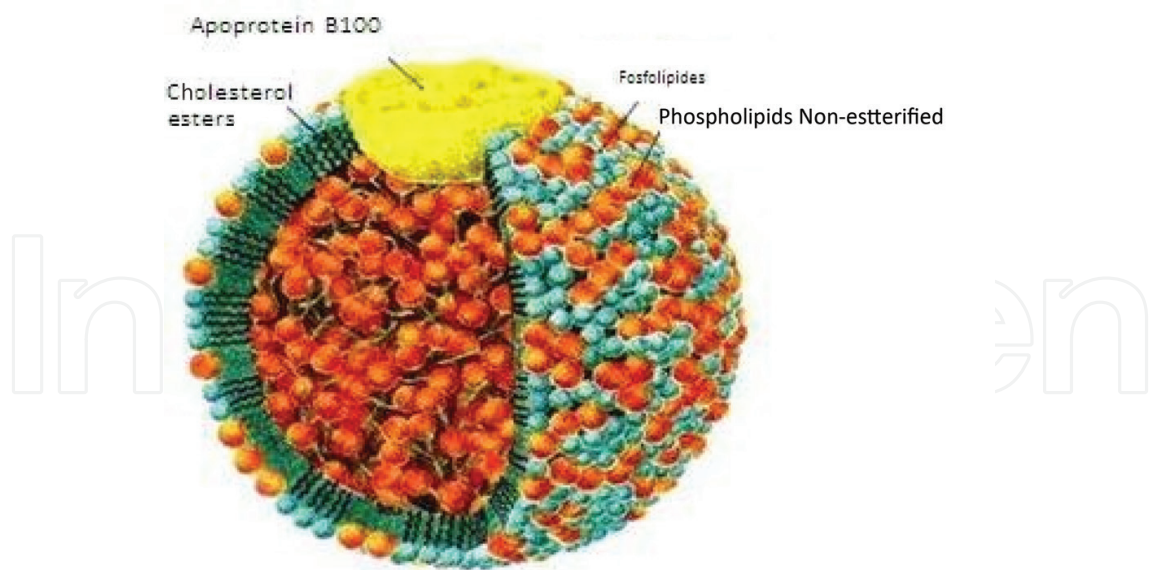
Nanotechnology and nanomedicine are two areas of great growth that have provided new diagnostic and therapeutic opportunities for cardiovascular, pulmonary, hematological, and sleep diseases. In the near future, nanotechnology will play an increasingly significant role in the day-to-day practice of cardiologists, pneumonologists, and hematologists.

The use of nanoparticles in medicine was first performed in the treatment of cancer and progressed rapidly, being well used to address the limitations of conventional drug delivery systems, such as nonspecific and target biodistribution, water solubility, poor oral bioavailability, and low therapeutic indexes.

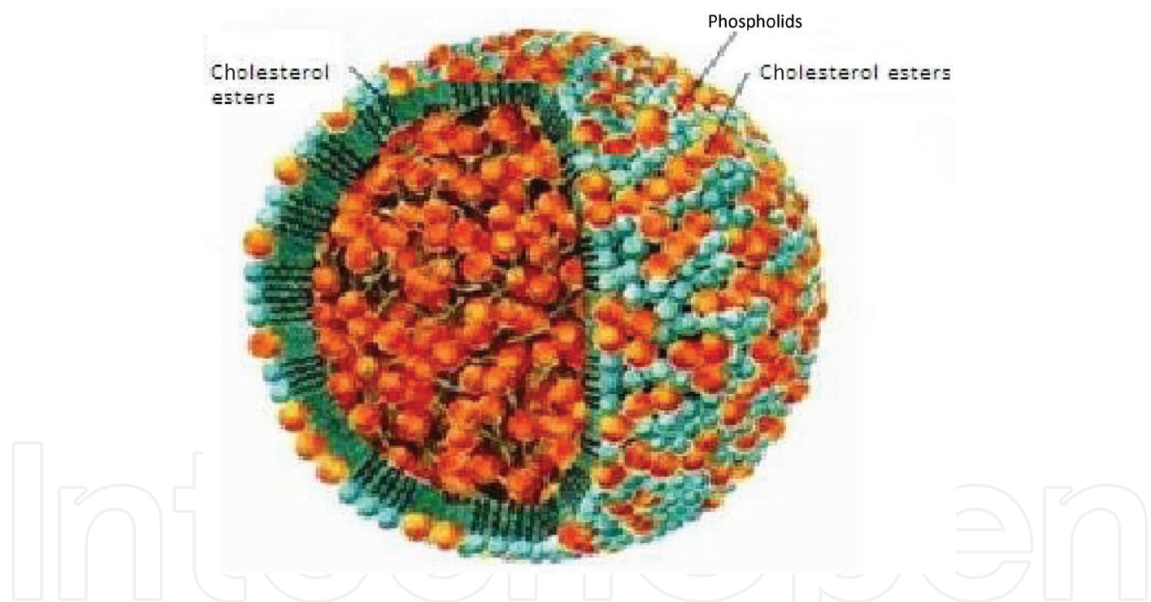
An effective way to achieve drug delivery efficiency will be to reasonably develop nanosystems based on their knowledge of their interactions with the biological environment, target cell population, changes in cellular receptors that occur with disease progression, mechanism and site of drug action, drug retention, multiple drug administration, molecular mechanism, and pathobiology of the disease under consideration [39].

In the area of biomedical nanotechnology, the group led by Maranhão has made pioneering contributions in the world: they described the first system of nanoparticles (non liposomal) produced in the laboratory, capable of directing and concentrating drugs at the drug targeting site for treatment for the treatment of proliferative diseases such as cancer and atherosclerosis [21, 40, 41] (**Pictures 1 and 2**).

A fascinating field of impact applications has been opened with the discovery that LDE, after injection into the circulatory system, is concentrated in the tumor tissues and can be used in the treatment of cancer as a vehicle to direct chemotherapeutics to the neoplastic cells [42]. The cell probably due to the need for greater lipid content required by accelerated proliferation has a marked increase in the expression of LDL receptors. This enables the use of LDE as a vehicle to concentrate neoplastic neoplastic tissue associated with the particles. Chemotherapeutics are thus diverted from the normal tissues of the organism. Thus, it is possible to increase the therapeutic efficacy of these agents and to reduce the side effects that constitute an important limitation to chemotherapy. The initial finding was described in patients with acute myelocytic leukemia, [40, 41] in whom overexpression of receptors reached up to 100-fold. More recently, it has been found that LDE can also be concentrated in tissues where there are nonneoplastic proliferative processes [43]. Then, in rabbits with



**Picture 1.** Structure of low density lipoprotein (LDL). Modified from [www.foodspace.wordpress.com](http://www.foodspace.wordpress.com)



**Picture 2.** Structure of lipid nanoemulsion (LDE). Modified from [www.foodspace.wordpress.com](http://www.foodspace.wordpress.com)

cholesterol-induced diet atherosclerosis, the inflammatory process in atherosclerosis also led to the concentration of nanoemulsion in injured arteries. These findings broadened the range of potential applications of nanoemulsion as a drug vehicle not only in neoplasias but also in atherosclerosis and other chronic inflammatory processes.

The incorporation and stability of drugs within the LDE were optimized with drug modification without loss of pharmacological effect. Thus, with the modification of these drugs, it was possible to proceed with the assembly of a therapeutic arsenal associated with nanoemulsions.



LDE preparations, associated with modified forms of etoposide chemotherapeutic agents, paclitaxel 18 and methotrexate, are ready and efficiently tested in vitro and in vivo. In all cases, comparing these associations with nanoemulsions to the respective commercial preparations, a greater therapeutic action at higher doses was shown in culture of neoplastic cells and models of tumors implanted in animals (Walker's tumor and B-16 melanoma). In clinical trials with carmustine, etoposide, and paclitaxel [18, 20, 42], it was found that in the use of these drugs associated with LDE, even at higher doses than those usually used in the clinic, the toxicity was practically absent.

The results described above then directed us to the application of these nanoemulsions in the treatment of patients with heart transplantation, in which two main problems predominate: rejection of the receptor to the transplanted organ and the SVD. These are two entities that are difficult to manage clinically, which seriously compromise the success of heart transplants and which require new therapeutic solutions. For DVE, in general, there is no conventional treatment, only retransplantation. The inflammatory and proliferative bases of SVD are similar to those of atherosclerotic cardiovascular disease. Thus, the fact that an antiproliferative agent associated with LDE has been effective in promoting the regression of experimental atherosclerosis suggests that it is equally efficient as a therapeutic approach to PVD.

## Author details

Lucas Barbieri<sup>1\*</sup>, Noedir Stolf<sup>1</sup>, Mariane Manso<sup>2</sup> and Wallace André Pedro da Silva<sup>3</sup>

\*Address all correspondence to: lucasbarbieri@usp.br

1 FMUSP-Incor, hospital BP, São Paulo, Brasil

2 FMABC, Santo André, São Paulo, Brasil

3 Hospital Geral de Palmas, Palmas, Brasil

## References

- [1] Korewicky J. Cardiac transplantation is still the method of choice in the treatment of patients with severe heart failure. *Cardiology Journal*. 2009;**16**(6):493-499
- [2] Ramakrishna H, Jaroszewski DE, Arabia FA. Adult cardiac transplantation: A review of perioperative management part-I. *Annals of Cardiac Anaesthesia*. 2009;**12**(1):71-78
- [3] Silva PR. Transplante cardíaco e cardiopulmonar: 100 anos de história e 40 de existência. *Revista Brasileira de Cirurgia Cardiovascular*. 2008;**23**(1):145-152
- [4] Fiorelli AI, Coelho HB, Oliveira Junior JL, Oliveira AS. Insuficiência cardíaca e transplante cardíaco. *Rev. Med. (São Paulo)*. 2008;**87**(2):105-120

- [5] Griep RB, Stinson EB, Clark DA, Shumway NE. A two-year experience with human heart transplantation. *California Medicine*. 1970;**113**(2):17-26
- [6] Rider AK, Copeland JG, Hunt SA, Mason J, Specter MJ, Winkle RA, et al. The status of cardiac transplantation. *Circulation*. 1975;**52**(4):531-539
- [7] Miller LW, Granville DJ, Narula J, Mcmanus BM. Apoptosis in cardiac transplant rejection. *Cardiology Clinics*. 2001;**19**:141-154
- [8] Rogers NJ, Lechler RI. Allorecognition. *American Journal of Transplantation*. 2001;**1**:97-102
- [9] Jukes JP, Jones ND. Immunology in the clinic review series; focus on host responses: Invariant natural killer T cell activation following transplantation. *Clinical and Experimental Immunology*. 2012;**167**:32-39
- [10] Weis M, Von Scheidt W. Coronary artery disease in the transplanted heart. *Annual Review of Medicine*. 2000;**5**(1):81-100
- [11] Diuvestijn AM, Derhaag JG, Van Breda Vriesman PJ. Complement activation by anti-endothelial cell antibodies in MHC-mismatched and MHC-matched heart allograft rejection: Anti-MHC-but not anti non-MHC alloantibodies are effective in complement activation. *Transplant International*. 2000;**13**:363-371
- [12] Lourenço-Filho DD, Maranhão RC, Méndez-Contreras CA, Tavares ER, Freitas FR, Stolf NA. An artificial nanoemulsion carrying paclitaxel decreases the transplant heart vascular disease: A study in a rabbit graft model. *The Journal of Thoracic and Cardiovascular Surgery*. 2011;**141**:1522-1528
- [13] Rora P, Edwards LB, Kucheryavaya AY, Christie JD, Dobbels F, Kirk R, et al. The registry of the International Society for Heart and Lung Transplantation: Thirteenth official pediatric lung and heart-lung transplantation report—2010. *The Journal of Heart and Lung Transplantation*. 2010;**29**:1129-1141
- [14] Fiorelli AI. Contribuição ao estudo da função do ventrículo esquerdo no pós-operatório de transplante cardíaco. Tese (Doutorado). São Paulo: Faculdade de Medicina da Universidade de São Paulo; 1992
- [15] Fiorelli AI, Stolf NAG, Graziosi P, Bocchi EA, Busnardo F, Gaiotto FA, et al. Incidência de coronariopatia após o transplante cardíaco ortotópico. *Revista Brasileira de Cirurgia Cardiovascular*. 1994;**9**:69-80
- [16] Bacal F, Veiga VC, Fiorelli AI, Bellotti G, Bocchi EA, Stolf NA, et al. Analysis of the risk factors for allograft vasculopathy in asymptomatic patients after cardiac transplantation. *Arquivos Brasileiros de Cardiologia*. 2000;**75**:421-428
- [17] Kobashigawa JA, Tobis JM, Starling RC, Tuzcu EM, Smith AL, Valentine HA, et al. Multicenter intravascular ultrasound validation study among heart transplant recipients: Outcomes after five years. *Journal of the American College of Cardiology*. 2005;**45**:1532-1537
- [18] Van Loosdregt J, Van Oosterhout MF, Bruggink AH, Van Wichen DF, Van Kuik J, De Koning E, et al. The chemokine and chemokine receptor profile of infiltrating cells

in the wall of arteries with cardiac allograft vasculopathy is indicative of a memory T-helper 1 response. *Circulation*. 2006;**114**:1599-1607

- [19] Weis M, Von Scheidt W. Coronary artery disease in the transplanted heart. *Annual Review of Medicine*. 2000;**51**:81-100
- [20] Labarrere CA, Nelson DR, Faulk WP. Myocardial fibrin deposits in first month after transplantation predict subsequent coronary artery disease and graft failure in cardiac allograft recipients. *The American Journal of Medicine*. 1998;**105**:207-213
- [21] Aranda JM, Hill J. Cardiac transplant vasculopathy. *Chest*. 2000;**118**:1792-1800
- [22] Wehner J, Morrell CN, Reynolds T, Rodriguez ER, Baldwin WM III. Antibody and complement in transplant vasculopathy. *Circulation Research*. 2007;**100**:191-203
- [23] Billingham ME. Histopathology of graft coronary disease. *The Journal of Heart and Lung Transplantation*. 1992;**11**:S38-S44
- [24] Costanzo-Nordin MR. Cardiac allograft vasculopathy: Relationship with acute cellular rejection and histocompatibility. *The Journal of Heart and Lung Transplantation*. 1992;**11**:S90-S103
- [25] Hammond EH, Yowell RL, Nunoda S, Menlove RL, Renlund DG, Bristow MR, et al. Vascular (humoral) rejection in heart transplantation: Pathologic observations and clinical implications. *The Journal of Heart Transplantation*. 1989;**8**:430-443
- [26] Kemna MS, Valantine HA, Hunt SA. Metabolic risk factors for atherosclerosis in heart transplant recipients. *American Heart Journal*. 1994;**128**:68-72
- [27] Colvin-Adams M, Agnihotri A. Cardiac allograft vasculopathy: Current knowledge and future direction. *Clinical Transplantation*. 2011;**25**:175-184
- [28] Sambiasi NV, Higuchi ML, Nuovo G, Gutierrez PS, Fiorelli AI, Uip DE, et al. Cmv and transplant-related coronary atherosclerosis: An immunohistochemical, in situ hybridization, and polymerase chain reaction in situ study. *Modern Pathology*. 2000;**13**:173-179
- [29] Schmauss D, Weis M. Cardiac allograft vasculopathy: Recent developments. *Circulation*. 2008;**117**:2131-2141
- [30] Rahmani M, Cruz RP, Granville DJ, McManus B. Allograft vasculopathy versus atherosclerosis. *Circulation Research*. 2006;**99**(8):801-815
- [31] Crespo-Leiro MG, Marzoa-Rivas R, Barge-Caballero E, Paniagua-Martín MJ. Prevention and treatment of coronary artery vasculopathy. *Current Opinion in Organ Transplantation*. 2012;**17**:546-550
- [32] Costanzo MR, Naftel DC, Pritzker MR, Heilman JK 3rd, Boehmer JP, Brozena SC, et al. Heart transplant coronary artery disease detected by coronary angiography: A multi-institutional study of preoperative donor and recipient risk factors. *Cardiac Transplant Research Database. Journal of Heart and Lung Transplantation*. 1998;**17**:744-753

- [33] Bocchi EA, Higuchi ML, Bellotti G, Kowabota VS, Assis RV, Stolf N, et al. Acute myocardial infarction with diffuse endarteritis, contraction bands, and distal thrombosis of the coronary arteries in a heart transplant patient. *The Journal of Heart and Lung Transplantation*. 1992;**11**:31-36
- [34] Sade LE, Sezgin A, Eroglu S, Bozbas H, Uluçam M, Müderrisoglu H. Dobutamine stress echocardiography in the assessment of cardiac allograft vasculopathy in asymptomatic recipients. *Transplantation Proceedings*. 2008;**40**:267-270
- [35] Eroglu E, D'hooge J, Sutherland GR, Marciniak A, Thijs D, Droogne W, et al. Quantitative dobutamine stress echocardiography for the early detection of cardiac allograft vasculopathy in heart transplant recipients. *Heart*. 2008;**94**:e3
- [36] Bacal F, Moreira L, Souza G, Rodrigues AC, Fiorelli A, Stolf N, et al. Dobutamine stress echocardiography predicts cardiac events or death in asymptomatic patients long-term after heart transplantation: 4-year prospective evaluation. *The Journal of Heart and Lung Transplantation*. 2004;**(23)**:1238-1244
- [37] Prada-Delgado O, Estévez-Loureiro R, López-Sainz A, Gargallo-Fernández P, Paniagua-Martín MJ, Marzoa-Rivas R, et al. Percutaneous coronary interventions and bypass surgery in patients with cardiac allograft vasculopathy: A single-center experience. *Transplantation Proceedings*. 2012;**44**:2657-2659
- [38] Bocchi EA, Vilas-Boas F, Pedrosa AA, Bacal F, Fiorelli A, Ariê S, et al. Percutaneous transluminal coronary angioplasty after orthotopic heart transplantation. *Arquivos Brasileiros de Cardiologia*. 1994;**62**:177-179
- [39] Suri SS, Fenniri H, Singh B. Nanotechnology-based drug delivery systems. *Journal of Occupational Medicine and Toxicology*. 2007;**2**:16
- [40] Maranhão RC, Garicochea B, Silva EL, Dorlhiac-Llacer P, Pileggi FJC, Chamone DAF. Increased plasma removal of microemulsions resembling the lipid phase of low-density lipoproteins (LDL) in patients with acute myeloid leukemia: A possible new strategy for the treatment of the disease. *Brazilian Journal of Medical and Biological Research*. 1992;**25**:1003-1007
- [41] Maranhão RC, Garicochea B, Silva EL, Dorlhiac-Llacer P, Cadena SM, Coelho IJ, et al. Plasma kinetics and biodistribution of a lipid emulsion resembling low density lipoprotein in patients with acute leukemia. *Cancer Research*. 1994;**54**:4660-4666
- [42] Maranhão RC, Graziani SR, Yamaguchi N, Melo RF, Latrilha MC, Rodrigues DG, et al. Association of carmustine with a lipid emulsion: In vitro, in vivo and preliminary studies in cancer patients. *Cancer Chemotherapy and Pharmacology*. 2002;**49**:487-498
- [43] Naoum FA, Gualandro SF, Latrilha MC, Maranhão RC. Plasma kinetics of a cholesterol-rich microemulsion in subjects with heterozygous Beta-thalassemia. *American Journal of Hematology*. 2004;**77**(4):340-345

