

We are IntechOpen, the world's leading publisher of Open Access books Built by scientists, for scientists

4,800

Open access books available

122,000

International authors and editors

135M

Downloads

Our authors are among the

154

Countries delivered to

TOP 1%

most cited scientists

12.2%

Contributors from top 500 universities



WEB OF SCIENCE™

Selection of our books indexed in the Book Citation Index
in Web of Science™ Core Collection (BKCI)

Interested in publishing with us?
Contact book.department@intechopen.com

Numbers displayed above are based on latest data collected.
For more information visit www.intechopen.com



HIV-Associated Cardiovascular Disease

Hadil Saad and Ntobeko A.B. Ntusi

Additional information is available at the end of the chapter

<http://dx.doi.org/10.5772/intechopen.80483>

Abstract

Currently, 17 million people worldwide are receiving antiretroviral therapy (ART) for human immunodeficiency viral (HIV) infection. There has been a dramatic decline in mortality from HIV infection in the last decade due to increased availability of ART. HIV-associated cardiac failure is on the increase, with more cases of diastolic dysfunction reported in the ART era. HIV increases the risk of CVD, because of longer survival on ART, ongoing subclinical inflammation, traditional cardiovascular risk factors and the complications of chronic ART use. HIV-associated CVD encompasses a wide spectrum of heterogeneous clinical entities, which include diastolic dysfunction, asymptomatic left ventricular dysfunction, cardiomyopathy, myocarditis, heart failure, myocardial fibrosis, myocardial steatosis, pulmonary hypertension, peripheral arterial disease, cerebrovascular disease, infective endocarditis, coronary artery disease and cardiac neoplasms (e.g. Kaposi sarcoma and B-cell immunoblastic lymphoma). In this chapter, we review the complex association of HIV infection and CVD. We describe important recent developments and perspectives based on a systematic analysis of the important advances in this field published in the last decade.

Keywords: HIV, heart failure, cardiovascular disease, inflammation, cardiomyopathy

1. Introduction

By end of 2017, about 37 million people worldwide were living with the human immunodeficiency virus (HIV) [1]. Sub-Saharan Africa (SSA) is the region of the world most severely affected by HIV infection, where 69% of the global population of people living with HIV reside [2]. South Africa has the largest population of HIV infected persons: an adult prevalence of 18.9% and an estimated 7.1 million people living with HIV in 2016 [2]. At the end of 2016, the country had 270,000 new infections while 110,000 South Africans died from AIDS-related illnesses [3].

The connection between HIV infection and cardiovascular disease (CVD) was established quite early in the history of the AIDS pandemic [4]. Early studies in Africans with HIV infection reported that CVD, involving predominantly the myocardium and pericardium, occurred in up to 60% of patients studied [5]. The frequency and pattern of CVD in HIV infected persons is determined by geography, access to combination antiretroviral therapy (ART) and degree of immunosuppression [6]; and several studies have reported the incidence of HIV-associated CVD to be much higher in SSA compared to high-income countries [7, 8].

The risk of CVD in HIV infected individuals is influenced not only by traditional cardiovascular risk factors, genetics and family history, but also by the effect of ART and the effect of HIV itself [9]. Common HIV-associated CVD manifestations include HIV-associated cardiomyopathy (38%), pericardial disease (13%) and pulmonary hypertension (8%) [10]. Approximately 50% of asymptomatic HIV infected persons without known CVD have been found to have diastolic dysfunction on echocardiography [11]. Studies from Africa have found the prevalence of diastolic dysfunction in HIV infected patients to be much higher and to be more severe in patients with AIDS at autopsy, where up to 40% of HIV infected patients were found to have histological evidence of interstitial fibrosis [12]. Despite effective suppression of viral replication, treated HIV infection is associated with persistent inflammation, tissue fibrosis, suboptimal immune recovery and organ damage [13].

2. Heart failure

Heart failure, a regular consequence of cardiac disease, appears to be more common among HIV patients. The global prevalence of heart failure in HIV infected patients in the pre-ART era was between 4 and 5 million cases [13]. Heart failure remains a significant problem in HIV infected patients; the incidence of HIV/AIDS related heart failure is on increase, and current evidence suggests that diastolic, rather than systolic dysfunction is the predominant form of heart failure in the era of ART [14, 15]. Risk factors for systolic dysfunction included elevated high-sensitivity C-reactive protein, tobacco use and prior myocardial infarction (MI); for diastolic dysfunction, risk factors were hypertension and older age [16–18]. In 2242 HIV infected patients on ART from 11 contemporaneous studies, systolic and diastolic dysfunction were in 8.3% and 43.4% of study subject, respectively [16].

2.1. Pathogenesis of HIV-associated heart failure

Several mechanisms may be responsible HIV-associated heart failure, as shown in **Figure 1**, including direct HIV infection, toxicity of HIV components and ART, opportunistic infections and abnormal autoimmune responses to viral infection [19, 20]. HIV associated myocarditis, malignancy, myocardial fibrosis, myocardial steatosis, arterial stiffness, endothelial dysfunction capillary leak syndrome and abnormal coagulation have been considered in the pathogenesis [21–27]. Also, traditional risk factors such as hypertension, diabetes, dyslipidaemia and smoking are more common in HIV infected people [28].

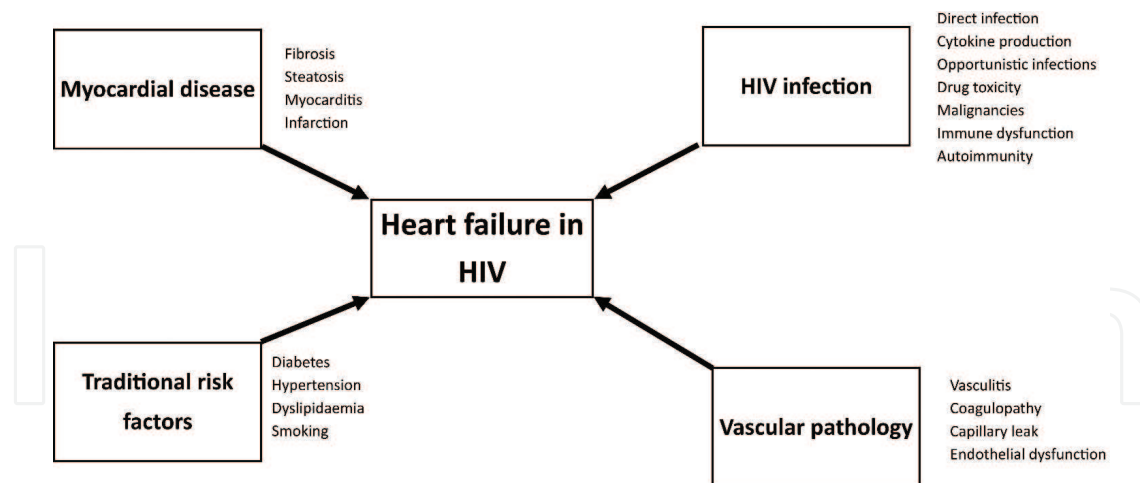


Figure 1. Mechanisms of cardiovascular involvement in HIV infection.

2.2. Myocarditis in HIV

At autopsy, myocarditis was reported in up to 50% of AIDS patients who had not died from cardiac reasons [29]. Direct invasion of cardiomyocytes by HIV has been described, however, the virus affects the myocardial cells in a haphazard fashion with no clear association between viral load and extent of myocardial involvement [30]. The invasion of cardiomyocytes in HIV infection can be through other microorganisms, including fungi (*Candida*, *Histoplasma capsulatum* [31], *Cryptococcus neoformans* [32], *Aspergillus* [32]); viruses (*Herpes simplex* [33], cytomegalovirus [30], Coxsackievirus B3 [34], Parvovirus [33]); bacteria (*Mycobacterium tuberculosis* [35], *Mycobacterium avium* [36]) and parasites (*Toxoplasma gondii* [37]).

Myocarditis with lymphocytic infiltration was reported in 40–52% of patients who died of AIDS in the pre-ART era, although no specific pathogen was reported in most affected patients and clinical presentation was heterogeneous with most remaining asymptomatic despite ongoing subclinical myocardial oedema and inflammation (**Figure 2**) [30]. In different study of HIV-associated cardiomyopathy, endomyocardial biopsy (EMB) of almost cases revealed myocarditis with cardiotropic viral infections [38]. The prevalence of myocarditis and cardiotropic viral genomes in HIV-associated cardiomyopathy, HIV uninfected idiopathic dilated cardiomyopathy (DCM) patients and orthotopic heart transplant recipients was compared using EMB and the immunohistological criteria of the World Heart Federation in 33 patients. Myocarditis was present in 44% of HIV-associated cardiomyopathy, 36% of heart transplant recipients and 25% of participants with idiopathic DCM. Multiple viruses were identified in most cases. Cardiotropic viral infection was present in all HIV-associated cardiomyopathy patients, with HIV-associated cardiomyopathy, heart transplant recipients and idiopathic DCM patients having an average of 2.5, 2.2 and 1.1 viruses per individual, respectively [39].

Viral and opportunistic infections trigger myocarditis in the setting of uncontrolled HIV infection. Direct invasion of cardiac myocytes by cardiotropic viruses, including HIV, leads to a local cytokine release and subsequent infiltration of the myocardium with clonal expansion

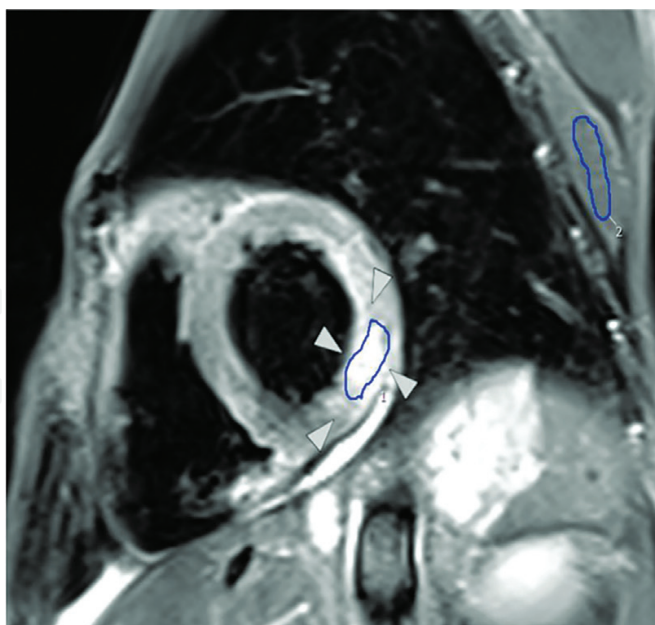


Figure 2. CMR T2-weighted short-tau inversion recovery image showing elevated myocardial: Skeletal muscle signal intensity ratio of the lateral wall (white arrows) in a patient with HIV-associated acute myocarditis. Regions of interest drawn in blue.

of B cells [40]. Reduction in opportunistic infections in patients on ART may be responsible for the impressive drop in myocarditis rates and declining prevalence of HIV-associated cardiomyopathy [15, 41, 42].

2.3. Cardiomyopathy and systolic dysfunction in HIV

The most commonly reported cardiac manifestations of HIV/AIDS in SSA are cardiomyopathy, pericardial disease (related to tuberculosis), and pulmonary hypertension [10]. Initial descriptions of HIV-associated cardiomyopathy have evolved since the 1980s [43]. The pathogenesis of HIV-associated cardiomyopathy is multifactorial and can be direct action of HIV on myocardial tissue or from proteolytic enzymes and cytokine mediators induced by HIV alone or in conjunction with cardiotropic viruses [44]. There has been a marked reduction in incidence of HIV-associated cardiomyopathy after the introduction of ART [15, 26, 41].

HIV-associated cardiomyopathy was showed manifestations of systolic dysfunction associated with a dilated left ventricle and indicated a poor prognosis [4]. The clinical presentation of HIV-associated cardiomyopathy is similar to that of DCM in HIV uninfected persons, and pathological features include dilated cardiac chambers with endocardial fibrosis and mural thrombus (**Figure 3**) [45]. Histologically, it manifests as myocyte hypertrophy and degeneration with increased interstitial and endocardial fibrin collagen and evidence of prior myocarditis [45]. However, more recent reports indicate that HIV-associated cardiomyopathy more commonly manifests with subclinical diastolic dysfunction, particularly in individuals with well controlled HIV infection [46]. Contemporaneous series of significant systolic dysfunction in treated HIV infection have been associated with prior myocardial infarction [47].

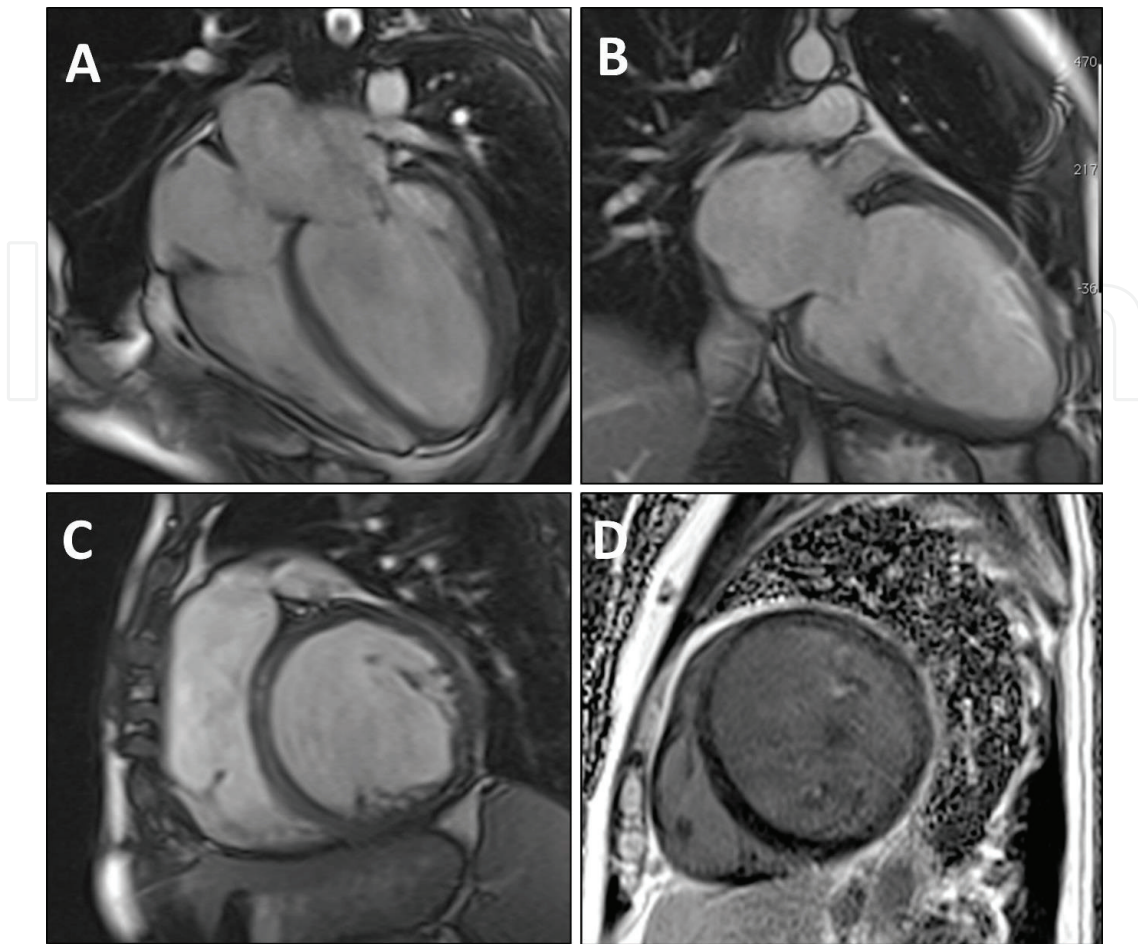


Figure 3. CMR balanced steady state free precession images showing (A) 4-chamber view, (B) 2-chamber view, and (C) a mid-ventricular short-axis image; and (D) late gadolinium enhancement image showing linear mid-wall enhancement in a patient diagnosed with HIV-associated cardiomyopathy.

A phenotype of HIV-associated heart muscle disease with normal chamber size and mildly impaired systolic function increases risk of heart failure, even in the absence of coronary artery disease [48].

2.4. Diastolic dysfunction in HIV

Left ventricular dysfunction associated with HIV is often clinically silent but may progress to symptomatic heart failure. Many studies have reported high incidence of diastolic dysfunction in HIV (Figure 4) [11, 12, 16–18, 22, 23, 47, 49, 50]. In addition, diastolic dysfunction is considered an early marker of coronary artery disease in HIV uninfected patients without cardiac symptoms and preserved systolic function [51]. Diastolic dysfunction in HIV is associated with longer duration of HIV infection, higher body mass index and exposure to zidovudine [52, 53]. In different echocardiographic screening studies of asymptomatic HIV infected individuals, diastolic dysfunction was seen in 26–48% [46, 47, 49, 54]. In these studies, diastolic dysfunction has been associated with elevated body mass, total cholesterol, hypertension, smoking and viral load.

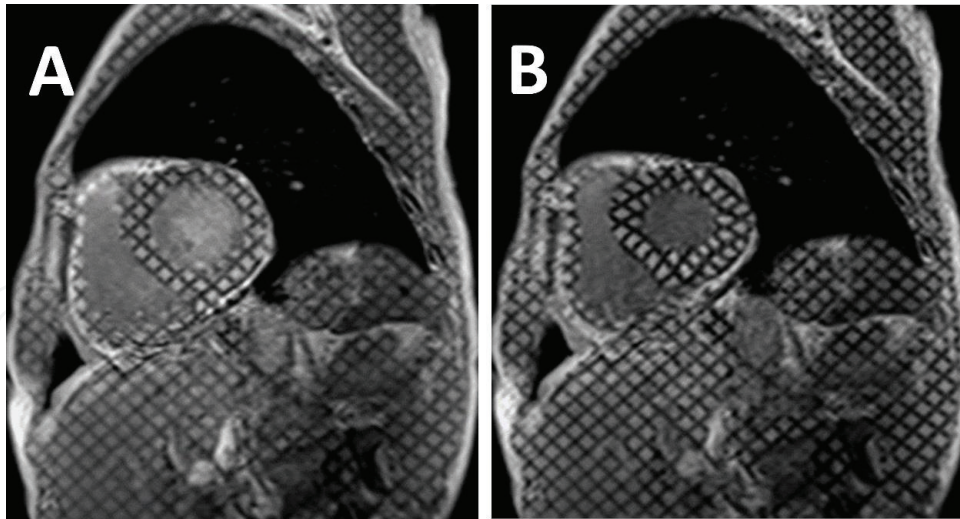


Figure 4. CMR cine tagging using spatial modulation of magnetisation in a short axis image through the mid left ventricle at end-diastole (a) and at end-systole (B) in a patient infected with HIV. Tagging for strain and strain rate imaging in circumferential, longitudinal and radial directions is one of the main techniques for assessment of diastolic dysfunction with CMR.

3. Myocardial fibrosis in HIV

Myocardial fibrosis an important reason of development and progression systolic and diastolic cardiac failure [55]. There is histological evidence of interstitial fibrosis at autopsy in 40% of subjects with HIV infection [29]. CMR studies have demonstrated a prevalence of focal fibrosis in asymptomatic HIV infected individuals of close to 80% (**Figure 5**) [22, 23, 25, 56]. Diffuse myocardial fibrosis estimated by extracellular volume (ECV) calculation was also found to be elevated in HIV infected individuals [56].

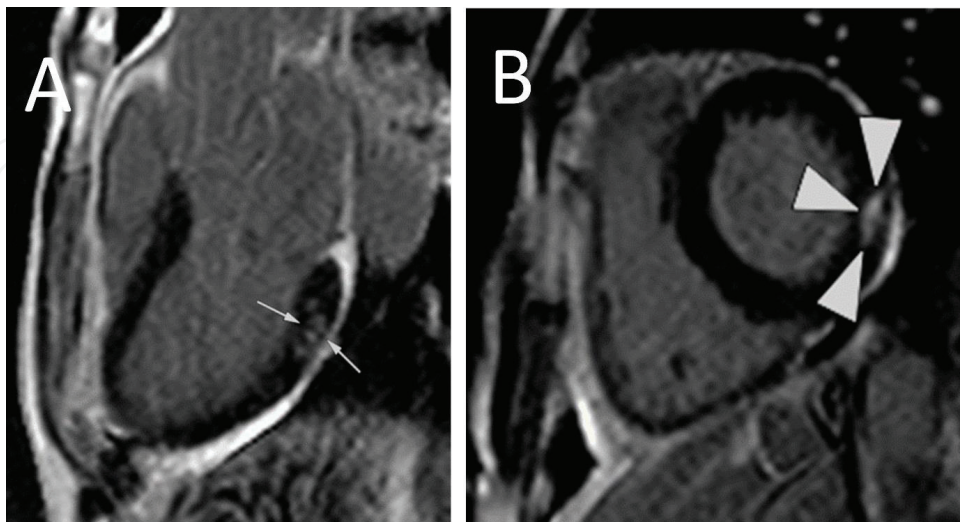


Figure 5. Late post gadolinium images showing mid-wall focal fibrosis in the basal inferolateral wall in (a) 3-chamber view and in the lateral wall in (B) short-axis (white arrows depict the fibrosis).

4. Myocardial steatosis in HIV

Cardiovascular magnetic resonance spectroscopy studies have reported increased incidence of myocardial lipidosis in HIV infected patients receiving ART, even in the absence of cardiovascular symptoms [22, 25]. In these studies, steatosis was associated with elevated serum lipid levels, duration of ART use and impaired strain.

5. HIV-associated pulmonary arterial hypertension

Primary pulmonary arterial hypertension is rare in HIV infected persons, with a prevalence of 0.5% [57]. The use of ART has not impacted on the epidemiology of HIV-associated pulmonary arterial hypertension [58]. There is no correlation between HIV-associated pulmonary arterial hypertension and CD4 cell count, HIV viremia, or duration since HIV diagnosis [47]. The pathogenesis of HIV-associated pulmonary arterial hypertension is poorly understood, with inflammatory and genetic factors both implicated [59]. Pulmonary hypertension in HIV occurs without documented thromboembolic disease, intravenous drug use or pulmonary infections [57, 58]. In a study of 47 patients in the Swiss Cohort Study, patients receiving ART had a significantly decreased median right ventricular systolic pressure over right atrial pressure gradient compared to patients who did not receive ART [60]. ART has also been reported to improve the 6 minute walk test in HIV infected patients with pulmonary hypertension, but with no effect on haemodynamic parameters [61]. Histologically, HIV-associated pulmonary arterial hypertension manifests most commonly as a plexogenic pulmonary arteriopathy, but thrombotic pulmonary arteriopathy and pulmonary veno-occlusive disease also described [62].

6. Pericardial disease in HIV

Pericardial effusion and pericarditis are encountered frequently in patients with HIV infection. The prevalence of symptomatic pericardial effusions before the advent of ART was up to 11% of patients with AIDS [63]. However, in the ART era, the incidence of pericardial effusions in HIV is much less: in a multicentre cohort study of treated HIV patients, only 2 of 872 HIV infected patients had pericardial effusions, neither clinically important [64]. Using CMR with greater resolution, our group has demonstrated the prevalence of small, asymptomatic pericardial effusions to be much higher [23]. While generally nonspecific, pericardial effusions may indicate active inflammation and may be associated with subclinical myocarditis or disseminated tuberculosis, particularly in patients with low CD4 cell counts. In patients with large pericardial effusions, *Mycobacterium tuberculosis* is likely pathogen, especially in tuberculosis endemic regions [65]. In prospective study of patients with a large pericardial effusion, tuberculosis was identified as cause in 85% of cases [66]. In HIV, tuberculous pericarditis is commonly associated with heart failure [67]. HIV is associated with reduced incidence of pericardial constriction [68].

Mortality of pericardial effusions in HIV-infected patients is based on the severity and aetiology of the disease, especially if associated with tuberculosis [69]. We have demonstrated more frequent myocardial fibrosis in HIV-associated pericardial constriction when compared to those without HIV infection [35]. Prednisone does not reduce mortality in tuberculous pericarditis, but has been shown to be associated with reduced hospitalisation and constriction, but with increased risk of malignancies in those with HIV infection [70]. Other causes of pericarditis and pericardial effusions in HIV include HIV itself, bacterial infections, Kaposi's sarcoma and lymphoma [71, 72].

7. Infective endocarditis in HIV

The epidemiology and clinical profile of infective endocarditis in HIV infection are the same as in uninfected individuals [73]. The one setting where HIV is associated with increased risk of infective endocarditis is intravenous drug abuse. *Staphylococcus aureus*, *Streptococcus viridans* and *Salmonella* species are the most common organisms and the tricuspid valve is most involved in intravenous drug users developing infective endocarditis [74, 75]. Nonbacterial (marantic) endocarditis has been described in HIV, usually clinically silent and manifests with large, friable, sterile vegetations on the cardiac valves, which can lead to pulmonary embolization [75]. Patients with low CD4 counts have a poorer prognosis when they develop infective endocarditis [76]. Rates of infective endocarditis have decreased with the advent of ARV therapy [76]. When intravenous drug use is excluded, HIV infection has not been shown to be a risk factor for infective endocarditis [77].

8. Coronary artery disease in HIV

HIV-infected patients are known to be at risk for premature coronary artery disease (CAD) [78]. Different factors related to HIV can lead to development atherosclerosis, including immune dysfunction, proliferation of T-cells, inflammation, endothelial dysfunction, and lipid abnormalities [79, 80]. During atherogenesis, HIV promotes monocyte penetration of the vascular intima to promote secretion of cytokines and expression of endothelial cell adhesion molecules [81]. The process of endothelial dysfunction in HIV patients may be driven by HIV transcription factors [82]. Increased risk of CVD in HIV infected patients is directly related to lower CD4 T-cell counts [83]. Higher number of activated CD8 T-cells is observed in relation to increased rates of coronary artery plaque and carotid artery stiffness [84].

In the early stage of HIV infection both total cholesterol and high-density lipoprotein cholesterol are decreased [85]. Lower levels of apolipoprotein B and smaller low-density lipoprotein cholesterol have been reported in more advanced stages of HIV infection [86]. In addition, deleterious metabolic effects such as dyslipidaemia and insulin resistance after exposure to certain ART treatments have been reported [79]. Recent studies observed that HIV infected

patients presented with large thrombus burden than atherosclerotic plaques suggesting *de novo* arteriothrombosis and thrombophilia as possible causes of CAD events [87, 88].

9. Cardiovascular malignancy in HIV

Cardiac malignancy usually manifests late in HIV disease. Kaposi's sarcoma and cardiac lymphoma are the main malignancies associated with HIV [89]. Non-Hodgkin lymphoma occurs 25–60 times more in HIV infected patients [90]. Cardiac lymphoma can infiltrate the myocardium, the subendocardial layer or be located within pericardial effusion [90]. Clinical features include dyspnoea, right-sided heart failure, heart failure, chest pain and arrhythmia. Presentations range from asymptomatic to cardiac tamponade, myocardial infarction, heart failure or conduction abnormalities [91].

In the pre-ART era, the prevalence of Kaposi's sarcoma from autopsy studies ranged from 12 to 28%, however, cardiac sarcomas were rare [6, 62]. In Kaposi's sarcoma, the coronary arteries are not affected. The incidence of non-Hodgkin lymphoma is not related to the level of immunosuppression and has not changed with ART use [92].

10. Conclusion

Two third of those infected with HIV reside in SSA. Currently, 17 million people globally receive ART for HIV infection. This widespread use of ART has been associated with a dramatic reduction in HIV-related mortality. CVD and heart failure are on the increase in HIV: the mechanisms responsible for HIV-associated CVD are manifold and incompletely understood. Diastolic dysfunction has emerged as the dominant form of HIV-associated CVD in the era of ART. HIV-associated CVD encompasses heterogeneous disorders and has the propensity to involve every segment of the cardiovascular axis. We have described important recent developments and perspectives based on a systematic analysis of the important advances in this field.

Conflicts of interest

None.

Funding

This manuscript is not funded. Dr. Ntusi gratefully acknowledges support from the American Heart Association, the National Institutes of Health/National Heart, Lung, and Blood Institute,

National Research Foundation and the Medical Research Council of South Africa, as well as the Harry Crossley Foundation.

Abbreviations

AIDS	acquired immunodeficiency syndrome
ART	antiretroviral therapy
CAD	coronary artery disease
CD	cluster of differentiation
CMR	cardiovascular magnetic resonance
CVD	cardiovascular disease
DCM	dilated cardiomyopathy
EMB	endomyocardial biopsy
HIV	human immunodeficiency syndrome
SSA	sub-Saharan Africa

Author details

Hadil Saad and Ntobeko A.B. Ntusi*

*Address all correspondence to: ntobeko.ntusi@uct.ac.za

Department of Medicine, Faculty of Health Sciences, University of Cape Town, Cape Town, South Africa

References

- [1] UNAIDS: 2012 Report on the Global AIDS Epidemic. UNAIDS. <http://www.unaids.org>. [Accessed: 07-Feb-2018]
- [2] UNAIDS. Ending AIDS: Progress towards the 90-90-90 Targets. UNAIDS. http://www.unaids.org/en/resources/documents/2017/20170720_Global_AIDS_update_2017. [Accessed: 12-Feb-2018]
- [3] UNAIDS. HIV Prevalence in South Africa. UNAIDS. <http://www.unaids.org/en/region-scountries/countries/southafrica>. [Accessed: 14-Aug-2017]
- [4] Lewis W. Cardiomyopathy in AIDS: A pathophysiological perspective. *Progress in Cardiovascular Diseases*. 2000;**43**(2):151-170

- [5] Hakim JG, Matenga JA, Siyiza S. Myocardial dysfunction in human immunodeficiency virus infection: An echocardiographic study of 157 patients in hospital in Zimbabwe. *Heart*. 1996;**76**(2):161-165
- [6] Ntsekhe M, Mayosi BM. Cardiac manifestations of HIV infection: An African perspective. *Nature Clinical Practice. Cardiovascular Medicine*. 2009;**6**(2):120-127
- [7] Magula N, Mayosi BM. Cardiac involvement in HIV-infected people living in Africa: A review. *Cardiovascular Journal of South Africa*. 2003;**14**(5):231-237
- [8] Ntsekhe M, Hakim J. Impact of human immunodeficiency virus infection on cardiovascular disease in Africa. *Circulation*. 2005;**112**(23):3602
- [9] Friis-Møller N, Thiébaud R, Reiss P, Weber R, Monforte AD, et al. Predicting the risk of cardiovascular disease in HIV-infected patients: The data collection on adverse effects of anti-HIV drugs study. *European Journal of Cardiovascular Prevention and Rehabilitation*. 2010;**17**(5):491-501
- [10] Sliwa K, Carrington MJ, Becker A, Thienemann F, Ntsekhe M, Stewart S. Contribution of the human immunodeficiency virus/acquired immunodeficiency syndrome epidemic to de novo presentations of heart disease in the heart of Soweto study cohort. *European Heart Journal*. 2012;**33**(7):866-874
- [11] Hsue PY, Hunt PW, Ho JE, Farah HH, Schnell A, et al. Impact of HIV infection on diastolic function and left ventricular mass. *Circulation. Heart Failure*. 2010;**3**(1):132-139
- [12] Longo-Mbenza B, Seghers LV, Vita EK, Tonduang K, Bayekula M. Assessment of ventricular diastolic function in AIDS patients from Congo: A Doppler echocardiographic study. *Heart*. 1998;**80**(2):184-189
- [13] Lipshultz SE, Easley KA, Orav EJ, Kaplan S, Starc TJ, et al. Cardiac dysfunction and mortality in HIV-infected children: The prospective P2C2 HIV multicenter study. Pediatric pulmonary and cardiac complications of vertically transmitted HIV infection (P2C2 HIV) study group. *Circulation*. 2000;**102**(13):1542-1548
- [14] Al-Kindi SG, ElAmm C, Ginwalla M, Mehanna E, Zacharias M, et al. Heart failure in patients with human immunodeficiency virus infection: Epidemiology and management disparities. *International Journal of Cardiology*. 2016;**218**:43-46
- [15] Ntusi NAB, Ntsekhe M. Human immunodeficiency virus-associated heart failure in sub-Saharan Africa: Evolution in the epidemiology, pathophysiology, and clinical manifestations in the antiretroviral era. *ESC Heart Failure Journal*. 2016;**3**(3):158-167
- [16] Cerrato E, D'Ascenzo F, Biondi-Zoccai G, Calcagno A, Frea S, et al. Cardiac dysfunction in pauci symptomatic human immunodeficiency virus patients: A meta-analysis in the highly active antiretroviral therapy era. *European Heart Journal*. 2013;**34**(19):1432-1436
- [17] Onur I, Ikitimur B, Oz F, Ekmekci A, Elitok A, et al. Evaluation of human immunodeficiency virus infection-related left ventricular systolic dysfunction by tissue Doppler strain echocardiography. *Echocardiography*. 2014;**31**(10):1199-1204

- [18] Reinsch N, Kahlert P, Esser S, Sundermeyer A, Neuhaus K, et al. Echocardiographic findings and abnormalities in HIV-infected patients: Results from a large, prospective, multicenter HIV-heart study. *American Journal of Cardiovascular Disease*. 2011;**1**(2): 176-184
- [19] Grody WW, Cheng L, Lewis W. Infection of the heart by the human immunodeficiency virus. *The American Journal of Cardiology*. 1990;**66**(2):203-206
- [20] Currie PF, Boon NA. Immunopathogenesis of HIV-related heart muscle disease: Current perspectives. *AIDS*. 2003;**17**(Suppl 1):S21-S28
- [21] Grinspoon S, Mulligan K, Department of Health and Human Services Working Group on the Prevention and Treatment of Wasting and Weight Loss. Weight loss and wasting in patients infected with human immunodeficiency virus. *Clinical Infectious Diseases*. 2003;**36**(Suppl 2):S69-S78
- [22] Holloway CJ, Ntusi N, Suttie J, Mahmood M, Wainwright E, et al. Comprehensive cardiac magnetic resonance imaging and spectroscopy reveal a high burden of myocardial disease in HIV patients. *Circulation*. 2013;**128**(8):814-822
- [23] Ntusi N, O'Dwyer E, Dorrell L, Wainwright E, Piechnik S, et al. HIV-1-related cardiovascular disease is associated with chronic inflammation, frequent pericardial effusions, and probable myocardial edema. *Circulation. Cardiovascular Imaging*. 2016;**9**(3):e004430
- [24] Rider OJ, Asaad M, Ntusi N, Wainwright E, Clutton G, et al. HIV is an independent predictor of aortic stiffness. *Journal of Cardiovascular Magnetic Resonance*. 2014;**16**:57
- [25] Thiara DK, Liu CY, Raman F, Mangat S, Purdy JB, et al. Abnormal myocardial function is related to myocardial steatosis and diffuse myocardial fibrosis in HIV-infected adults. *The Journal of Infectious Diseases*. 2015;**212**(10):1544-1551
- [26] Lipshultz SE, Mas CM, Henkel JM, Franco VI, Fisher SD, Miller TL. HAART to heart: Highly active antiretroviral therapy and the risk of cardiovascular disease in HIV-infected or exposed children and adults. *Expert Review of Anti-Infective Therapy*. 2012;**10**(6):661-674
- [27] Gresele P, Falcinelli E, Sebastiano M, Baldelli F. Endothelial and platelet function alterations in HIV-infected patients. *Thrombosis Research*. 2012;**129**(3):301-308
- [28] Triant VA, Lee H, Hadigan C, Grinspoon SK. Increased acute myocardial infarction rates and cardiovascular risk factors among patients with human immunodeficiency virus disease. *The Journal of Clinical Endocrinology and Metabolism*. 2007;**92**(7):2506-2512
- [29] d'Amati G, di Gioia CR, Gallo P. Pathological findings of HIV-associated cardiovascular disease. *Annals of the New York Academy of Sciences*. 2001;**946**:23-45
- [30] Barbaro G, Di Lorenzo G, Grisorio B, Barbarini G. Cardiac involvement in the acquired immunodeficiency syndrome: A multicenter clinical-pathological study. Gruppo Italiano per lo Studio Cardiologico dei pazienti affetti da AIDS Investigators. *AIDS Research and Human Retroviruses*. 1998;**14**(12):1071-1077

- [31] Hofman P, Drici MD, Gibelin P, Michiels JF, Thyss A. Prevalence of toxoplasma myocarditis in patients with the acquired immunodeficiency syndrome. *British Heart Journal*. 1993;**70**(4):376-381
- [32] Kinney EL, Monsuez JJ, Kitzis M, Vittecoq D. Treatment of AIDS-associated heart disease. *Angiology*. 1989;**40**(11):970-976
- [33] Freedberg RS, Gindea AJ, Dieterich DT, Greene JB. Herpes simplex pericarditis in AIDS. *New York State Journal of Medicine*. 1987;**87**(5):304-306
- [34] Barbaro G, Di Lorenzo G, Soldini M, Giancaspro G, Grisorio B, et al. Intensity of myocardial expression of inducible nitric oxide synthase influences the clinical course of human immunodeficiency virus-associated cardiomyopathy. Gruppo Italiano per lo studio Cardiologico Dei pazienti affetti da AIDS (GISCA). *Circulation*. 1999;**100**(9):933-939
- [35] Ntusi NAB, Palkowski G, Samuels P, Moosa S, Ntsekhe M, et al. Cardiovascular magnetic resonance characterisation of pericardial and myocardial involvement in patients with tuberculous pericardial constriction with and without HIV co-infection. *Journal of Cardiovascular Magnetic Resonance*. 2016;**8**(Suppl 1):Q29
- [36] Barbaro G. Cardiovascular manifestations of HIV infection. *Journal of the Royal Society of Medicine*. 2001;**94**(8):384-390
- [37] Adair OV, Randive N, Krasnow N. Isolated toxoplasma myocarditis in acquired immune deficiency syndrome. *American Heart Journal*. 1989;**118**(4):856-857
- [38] Herskowitz A, Wu TC, Willoughby SB, Vlahov D, Ansari AA, et al. Myocarditis and cardiotropic viral infection associated with severe left ventricular dysfunction in late-stage infection with human immunodeficiency virus. *Journal of the American College of Cardiology*. 1994;**24**(4):1025-1032
- [39] Shaboodien G, Maske C, Wainwright H, Smuts H, Ntsekhe M, et al. Prevalence of myocarditis and cardiotropic virus infection in Africans with HIV-associated cardiomyopathy, idiopathic dilated cardiomyopathy and heart transplant recipients: A pilot study: Cardiovascular topic. *Cardiovascular Journal of Africa*. 2013;**24**(6):218-223
- [40] Magnani JW, Dec GW. Myocarditis: Current trends in diagnosis and treatment. *Circulation*. 2006;**113**(6):876-890
- [41] Pugliese A, Isnardi D, Saini A, Scarabelli T, Raddino R, Torre D. Impact of highly active antiretroviral therapy in HIV-positive patients with cardiac involvement. *The Journal of Infection*. 2000;**40**(3):282-284
- [42] Barbaro G, Barbarini G. Human immunodeficiency virus & cardiovascular risk. *The Indian Journal of Medical Research*. 2011;**134**(6):898-903
- [43] Cohen IS, Anderson DW, Virmani R, Reen BM, Macher AM, et al. Congestive cardiomyopathy in association with the acquired immunodeficiency syndrome. *The New England Journal of Medicine*. 1986;**315**(10):628-630

- [44] Pozzan G, Pagliari C, Tuon FF, Takakura CF, Kauffman MR, Duarte MI. Diffuse-regressive alterations and apoptosis of myocytes: Possible causes of myocardial dysfunction in HIV-related cardiomyopathy. *International Journal of Cardiology*. 2009;**132**(1):90-95
- [45] Barbaro G. Evolution of the involvement of the cardiovascular system in HIV infection. *Advances in Cardiology*. 2003;**40**:15-22
- [46] Remick J, Georgiopoulou V, Marti C, Ofotokun I, Kalogeropoulos A, Lewis W, Butler J. Heart failure in patients with human immunodeficiency virus infection: Epidemiology, pathophysiology, treatment, and future research. *Circulation*. 2014;**129**(17):1781-1789
- [47] Mondy KE, Gottdiener J, Overton ET, Henry K, Bush T, et al. High prevalence of echocardiographic abnormalities among HIV-infected persons in the era of highly active antiretroviral therapy. *Clinical Infectious Diseases*. 2011;**52**(3):378-386
- [48] Butt AA, Chang CC, Kuller L, Goetz MB, Leaf D, et al. Risk of heart failure with human immunodeficiency virus in the absence of prior diagnosis of coronary heart disease. *Archives of Internal Medicine*. 2011;**171**(8):737-743
- [49] Cardoso JS, Moura B, Martins L, Mota-Miranda A, Rocha Gonçalves F, Lecour H. Left ventricular dysfunction in human immunodeficiency virus (HIV)-infected patients. *International Journal of Cardiology*. 1998;**63**(1):37-45
- [50] Schuster I, Thöni GJ, Edérhy S, Walther G, Nottin S, et al. Subclinical cardiac abnormalities in human immunodeficiency virus-infected men receiving antiretroviral therapy. *The American Journal of Cardiology*. 2008;**101**(8):1213-1217
- [51] Nayak G, Ferguson M, Tribble DR, Porter CK, Rapena R, et al. Cardiac diastolic dysfunction is prevalent in HIV-infected patients. *AIDS Patient Care and STDs*. 2009;**23**(4):231-238
- [52] Luo L, Ye Y, Liu Z, Zuo L, Li Y, et al. Assessment of cardiac diastolic dysfunction in HIV-infected people without cardiovascular symptoms in China. *International Journal of STD & AIDS*. 2010;**21**(12):14-18
- [53] Blaylock JM, Byers DK, Gibbs BT, Nayak G, Ferguson M, et al. Longitudinal assessment of cardiac diastolic function in HIV-infected patients. *International Journal of STD & AIDS*. 2012;**23**(2):105-110
- [54] Kelly KM, Tarwater PM, Karper JM, Bedja D, Queen SE, et al. Diastolic dysfunction is associated with myocardial viral load in simian immunodeficiency virus-infected macaques. *AIDS*. 2012;**26**(7):815-823
- [55] Krenning G, Zeisberg EM, Kalluri R. The origin of fibroblasts and mechanism of cardiac fibrosis. *Journal of Cellular Physiology*. 2010;**225**(3):631-637
- [56] Luetkens JA, Doerner J, Schwarze-Zander C, Wasmuth JC, Boesecke C, et al. Cardiac magnetic resonance reveals signs of subclinical myocardial inflammation in asymptomatic HIV-infected patients. *Circulation. Cardiovascular Imaging*. 2016;**9**(3):e004091
- [57] Janda S, Quon BS, Swiston J. HIV and pulmonary arterial hypertension: A systematic review. *HIV Medicine*. 2010;**11**(10):620-634

- [58] Cicalini S, Almodovar S, Grilli E, Flores S. Pulmonary hypertension and human immunodeficiency virus infection: Epidemiology, pathogenesis, and clinical approach. *Clinical Microbiology and Infection*. 2011;**17**(1):25-33
- [59] Pellicelli AM, Palmieri F, Cicalini S, Petrosillo N. Pathogenesis of HIV-related pulmonary hypertension. *Annals of the New York Academy of Sciences*. 2001;**946**:82-94
- [60] Zuber JP, Calmy A, Evison JM, Hasse B, Schiffer V, et al. Pulmonary arterial hypertension related to HIV infection: Improved hemodynamics and survival associated with antiretroviral therapy. *Clinical Infectious Diseases*. 2004;**38**(8):1178-1185
- [61] Degano B, Guillaume M, Savale L, Montani D, Jaïs X, et al. HIV-associated pulmonary arterial hypertension: Survival and prognostic factors in the modern therapeutic era. *AIDS*. 2010;**24**(1):67-75
- [62] Klatt E. Cardiovascular pathology in AIDS. In: Barbardo G, editor. *HIV and the Cardiovascular System*. Adv Cardiol. Vol. 40. Basel: Karger; 2003. pp. 21-48
- [63] Heidenreich PA, Eisenberg MJ, Kee LL, Somelofski CA, Hollander H, Schiller NB, et al. Pericardial effusion in AIDS. Incidence and survival. *Circulation*. 1995;**92**(11):3229-3234
- [64] Lind A, Reinsch N, Neuhaus K, Esser S, Brockmeyer NH, et al. Pericardial effusion of HIV-infected patients? Results of a prospective multicenter cohort study in the era of antiretroviral therapy. *European Journal of Medical Research*. 2011;**16**(11):480-483
- [65] Mayosi BM, Wiysonge CS, Ntsekhe M, Volmink JA, Gumedze F, et al. Clinical characteristics and initial management of patients with tuberculous pericarditis in the HIV era: The investigation of the Management of Pericarditis in Africa (IMPI Africa) registry. *BMC Infectious Diseases*. 2006;**6**:2
- [66] Reuter H, Burgess LJ, Doubell AF. Epidemiology of pericardial effusions at a large academic hospital in South Africa. *Epidemiology and Infection*. 2005;**133**(3):393-399
- [67] Syed FF, Ntsekhe M, Gumedze F, Badri M, Mayosi BM. Myopericarditis in tuberculous pericardial effusion: Prevalence, predictors and outcome. *Heart*. 2014;**100**(2):135-139
- [68] Ntsekhe M, Wiysonge CS, Gumedze F, Maartens G, Commerford PJ, et al. HIV infection is associated with a lower incidence of constriction in presumed tuberculous pericarditis: A prospective observational study. *PLoS One*. 2008;**3**(6):e2253
- [69] Mayosi BM, Wiysonge CS, Ntsekhe M, Gumedze F, Volmink JA, et al. Mortality in patients treated for tuberculous pericarditis in sub-Saharan Africa. *South African Medical Journal*. 2008;**98**(1):36-40
- [70] Mayosi BM, Ntsekhe M, Bosch J, Pandie S, Jung H, et al. Prednisolone and *Mycobacterium indicus pranii* in tuberculous pericarditis. *The New England Journal of Medicine*. 2014;**371**(12):1121-1130
- [71] Gowda RM, Khan IA, Mehta NJ, Gowda MR, Sacchi TJ, Vasavada BC. Cardiac tamponade in patients with human immunodeficiency virus disease. *Angiology*. 2003;**54**(4):469-474

- [72] Stotka JL, Good CB, Downer WR, Kapoor WN. Pericardial effusion and Tamponade due to Kaposi's sarcoma in acquired immunodeficiency syndrome. *Chest*. 1989;**95**(6):1359-1361
- [73] Vasudev R, Shah P, Bikkina M, Shamoon F. Infective endocarditis in HIV. *International Journal of Cardiology*. 2016;**214**:216-217
- [74] Fisher SD, Kanda BS, Miller TL, Lipshultz SE. Cardiovascular disease and therapeutic drug-related cardiovascular consequences in HIV-infected patients. *American Journal of Cardiovascular Drugs*. 2011;**11**(6):383-394
- [75] Miró JM, del Río A, Mestres CA. Infective endocarditis and cardiac surgery in intravenous drug abusers and HIV-1 infected patients. *Cardiology Clinics*. 2003;**21**(2):167-184
- [76] Gebo KA, Burkey MD, Lucas GM, Moore RD, Wilson LE. Incidence of, risk factors for, clinical presentation, and 1-year outcomes of infective endocarditis in an urban HIV cohort. *Journal of Acquired Immune Deficiency Syndromes*. 2006;**43**(4):426-432
- [77] Sudano I, Spieker LE, Noll G, Corti R, Weber R, Lüscher TF. Cardiovascular disease in HIV infection. *American Heart Journal*. 2006;**151**(6):1147-1155
- [78] d'Arminio A, Sabin CA, Phillips AN, Reiss P, Weber R, et al. Cardio- and cerebrovascular events in HIV-infected persons. *AIDS*. 2004;**18**(13):1811-1817
- [79] DAD Study Group, Friis-Møller N, Reiss P, Sabin CA, Weber R, et al. Class of antiretroviral drugs and the risk of myocardial infarction. *The New England Journal of Medicine*. 2007;**356**(17):1723-1735
- [80] Hazenberg MD, Stuart JW, Otto SA, Borleffs JC, Boucher CA, et al. T-cell division in human immunodeficiency virus (HIV)-1 infection is mainly due to immune activation: A longitudinal analysis in patients before and during highly active antiretroviral therapy (HAART). *Blood*. 2000;**95**(1):249-255
- [81] Park IW, Wang JF, Groopman JE. HIV-1 tat promotes monocyte chemoattractant protein-1 secretion followed by transmigration of monocytes. *Blood*. 2001;**97**(2):352-358
- [82] Kaplan RC, Sinclair E, Landay AL, Lurain N, Sharrett AR, et al. T cell activation predicts carotid artery stiffness among HIV-infected women. *Atherosclerosis*. 2011;**217**(1):207-213
- [83] Hsue PY, Deeks SG, Hunt PW. Immunologic basis of cardiovascular disease in HIV-infected adults. *The Journal of Infectious Diseases*. 2012;**205**(Suppl 3):S375-S382
- [84] Kaplan RC, Sinclair E, Landay AL, Lurain N, Sharrett AR, et al. T cell activation and senescence predict subclinical carotid artery disease in HIV-infected women. *The Journal of Infectious Diseases*. 2011;**203**(4):452-463
- [85] Calza L, Manfredi R, Verucchi G. Myocardial infarction risk in HIV-infected patients: Epidemiology, pathogenesis, and clinical management. *AIDS*. 2010;**24**(6):789-802
- [86] Riddler SA, Smit E, Cole SR, Li R, Chmiel JS, et al. Impact of HIV infection and HAART on serum lipids in men. *JAMA*. 2003;**289**(22):2978-2982

- [87] Becker AC, Jacobson B, Singh S, Sliwa K, Stewart S, et al. The thrombotic profile of treatment-naïve HIV-positive black south Africans with acute coronary syndromes. *Clinical and Applied Thrombosis/Hemostasis*. 2011;**17**(3):264-272
- [88] Becker AC, Sliwa K, Stewart S, Libhaber E, Essop AR, et al. Acute coronary syndromes in treatment-naïve black south Africans with human immunodeficiency virus infection. *Journal of Interventional Cardiology*. 2010;**23**(1):70-77
- [89] Ioachim HL, Cooper MC, Hellman GC. Lymphomas in men at high risk for acquired immune deficiency syndrome (AIDS). A study of 21 cases. *Cancer*. 1985;**56**(12):2831-2842
- [90] Nishikawa Y, Akaishi M, Handa S, Nakamura Y, Hori S, Ogata K, Hosoda Y. A case of malignant lymphoma simulating acute myocardial infarction. *Cardiology*. 1991;**78**:357-362
- [91] Llitjos JF, Redheuil A, Puymirat E, Vedrenne G, Danchin N. AIDS-related primary cardiac lymphoma with right-sided heart failure and high-grade AV block: Insights from magnetic resonance imaging. *Annales de cardiologie et d'angéiologie (Paris)*. 2014;**63**(2): 99-101
- [92] Zoufaly A, Stellbrink HJ, Heiden MA, Kollan C, Hoffmann C, van Lunzen J, Hamouda O, ClinSurv Study Group. Cumulative HIV viremia during highly active antiretroviral therapy is a strong predictor of AIDS-related lymphoma. *The Journal of Infectious Diseases*. 2009;**200**(1):79-87

