

# We are IntechOpen, the world's leading publisher of Open Access books Built by scientists, for scientists

4,800

Open access books available

122,000

International authors and editors

135M

Downloads

Our authors are among the

154

Countries delivered to

TOP 1%

most cited scientists

12.2%

Contributors from top 500 universities



WEB OF SCIENCE™

Selection of our books indexed in the Book Citation Index  
in Web of Science™ Core Collection (BKCI)

Interested in publishing with us?  
Contact [book.department@intechopen.com](mailto:book.department@intechopen.com)

Numbers displayed above are based on latest data collected.  
For more information visit [www.intechopen.com](http://www.intechopen.com)



---

## Patent Arterial Duct

---

Ageliki A. Karatza and Xenophon Sinopidis

Additional information is available at the end of the chapter

<http://dx.doi.org/10.5772/intechopen.79956>

---

### Abstract

The arterial duct is a short vessel that connects the junction of the main and left pulmonary artery to the descending aorta just distal to the left subclavian artery. In foetal life, it is an essential vascular structure that allows oxygenated blood to bypass the pulmonary circulation, since the lungs are not involved in oxygenation and enter systemic circulation. Persistent patency of the arterial duct after 3 months of age in term infants is a common form of congenital cardiovascular abnormality representing 5–10% of all congenital heart defects. Also, persistent patency of the arterial duct is a common problem in very premature sick neonates, which is associated with significant morbidity and mortality and is attributed to immaturity of the duct and associated co-morbidities in this population.

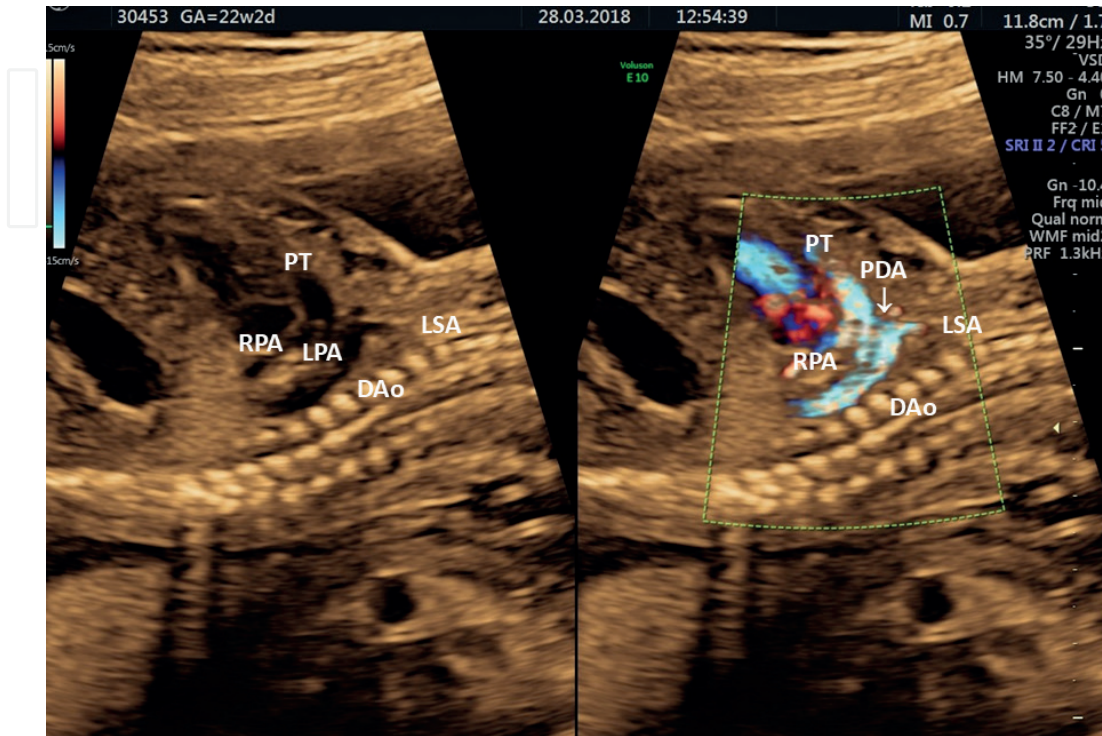
**Keywords:** patent arterial duct, congenital heart disease, premature neonate, ibuprofen, indomethacin, transcatheter closure, surgical ligation, Eisenmenger syndrome, foetal cardiovascular physiology, transitional circulation

---

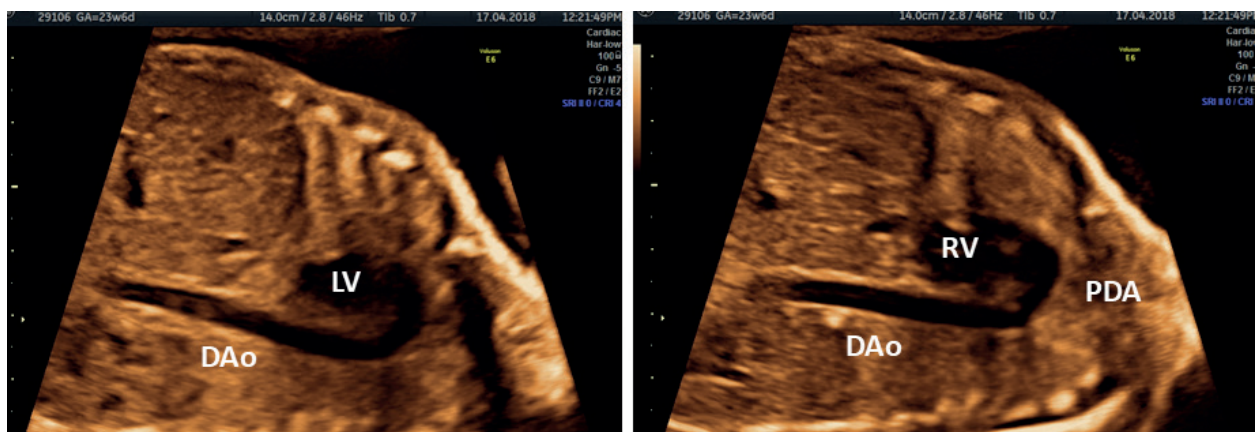
### 1. Introduction

The arterial duct is a short vessel that derives from the distal portion of the left sixth embryonic arch and connects the junction of the main and left pulmonary artery to the descending aorta just distal to the left subclavian artery (**Figures 1–3**) [1–3]. This process is complete by the eighth week of foetal life and is necessary for normal foetal circulation and intrauterine survival [1]. During development, the arterial duct allows oxygenated blood to bypass the pulmonary circulation, since the lungs are not involved in oxygenation and enter directly into systemic circulation. After birth, the arterial duct closes via a complex biphasic process and becomes the ‘ligamentum arteriosum’ [4]. The arterial duct closes spontaneously in about

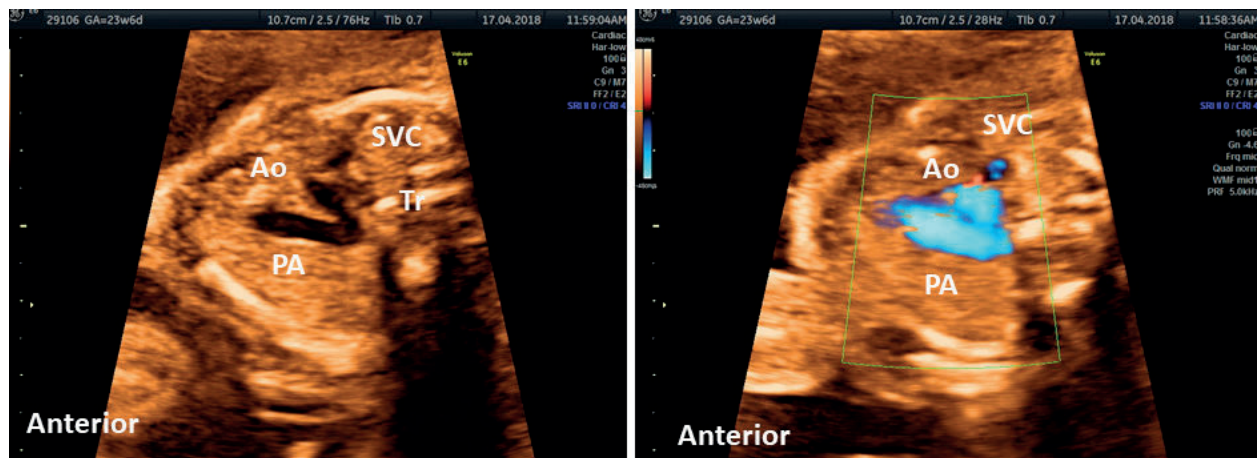
90% of full-term infants during the first 48 hours of life [5]. Persistent patency beyond the third month of life in term infants is a common form of congenital heart disease with an incidence of 1–2000 representing 5–10% of all congenital heart anomalies [1–3].



**Figure 1.** Saggital view of the foetal heart showing the pulmonary trunk, the aorta and the arterial duct at the same plane and the connection of the junction of the main and left pulmonary artery to the descending aorta just distal to the left subclavian artery. PT: pulmonary trunk; RPA: right pulmonary artery; LPA: left pulmonary artery; PDA: patent arterial duct; Dao: descending aorta.



**Figure 2.** Saggital views of the foetal heart showing the aortic and the ductal arch. The scan angle between the ductal arch and the thoracic aorta ranges between 10° and 19° during pregnancy. Note that the ductal arch has a similar size to the aortic arch in the foetus. **Left:** *Aortic arch view.* The ‘candy cane-like’ aorta gives rise to the three head and neck vessels, i.e. the brachiocephalic, left common carotid and left subclavian arteries [3, 4]. **Right:** *Ductal arch view.* The arterial duct connects the main pulmonary artery to the descending aorta, forming a ‘hockey stick-shaped’ arch. LV: left ventricle; RV: right ventricle; PDA: patent arterial duct; Dao: descending aorta.



**Figure 3.** The ‘3 vessel and tracheal view’ (3VT) is a standardised transverse plane of the upper mediastinum demonstrating simultaneously the course and the connection of both the aortic and ductal arches and a cross-section of the superior vena cava [1, 2]. **Left:** The three vessels are arranged in an oblique line, with the pulmonary artery in the most anterior position, the superior vena cava in the most posterior position and the aorta in between. **Right:** Transverse view of aortic and ductal arch identifies two vessels merging at the isthmus to form a V-shaped structure and Doppler imaging shows that blood flow in both arches has the same direction (blue colour). Tr: trachea; SVC: superior vena cava; Ao: aorta; PA: pulmonary artery.

Persistent patency of the arterial duct is a common problem in sick premature and extremely low-birth weight neonates, having an incidence of 65% in those weighing less than 1 kg and is associated with increased morbidity and mortality related to the consequences of a significant left-to-right shunt [6, 7].

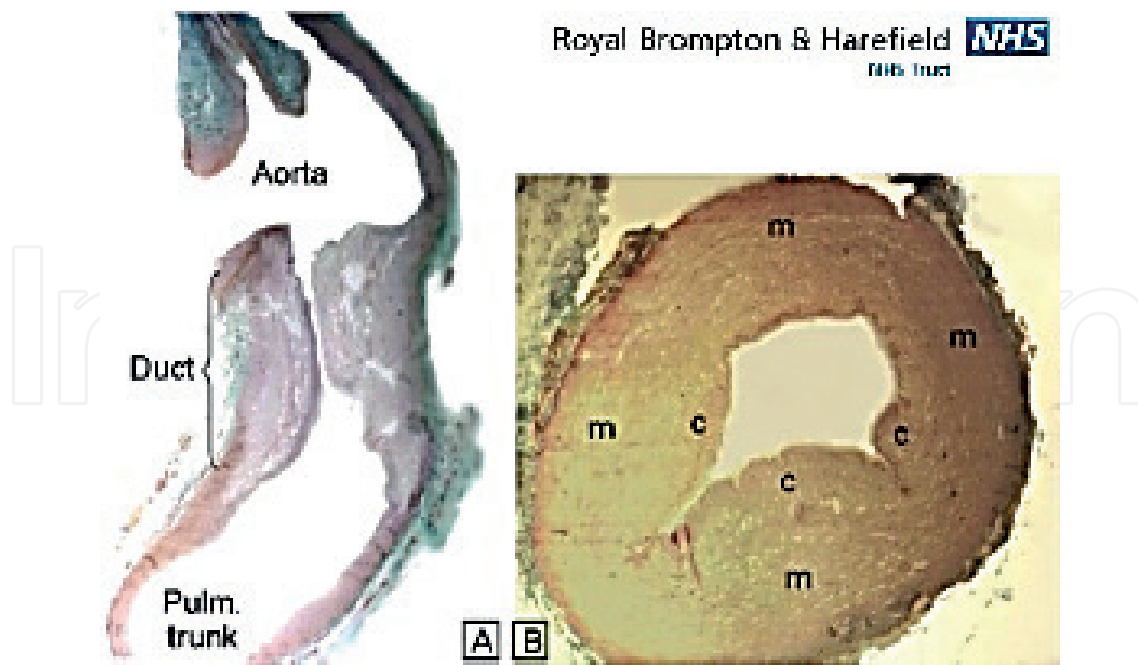
Patent arterial duct (PAD) may present in adults with dyspnoea due to cardiac failure, pulmonary hypertension/Eisenmenger syndrome, infectious endarteritis, atrial fibrillation or be an incidental finding on routine physical examination or on transthoracic echocardiography performed for other purposes in an asymptomatic subject (‘a silent duct’) [8].

### 1.1. Normal histology and changes after birth

The arterial duct is a muscular artery and its histology is easily distinguishable from that of the aorta and pulmonary artery, the walls of which are composed of elastic fibers, which are arranged circumferentially [9]. The internal surface of the normal arterial duct is lined by a layer of endothelial cells that overlies an internal elastic lamina. The elastic lamina is fragmented and sometimes split up into several layers and is interrupted by intimal cushions that lie underneath it (**Figure 4**). The media of the ductal wall consists of two layers of smooth muscles, which have spiral arrangements in opposite directions. The outer spiral is more acute, giving the impression of circularly arranged smooth muscle fibres, whereas the inner spiral is more gradual, so the fibres appear longitudinal [9].

In utero, the patency of the arterial duct is maintained mainly due to the low oxygen tension in the foetal blood and the increased concentrations of cyclooxygenase-mediated products of arachidonic acid metabolism, primarily prostaglandin  $E_2$  and prostacyclin [2, 10, 11]. These are produced by the duct itself and the placenta and their metabolism, which is normally performed by the pulmonary parenchyma is low, as the lungs are non-functional [2, 10, 11].





**Figure 4.** The 'Krichenko Classification' for anatomical classification of the PDA.

After birth, the arterial duct closes via a complex biphasic process. During the first stage, constriction of the smooth muscle in the media of the ductal wall takes place, producing shortening and thickening of the wall. These changes induce significant ischaemic hypoxia, which leads to production of several angiogenic factors and inflammatory mediators [9]. The intimal cushions disrupt the internal elastic membrane, form swollen protrusions into the ductal lumen, gradually unite and finally obliterate the lumen [9]. During the second stage of closure, proliferation of connective tissue in the intima and media takes place alongside with atrophy of smooth muscle cells and finally the arterial duct is transformed into a non-contractile ligament (the 'ligamentum arteriosum') [9].

The architecture of the arterial duct predisposes the tissue to contraction and lumen obliteration under appropriate signals and conditions, such as the increase in oxygen tension that normally takes place after birth [15]. Furthermore, there are various vasoactive substances such as bradykinin and endogenous catecholamines, which also mediate ductal closure after birth [9]. Prostaglandins exert an effect on ductal wall that is opposite to oxygen, causing relaxation of the smooth muscles, and inhibit the obliteration of the lumen [9]. However, their concentrations normally decrease after birth due to the removal of the placenta and their metabolism by the lungs [2].

## 1.2. Epidemiology and aetiology

In normal term infants, the closure of the arterial duct may be delayed until 3 months of life, after which the incidence of spontaneous closure is very low [1, 3]. If the duct remains open beyond 3 months of life in full-term infants, it is termed 'persistently patent arterial duct' and its patency has been attributed to inherent abnormality of the ductal tissue and/or signalling pathways that normally trigger its closure [12]. However, the exact mechanisms as to why the duct will not close in some full-term infants remain unknown [3].

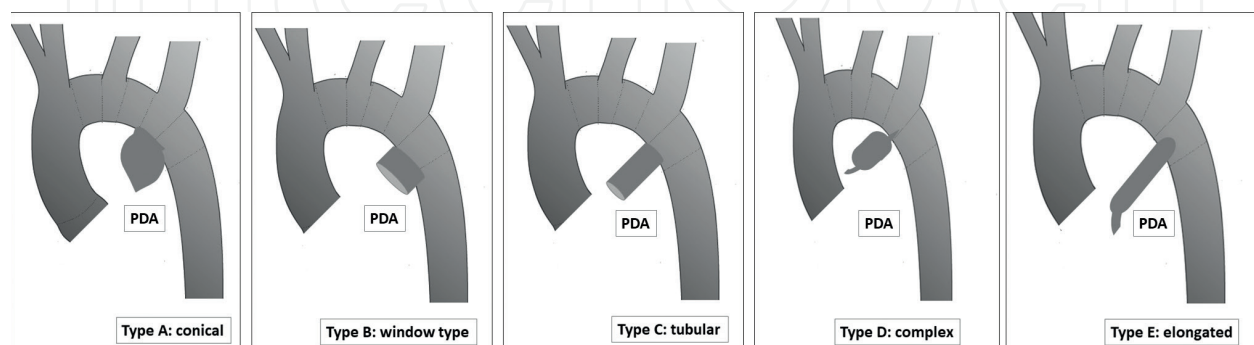
Also, the incidence of PAD in infants and children born at full term is not precisely known due to the fact that most subjects are asymptomatic. Before the widespread use of echocardiography, the incidence of clinically evident persistent PAD was reported to be about 1 in 2000 births, which accounts for approximately 5–10% of all congenital heart defects [1–3]. If cases detected incidentally by echocardiography are included, the incidence will be much higher and is estimated to be 1:500 [1, 3].

The female-to-male ratio for PDA is about 2:1. In addition, PAD occurs with increased frequency in several genetic syndromes, including Down syndrome (trisomy 21), trisomy 18, Char syndrome (autosomal dominant), Carpenter syndrome (single gene mutation), Holt-Oram syndrome (autosomal dominant) and incontinentia pigmenti (X-linked). Although, most cases are sporadic, there is increasing evidence that genetic factors are involved in many patients. Prenatal infection, such as rubella, may also play a role in some cases [1, 3].

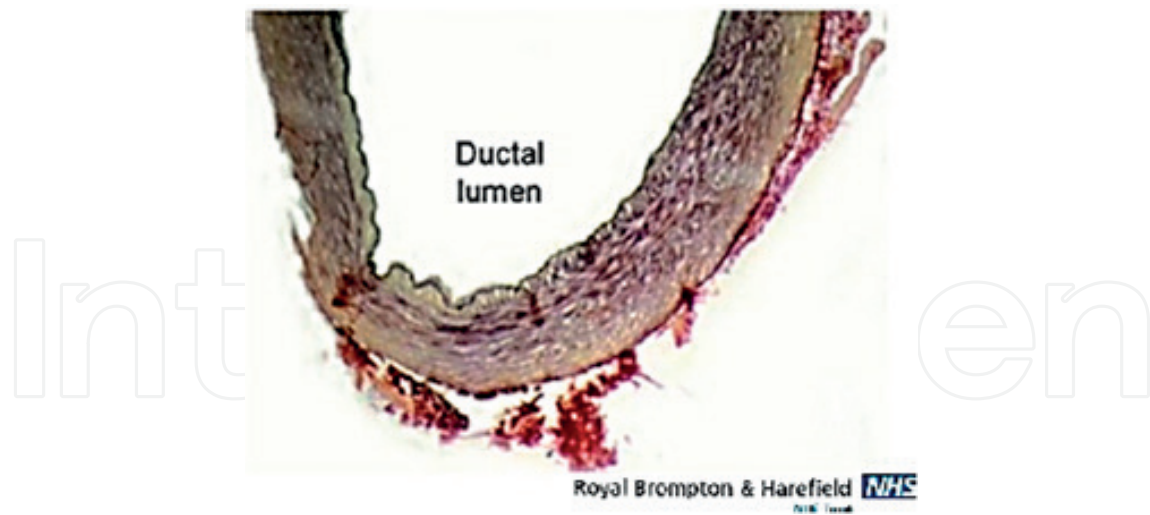
### 1.3. Anatomy and histology

A universally accepted system for anatomical classification of the PAD is the ‘Krichenko Classification’, which is based on the angiographic appearance of the duct [14]. The five Krichenko PDA subtypes are: type A (conical), type B (window type), type C (tubular), type D (complex) and type E (elongated), with a relative incidence of approximately 85% for type A, 10% for both types D and E combined and 5% for both types B and C combined [13] (**Figure 5**). Most commonly, a patent arterial duct occurs as an isolated congenital heart defect. Histologically, the internal elastic lamina of the PAD is generally intact and the intimal cushions are absent or are less well formed than normal [14] (**Figure 6**). Morphologically, a progressive transformation of the duct wall to the elastic-type artery has been observed with light microscopy. In this transformation, three stages were determined—stage I: laminar elastosis of the intima; stage II: same as stage I plus incomplete elastic transformation of the media and stage III: fully developed elastic-type artery [14].

However, in normal subjects, selective constriction of arterial duct suggests the presence of highly specialised contractile mechanisms. Indeed, smooth muscles in arterial duct are more differentiated compared to those in other arteries, which may be one of the cellular mechanisms responsible for the closure of the arterial duct after birth [15]. Postnatal constriction



**Figure 5.** Histologic sections through two normal ducts from neonates. (a) This longitudinal section shows the distinctive appearance of the ductal wall composed mainly of smooth muscle compared to the walls of the aorta and pulmonary trunk, which are composed primarily of elastic tissue. (b) This transverse section shows the intimal cushions (c) that protrude towards the ductal lumen. m = media. [trichrome stain].

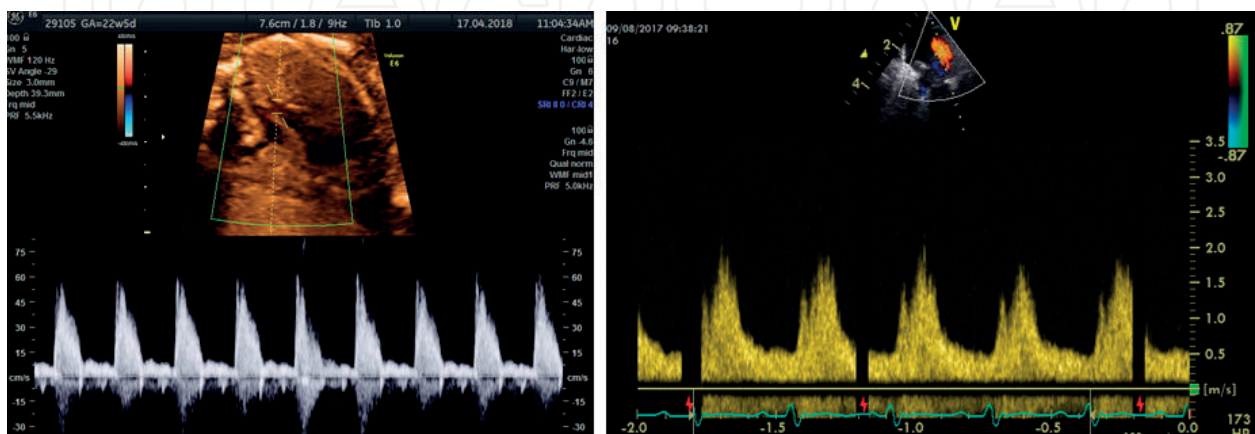


**Figure 6.** Histology image showing part of a persistently patent duct cut in cross-section. The internal elastic lamina is intact and appears as a black line lining the ductal lumen. Intimal cushions are barely formed, leaving a widely patent lumen. [elastic van Geison stain].

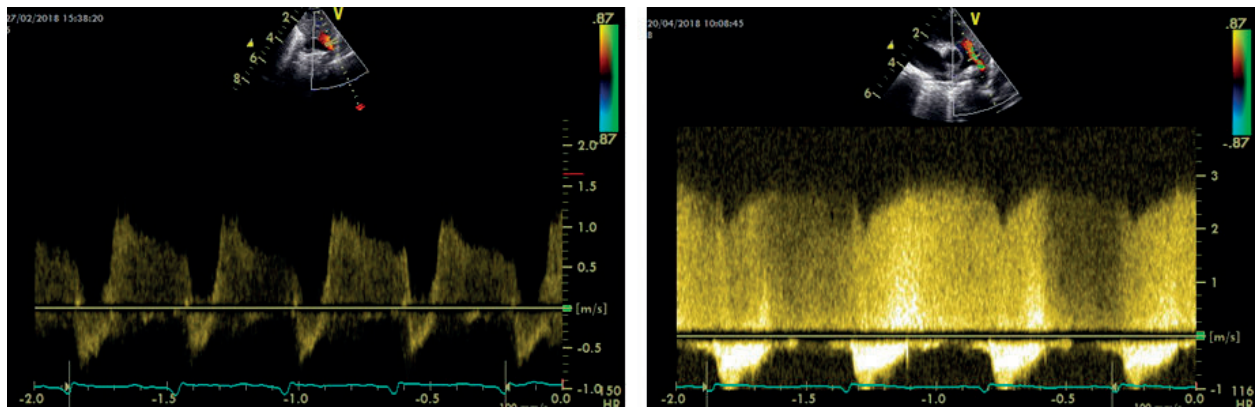
of the full-term arterial duct arteriosus produces cell death and remodelling of its wall. The extensive degree of cell death that occurs in the newborn duct after birth is associated primarily with ATP depletion. The increased glycolytic capacity of the immature duct may enable it to tolerate episodes of hypoxia and nutrient shortage, making it more resistant to developing postnatal cell death and permanent obliteration of its lumen [16].

#### 1.4. Pathophysiology and clinical picture

After birth, systemic resistance increases markedly as the placenta is disconnected from the systemic circulation, and pulmonary vascular resistance decreases significantly over time [10, 11, 17]. Therefore, in patients in which the arterial duct remains persistently patent, the direction of flow is left-to-right and the amount of shunt is determined by the difference in systemic and pulmonary vascular resistance, as well as by the resistance to blood flow determined by the residual diameter, geometry and distensibility of the duct (**Figures 7–9**) [18].



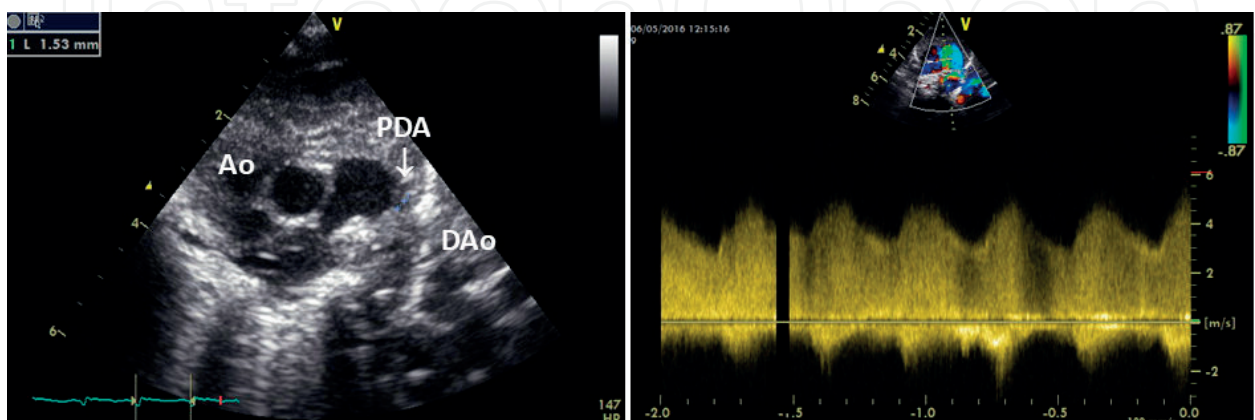
**Figure 7.** Left: Normal (right-to-left) ductal Doppler in a 22-week + 5-day-old foetus. Right: Left-to-right ductal Doppler in an extremely premature neonate showing a similar pulsatile unrestrictive, but reversed, pattern of flow.



**Figure 8. Left:** Early postnatal ductal Doppler, which is bi-directional with predominant left-to right, suggesting a decline of pulmonary resistance after birth. **Right:** Late postnatal restrictive ductal Doppler, which is pure left-to right, suggesting further decline of pulmonary resistance and a normal adaptation to extra-uterine life.

In patients with isolated persistency of the arterial duct, the clinical manifestations and complications are mainly related to the degree of pulmonary over-circulation and left ventricular volume overload [1–3, 12]. The increased pulmonary venous return to the left heart results in increased left ventricular volume and end-diastolic pressure, as well as increased left atrial size and pressure. The left ventricle compensates by increasing stroke volume, and eventually may hypertrophy in order to normalise wall stress [1].

Most patients are asymptomatic when the duct is small. In a moderate-to-large duct, infants may have increased work of breathing, which becomes manifest as fast or laboured breathing and tiredness during feeds. In older children, there may be a history of exertional dyspnoea. Large shunts may lead to failure to thrive, recurrent respiratory tract infections and congestive heart failure [1, 2]. In patients with long-standing moderate-to-large left-to-right shunt, irreversible pulmonary vascular changes may occur over time, secondary to prolonged exposure to high pulmonary blood flow [3, 12]. These changes include arteriolar medial hypertrophy, intimal proliferation and fibrosis. When pulmonary arterial pressure exceeds systemic pressure, the flow across the duct is reversed and right-to-left shunting occurs (Eisenmenger syndrome) [18].



**Figure 9. Left:** 'ductal shot' which is a modified shot axis view showing a patent arterial duct measuring 1.53 mm (the 'three leg stool appearance'). **Right:** Non-restrictive ductal Doppler in the same patient. Ao: aorta; PDA: patent arterial duct; DAo: descending aorta. Ao: aorta; PT: pulmonary trunk; DAo: descending aorta; PDA device: Amplatzer duct occluder.



## 1.5. Physical examination

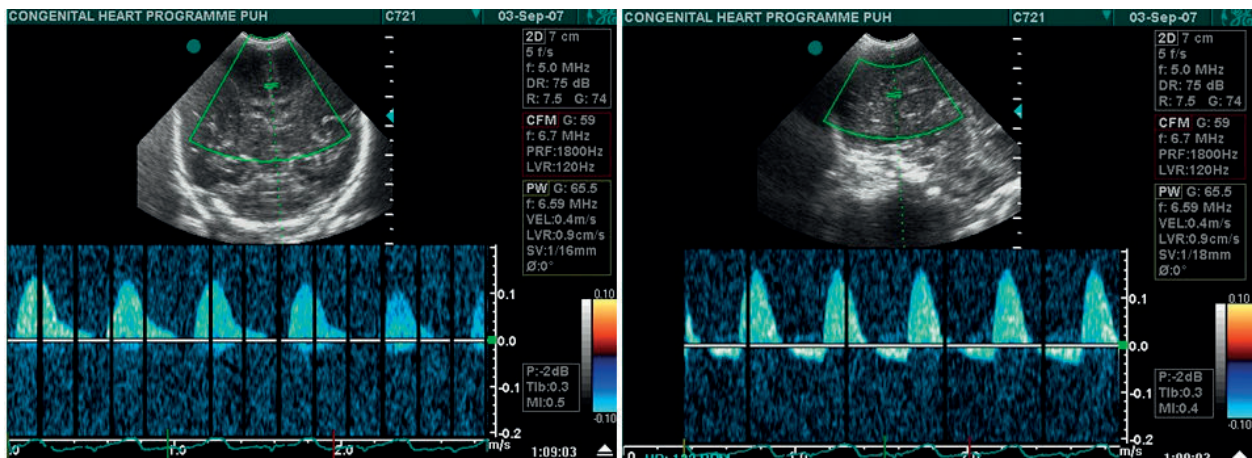
Physical examination findings depend on the size of the patent arterial duct and the presence of associated defects. A small PAD presents with a continuous 'machinery' type murmur, which is best heard at the left infraclavicular area [1–3, 12]. In case of a large duct with pure left-to-right shunt, besides the classic 'machinery' murmur, there may be bounding peripheral pulses due to hyperdynamic circulation and a wide pulse pressure. Adults with a large, non-restrictive PDA, however, may have suprasystemic pulmonary artery pressure and develop Eisenmenger physiology with a right-to-left shunt. In these patients, the continuous 'machinery' murmur is no longer audible. They may develop differential cyanosis, with more profound desaturation of the lower extremities associated with clubbing, which is more prominent in the toes. This represents the most specific physical sign of a large PAD associated with shunt reversal [20]. On the contrary, a trivial arterial duct is totally asymptomatic, flow through it is minimal and non-turbulent and thus no murmur is audible [1–3].

## 1.6. Specific age groups

### 1.6.1. Patent arterial duct in the preterm neonate

Prematurity increases the likelihood of persistent ductal patency, which is seen in about 30% of very low-birth weight and up to 65% of extremely low-birth weight infants [21]. The incidence of patent arterial duct increases with decreasing gestational age. The inherent immaturity in the muscular wall of the duct in preterm infants is associated with decreased oxygen sensitivity and increased sensitivity to prostaglandins and nitric oxide, leading to reduced ductal constriction. Without sufficient enough physiologic hypoxia to promote vascular remodelling, anatomic closure will not occur and the duct may fail to close or reopen after closure [21]. Also, very premature infants usually have respiratory distress syndrome and relatively low oxygen levels after birth, contributing to delayed effective ductal closure [10, 22]. Although the duct, the preterm newborn continues to respond to PGE<sub>2</sub> after birth, it becomes less dependent on prostaglandins and more dependent on other vasodilators during the weeks following delivery. This could explain why the effectiveness of prostaglandin inhibitors, as a pharmacologic treatment to promote ductal closure, wanes with increasing postnatal age [23].

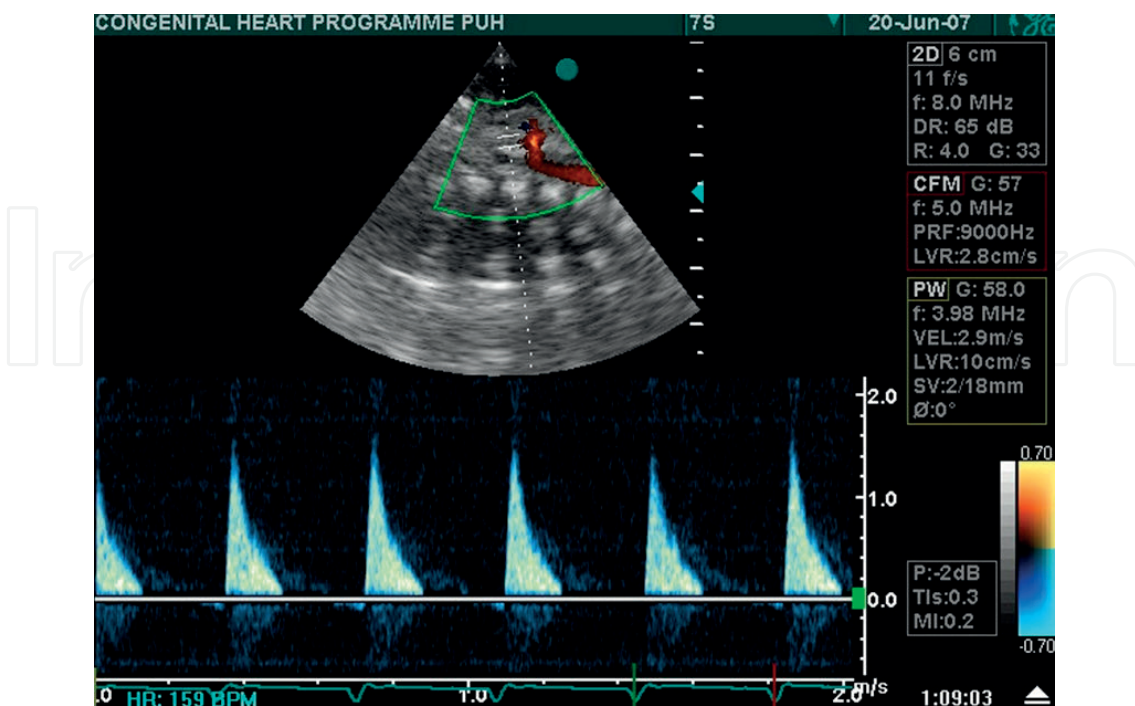
The pathophysiologic features of a PAD depend both on the magnitude of the left-to-right shunt and on the cardiac and pulmonary responses to the shunt. The consequences may include pulmonary over-circulation and/or systemic hypoperfusion [24]. Despite the ability of the left ventricle to increase its output in the setting of a significant left-to-right shunt, 'ductal steal' occurs, resulting in hypoperfusion of peripheral organs (**Figures 10** and **11**). Also, the decreased ability of the preterm infant to maintain active pulmonary vasoconstriction combined by the use of surfactant replacement therapy in preterm infants with respiratory distress syndrome lead to a more rapid drop in pulmonary vascular resistance and exacerbate the magnitude of left-to-right shunt. This results in lung congestion and volume overload of the preterm left atrium and ventricle (**Figure 12**) [22]. Although 75% of premature infants with PAD at discharge from the neonatal intensive care unit will have spontaneous closure during the first year of life, prolonged exposure to PAD has been associated with significant morbidity, and a four to sevenfold increase in mortality [21]. Complications associated with a



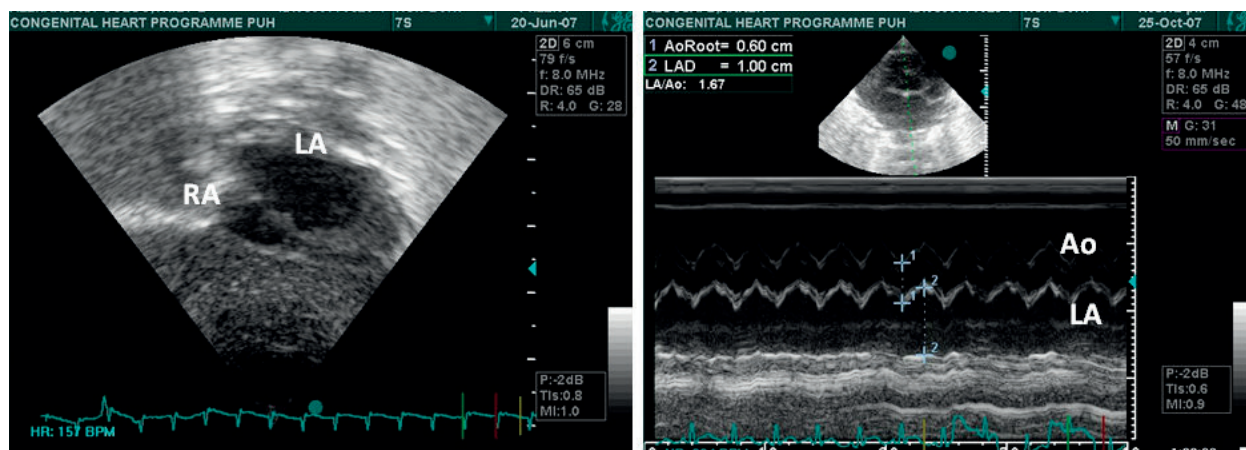
**Figure 10.** Abnormal middle cerebral artery Doppler with absence of end-diastolic flow (left) and reversal of end-diastolic flow (right) predisposing to intra/periventricular haemorrhage.

patent arterial duct in preterm infants include peri/intraventricular haemorrhage, necrotising enterocolitis, renal failure, congestive heart failure with hypotension and metabolic acidosis, haemorrhagic pulmonary oedema and prolonged ventilator dependence with subsequent chronic lung disease [21].

Whether to treat or not, as well as when to treat a PAD, has been a controversial topic for the past decade [21, 24, 25]. It has become apparent from systematic review of the literature that there is no clear evidence of effect on long-term outcomes of treating PAD, which some authors consider a physiologic phenomenon in sick preterm infants [23, 24].



**Figure 11.** Abnormal superior mesenteric artery Doppler with absence of end-diastolic flow predisposing to necrotising enterocolitis.



**Figure 12.** Left atrial dilatation (left) as a result of a significant left-to-right shunt with left atrium in systole to aorta in diastole ratio (right), LA/Ao = 1.67 (normal values <1.40). RA: right atrium; LA: left atrium; Ao: aorta.

Non-steroidal anti-inflammatory drugs have been traditionally used to close PADs to prevent associated complications [21, 24]. As a large proportion of the PADs in preterm infants will spontaneously close within the first few days, in recent years emphasis has been given to targeted treatment of PADs when considered haemodynamically significant based on clinical and echocardiographic criteria. The two most commonly used treatment options are intravenous ibuprofen and intravenous indomethacin [21, 24]. Recent observational studies suggest that paracetamol may have a role in PAD closure in infants who are resistant to conventional treatment or those with contraindications to conventional medical therapy [26]. A recent meta-analysis which included preterm infants treated with intravenous or oral indomethacin, ibuprofen, acetaminophen, placebo or no treatment concluded that high doses of oral ibuprofen are associated with a higher likelihood of closure of a haemodynamically significant PAD versus standard doses of intravenous ibuprofen or intravenous indomethacin. However, placebo or no treatment did not significantly change the risk of mortality, necrotising enterocolitis or intraventricular haemorrhage [27].

### 1.6.2. Adults with untreated patent arterial duct

The mortality in adults with an unoperated PAD is estimated to be 1–1.5% in the third decade, 2–2.5% in the fourth decade and increases by 4% per year thereafter, with 33% mortality at the age of 40 and 60% at 60 years of life [28]. Untreated PAD may cause congestive heart failure due to left heart volume overload and increased pulmonary blood flow; atrial fibrillation or flutter due to atrial enlargement; infective endocarditis/endarteritis, which is more common in the second or third decade of life; lower respiratory tract infections; calcification and pulmonary vascular disease/Eisenmenger syndrome [20]. Adult patients with Eisenmenger syndrome have dyspnoea on exertion, fatigue, syncope due to low systemic cardiac output, neurologic abnormalities due to secondary erythrocytosis and hyperviscosity, right heart failure, arrhythmias and haemoptysis due to pulmonary infarction [19].

Other more uncommon complications include aneurysmal dilatation of the duct, recurrent laryngeal nerve paralysis due to compression from a dilated pulmonary artery, peripheral emboli and exceedingly rarely aortic or pulmonary artery dissection [19, 20, 29].



Echocardiography is the key diagnostic imaging modality; however, it may be difficult in patients with Eisenmenger physiology [30]. Echocardiography defines the presence and the size of the PAD, the effect of the shunt on the left atrium and left ventricle, the pulmonary circulation and any associated lesions [31]. Magnetic resonance imaging (MRI) or computed tomography (CT) is indicated to evaluate pulmonary artery anatomy or to obtain more precise left ventricular volumes. Cardiac catheterisation is reserved for cases with signs of pulmonary hypertension on echocardiography to estimate pulmonary vascular resistance and assess the reactivity of the pulmonary vascular bed [30, 31].

Transcatheter occlusion is the treatment of choice, even if operation for associated anomalies has been scheduled. In adults, the duct is often calcified and the tissue in the area of the aortic isthmus and pulmonary artery is friable, making surgical ligation difficult and more hazardous compared to paediatric patients [30, 31]. Surgical ligation is thus reserved for patients with very large ducts, those with difficult anatomy or aneurysmal dilatation [30].

Arterial duct occlusion eliminates volume overload of the left ventricle and pulmonary over-circulation, treats congestive heart failure and prevents both the development of obstructive pulmonary vascular disease/Eisenmenger syndrome and subacute endocarditis/endarteritis [1–3, 29]. Routine follow-up is recommended every 3–5 years for patients with a small PAD without evidence of left-heart volume overload. Also, follow-up approximately every 5 years for patients who received a device is recommended because of the lack of long-term data [20].

## 2. Management: surgical and transcatheter techniques

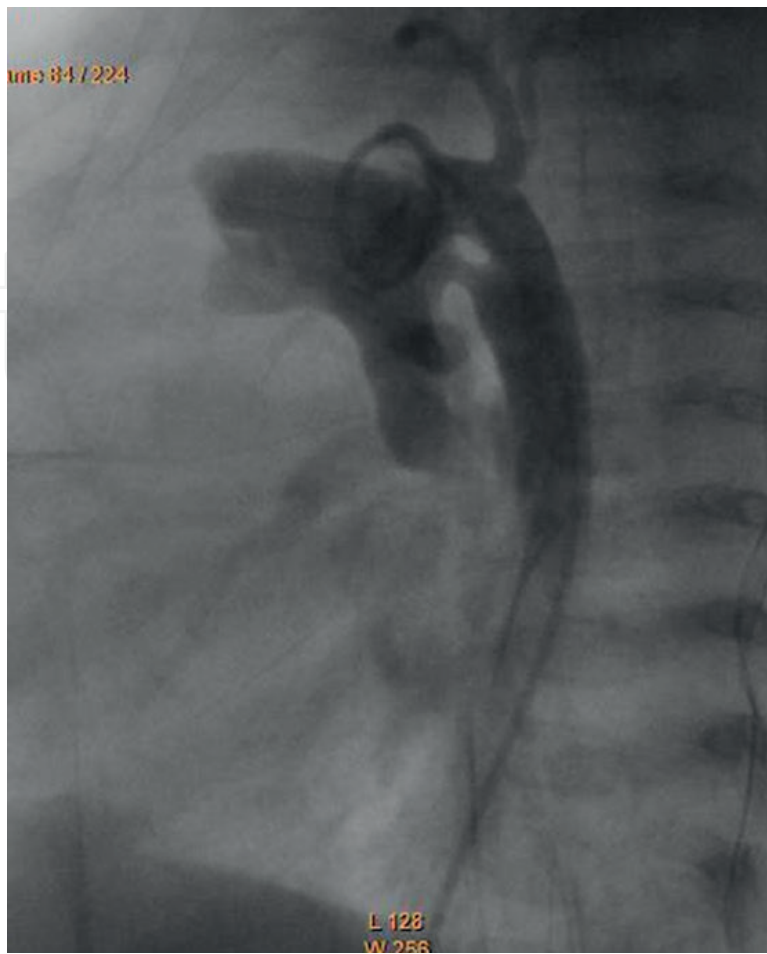
Over the past 15–20 years, transcatheter closure of PADs has become the standard of care for most patients and surgery is reserved for those with very large ducts or low-weight babies (**Figures 13** and **14**) [6]. A number of studies have been published reporting experience with transcatheter PAD closure, in particular using detachable coils and the Amplatzer ductal occluder device [6, 29]. In the reported series of transcatheter closure, major procedural events occurred in 1.0% of cases, a risk not related to ductal size [6]. The procedural risks specifically associated with closure of a silent duct are not known.

According to the scientific statement from the American Heart Association (AHA) concerning cardiac catheterisation and intervention in paediatric cardiac disease, transcatheter PAD closure is indicated for the treatment of a moderate-sized or large PAD with left-to-right shunt associated with congestive heart failure, failure to thrive, an enlarged left atrium or left ventricle or pulmonary over-circulation, provided the anatomy and patient size are suitable (**Figure 15**) [29].

Transcatheter PAD occlusion is considered reasonable in the presence of a small left-to-right shunt with normal-sized heart chambers when the PAD is audible by standard auscultation techniques [29]. Small PADs without haemodynamic overload are generally closed because of the risk of subacute bacterial endocarditis [29, 32].

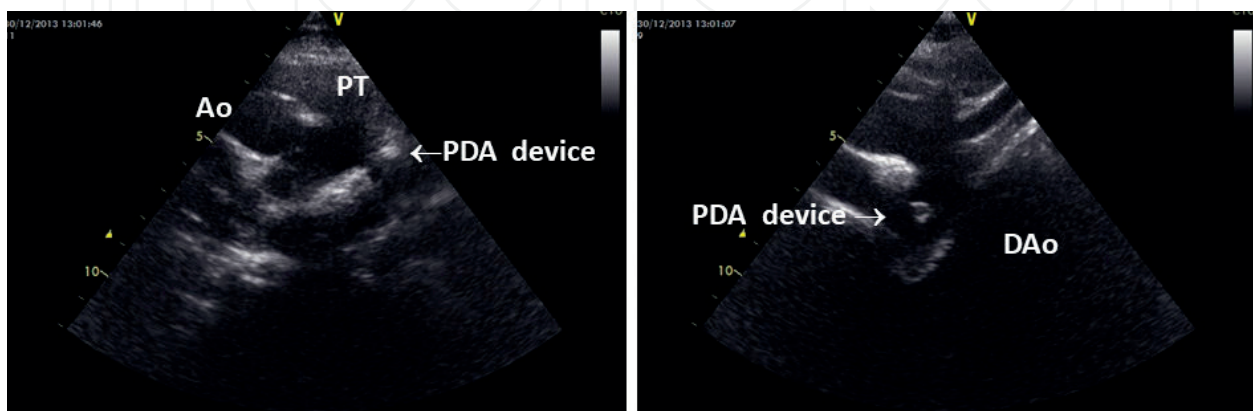
In the current era, transcatheter techniques are used to close PADs in most patients who weigh more than 5–6 kg [33]. The size and stiffness of the delivery sheath limit this approach in infants with low body weight; however, transcatheter occlusion has been applied with good success in symptomatic infants as small as 1800 g to avoid thoracotomy and the complications



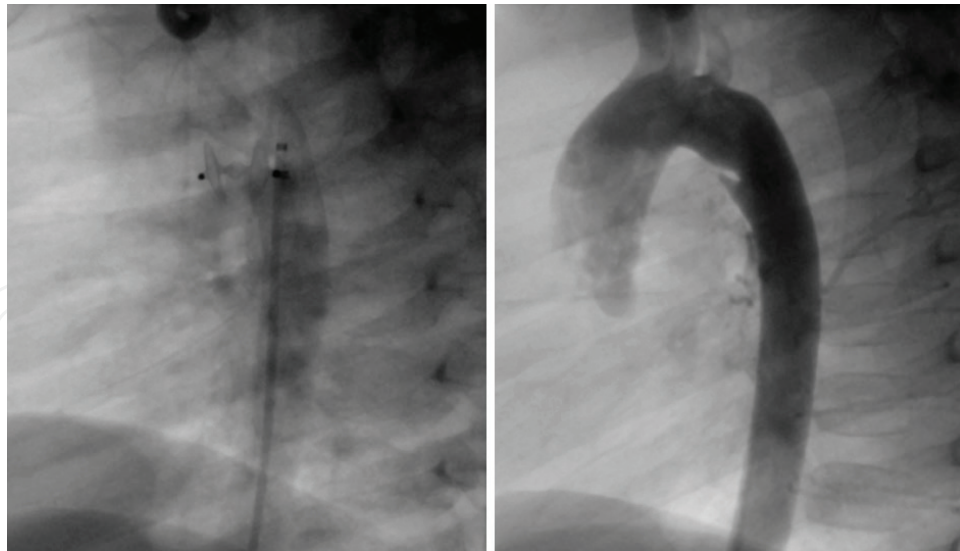


**Figure 13.** Angiography prior to transcatheter closure attempt showing a large patent arterial duct.

associated with surgical ligation [34]. Excellent results have been achieved using coil devices or plugs implanted into the arterial duct via the descending thoracic aorta using a transfemoral approach. Potential complications include device embolization, vascular injury, partial occlusion of the left pulmonary artery or aorta by the plug, and residual shunting [33]. Surgical strategies are applied for the larger arterial duct. The most typical surgical management of a PAD in older children is with ligation and division of the duct through a left thoracotomy.



**Figure 14.** Patient of **Figure 9** after successful amplatzer duct occlusion showing the device in correct position. **Left:** aortic arch view. **Right:** short axis view.



**Figure 15.** Left: Angiography during transcatheter closure attempt with an Amplatzer duct occluder. Right: angiography showing successful PAD closure in the same patient.

Video-assisted thoracoscopic PAD ligation is a less invasive technique that may be considered for selected patients [35]. Unsuccessfully performed thoracoscopic surgeries can safely be converted to conventional thoracotomy. Video-assisted thoracoscopic surgery is a less invasive approach, leads to a better aesthetic effect and lower surgical complication rate [35]. The postoperative management of older infants and children is usually quite straightforward. Most patients have a substantial improvement in the haemodynamic efficiency of the heart following this operation and do not require inotropic support or significant manipulation of the systemic and pulmonary vasculature in the perioperative period [33].

In premature babies and small infants, simple double ligation is performed. Surgical PAD closure may be considered for patients who do not respond to medical management, or if medical management is contraindicated [33]. A subset of premature neonates develop transient haemodynamic instability characterised by left ventricular dysfunction, low cardiac output syndrome and the need for increased respiratory support. Patients weighing less than 1000 g are at particular risk, likely related to the immaturity of the myocardium [33]. Although uncommon, a number of complications may develop following surgical PAD ligation. Residual shunting may uncommonly occur through a PAD that has been ligated but not divided. Because the recurrent laryngeal nerve travels around the PAD, consideration should be given to prevent potential injury to the nerve during duct ligation [33].

### 3. Current controversies

#### 3.1. Infective endocarditis/endarteritis prophylaxis

Subacute bacterial endocarditis/endarteritis has been reported in both symptomatic and asymptomatic patients with a patent arterial duct; however, the necessity for subacute endocarditis prophylaxis remains to be defined [36–38]. Infective endocarditis is an uncommon but life-threatening disease and prevention is preferable to treatment of established infection.

Bacteraemia with organisms known to cause infective endocarditis occurs commonly in association with invasive dental, gastrointestinal or genitourinary tract procedures. However, infective endocarditis is much more likely to result from frequent exposure to random bacteraemias associated with daily activities. Although prophylaxis may prevent an exceedingly small number of cases of infective endocarditis in individuals who undergo a dental, gastrointestinal tract or genitourinary tract procedure, the risk of antibiotic-associated adverse events exceeds the benefit. Therefore, maintenance of optimal oral health and hygiene may reduce the incidence of bacteraemia from daily activities and is more important than prophylactic antibiotics for a dental procedure to reduce the risk of infective endocarditis. These were the primary reasons for the revision of the infective endocarditis prophylaxis guidelines of the American Heart Association Committee on Rheumatic Fever, Endocarditis and Kawasaki disease, which does not recommend routine subacute bacterial endocarditis prophylaxis for unrepaired PAD [32].

The impacts of the application of the 2007 AHA antibiotic prophylaxis guidelines for infective endocarditis were studied using a nationally representative cohort of paediatric patients in the US. The data did not demonstrate significant changes on the overall incidence or severity of paediatric infective endocarditis in the period 2001–2012 [37]. However, a significant increase in disease incidence trend due to viridans group streptococci was observed in the 10–17 age group in the postguideline period. Infective endocarditis due to viridans group streptococci is presumed to result principally from bacteraemia during dental work, which is more common in older children. It should be noted that the absence of overall change in infective endocarditis incidence from pre- to postguideline might in part reflect poor adherence to the 2007 AHA policy [39, 40].

### 3.2. The 'silent arterial duct'

With the advent of novel ultrasound technologies, the incidence of persistent patency of the arterial duct is expected to become much higher. If cases detected incidentally on transthoracic echocardiography performed for other purposes are included, the incidence is estimated to be 1:500 individuals [1–3, 20]. When the duct becomes very small, flow is diminished and non-turbulent and thus no murmur is audible. The very small duct, which is identified incidentally in asymptomatic subjects and produces no murmur on auscultation, is termed 'the silent arterial duct' [10, 29].

There is still controversy related to the need of closure of a silent arterial duct which is associated with a small left-to-right shunt, a normal heart size and an inaudible murmur (AHA Class of recommendation IIb; Level of evidence C) [29]. There are few data supporting significant benefits of occluding it solely to prevent subacute infective endocarditis. A tiny patent arterial duct does not have a high enough velocity of flow through it to cause endothelial damage, which is the substrate for bacterial growth [20]. According to the European Society of Cardiology (ESC), device closure should be considered in small PADs with continuous murmur, normal left ventricular and pulmonary artery pressure (Level of Evidence IIa; Class of Recommendation C C), but should be avoided in the silent duct (Level of Evidence III; Class of Recommendation C) [29].

## 4. Conclusion

A patent arterial duct is a cardiovascular disorder documented in patients of all ages, from extremely premature infants to elderly subjects [41, 42]. Currently, the widespread availability of echocardiography has resulted in improved detection and detailed characterisation of the size of a PAD, the effects on the left atrium and left ventricle, the pulmonary circulation and any associated lesions. The haemodynamic consequences of PDA are analogous to the magnitude and the direction of the shunt, which depends on the flow resistance within the duct, and the dynamic pressure gradient between the pulmonary and systemic blood flow [42]. Catheter occlusion is the treatment of choice and surgical ligation is reserved for patients with very large ducts or when interventional closure is not feasible. However, the optimal management of the 'silent arterial duct' remains controversial and requires further investigation.

## Acknowledgements

The authors would like to thank professor Vassileios Papadopoulos and Dr. Konstantinos Tziveriotis, Academic Obstetricians of the feto-maternal Unit at the University of Patras Medical School for the provision of the foetal images.

## Conflict of interest

The authors declare that there are no real or potential conflicts of interest.

## A. Appendix 1

[1] The application of classification of recommendations and level of evidence according to AHA/ACC is published in *Circulation* [43].

[2] The recommendations for formulating and issuing ESC Guidelines can be found on the ESC Web Site. (<http://www.escardio.org/guidelines-surveys/esc-guidelines/about/Pages/rules-writing.aspx>).

## B. Appendix 2

Further reading regarding assessment of a PAD with foetal and neonatal echocardiography. See Ref. [43].



## Author details

Ageliki A. Karatza<sup>1\*</sup> and Xenophon Sinopidis<sup>2</sup>

\*Address all correspondence to: [agelikikaratza@hotmail.com](mailto:agelikikaratza@hotmail.com)

1 Department of Paediatrics, University of Patras Medical School, Patras, Greece

2 Department of Paediatric Surgery, University of Patras Medical School, Patras, Greece

## References

- [1] Schneider DJ. The patent ductus arteriosus in term infants, children and adults. *Seminars in Perinatology*. 2012;**36**(2):146-153
- [2] Schneider DJ, Moore JW. Patent ductus arteriosus. *Circulation*. 2006;**114**(917):1873-1882
- [3] Anilkumar M. Patent ductus arteriosus. *Cardiology Clinics*. 2013;**31**(3):417-430
- [4] Huff T, Bhimji SS. Anatomy, Thorax, Heart, Ductus Arteriosus. StatPearls [Internet]. Treasure Island (FL): StatPearls Publishing; 2018-2017
- [5] Kang C, Zhao E, Zhou Y, Zhao H, Liu Y, Gao N, et al. Dynamic changes of pulmonary arterial pressure and ductus arteriosus in human newborns from birth to 72 hours of age. *Medicine (Baltimore)*. 2016;**95**(3):e2599
- [6] Baruteau AE, Hascoët S, Baruteau J, Boudjemline Y, Lambert V, Angel CY, et al. Transcatheter closure of patent ductus arteriosus. Past, present and future. *Archives of Cardiovascular Diseases*. 2014;**107**(2):122-132
- [7] Garcia AV, Luckish J. Minimally invasive patent ductus arteriosus ligation. *Clinics in Perinatology*. 2017;**44**(4):763-771
- [8] Fortescue EB, Lock JE, Galvin T, McElhinney DB. To close or not to close: The very small patent ductus arteriosus. *Congenital Heart Disease*. 2010;**5**(4):354-365
- [9] Marsui H, McCarthy KP, Ho SY. Morphology of the patent arterial duct: Features relevant to treatment. *Images in Paediatric Cardiology*. 2008;**10**(1):27-38
- [10] Finnemore A, Groves A. Physiology of the fetal and transitional circulation. *Seminars in Fetal & Neonatal Medicine*. 2015;**20**(4):210-216
- [11] Morton S. Fetal physiology and the transition to extrauterine life. *Clinics in Perinatology*. 2016;**43**(3):395-407
- [12] Forsey JT, Elmasry OA, Martin RP. Patent arterial duct. *Orphanet Journal of Rare Diseases*. 2009;**4**:17
- [13] Ho SY, Anderson RH. Anatomical closure of the ductus arteriosus: A study in 35 specimens. *Journal of Anatomy*. 1979;**128**(4):829-836

- [14] Chuaqui B, Piwonka G, Farrú O. The wall in persistent ductus arteriosus (Author's translation). (article in German). *Virchows Archiv. A, Pathological Anatomy and Histology*. 1977;**372**(4):315-324
- [15] Kim HS, Aikawa M, Kimura K, Kuro-o M, Nakahara K, Suzuki T, et al. Ductus arteriosus. Advanced differentiation of smooth muscle cells demonstrated by myosin heavy chain isoform expression in rabbits. *Circulation*, 1810. 1993;**88**(4 Pt 1):1804
- [16] Levin M, Goldbarg S, Lindqvist A, Swärd K, Roman C, Liu BM, et al. ATP depletion and cell death in the neonatal lamb ductus arteriosus. *Pediatric Research*. 2005;**57**(6):801-805
- [17] Evans NJ, Archer LN. Postnatal circulatory adaptation in healthy term and preterm neonates. *Archives of Disease in Childhood*. 1990;**65**(10):24-26
- [18] Tomita H, Fuse S, Hatakeyama K, Chiba S. Epinephrine-induced constriction of the persistent ductus arteriosus and its relation to distensibility. *Japanese Circulation Journal*. 1998;**62**(12):913-914
- [19] Mebus S, Schulze-Neick I, Oechslin E, Niwa K, Trindade PT, Hager A, Hess J, Kaemmerer H. The adult patient with Eisenmenger syndrome: A medical update after Dana Point Part I: Epidemiology, clinical aspects and diagnostic options. *Current Cardiology Reviews*. 2010; **6**(4):356-362
- [20] Warnes CA, Williams RG, Bashore TM, Child JS, Connolly HM, Dearani JA, et al. ACC/AHA 2008 Guidelines for the Management of Adults With Congenital Heart Disease. A report of the American College of Cardiology/American Heart Association Task Force on Practice Guidelines (Writing Committee to Develop Guidelines on the Management of Adults With Congenital Heart Disease). *Circulation*. 2008;**118**(23):e714-e833
- [21] Prescott S, Keim-Malpass J. Patent ductus arteriosus in the preterm infant. diagnostic and treatment options. *Advances in Neonatal Care*. 2017;**17**(1):10-18
- [22] Evans N. Preterm patent ductus arteriosus: A continuing conundrum for the neonatologist? *Seminars in Fetal & Neonatal Medicine*. 2015;**20**(4):272-277
- [23] Teixeira LS, McNamara PJ. Enhanced intensive care for the neonatal ductus arteriosus. *Acta Paediatrica*. 2006;**95**(4):394-403
- [24] EL-Khuffash A, Weisz DA, PJ MN. Reflections of the changes in patent ductus arteriosus management during the last 10 years. *Archives of Disease in Childhood. Fetal and Neonatal Edition*. 2016;**101**(5):F474-F478
- [25] Mitra S, Rønnestad A, Holmstrøm H. Management of patent ductus arteriosus in preterm infants—Where do we stand? *Congenital Heart Disease*. 2013;**8**(6):500-512
- [26] Hammerman C, Bin-Nun A, Markovitch E, Schimmel MS, Kaplan M, Fink D. Ductal closure with paracetamol: A surprising new approach to patent ductus arteriosus treatment. *Pediatrics*. 2011;**128**(6):e1618-e1621
- [27] Mitra S, Florez ID, Tamayo ME, Mbuagbaw L, Vanniyasingam T, Veroniki AA, et al. Association of placebo, indomethacin, ibuprofen, and acetaminophen with closure of

- hemodynamically significant patent ductus arteriosus in preterm infants: A systematic review and meta-analysis. *Journal of the American Medical Association*. 2018;**319**(12):1221-1238
- [28] Campbell M. Natural history of persistent ductus arteriosus. *British Heart Journal*. 1968;**30**(1):4-13
- [29] Feltes TF, Bacha E, Beekman RH 3rd, Cheatham JP, Feinstein JA, Gomes AS, et al. Indications for cardiac catheterization and intervention in pediatric cardiac disease: A scientific statement from the American Heart Association. *Circulation*. 2011;**123**(22):2607-2652
- [30] Chugh R, Salem MM. Echocardiography for patent ductus arteriosus including closure in adults. *Echocardiography*. 2015;**32**(Suppl 2):S125-S139
- [31] Baumgartner H, Bonhoeffer P, De Groot NM, de Haan F, Deanfield JE, Galie N, et al. ESC Guidelines for the management of grown-up congenital heart disease (new 2010). *European Heart Journal*. 2010;**31**(23):2915-2957
- [32] Wilson W, Taubert KA, Gewitz M, Lockhart PB, Baddour LM, Levison M, et al. Prevention of infective endocarditis: Guidelines from the American Heart Association: A guideline from the American Heart Association Rheumatic Fever, Endocarditis, and Kawasaki Disease Committee, Council on Cardiovascular Disease in the Young, and the Council on Clinical Cardiology, Council on Cardiovascular Surgery and Anesthesia, and the Quality of Care and Outcomes Research Interdisciplinary Working Group. *Circulation*. 2007;**116**(15):1736-1754
- [33] Backer CL, Eltayeb O, Mongé MC, Mazwi ML, Costello JM. Shunt lesions part I: Patent ductus arteriosus, atrial septal defect, ventricular septal defect, and atrioventricular septal defect. *Pediatric Critical Care Medicine*. 2016;**17**(8 Suppl 1):S302-S309
- [34] Prescott S, Keim-Malpass J. Patent ductus arteriosus in the preterm infant. *Advances in Neonatal Care*. 2017;**17**(1):10-18
- [35] Stankowski T, Aboul-Hassan SS, Marczak J, Szymanska A, Augustyn C, Cichon R. Minimally invasive thoracoscopic closure versus thoracotomy in children with patent ductus arteriosus. *The Journal of Surgical Research*. 2017;**208**(2):1-9
- [36] Ozkokeli M, Ates M, Uslu N, Akcar M. Pulmonary and aortic valve endocarditis in an adult patient with silent patent ductus arteriosus. *Japanese Heart Journal*. 2004;**45**(6):1057-1056
- [37] Balzer DT, Spray TL, McMullin D, Cottingham W, Canter CE. Endarteritis associated with a clinically silent patent ductus arteriosus. *American Heart Journal*. 1993;**125**(4):1192-1193
- [38] Parthenakis FI, Kanakaraki MK, Vardas PE. Images in cardiology: Silent patent ductus arteriosus endarteritis. *Heart*. 2000;**84**(6):619
- [39] Sakai Bizmark R, Chang RR, Tsugawa Y, Zangwill KM, Kawachi I. Impact of AHA's 2007 guideline change on incidence of infective endocarditis in infants and children. *American Heart Journal*. 2017;**189**(7):110-119

- [40] Naik RJ, Patel NR, Wang M, Shah NC. Infective endocarditis prophylaxis: Current practice trend among paediatric cardiologists: Are we following the 2007 guidelines? *Cardiology in the Young*. 2016;**26**(6):1176-1182
- [41] Elsayed YN, Fraser D. Patent ductus arteriosus in preterm infants, Part 1: Understanding the pathophysiologic link between the patent ductus arteriosus and clinical complications. *Neonatal Network*. 2017;**36**(5):265-272
- [42] Boyalla V, Putzu P, Dierckx R, Clark AL, Pellicori P. Patent ductus arteriosus in older adults: Incidental finding or relevant pathology? *Journal of the American Geriatrics Society*. 2015; **63**(20):409-411
- [43] Jacobs AK, Anderson JL, Halperin JL. The evolution and future of ACC/AHA clinical practice guidelines: A 30-year journey: A report of the American College of Cardiology/American Heart Association Task Force on Practice Guidelines. *Circulation*. 2014; **130**(14):1208-1217. <http://circ.ahajournals.org/content/130/14/1208/tab-article-info>



