

We are IntechOpen, the world's leading publisher of Open Access books Built by scientists, for scientists

4,800

Open access books available

122,000

International authors and editors

135M

Downloads

Our authors are among the

154

Countries delivered to

TOP 1%

most cited scientists

12.2%

Contributors from top 500 universities



WEB OF SCIENCE™

Selection of our books indexed in the Book Citation Index
in Web of Science™ Core Collection (BKCI)

Interested in publishing with us?
Contact book.department@intechopen.com

Numbers displayed above are based on latest data collected.
For more information visit www.intechopen.com



HCC in Elderly Patients. Curative Intraoperative Strategies and Management in Recurrences

Stefania Brozzetti, Simone Bini,
Leonardo Luca Chiarella, Katia Fazzi,
Michele Di Martino and Mario Bezzi

Additional information is available at the end of the chapter

<http://dx.doi.org/10.5772/intechopen.79748>

Abstract

Hepatocellular carcinoma (HCC) incidence is growing among general population and especially in elderly patients. Recent development in surgical technique, surgical equipment, interventional radiology, and radiotherapy (hadrontherapy) allows us to use different techniques and approaches in order to treat this cancer. Patients are conventionally considered disease-free after a 10-year recurrence-free period. Commonly, patients remain into a lifelong follow-up and recurrences are treated as they show. In this chapter, we will give description and indications of different curative techniques, especially hepatic resections and Radio-frequency thermal ablation (RFTA). We will also describe and give indications to palliative care techniques such as transarterial chemoembolization (TACE), Selective Internal Radio-Therapy (SIRT), hadrontherapy, and supportive care. The aim of this chapter is to give information to clinicians and specialists dealing with the disease about the most effective approach to treat HCC, taking into account not only biological age, but also “physiological age,” performance status, comorbidities, and number of liver operative treatments. This chapter highlights that patients advanced in age are in particular need of a tailored medicine, where benefits are well weighted against invasivity of treatment and its side effects, in spite of assuring the best QoL and survival.

Keywords: HCC elderly, HCC metastases, HCC intervention radiology, HCC surgery, HCC patient management, HCC hadrontherapy, HCC liver resection, HCC cryoablation, HCC laser ablation, RFTA, TACE

1. Introduction

Hepatocellular carcinoma (HCC) is characterized by high clinical and biological variability [1]. Diagnosis and treatment of HCC always require multidisciplinary approaches.

Treatment requires commonly to make a decision between several specific interventions and to choose the one that allows the best risk-benefit ratio for a chosen patient.

Therapeutical approach shall take into account acute cirrhotic impairment risk and patient management experience, thus to avoid iatrogenic prognosis worsening.

Nowadays, patients older than 75 years account for 22% of HCC patients [2]. That is due to treatment and technological advancements which allow to reach an overall survival of decades, if therapy is well pondered; patients are kept in lifelong follow-up and intervention is timed well.

Therapeutical approaches to treat HCC can be divided into surgical approaches, such as major hepatic resection, minor hepatic resection, and wedge resection. Nonsurgical approaches are interventional radiology, chemotherapy, and most recently hadrontherapy. Since people older in age frequently have several comorbidities, often a specific less invasive therapeutical approach is needed.

Age is not a good outcome predictor: fit elderly patients may tolerate radical and invasive approaches, while unfit patients may not [3]. Treatment of older adults must take into account multiple issues related to the condition of aging itself. First of all, patient's frailty, thus invasive approaches are commonly excluded in patients advanced in age; on the other hand, noninvasive treatments are often palliative and do not achieve a satisfactory disease-free survival (DFS) or long-term survival (LTS) [3, 4]. Into this complex scenario, treatment strategies should also consider obstacles to cure the patients either physical or psychological, illness awareness, linguistic or cultural barriers, poverty, depression, and family environment.

Giving indication for or against invasive treatments is arduous in elderly. A decision for intervention shall consider either oncological principles and radical excision on one side or performance status, tolerability of treatment, and actual life expectancy on the other. HCC patients are not only in need for specific treatments, they must also be guided through routine activities in order to ameliorate their own hepatopathic condition, such as lifestyle correction (diet, water and salt assumption, physical activity, and smoking); instructions to the patient himself and to his family for therapeutical adhesion and instruction for early recognition of cirrhotic impairment or therapeutical side effects.

Physiological age is a new fundamental concept which is crucial in evaluating an advance in aged patient's performance status beyond his chronological age, which is still today too often used as a threshold to exclude or include a patient into specific treatment protocols [4].

The aim of this chapter is to give guidelines about management of elderly patients suffering from HCC and to give indications to treat those suffering from HCC as primary malignancy, recurrent illness, or metastatic disease either.

2. Patient management

2.1. Epidemiology and risk factors

Hepatocellular carcinoma (HCC) is the fifth most common cancer worldwide and the third most common cause of cancer mortality. In almost all populations, males have higher liver cancer rates than females, with male/female ratios usually averaging between 2:1 and 4:1 [1, 2].

HCC global distribution varies by region, incidence rate, sex, and also, by etiology. Normally, HCC incidence in female peaks 5 years later than males. Age-specific onset patterns are likely related to differences in the dominant hepatitis virus in population, age at viral infection, and the existence of other risk factors. As for average age at infection, normally, HCV carriers became infected in adulthood, while HBV carriers tend to become infected in childhood [2].

Recently, a significant increase in HCC incidence in hepatitis-free patients was noted; this index had a boost and went from 22% in 2000–2004 to 31% in 2010–2014 (database ITALICA) [5]. Among nonvirus-related hepatopathy, incidence of HCC in Alcoholic fatty liver disease patients (AFLD-patients) remains stable (17 vs. 19%), while a significant incidence increase was seen in Non Alcoholic fatty liver disease Patients (NAFLD-Patients) or in patients suffering from cryptogenic cirrhosis (0.5 vs. 9%) [5].

Often NAFLD-patients are demanding to treat; patients in this group have commonly several comorbidities such as metabolic syndrome; therefore, they need a more accurate and multidimensional clinical evaluation in order to choose the best treatment and achieve the best outcome from their condition.

HCV interferon-mediated clearance, associated with mild to severe fibrosis reduces hepatopathy progression and cirrhosis incidence, thus HCC's incidence reduction in SVR patients is expectable.

HCC hazard in HBV replication-controlled infection is reduced but not abolished, although effective antiviral therapy reduces HCC incidence in HBV- or HCV-positive patients [6].

Sudden HCC recurrence was reported by several papers after Direct Acting Antiretrovirals (DAA) mediated HCV clearance [7]. Other papers have found similar incidence of HCC after DAA-mediated HCV clearance when compared to IFN-mediated SVR but considering an overall 24-month follow-up [7]. HCC incidence after HCV clearance is still not sufficiently evaluated.

2.2. Elderly management and evaluation

More than two-third of patients newly diagnosed with HCC are aged >65 years [8], and this number is expected to increase as the world population ages. Furthermore, there is heterogeneity in the aging process, which further contributes to the complexity of treatment decisions. These factors contribute to age-related variations in treatment patterns and outcomes, potentially resulting in increased likelihood of under- or overtreatment, which can influence both risk of treatment toxicity and survival [9].

Geriatric patients may be extremely complex to treat due to comorbidities that may affect them. Therefore, a clinical evaluation is fundamental to assess the best treatment for each patient.

Aspects that must be considered comprehend not only biological age, HCC stage, and liver status, but also general patient conditions, performance status, and, in particular, individual and familial psychological frame, will to fight against the disease, and treatment tolerability. All these parameters are included into the concept of physiological age which goes far beyond chronological age and considers many crucial aspects of aging which is an extremely individual process.

Since chronologic age alone is a poor descriptor of heterogeneity in the aging process, a systematic and evidence-based way to assess physiological age is needed to guide treatment decisions.

Comprehensive geriatric assessment (CGA) is defined as a multidimensional, interdisciplinary diagnostic process focusing on determining an older person's medical, psychosocial, and functional capabilities to develop a coordinated and integrated plan for treatment and long-term follow-up [10] (**Table 1**).

Important reasons to perform GA in older patients with cancer are detection of unidentified problems and risks for which targeted interventions can be applied and prediction of adverse outcomes (e.g., toxicity, other relevant items such as functional or cognitive decline, postoperative complications); and better estimation of residual life expectancy and lethality of the malignancy in the context of competing comorbidities and general health problems. There is

COMPREHENSIVE GERIATRIC ASSESSMENT
<ul style="list-style-type: none"> • Medical history and tumor staging; • Physical examination and physical performance test; • Karnofsky Performance Status; • Activities of daily living (ADL); • Instrumental activities of daily living (IADL); • Charlson comorbidity score and review of medication; • Geriatric depression scale; • Mini mental state; • Nutritional status (BMI, albumin, haemoglobin, transferrin); • Social and economic conditions; • Geriatric Syndromes (Dementia/ Depression/Delirium, Neglect or Abuse, Failure to thrive, Osteoporosis, Falls, Incontinence)

Table 1. Considered parameters in Comprehensive geriatric Assessment.

clear evidence that GA items independently predict OS in a variety of oncology diseases and treatment settings. Poorer OS in older patients with cancer and deficits identified in geriatric domains might potentially be explained by several factors (e.g., increased risk of death resulting from causes other than cancer, increased death resulting from cancer because of less aggressive treatment, or death resulting from complications of cancer treatment) [9].

Patients with risk factors, in particular if older in age, must be lifelong under clinical surveillance for HCC onset. Principal conditions that require normally a twice per year follow-up are advanced cirrhosis, active HCV infection or cleared HCV infection, and HBV-controlled infection. Surveillance is made by liver-US and serum α -fetoprotein assessment. Oncological-marker-only surveillance is not recommendable and since cirrhotic parenchyma is on average poorly explorable, imaging shall be performed by a hepatobiliary dedicated team. Suspect nodules shall be further investigated by CT scan or hepatospecific MRI, which allows to make in the same session either a noninvasive diagnosis or staging when nodule is >10 mm in diameter [11]. Noninvasive diagnosis is cost-effective and a big advantage especially for elderly in poor performance status.

Patients older in age are the cohort that receives the highest benefit in early cancer detection since lower stage HCCs are associated with less invasive interventions, faster recovery, lower mortality rate, and better QoL [4].

Therefore, geriatric patients shall be educated to strictly comply to follow-up timing and to change their lifestyle in order to ameliorate liver function and reduce liver damage.

HCC shall never be considered as a single-cell malignancy: it is a whole organ malignancy; cell transformation is due to liver damage from hepatotropic viruses, toxins, and metabolic syndrome [2, 4]. Even a radical liver resection that cures the single malignancy does not exclude the onset of further lesions and rarely metastases after radical resection is possible [12].

The aim of HCC treatment is to freeze the disease into a chronic stage and to treat lesions as they show. There are several possible treatments that allow in some cases extremely long survival, even in metastatic patients [12].

Management of HCC patients can be extremely complex, so only dedicated multidisciplinary teams shall treat these patients who are regularly discussed into liver units [4].

3. Surgical therapy

3.1. Hepatic resection

Hepatic resection is the gold standard in noncirrhotic liver. In western countries, HCC incidence is raising, mostly due to NAFLD and metabolic syndrome [13].

Patients with these pathologic conditions can develop HCC in the absence of cirrhosis or severe fibrosis [14], although hepatic parenchyma shall not be considered healthy since steatosis is determinable in 50% of patients and steatohepatitis (NASH) in 25% [15, 16]. A

multicentric study confirmed that HCC patients suffering from metabolic syndrome have higher postoperative hepatic failure, mortality, and morbidity rates [15, 16].

Nevertheless, hepatic resection on metabolic syndrome-liver has excellent oncologic effectiveness and leads to long-time survival [16].

In cirrhotic patients, hepatic resection is the first-line treatment for single HCC nodule and preserved hepatic function, strict indications for hepatic resection are serum-bilirubin <1.5 mg/dl and Hepatic Portal-Venous Gradient (HPVG) ≤ 10 mmHg or platelets $\geq 100,000$ [17].

Resection in patients with light portal hypertension and nonenrollable for liver transplant shall be well weighted against locoregional treatments [17].

Cirrhotic liver resection can be a safe practice in well-selected patients with low morbidity and mortality rates [18]. Selection shall be lead through a global, multiparametric evaluation of the patient and shall pass beyond a dogmatic data interpretation.

All guidelines agree that is needed to select cirrhotic patients for hepatic resection thus to achieve the best outcome, but selection criteria are not universally accepted, the ones suggested from several surgical groups are not based on strong evidence. Therefore, it is necessary to develop a multiparametric evidence-based prognostic score to allow to evaluate a "tailored" operative risk and expected survival.

Tailored-risk evaluation is even more important in elderly patients since aging is a strict-individual process, multidimensional evaluation, and CGA score, in particular, are crucial to assess whether advanced in aged patients can be either enrolled or not for surgery with a deep gap in quality of life and overall survival [4].

Child-Pugh class B patients are routinely excluded from surgery; however, in some cases, satisfying outcome was achieved by performing limited hepatic resections in strictly selected patients, with mild serum bilirubin raise (≤ 2 mg/dl) and without portal hypertension [19] (Table 2).

Laparoscopic or robotic approaches could widen indications to Child-Pugh class B patients due to their little invasivity.

In elderly patients, these approaches are extremely interesting.

HEPATIC RESECTION FOR HCC- INDICATION	
<ul style="list-style-type: none"> • Non-cirrhotic liver (HBV/HCV related liver disease, AFLD, NAFLD); • Cirrhotic liver: Child Pugh A-B (5-7), MELD <10 Serum bilirubin <1,5 mg/dL HPVG ≤ 10 Platelets ≥ 100.000; • Tumor staging/ chance of radical resection; • No severe comorbidities/ ASA I-III; 	

Table 2. Indications to liver resection in HCC patient.

Hepatic surgery obtains excellent results in elderly patients, even if cirrhotic. Advance age alone is no more a contraindication to surgery.

However, elderly patients, cirrhotic or not, are often excluded from surgery due to comorbidities that rise ASA score and operative risk. Mini-invasive procedures on the one hand make operative time longer and worsen blood-gases control; on the other hand, they allow to spare hepatic parenchyma and shorten hospitalization and recovery [20]. Therefore, patients treated with mini-invasive surgery vs. open achieve a better outcome, especially if elderly, who often suffer longer hospitalizations either physically (reduced physical activity and nosocomial infection risk) and psychologically (depression, confusion, and dizziness) [20].

As reported by a recent meta-analysis, even better outcome is achieved with surgery (open or mini-invasive) vs. transarterial chemoembolization (TACE), which is the most used palliative care technique for HCC, whose advantage remains consistent even in advance HCC, even if vascular invasion is present, so up to stage Barcelona Clinic Liver Cancer (BCLC) stage C [17, 21].

Portal hypertension is often associated with hepatic damage. However, several studies proved that hepatic residual functionality and not portal hypertension affects short- and long-time outcome of hepatic resections [22, 23].

Patients with mild portal hypertension and preserved hepatic functionality can receive limited resections with morbidity, mortality, and OS similar to patients without portal hypertension [19].

HCC frequently develops and spreads through the portal system and that is why several authors recommend performing anatomical resections; these studies prove a better OS and local disease control for anatomic resection vs. wedge resection [24, 25].

More recently, a large Japanese retrospective study (more than 72,000 patients) proved superiority of anatomical resection only for HCC diameter >2 and <5 cm. Superiority is not proven if HCC diameter is <2 cm since portal diffusion risk is very low or >5 cm because other factors influence prognosis [26].

It is also possible to match a parenchyma-sparing surgery with anatomical resection, thanks to subsegmental US-guided resections [27]. This technique with laparoscopic subglissonian or extraglissonian approach is not of common use, due to its technical difficulty and exclusion criteria, that are ascites and moderate to severe portal hypertension. The approach remains interesting and future technical development is possible, especially thanks to robotic surgery. Subsegmental resection shall not be performed for advanced HCC (diameter >2 cm) in order to respect oncologic principles of a radical resection [27]. The procedure allows to spare liver parenchyma, and it may be really interesting for elderly even if cirrhotics with an early-HCC diagnosis.

3.2. Liver transplantation

Liver transplantation (LT) is considered the first-line treatment for cirrhotic patients. LT indications are given following the Milan criteria: single HCC nodules (diameter <5 cm) or less than 3 HCC nodules all <3 cm and in any case nonresectable [17].

A modest expansion to Milan criteria was given by “up to seven criteria,” which had achieved satisfactory results in patients without extrahepatic metastases and/or macrovascular invasion. A prospective validation is needed [28].

An increasing number of older patients with end-stage liver disease (ESLD) are evaluated for liver transplantation (LT). In fact, patients aged ≥ 65 years represent one of the fastest-growing patient populations in LT [29]. The most extreme of these patients, those aged ≥ 70 years, are associated with several difficult clinical dilemmas. Firstly, advanced patient age is associated with higher risk and poorer outcomes after complex surgical procedures [30]. LT in advanced age patients is associated with increased risk for infection and cardiovascular impairment, increased resource utilization, and lower patient survival [31]. Since the number of adult candidates on the waiting list continues to rise and organ availability remains unable to fully meet this demand, proper organ allocation and utilization are critically important.

Equivalent outcomes can be achieved in elderly recipients and age alone should not be used as a barrier to LT.

Recent data for waitlist registrants on the SRTR registry suggest that $<12\%$ of waitlisted patients are aged ≥ 65 years, but this proportion has steadily increased over the past decade. Continued improvements in care in pre- and posttransplant medicine and surgery suggest that this age group will continue to grow on the waiting list. With this demographic shift in the ESLD, more elderly patients will be considered for LT, and the use of scarce donor livers will need to be addressed because these recipients have a shorter life expectancy compared with younger patients. Despite the shortened lifespan, single-centered reports have shown equivalent posttransplant survival in super-selected patients [32, 33].

Due to physical and psychological impairment, elderly patients are often considered unfit for liver transplantation, since in super-selected groups only satisfying result in LT is achieved, surgical resection remains, for elderly, the first-line approach when performable.

4. Nonsurgical therapies

4.1. Intervention radiology

4.1.1. Radiofrequency thermoablation and microwave thermoablation

Percutaneous radiofrequency thermoablation (RFTA) and microwave thermoablation (MWA) are considered the standard care for patients with BCLC 0-A HCC, who are not eligible for surgical treatment.

Percutaneous ablation techniques are indicated for HCC nodules <2 cm, while nodules with diameter between 2 and 3 cm need to be discussed in a multidisciplinary unit in order to determine an appropriate management plan (**Table 3**). In patients with a single HCC nodule less than 2 cm in diameter, a complete necrosis ratio of 97% is expected [34].

RADIOFREQUENCY THERMO-ABLATION (RTA)- INDICATIONS
<ul style="list-style-type: none">• HCC nodules diameter < 2 cm / 2-3 cm in selected cases• Contraindication for Subglissonian localization, near to vessels or biliary branches due to heat-sink effect• Contraindication in advanced cirrhosis Child-Pugh > B7 or important ascites

Table 3. Indications to Radio-Frequency Thermal Ablation.

Several randomized studies have documented the superiority of surgical resection over percutaneous ablation techniques in terms of efficacy, while thermoablation has shown lower morbidity, mortality, hospitalization rates, and costs [35].

MWA and RFTA have shown comparable safety and effective results, although MWA seems to have certain theoretical advantages compared to RFTA: shorter procedure, higher ablation temperature, larger area of necrosis, lower probability of biliary duct injury, and reduction in the heat-sink effect through a more uniform heating in the volume of ablation. However, these advantages have not been confirmed in clinical practice. Although EASL guidelines recommend the use of MWA for nodules up to 4 cm, a recent phase II trial, comparing the two techniques in patients with similar mean lesion volumes, showed no significant difference between them in terms of outcome and recurrence ratio [36].

RFTA and MWA can also be safely and effectively performed via a video laparoscopic (VL) approach [37]. VL allows the operator to treat nodules that would normally not be eligible for a percutaneous approach due to nonaccessible locations and allows for hybrid management of patients with multiple nodules (e.g., surgical resection and RFTA on additional nonresectable nodules).

Percutaneous ablation techniques are a precious tool in management of elderly patients with multiple comorbidities.

HCC is often methachronous and new nodules are expected to develop during follow-up after the first tumor. Therefore, it is crucial to perform an appropriate follow-up in patients who have been treated for HCC, in order to detect new nodules at an early stage, so that the least invasive treatment available can be delivered. This is particularly relevant in elderly patients, or those who have already undergone extensive hepatic resection, who might not be eligible for surgery.

Percutaneous ablation is a recommended treatment modality, when indicated, due to its mini-invasive nature, high effectiveness, low rates of adverse events, short hospitalization times, and its relatively few contraindications.

4.1.2. Transarterial chemoembolization

Transarterial chemoembolization (TACE) is a palliative treatment that is routinely used in patients with HCC that are neither eligible for surgery nor for percutaneous ablation, and in

stage BCLC B HCC. TACE is indicated for asymptomatic patients in Child-Pugh class up to B7 and PS \leq 1 [17] (**Table 4**).

A study found no significant difference in survival following TACE in patients with Child-Pugh Class 8–9 compared to class 7; however, patients with Child-Pugh 8–9 had a significant worse prognosis and more dangerous side effects [38].

TACE is not indicated for patients with signs of HCC vascular invasion, metastases, untreatable ascites, jaundice, thrombosis of a major portal vessel, and HCC nodules >10 cm. In these cases, due to an already compromised liver function, there is a high risk of liver failure and eventually death.

Drug-eluting beads TACE (DEB-TACE) is a more recent variation of conventional TACE (cTACE) that uses embolizing beads eluted with doxorubicin as a chemotherapeutic agent. It has shown overall similar effectiveness, but less systemic side effects compared to cTACE.

Randomized trials have found superior outcomes with DEB-TACE compared to cTACE in patients with Child-Pugh class B and/or PS \geq 1 [39, 40].

Although contrast-enhanced CT (CECT) or MRI with hepatospecific contrast agent is recommended for TACE outcome evaluation, contrast-enhanced US (CEUS) could be an appropriate alternative in patients with less than four nodules [41].

If imaging follow-up detects residual or recurrent HCC nodules, TACE can be repeated up to three times per nodule. Treatment failure is considered when there are no signs of lesion response, as assessed using the mRECIST criteria, after two treatments or if there is no complete response after three treatments [42]; in eastern countries, different staging criteria, RECICIL, are actually in use [43].

TACE has been proved safe and effective in elderly as well as in younger patients. In particular, a prospective study found that elderly patients suffered from the same complication rates as nonelderly, while effectiveness rates were similar [44].

More important than age is the liver functional status, and the patient's performance status that mostly affects the safety profile of TACE. Therefore, TACE can be an effective palliative treatment able to give benefits in terms of disease control and improved quality of life in elderly patients with HCC.

TRANS-ARTERIAL CHEMO-EMBOLIZATION (TACE)	
Indications	Contraindications
<ul style="list-style-type: none"> • Patients not eligible for surgery nor percutaneous ablation; • Child Pugh 8-9; • Performance Status \leq1 	<ul style="list-style-type: none"> • Nodules >10 cm; • Vascular invasion/ Thrombosis of major portal vessels; • Metastases; • Untreatable ascites; • Jaundice

Table 4. Indications to Trans Arterial Chemo-Embolization.

TACE can also be combined with percutaneous ablation, particularly in patients with tumor recurrence within 1 year since the initial treatment, those with tumor diameters of 3.1–5.0 cm, and those with tumor recurrences after initial treatment with thermoablation, where sequential TACE-thermoablation might be the best treatment option [45].

The benefit of this sequential approach is due to the occlusion of hepatic arterial flow by means of embolization before ablation. Furthermore, lipiodol and gelatine sponge particles used in TACE reduce the portal flow around the tumor by filling the peripheral portal vein via multiple arteriportal communications. Therefore, the reduced cooling effect of the hepatic blood flow on ablation-induced thermal coagulation allows the achievement of an enlarged ablation zone which might reduce recurrence rates.

4.1.3. *Transarterial radioembolization*

Transarterial radioembolization (TARE) is a palliative brachytherapy for HCC. Radioactive substances (¹³¹I-lipiodol or Y90-beads) are delivered into the tumor by injecting them selectively into its feeding arteries.

This is a complex technique that requires a high-level specialization and has potentially severe side effects such as hepatic, intestinal, and lung toxicity [17]. Therefore, it should only be performed in specialized centers, with high volume activity and experience with this procedure.

Given the fact that TARE has minimal embolizing effects, it can be safely performed even in patients with thrombosis of the portal vein or its branches.

It can be used as a first-line treatment when TACE is not recommended, such as in the case of large or multifocal HCC or if there are signs of portal thrombosis. However, liver function must be conserved (Child-Pugh ≤ 7 , bilirubin ≤ 2.0 mg/dl, no ascites) [17].

TARE has also been shown to be an appropriate bridge or downstaging treatment in order to meet liver transplantation criteria [17, 46].

Furthermore, TARE can be used as a second-line treatment in patients who did not respond to TACE or who are intolerant to chemotherapy [17, 47].

Mean survival for Child-Pugh class A or B patients who underwent TARE is, respectively, 17.2 and 7.7 months [48, 49]. Mean survival for patients with portal vein thrombosis is 9 months, while for those with intrahepatic portal thrombosis is 17 months [50].

A study has revealed similar results in terms of overall survival (OS) and toxicity between cTACE and TARE in patients with nonresectable HCC [51]; another study has shown a better time-to-progression (TTP) and lower toxicity following TARE compared to TACE [52].

TARE cannot be performed in patients with a pulmonary shunt $>20\%$ or if other vascular anomalies may cause irradiation of visceral organs (stomach and intestine) [17].

Indications for this treatment are often controversial and should only be discussed in dedicated multidisciplinary teams. The difficulty in determining the precise indications of TARE is in part due to the lack of cost-effectiveness studies and the fact that its therapeutical equivalence to TACE has only been proved in selected patients. TARE is usually indicated in patients with stage BCLC C HCC, especially those with portal vein thrombosis and preserved liver function.

TARE is usually not indicated in elderly patients, who often have a compromised liver function, and therefore, risks of liver failure and death are high. TARE can be performed in elderly with good performance status and liver functionality as a second-line treatment in patients with treatment failure following TACE.

TARE has not been shown superior to sorafenib in treating advanced HCC; therefore, sorafenib could be a safer treatment in elderly patients who can tolerate chemotherapy [53].

4.1.4. Other

4.1.4.1. Percutaneous ethanol injection (PEI)

PEI induces cell necrosis through dehydration, protein denaturation, and small vessel disruption. It is not often used since it can only be performed in lesions <2 cm and it has a higher recurrence ratio than percutaneous ablation. It has indication only in lesions that are not considered safe for ablation due to their localization [54].

Compared to PEI, RF has shown better outcomes in terms of overall survival, survival at 1, 2, and 3 years, and cancer-free survival at 1, 2, and 3 years. This is probably due to the better performance of RF in terms of complete necrosis of the lesion and the low percentage of local recurrence [54].

RF requires fewer treatment sessions and shorter hospitalization than ethanol injection: although the quality of life of these patients was not evaluated, there was a decrease in hospitalization rates [54].

4.1.4.2. Cryoablation

Cell death with cryoablation is different than that with thermal ablation. The freezing process results in both intracellular and extracellular ice formation, both of which can result in cellular death, but by different mechanisms. Since the ablation zone is reperfused after the ice ball melts, the result is a rapid release of cellular debris into the systemic circulation. This probably explains the systemic complications of cryoablation (i.e., cryoshock) that are rare with heat-based ablation. Thermoablation is the preferred ablation method for treating HCC in patients with cirrhosis because of the increased risk of bleeding and of disseminated intravascular coagulation-like reaction (called cryoshock) associated with cryoablation [55, 56]. Therefore, although many studies have shown that small-volume cryoablation is feasible in patients with cirrhosis and HCC, it is difficult to justify the additional risk of cryoablation in these patients when viable heat-based alternatives are available [55].

4.1.4.3. Laser ablation (LA)

The term laser ablation refers to the thermal tissue destruction by conversion of absorbed light (usually infrared) into heat. Infrared energy penetrates tissue for 12–15 mm in depth; heat is conducted beyond this range thereby creating a larger ablation area. Optical penetration has been shown to be increased in malignant tissue compared to normal parenchyma [57].

Local tissue properties, in particular perfusion, have a significant impact on the size of the ablation zone. Highly perfused tissue and large blood vessels act as a heat sink, since infrared energy is absorbed by erythrocytic heme and transported away from the target area. This phenomenon makes normal liver parenchyma relatively more resistant to LA than tumor tissue and this is the rationale for using hepatic inflow occlusion techniques such as arterial embolization (TACE) in conjunction with laser therapy [57].

Light transmission into tissues and the size of the ablation zone increase with higher laser power, as does the local tissue temperature reached during ablation, with consequent higher risk of overheating and carbonization of the adjacent normal tissue.

The use of water-cooled laser application sheaths allows the use of a higher laser power output while preventing carbonization [58]. When using multiple water-cooled higher power fibers, ablation zones of up to 80 mm diameter can be obtained.

Major complications of LA are liver failure, segmental infarction, hepatic abscess, cholangitis, bile duct injury, and hemorrhage. The technique is considered safe by rates of 1.8% for major complications and a mortality rate of 0.1% [59] and can also be used safely in elderly patients with advanced liver disease up to Child–Pugh class B [57]. Tumor seeding after percutaneous biopsy and ablative therapies is a well-known phenomenon, but it has rarely been reported following laser ablation [57].

A recent study compared LA and TACE in patients with a single large HCC and found a significant superiority in multifiber-LA vs. TACE in terms of recurrence rates, especially in nodules >4 cm, while OS was similar between both groups [60].

Ablation size is critical to predict outcome; patients with lesions >6 cm or with multifocal disease (more than five nodules) are usually managed with other treatment modalities.

LA can be used with a curative intent only in patients with early-stage HCC. In this setting, it has shown similar outcomes compared to RFTA when treating nodules <3 cm [57, 60].

In patients with advanced local HCC, LA should only be used as a palliative treatment. The use of laser ablation is not currently extensively adopted for the treatment of HCC, but given the promising outcomes shown in recent studies and the expected technical advancements, it could become an increasingly more important treatment modality for HCC in the near future.

4.2. Chemotherapy

Systemic therapy is recommended for HCC patients in stage BCLC-C with conserved liver functionality (Child-Pugh A), good performance status, advanced disease, and/or extrahepatic diffusion. Systemic therapy is also recommended for patients with progressive HCC after locoregional treatments or HCC with vascular invasion not enrollable for other local treatments [17].

Target therapy with sorafenib proved to give survival benefits versus either placebo or cytotoxic and hormonal therapy [61].

Observational studies suggest that sorafenib administration in Child-Pugh B patients is as safe as administration in class A patients [62].

Recently, RESORCE trial showed survival benefit in regorafenib administration vs. placebo for HCC patients that went to tumor progression after sorafenib administration; all patients had tyrosine kinases-associated adverse effects [63].

Cytotoxic chemotherapy, such as doxorubicin or FOLFOX4 scheme, can be considered in patients with conserved liver functionality and after that sorafenib therapy has suspended for adverse effects [17] (Table 5).

Adverse effects of sorafenib especially dermatological, hypertension, or diarrhea in the first month of treatment are a frequent cause of treatment failure; it was proved that half-dose administration after adverse effects is associated with survival benefits [64].

In some cases, for fit and super-selected patients, intolerant to sorafenib, in case of oligometastatic disease, a different disease management can be done. Mini-invasive surgical therapy along with intervention radiology may be able to remove several metastases and treat them as they show; once the primitive tumor is surgically resected, a chronic metastatic disease can be surgically controlled with survival benefits [12]. Only case reports on this field have been published, but these authors believe that more research shall be done with multicentric clinical trials to prove what has been shown only in case reports.

Elderly can hardly ever be treated with surgical therapy due to their frailty and low PS even if in many cases, biological age does not correspond to chronological age. Sorafenib showed similar results in terms of safety and effectiveness in elderly and younger HCC populations. When administering systemic therapy, careful baseline evaluation is needed for patient's selection in elderly population, including discussion about antiplatelet therapy discontinuation, and caution in PS ≥ 1 patients, as well as active management of toxicity.

Asthenia and bleeding are more frequent in the elderly. The higher frequency of bleeding is explained by concomitant antiplatelet treatments, and major asthenia is frequent in PS ≥ 1 elderly patients [65].

A multidimensional evaluation is crucial for elderly patients and also in advanced HCC, and decision to start systemic therapy shall be made by experienced and dedicated units.

Adverse Effects of Sorafenib
<ul style="list-style-type: none"> • Dermatological toxicity; • Hypertension; • Diarrhea; • Nausea and vomiting; • Haematological toxicity

Table 5. Most common adverse effects of Sorafenib.

4.3. Best supportive care

Palliative treatments and supportive care aim at ameliorating patients QoL and at giving relief by symptoms. Terminal-stage HCC may have several symptoms associated with liver dysfunction due to cirrhosis, such as ascites, esophageal hemorrhage, and hepatic encephalopathy. Abdominal pain and asthenia are common.

Paracetamol and opioids are the safest drugs for pain control in hepatopathics; Non Steroideal Antinflammatory Drugs (NSAIDs) shall be avoided due to hemorrhage risk, kidney dysfunction risk, and resistant ascites development.

Radiotherapy is effective in pain control due to bone metastases; control results complete in 50% of patients and partial in 80–90% [66].

Percutaneous cementoplasty is effective in controlling HCC vertebral metastases' pain [67]. Brain metastases are rare and selected cases can be treated with stereotaxic radiotherapy [68].

Malnutrition and cachectic-state is common in end-stage oncological patients, in particular if affected by noncontrolled cirrhosis which enhances weight loss and muscular tissue loss.

Nutritional state assessment is important in HCC patients and was observed that prognostic nutritional index can predict survival expectancy in HCC patients [69].

4.4. Frontiers in palliative treatment of HCC: hadrontherapy

Hadrontherapy or heavy charged particle therapy (CPT) is one of the newest palliative treatments available against HCC.

Hadrontherapy technology is based on charged particles (carbon ions), which accelerated by cyclotrons or synchrotrons are conveyed into a beam to irradiate the tumor. Different from X-rays, charged particles have a sharp Bragg's peak which is even sharper than the one of protons; therefore, they release a great part of their energy at a specific level of tissue penetration which is proportional to their kinetic energy.

This technology allows to concentrate cellular damage into a very small area; therefore, CPT has higher tumor control probability (TCP) and relative biological effectiveness (RBE) than other radiotherapy techniques, it can also reduce organs at risk (OAR) and nonmalignant tissue complications probability (NTCP) [70].

Due to the physical properties of charged particles and, in particular, the possibility to generate a heavy concentrated damage, hypofractioning is possible with good results in terms of adverse effects.

Clinical trials on CPT are still running; first data are hopeful; in a Japanese study that used CPT in nontreatable HCC, a 5-year local control rate was 81% and survival was 33%; results are similar to those for proton therapy with 20 fractions, but by using a total of 4 fractions in 2 days [71]. Good results are also obtained with difficult to treat porta-hepatic HCC [69]. As for HCC metastases, they can be treated with a 50.4 Gy irradiation in 12 fractions [12, 71].

Summary – HCC treatment decision chart in elderly recipients

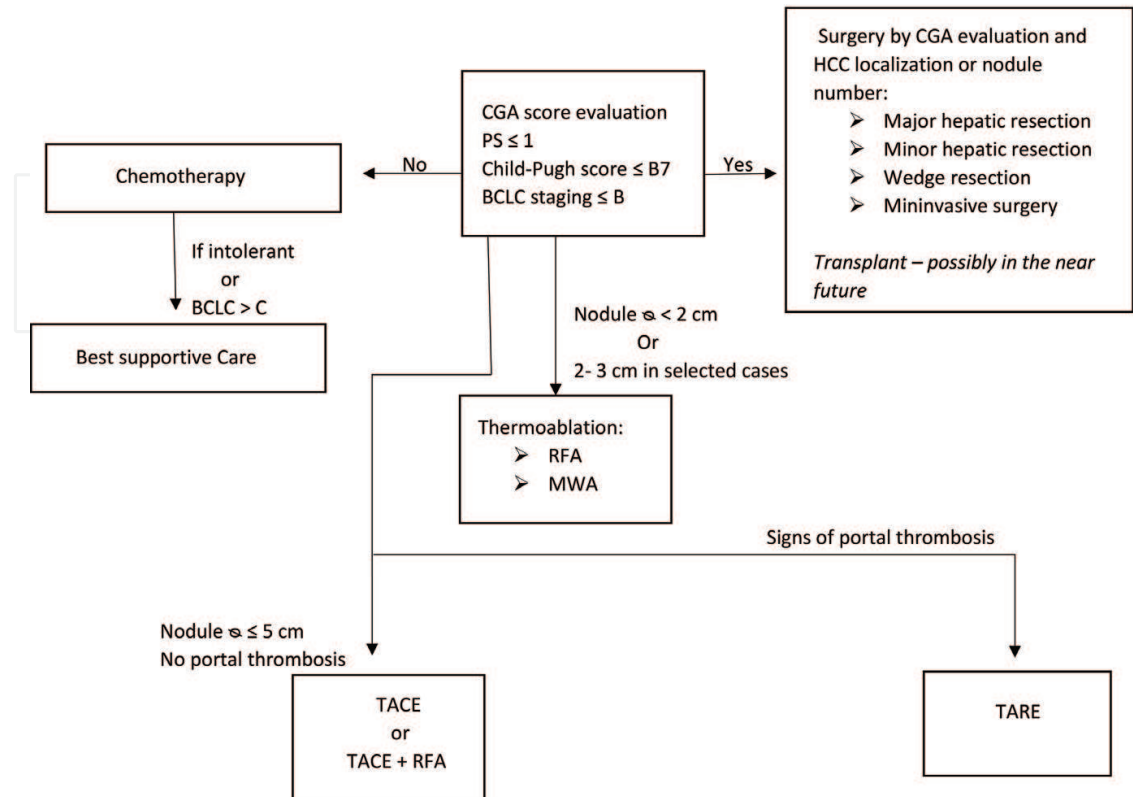


Figure 1. Summary –HCC treatment decision chart in elderly recipients.

These treatments are still experimental but results of trials until now are encouraging, in the next future hadrontherapy may be one of the pillars of advance HCC treatment.

Hadrontherapy may be extremely interesting as a treatment also for elderly, since it has little adverse effect and thanks to hypofractioning and noninvasivity; in the future, it may become a treatment of choice for difficult-to-treat HCC in elderly and for metastatic disease. It may ensure long-time tumor control and good QoL even in people advanced in age; the only issue of this treatment is its high cost-effectiveness ratio, even though cost-effectiveness trials for CPT are not still published a CPT apparatus costs around US\$ 200 million; only three carbon ion centers are available in Western Europe, seven in Asia (Japan and China), and none in US [65] (**Figure 1**).

5. Conclusion

The aim of this chapter is to give information and indications about the most recent operative and nonoperative existing techniques to treat HCC. Focus on older adults' case evaluation is of extreme importance; because lifespan enlargement will produce, in next decades, a sharp rise in HCC incidence among elderly [2].

It is strongly believed, by this multidisciplinary team, that early diagnosis is the key for HCC eradication in general population and in particular in elderly: dealing with a lower-staged cancer allows to use both less invasive and more radical treatments. Patients would then suffer less hospitalization time; would have faster recovery and lower infection risk [4]. Hospitalization time and subsequent infections are the most common cause of death for hospitalized elderly patients. Early-HCCs grow slowly when they develop in elderlies and when removed surgically or with interventional radiology mean (RFTA or MWA) recurrences appear after a sufficient time latency thus to make it possible to chronize the disease and allow to reach survival rates not different from general population [4].

The elderlies are a very heterogenic population; therefore, this kind of patients cannot be treated with a standardized protocol, but a tailored approach is needed. Each patient has its own comorbidities that must be taken into account; moreover, aging itself is an extremely individual process and different patients may have wide differences in performance status and therefore different treatment indications. Life expectancy, comorbidities, liver functionality, cancer progression, patient's therapy compliance, psychological status, and performance status shall be all taken into account when cases are discussed into multidisciplinary teams in order to assure the best treatment, and therefore, the best OS and QoL.

Author details

Stefania Brozzetti^{1*}, Simone Bini¹, Leonardo Luca Chiarella¹, Katia Fazzi¹, Michele Di Martino² and Mario Bezzi²

*Address all correspondence to: stefania.brozzetti@uniroma1.it

1 Department of Surgery "Pietro Valdoni", University of Rome La Sapienza, Policlinico Umberto I, Rome, Italy

2 Department of Radiological Sciences, University of Rome La Sapienza, Policlinico Umberto I, Rome, Italy

References

- [1] Cabibbo G, Enea M, Attanasio M, Bruix J, Craxí A, Cammà, C. A meta-analysis of survival rates of untreated patients in randomized clinical trials of hepatocellular carcinoma. *Hepatology*. 2010;**51**(4):1274-1283. DOI: 10.1002/hep.23485
- [2] El-Serag HB, Rudolph KL. Hepatocellular carcinoma: Epidemiology and molecular carcinogenesis. *Gastroenterology*. 2007;**132**(7):2557-2576. DOI: 10.1053/j.gastro.2007.04.061
- [3] Basso U, Monfardini S. Multidimensional geriatric evaluation in elderly cancer patients: A practical approach. *European Journal of Cancer Care*. 2004;**13**(5):424-433. DOI: 10.1111/j.1365-2354.2004.00551

- [4] Brozzetti S, Bezzi M, de Sanctis GM, Andreoli GM, de Angelis M, Miccini M, Tocchi A, et al. Elderly and very elderly patients with hepatocellular carcinoma: Strategy for a first line treatment. *Annali Italiani di Chirurgia*. 2014;**85**(2):1-10
- [5] Leoni S, Piscaglia F, Serio I, Terzi E, Pettinari I, Croci L, Bolondi L, et al. Adherence to AASLD guidelines for the treatment of hepatocellular carcinoma in clinical practice: Experience of the Bologna Liver Oncology Group. *Digestive and Liver Disease*. 2014;**46**(6):549-555. DOI: 10.1016/j.dld.2014.02.012
- [6] Van der Meer AJ, Veldt BJ, Feld JJ, Wedemeyer H, Dufour JF, Lammert F, Duarte-Rojo A, et al. Association between sustained virological response and all-cause mortality among patients with chronic hepatitis C and advanced hepatic fibrosis. *JAMA*. 2012;**308**:2584-2593
- [7] Schietroma I, Scheri GC, Pinacchio C, Statzu M, Pascale FG. Hepatitis C virus and hepatocellular carcinoma—Pathogenetic mechanisms and impact of direct-acting antivirals. *Open Virology Journal*. 2018;**12**:16-25. DOI: 10.2174/1874357901812010016
- [8] Liu P, Xie S, Hu S, Cheng X, Gao T, Zhang C. Age-specific sex difference in the incidence of hepatocellular carcinoma in the United States. *Oncotarget*. 2017;**8**(40):68131-68137
- [9] Wildiers H, Heeren P, Puts M, Topinkova E, Janssen-Heijnen MLG, Extermann M, Hurria A, et al. International society of geriatric oncology consensus on geriatric assessment in older patients with cancer. *Journal of Clinical Oncology*. 2014;**32**(24):2595-2603. DOI: 10.1200/JCO.2013.54.8347
- [10] Extermann M, Hurria A. Comprehensive geriatric assessment for older patients with cancer. *Journal of Clinical Oncology*. 2007;**25**:1824-1831
- [11] Ayuso C, Rimola J, Vilana R, Burrel M, Darnell A, García-Criado Á, Brú C, et al. Diagnosis and staging of hepatocellular carcinoma (HCC): Current guidelines. *European Journal of Radiology*. 2018;**101**:72-81. DOI: 10.1016/j.ejrad.2018.01.025
- [12] Brozzetti S, Bini S, Fazzi K, Chiarella LL, Ceccarossi V, Lucia, De C, Toma, De G. Case report—Metastases in a low-stage middle-graded HCC in cleared HCV infection, non-cirrhotic liver: Surgical therapy. *International Journal of Surgery Case Reports*. 2018;**47**:19-21. DOI: 10.1016/j.ijscr.2018.04.013
- [13] Siegel AB, Zhu AX. Metabolic syndrome and hepatocellular carcinoma: Two growing epidemics with a potential link. *Cancer*. 2009;**115**:5651-5661
- [14] Piscaglia F, Svegliati-Baroni G, Barchetti A, Pecorelli A, Marinelli S, Tiribelli C, Bellentani S, et al. Clinical patterns of hepatocellular carcinoma in nonalcoholic fatty liver disease: A multicenter prospective study. *Hepatology*. 2016;**63**:827-838
- [15] Vigano L, Conci S, Cescon M, Fava C, Capelli P, D'Errico A, Torzilli G, et al. Liver resection for hepatocellular carcinoma in patients with metabolic syndrome: A multicenter matched analysis with HCV-related HCC. *Journal of Hepatology*. 2015;**63**:93-101
- [16] Cauchy F, Zalinski S, Dokmak S, Fuks D, Farges O, Castera L, Paradis V, et al. Surgical treatment of hepatocellular carcinoma associated with the metabolic syndrome. *The British Journal of Surgery*. 2013;**100**:113-121

- [17] Dufour JF, Greten TF, Raymond E, Roskams T, De T, Ducreux M, Governing E, European Organisation for Research and Treatment of Cancer, et al. EASL—EORTC clinical practice guidelines: Management of hepatocellular carcinoma. *Journal of Hepatology*. 2012;**56**(4):908-943. DOI: 10.1016/j.jhep.2011.12.001
- [18] Krenzien F, Strucker B, Raschzok N, Ollinger R, Pascher A, Bahra M, Sauer I, Schmelzle M, Pratschke J, Andreou A. Liver transplantation and liver resection for cirrhotic patients with hepatocellular carcinoma: Comparison of long-term survivals. *Transplant International*. 2017;**30**:28-46. DOI: 10.1111/tri.13065
- [19] Roayaie S, Jibara G, Tabrizian P, Park JW, Yang J, Yan L, Schwartz M, et al. The role of hepatic resection in the treatment of hepatocellular cancer. *Hepatology*. 2015;**62**:440-451
- [20] Gerges FJ, Kanazi GE, Jabbour-Khoury SI. Anesthesia for laparoscopy: A review. *Journal of Clinical Anesthesia*. 2006;**18**(1):67-78. DOI: 10.1016/j.jclinane.2005.01.013
- [21] Hyun MH, Lee Y, Kim JH, Lee CU, Jung YK, Seo YS, Byun KS, et al. Hepatic resection compared to chemoembolization in intermediate to advanced stage hepatocellular carcinoma: A meta-analysis of high-quality studies. *Hepatology*. 2018;**15**. DOI: 10.1002/hep
- [22] Ishizawa T, Hasegawa K, Aoki T, Takahashi M, Inoue Y, Sano K, Imamura H, et al. Neither multiple tumors nor portal hypertension are surgical contraindications for hepatocellular carcinoma. *Gastroenterology*. 2008;**134**:1908-1916
- [23] Giannini EG, Savarino V, Farinati F, Ciccarese F, Rapaccini G, Marco MD, Benvegna L, et al. Influence of clinically significant portal hypertension on survival after hepatic resection for hepatocellular carcinoma in cirrhotic patients. *Liver International*. 2013;**33**: 1594-1600
- [24] Cucchetti A, Qiao GL, Cescon M, Li J, Xia Y, Ercolani G, Shen F, et al. Anatomic versus nonanatomic resection in cirrhotic patients with early hepatocellular carcinoma. *Surgery*. 2014;**155**:512-521
- [25] Agrawal S, Belghiti J. Oncologic resection for malignant tumors of the liver. *Annals of Surgery*. 2011;**253**(4):656-665. DOI: 10.1097/SLA.0b013e3181fc08ca
- [26] Eguchi S, Kanematsu T, Aarii S, Okazaki M, Okita K, Omata M, Takayasu K, et al. Comparison of the outcomes between an anatomical subsegmentectomy and a non-anatomical minor hepatectomy for single hepatocellular carcinomas based on a Japanese nationwide survey. *Surgery*. 2008;**143**(4):469-475. DOI: 10.1016/j.surg.2007.12.003
- [27] Torzilli G, Procopio F, Cimino M, Del Fabbro D, Palmisano A, Donadon M, Montorsi M. Anatomical segmental and subsegmental resection of the liver for hepatocellular carcinoma: A new approach by means of ultrasound-guided vessel compression. *Annals of Surgery*. 2010;**251**:229-235
- [28] Cascales-Campos P, Martinez-Insfran L a, Ramirez P, Ferreras D, Gonzalez-Sanchez MR, Sanchez-Bueno F, Parrilla P, et al. Liver transplantation in patients with hepatocellular carcinoma outside the Milan criteria after downstaging: Is it worth it? *Transplantation Proceedings*. 2018;**50**(2):591-594. DOI: 10.1016/j.transproceed.2017.09.063

- [29] Kim WR, Stock PG, Smith JM, Heimbach JK, Skeans MA, Edwards EB, et al. OPTN/SRTR 2011 annual data report: Liver. *American Journal of Transplantation*. 2013;**13**(Suppl. 1):73-102
- [30] Finlayson E, Fan Z, Birkmeyer JD. Outcomes in octogenarians undergoing high-risk cancer operation: A national study. *Journal of the American College of Surgeons*. 2007;**205**:729-734
- [31] Berg CL, Steffick DE, Edwards EB, Heimbach JK, Magee JC, Washburn WK, et al. Liver and intestine transplantation in the United States 1998-2007. *American Journal of Transplantation*. 2009;**9**(4 Pt 2):907-931
- [32] Lipshutz GS, Hiatt J, Ghobrial RM, Farmer DG, Martinez MM, Yersiz H, et al. Outcome of liver transplantation in septuagenarians: A single-centre experience. *Archives of Surgery*. 2007;**142**:775-781
- [33] Wilson GC, Quillin RC, Wima K, Sutton JM, Hoehn RS, Hanseman DJ, Shah SA, et al. Is liver transplantation safe and effective in elderly (≥ 70 years) recipients? A case-controlled analysis. *HPB*. 2014;**16**(12):1088-1094. DOI: 10.1111/hpb.12312
- [34] Wang Y, Luo Q, Li Y, Deng S, Wei S, Li X. Radiofrequency ablation versus hepatic resection for small hepatocellular carcinomas: A meta-analysis of randomized and nonrandomized controlled trials. *PLoS One*. 2014;**9**:e84484
- [35] Huang J, Yan L, Cheng Z, Wu H, Du L, Wang J, Xu Y, et al. A randomized trial comparing radiofrequency ablation and surgical resection for HCC conforming to the Milan criteria. *Annals of Surgery*. 2010;**252**:903-912
- [36] Vietti Violi N, Duran R, Guiu B, Cercueil JP, Aubé C, Digkila A, Denys A, et al. Efficacy of microwave ablation versus radiofrequency ablation for the treatment of hepatocellular carcinoma in patients with chronic liver disease: A randomised controlled phase 2 trial. *The Lancet Gastroenterology & Hepatology*. 2018;**3**(5):317-325. DOI: 10.1016/S2468-1253(18)30029-3
- [37] Herbold T, Wahba R, Bangard C, Demir M, Drebber U, Stippel DL. The laparoscopic approach for radiofrequency ablation of hepatocellular carcinoma—Indication, technique and results. *Langenbeck's Archives of Surgery*. 2013;**398**(1):47-53. DOI: 10.1007/s00423-012-1018-5
- [38] Yamakado K, Miyayama S, Hirota S, Mizunuma K, Nakamura K, Inaba Y, Yamaguchi M, et al. Subgrouping of intermediate-stage (BCLC stage B) hepatocellular carcinoma based on tumor number and size and Child-Pugh grade correlated with prognosis after transarterial chemoembolization. *Japanese Journal of Radiology*. 2014;**32**(5):260-265. DOI: 10.1007/s11604-014-0298-9
- [39] Golfieri R, Giampalma E, Renzulli M, Cioni R, Bargellini I, Bartolozzi C, Breatta AD, et al. Randomised controlled trial of doxorubicin-eluting beads vs conventional chemoembolisation for hepatocellular carcinoma. *British Journal of Cancer*. 2014;**111**:255-264

- [40] Lammer J, Malagari K, Vogl T, Pilleul F, Denys A, Watkinson A, Pitton M, et al. Prospective randomized study of doxorubicin-eluting-bead embolization in the treatment of hepatocellular carcinoma: Results of the PRECISION V study. *Cardiovascular and Interventional Radiology*. 2009;**33**:41-52
- [41] Moschouris H, Malagari K, Papadaki MG, Kornezos I, Gkoutzios P, Tepelenis N, Matsaidonis D. Short-term evaluation of liver tumors after transarterial chemoembolization: Limitations and feasibility of contrast-enhanced ultrasonography. *Abdominal Imaging*. 2011;**36**(6):718-728. DOI: 10.1007/s00261-011-9690-4
- [42] Lencioni R, Llovet J. Modified RECIST (mRECIST) assessment for hepatocellular carcinoma. *Seminars in Liver Disease*. 2010;**30**(01):052-060. DOI: 10.1055/s-0030-1247132
- [43] Kudo M, Trevisani F, Abou-Alfa GK, Rimassa L. Hepatocellular carcinoma: Therapeutic guidelines and medical treatment. *Liver Cancer*. 2017;**6**(1):16-26. DOI: 10.1159/000449343
- [44] Cohen MJ, Bloom AI, Barak O, Klimov A, Neshet T, Shouval D, Shibolet O, et al. Transarterial chemo-embolization is safe and effective for very elderly patients with hepatocellular carcinoma. *World Journal of Gastroenterology*. 2013;**19**(16):2521-2528. DOI: 10.3748/wjg.v19.i16.2521
- [45] Peng Z-W, Zhang Y-J, Liang H-H, Lin X-J, Guo R-P, Chen M-S. Recurrent hepatocellular carcinoma treated with sequential transcatheter arterial chemoembolization and RF ablation versus RF ablation alone: A prospective randomized trial. *Radiology*. 2012;**262**(2):689-700. DOI: 10.1148/radiol.11110637
- [46] Kallini JR, Gabr A, Ali R, Abouchaleh N, Riaz A, Baker T, Lewandowski RJ, et al. Pretransplant intra-arterial liver-directed therapy does not increase the risk of hepatic arterial complications in liver transplantation: A single-center 10-year experience. *Cardiovascular and Interventional Radiology*. 2017;**41**(2):231-238. DOI: 10.1007/s00270-017-1793-z
- [47] Moreno-Luna LE, Yang JD, Sanchez W, Paz-Fumagalli R, Harnois DM, Mettler TA, Roberts LR, et al. Efficacy and safety of transarterial radioembolization versus chemoembolization in patients with hepatocellular carcinoma. *Cardiovascular and Interventional Radiology*. 2013;**36**(3):714-723. DOI: 10.1007/s00270-012-0481-2
- [48] Salem R, Lewandowski RJ, Mulcahy MF, Riaz A, Ryu RK, Ibrahim S, Atassi B, et al. Radioembolization for hepatocellular carcinoma using yttrium-90 microspheres: A comprehensive report of long-term outcomes. *Gastroenterology*. 2010;**138**:52-64
- [49] Sangro B, Carpanese L, Cianni R, Golfieri R, Gasparini D, Ezziddin S, Paprottka PM, et al. Survival after yttrium-90 resin microsphere radioembolization of hepatocellular carcinoma across Barcelona clinic liver cancer stages: A European evaluation. *Hepatology*. 2011;**54**:868-878
- [50] Mazzaferro V, Sposito C, Bhoori S, Romito R, Chiesa C, Morosi C, Maccauro M, et al. Yttrium-90 radioembolization for intermediate-advanced hepatocellular carcinoma: A phase 2 study. *Hepatology*. 2013;**57**:1826-1837

- [51] Kooby DA, Egnatashvili V, Srinivasan S, Chamsuddin A, Delman KA, Kauh J, Staley CA 3rd, et al. Comparison of yttrium-90 radioembolization and transcatheter arterial chemoembolization for the treatment of unresectable hepatocellular carcinoma. *Journal of Vascular and Interventional Radiology*. 2010;**21**:224-230
- [52] Salem R, Lewandowski RJ, Kulik L, Wang E, Riaz A, Ryu RK, Sato KT, et al. Radioembolization results in longer time-to-progression and reduced toxicity compared with chemoembolization in patients with hepatocellular carcinoma. *Gastroenterology*. 2011;**140**:497-507 e492
- [53] Gramenzi A, Golfieri R, Mosconi C, Cappelli A, Granito A, Cucchetti A, Trevisani F, et al. Yttrium-90 radioembolization vs sorafenib for intermediate-locally advanced hepatocellular carcinoma: A cohort study with propensity score analysis. *Liver International*. 2015;**35**(3):1036-1047. DOI: 10.1111/liv.12574
- [54] Orlando A, Leandro G, Olivo M, Andriulli A, Cottone M. Radiofrequency thermal ablation vs. percutaneous ethanol injection for small hepatocellular carcinoma in cirrhosis: Meta-analysis of randomized controlled trials. *American Journal of Gastroenterology*. 2009;**104**(2):514-524. DOI: 10.1038/ajg.2008.80
- [55] Jansen MC, van Hillegersberg R, Schoots IG, et al. Cryoablation induces greater inflammatory and coagulative responses than radiofrequency ablation or laser induced thermotherapy in a rat liver model. *Surgery*. 2010;**147**(5):686-695
- [56] Hinshaw JL, Lubner MG, Ziemlewicz TJ, Lee FT, Brace CL. Percutaneous tumor ablation tools: Microwave, radiofrequency, or cryoablation—What should you use and why? *Radiographics*. 2014;**34**(5):1344-1362. DOI: 10.1148/rg.345140054
- [57] Gough-Palmer A-L. Laser ablation of hepatocellular carcinoma—A review. *World Journal of Gastroenterology*. 2008;**14**(47):7170. DOI: 10.3748/wjg.14.7170
- [58] Vogl TJ, Straub R, Zangos S, Mack MG, Eichler K. MR-guided laser-induced thermotherapy (LITT) of liver tumours: Experimental and clinical data. *International Journal of Hyperthermia*. 2004;**20**:713-724
- [59] Vogl TJ, Straub R, Eichler K, Woitaschek D, Mack MG. Malignant liver tumors treated with MR imaging guided laser-induced thermotherapy: Experience with complications in 899 patients (2,520 lesions). *Radiology*. 2002;**225**:367-377
- [60] Morisco F, Camera S, Guarino M, Tortora R, Cossiga V, Vitiello A, Ravaioli F, et al. Laser ablation is superior to TACE in large-sized hepatocellular carcinoma: A pilot case-control study. *Oncotarget*. 2018;**9**(25):17483-17490. DOI: 10.18632/oncotarget.24756
- [61] Manuscript A, Review S. Sorafenib for treatment of hepatocellular carcinoma: A systematic review. *Digestive Diseases and Sciences*. 2013;**57**(5):1122-1129. DOI: 10.1007/s10620-012-2136-1
- [62] Kudo M, Ikeda M, Takayama T, Numata K, Izumi N, Furuse J, Kokudo N, et al. Safety and efficacy of sorafenib in Japanese patients with hepatocellular carcinoma in clinical practice: A subgroup analysis of GIDEON. *Journal of Gastroenterology*. 2016;**51**(12):1150-1160. DOI: 10.1007/s00535-016-1204-2

- [63] Tovoli F, Granito A, De Lorenzo S, Bolondi L. Regorafenib for the treatment of hepatocellular carcinoma. *Drugs Today (Barc)*. 2018;**54**(1):5-13
- [64] Reig M, Torres F, Rodriguez-Lope C, Forner A, LLarch N, Rimola J, Darnell A, et al. Early dermatologic adverse events predict better outcome in HCC patients treated with sorafenib. *Journal of Hepatology*. 2014;**61**:318-324
- [65] Edeline J, Crouzet L, Le Sourd S, Larible C, Brunot A, Le Roy F, Boucher E, et al. Sorafenib use in elderly patients with hepatocellular carcinoma: Caution about use of platelet aggregation inhibitors. *Cancer Chemotherapy and Pharmacology*. 2015;**75**(1):215-219. DOI: 10.1007/s00280-014-2645-z
- [66] He J, Zeng ZC, Tang ZY, Fan J, Zhou J, Zeng MS, Wang JH, et al. Clinical features and prognostic factors in patients with bone metastases from hepatocellular carcinoma receiving external beam radiotherapy. *Cancer*. 2009;**115**:2710-2720
- [67] Kodama H, Aikata H, Uka K, Takaki S, Mori N, Waki K, Jeong SC, et al. Efficacy of percutaneous cementoplasty for bone metastasis from hepatocellular carcinoma. *Oncology*. 2007;**72**:285-292
- [68] Choi HJ, Cho BC, Sohn JH, Shin SJ, Kim SH, Kim JH, Yoo NC. Brain metastases from hepatocellular carcinoma: Prognostic factors and outcome: Brain metastasis from HCC. *Journal of Neuro-Oncology*. 2009;**91**:307-313
- [69] Pinato DJ, North BV, Sharma R. A novel, externally validated inflammation-based prognostic algorithm in hepatocellular carcinoma: The prognostic nutritional index (PNI). *British Journal of Cancer*. 2012;**106**:1439-1445
- [70] Durante M, Orecchia R, Loeffler JS. Charged-particle therapy in cancer: Clinical uses and future perspectives. *Nature Reviews. Clinical Oncology*. 2017;**14**(8):483-495. DOI: 10.1038/nrclinonc.2017.30
- [71] Kamada T, Tsujii H, Blakely EA, Debus J, De Neve W, Durante M, Chu WT, et al. Carbon ion radiotherapy in Japan: An assessment of 20 years of clinical experience. *The Lancet Oncology*. 2015;**16**(2):e93-e100. DOI: 10.1016/S1470-2045(14)70412-7

