

# We are IntechOpen, the world's leading publisher of Open Access books Built by scientists, for scientists

## 4,800

Open access books available

## 122,000

International authors and editors

## 135M

Downloads

Our authors are among the

## 154

Countries delivered to

## TOP 1%

most cited scientists

## 12.2%

Contributors from top 500 universities

**WEB OF SCIENCE™**Selection of our books indexed in the Book Citation Index  
in Web of Science™ Core Collection (BKCI)

Interested in publishing with us?  
Contact [book.department@intechopen.com](mailto:book.department@intechopen.com)

Numbers displayed above are based on latest data collected.

For more information visit [www.intechopen.com](http://www.intechopen.com)

---

## **Introductory Chapter: Vasculitis**

---

Reem Hamdy A. Mohammed

Additional information is available at the end of the chapter

<http://dx.doi.org/10.5772/intechopen.79560>

---

### **1. Introduction**

The nomenclature “Vasculitis” is a pathologic term that refers to an inflammatory process affecting a vessel wall, the inflammation leads to fibrinoid necrosis and vessel wall damage. The inflammatory process takes place in either isolate or mixed forms synchronously or sequentially with interruption of the blood flow to vital tissues giving protean presentations. It is the territorial and developmental characteristics of the vessels that determine the patterns and the after comings of the pathology. The etiology of the disease remains largely unexplored. On the one hand, when vessel inflammation exists as an independent pathology, it is usually classified as primary vasculitis; on the other hand, if vessel inflammation develops as a part of an existing primary pathology, it is classified as secondary vasculitis. An evidence-based approach to the classification of vasculitis has been challenged by the uniquely heterogeneous pattern of the inflammatory process, the confusing serology, non-uniform response to therapy, and poorly identified prognostic markers [1].

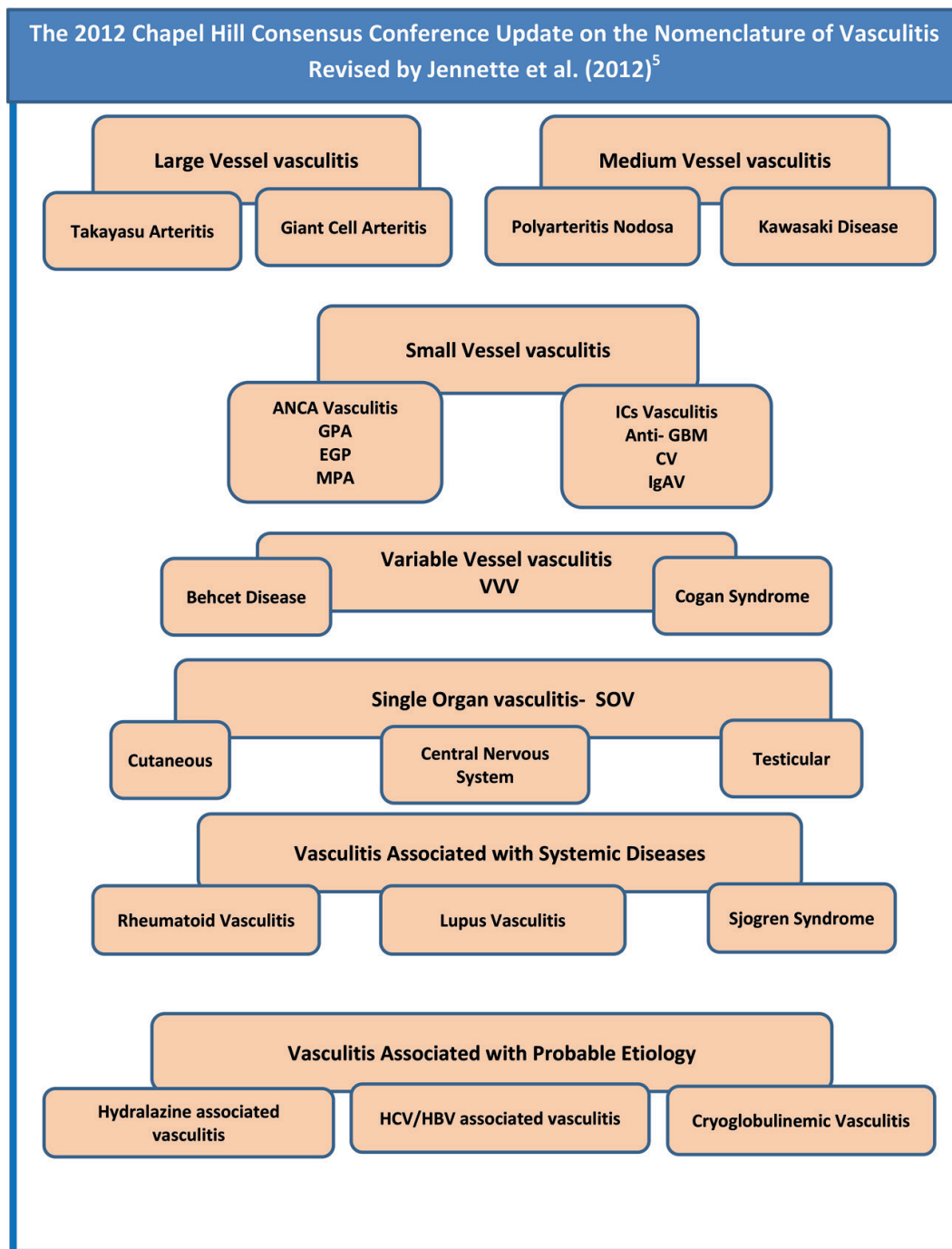
In 1994, the Chapel Hill Consensus Conference designed a nomenclature classification of vasculitis based on the size of the affected vessel [2, 3]. Clinical and research evidences have proven that considering vessel caliber as the sole determining factor for a multiplicity of heterogeneous consequences seems a rather simple hypothesis for a more complex pathology. The disappearance of specific clinic-pathologic variants of vasculitis that are commonly encountered in practice was one important shortcoming of the 1994 classification. With advancing research and disclosure of a number of potential developmental and pathogenic interplayers provided an in-depth understanding of the disease. Scientific research illustrated that the vascular developmental patterns and the territorial distribution are major determinants of vessel wall reactivity to inflammation, endothelial antigenic cross talks, and response to inflammatory mediators. Vascular beds in different organs vary

with respect to organ function in multiple aspects including morphology and function of the endothelial cells, intercellular junctions, the subendothelial matrix, the types of matrix components (including collagens, laminins, nidogens, fibronectin, vitronectin, and fibrillins), membrane proteins (adhesion molecules and Toll-like receptors—TLRs), and the pericytes that surround the endothelial cells. Such variations influence cell proliferation, migration, differentiation, transvascular passage of solutes and cellular diapedesis, chemotaxis, and tissue injury-response patterns. Microvascular diversities have been even seen within the same organ with the kidney featuring one good model [1–4].

In 2012, the Chapel Hill Consensus Conference went for revision of the 1994 classification to provide more precise classification of vasculitis with illustration of the different forms of vasculitis encountered in practice considering the nature of the pathology, the vessel size, and the etiology [5] **Figure 1**.

Definitions for vasculitides adopted by the 2012 International Chapel Hill Consensus Conference on the Nomenclature of Vasculitides (CHCC2012) [5, 6]:

- I. *Large-vessel vasculitis (LVV)*: vasculitis predominantly affecting large arteries (the aorta and its major branches); however, any size may be affected. It includes two main subtypes:
  - a. *Takayasu arteritis (TAK)*: granulomatous arteritis affecting the aorta and/or its major branches in patients younger than 50 years. The consensus retained the eponym “Takayasu” against the proposed non-eponymous term “early onset granulomatous aortitis/arteritis” being more effective than any alternative.
  - b. *Giant cell arteritis (GCA)*: granulomatous arteritis, usually affecting the aorta and/or its major branches, with a higher predilection for the branches of the carotid and vertebral arteries usually in patients older than 50 years and commonly associated with polymyalgia rheumatic. The disease often involves the temporal artery with the term “temporal arteritis” being commonly in use; however, not all patients with GCA have temporal artery involvement.
- II. *Medium-vessel vasculitis (MVV)*: vasculitis predominantly affecting medium-sized arteries defined as the main visceral arteries and their branches, and any size artery may be affected by the pathology. Inflammatory aneurysmal dilatations and arterial narrowing are common.
  - a. *Polyarteritis nodosa (PAN)*: necrotizing arteritis of the medium or small arteries or vasculitis in arterioles, capillaries, or venules, not associated with antineutrophil cytoplasmic antibodies (ANCA).
  - b. *Kawasaki disease (KD)*: arteritis involving the medium- and small-sized arteries. The disease occurs in infants and young children presenting with mucocutaneous lymph node syndrome. Coronary arteritis remains a hallmark being frequently involved, while the aorta and large arteries may get involved.
- III. *Small-vessel vasculitis (SVV)*: vasculitis predominantly affecting small vessels defined as small intraparenchymal arteries, arterioles, capillaries, and venules. Similarly, medium arteries and veins may be affected.



**Figure 1.** The 2012 Update of the Chapel Hill Consensus Conference on the Nomenclature and Classification of Vasculitides.

- a. *ANCA-associated vasculitis (AAV)*: necrotizing vasculitis, with few or no immune deposit, that is, pauci-immune necrotizing vasculitis, predominantly affecting the small vessels (i.e., capillaries, venules, arterioles, and small arteries), usually associated with antibodies to myeloperoxidase (MPO) or proteinase 3 (PR3) classified as either MPO-ANCA or PR3-ANCA, although not all the patients with this form of necrotizing vasculitis are ANCA positive.

1. *Microscopic polyangiitis (MPA)*: necrotizing vasculitis, with few or no immune deposits, predominantly affecting small vessels (i.e., capillaries, venules, or arterioles). Necrotizing pauci-immune arteritis involving small- and medium-sized arteries and necrotizing glomerulonephritis and pulmonary capillaritis are frequent presentations, while granulomatous inflammation is absent.
  2. *Granulomatosis with polyangiitis (Wegener's) (GPA)*: necrotizing granulomatous vasculitis affecting predominantly from small to medium vessels (e.g., capillaries, venules, arterioles, arteries, and veins) usually involving the upper and lower respiratory tract. Necrotizing glomerulonephritis is common.
  3. *Eosinophilic granulomatosis with polyangiitis (Churg-Strauss) (EGPA)*: EGPA is an eosinophil-rich necrotizing granulomatous inflammation predominantly affecting from small to medium vessels often involving the respiratory tract and associated with asthma and eosinophilia. Nasal polyps are common. ANCA is more frequent when glomerulonephritis is present. The eponym "Churg-Strauss syndrome" was replaced by "EGPA" in part to achieve nomenclature symmetry with MPA and GPA.
- b. *Immune complex vasculitis*: vasculitis predominantly affecting small vessels (i.e., capillaries, venules, arterioles, and small arteries) with moderate to marked immune complex deposits within vessel wall. Glomerulonephritis is frequent.
  - c. *Anti-glomerular basement membrane (anti-GBM) disease*: vasculitis affecting glomerular capillaries, pulmonary capillaries, or both, with GBM deposition of anti-GBM autoantibodies. Lung involvement causes pulmonary hemorrhage, and renal involvement causes glomerulonephritis with necrosis and crescents.
  - d. *Cryoglobulinemic vasculitis (CV)*: vasculitis with immune deposits affecting small vessels (predominantly capillaries, venules, or arterioles) and associated with circulating cryoglobulins. Skin, glomeruli, and peripheral nerves are often involved.
  - e. *IgA vasculitis (Henoch-Schönlein) (IgAV)*: vasculitis, with IgA1-dominant immune deposits, affecting small vessels (predominantly capillaries, venules, or arterioles). Skin, gastrointestinal tract, and joints are frequently involved. Glomerulonephritis indistinguishable from IgA nephropathy may occur.
  - f. *Hypocomplementemic urticarial vasculitis (HUV) (anti-C1q vasculitis)*: vasculitis affecting small vessels (i.e., capillaries, venules, or arterioles) manifesting by urticaria and associated with hypocomplementemia and anti-C1q antibodies. Glomerulonephritis, arthritis, obstructive pulmonary disease, and ocular inflammation are common presentations.
- IV. Variable vessel vasculitis (VVV)**: a form of vasculitis that can affect vessels of any size (small, medium, and large) and type (arteries, veins, and capillaries).
- a. *Behcet's disease (BD)*: vasculitis that can affect arteries or veins of variable calibers, characterized by recurrent oral and/or genital aphthous ulcers and accompanied by cutaneous, ocular, articular, gastrointestinal, and/or central nervous system inflammatory lesions. Small vessel vasculitis, thromboangiitis, thrombosis, arteritis, and arterial aneurysms may occur.

- b. *Cogan's syndrome (CS)*: Cogan's syndrome is a form of vasculitis that can affect vessels of variable sizes. The disease leads to arteritis (affecting small, medium, or large arteries), aortitis, aortic aneurysms, and aortic and mitral valvulitis. Clinically presents by ocular inflammatory lesions, including interstitial keratitis, uveitis, and episcleritis, and inner ear disease, including sensorineural hearing loss and vestibular dysfunction.
- V. *Single-organ vasculitis (SOV)*: vasculitis in arteries or veins of any size in a single organ that has no features that indicate that it is a limited expression of a systemic vasculitis. Vasculitis may be unifocal or multifocal/diffuse within the same organ. Usually defined in terms of the involved organ and vessel type, for example, cutaneous small vessel vasculitis, testicular arteritis, and central nervous system vasculitis. Some patients originally diagnosed as SOV may develop additional disease manifestations that warrant redefining the case as one of the systemic vasculitides, for example, cutaneous arteritis later becoming systemic polyarteritis nodosa, and so on.
- VI. *Vasculitis associated with systemic disease*: vasculitis that is associated with and/or may be secondary to a systemic disease. The diagnosis should specify the systemic disease, for example, rheumatoid vasculitis, lupus vasculitis, and so on.
- VII. *Vasculitis associated with probable etiology*: vasculitis that is associated with a probable specific etiology, for example, hydralazine-associated microscopic polyangiitis, hepatitis B virus-associated vasculitis, hepatitis C virus-associated cryoglobulinemic vasculitis, and so on.

In this book, the authors will provide and discuss an update on specific clinic-pathologic (Figure 2) subtypes of vasculitis including the pauci-immune vasculitis and immune

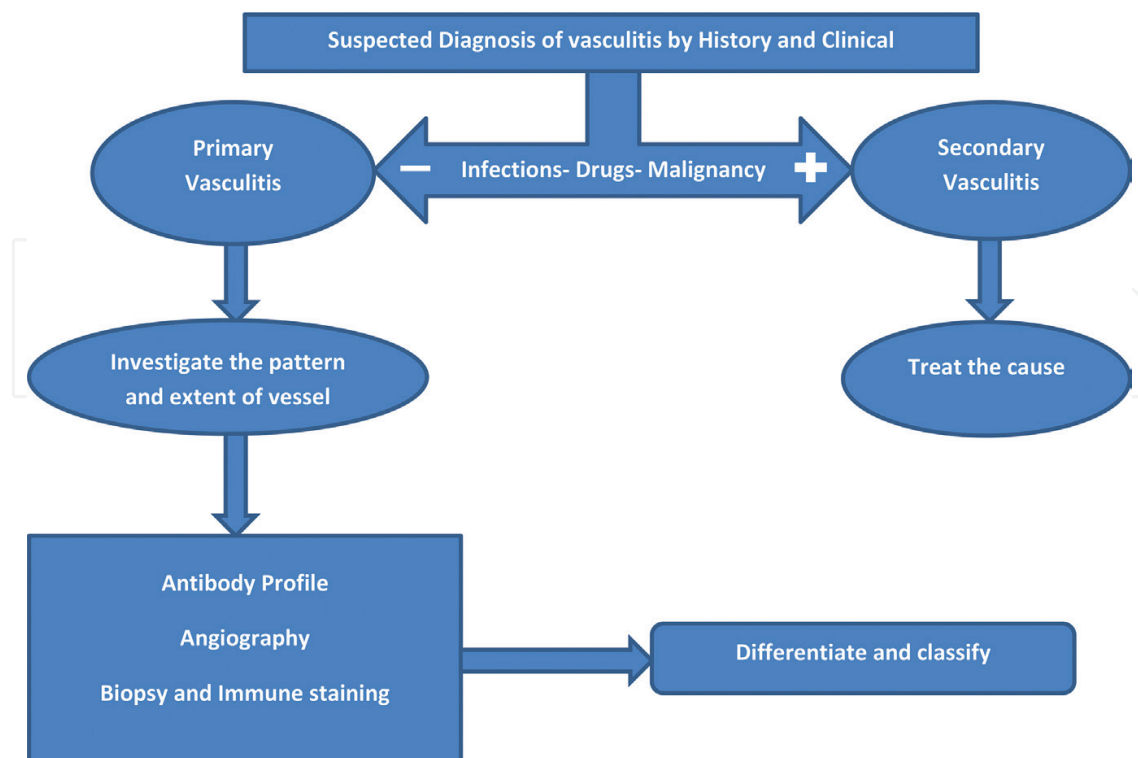


Figure 2. Algorithm for approaching diagnosis in vasculitis.

complex-mediated small vessel vasculitis with a special focus on renal disease among other vasculitis-related pathologies.

## Author details

Reem Hamdy A. Mohammed

Address all correspondence to: [rmhamdy@yahoo.com](mailto:rmhamdy@yahoo.com)

Department of Rheumatology and Rehabilitation, Kasr Alaini School of Medicine, Cairo University, Egypt

## References

- [1] Hoffman G, Calabrese L. Vasculitis: Determinants of disease patterns. *Nature Reviews Rheumatology*. 2014;**10**:454-462
- [2] Elefante E, Tripoli A, Ferro F, Baldini C. One year in review: Systemic vasculitis. *Clinical and Experimental Rheumatology*. 2016;**34**(Suppl. 97):S1-S6
- [3] Jennette JC, Folk RJ, Andrassy K, et al. Nomenclature of systemic vasculitides: The proposal of an international consensus conference. *Arthritis and Rheumatism*. 1994;**37**: 187-192
- [4] Falk RJ, Gross WL, Guillevin L, Hoffman GS, Jayne DR, Jennette JC, et al. American College of Rheumatology; American Society of Nephrology; European League Against Rheumatism. Granulomatosis with polyangiitis (Wegener's): An alternative name for Wegener's granulomatosis. *Arthritis and Rheumatism*. 2011 Apr;**63**(4):863-864
- [5] Jennette JC, Folk RJ, Bacon K, et al. 2012 revised International Chapel Hill Consensus Conference nomenclature of vasculitides. *Arthritis and Rheumatism*. 2013;**65**:1-11
- [6] Okazaki T, Shinagawa S, Mikage H. Vasculitis syndrome—Diagnosis and therapy. *Journal of General and Family Medicine*. 2017;**18**:72-78