

We are IntechOpen, the world's leading publisher of Open Access books Built by scientists, for scientists

4,800

Open access books available

122,000

International authors and editors

135M

Downloads

Our authors are among the

154

Countries delivered to

TOP 1%

most cited scientists

12.2%

Contributors from top 500 universities



WEB OF SCIENCE™

Selection of our books indexed in the Book Citation Index
in Web of Science™ Core Collection (BKCI)

Interested in publishing with us?
Contact book.department@intechopen.com

Numbers displayed above are based on latest data collected.
For more information visit www.intechopen.com



Donor-Specific Anti-HLA Antibodies in Organ Transplantation: Transition from Serum DSA to Intra-Graft DSA

Tsukasa Nakamura, Hidetaka Ushigome,
Takayuki Shirouzu and Norio Yoshimura

Additional information is available at the end of the chapter

<http://dx.doi.org/10.5772/intechopen.79846>

Abstract

In the field of organ transplantation, donor-specific anti-HLA antibodies (DSA) have gained more popularity, as antibody-mediated rejection (AMR) has been recognized as an important factor to determine allograft survival. Thus, it is reasonable to believe that appropriate control of DSA is directly linked to well-managed immunosuppression, resulting in free from AMR. First, in order to prevent and manage AMR, it is of vital importance to be familiar with updated knowledge regarding crossmatch test and DSA detection methods, including intra-graft DSA. Second, it is also crucial to understand the standard criteria to diagnose AMR. Although pathological diagnosis and serum DSA (s-DSA) detection play the central role, the recent trend seems to be detection of intra-graft DSA (g-DSA). Third, regarding organ transplantation between sensitized pairs, the acceptable outcomes are obtained owing to recent preoperative desensitization protocols: depletion/modification of B cells, apheresis for antibodies, and inhibition of reaction between DSA and HLA. Finally, we would like to discuss the treatment of AMR. Further advances in diagnosis methods and emergences of effective treatments would be expected for acceptable control of AMR. In this chapter, we will review from the basics to recent topics in order to understand DSA and AMR.

Keywords: organ transplantation, antibody-mediated rejection, donor-specific anti-HLA antibodies, intra-graft donor-specific anti-HLA antibodies, immunocomplex capture fluorescence analysis

1. Introduction

Recent advances in immunosuppression permit for organ transplantation between sensitized recipients and donors with acceptable outcomes. However, it is true that the management of acute or, in particular, chronic antibody-mediated rejection (AMR) due to donor-specific anti-HLA antibodies (DSA) is still a crucial issue to improve long-term graft survival. Because chronic changes of AMR are irreversible, it is also true that an early accurate diagnosis of AMR is required to prevent severe consequences. Thus, it is reasonable to believe that DSA is a main research topic to improve the outcome of organ transplantation. In the 1960s, the introduction of azathioprine brought the beginning of contemporary organ transplantation [1]. Following this era, incompatibilities, anti-AB [2, 3] and anti-HLA antibodies [4], were recognized as a crucial barrier for organ transplantation. In the next half-century, the main attention was paid to cellular rejection: T-cell-mediated rejection [5]. This resulted in the development of calcineurin inhibitors [6] and several antibody drugs [7]: a depletion of lymphocytes that enabled the control of T-cell-mediated rejection. However, AMR remains an important issue that is still not addressed. Then, DSA have finally received strong attention in the twenty-first century because DSA are important factors to determine long-term graft survival. In this chapter, we will review DSA in organ transplantation and discuss effectiveness of a novel application of immunocomplex capture fluorescence analysis (ICFA), as well as crossmatch examinations, protocols of desensitization, and outcomes of crossmatch positive organ transplantation.

2. Assessment for donor-specific anti-HLA antibodies

To assess reactive DSA in recipient serum, a crossmatch test or measurement of DSA is performed routinely in clinical organ transplantation. There are several crossmatch methods: lymphocyte cytotoxic test (LCT), flow cytometry crossmatch (FCXM), and ICFA. In addition to crossmatch test, antibody detection methods such as flow PRA screening and single antigen bead assay (SAB) are utilized in clinical settings. Generally, it is important to understand the advantages and disadvantages of these methods and interpret appropriately.

2.1. Lymphocyte cytotoxic test

Antigen–antibody and complement-dependent reactions are observed in this traditional direct-crossmatch test. Donor lymphocytes are incubated in the recipient serum, followed by the addition of complements. Under the circumstances where there are DSA in the recipient serum, lymphocytes are necrotized by the complement-dependent cytotoxicity reaction. Then, adding eosin dye, the ratio of necrotized lymphocytes is counted by a phase-contrast microscopy (**Figure 1**). The disadvantages of LCT are relatively low sensitivity, difficulty in obtaining donor alive lymphocytes, and subjective judges. Furthermore, it should be noted that sometimes non-DSA reaction can be observed. Conversely, only this traditional method is capable of visualizing real reactions against donor cells, including non-DSA reactions [8]. Thus, it is true that careful attention should be paid when positive reaction in LCT is detected [9].

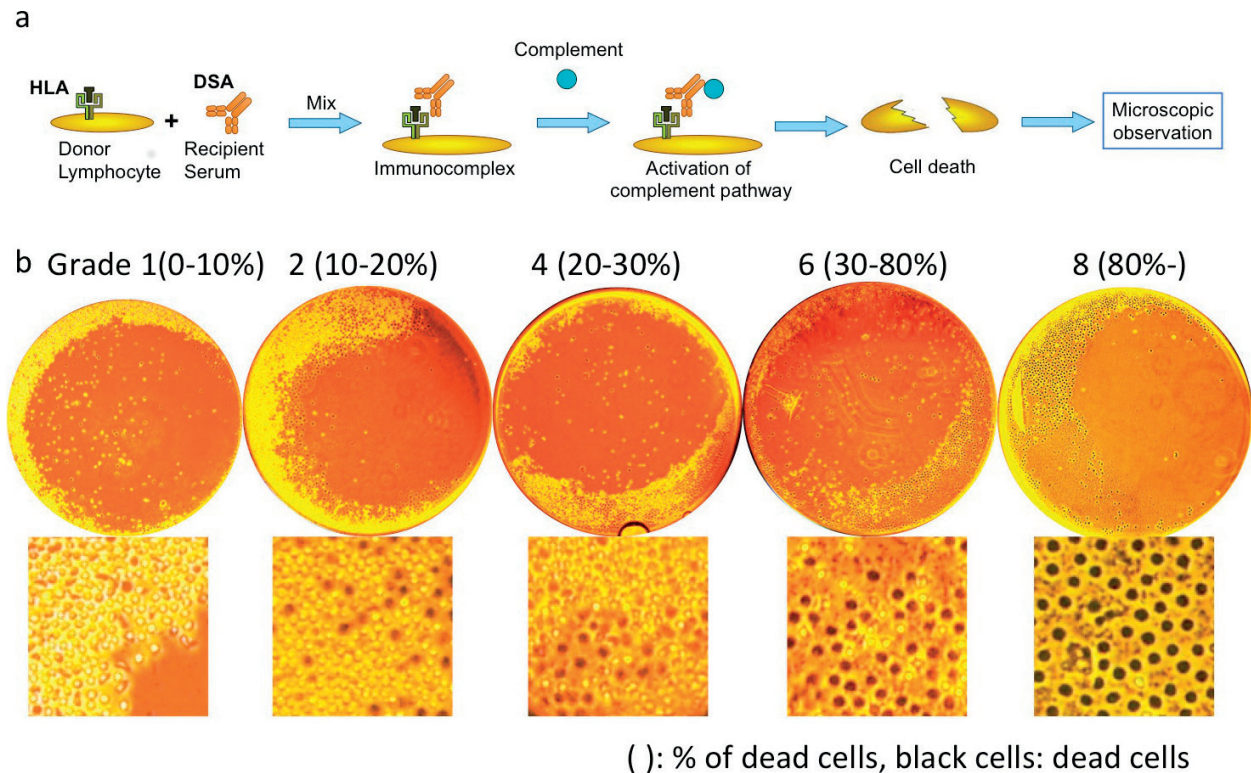


Figure 1. Lymphocyte cytotoxicity test (LCT). (a) Schematic presentation of LCT. (b) Representative results of LCT. Necrotized lymphocytes were stained in black by eosin dye. Negative reaction (grade 1–2) and positive reaction (grade 4–8).

2.2. Flow cytometry crossmatch

FCXM is an examination that flow cytometry technology is applied. As characteristics of FCXM test, sensitivity is high enough to detect a slight amount of DSA. Therefore, it should be paid attention that non-HLA antibodies might be detected: false positive. Because of high-sensitivity examination, rigorous quality control is required. To apply FCXM, donor lymphocytes and recipient serum samples were utilized. Subsequently, antihuman IgG antibodies are added and positivity is determined [10]. In addition, to add CD3 or CD19, T cells and B cells can be separated and analyzed simultaneously (Figure 2).

2.3. Immunocomplex capture fluorescence analysis

WAKFlow HLA antibody class I and II ICFA (Wakunaga Pharmaceutical Co., Ltd., Osaka, Japan) is one of the crossmatch tests by using donor lymphocytes and recipient serum [11]. This technique can detect DSA immunocomplex with high specificity [12]. As a detection system, Luminex xMAP technology (Luminex Corporation, Austin, TX) is applied. Schematic presentation of ICFA is shown in Figure 3. First, HLA and DSA complexes are formed following the reaction between donor lymphocytes and recipient serum containing DSA. Second, lymphocytes are lysed and complexes remain in lysates. Third, these complexes are captured by anti-HLA monoclonal antibodies fixed on Luminex beads, and subsequently PE-conjugated human anti-IgG is added. Finally, Luminex system detects these PE-conjugated anti-human

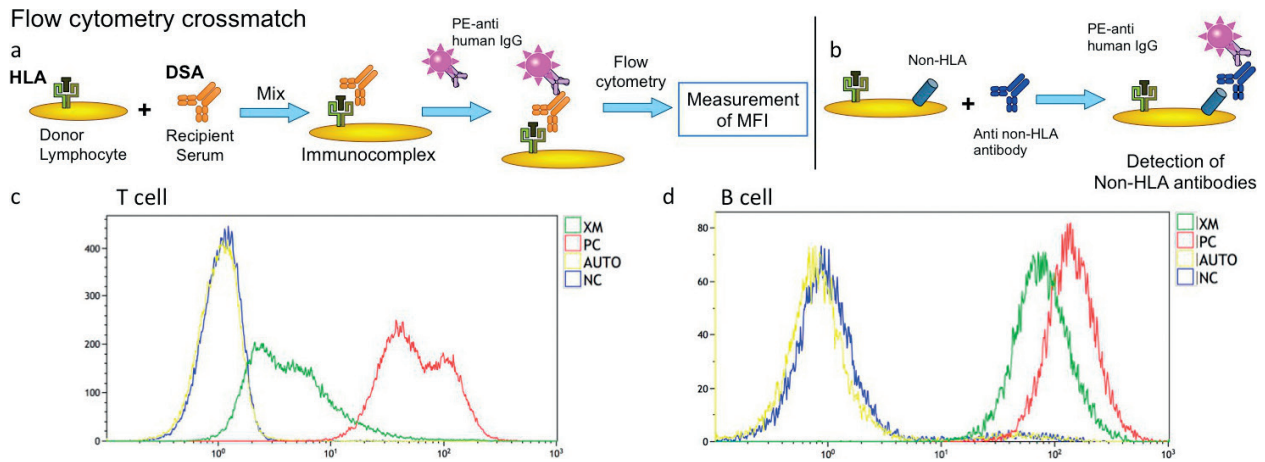


Figure 2. Flow cytometry crossmatch (FCXM). (a) Schematic presentation of FCXM. (b) an example of positive reaction by non-HLA antibodies. (c), (d) representative results of FCXM using T cell (c) or B cell (d).

Immunocomplex Capture Fluorescence Analysis

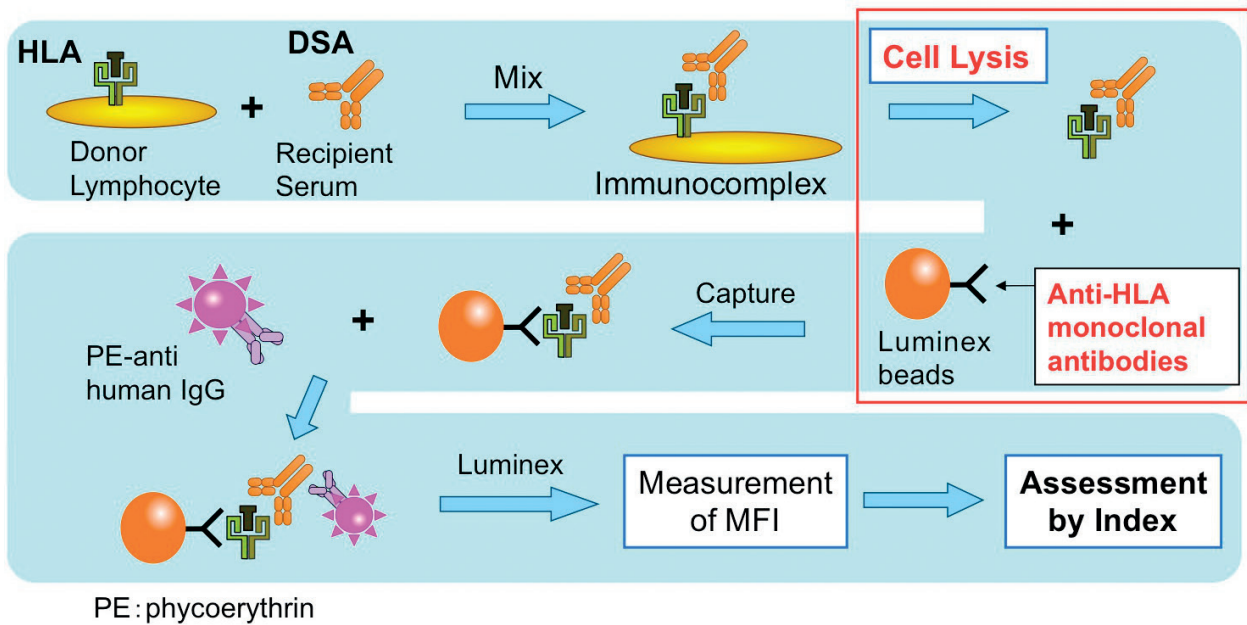


Figure 3. Schematic presentation of immunocomplex capture fluorescence analysis (ICFA).

IgG signals. As ICFA characteristics, the following features are noted: (1) the specificity of identifying HLA antibodies is high, and (2) class I and II antibodies can be identified separately. Furthermore, in terms of recent advances in ICFA, DR, DQ, and DP, DSA can be identified separately.

2.4. FlowPRA screening

To identify anti-HLA antibodies in serum, FlowPRA screening test is performed. First, a reaction is caused between anti-HLA antibodies and latex beads coated with HLA antigens. Then,

FITC-conjugated antihuman IgG is added. Subsequently, mean fluorescence intensity (MFI) and shift from negative control are calculated based on flow cytometry analyses (**Figure 4**). Each mixed class I and II HLA antigen is separately coated on latex beads, derived from about 30 types of panel cells [13]. Depending on the human race, there is a possibility that rare HLA

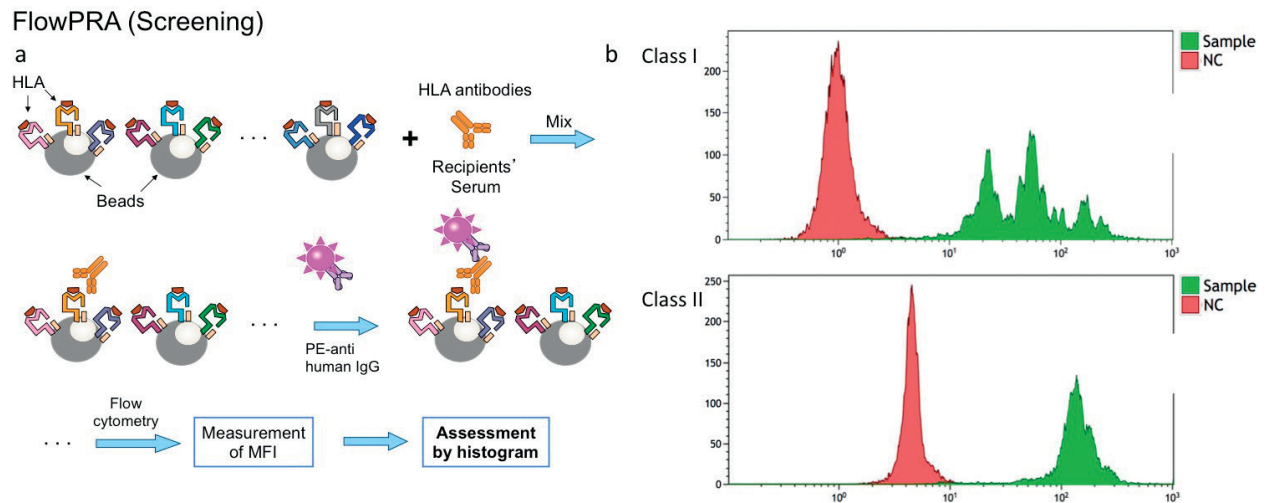


Figure 4. FlowPRA screening. (a) Schematic presentation of FlowPRA screening. (b) Examples of positive FlowPRA screening results about class I (upper) and class II (lower).

Single Antigen bead assay

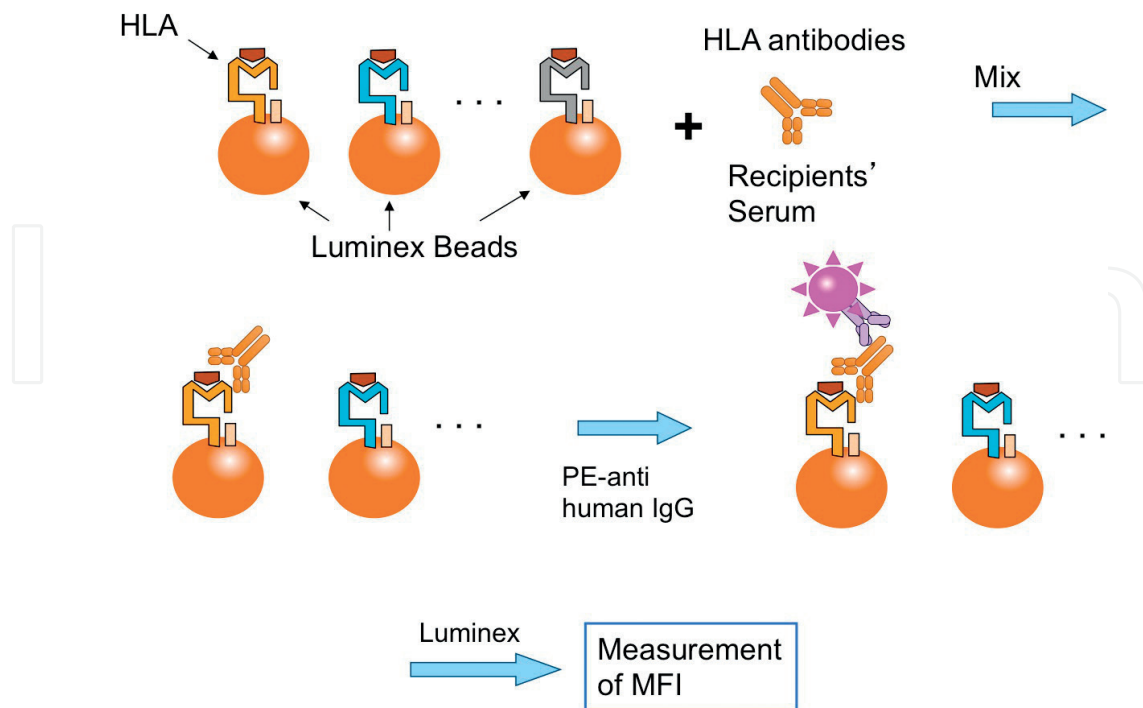


Figure 5. Schematic presentation of single antigen bead assay (SAB).

antigens are not covered. These disadvantages should be recognized. Generally, if a positive reaction would be observed, the following SAB is applied to identify the specificity of anti-HLA antibodies.

2.5. Single antigen bead assay

To identify the specificity of anti-HLA antibodies, SAB is performed when crossmatch test and/or FlowPRA is positive. First, a reaction is observed between anti-HLA antibodies and Luminex beads coated with a single HLA antigen extracted from gene-modified cells. Following steps are similar to those of FCXM. Finally, these reactions, MFI of PE signals, were calculated by Luminex system (Luminex Corporation). According to HLA typing of donor, the presence of DSA is judged. It is often used in LABScreen single antigen HLA class I/II beads: LABScreen single antigen class I/LABScreen single antigen class II (One Lambda Inc., Canoga Park, CA) or WAKFlow HLA antibody class I HR and WAKFlow HLA antibody class II HR (Wakunaga Pharmaceutical Co., Ltd) (**Figure 5**). As an important point, because these single HLA antigen beads do not include all types of HLA antigens, we should be familiar with SAB kit to judge the existence of DSA appropriately.

3. Assessment for intra-graft donor-specific anti-HLA antibodies

Due to recent advances in examinations for DSA, the assessment for g-DSA has been paid attention. In fact, it is hard to understand that s-DSA damage allografts without localization in target organs. Thus, hereafter, the assessment of g-DSA would gain more popularity as diagnosis or prognosis factors. Although the presence of g-DSA is not included in AMR diagnosis criteria currently, g-DSA might be a key criterion for considering AMR in the near future. It would be better that clinicians and researchers are aware of this novel topic. Here, we will present representative two different methods. We will also delve into graft ICFA technique in this section.

3.1. Dissociation between HLA and DSA (acid elution method)

To obtain free DSA from allografts, dissociation HLA and DSA complexes are attempted. So far, g-DSA detection in the kidney [14–16], liver [17], and lung [18] were reported. This method requires the following steps: (1) Wash more than seven times to prevent from detection s-DSA incorrectly. (2) Dissociate these complexes by acid (buffer). (3) Detect dissociated DSA by SAB (**Figure 6**). As compared to graft ICFA, mentioned later, acid elution method has weak points regarding simplicity and remains doubtful points whether DSA denature or not during the acid elution step. However, SAB analysis following acid elution seems to be accepted widely and allows to identify specific DSA even where multiple candidate DSA exist. The common recognition of g-DSA assessment seems to be that g-DSA is an important factor to determine graft survival and more sensitive than s-DSA [14].

3.2. Graft immunocomplex capture fluorescence analysis (non-dissociation technique)

WAKFlow HLA antibody class I and II ICFA is an attractive tool to identify HLA/DSA complexes as mentioned above, by means of WAKFlow HLA antibody class I and II (Wakunaga

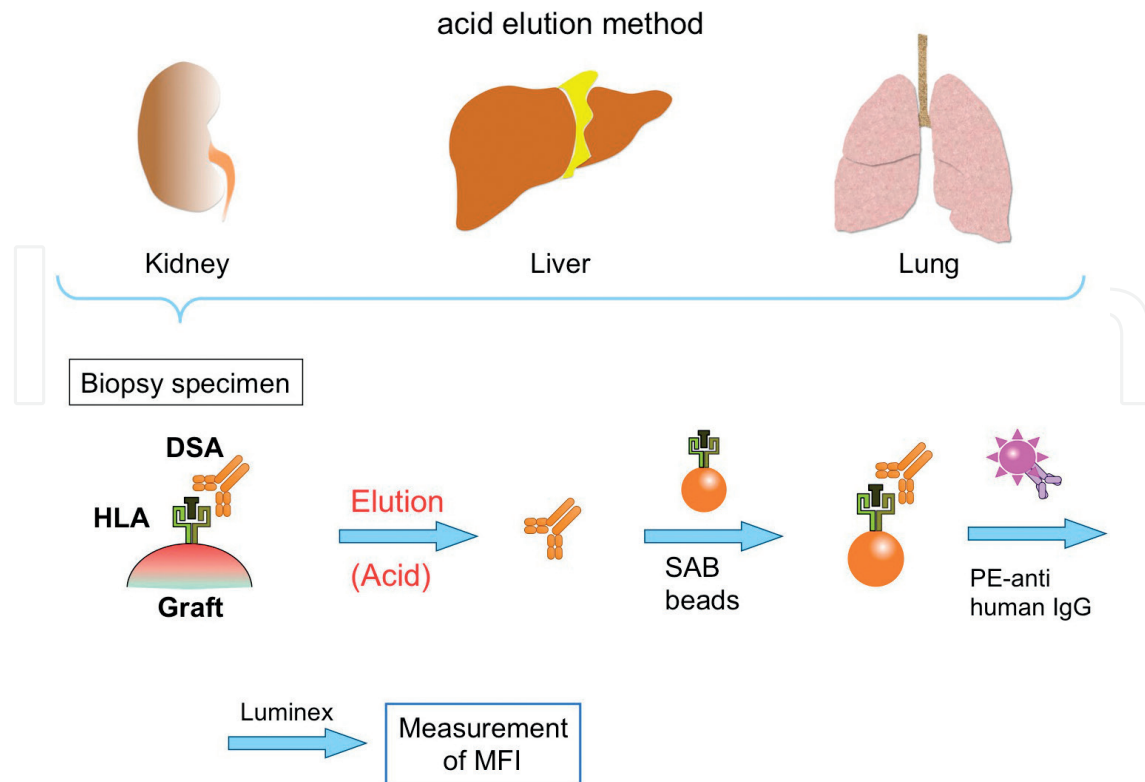


Figure 6. The flowchart of the acid elution method (dissociation technique).

Pharmaceutical). It is not only for serum of recipients but also for allograft specimens. The first graft ICFA was introduced as an effective tool for detection of g-DSA in 2017 [19, 20]. Graft ICFA can be performed as previously described by Nakamura et al. Graft samples were obtained by means of a percutaneous needle biopsy. To standardize the results of graft ICFA, 2 mm specimen was used for each analysis. Regarding graft ICFA to identify HLA expression, samples were washed enough in PBS. As compared to acid elution method of DSA from grafts associated to g-DSA detection by SAB, graft ICFA does not allow to identify individual responsible HLA alleles, such as HLA-A24, etc. However, in the setting of real organ transplantation, generally HLA alleles are identified prior to transplantation. Thus, it does not seem to be difficult to narrow down candidate HLA. It is true, therefore, that current graft ICFA is clinically useful to diagnose AMR. Moreover, the combination of acid elution method and graft ICFA allows to obtain useful information regarding g-DSA. Further advances in graft ICFA would be expected.

(Ethics Committee approval was obtained from the internal research ethics committee of Kyoto Prefectural University of Medicine. The clinical trial registration number is UMIN000023787.)

3.3. Data interpretation

MFI of samples was calculated by the Luminex system. A ratio of sample MFI/blank beads MFI of all negative samples, including HLA matched recipients' samples, + 2SD is demonstrated below 0.9 (data not shown) (please refer to [19, 20]). Then the ratio was determined, and ≥ 1.0 was considered as a positive result. Furthermore, to compensate baseline reaction, the following index was also calculated. Index = $(X_{HLA} - (N_{HLA} - N_{BB})X_{BB}/N_{BB})/X_{BB}$; X_{HLA} , sample

MFI; X_{BB} sample blank beads MFI; N_{HLA} the mean MFI of negative samples; and N_{BB} the mean blank beads MFI of negative samples. Given the results of negative samples, the index ≥ 1.5 was considered as a positive result.

3.4. DSA-HLA complexes in the liver, heart, lungs, pancreas, and small intestine are also successfully detected by graft ICFA

To confirm whether graft ICFA can be applied to other organs besides the kidney [19, 20], we employed ten liver transplant recipients and a liver transplant recipient who underwent autopsy due to primary graft dysfunction. Samples of other possible organs such as the heart, lung, pancreas, and small intestine from this patient were pretreated according to the graft ICFA preparation method. Contaminated blood cells in samples were minimum, confirmed by histology. Luminex analyses detected PE signals from the positive control samples in all organs. Thus, it can be concluded that graft ICFA can be applied for all organ transplantation (**Figure 7**).

3.5. Sensitivity and specificity of graft ICFA to determine pathological AMR in renal transplantation

In order to prove a hypothesis—graft ICFA is useful to detect g-DSA and AMR—a total of 40 Japanese renal transplant recipients were included prospectively. They underwent graft biopsy and were examined by graft ICFA as previously described [19, 20]. According to the results of graft ICFA, these patients were divided into the g-DSA+ and g-DSA- groups to assess

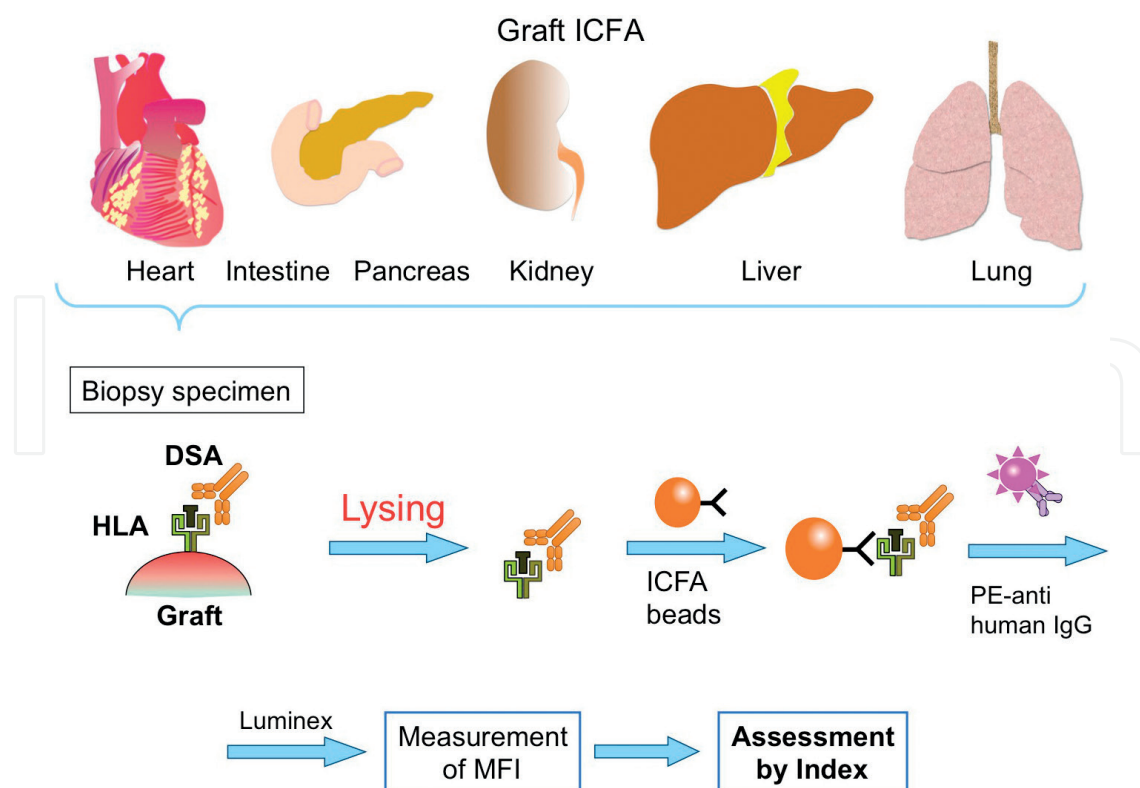


Figure 7. Intra-graft DSA (g-DSA) in all possible allografts can be analyzed by graft ICFA.

the sensitivity and specificity of graft ICFA to predict pathological AMR. In the current study, this technique has demonstrated 100% sensitivity (12/12) and 92.9% specificity (26/28). Thus, it is reasonable to believe that positive graft ICFA results strongly suggest the onset of AMR.

4. Diagnosis of antibody-mediated rejection

4.1. Renal transplantation

With renal allograft dysfunction, it can be diagnosed as AMR, provided that C4d deposited in peritubular capillaries (ptc) and antibodies or complement deposition are confirmed in vascular fibrinoid necrosis, in addition to s-DSA detection. Recently, AMR can be diagnosed according to the Banff classification 2015 [21].

Acute AMR:

The following three criteria should be met when acute AMR is diagnosed:

1. Histological features of acute tissue injury, including at least one of the following
 - Microvascular inflammation $g > 0$ (excluding recurrent or de novo glomerulonephritis), $ptc > 0$, or $v > 0$ (intimal/transmural arteritis).
 - Acute thrombotic microangiopathy (without any other apparent reasons).
 - Acute tubular injury (without any other apparent reasons).
2. Histological features due to DSA and vascular endothelium reaction
 - Linear C4d deposition in ptc (C4d2 or C4d3 (frozen sections)/C4d > 0 (paraffin embedded sections))
 - Moderate microvascular inflammation $g + ptc \geq 2$.
 - Detection of genetic transcript expression in biopsy specimens due to endothelial injury.
3. Detection of s-DSA

Chronic AMR:

The following three criteria have to be met:

1. Histological features of chronic tissue injury, including at least one of the following
 - Transplant glomerulopathy ($cg > 0$), in the case of no chronic thrombotic microangiopathy, includes histologic features detected by electron microscope (EM).
 - Severe ptc basement membrane multilayering by EM.
 - New onset of arterial intimal fibrosis (without any other apparent reasons).

2. Histological features due to DSA and vascular endothelium reaction

- Linear C4d deposition in PTC (C4d2 or C4d3(frozen sections)/C4d > 0 (paraffin embedded sections))
- Moderate microvascular inflammation $g + ptc \geq 2$.
- Detection of genetic transcript expression in biopsy specimens due to endothelial injury.

3. Detection of serum DSA

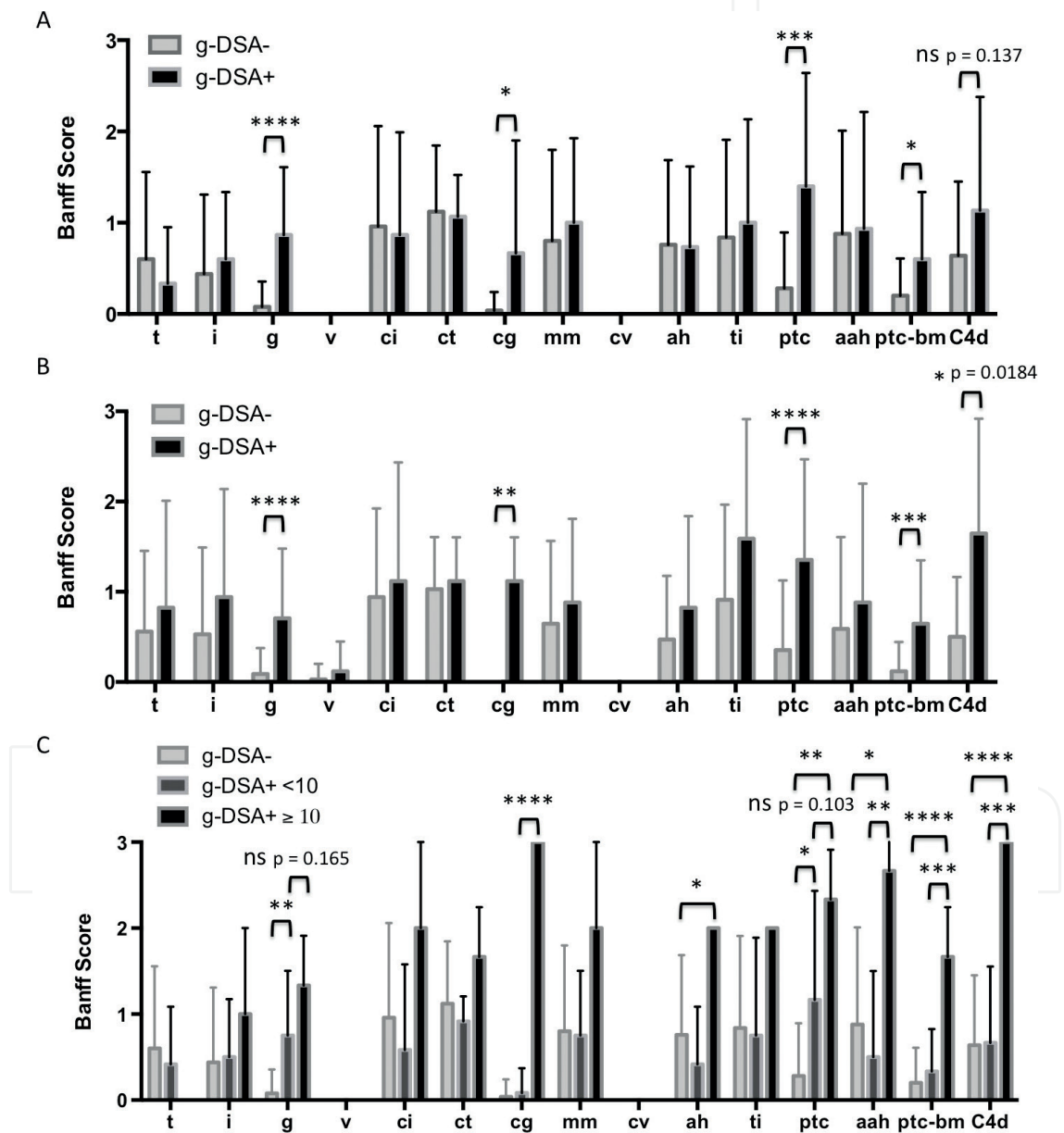


Figure 8. Histopathological impacts of g-DSA presence. A. The Banff histologic scores are analyzed individually based on the g-DSA status: G-DSA- or g-DSA+. B. The Banff histologic scores based on the g-DSA status: G-DSA- or g-DSA+ without ABO-incompatible cases. C. These items are reanalyzed depending on g-DSA values: G-DSA-, g-DSA < 10, and g-DSA ≥ 10, including ABO-incompatible cases. ****p < 0.0001, ***p < 0.0005, **p < 0.005, and *p < 0.05.

4.1.1. *The presence of g-DNA (graft ICFA) is associated with microvascular lesions in renal transplantation*

To confirm the consistency of graft ICFA results, the individual scores of the Banff classification were analyzed between g-DNA- and g-DNA+ renal transplant recipients (g-DNA+ 15, g-DNA- 25 recipients). As a result, individual g, cg, ptc, and ptc-bm scores were significantly higher in g-DNA+ patients. Interestingly, there was no apparent difference in the C4d staining score, primarily due to the presence of ABO-incompatible cases in both groups (32.0% and 33.3% in the g-DNA- and + groups, respectively) (**Figure 8A**). Thus, ABO-incompatible cases were removed from both groups. Then, the C4d result showed that 0.45 ± 0.17 and 1.73 ± 0.33 in the g-DNA- and g-DNA+ groups, respectively ($p = 0.0184$) (**Figure 8B**). Next, g-DNA+ patients were divided into low g-DNA group, g-DNA+ < 10, and high g-DNA group, g-DNA+ ≥ 10 . Then, this result demonstrated that g and ptc deteriorated in g-DNA concentration manner. In contrast, only g-DNA+ ≥ 10 group showed significant higher scores in cg, mm, ptc-bm, and C4d (**Figure 8C**). These results might indicate that g-DNA causes microcirculation lesions and high g-DNA means chronic allograft damages. To correspond to a recent functional concept, g + ptc (microvascular inflammation), g + cg + ptc (microvascular lesions), and cg + mm (microvascular deterioration), we also analyzed these scores again. Expectedly, g + ptc and g + cg + ptc deteriorated stepwise according to g-DNA scores, but cg + mm referring chronic lesions is clearly higher only in the g-DNA ≥ 10 group (**Figure 9**). It is true, therefore, that g-DNA assessment by graft ICFA accurately supports the diagnosis of AMR.

4.2. Liver transplantation

Generally, it is often discussed that liver allografts tend to be resistant against AMR due to Kupffer cell DSA clearance, HLA expression in microvasculature, allografts size, and regenerative capacity of the liver. Diagnosis criteria are suggested in the Banff meeting [22].

Define acute AMR:

The following four criteria should be met to diagnose acute AMR:

1. Histological features of acute tissue injury, including at least one of the following
Portal microvascular endothelial cell hypertrophy, eosinophilic and neutrophilic portal microvasculitis, portal edema, and ductular reaction; cholestasis is usually present but variable; edema and periportal hepatocyte necrosis, active lymphocytic, and/or necrotizing arteritis.
2. Positive s-DNA.
3. Diffuse microvascular C4d staining (C4d = 3).
4. Excluding other lesions possibly mimic AMR.

Suspicious for AMR (both criteria required).

Serum DSA + and positive histopathology score (h-score) (C4d + h-score ≥ 3).

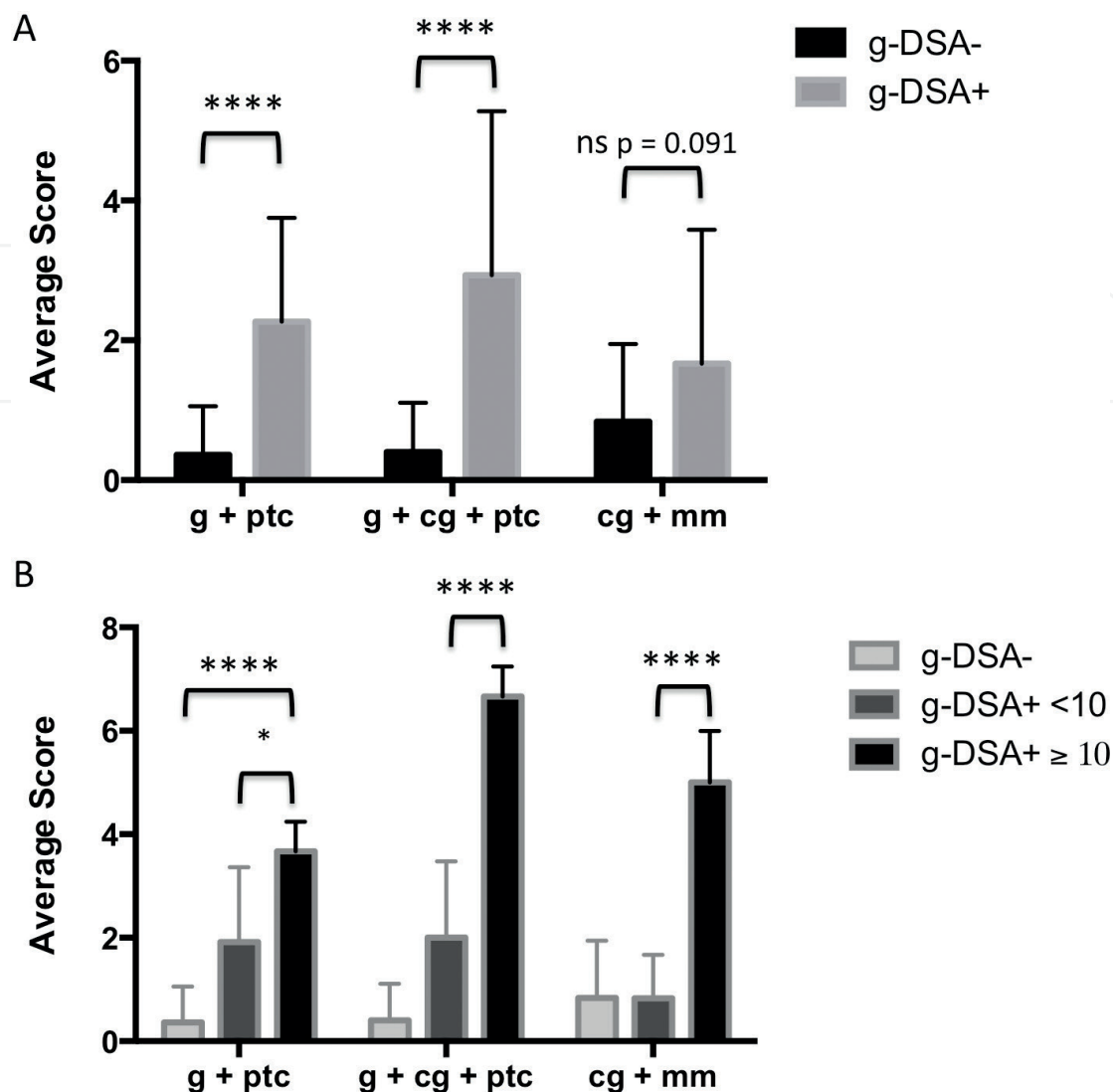


Figure 9. G-DSA effects on the functional clusters of the Banff classification. The functional clusters, g + ptc (microvascular inflammation), g + cg + ptc (microvascular lesions), and cg + mm (microvascular deterioration), are analyzed according to the presence or absence of g-DSA (A) and g-DSA values: G-DSA-, g-DSA < 10, and g-DSA ≥ 10 (B). **** $p < 0.0001$ and * $p < 0.05$.

Indeterminate for AMR:

1. C4d + h-score ≥ 2.
2. DSA and C4d immunohistochemistry not available and not apparent.
3. Coexisting pathophysiology might cause similar injury.

Liver allograft chronic active AMR is also considered as an important factor for determining long-term outcome [23, 24]. Chronic active AMR is diagnosed when the condition meets the all following criteria:

1. Histologic features consistent with chronic active AMR. (a) At least mild mononuclear portal and/or perivenular inflammation with interface and/or perivenular necroinflammatory activity. (b) At least portal/periportal, sinusoidal, and/or perivenular fibrosis.

2. Detection of serum DSA.
3. Focal C4d deposition in portal tract microvascular endothelia (> 10%).
4. Other lesions can be denied.

4.3. Heart transplantation

Following heart transplantation, the onset of AMR is generally estimated around 10–20% [25]. In the field of heart transplantation, AMR is also considered as an important prognosis factor. In fact, the consequences are severe, and the development of cardiac allograft vasculopathy (CAV) has a huge impact. As with other organ transplantations, timing of AMR onset is diverse: both acute AMR within 1 week after transplantation and chronic AMR in the remote period can be seen. Again, allograft biopsy also plays a crucial role to accurately diagnose AMR. Repeated allograft biopsies seem to be required for achieving good long-term outcomes. Interestingly, regarding de novo DSA synthesized after 2 months following heart transplantation, class II DSA are dominant [25].

Diagnosis criteria of heart allograft AMR were discussed in the international society for heart and lung transplantation working formulation consensus [26]. First of all, substrates were divided into two categories: histologic investigations (H) and immunopathologic studies (I). Histologic features of heart AMR are as follows: activated mononuclear cell infiltration, interstitial edema, hemorrhage, necrosis, and vascular thrombosis. On the other hand, C4d, CD68 (paraffin section), C4d, or C3d (frozen section) are considered mandatory panels of immunopathologic studies. Furthermore, CD3, CD20, C3d, endothelial cell CD31 or CD34, complement regulatory proteins (paraffin section), and fibrin and immunoglobulin G/M (frozen section) are regarded as secondary or optional panels. In total, the current report of AMR in heart is noted from Grade 0 to 3 as follows:

pAMR 0: negative for pathologic AMR (H0/I0)

pAMR 1(H+): histopathologic AMR (H+/I-)

pAMR 1 (I+): immunopathologic AMR (H-/I+)

pAMR 2: pathologic AMR (H+/I+)

pAMR 3: severe AMR (interstitial hemorrhage, capillary fragmentation, mixed inflammatory cell infiltration, endothelial cell pyknosis and/or karyorrhexis, and marked edema and I+)

pAMR 3 cases usually demonstrate severe hemodynamic dysfunction and poor consequences.

Scoring system of criteria for pathologic diagnosis of cardiac AMR is slightly different between immunohistochemistry and immunofluorescence analyses. These criteria are summarized in **Table 1**.

4.4. Lung transplantation

Regarding AMR following lung transplantation, the main reason is also DSA, although a role of non-HLA antibodies was also described [27]. Hachem et al. [28] have reported, in 2010, a prospective study on AMR after lung transplantation, which deepened our

Immunohistochemistry scoring system				Immunofluorescence scoring system			
Capillary C4d distribution	0	< 10%	Negative	Capillary C4d/C3d distribution	0	< 10%	Negative
	1	10–50%	Focal		1	10–50%	Focal
	2	> 50%	multifocal/diffuse		2	> 50%	Multifocal/diffuse
Capillary C4d intensity	0	Negative/equivocal		Capillary C4d/C3d intensity	0	Negative/equivocal	
	1	Faint positive			1	Faint positive = 0–1+	
	2	Strong positive			2	Strong positive = 2–3+	
Intravascular CD68 distribution	0	< 10%	Negative	HLA-DR distribution	0	< 10%	Negative
	1	10–50%	Focal		1	10–50%	Focal
	2	> 50%	Multifocal/diffuse		2	> 50%	Multifocal/diffuse
				HLA-DR intensity	0	Negative/equivocal	
					1	Faint positive = 0–1+	
					2	Strong positive = 2–3+	

Table 1. Immunohistochemistry and immunofluorescence scoring system in heart AMR.

understanding of clinical AMR managements. In 2016, a consensus statement has been proposed from the international society for heart and lung transplantation [29].

Lung allograft AMR can be divided into clinical and subclinical AMR, depending on whether there is allograft dysfunction or not. Next, as similar to other organs, these clinical and subclinical AMR are subcategorized as define, probable, or possible. To determine certainty of clinical AMR, the following five criteria are proposed: allograft dysfunction, other causes excluded, lung histology, lung biopsy C4d, and s-DSA. Define lung AMR is determined by positive for all five criteria. In case anyone of them is negative, it is considered as probable AMR, excluding allograft dysfunction (**Table 2**). There are histopathologic features of AMR, including the following—neutrophil margination, neutrophil capillaritis/arteritis without any signs of pneumonia, or other apparent reasons—though these features are not specific for lung AMR. In terms of lung histology, further advancement and organization would be required.

4.5. Small bowel transplantation

Due to recent increased recognition of AMR, AMR is also considered as a serious issue in the small bowel transplantation field. However, the define diagnosis criteria have not been established in the small bowel transplantation yet. There are few series of case reports in terms of intestine AMR. Although common understandings of AMR also seem to be C4d deposition, capillaritis, and s-DSA positivity [30], there is a report which did not find clinical evidence between C4d positivity and the onset of AMR [31]. The establishment of diagnostic criteria should be required to standardize and manage AMR in intestine transplantation. The future contribution of g-DSA assessment would be also expected in this field.

	Allograft dysfunction	Other causes excluded	Lung histology compatible with AMR	C4d	s-DSA
Define	+	+	+	+	+
Probable*	+	+	+	-	+
	+	-	+	+	+
	+	+	-	+	+
	+	+	+	+	-
Possible	+	-	-	+	+
	+	+	-	-	+
	+	+	+	-	-
	+	-	+	-	+
	+	-	+	+	-
	+	+	-	+	-

There is growing evidence that C4d negative AMR exists. Thus, the second line * cases are considered as an independent group.

Table 2. Lung AMR diagnosis criteria.

5. Preoperative desensitization

To perform organ transplantation between a sensitized recipient and donor pair, preoperative desensitization is required. Generally, crossmatch positive organ transplantation is mainly performed in kidney and liver transplantation. Desensitization can be divided into three main treatments: depletion/modification of B cells, apheresis for antibodies, and inhibition of reaction between DSA and HLA. The golden standard of B-cell depletion therapy is rituximab (anti-CD20 antibodies) administration [32–35]. There are a wide variety of rituximab administration protocols in terms of a dosage and schedule. In our institution, generally, rituximab (375 mg/m²) is administered in 2 weeks prior to organ transplantation [20]. Subsequent B-cell count in the peripheral blood is measured by flow cytometry. In addition to rituximab, to deplete B cells, anti-CD52 antibodies (alemtuzumab) also can be used, because higher than 95% B cells express CD52 on the cell surface [36]. It has been reported that alemtuzumab-combined regimens are safe and effective for highly sensitized recipients [36, 37]. Other antibodies' introduction would be expected regarding induction regimens.

To decrease DSA production and reaction, the importance of intravenous immune globulin (IVIG) has been reported. IVIG infusion significantly decreased the baseline flowPRA levels [38]. There is a variety of reports regarding the dosage and duration of IVIG (100 mg/kg/day–4 g/kg/day, etc.), partially due to the cost problems.

Regarding apheresis therapy, double filtration plasmapheresis (DFPP) or plasma exchange (PE) is generally performed. Usually, as an index of DSA titer, MFI has gained its popularity. Given the fact of g-DSA and s-DSA assessments, DSA with MFI < 2500 might not deposit and cause clinical damages to allografts. Thus, although it depends on each institution, acceptable DSA MFI prior to surgery might be estimated around 2000 [20] in renal transplantation. However, on the other hand, intensive posttransplant desensitization also can result in

comparable outcomes with non-sensitized transplantation [39]. For highly sensitized recipients, a phased desensitization protocol by using rituximab and bortezomib was advocated [34]. In fact, it is true that rituximab administration can deplete B cells but not plasma cells. Thus, it is reasonable to believe that rituximab and bortezomib combination therapy eradicates the B-cell lineage which is potentially associated with AMR.

Furthermore, the idea only relying on MFI might be unrefined. In other words, the quality of DSA is also important to determine the impact of DSA. Regarding the quality, IgG subclasses [1–4, 40] and complement fixing ability [41] seem to be paid attention, considering the severity of subsequent AMR and graft survival.

On the other hand, in liver transplantation, there seems to be no concrete evidence regarding DSA MFI just prior to transplantation. A large amount of hemorrhage during surgery and liver allograft resistance against DSA, etc., might complicate to set a MFI threshold. Nevertheless, Yoshizawa et al. [42] reported that class I DSA MFI > 10,000 has a negative impact on graft survival. Thus, it is important to keep circumstances where allograft injury due to remnant DSA is minimum and additional DSA production inhibited.

6. Treatment for antibody-mediated rejection

In other words, this is a treatment for B cells/plasma cells and DSA and reaction between DSA and HLA. Both for acute AMR and chronic active AMR, generally clinical managements also can be divided into medications and apheresis: steroid pulse, IVIG, Rituximab, etc., and DFPP or PE. In severe cases, it is true that splenectomy has a certain effect on AMR [43]. Regarding treatment for acute AMR, the concepts are the same: depletion of B cells, reduction of DSA, and inhibition of reaction between DSA and HLA. The core agents and methods are summarized in Table. It is true that high-dose steroid administration is effective on all aspects of AMR treatment. There is no fixed data to determine the dosage and duration of steroid pulse therapy. However, generally, 10–100 mg/kg/day equivalent dosage of hydrocorticoid is administered as steroid pulse therapy, depending on the severity of AMR. For depletion of B cells, rituximab, alemtuzumab, or splenectomy is utilized. To reduce DSA, DFPP, or PE, apheresis methods are commonly used in the same way as desensitization. As immunomodulation, IVIG administration also plays an important role in controlling acute AMR. Given the fact of AMR pathogenesis, complement activation should be paid attention. Final tissue injury due to AMR would occur following activation of antibody-induced terminal complement cascade. Albeit limited evidence, it has been reported that eculizumab C5 inhibitor is effective to rescue an AMR allograft [44–47].

Recently, chronic active AMR has been paid strong attention, because this pathologic condition directly deteriorates the long-term graft survival. Despite the recognition of chronic active AMR, diagnostic criteria are only established in kidney [21] and liver transplantation [22]. There seems to be no therapeutic consensus on this condition. Furthermore, it has generally resistance to ordinal AMR managements discussed above [48–50], although limited effectiveness was observed in few studies [51, 52]. Bachelet et al. [50] reported a treatment for chronic active AMR (mean eGFR 30.6 mL/min/1.73 m²) by utilizing rituximab (375 mg/m²) and IVIG (1 g/kg/week × 4 weeks). Although serum MFI tends to decrease, there is no difference in

Treatment for chronic active AMR				
Author	Organ	Treatment	Schedule	Outcomes
Billing 2012 [51]	Kidney	IVIG; Rit	1 g/kg/week for 4 weeks; 375 mg/m ² × 1	The treatment reduced or stabilized the progressive loss of transplant function in pediatric patients
Cooper 2014 [49]	Kidney	IVIG	High-dose (5 g/kg) IVIG dosed over 6 months	No clinical treatment benefit
An 2014* [54]	Kidney	IVIG; Rit	400 mg/kg × 4 days; 375 mg/m ²	The treatment delayed CAMR progression
Bachelet 2015 [50]	Kidney	IVIG; Rit	1 g/kg/week for 4 weeks; 375 mg/m ² /week in the first 2 weeks	The treatment did not seem to change the natural history of AMR
Redfield 2016 [55]	Kidney	Dex; IVIG; Rit (PE, Thymoglobulin)	100 mg of Dex; 4 weekly doses 100 mg/kg; 375 mg/m ² body, or 1000 mg	Better graft survival
Kulkarni 2017 [53]	Kidney	Eculizumab	600 mg/week for 4 weeks followed by 900 mg every 2 weeks for a total of 26 weeks	Better eGFR in patients with C1q positive
Parajuli 2017 [52]	Kidney	Dex; IVIG; Rit	100 mg; 200 mg/kg/2 weeks for 3 weeks; 375 mg/m ² /week	The treatment was effective in reducing DSA and microcirculation inflammation
Ban 2017* [56]	Kidney	IVIG; Rit	400 mg/kg × 4 days; 375 mg/m ²	The treatment reduced the progression of CAMR

*: Reported from the same group.

Table 3. Summary of recent reports on treatments for chronic active antibody-mediated rejection (AMR).

2-year graft survival between the treatment (47%) and without treatment groups (40%). These reports suggest a difficulty in the management for chronic changes in allografts. In addition to acute AMR, eculizumab was also challenged for chronic active AMR. Although there were no notable differences in eGFR between treatment and control groups, C1q-positive recipients demonstrated significant better eGFR than recipients with C1q-negative status [53]. Inhibition of complement-dependent allograft injury would bring benefits on certain population. Recent reports discussing treatment for chronic active AMR are summarized in **Table 3**.

In total, it is of vital importance to prevent from developing into chronic lesions and initiate appropriate treatment in the early stages of AMR, because fully established chronic lesions are irreversible. It is reasonable to believe that these managements lead to improvements of the long-term allograft survival.

7. Conclusion

Under the present circumstances, it is of vital importance to control AMR in advance in order to improve graft survival rate in all fields of organ transplantation. To detect early-stage AMR, clinicians need to be aware of recent advances in DSA analyses, including graft ICFA and an acid elution method to assess intra-graft DSA status. Preoperative desensitization therapies and management plans are decided depending on classes of DSA and s-DSA MFI. Conversely,

even in crossmatch-negative cases, there is a possibility that memory B cells might evoke severe AMR 1 week following transplantation. In addition, there might be a discrepancy between s-DSA and g-DSA. It is also true that only relying on s-DSA MFI is difficult to determine appropriate managements. Further research is required for addressing these issues.

Conflict of interest

None.

Abbreviation

AMR	antibody-mediated rejection
DSA	donor-specific antibodies
ICFA	immunocomplex capture fluorescence analysis
LCT	lymphocyte cytotoxic test
FCXM	flow cytometry crossmatch
SAB	single antigen bead assay
MFI	mean fluorescence intensity
g-DSA	intra-graft DSA
s-DSA	serum DSA
ptc	peritubular capillaries

Author details

Tsukasa Nakamura^{1*}, Hidetaka Ushigome¹, Takayuki Shirouzu² and Norio Yoshimura¹

*Address all correspondence to: tsukasa@koto.kpu-m.ac.jp

1 Department of Organ Transplantation and General Surgery, Kyoto Prefectural University of Medicine, Kyoto-prefecture, Japan

2 Wakunaga Pharmaceutical Co., Ltd. Molecular Diagnostics Division, Japan

References

- [1] Starzl TE, Marchioro TL, Rifkind D, Holmes JH, Rowlands DT Jr, Waddell WR. Factors in successful renal transplantation. *Surgery*. 1964;**56**:296-318

- [2] Rapaport FT, Dausset J, Legrand L, Barge A, Lawrence HS, Converse JM. Erythrocytes in human transplantation: Effects of pretreatment with ABO group-specific antigens. *The Journal of Clinical Investigation*. 1968;**47**(10):2206-2216
- [3] Paul LC, van Es LA, Riviere GB, Eernisse G, de Graeff J. Blood group B antigen on renal endothelium as the target for rejection in an ABO-incompatible recipient. *Transplantation*. 1978;**26**(4):268-271
- [4] Kashiwagi N, Corman J, Iwatsuki S, Ishikawa M, Fiala JM, Johansen TS, et al. Mixed lymphocyte culture and graft rejection. *Surgical Forum*. 1973;**24**:345-348
- [5] Wagner H, Cone RE. Adjuvant effect of poly(A:U) upon T cell-mediated in vitro cytotoxic allograft responses. *Cellular Immunology*. 1974;**10**(3):394-403
- [6] Todo S, Porter KA, Kam I, Lynch S, Venkataramanan R, DeWolf A, et al. Canine liver transplantation under Nva2-cyclosporine versus cyclosporine. *Transplantation*. 1986;**41**(3):296-300
- [7] Cosimi AB, Burton RC, Colvin RB, Goldstein G, Delmonico FL, LaQuaglia MP, et al. Treatment of acute renal allograft rejection with OKT3 monoclonal antibody. *Transplantation*. 1981;**32**(6):535-539
- [8] Pena JR, Fitzpatrick D, Saidman SL. Complement-dependent cytotoxicity crossmatch. *Methods in Molecular Biology (Clifton, NJ)*. 2013;**1034**:257-283
- [9] Patel R, Terasaki PI. Significance of the positive crossmatch test in kidney transplantation. *The New England Journal of Medicine*. 1969;**280**(14):735-739
- [10] Maguire O, Tario JD Jr, Shanahan TC, Wallace PK, Minderman H. Flow cytometry and solid organ transplantation: A perfect match. *Immunological Investigations*. 2014;**43**(8):756-774
- [11] Nishimura K, Hashimoto M, Kinoshita T, Shiraishi Y, Ueda N, Nakazawa S, et al. Excellent results of immunocomplex capture fluorescence analysis-I for cross-match test in renal transplantation. *Transplantation Proceedings*. 2014;**46**(2):332-335
- [12] Fujiwara K, Shimano K, Tanaka H, Sekine M, Kashiwase K, Uchikawa M, et al. Application of bead array technology to simultaneous detection of human leucocyte antigen and human platelet antigen antibodies. *Vox Sanguinis*. 2009;**96**(3):244-251
- [13] Bray RA, Tarsitani C, Gebel HM, Lee JH. Clinical cytometry and progress in HLA antibody detection. *Methods in Cell Biology*. 2011;**103**:285-310
- [14] Bachelet T, Couzi L, Lepreux S, Legeret M, Pariscoat G, Guidicelli G, et al. Kidney intra-graft donor-specific antibodies as determinant of antibody-mediated lesions and poor graft outcome. *American Journal of Transplantation : Official Journal of the American Society of Transplantation and the American Society of Transplant Surgeons*. 2013;**13**(11):2855-2864
- [15] Milongo D, Kamar N, Del Bello A, Guilbeau-Frugier C, Sallusto F, Esposito L, et al. Allelic and Epitopic characterization of intra-kidney allograft anti-HLA antibodies at allograft nephrectomy. *American Journal of Transplantation : Official Journal of the American Society of Transplantation and the American Society of Transplant Surgeons*. 2016

- [16] Nocera A, Tagliamacco A, Cioni M, Innocente A, Fontana I, Barbano G, et al. Kidney Intragraft homing of De novo donor-specific HLA antibodies is an essential step of antibody-mediated damage but not per se predictive of graft loss. *American Journal of Transplantation: Official Journal of the American Society of Transplantation and the American Society of Transplant Surgeons*. 2017;**17**(3):692-702
- [17] Neau-Cransac M, Le Bail B, Guidicelli G, Visentin J, Moreau K, Quinart A, et al. Evolution of serum and intra-graft donor-specific anti-HLA antibodies in a patient with two consecutive liver transplantations. *Transplant Immunology*. 2015;**33**(2):58-62
- [18] Visentin J, Chartier A, Massara L, Linares G, Guidicelli G, Blanchard E, et al. Lung intra-graft donor-specific antibodies as a risk factor for graft loss. *The Journal of Heart and Lung Transplantation: The Official Publication of the International Society for Heart Transplantation*. 2016;**35**(12):1418-1426
- [19] Nakamura T, Ushigome H, Watabe K, Imanishi Y, Masuda K, Matsuyama T, et al. Graft Immunocomplex capture fluorescence analysis to detect donor-specific antibodies and HLA antigen complexes in the allograft. *Immunological Investigations*. 2017;**46**(3):295-304
- [20] Nakamura T, Ushigome H, Watabe K, Imanishi Y, Masuda K, Matsuyama T, et al. Influences of pre-formed donor-specific anti-human leukocyte antigen antibodies in living-donor renal transplantation: Results with graft Immunocomplex capture fluorescence analysis. *Transplantation Proceedings*. 2017;**49**(5):955-958
- [21] Loupy A, Haas M, Solez K, Racusen L, Glotz D, Seron D, et al. The Banff 2015 kidney meeting report: Current challenges in rejection classification and prospects for adopting molecular pathology. *American Journal of Transplantation : Official Journal of the American Society of Transplantation and the American Society of Transplant Surgeons*. 2017;**17**(1):28-41
- [22] Demetris AJ, Bellamy C, Hubscher SG, O'Leary J, Randhawa PS, Feng S, et al. Comprehensive update of the Banff working group on liver allograft pathology: Introduction of antibody-mediated rejection. *American Journal of Transplantation : Official Journal of the American Society of Transplantation and the American Society of Transplant Surgeons*. 2016
- [23] Del Bello A, Congy-Jolivet N, Muscari F, Lavayssiere L, Esposito L, Cardeau-Desangles I, et al. Prevalence, incidence and risk factors for donor-specific anti-HLA antibodies in maintenance liver transplant patients. *American Journal of Transplantation : Official Journal of the American Society of Transplantation and the American Society of Transplant Surgeons*. 2014;**14**(4):867-875
- [24] O'Leary JG, Cai J, Freeman R, Banuelos N, Hart B, Johnson M, et al. Proposed diagnostic criteria for chronic antibody-mediated rejection in liver allografts. *American Journal of Transplantation: Official Journal of the American Society of Transplantation and the American Society of Transplant Surgeons*. 2016;**16**(2):603-614
- [25] Kobashigawa J, Crespo-Leiro MG, Ensminger SM, Reichenspurner H, Angelini A, Berry G, et al. Report from a consensus conference on antibody-mediated rejection in heart

- transplantation. *The Journal of Heart and Lung Transplantation: The Official Publication of the International Society for Heart Transplantation*. 2011;**30**(3):252-269
- [26] Berry GJ, Burke MM, Andersen C, Bruneval P, Fedrigo M, Fishbein MC, et al. The 2013 International Society for Heart and Lung Transplantation working formulation for the standardization of nomenclature in the pathologic diagnosis of antibody-mediated rejection in heart transplantation. *The Journal of Heart and Lung Transplantation: The Official Publication of the International Society for Heart Transplantation*. 2013;**32**(12):1147-1162
- [27] Shilling RA, Wilkes DS. Immunobiology of chronic lung allograft dysfunction: New insights from the bench and beyond. *American Journal of Transplantation : Official Journal of the American Society of Transplantation and the American Society of Transplant Surgeons*. 2009;**9**(8):1714-1718
- [28] Hachem RR, Yusef RD, Meyers BF, Aloush AA, Mohanakumar T, Patterson GA, et al. Anti-human leukocyte antigen antibodies and preemptive antibody-directed therapy after lung transplantation. *The Journal of Heart and Lung Transplantation: The Official Publication of the International Society for Heart Transplantation*. 2010;**29**(9):973-980
- [29] Levine DJ, Glanville AR, Aboyou C, Belperio J, Benden C, Berry GJ, et al. Antibody-mediated rejection of the lung: A consensus report of the International Society for Heart and Lung Transplantation. *The Journal of Heart and Lung Transplantation: The Official Publication of the International Society for Heart Transplantation*. 2016;**35**(4):397-406
- [30] Rabant M, Racape M, Petit LM, Taupin JL, Aubert O, Bruneau J, et al. Antibody-mediated rejection in pediatric small bowel transplantation: Capillaritis is a major determinant of C4d positivity in intestinal transplant biopsies. *American Journal of Transplantation: Official Journal of the American Society of Transplantation and the American Society of Transplant Surgeons*. 2018
- [31] de Serre NP, Canioni D, Lacaille F, Talbotec C, Dion D, Brousse N, et al. Evaluation of c4d deposition and circulating antibody in small bowel transplantation. *American Journal of Transplantation: Official Journal of the American Society of Transplantation and the American Society of Transplant Surgeons*. 2008;**8**(6):1290-1296
- [32] Nakao T, Ushigome H, Kawai K, Nakamura T, Harada S, Koshino K, et al. Evaluation of rituximab dosage for ABO-incompatible living-donor kidney transplantation. *Transplantation Proceedings*. 2015;**47**(3):644-648
- [33] Kubal CA, Mangus RS, Saxena R, Lobashevsky A, Higgins N, Agarwal A, et al. Crossmatch-positive liver transplantation in patients receiving thymoglobulin-rituximab induction. *Transplantation*. 2014;**97**(1):56-63
- [34] Ide K, Tanaka Y, Sasaki Y, Tahara H, Ohira M, Ishiyama K, et al. A phased desensitization protocol with rituximab and Bortezomib for highly sensitized kidney transplant candidates. *Transplantation Direct*. 2015;**1**(5):e17
- [35] Ishida H, Furusawa M, Shimizu T, Nozaki T, Tanabe K. Influence of preoperative anti-HLA antibodies on short- and long-term graft survival in recipients with or without rituximab treatment. *Transplant International: Official Journal of the European Society for Organ Transplantation*. 2014;**27**(4):371-382

- [36] Vo AA, Wechsler EA, Wang J, Peng A, Toyoda M, Lukovsky M, et al. Analysis of subcutaneous (SQ) alemtuzumab induction therapy in highly sensitized patients desensitized with IVIG and rituximab. *American Journal of Transplantation : Official Journal of the American Society of Transplantation and the American Society of Transplant Surgeons*. 2008;**8**(1):144-149
- [37] Kim IK, Choi J, Vo AA, Kang A, Patel M, Toyoda M, et al. Safety and efficacy of Alemtuzumab induction in highly sensitized pediatric renal transplant recipients. *Transplantation*. 2017;**101**(4):883-889
- [38] Jordan SC, Tyan D, Stablein D, McIntosh M, Rose S, Vo A, et al. Evaluation of intravenous immunoglobulin as an agent to lower allosensitization and improve transplantation in highly sensitized adult patients with end-stage renal disease: Report of the NIH IG02 trial. *Journal of the American Society of Nephrology: JASN*. 2004;**15**(12):3256-3262
- [39] Amrouche L, Aubert O, Suberbielle C, Rabant M, Van Huyen JD, Martinez F, et al. Long-term outcomes of kidney transplantation in patients with high levels of preformed DSA: The Necker high-risk transplant program. *Transplantation*. 2017;**101**(10):2440-2448
- [40] Lefaucheur C, Viglietti D, Bentlejewski C, Duong van Huyen JP, Vernerey D, Aubert O, et al. IgG donor-specific anti-human HLA antibody subclasses and kidney allograft antibody-mediated injury. *Journal of the American Society of Nephrology: JASN*. 2016;**27**(1):293-304
- [41] Yabu JM, Higgins JP, Chen G, Sequeira F, Busque S, Tyan DB. C1q-fixing human leukocyte antigen antibodies are specific for predicting transplant glomerulopathy and late graft failure after kidney transplantation. *Transplantation*. 2011;**91**(3):342-347
- [42] Yoshizawa A, Egawa H, Yurugi K, Hishida R, Tsuji H, Ashihara E, et al. Significance of semiquantitative assessment of preformed donor-specific antibody using luminex single bead assay in living related liver transplantation. *Clinical & Developmental Immunology*. 2013;**2013**:972705
- [43] Locke JE, Zachary AA, Haas M, Melancon JK, Warren DS, Simpkins CE, et al. The utility of splenectomy as rescue treatment for severe acute antibody mediated rejection. *American Journal of Transplantation : Official Journal of the American Society of Transplantation and the American Society of Transplant Surgeons*. 2007;**7**(4):842-846
- [44] Orandi BJ, Zachary AA, Dagher NN, Bagnasco SM, Garonzik-Wang JM, Van Arendonk KJ, et al. Eculizumab and splenectomy as salvage therapy for severe antibody-mediated rejection after HLA-incompatible kidney transplantation. *Transplantation*. 2014;**98**(8):857-863
- [45] Fan J, Tryphonopoulos P, Tekin A, Nishida S, Selvaggi G, Amador A, et al. Eculizumab salvage therapy for antibody-mediated rejection in a desensitization-resistant intestinal re-transplant patient. *American Journal of Transplantation : Official Journal of the American Society of Transplantation and the American Society of Transplant Surgeons*. 2015;**15**(7):1995-2000
- [46] Thrush PT, Pahl E, Naftel DC, Pruitt E, Everitt MD, Missler H, et al. A multi-institutional evaluation of antibody-mediated rejection utilizing the pediatric heart transplant

- study database: Incidence, therapies and outcomes. *The Journal of Heart and Lung Transplantation: The Official Publication of the International Society for Heart Transplantation*. 2016;**35**(12):1497-1504
- [47] Muller YD, Aubert JD, Vionnet J, Rotman S, Sadallah S, Aubert V, et al. Acute antibody-mediated rejection one week after lung transplantation successfully treated with eculizumab, intravenous immunoglobulins and rituximab. *Transplantation*. 2018
- [48] Moreso F, Crespo M, Ruiz JC, Torres A, Gutierrez-Dalmau A, Osuna A, et al. Treatment of chronic antibody mediated rejection with intravenous immunoglobulins and rituximab: A multicenter, prospective, randomized, double-blind clinical trial. *American Journal of Transplantation: Official Journal of the American Society of Transplantation and the American Society of Transplant Surgeons*. 2018;**18**(4):927-935
- [49] Cooper JE, Gralla J, Klem P, Chan L, Wiseman AC. High dose intravenous immunoglobulin therapy for donor-specific antibodies in kidney transplant recipients with acute and chronic graft dysfunction. *Transplantation*. 2014;**97**(12):1253-1259
- [50] Bachelet T, Nodimar C, Taupin JL, Lepreux S, Moreau K, Morel D, et al. Intravenous immunoglobulins and rituximab therapy for severe transplant glomerulopathy in chronic antibody-mediated rejection: A pilot study. *Clinical Transplantation*. 2015;**29**(5):439-446
- [51] Billing H, Rieger S, Susal C, Waldherr R, Opelz G, Wuhl E, et al. IVIG and rituximab for treatment of chronic antibody-mediated rejection: A prospective study in paediatric renal transplantation with a 2-year follow-up. *Transplant International: Official Journal of the European Society for Organ Transplantation*. 2012;**25**(11):1165-1173
- [52] Parajuli S, Mandelbrot DA, Muth B, Mohamed M, Garg N, Aziz F, et al. Rituximab and monitoring strategies for late antibody-mediated rejection after kidney transplantation. *Transplantation Direct*. 2017;**3**(12):e227
- [53] Kulkarni S, Kirkiles-Smith NC, Deng YH, Formica RN, Moeckel G, Broecker V, et al. Eculizumab therapy for chronic antibody-mediated injury in kidney transplant recipients: A pilot randomized controlled trial. *American Journal of Transplantation: Official Journal of the American Society of Transplantation and the American Society of Transplant Surgeons*. 2017;**17**(3):682-691
- [54] An GH, Yun J, Hong YA, Khvan M, Chung BH, Choi BS, et al. The effect of combination therapy with rituximab and intravenous immunoglobulin on the progression of chronic antibody mediated rejection in renal transplant recipients. *Journal of Immunology Research*. 2014;**2014**:828732
- [55] Redfield RR, Ellis TM, Zhong W, Scalea JR, Zens TJ, Mandelbrot D, et al. Current outcomes of chronic active antibody mediated rejection - a large single center retrospective review using the updated BANFF 2013 criteria. *Human Immunology*. 2016
- [56] Ban TH, Yu JH, Chung BH, Choi BS, Park CW, Kim YS, et al. Clinical outcome of rituximab and intravenous immunoglobulin combination therapy in kidney transplant recipients with chronic active antibody-mediated rejection. *Annals of Transplantation: Quarterly of the Polish Transplantation Society*. 2017;**22**:468-474

