

# We are IntechOpen, the world's leading publisher of Open Access books Built by scientists, for scientists

4,800

Open access books available

122,000

International authors and editors

135M

Downloads

Our authors are among the

154

Countries delivered to

TOP 1%

most cited scientists

12.2%

Contributors from top 500 universities



WEB OF SCIENCE™

Selection of our books indexed in the Book Citation Index  
in Web of Science™ Core Collection (BKCI)

Interested in publishing with us?  
Contact [book.department@intechopen.com](mailto:book.department@intechopen.com)

Numbers displayed above are based on latest data collected.  
For more information visit [www.intechopen.com](http://www.intechopen.com)



---

# Thyroidectomy without Ligatures in Differentiated Thyroid Cancer

---

Molnar Călin, Butiurca Vlad Olimpiu,  
Molnar Varlam Claudiu and Botoncea Marian

Additional information is available at the end of the chapter

<http://dx.doi.org/10.5772/intechopen.79730>

---

## Abstract

Technical improvements in thyroid surgery are nearly close with the progress of the vessels sealing systems. In all cases, we need to obtain a radical and safe thyroid excision. This chapter is conducted to evaluate the technical key point and the postoperative benefits of our procedure using vessels sealing devices in differentiated thyroid cancers. A prospective study, carried out in First Surgical Clinic, Emergency County Clinical Hospital Tirgu Mureş, Romania from January 01, 2013 to March 01, 2018, based on 100 consecutive patients, divided into two groups: first group without ligatures, using Small Jaw LigaSure™, and the second group operated by conventional procedure. Statistical analysis of some parameters (the thyroid pathology, operative time, hospitalization days, analgesic drugs, immediate postoperative complications and histopathological findings) shows that this procedure provides a total and “complete” removal of the thyroid specimen, with a decreased operative time and fewer hospitalization days.

**Keywords:** thyroid cancer, LigaSure™ small jaw, vessel sealing device

---

## 1. Introduction

Thyroid cancer represents approximately 3.8% of all new cancer cases having different genetics, histogenesis and evolution, requiring specific management protocols and consensus [1]. Although a diagnosis of cancer is frightening, the vast majority of thyroid cancers is highly treatable and in most cases curable with a multidisciplinary treatment in which surgery plays an important role.

In this chapter, we present the technical key points and postoperative benefits of the procedure, using LigaSure™ small jaw in differentiated thyroid cancer.

## 2. Short history of thyroidectomy

During the twelfth and thirteenth century, there were many speculations regarding the role and the function of the thyroid gland and surgeries have been done according to them [2]. Roger Frugardi was first, in 1170, to describe the extirpation of the gland using setons, hot irons and caustic powder [3].

Evolution of thyroidectomy is related to the advances of the technology even though in the nineteenth century this procedure was considered “barbaric horrid butchery” (by S. Gross) [4]. Later on, in 1880, Jules Boeckel of Strasbourg introduced the collar incision to thyroid surgery, and this approach was popularized, later on, by Theodor Kocher.

The thyroidectomy (near or total), as we know it today, began in the 1860s with the help of Billroth [5]. Thyroid surgery was undertaken before the physiology was understood leading to complications, including massive hemorrhage, infection or injuries of the surrounding structures, which were associated with morbidity and mortality rates of about 40% [4].

In 1880, Sandstrom discovered the parathyroid glands but the fact that hypocalcemia was the definitive cause of tetany was not accepted until the twentieth century [6].

Later, in the nineteenth and the beginning of the twentieth centuries, Theodor Kocher practiced a meticulous thyroidectomy being able to report a mortality rate of 1%. He also described the “cachexia strumipriva” in patients following total thyroidectomy. For his contribution to thyroid pathology, Kocher received the Nobel Prize in 1909 [7, 8].

In 1920, the advances in thyroidectomy reached the peak making Halsted to refer to this surgery as a “feat which today can be accomplished by any competent operator without danger of mishap” [1].

Nowadays, thyroid surgery can be performed with a low mortality as well as with low morbidity. In order to obtain such results, surgeon must be aware of the pathophysiology of the thyroid disorders and must know very well the cervical anatomy.

## 3. Differentiated thyroid cancer

According to the American Cancer Society, differentiated thyroid cancer (DTC) derives from thyrocytes and expresses the sodium iodine symporter. DTC includes papillary, follicular and Hurthle cell cancer and represents most of thyroid cancer (90%).

### 3.1. Papillary cancer

About 80% of the patients diagnosed with thyroid cancers present the form of papillary carcinoma. This form of papillary cancer develops slowly, and it usually affects only one thyroid

Papillary thyroid cancer	Variants
	Classic (usual)
	Clear cell
	Columnar cell
	Cribriform-morular
	Diffuse sclerosing
	Follicular
	Macrofollicular
	Microcarcinoma (occult, latent, small, microtumor)
	Solid
	Tall cell
	Warthin-like

**Table 1.** Variants of papillary thyroid cancer.

lobe. With a slow growth, the papillary cancers often spread to the locally lymph nodes. Even it also affects the local lymph nodes, this cancer responds well to the treatment and is rarely fatal. There are several subtypes of papillary cancers, more than 10 histological variants which are documented and can be seen in **Table 1** [9, 10].

### 3.2. Follicular cancer

Unlike the papillary form, the follicular cancer is the second most common thyroid cancer, affecting 10% of the persons diagnosed with thyroid cancer. It is more common in patients whose diet is poor in iodine. This type of cancer is characterized by the development of distant metastases, affecting organs such as the lungs and bones. The prognosis of this type of cancer varies depending on the degree of invasiveness. In the traditional classification of follicular thyroid cancer (FTC), there are two groups: minimally invasive and widely invasive [11–13].

### 3.3. Hurthle cell cancer

This type is also known as oxyphil cell carcinoma. About 3% of thyroid cancers are of this type. Most of the authors consider it as a form of follicular cancer [14].

## 4. Risk classification of DTC

The risk classification helps to predict the risk of local recurrence and developing metastases and the mortality in patients with DTC. It uses multiple staging systems which are based on a combination of the size of the primary tumor, specific histology, extrathyroidal spread of the tumor and the age at diagnosis.

The staging system most often used for thyroid cancer is the **TNM (Table 2)** system, which is based on three key pieces of information:

- T = the size of the tumor
- N = the spread to the nearby lymph nodes
- M = the spread to distant sites (metastasis)

The most common risk classification is based on the tumor node metastasis (TNM) classification:

- very low-risk group: pT1a, cN0/pN0, cM0;
- low-risk group: pT1b, pT2, cN0/pN0, cM0;
- high-risk group: pT3, pT4, each N1, all M1.

---

**TX:** Primary tumor cannot be evaluated

**T0:** There is no evidence of primary tumor

**T1:** Tumor limited to the thyroid, whose maximum dimension does not exceed 2 cm

**T1a:** Tumor limited to the thyroid, whose greatest dimension does not exceed 1 cm

**T1b:** Tumor limited to the thyroid gland with dimension >1 cm, but lower than 2 cm in greatest dimension

**T2:** Tumor >2 cm but ≤4 cm in greatest dimension limited to the thyroid

**T3:** Tumor limited to the thyroid or with minimal extrathyroidal extension, with dimension <4 cm

**T3a:** Tumor dimension >4 cm but is limited to the thyroid

**T3b:** Minimal extrathyroidal extension invading the strap muscles (sternohyoid, sternothyroid, thyrohyoid or omohyoid muscles) from a tumor of any size

**T4:** Includes extrathyroidal extension into neck major structures

**T4a:** Tumor of any size with extrathyroidal extension invading subcutaneous soft tissues, larynx, trachea, esophagus or recurrent laryngeal nerve

**T4b:** Tumor of any size with extrathyroidal extension invading prevertebral fascia or encasing carotid artery or mediastinal vessels

**NX:** Regional lymph nodes cannot be evaluated

**N0:** There is no evidence of regional lymph node metastasis

**N1:** Metastasis to regional nodes

**N1a:** Unilateral or bilateral disease involving level VI or VII lymph nodes metastasis (pretracheal, paratracheal, prelaryngeal / Delphian or upper mediastinal)

**N1b:** Unilateral, bilateral or contralateral lymph nodes metastasis (levels I, II, III, IV or V) or retropharyngeal lymph nodes

**M0:** No distant metastasis

**M1:** Distant metastasis

---

**Table 2.** TNM classification, 8th edition [15].

<i>Age at diagnosis &lt;55 years</i>			
Stage I:	any T	any N	M0
Stage II:	any T	any N	M1
<i>Age at diagnosis ≥55 years</i>			
Stage I:	T1	N0/NX	M0
	T2	N0/NX	M0
Stage II:	T1	N1	M0
	T2	N1	M0
	T3a/T3b	any N	M0
Stage III:	T4a	any N	M0
Stage IVA:	T4b	any N	M0
Stage IVB:	any T	any N	M1

**Table 3.** Stage grouping according to AJCC.

Based on the risk of structural disease recurrence, the American Thyroid Association defines in their current guideline the next classification [16]:

- high-risk group: gross extrathyroidal extension, incomplete tumor resection, distant metastases, or lymph node >3 cm;
- intermediate-risk group: aggressive histology, minor extrathyroidal extension, vascular invasion, or >5 involved lymph nodes (0.2–3 cm);
- low-risk group: intrathyroidal DTC, ≤5 lymph nodes micrometastases (<0.2 cm)

The American Joint Committee on Cancer (AJCC) uses the combination of TNM classification and an age of more than 55 years at diagnosis as risk factor (**Table 3**).

## 5. Surgery without ligatures

Total complete thyroidectomy is the procedure that can be defined as an extracapsular thyroidectomy in which we remove the entire gland without remnant tissue.

### 5.1. Surgical instruments

The tool kit consists of a scalpel, Pean forceps (1–2 pieces), anatomical and surgical forceps, scissors, Farabeuf or Kocher spacers, monopolar cautery and LigaSure™ small jaw.

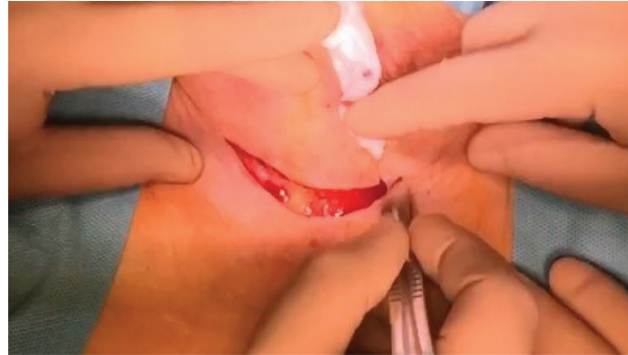
### 5.2. Incision

A 5–6 cm Kocher incision is performed in a flexion fold at 2–2.5 cm of the sternal notch. The skin, the subcutaneous cellular tissue and the platysma muscle are cut, after which a superior

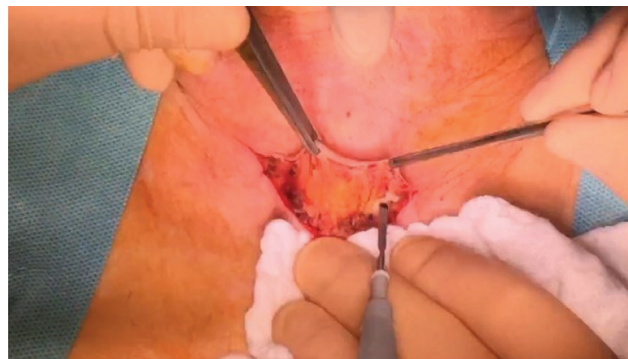and a lower flap is made by dissection using LigaSure™ or electrocautery. The upper flap is suspended, exposing the white line (**Figures 1–3**).

### 5.3. How we do it

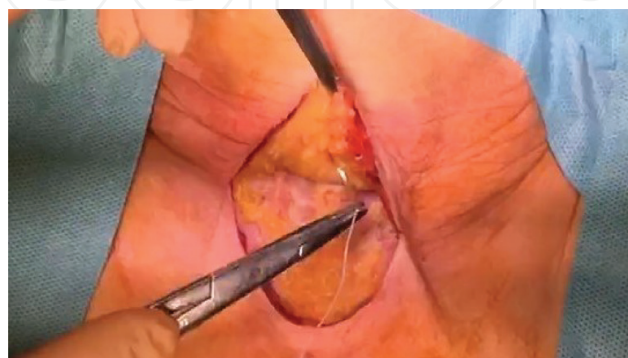Penetration into the cleavage space by cutting the medial raf and releasing the anterior face of the anterior thyroide lobe. The thyroid lobe is mobilized with a thread (**Figure 4**).The dissection is continued laterally by sealing the middle thyroid vein with the LigaSure™ small



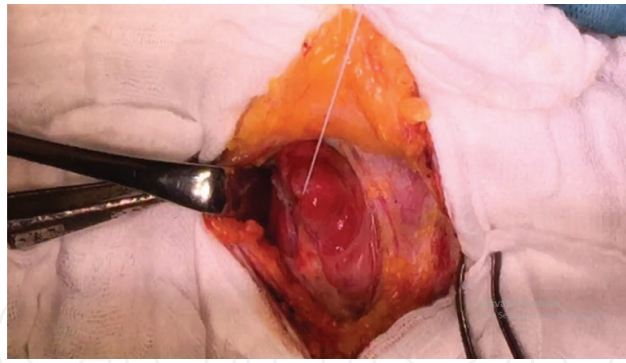
**Figure 1.** Kocher incision.



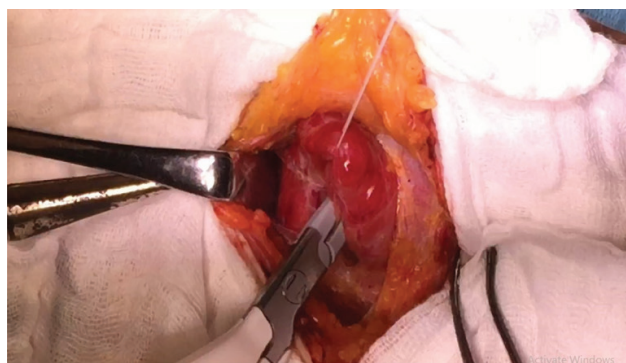
**Figure 2.** Preparing the upper and lower flap.



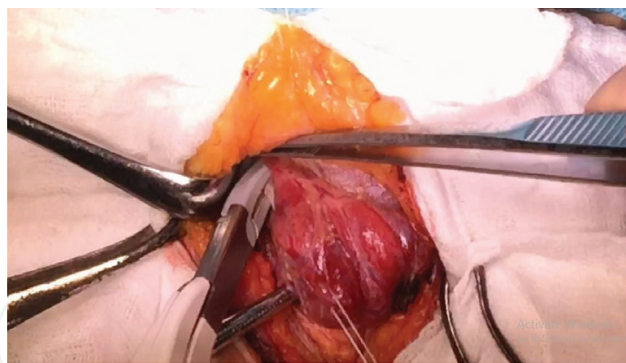
**Figure 3.** Suspending the upper flap.



**Figure 4.** Traction of the thyroid lobe using thread.



**Figure 5.** Lateral dissection with the sealing of the medial vein.



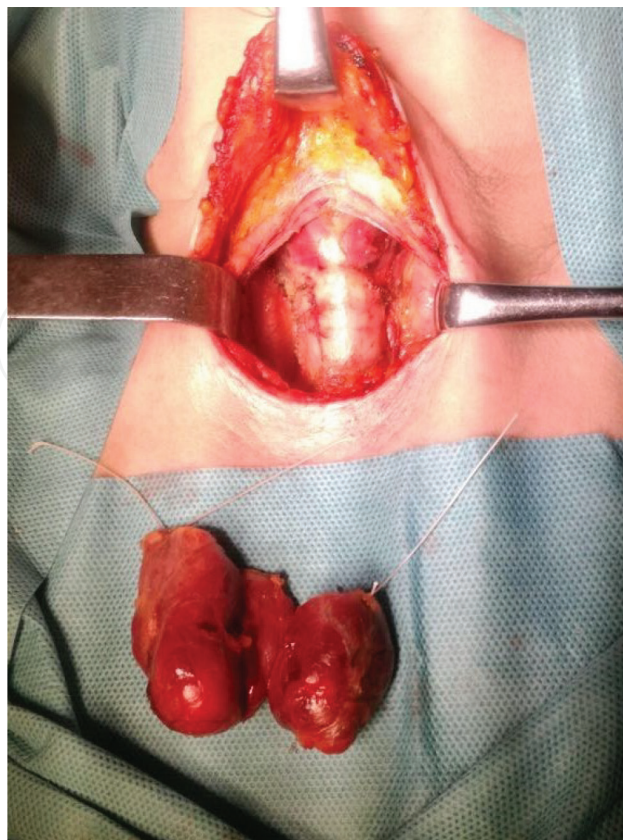
**Figure 6.** Sealing the upper thyroid pedicle.

jaw, then continuing cranially to the upper thyroid at the same time as the thyroid lobe dislocates (**Figure 5**).

Upper pole dissection with LigaSure™ *Small Jaw*, sealing the upper thyroid vascular pedicle (**Figure 6**).

The sealing of the lower branches of the lower thyroid pedicle is the essential time of this intervention, with the preservation of parathyroids, secondary branches of the inferior artery and the recurrent nerve. Dissection proceeds to the median line, sectioning Berry's ligaments.





**Figure 7.** Monobloc resection of the thyroid gland.

Lobectomy ends with the separation of the isthmus, being an optional time, or we can achieve a monobloc resection of the gland (**Figure 7**).

Control of the hemostasis, drainage of the thyroid cavity, intradermal resorbable suture.

## 6. Evaluation of the technique

### 6.1. Study description

In order to evaluate the feasibility of the technique, we conducted a prospective study which was carried out in Clinic of Surgery I, Emergency Clinical County Hospital Târgu Mureş from January 01, 2013 to June 01, 2017. The study enrolled 100 consecutive patients divided into two lots: 50 who underwent total complete thyroidectomy using LigaSure™ small jaw, including 10 with “monobloc resection” and 50 in whom total thyroidectomy was performed by conventional procedure (by using ligatures). The two groups were compared using statistical analysis following the next parameters: the thyroid pathology, operative time, hospitalization days, analgesia used and immediate postoperative complications. Statistical analysis was performed employing Student’s test for comparison of the continuous variables. Differences between nonparametrical variables were compared using the Mann-Whitney U-test. Descriptive data were reported as the mean  $\pm$  SD. The level of significance was set at  $p < 0.05$ .

All patients have been prior diagnosed by fine needle aspiration (FNA) biopsy showing either papillary or follicular cancer.

All patients had preoperative and postoperative endocrinological consultations, and all the female patients had gynecological examination prior to the surgery.

## 6.2. Results

Extracapsular thyroidectomy was performed in all patients.

Surgery consisted of performing total thyroidectomy and double drainage of the thyroid compartment.

The two groups included in this study had similar demographics (age, sex) and the thyroid pathology also being the same (**Table 4**).

In the evaluation of the operative time measured from the moment of the skin incision to wound closure, we have found that statistical data followed a Gaussian distribution and it could be interpreted by Student's t-test. The mean operative time in group 1 was  $73.81 \pm 16.96$  min, which is significantly less than the operative time in the second group (conventional)  $106.19 \pm 31.66$  min (**Table 5**).

To appreciate the length of hospital stay, we applied the nonparametric Mann-Whitney test, since the two groups did not have a Gaussian distribution pattern, because of the value of 17 days in group 1 and of 19 days in group 2. For group 1, the mean hospitalization time was of 4 days (range: 2–17 days), and for group 2, it was also 4 days (range: 3–19 days) (**Table 6**). We have not found statistically significant differences relating to these parameters of the patients in the two groups, regardless of the statistic method applied.

	Group 1	Group 2
Mean age	54	52
Sex ratio F:M	45:5	43:7

**Table 4.** Patient's demographic characteristics.

Minimum	45	65
Mean	73.81	106.19
Maximum	120	200
Median	72.5	100
Standard deviation	16.96	31.66

**Table 5.** Distribution of patients depending to the operative time.

	Group 1	Group 2
Minimum	2	2
Mean	4.09	4.61
Maximum	17.00	19.00
Median	3.00	4.00
Standard deviation	2.95	3.21

**Table 6.** Distribution of patients depending on length of hospitalization.

	Group 1	Group 2
Low pitched voice	3	4
Haematoma	2	4

**Table 7.** Complications in the two groups.

The evaluation of postoperative analgesia was performed by measuring the dose of analgesic drugs administered to each patient. The nonparametric Mann-Whitney test had been applied considering that the two groups did not have a Gaussian distribution (because of a maximal value of 17 days observed in the LigaSure-group and a maximal value of 19 days identified in the conventional group). The mean period of analgesia in group 1 was 2.5 days (range 1–16 days), while in group 2, it was 3 days (range: 2–19 days). There was no statistically significant difference between the period of analgesic drug requirement in the two groups ( $p = 0.06$ ).

No patients developed manifestations of hypocalcemia (hypoparathyroidism). There were few patients who experienced a change in voice (low pitched voice) seen in three patients from group 1 and in four patients in group 2. Hematoma was observed in two patients belonging to group 1 and in four patients belonging to group 2. There is no statistic significant difference between the incidence of early postoperative complications in the two groups (**Table 7**).

## 7. Discussion

Recently, thyroid surgery is considered quite safe, thanks to the proper surgical techniques that kept complications at a minimum rate (2–3%) [17].

The introduction of the new sealing devices in thyroid surgery benefits both patients and the surgeons. LigaSure™ small jaw is a proper device used to perform total complete thyroidectomy, and it gives some technical advantages like: creates a clean surgical field providing better visibility, observed in other study [18]; no need to expose the vascular pedicles their dissection being possible using the device's forceps; reduces the operative time, also observed by Gac, Cabane and Hou Shan Yao [19, 20]; performs safe sealing of blood vessels, observed

also by Marazzo and Lepner [20, 21]. This device can also remove the complications regarding the thread pathology.

The extracapsular total complete thyroidectomy can be performed without isthmectomy.

Dissection of vascular pedicles is relatively easy, allowing sufficient exposure to a very narrow anatomical space, and the separation and preservation of the integrity of the laryngeal nerves and parathyroid glands are possible in the absence of invasion by the pathological process (tumor or inflammatory).

By lower temperature dispersion (1–2 mm) from the device's jaws, the nerve elements are spared, detaching the thyroid by cutting the Berry ligaments and avoiding burns in the laryngeal tracheal conduit.

In order to avoid the possible thyroidectomy complications such as parathyroid trauma or laryngeal nerves injuries, a good hemostasis becomes the priority for the thyroid surgeons. Hemostasis achieved by classic methods such as tie and clamp, electrocautery, clips is time consuming and can lead to knot slipping and thermal trauma of the surrounding tissues [22].

Nowadays, minimally invasive surgical techniques are used on a large scale in other surgical fields but thyroid gland resections, for both benign and malignant tumors are rarely performed. Zorron et al. described an endoscopic approach in patients without preexisting neck operations using transoral-vestibular approach but with the limitation of the study due to the need of the evaluation of the technique [23].

## 8. Conclusion

Total and "complete" thyroidectomy represents a feasible technique in our days.

In our opinion, based on the results, this technique can be considered safe.

Using the vessel sealing devices brings real benefits both for patients and surgeons.

In surgical services that do not have assisted video surgery, this technique can be considered "gold standard" in selected cases.

## Acknowledgements

Publications of this chapter has been funded by the "Toma Ionescu" Foundation, Gheorghe Marinescu Street no. 50, Targu-Mures, Romania.

## Conflict of interest

There is nothing to declare.

## Author details

Molnar Călin<sup>1</sup>, Butiurca Vlad Olimpiu<sup>1\*</sup>, Molnar Varlam Claudiu<sup>2</sup> and Botoncea Marian<sup>1</sup>

\*Address all correspondence to: vladbutiurca@yahoo.com

1 Surgery Department, Tîrgu Mureş Emergency Clinical County Hospital, University of Medicine and Pharmacy Tîrgu Mureş, Tîrgu Mureş, România

2 Obstetrics and Gynecology Department, Tîrgu Mureş Emergency Clinical County Hospital, University of Medicine and Pharmacy Tîrgu Mureş, Tîrgu Mureş, România

## References

- [1] National Cancer Institute. Surveillance, Epidemiology, and End Results (SEER). SEER Stat Fact Sheets: Thyroid Cancer. <http://seer.cancer.gov/statfacts/html/thyro.html> [Accessed: April 20, 2018]
- [2] Goyal N. Thyroidectomy: Overview, Preparation, Technique; <http://emedicine.medscape.com/article/1891109-overview> [Accessed: April 20, 2018]
- [3] Shuja A. History of thyroid surgery. Professional Medical Journal. 2008;**15**(2):295-297
- [4] Schneider DF, Mazeh H, Oltmann SC, Chen H, Sippel RS. Novel thyroidectomy difficulty scale correlates with operative time. World Journal of Surgery. 2014;**38**(8):1984-1989
- [5] Halsted WS. The operative story of goitre. Johns Hopkins Hospital Reports. 1920;**19**:71
- [6] Thompson NW. The history of hyperparathyroidism. Acta Chirurgica Scandinavica. 1990;**156**:5-21
- [7] Jancewicz S, Sidhu S, Jalaludin B, Campbell P. Optimal position for a cervical collar incision: A prospective study. ANZ Journal of Surgery. 2002;**72**(1):15-17
- [8] Kocher T. Uber Kropfextirpation und ihre Folgen. Archiv fuer Klinische Chirurgie. 1883;**29**:254
- [9] Nikiforov YE, Otori NP. Papillary carcinoma. In Diagnostic Pathology and Molecular Genetics of the Thyroid, 1st ed.; Nikiforov YE, Biddinger PW, Thompson LDR, Eds.; Lippincott: Philadelphia, PA, USA, 2012; pp. 183-262. 17
- [10] Seethala RR, Asa SL, Carty SE, Hodak SP, McHugh JB, Richardson MS, Shah J, Thompson LDR, Nikiforov YE. For the Members of the Cancer Committee, College of American Pathologists. Protocol for the Examination of Specimens from Patients with Carcinomas of the Thyroid Gland, Based on AJCC/UICC TNM. 7th ed. Version: Thyroid 3.2.0.0. Available from: <http://www.cap.org/ShowProperty?nodePath=/UCMCon/Contribution%20Folders/WebContent/pdf/cp-thyroid-16protocol-3200.pdf> [Accessed: April 20, 2018]

- [11] Brennan MD, Bergstralh EJ, van Heerden JA, McConahey WM. Follicular thyroid cancer treated at the Mayo Clinic, 1946 through 1970: Initial manifestations, pathologic findings, therapy, and outcome. *Mayo Clinic Proceedings*. 1991;**66**:11-22
- [12] Collini P, Sampietro G, Pilotti S. Extensive vascular invasion is a marker of risk of relapse in encapsulated non-Hürthle cell follicular carcinoma of the thyroid gland: A clinicopathological study of 18 consecutive cases from a single institution with a 11-year median follow-up. *Histopathology*. 2004;**44**:35-39. [PubMed]
- [13] Lang W, Choritz H, Hundeshagen H. Risk factors in follicular thyroid carcinomas. A retrospective follow-up study covering a 14-year period with emphasis on morphological findings. *The American Journal of Surgical Pathology*. 1986;**10**:246-255. [PubMed]
- [14] DeLellis RA, Lloyd RV, Heitz PU, Eng C, editors. *Pathology and Genetics of Tumors of the Endocrine Organs*. Lyon: IARC Press; 2004
- [15] Schmid KW, Synoracki S, Dralle H, et al. Proposal for an extended pTNM classification of thyroid carcinoma. *Der Pathologe*. July 2018;**89**(7):529-539. DOI: 10.1007/s00292-018-0418-x
- [16] Haugen BR, Alexander EK, Bible KC, et al. American Thyroid Association Management Guidelines for Adult Patients with Thyroid Nodules and Differentiated Thyroid Cancer: The American Thyroid Association Guidelines Task Force on Thyroid Nodules and Differentiated Thyroid Cancer. *Thyroid*. 2016;**26**(1):1-133. DOI: 10.1089/thy.2015.0020
- [17] Savargaonkar AP. Post-thyroidectomy haematoma causing total airway obstruction—A case report. *Indian Journal of Anaesthesia*. 2004;**48**:483-485
- [18] Kirdak T, Korun N, Ozguc H. Use of ligasure in thyroidectomy procedures: Results of a prospective comparative study. *World Journal of Surgery*. 2005;**29**(6):771-774
- [19] Gac P, Cabane P, Amat J, Rodriguez F, Cardemil F, Parada F et al. Tiroidectomia sin ligaduras: evaluando Ligasure Precise. *Chilena de Cirurgia*. Abril. 2008;**60**(2):127-131
- [20] Yao HS, Wang Q, Wang WJ, Ruan CP. Prospective clinical trials of thyroidectomy with LigaSure vs conventional vessel ligation: A systematic review and meta-analysis. *The Archives of Surgery*. 2009;**144**(12):1167-1174
- [21] Marrazzo A, Casà L, David M, Lo Gerfo D, Noto A, Riili I, et al. Thyroidectomy with LigaSure versus traditional thyroidectomy: Our experience. *Chirurgia Italiana*. 2007; **59**(3):361-365. Italian
- [22] Al-Dhahiry JKS, Hameed HM. Total thyroidectomy: Conventional suture ligation technique versus sutureless techniques using harmonic scalpel or maxium. *Annals of Medicine and Surgery*. 2016;**5**:29-34. DOI: 10.1016/j.amsu.2015.11.010
- [23] Zorron R, Bures C, Brandl A, et al. Tips and technical issues for performing transoral endoscopic thyroidectomy with vestibular approach (TOETVA): A novel scarless technique for neck surgery. *Chirurg*. February 2018;**39**(1):49-56. DOI: 10.1007/s00104-018-0658-

