

We are IntechOpen, the world's leading publisher of Open Access books Built by scientists, for scientists

4,800

Open access books available

122,000

International authors and editors

135M

Downloads

Our authors are among the

154

Countries delivered to

TOP 1%

most cited scientists

12.2%

Contributors from top 500 universities



WEB OF SCIENCE™

Selection of our books indexed in the Book Citation Index
in Web of Science™ Core Collection (BKCI)

Interested in publishing with us?
Contact book.department@intechopen.com

Numbers displayed above are based on latest data collected.
For more information visit www.intechopen.com



Advances in the Treatment of Postsurgical Benign Colorectal Strictures

Isabel Pinto García, Luis Antonio Vázquez Pedreño, Asunción Durán Campos, Miguel Jiménez Pérez and David Marín García

Additional information is available at the end of the chapter

<http://dx.doi.org/10.5772/intechopen.79618>

Abstract

Postsurgical benign colorectal strictures occur in up to 20% of patients who undergo colon or rectal resection. Traditionally, treatment has been surgical, but recent decades have seen the growing importance of an endoscopic approach, particularly balloon dilatation, which is now considered the first-line treatment for these benign strictures. However, balloon dilatation is associated with a recurrence of the stricture in up to 25% of cases. When this arises, one can opt for surgery aimed at performing a reanastomosis; a new intestinal anastomosis may be technically complex or even impossible, which would result in the patient requiring a permanent colostomy, with its consequent negative impact on quality of life. Accordingly, different endoscopic approaches have been evaluated for strictures refractory to balloon dilatation, such as the implant of self-expanding metallic stents, biodegradable stents, or incisional therapy, with variable results in efficacy.

Keywords: benign colorectal strictures, postsurgical strictures, self-expanding metallic stents, biodegradable stents, incisional endoscopic therapy

1. Introduction

Acute obstruction of colorectal transit is an emergency, the initial management of which is surgery. In most cases, the obstruction is caused by a malignant condition [1], although multiple other benign causes also exist, like surgical anastomosis, postradiotherapy complications,

Benign colorectal strictures

1. Postsurgical
 2. Inflammatory bowel disease
 3. Diverticular disease
 4. Postradiotherapy
 5. Ischaemic
 6. Iatrogenic due to chronic use of NSAIDs
 7. Treatment of prior lesions by endoscopic submucosal resection
-

Table 1. Aetiology of benign colorectal strictures.

diverticulitis, inflammatory bowel disease, ischaemia, chronic treatment with NSAIDs (**Table 1**). Endoscopic treatment with submucosal resection of large lesions has been postulated as another common cause in the not too distant future [2].

The most common cause of benign colorectal strictures is currently postsurgical stenosis [3]. This occurs in 5–20% of all surgeries [4], especially affecting anastomoses in the distal extra-peritoneal rectum. The factors leading to the appearance of these strictures are not completely clear although certain related factors have been identified, such as the presence of anastomotic leaks, radiotherapy before surgery, relative ischaemia due to excessive tension in the anastomosis, and recently a relation has been found between its increased incidence and the use of mechanical intestinal sutures [5]. The incidence of stenosis is greater with the use of circular endostaplers.

Most studies define postsurgical strictures as those that cannot be traversed by a standard calibre colonoscope. This definition, however, is hardly homogenous as there exist small but substantial technical differences between the various endoscopes. Truong et al. [6], in a study of 36 patients who underwent endoscopic treatment, defined three degrees of stenosis according to its diameter, which were related with the presence of obstructive intestinal symptoms, in particular Grade 3 or less than 5 mm diameter. Most appear during the first year after surgery, though in some cases they may appear and become symptomatic several years after surgery.

2. Treatment of postsurgical colorectal strictures

Treatment of all postsurgical strictures is recommended when they are symptomatic or when a diagnostic or therapeutic procedure proximal to the stricture is required. Special attention must be given to patients who have undergone surgery for a malignant colorectal cancer in order to be able to undertake an endoscopic follow-up due to the risk of metachronous cancer [7].

Postsurgical strictures have traditionally been managed surgically with dissection and reanastomosis. This, however, does not rule out the possibility of stenosis in the newly created anastomosis nor is it always possible, due to inflammatory phenomena and fibrosis that can appear in the surrounding tissues, particularly in anastomosis of the inferior rectum, where

reintervention is technically more demanding. In some cases, this may lead to the creation of a definitive stoma, with the corresponding reduction in quality of life for the patient. As a result, various minimally invasive strategies have been studied aimed at the treatment of postsurgical strictures.

2.1. Dilatation

Since the first balloon dilatation of a benign rectal stricture in 1984, this technique has become the treatment of choice for this condition, especially when the stricture is postsurgical and related with inflammatory bowel disease [3, 7].

Multiple dilatation techniques have been described, whether guided by radioscopy or by endoscopy. Initially, Savary-Gilliard wire guides were used, but with these only the most distal strictures were accessible. Later there appeared dilatation balloons, OTW (over the wire or achalasia balloon dilation) or TTS (through the scope). The balloons only exert radial force on the stenosis and therefore present a lower risk of perforation, improving the clinical results of the dilatation as compared with guide wires. Generally, the technique requires various sessions with a progressive increase in balloon diameter until the stricture is definitively solved.

Several factors of the stricture can be correlated with the results of balloon dilatation [8] as factors predicting success: a stricture calibre around 10 mm, a length of the stenotic segment less than 4 cm and the postsurgical aetiology of the stricture. Factors predicting failure of the dilatation include malignancy of the stricture, presence of more than one stricture, association of fistulas, complete obstruction of the lumen, active inflammation or marked angulation of the stenotic segment.

The initial success rate of balloon dilatation of postsurgical strictures is 91–100%, depending on the series [7, 9]. Long-term follow-up studies show its effectiveness is maintained, avoiding the need for surgery in 75% of strictures [9, 10], with a low rate of complications, around 15%, mostly minor (such as mild bleeding) that can generally be managed conservatively. A recent review of 850 procedures [11] estimated the overall rate of perforation with this technique at 1.1%.

Recurrence of the stricture does not appear to be clearly related with the number of sessions needed to achieve the cure.

2.2. Self-expanding metal stents (SEMS)

A metal stent is just a cylindrical metal mesh that, when released by its holding device, tends to recover its original shape until it reaches its maximum diameter. They can be made of various different materials, such as stainless steel, elgiloy (alloy of cobalt and nickel) or nitinol (alloy of nickel and titanium). This latter is currently the most widely used and is characterised by its flexibility, which thus enables the stent to be placed in areas with marked angles.

There exists a great range of lengths and diameters among stents, and their designs usually involve larger cups at the ends to prevent migration. Covered stents (either fully or partially) have a silicone membrane covering the openings of the metal mesh (see **Figure 1**).




Figure 1. Types of stent.

Table 2 shows the different types of stents used for the treatment of postsurgical colon strictures, explained here and below.

In the context of malignant neoplastic strictures, self-expanding metal stents, or SEMS, have clearly proven their usefulness, both as palliative definite treatment and as bridge therapy to elective surgery. However, their role is not so clear in cases of benign colorectal strictures [12].

The results of studies about benign strictures are difficult to interpret, as most studies involved a low number of patients and a wide variability in the type of stent implanted (uncovered, partially covered or fully covered) as well as the aetiology of the stricture [13–16].

Uncovered stents have a lower risk of migration, but they are difficult to withdraw due to the hyperplastic reaction generated within a few days of implantation. Covered stents, however, are very easy to withdraw but at the expense of a greater risk of migration.

Self-expanding stents

1. Uncovered metal stent
 2. Partially covered metal stent
 3. Fully covered metal stent
 4. Biodegradable stent
 5. Lumen-apposing metal stent
-

Table 2. Types of self-expanding stents used for the treatment of postsurgical strictures.

Studies have evaluated the use of stents as a bridge to surgery (as in malignant diseases) to thereby avoid having to make a stoma in the event of acute colon obstruction of benign origin [13, 14]. The clinical success rate reaches 91%, with major complications in up to 38% of cases. The most frequent complication is stent migration, though this is mostly with effect from 7 days of implantation and in strictures of diverticular or actinic obstruction. A systematic review in 2013 about the use of stents for the management of benign colorectal obstruction [16] that included 122 patients found that a stoma was only avoided in 48% of the patients.

The high rate of recurrence of postsurgical strictures after balloon dilatation, around 25%, especially in long strictures, with a technique not exempt from complications, has led to multiple studies assessing the role of SEMs [15, 17–20], although all involved just a few patients. Unlike balloon dilatation, stents apply a constant prolonged radial force on the stricture, due to the natural tendency of nitinol to recover its original shape once released. This quality permits definitive remodelling of the stricture, and covered stents also afford the possibility of sealing anastomotic leaks when they are associated with the stricture [17, 18].

The immediate clinical efficacy reported in various studies ranges from 36 to 81% [15, 17, 19–21] and improves with larger diameter stents [19]. However, they are associated with a high rate of complications, mainly migration in 19–63% of cases [17, 19, 21], which, if early, necessitates additional treatment of the stricture, reobstruction due to hyperplastic reaction in the extremes or stool impaction, necrosis due to pressure, bleeding, anal pain or perforation in up to 28% of cases.

Three recent studies of covered metal stents for postsurgical strictures [19–21] report clinical success rates of 100, 100 and 81%, respectively, with long-term results of solving obstruction ranging from 53 to 70% after follow-up periods of 18–21 months.

In 2015, Park et al. [3] compared a group of 43 patients with benign strictures who were divided into two treatment arms (dilatation and SEMs). They found no significant differences in clinical success between the two groups.

The disparity in the results makes it impossible to conclude that metal stents are a suitable option for first-line treatment of strictures in surgical anastomoses, though the results of some studies [19–21] suggest that fully covered metal stents could play a role in those cases that are refractory to treatment with dilatation.

2.3. Biodegradable stents

Recent years have seen the development of stents made from biodegradable materials, used more often in the field of endovascular therapy. They are composed of synthetic biocompatible polymers that gradually dissolve through a process of hydrolysis without generating any harmful products during their degradation. The most used are polylactic acid and polydioxanone. Their rate of degradation depends on the structure and size of the stent, in addition to the temperature, pH and type of tissue with which they are in contact [22]. The most used in the gastrointestinal area are polydioxanone stents (SX-ELLA oesophageal stents), initially designed for the treatment of oesophageal strictures refractory to conventional treatment. They afford the

possibility of maintaining dilatation prolonged over 6–8 weeks, avoiding the need to withdraw the stent, this being their main advantage compared with self-expanding metal stents. They degrade completely after some 11–12 weeks as part of the stent is absorbed and part expelled via the gastrointestinal tract. Their degradation is hastened in media with an acid pH.

A particular feature of these stents is that they require ultrarigid guide wires for placement, with a stricture calibre of at least 9.4 mm to enable passage of the 28 F release system. Thus, prior dilatation of the stricture is often necessary. The release device measures 75 cm, which limits its use in proximal colon strictures [23], though this may be feasible with the use of overtubes.

Potential complications are the same as those for conventional metal stents: perforation, migration, occlusion due to faecal impaction or hyperplastic reaction of the mucus and haemorrhage.

Little evidence exists about the use of biodegradable stents in the treatment of benign post-surgical strictures. Most reports concern clinical cases [24, 25] or series with a low number of patients [23, 26]. The stricture is resolved in up to 45% of cases [26]. The main cause of this poor response is early stent migration, facilitated by the predilatation needed for insertion (minimum calibre 9.4 mm) and intestinal peristalsis exacerbated by the use of laxatives. Their systematic use to avoid faecal impaction in the stent is therefore questioned [27]. Clips and cyanoacrylate have been used to fix the proximal end [23].

A recently published review [27] collects various studies with a total of 36 patients. The technical success ranged from 86 to 100%, the clinical success varied from 45 to 100% and the rate of migration ranged from 0 to 36%.

A specific design of these stents for placement in the colon to reduce early migration as well as the development of adequate fixation systems could possibly improve the long-term results of these stents. The currently available data do not appear to show they are superior to covered metal stents as an alternative in refractory strictures.

2.4. Incisional therapy (EEI: endoscopic electrocautery incision)

An alternative has recently been described for the treatment of benign colorectal anastomotic strictures. Like other treatments for this condition, it has been exported after its use in post-surgical strictures in the upper digestive tract. It is a simple, cheap and accessible technique in most endoscopy units. It consists of performing various radial incisions of the stricture using polypectomy loops, sphincterotomes or an IT knife (insulated tip knife).

Case reports exist of the exclusive performance of radial incisions in the stricture [28], arguing that no additional manoeuvre is needed as the simple passage of stools through the stenotic area will dilate it (**Figure 2**).

Modifications have been made to this technique, withdrawing the tissue from between the radial incisions (RIC: radial incision and cutting) with an IT knife [29, 30] or with argon plasma [31], or else combining balloon dilatation with radial incisions (**Figures 3 and 4**). Other combined treatments give a steroid injection in the incisions to avoid relapse of the stricture.

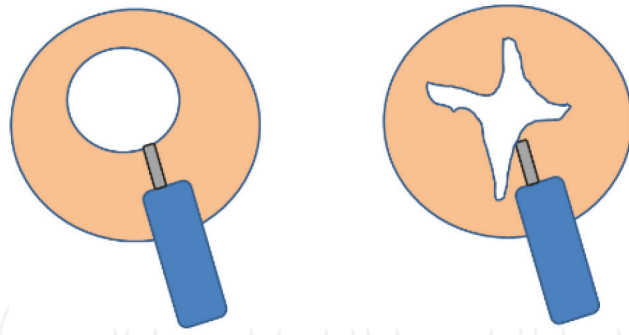


Figure 2. Endoscopic electrocautery incision (EEI).

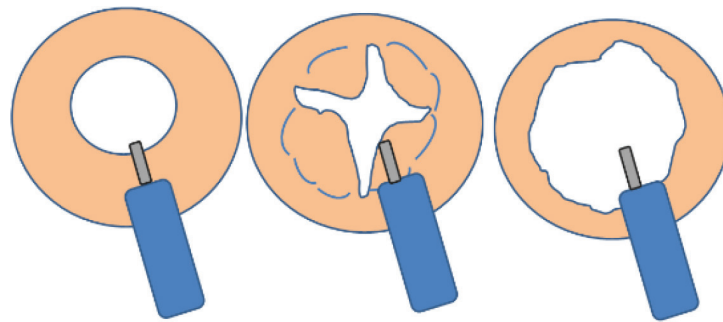


Figure 3. Radial and incisional cutting (RCI).

The following figures show the various steps of the technique combined with dilatation: **Figure 5**, colon stricture; **Figure 6**, making the radial incisions; **Figure 7**, dilatation; **Figure 8**, final result after dilatation and **Figure 9**, endoscopic review after 4 weeks.

In 2016, Bravi et al. [32] reported a series of 60 patients with diaphragm-like strictures no larger than 3 mm. At least 4 radial incisions were made with a needle sphincterotome with no other technique. The stricture was resolved in 100% of the cases, with no complications, in one single session and with a recurrence rate of the strictures of 5% over a follow-up period of 35 months.

In 2017, a meta-analysis [33] of 10 studies involving a total of 186 patients treated with this technique, either alone or in combination with other techniques, found clinical success in

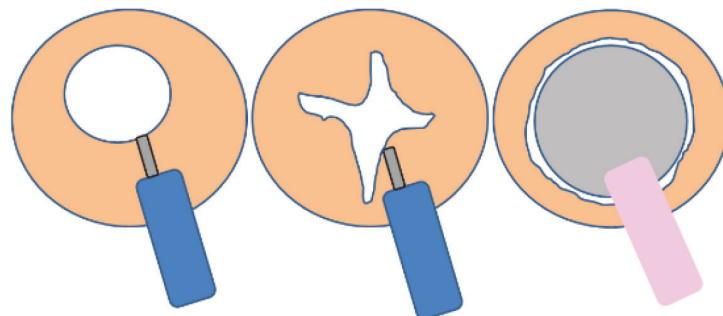


Figure 4. Combined EEI and dilatation.

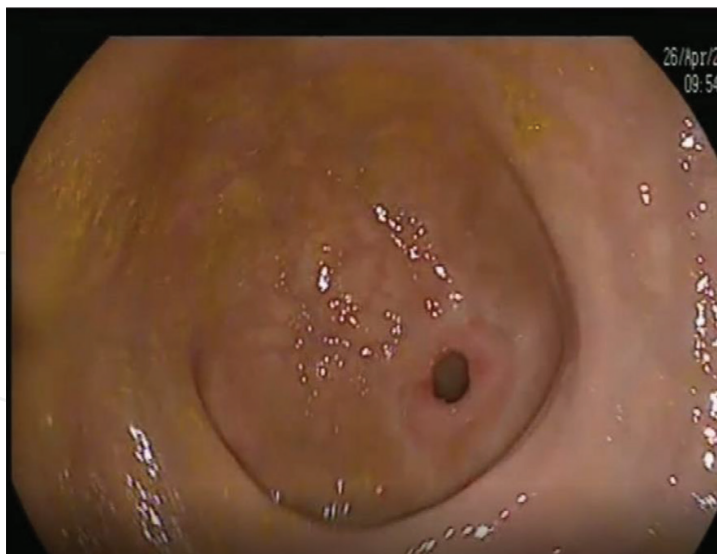

Figure 5. Colon stricture.

95.2% of cases for EEI, 95.8% for RIC and 87.8% for EEI combined with balloon dilatation. The recurrence rate of the strictures was 4.8, 0 and 12.5%, respectively. Complications occurred in 3.8% of cases, consisting of post-procedure abdominal pain. No other complication like bleeding, infection or perforation was noted.

Of note is the greater recurrence when incisions are combined with balloon dilatation. This could be explained by the fact that the dilatation increases the trauma to the stricture, with the corresponding inflammatory changes and retraction.

Accordingly, the results of this last meta-analysis suggest that this technique, either alone or accompanied by others, could be a safe and efficient alternative for short refractory postsurgical strictures or even possibly in naïve patients as it has a lower rate of complications and recurrences than balloon dilatation [34].

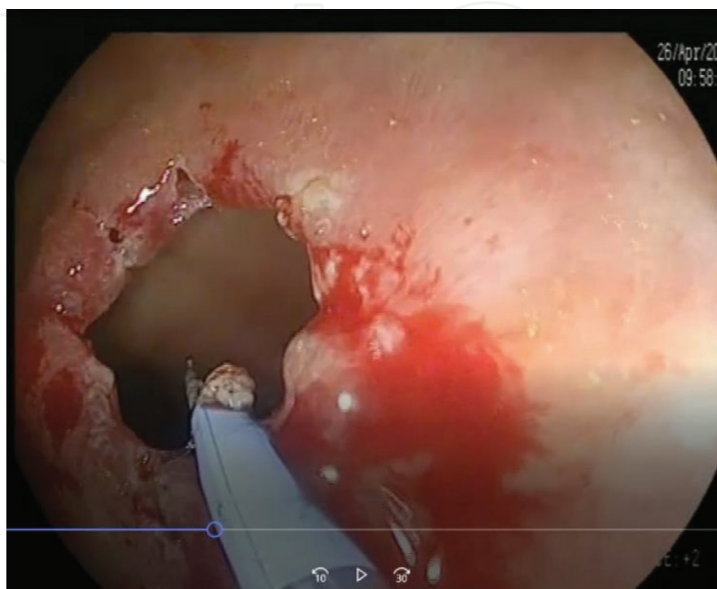


Figure 6. Making the radial incisions.

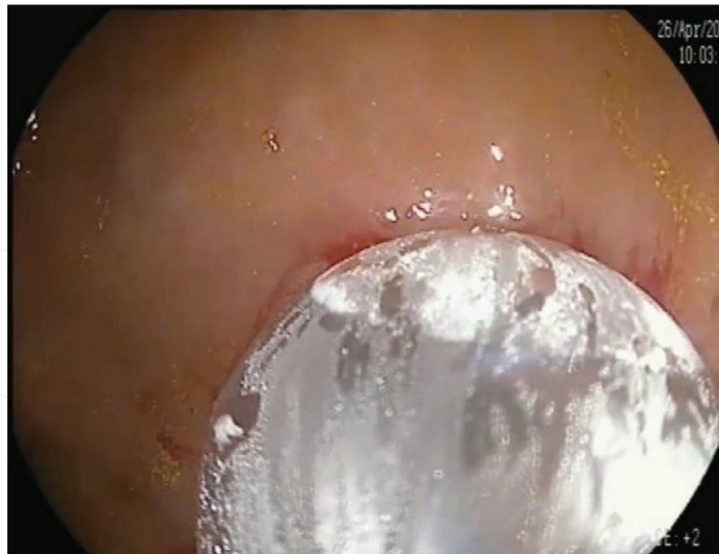

Figure 7. Dilatation.

2.5. Novel treatments: lumen-apposing metal stents

Lumen-apposing metal stents have very recently been incorporated for the treatment of postsurgical benign colon strictures. This stent was designed for the treatment of peripancreatic fluid collections. The ends are shaped like a diabolo, enabling the stent to be anchored by creating an anastomosis between the digestive tract and the fluid to be drained. This reduces the possibility of migration and, as they are fully covered, their later withdrawal is relatively easy (see **Figure 10**).

This characteristic led to its use in the treatment of benign strictures of the digestive tract. Several studies have assessed its usefulness, although with only a few patients and mostly concerning benign strictures of the upper digestive tract; however, some include postsurgical colon strictures [35–38].

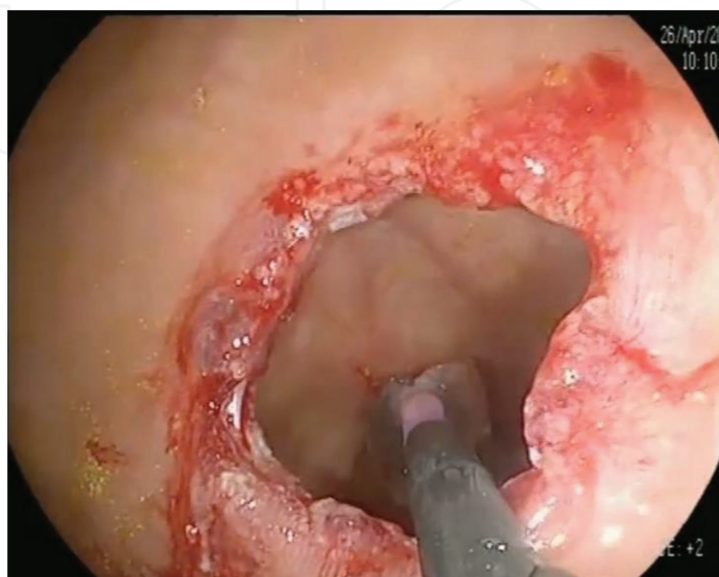


Figure 8. Final result after dilatation.

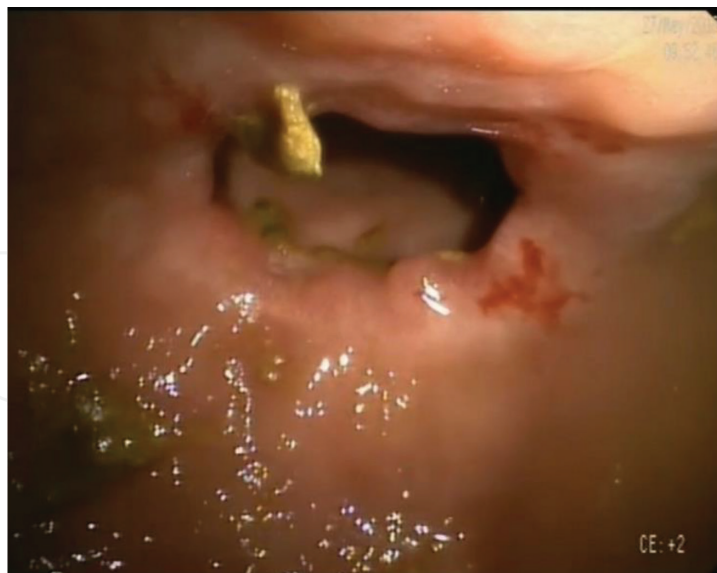

Figure 9. Review after 4 weeks.



Figure 10. Lumen-apposing metal stent.

The clinical success rate improves significantly as compared with the traditional covered metal stents, reducing the rate of stent migration and with a lower complication rate. The study by Irani et al. [35] reports 25 patients, including one case of a colon anastomotic stricture, with a clinical success rate of 60% over a follow-up period of 6 months and a migration rate of just 7%.

Yang et al. [36] presented results for 30 patients, with a clinical success rate of 82.6% after a follow-up period of 100 days. The migration rate was 8%, and complications arose in 13.3% of the patients, only two of which were severe (6.7%). This study included four postsurgical colon strictures, of which three failed to achieve long-term resolution of symptoms.

Other studies, such as those of Bazerbachi et al. [37] or Santos-Fernandez et al. [38], report higher stent migration rates (17.9 and 19%, respectively), at the expense of those implanted for colon strictures. Nonetheless, this complication is considerably less than that observed with conventional metal stents. It should be noted that the former study included seven patients with postsurgical colon strictures and the latter just two patients.

No large series have evaluated the efficacy of lumen-apposing stents in this particular indication; just the patients included in the previously mentioned series or isolated clinical cases [39]. However, they seem to have a promising role if they are able to reduce the complications seen with other types of stent, as seems possible.

Finally, as a novelty, reports exist of the treatment of complete anastomotic strictures in patients with a stoma, approached via distal endoscopic ultrasound-guided rendezvous [39], filling the proximal colon with water to locate by ultrasound the suitable puncture point and then placement of the stent.

3. Conclusions

Although there are no clinical guidelines with established algorithms for the treatment of benign postsurgical strictures, current evidence suggests that the first therapeutic option should be balloon dilation. In cases refractory to this treatment after at least three sessions, one of the following alternatives can be considered: incisional therapy or metal stent, and for the latter, the greatest evidence for safety and efficacy favours fully covered stents. The possible usefulness of lumen-apposing metal stents remains to be established. Biodegradable stents, at least at the present time, have a marginal role with less evidence for their usefulness. Prospective controlled studies are required to determine whether incisional therapy can replace balloon dilatation as first-line therapy.

Conflicts of interest

The authors have no conflicts of interest to declare.

Author details

Isabel Pinto García, Luis Antonio Vázquez Pedreño, Asunción Durán Campos, Miguel Jiménez Pérez* and David Marín García

*Address all correspondence to: mjimenezp@commalaga.com

Department of Gastroenterology and Hepatology, Endoscopy Unit, Regional University Hospital, Malaga, Spain

References

- [1] Feo L, Schaffzin DM. Colonic stents: The modern treatment of colonic obstruction. *Advances in Therapy*. 2011;**28**:73-86. DOI: 10.1007/s12325-010-0094-6
- [2] Kawaguchi K, Kurumi H, Takeda Y, et al. Management of esophageal strictures post ESD. *Annals of Translational Medicine*. 2017;**5**(8):184. DOI: 10.21037/atm.2017.04.22
- [3] Park CH, Yoon JY, Park SJ, et al. Clinical efficacy of endoscopic treatment for benign colorectal stricture: Balloon dilatation vs stenting. *Gut and Liver*. 2015;**9**:73-79. DOI: 10.5009/gnl13326
- [4] Luchtefeld M, Milson J, Senagore A, et al. Colorectal anastomotic stenosis. Result of a survey of ASCRS membership. *Diseases of the Colon and Rectum*. 1989;**32**:733. DOI: 10.1007/BF02562119
- [5] Polese L, Vecchiato M, Frigo AC, et al. Risk factors for colorectal anastomotic stenoses and their impact on quality of life: What are the lessons to learn? *Colorectal Disease*. 2012;**14**(3):124-128. DOI: 10.1111/j.1463-1318.2011.02819.x
- [6] Truong S, Willis S, Schumpelick V. Endoscopic therapy of benign anastomotic strictures of the colorectum by electroincision and balloon dilatation. *Endoscopy*. 1997;**29**:845-849. DOI: 10.1055/s-2007-1004319
- [7] Araujo SE, Furtado Costa A. Efficacy and safety of endoscopic balloon dilation of benign anastomotic strictures after oncologic anterior rectal resection: Report on 24 cases. *Surgical Laparoscopy, Endoscopy & Percutaneous Techniques*. 2008;**18**:565-568. DOI: 10.1097/SLE.0b013e31818754f4
- [8] Kwon YH, Jeon SW, Lee YK. Endoscopic management of refractory benign colorectal strictures. *Clinical Endoscopy*. 2013;**46**:472-475. DOI: 10.5946/ce.2013.46.5.472
- [9] Biraima M, Adamina M, Jost R, et al. Long-term results of endoscopic balloon dilation for treatment of colorectal anastomotic stenosis. *Surgical Endoscopy*. 2016;**30**:4432. DOI: 10.1007/s00464-016-4762-8
- [10] Di ZH, Shin JH, Kim JH, et al. Colorectal anastomotic strictures: Treatment by fluoroscopic double balloon dilation. *Journal of Vascular and Interventional Radiology*. 2005;**16**(1):75-80. DOI: 10.1097/01.RVI.0000142595.83630.EE
- [11] Ragg J, Garimella V, Cast J, et al. Balloon dilatation of benign rectal anastomotic strictures-a review. *Digestive Surgery*. 2012;**29**:287-291. DOI: 10.1159/000341657
- [12] Mangiavillano B, Pagano N, Arena M, et al. Role of stenting in gastrointestinal benign and malignant diseases. *World Journal of Gastrointestinal Endoscopy*. 2015;**7**(5):460-480. DOI: 10.4253/wjge.v7.i5.460
- [13] Small AJ, Young-Fadok TM, Baron TH. Expandable metal stent placement for benign colorectal obstruction: Outcomes for 23 cases. *Surgical Endoscopy*. 2008;**22**:454-462. DOI: 10.1007/s00464-007-9453-z

- [14] Jessamy K, Ozden N, Simon HM, et al. Self-expanding metal stenting in the management of a benign colonic stricture. *Case Reports in Gastroenterology*. 2016;**10**:127-131. DOI: 10.1159/000445185
- [15] Dai Y, Chopra SS, Wysocki WM, et al. Treatment of benign colorectal strictures by temporary stenting with self-expanding stents. *International Journal of Colorectal Disease*. 2010;**25**:1475-1479. DOI: 10.1007/s00384-010-1038
- [16] Currie A, Christmas C, Aldean H, et al. Systematic review of self-expanding stents in the management of benign colorectal obstruction. *Colorectal Disease*. 2014;**16**(4):239-245. DOI: 10.1111/codi.12389
- [17] Cereatti F, Fiocca F, Dumont JL, et al. Fully covered self-expandable metal stent in the treatment of postsurgical colorectal diseases: Outcome in 29 patients. *Therapeutic Advances in Gastroenterology*. 2016;**9**(2):180-188. DOI: 10.1177/1756283X15610052
- [18] Lamazza A, Fiori E, Schillaci A, et al. Treatment of anastomotic stenosis and leakage after colorectal resection for cancer with self-expandable metal stents. *American Journal of Surgery*. 2014;**208**(3):465-469. DOI: 10.1016/j.amjsurg. 2013.09.032
- [19] Caruso A, Conigliaro R, Manta R, et al. Fully covered self-expanding metal stents for refractory anastomotic colorectal strictures. *Surgical Endoscopy*. 2015;**29**(5):1175-1178. DOI: 10.1007/s00464-014-3785-2
- [20] Lamazza A, Fiori E, Sterpetti V, et al. Self-expandable metal stents in the treatment of benign anastomotic stricture after rectal resection for cancer. *Colorectal Disease*. 2014;**16**(4):O150-O153. DOI: 10.1111/codi.12488
- [21] Vanbiervliet G, Bichard P, Demarquay JF, et al. Fully covered self-expanding metal stents for benign colonic strictures. *Endoscopy*. 2013;**45**:35-41. DOI: 10.1055/s-0032-1325769
- [22] Lorenzo-Zuñiga V, Moreno de Vega V, Marín I, et al. Biodegradable stents in gastrointestinal endoscopy. *World Journal of Gastroenterology*. 2014;**20**(9):2212-2217. DOI: 10.3748/wjg.v20.i9.2212
- [23] Pérez Roldán F, González Carro P, Villafáñez García MC, et al. Usefulness of biodegradable polydioxanone stents in the treatment of postsurgical colorectal strictures and fistulas. *Endoscopy*. 2012;**44**:97-300. DOI: 10.1055/s-0031-1291482
- [24] Janíček V, Horák L, Hnaníčěk J, et al. Biodegradable polydioxanone stent: A new option for therapy-resistant anastomotic strictures of the colon. *European Radiology*. 2011;**21**:1956-1961. DOI: 10.1007/s00330-011-2131-5
- [25] Toth E, Nielsen J, Nemeth A, et al. Treatment of a benign colorectal anastomotic stricture with a biodegradable stent. *Endoscopy*. 2011;**43**:E252-E253. DOI: 10.1055/s-0030-1256462
- [26] Repici A, Pagano N, Rando G, et al. A retrospective analysis of early and late outcome of biodegradable stent placement in the management of refractory anastomotic colorectal strictures. *Surgical Endoscopy*. 2013;**27**:2487-2491. DOI: 10.1007/s00464-012-2762-x

- [27] Jain D, Mahmood E, Singhal S. Biodegradable stents: An evolution in management of benign intestinal strictures. *Journal of Clinical Gastroenterology*. 2017;**51**(4):295-299. DOI: 10.1097/MCG.0000000000000725
- [28] Chen TA, Hsu WL. Successful treatment of colorectal anastomotic stricture by using sphincterotomes. *Frontiers in Surgery*. 2014;**1**:22. DOI: 10.3389/fsurg.2014.00022
- [29] Osera S, Ikematsu H, Odagaki T, et al. Efficacy and safety of endoscopic radial incision and cutting for benign severe anastomotic stricture after surgery for lower rectal cancer (with video). *Gastrointestinal Endoscopy*. 2015;**81**(3):770-773. DOI: 10.1016/j.gie.2014.11.011
- [30] Kawaguti FS, Martins BC, Nahas CS, et al. Endoscopic radial incision and cutting procedure for a colorectal anastomotic stricture. *Gastrointestinal Endoscopy*. 2015;**82**(2):408-409. DOI: 10.1016/j.gie.2015.03.1975
- [31] Schubert D, Kuhn R, Lippert H, et al. Endoscopic treatment of benign gastrointestinal anastomotic strictures using argon plasma coagulation in combination with diathermy. *Surgical Endoscopy*. 2003;**17**(10):1579-1582. DOI: 10.1007/s00464-002-9173-3
- [32] Bravi I, Ravizza D, Fiori G, et al. Endoscopic electrocautery dilatation of benign anastomotic colonic strictures: A single-center experience. *Surgical Endoscopy*. 2016;**30**:229-232. DOI: 10.1007/s00464-015-4191-0
- [33] Jain D, Sandhu N, Singhal S. Endoscopic electrocautery incision therapy for benign lower gastrointestinal tract anastomotic strictures. *Annals of Gastroenterology*. 2017;**30**(5):473-485. DOI: 10.20524/aog.2017.0163
- [34] Ridditid W, Siripun A, Rerknimitr R. Stricture at colorectal anastomosis: To dilate or to incise. *Endoscopy International Open*. 2018;**6**(3):E340-E341. DOI: 10.1055/s-0043-122495
- [35] Irani S, Jalaj S, Ross A, Larsen M, et al. Use of a lumen-apposing metal stent to treat GI strictures (with videos). *Gastrointestinal Endoscopy*. 2017 Jun;**85**(6):1285-1289. DOI: 10.1016/j.gie.2016.08.028
- [36] Yang D, Nieto JM, Siddiqui A, et al. Lumen-apposing covered self-expandable metal stents for short benign gastrointestinal strictures: A multicenter study. *Endoscopy*. 2017 Apr;**49**(4):327-333. DOI: 10.1055/s-0042-122779
- [37] Bazerbachi F, Heffley JD, Abu Dayyeh BK, et al. Safety and efficacy of coaxial lumen-apposing metal stents in the management of refractory gastrointestinal luminal strictures: A multicenter study. *Endoscopy International Open*. 2017 Sep;**5**(9):E861-E867. DOI: 10.1055/s-0043-114665
- [38] Santos-Fernandez J, Paiji C, Shakhathreh M, et al. Lumen-apposing metal stents for benign gastrointestinal tract strictures: An international multicenter experience. *World Journal of Gastrointestinal Endoscopy*. 2017;**9**(12):571-578. DOI: 10.4253/wjge.v9.i12.571
- [39] Poincloux L, Pezet D, Rouquette O. Successful recanalization of complete anastomotic stricture using colorectal endoscopic ultrasound-guided rendezvous thus allowing stoma reversal: Two cases. *Endoscopy*. 2016;**48**(S 01):E353-E354. DOI: 10.1055/s-0042-118179