

We are IntechOpen, the world's leading publisher of Open Access books Built by scientists, for scientists

4,800

Open access books available

122,000

International authors and editors

135M

Downloads

Our authors are among the

154

Countries delivered to

TOP 1%

most cited scientists

12.2%

Contributors from top 500 universities



WEB OF SCIENCE™

Selection of our books indexed in the Book Citation Index
in Web of Science™ Core Collection (BKCI)

Interested in publishing with us?
Contact book.department@intechopen.com

Numbers displayed above are based on latest data collected.
For more information visit www.intechopen.com



Relation between Metopic Suture Persistence and Frontal Sinus Development

Silviya Nikolova, Diana Toneva, Ivan Georgiev and Nikolai Lazarov

Additional information is available at the end of the chapter

<http://dx.doi.org/10.5772/intechopen.79376>

Abstract

The frontal bone develops as two halves, which further unite in a single bone by the closure of the mid-sagittal metopic suture, typically by the end of the first postnatal year. The frontal sinus begins to expand into the orbital and vertical plates of the frontal bone postnatally and reaches the level of the *nasion* by the fourth year of age. At this time, the metopic suture is usually entirely closed. However, in the cases of failed closure of the metopic suture, its relationship to the frontal sinus development is still obscure. Here, we review the relevant literature and discuss the frontal bone development and maturation, from the viewpoint of the frontal sinus pneumatization in relation to the metopic craniosynostosis and failed closure of the metopic suture. The peculiar to the metopic skulls frontal bone configuration is rather an expression of the underlying neural mass demands than a consequence of the metopic suture persistence. Furthermore, the persistent metopic suture is frequently associated with a frontal sinus underdevelopment. It seems that the metopic suture does not inhibit the frontal sinus pneumatization itself, but rather both traits are an expression or an aftereffect of a certain condition during the early development.

Keywords: frontal bone, frontal sinus, persistent metopic suture, *metopism*, metopic craniosynostosis

1. Introduction

The different partitions and layers of the frontal bone develop and mature simultaneously, but independently from one another in accordance with the functional demands of the related soft tissues/cavities [1]. It has been observed that in cases of persistent metopic suture (MS), the frontal sinus (FS) develops separately on either side of the suture, as well as the MS precludes

the likelihood of development of the sinus beyond the median plane [2–4]. Nevertheless, the supposed influence of *metopism* on the FS development has not been synonymous. Some authors did not find a significant correlation between *metopism* and the underdevelopment of the FS [5–8], which leads to the assertion that the association of these variations is rather random. Other studies, however, revealed a tendency of MS persistence to be significantly related to the FS underdevelopment, including both FS aplasia and hypoplasia [4, 9–14]. Both the MS persistence and FS underdevelopment are not exceptional variations, but the correlation between them is intricate. There are many congenital disorders characterized by an underdevelopment of the nasomaxillary complex accompanied with diminished pneumatization of the FS such as Hajdu-Cheney syndrome, Down syndrome (DS), cleidocranial dysostosis and pyknodysostosis [11], which also feature a preservation of the MS [15–17]. In healthy adults, this correlation is still misunderstood. An adequate assessment of the relation between the frontal sinus development and metopic suture persistence requires a precise study of the events during their formation, development and maturation. In this study, we review the extant literature and discuss the frontal bone development and maturation, from the viewpoint of the frontal sinus pneumatization in relation to the metopic craniosynostosis and failed closure of the metopic suture. We aimed to reveal the possible underlying factors causing a delayed MS closure along with FS underdevelopment.

2. Frontal bone as a functional unit

The functional matrix concept of Moss [1, 18] considers the adult human frontal bone as a single morphological structure, which by no means is a single functional unit. In fact, the form of the frontal bone accurately reflects the functional demands of the protected and supported soft tissues/cavities. Furthermore, each of the three bone layers is functionally independent and responds to different functional demands. The inner table of the frontal bone is functionally associated with the development of the frontal lobe of the cerebral cortex and is exquisitely sensitive to alterations in the cerebral morphology throughout life [18]. The intimate dependence of endocranial form upon the state of adjacent soft tissues could be traced in examples like an extensive compensatory pneumatization and inward displacement of the frontal endocranial plate followed by an atrophy of the frontal cerebral lobe/cerebral hemiatrophy [18, 19]. The differentiation of the outer table is correlated with the increasing demands of the scalp tissues in general and of calvarial muscles in particular [1, 20], as well as with the growing nasomaxillary facial complex [11]. The diploë has several simultaneous functions, including hematopoiesis, weight reduction and pneumatization, functionally responsive to the respiratory system. Even the MS is far from being a simple, intrinsically regulated entity, being greatly influenced by related soft tissues, dura and cranial base [18].

3. Frontal sinus

3.1. Anatomy and development

The FS is one of the four paranasal sinuses and represents a space of variable shape and size between the inner and outer tables of the frontal bone. In adults, the FS appears as two

irregularly shaped cavities separated from each other by a thin septum commonly deviated from the mid-sagittal plane. Usually, the FS lobes extend vertically upwards into the frontal bone squama, but could also expand horizontally backwards between the two tables of the orbital plate [21] and sometimes into the crista galli of the ethmoid bone [11]. Not infrequently, the FS does not invade far into the vertical portion, but grows extensively into the horizontal one and forms large air spaces over the orbits [2]. In cases of the so-called ethmofrontal, orbital or infantile FS [2], it adheres closely to the ethmoidal labyrinth and extends only into the horizontal portion of the frontal bone. In rare cases, the pneumatization could be so profuse to extend beyond the frontal bone into the lesser and greater wings of the sphenoid, the parietal, the temporal, the nasal bone and even into the frontal process of the maxilla [11]. Furthermore, many other variations such as single midline sinus, due to a lack of septum, or supernumerary septa forming additional chambers in a variable pattern, have been reported [2, 11, 22].

Unlike the other sinuses, the FS is practically absent at birth. It could be recognized during the fourth fetal month as diverticula from the lateral nasal wall following the development of the frontal recess. The FS may also arise from the laterally placed anterior ethmoidal cells, the anterior part of the frontal recess or from the frontal furrow [23], but does not pneumatize the frontal bone until the postnatal period. The pneumatization begins in the horizontal (orbital) plate during the first year of life, whereas the pneumatization of the vertical plate commences during the latter half of the second postnatal year and progresses slowly to reach the level of the *nasion* by the fourth year of age [11]. Both lobes of the FS develop independently, and therefore they are often highly asymmetrical due to more rapid pneumatization on one side at the expense of the other [21]. The main period of enlargement coincides with the pubertal growth spurt, but may go on increasing into the fourth decade of life [24].

From the viewpoint of the functional matrix concept, the FS develops through resorption of the diploë, which is housed between the two functionally independent bone tables. The internal table is the intrinsic part of the cerebral capsule, since its periosteum is the outer layer of the dura and is functionally related to the configuration of the frontal lobes. The outer table is related with the increasing demands of the scalp tissues, calvarial muscles [1] and nasomaxillary facial complex [11]. During the first few years of life, the inner table drifts anteriorly in response to the growing frontal lobes. Since there is no significant diploë at this time, the inner table carries the contiguous outer table along with it. After the frontal lobes have undergone their major development at the age of 6–7 years, growing of the inner table ceases and adopts the general shape of the brain. However, the functionally independent outer table continues to drift anteriorly in response to the stimulus of the growing nasomaxillary facial complex, which during puberty is intensively remodeled and displaced more anteriorly and inferiorly. This results in a progressive separation of both tables of the frontal bone, resorption of the diploë and formation of the FS cavities [11].

3.2. Function

Currently, the insight into the biological and functional significance of the paranasal sinuses is speculative rather than known. It has been suggested that the FS contributes to the ventilation and air-conditioning (heating and humidifying the inspired air), the increase in the olfactory membrane area, the lightening of the skull, voice resonance, protection and thermal insulation of the cerebrum and orbits, shock absorption, an adjustment to the growth and development of the cranium. Finally, the FS has been supposed to be an evolutionary residual space [25, 26].

3.3. Factors affecting the FS development and morphology

The factors modifying the FS development and morphology are heterogeneous and are of genetic, environmental or pathological origin. Factors related to the final shaping of the FS and responsible for the wide variations are supposed to be a craniofacial configuration, frontal bone thickness, extent of the supraorbital ridges [27], hormonal growth factors, *metopism*, [11], sex [28, 29], cranial indices and ancestry [30], climatic factors [26, 28, 31], a varying degree of resorption of the diploë, an ambient air pressure and breathing [32]. According to Arnaud et al. [33], both craniofacial configuration and frontal bone width related to the intracranial pressure influence the frontal pneumatization. Heterogeneous pathological condition such as trauma, infection, tumors, mucoceles and various congenital disorders have also been reported as factors affecting the frontal sinus size and morphology in a different way [11].

3.4. FS aplasia

The FS is topographically ethmoidal before it becomes a frontal through pneumatization of the frontal bone, and in this way, it is conspicuously present at birth in all cases [2]. A total agenesis of the FS or the lack of any pneumatization of the frontal bone in healthy adults is very rare [2, 21]. The FS aplasia has been reported to vary from 0.7 to 62% in different population groups [4, 21, 23, 28, 31, 34–39]. The unilateral aplasia of the FS has been found to be more common than the considerably rarer bilateral one [4, 21, 40]. The side prevalence varies in different population groups, but right-sided aplasia seems to be more frequent [4, 8, 21]. There have also been reported cases of agenetic FS, where the contralateral sinus expands and crosses the midline towards the agenetic side and mimics the presence of bilateral frontal sinuses [41]. Sex differences in the frequency of the FS aplasia have been established as well and it tends to be more common in females [21, 35, 38].

3.5. Relation between FS development and definite pathological conditions

Abnormal pneumatization of the FS has been a concomitant finding in a number of heterogeneous disorders. It has been noted that in patients with cerebral hypoplasia, the FS is larger in size while in hypoplasia of the midface, it is smaller [11].

3.5.1. FS hyperpneumatization

The etiology of an excessive sinus aeration and growth resulting in a condition known as “pneumosinus dilatans” is unclear [42]. Pneumosinus dilatans is a generalized or partial enlargement of the paranasal sinuses containing only air. Pneumosinus dilatans occurs as an idiopathic disorder as well as in association with other disorders, including cerebral hemiatrophy [19]. Furthermore, the extreme sinus pneumatization has been associated with heterogeneous disorders such as osteogenesis imperfecta tarda, Turner syndrome, Klinefelter syndrome and acromegaly [11].

3.5.2. FS underdevelopment

The *FS underdevelopment* usually occurs in patients with craniofacial abnormalities. There are many congenital disorders characterized by an underdevelopment of the nasomaxillary

complex. According to Shapiro and Schorr [11], the hypoplasia of the midface blocks one of the major stimuli for the FS pneumatization, i.e. the need to provide a structural bridge between the cranium and the face. Such disorders like Hajdu-Cheney syndrome, cleidocranial dysostosis and pyknodysostosis exhibit diminished pneumatization of the FS [11, 43] and also feature a preservation of the MS [15–17]. Aplasia/hypoplasia of the FS has also been associated with Down syndrome, Apert syndrome, maxillofacial dysplasia, osteodysplasia (Melnick-Needles), Treacher-Collins syndrome [11], cystic fibrosis [44], etc.

3.6. FS in forensic medicine for identification in medico-legal cases

The FS has been considered to be unique in each person [45, 46]. Its shape differs significantly even in monozygotic twins [47]. Being an internal skull structure between the plates of the frontal bone, the FS is well protected from injuries and taphonomic processes. Thus, due to its uniqueness, relatively constant morphology, protected location and frequent radiological documentation, the FS is particularly useful for the identification of human remains [48–52]. The FS has also been used as a feature for sex prediction [53].

3.7. Neurosurgery and endoscopic surgery

The FS morphology has an impact in neurosurgical and endoscopic nasal interventions because of its proximity to the orbit and the anterior cranial base [41, 54]. The possibility to identify the internally located FS through superficial anatomical landmarks is essential for neurosurgery to avoid injury of the FS during intervention, which could lead to postoperative complications [54].

3.8. Methods for FS investigation

As an internal skull structure, the FS has been investigated using different destructive and non-destructive methods with specific advantages and shortcomings which are briefly considered. It has to be noted that when comparing data of the FS agenesis, development, morphology and morphometry, the examining techniques and equipment should be carefully taken into account.

3.8.1. Destructive methods

The FS has been investigated directly through sectioning of dry macerated skulls [7, 55] or by cadaveric dissections [2, 41, 54, 56]. These approaches are applicable for FS investigation on osteological material and in forensic aspect in medico-legal cases.

3.8.2. Non-destructive methods

3.8.2.1. Transillumination

It is the technique of illumination by the transmission of light through a sample/body part. Transillumination of the FS with electric lamp and permanent mapping of its outlines by drawing of the illuminated area with a pencil has been used for FS investigation and measurement in healthy living persons, patients with chronic suppuration, cadavers and macerated skulls in the beginning of the twentieth century [21]. The method has many limitations and is not widely used thereafter.

3.8.2.2. Radiological investigation

With the discovery of the X-rays in 1895 by Wilhelm Röntgen and the subsequent fast development of the radiography, computed tomography (CT) and their application in the clinical practice, the non-invasive diagnostic has been significantly improved. *Radiography (projectional radiography)* is an imaging technique using X-rays to visualize the internal structure of an object. Basically, a beam of X-rays, produced by an X-ray generator, is transmitted through the specimen. The X-rays are absorbed in different amounts by the object they pass through, depending on its density and composition. The unabsorbed X-rays, passed through the object, are recorded on an X-ray sensitive film or a digital detector. The first radiographic signs of FS development are detected between the ages of 4 and 11, with an average of 8.3 years [57]. It is well known that the investigation of a complex 3D structure like FS on 2D radiographs has some inherent limitations. The superimposition of anatomical structures beyond the plain of interest complicates the interpretation of the FS morphology. Furthermore, the estimation of the FS depth, area and volume is complicated and rude [50]. In radiograph-based measurements of the FS, the magnification, positioning and angulation of the skull are crucial for a reliable morphometry [4, 58]. Therefore, in radiographic FS investigations, a definite head/skull orientation is indispensable. Caldwell's view is recommendable, since it provides the clearest FS silhouette and the least chance for error in the interpretation [22]. In Caldwell's view, the skull is inclined 20° from the Frankfurt horizontal plane (FH), the one determined by both landmarks of *porion* and the left *orbitale*. An inclination of 45° from the FH or the so-called Waters' view is also acceptable, but a little bit incorrect for FS measurements [58]. On the plain radiography, the orbital pneumatization is hardly recognizable and is commonly reported as FS aplasia, which unavoidably increases the frequency of FS agenesis [30]. *Conventional plain radiography* has been widely used for FS investigation due to its accessibility. Until now, the conventional plain radiography has been used as a frequent method for diagnostic imaging and documentation of the head including the dentition. Thus, many investigations of the FS in different contexts have been carried out on such datasets of patients' archives. The conventional plain radiography has also been purposefully used for FS investigation on osteological material [26, 30]. In *digital radiography*, the X-ray film/plaque is replaced by a digital X-ray detector. Digital radiography performed on industrial CT systems has been termed an *industrial digital radiography*. Its application as a modality for FS investigation and morphometry in dry skulls has been discussed by Nikolova et al. [4, 14, 58]. Industrial digital radiography allows a precise orientation at the appropriated position, a real-time inspection with optimal X-ray parameters and storage of the captured projections in image file formats. The high resolution of the flat panel detector ensures perfect image quality, precise scaling of the pixel size and reliable readings of the linear FS measurements (**Figure 1**).

3.8.2.3. Volumetric imaging (3D)

It has many advantages and enables the examination of the inner structure of the scanned object into the three orthogonal plains. The volumetric imaging allows the selection of a definite structure as a "region of interest" and its further segmentation. After segmentation,

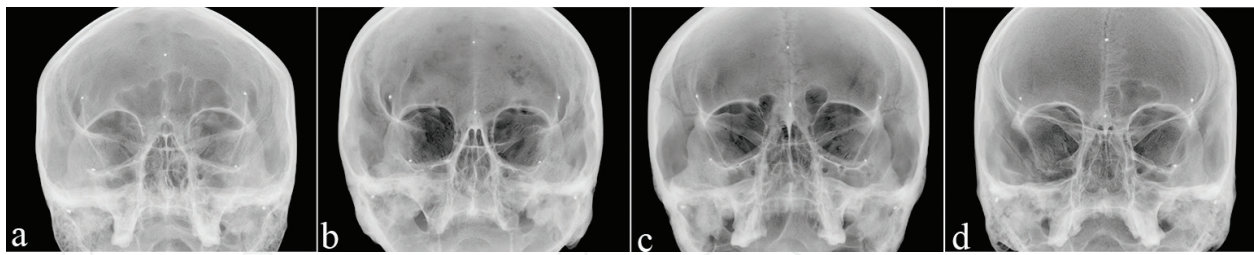


Figure 1. Industrial digital radiographs of dry adult male skulls oriented in Caldwell's view: (a) frontal sinus of normal size; (b) bilateral aplasia of the frontal sinus; (c) underdeveloped frontal sinus of the orbital type in a metopic skull; and (d) right-sided frontal sinus aplasia in a metopic skull.

a representation of the FS cavities could be generated as a separate 3D object, the so-called virtual endocast (**Figure 2**). The virtual endocasts ensure precise metric analyses, storage and further verification of the obtained results, as well as visualization of the real object by 3D printing (**Figure 3**). However, both the resolution and segmentation algorithm are essential for the endocasts reliability (**Figure 4**). In principle, medical and industrial CT systems use different scanning process and algorithms for the calculation and reconstruction

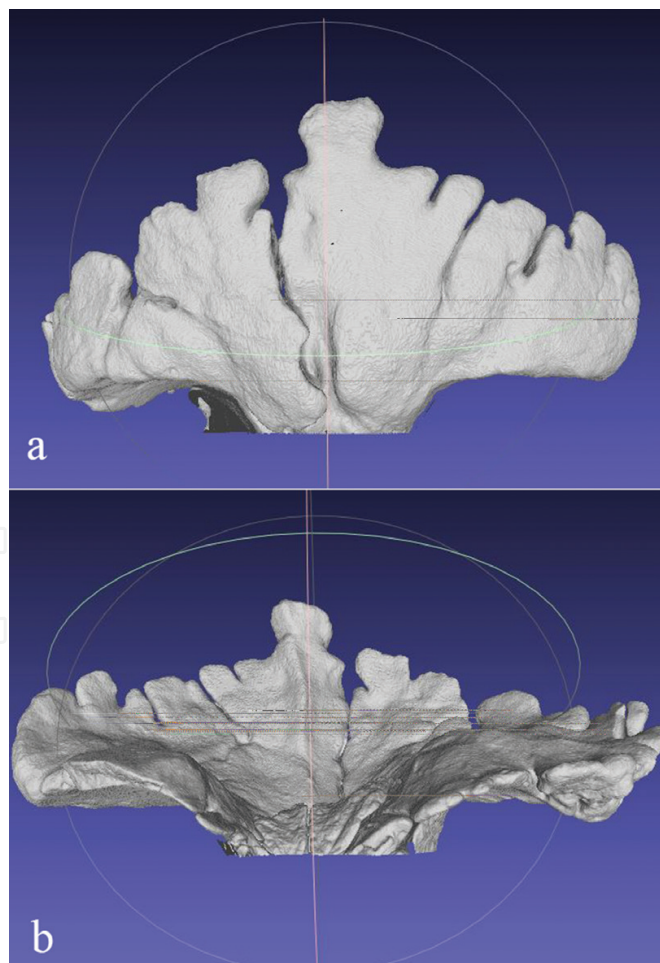


Figure 2. Virtual endocast of the hyperpneumatized frontal sinus segmented from an industrial μ CT dataset above the *nasion*: (a) frontal view and (b) backward view.

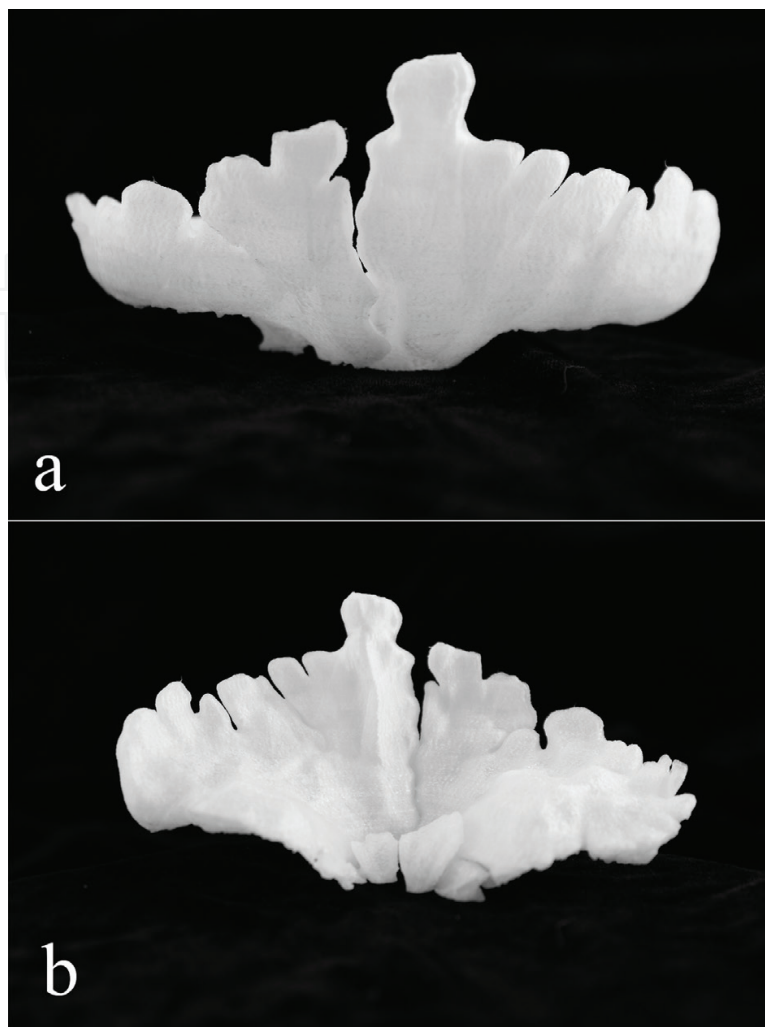


Figure 3. A 3D printed representation of the same hyperpneumatized frontal sinus in real size: (a) frontal view and (b) backward view.

of the volume of the object. Both types of CT systems have their advantages and limitations. For instance, medical CT systems are able to perform fast scan of a large object such as the human body. Limitations are the short exposure time with minimal radiation doses; hence, the images have relatively low resolution. On the other hand, the diagnostic imaging of patients enables the accumulation of large databases which could be used for various investigations on the contemporary populations. Industrial μ CT systems are highly versatile and generate images with a high resolution, which allow qualitative observation [59] and quantitative calculation of stereological parameters and degree of anisotropy for porous materials like bone tissue directly from the datasets [60]. Besides, the virtual endocasts of the FS generated from μ CT data are very reliable. However, the dimensions of the scan object are too limited, the generated files are large and the modality is entirely inapplicable *in vivo*.

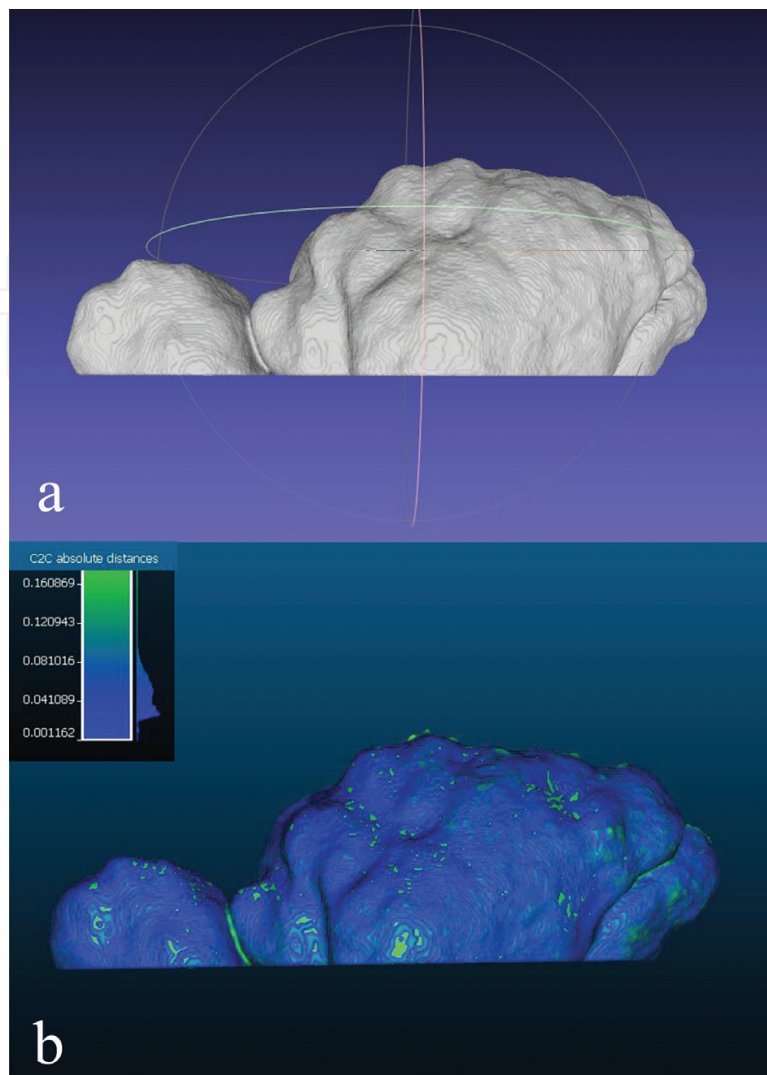


Figure 4. Comparison of frontal sinus virtual endocasts for the establishment of their reliability: (a) virtual endocast and (b) superimposition of two virtual endocasts of the same frontal sinus.

4. Metopic suture, metopic craniosynostosis and *metopism*, definitions and causative factors

The MS is considered an anterior continuation of the sagittal suture. It runs from *nasion* to the anterior border of the anterior fontanelle and is responsible for the growth of the anterior part of the calvaria in width. During the fetal life, the frontal bones undergo intramembranous ossification from a single primary centre located in each halve. The halves are separated by the sutural space [61]. At the ninth gestational week, a small ossification centre is visible in the middle of each supraorbital part of the frontal bones, and subsequently the ossification spreads. The frontal bones reach the midline at the nasal area at the 11th gestational week. The

gap between the two frontal bones in the midline starts closing from the nasal region at around the 16th intrauterine week and moves superiorly towards the anterior fontanelle by the 28th week. At the 32nd week of gestation, there is apparent closure of the MS at the supranasal region, and subsequently, the closure moves superiorly towards the anterior fontanelle [62].

The metopic sutural area, i.e. the adjacent frontal bone edges along with the intervening soft tissues, tends to have a simple “butt-ended” appearance. The interdigitation is a secondary response to imposed biomechanical extrinsic forces [63] and does not follow any special pattern [61], but its widespread presence suggests that the suture is under increased biomechanical stimulation [64]. Some of the interdigitations are united by thin bridges of chondroid tissue which pass through the sutural space, constituting the first microscopic sign of frontal fusion [61]. The location of the fusion point is not invariably endocranial as it is in rats [65], but is sparse and randomly distributed [61].

The MS is the first one to close physiologically as its fusion is a progressive process initiated at the nasion and completed at the anterior fontanelle [62, 66, 67]. The completion of normal fusion occurs between 2 and 14 months in 95% of the normal population with an estimated average age of completion at 8.24 months [68]. After the initiation at an average of 5 months, the process of fusion takes approximately 3–4 months to complete. Furthermore, when the fusion process starts at a younger age, it takes less time to complete [68]. However, the MS has been reported to remain patent up to the seventh year [69].

Premature closure of the MS, metopic craniosynostosis, results in a growth restriction of the frontal bones which leads to a skull deformation known as trigonocephaly [70]. The epidemiology of metopic synostosis has been reported to be 1:5200 newborns, and it is the second most frequently seen type of isolated craniosynostosis after the sagittal one [70]. The etiology of metopic synostosis is multifactorial and has been supposed to be related to intrinsic bone malformation occurred either by genetic, metabolic, or pharmaceutical means [70]. According to Moss [1], the calvaria, dura and cranial base form a single biomechanical entity, and a primary malformation of the cranial base produces abnormal forces within its attached dural fiber tracts, which, in turn, produces premature cranial synostosis. In this sense, the observed neurocranial deformation is the final result. Premature synostosis of the MS, for instance, has been found to be a frequent characteristic of the cleft-palate skull. A cranial base malformation (dysostosis sphenoidalis) was a primary morphological event associated with orofacial clefting. This condition, characterized by a strong basal kyphosis, sets up abnormal tensile condition in the falx cerebri, resulting in the fusion of the overlaying suture [71]. A reported case of trigonocephaly with open MS also suggests that the primary cause is not the MS synostosis, but rather it is a consequence and the underlying cause could be an intrinsic malformation such as hypoplasia of the frontal lobes, which thus require only limited space in the anterior cranial fossa [72]. Furthermore, it has experimentally been established that the normal endocranial fusion of the posterior portion of the MS is well correlated with the structural alterations in the falx cerebri. In rats, normal metopic fusion was inhibited when the underlying dural (falx cerebri) fibre tract was separated from the overlaying sutural area. Conversely, periosteal stripping was followed by synostosis of calvarial sutures that normally are patent throughout life [1].

Failed fusion of the MS leads to a condition known as *metopism*. In such cases, the MS runs from *nasion* to *bregma*, the intersection of sagittal and coronal sutures (**Figure 5**). It is

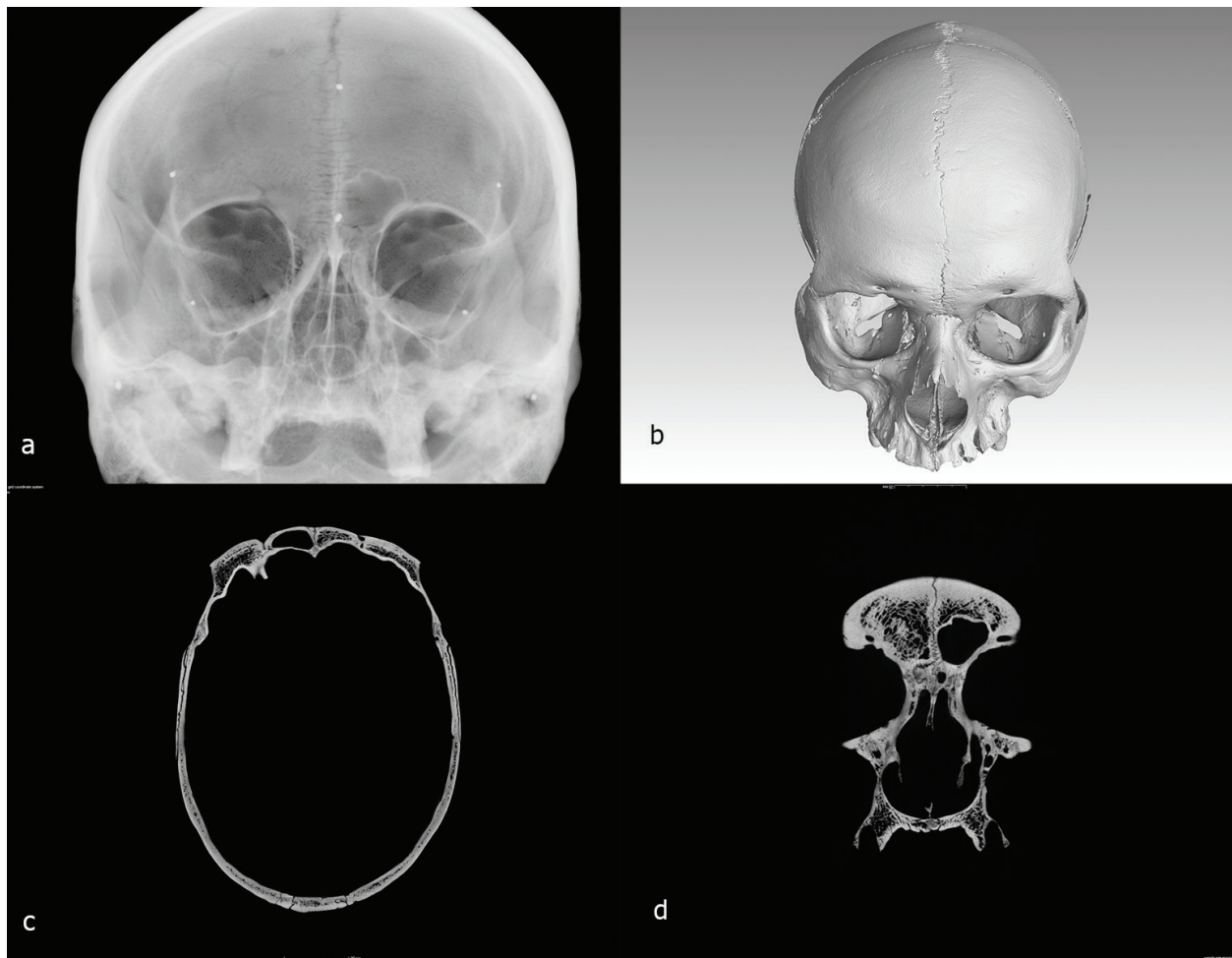


Figure 5. Metopic skull of adult male with aplasia of the right FS: (a) industrial digital radiograph in Caldwell's view; (b) 3D volume representation obtained after scanning with industrial μ CT; (c) axial tomogram at the level of FS; and (d) coronal tomogram at the level of FS.

reported that the preserved MS ranges from 0.8 up to 15% in different population groups [14, 73–79]. The persistence of the MS in adults is not reported to cause any abnormalities by itself. However, it has been found as a concomitant finding in numerous disorders [16, 80]. Among the causative factors for *metopism* are considered to be stenocrotaphy, plagiocephaly, brachycephaly, encephalic pressure, diminution of muscular pressure, endocrine dysfunction, atavism, heredity and heredo-specific factors [81], an abnormal growth of the cranial bones, hydrocephaly, growth retardation, sexual influence, scaphocephaly and mechanical causes [82].

It has already been established that metopic skulls possess specific distinctive configuration of the neurocranium characterized by a broad forehead with greater inter-frontal and inter-orbital breadths [4, 81, 83–85], as well as a greater frontal curvature [75]. The metopic skulls attain a given capacity by a greater expansion in the forward direction and a smaller development in the hinder part of the vault. Therefore, the *metopism* could not be explained merely by a supposed expansion of the frontal lobes and namely the prefrontal cortex, but rather as an adjustment of the braincase as a whole to its contents [83]. Furthermore, despite the close developmental interrelation between the neuro- and

basicranium, the preservation of the MS along with a specific construction of the neurocranium was not found to be related to an alteration in the cranial base expressed by cranial base angle [86]. All this suggests that the *metopism* is not related to a primary cranial base deformation.

The neurocranial capsule responds secondarily to the primary expansion of the neural mass, consisting of brain, leptomeninges and cerebrospinal fluid, by passive translation of the bones outwards [1]. Hyper- and hypovolumetric growth of the neural mass volume is the primary etiological factor in macro- and microcephaly, respectively. That the volume alone is responsible is well demonstrated by the essentially normal neurocranial sizes and shapes of hydranencephaly [1, 18]. Consequently, the MS persistence is not responsible for the distinctive skull configuration, but rather is an expression of the underlying neural mass specific demands.

5. Metopic suture persistence and frontal sinus development

It has been suggested that the MS preservation suppresses the FS development [27, 40]. A possible explanation has been supposed to be the simultaneous FS development along with the frontal bone growth, most probably with a feedback regulating mechanism. Thus, if the frontal bones fail to fuse, the MS persists and the pneumatization of the frontal sinuses could be retarded or entirely suppressed [32]. Another suggestion is that the MS does not inhibit the FS development itself, but rather the accumulation of both features in nonsyndromic individuals is an expression or an aftereffect of a certain condition during the early development [4]. It is known that the craniosynostosis results in an underdevelopment of the FS due to the increased intracranial pressure (ICP) that hinders pneumatization of the sinuses [87, 88], since the FS development is an inverse ratio to the ICP [89]. However, a surgical enlargement of the neurocranium with an adequate stabilization leads to a decrease in the pressure on the inner frontal cortex; thereafter, the FS pneumatization proceeds normally [88]. Nevertheless, the FS pneumatization seems to depend on the craniosynostosis and on the type of surgery performed [33]. According to McCarthy et al. [87], the fronto-orbital advancement appears to have the detrimental effect on FS development, whereas the strip craniectomy procedures do not. It has been speculated that the path of the ethmoid pneumatization into the FS is interrupted by the saw cut, the gap or defect resulting from the advancement/displacement of the supraorbital bar, as well as residual bone formation. Contrarily, Locher et al. [88] stated that following bilateral fronto-orbital advancement, a nearly regular FS development is possible, with the exception perhaps of the severe cases of Crouzon syndrome. Notwithstanding, if the FS developed after the surgical intervention, it is often located in the roof of the orbits [33].

Besides craniosynostosis, the elevation of the ICP could be a consequence of many other heterogeneous conditions such as haematoma, neoplasm, trauma, seizure, hydrocephalus, meningitis, etc. [90], and most of them are not associated with a distortion of the skull configuration. In newborns and infants, the main signs of acute and chronic elevation of ICP are

suture diastasis (mainly coronal and metopic) and bulging of the anterior fontanelle [90]. The excessive head growth is a major feature for an increased ICP until the age of 3 years since the expansion of the skull volume allows partial venting of the increased pressure [91]. Nonetheless, the normal head growth does not preclude the presence of an increased ICP, as the rate of the pressure increase is also important, because the intracranial structures accommodate remarkably well to slowly increasing pressure, while sudden changes are intolerable and result in definite symptoms [91].

The *metopism* has been supposed to be related with the hypofunction of the thymus inducing a condition of prolonged infantilism, which finds expression in the persistence of the MS. Another suggestion is that the hypopituitarism has been concerned in the MS persistence. Both the hypofunction of thymus and pituitary glands independently result in a retardation of bone growth similar to that in rickets, with a marked deficiency in the normal processes of ossification and a tendency for arrested suture obliteration [81]. The iron deficiency anemia (IDA) is a common type of anemia, which has been reported to be associated with an impaired thymus function [92] and a well-known consequence of hypopituitarism [93]. The IDA has been identified as one of the risk factors for vitamin D deficiency in some populations [94]. Patients with IDA have been reported to feature MS preservation [95]. Furthermore, due to the overgrowing red marrow, the severe IDA causes skull thickening, which in turn involves FS underdevelopment [11, 96]. The IDA has also been associated with an increased ICP [97, 98]. The intracranial hypertension has been supposed to be a possible underlying cause for MS persistence along with the FS underdevelopment [4, 59].

The MS preservations, a delayed closure of the anterior fontanelle and wormian bone formation have been found to be common in patients with Down's syndrome [99]. Underdeveloped FS is also typical of the DS [43]. In patients with DS, the thymus function has been significantly impaired [100]; however, it is still unclear whether or not the short stature in DS involves pituitary hypofunction due to the suboptimal production of the growth hormone, or rather involves hypothalamic dysfunction [101, 102]. Interestingly, the IDA is a frequent condition in DS [103].

It could be seen that the persistent MS along with FS underdevelopment and other common symptoms are typical of heterogeneous disorders like DS and IDA, and both conditions involve or are due to an iron deficiency. The iron deficiency is a widespread nutritional disorder in infants, children and women of reproductive age. It has already been suggested that the *metopism* probably is caused by impairment of the ossification process due to a nutritional deficiency and more exactly the lack of calcium. This suggestion has been based on the assumption that the *metopism* has been more prevalent in the medieval than today, in populations with a low life expectancy and among women who have become pregnant and have given birth immaturely [104]. Bearing in mind the symptoms and consequences of IDA, it seems reasonable to suggest that the MS preservation along with the FS underdevelopment could be an expression or aftereffect of nutritional deficiency and more exactly the iron deficiency during early development. This suggestion could be verified through a purposeful monitoring and longitudinal study of patients with confirmed IDA.

6. Conclusion

The peculiar to the metopic skulls frontal bone configuration is rather an expression of the underlying neural mass demands than a consequence of the MS persistence. Moreover, the persistent MS is frequently associated with FS underdevelopment. It is reasonable to suggest that the MS does not inhibit the frontal sinus pneumatization itself, but rather both traits are expression or aftereffect of a certain condition during the early development.

Acknowledgements

This work was supported by the Bulgarian National Science Fund, grants DN01/15-20.12.2016 and DN11/09-15.12.2017.

Conflict of interest

The authors declare no conflict of interest.

Author details

Silviya Nikolova^{1*}, Diana Toneva¹, Ivan Georgiev^{2,3} and Nikolai Lazarov^{4,5}

*Address all correspondence to: sil_nikolova@abv.bg

1 Department of Anthropology and Anatomy, Institute of Experimental Morphology, Pathology and Anthropology with Museum, Bulgarian Academy of Sciences, Sofia, Bulgaria

2 Department of Scientific Computations, Institute of Information and Communication Technologies, Bulgarian Academy of Sciences, Sofia, Bulgaria

3 Department of Mathematical Modeling and Numerical Analysis, Institute of Mathematics and Informatics, Bulgarian Academy of Sciences, Sofia, Bulgaria

4 Department of Anatomy and Histology, Medical University of Sofia, Sofia, Bulgaria

5 Department of Synaptic Signaling and Communications, Institute of Neurobiology, Bulgarian Academy of Sciences, Sofia, Bulgaria

References

- [1] Moss ML. Functional anatomy of cranial synostosis. *Child's Brain*. 1975;1:22-33. DOI: 10.1159/000119554

- [2] Schaeffer J. *The Embryology, Development and Anatomy of the Nose, Paranasal Sinuses, Nasolacrimal Passageways and Olfactory Organs in Man*. Philadelphia: P Blakiston's Son; 1920
- [3] Davis WB. *Development and Anatomy of the Nasal Accessory Sinuses in Man*. London: WB Saunders Company; 1914
- [4] Nikolova S, Toneva D, Georgiev I, Lazarov N. Digital radiomorphometric analysis of the frontal sinus and assessment of the relation between persistent metopic suture and frontal sinus development. *American Journal of Physical Anthropology*. 2018;**165**:492-506. DOI: 10.1002/ajpa.23375
- [5] Marciniak R, Nizankowski C. Metopism and its correlation with the development of the frontal sinuses. *Acta Radiologica*. 1959;**51**:343-352. DOI: 10.3109/00016925909171105
- [6] Hunt DR, Everest K. Frontal sinus size: Sex, population and metopism affinities. *American Journal of Physical Anthropology*, Abstracts of AAPA poster and podium presentations. 2001;**114**(S32):82-83. DOI: 10.1002/ajpa.1035
- [7] Pondé JM, Andrade RN, Via JM, Metzger P, Teles AC. Anatomical variations of the frontal sinus. *International Journal of Morphology*. 2008;**26**:803-808. DOI: 10.1055/s-2003-37956
- [8] Bilgin S, Kantarcı UH, Duymus M, Yildirim CH, Ercakmak B, Orman G, Gunenc Beser C, Kaya M, Gok M, Akbasak A. Association between frontal sinus development and persistent metopic suture. *Folia Morphologica*. 2013;**72**:306-310. DOI: 10.5603/FM.2013.0051
- [9] Rochlin DG, Rubaschewa A. Zum Problem des Metopismus. *Zeitschrift für Menschliche Vererbungs- und Konstitutionslehre*. 1934;**18**:339-348
- [10] Torgersen J. A roentgenological study of the metopic suture. *Acta Radiologica*. 1950; **33**:1-11
- [11] Shapiro R, Schorr SA. A consideration of the systemic factors that influence frontal sinus pneumatization. *Investigative Radiology*. 1980;**15**:191-202
- [12] Baaten PJ, Haddad M, Abi-Nader K, Abi-Ghosn A, Al-Kutoubi A, Jurjus AR. Incidence of metopism in the Lebanese population. *Clinical Anatomy*. 2003;**16**:148-151. DOI: 10.1002/ca.10050
- [13] Guerram A, Le Minor JM, Renger S, Bierry G. Brief communication: The size of the human frontal sinuses in adults presenting complete persistence of the metopic suture. *American Journal of Physical Anthropology*. 2014;**154**:621-627. DOI: 10.1002/ajpa.22532
- [14] Nikolova S, Toneva D, Georgiev I. A persistent metopic suture – Incidence and influence on the frontal sinus development (preliminary data). *Acta Morphologica et Anthropologica*. 2016a;**23**:83-90
- [15] Castriota-Scanderbeg A, Dallapiccola B. *Abnormal Skeletal Phenotypes: From Simple Signs to Complex Diagnoses*. Berlin Heidelberg: Springer Verlag; 2005
- [16] Nikolova S, Toneva D, Yordanov Y, Lazarov N. Multiple Wormian bones and their relation with definite pathological conditions in a case of an adult cranium. *Anthropologischer Anzeiger*. 2014;**71**:169-190. DOI: 10.1127/0003-5548/2014/0355

- [17] Palav S, Vernekar J, Pereira S, Desai A. Hajdu-Cheney syndrome: A case report with review of literature. *Journal of Radiology Case Reports*. 2014;**8**:1-8. DOI: 10.3941/jrcr.v8i9.1833
- [18] Moss ML, Young RW. A functional approach to craniology. *American Journal of Physical Anthropology*. 1960;**18**:281-292. DOI: 10.1002/ajpa.1330180406
- [19] van Schayck R, Niedeggen A. Pneumosinus dilatans after prolonged cerebrospinal fluid shunting in young adults with cerebral hemiatrophy. A report of two cases and review of the literature. *Neurosurgical Review*. 1992;**15**:217-223. DOI: 10.1007/BF00345938
- [20] Washburn SL. The relation of the temporal muscle to the form of the skull. *The Anatomical Record*. 1947;**99**:239-248. DOI: 10.1002/ar.1090990303
- [21] Turner AL. *The Accessory Sinuses of the Nose*. New York: Longmans, Green & Co; 1901
- [22] Yanagisawa E, Smith HM. Radiographic anatomy of the Paranasal sinuses IV. Caldwell view. *Archives of Otolaryngology*. 1968;**87**:311-322. DOI: 10.1001/archotol.1968.00760060313016
- [23] Donald PJ, Gluckmann JL, Rice DH. *The Sinuses*. New York: Raven Press; 1994
- [24] Scheuer L, Black S. *Developmental juvenile osteology*. San Diego: Academic Press; 2000
- [25] Takahashi R. The formation of the human Paranasal sinuses. *Acta Oto-Laryngologica*. 1984;**97**(408):1-28
- [26] Kondrat JW. *Frontal Sinus Morphology: An analysis of craniometric and environmental variables on the morphology of modern human frontal sinus patterns [Thesis]*. Dekalb (IL): Northern Illinois University; 1995
- [27] Samuel E, Lloyd GAS. *Clinical Radiology of the Ear, Nose and Throat*. 2nd ed. London: Lieut.-Col; 1978
- [28] Hanson CL, Owsley DW. Frontal sinus size in Eskimo populations. *American Journal of Physical Anthropology*. 1980;**53**:251-255. DOI: 10.1002/ajpa.1330530209
- [29] Tatlisumak E, Ovali GY, Asirdizer M, Aslan A, Ozyurt B, Bayindir P, Tarhan S. CT study on morphometry of frontal sinus. *Clinical Anatomy*. 2008;**21**:287-293. DOI: 10.1002/ca.20617
- [30] Christensen AM. *An empirical examination of frontal sinus outline variability using elliptic Fourier analysis: Implications for identification, standardization, and legal admissibility [Thesis]*. University of Tennessee: Knoxville; 2003
- [31] Koertvelyessy T. Relationships between the frontal sinus and climatic conditions: A skeletal approach to cold adaptation. *American Journal of Physical Anthropology*. 1972;**37**:161-172. DOI: 10.1002/ajpa.1330370202
- [32] Schuller A. A note on the identification of skull X-ray pictures of the frontal sinus. *The Medical Journal of Australia*. 1943;**25**:554-556
- [33] Arnaud E, Reniet D, Marchac D. Development of the frontal sinus and glabellar morphology after frontocranial remodelling for craniosynostosis in infancy. *Journal of Cranio-Maxillo-Facial Surgery*. 1994;**5**:81-92. DOI: 10.1097/00001665-199405000-00006

- [34] Kim GR. A morphological study of the paranasal sinuses in Koreans. *Yonsei Medical Journal*. 1962;**3**:11-17
- [35] Aydinlioğlu A, Kavakli A, Erdem S. Absence of frontal sinus in Turkish individuals. *Yonsei Medical Journal*. 2003;**4**:215-218. DOI: 10.3349/ymj.2003.44.2.215
- [36] Çakur B, Sumbullu MA, Durna MB. Aplasia and agenesis of the frontal sinus in Turkish individuals: A retrospective study using dental volumetric tomography. *International Journal of Medical Sciences*. 2011;**8**:278-282. DOI: 10.7150/ijms.8.278
- [37] Soman BA, Sujatha GP, Lingappa A. Morphometric evaluation of the frontal sinus in relation to age and gender in subjects residing in Davangere, Karnataka. *Journal of Forensic Dental Sciences*. 2016;**8**:57. DOI: 10.4103/0975-1475.176945
- [38] Danesh-Sani SA, Bavandi R, Esmaili M. Frontal sinus agenesis using computed tomography. *The Journal of Craniofacial Surgery*. 2011;**22**:e48-e51. DOI: 10.1097/SCS.0b013e318231e26c
- [39] Moideen SP, Khizer Hussain Afroze M, Mohan M, Regina M, Sheriff RM, Moideen CP. Incidence of frontal sinus aplasia in Indian population. *International Journal of Otolaryngology and Head & Neck Surgery*. 2017;**3**:108-111. DOI: 10.18203/issn.2454-5929.ijohns20164811
- [40] Hodgson G. In: *A Text-Book of x-Ray Diagnosis*. 3rd ed. Vol. 1. London: H.K. Lewis; 1939
- [41] Ozgursoy OB, Comert A, Yorulmaz I, Tekdemir I, Elhan A, Kucuk B. Hidden unilateral agenesis of the frontal sinus: Human cadaver study of a potential surgical pitfall. *American Journal of Otolaryngology*. 2010;**31**:231-234. DOI: 10.1016/j.amjoto.2009.02.010
- [42] Urken ML, Som PM, Edelstein D, Lawson W, Weber AL, Biller HF. Abnormally large frontal sinus. II. Nomenclature, pathology, and symptoms. *The Laryngoscope*. 1987;**97**:606-611. DOI: 10.1288/00005537-198705000-00014
- [43] Canalis E, Zanotti S. Hajdu-Cheney syndrome: A review. *Orphanet Journal of Rare Diseases*. 2014;**9**:200. DOI: 10.1186/s13023-014-0200-y
- [44] Eggesbø HB, Søvik S, Dølvik S, Eiklid K, Kolmannskog F. CT characterization of developmental variations of the paranasal sinuses in cystic fibrosis. *Acta Radiologica*. 2001;**42**:482-493. DOI: 10.1080/028418501127347214
- [45] Yoshino M, Miyasaka S, Sato H, Seta S. Classification system of frontal sinus patterns by radiography. Its application to identification of unknown skeletal remains. *Forensic Science International*. 1987;**34**:289-299. DOI: 10.1016/0379-0738(87)90041-7
- [46] Christensen AM. Assessing the variation in individual frontal sinus outlines. *American Journal of Physical Anthropology*. 2005;**127**:291-296. DOI: 10.1002/ajpa.20116
- [47] Uthman AT, Al-Rawi NH, Al-Naaimi AS, Tawfeeq AS, Suhail EH. Evaluation of frontal sinus and skull measurements using spiral CT scanning: An aid in unknown person identification. *Forensic Science International*. 2010;**197**:124.e1-124.e7. DOI: 10.1016/j.forsciint.2009

- [48] Quatrehomme G, Fronty P, Sapanet M, Grévin G, Bailet P, Ollier A. Identification by frontal sinus pattern in forensic anthropology. *Forensic Science International*. 1996;**83**:147-153. DOI: 10.1016/S0379-0738(96)02033-6
- [49] Ruder TD, Brun C, Christensen AM, Thali MJ, Gascho D, Schweitzer W, Hatch GM. Comparative radiologic identification with CT images of paranasal sinuses – Development of a standardized approach. *Journal of Forensic Radiology and Imaging*. 2016;**7**:1-9. DOI: 10.1016/j.jofri.2016.09.001
- [50] Cossellu G, De Luca S, Biagi R, Farronato G, et al. Reliability of frontal sinus by cone beam-computed tomography (CBCT) for individual identification. *La Radiologia Medica*. 2015;**120**:1130-1136. DOI: 10.1007/s11547-015-0552-y
- [51] Soares CB, Almeida MS, Lopes Pde M, Beltrão RV, Pontual Ados A, Ramos-Perez FM, Figueroa JN, Pontual ML. Human identification study by means of frontal sinus imaginological aspects. *Forensic Science International*. 2016;**262**:183-189. DOI: 10.1016/j.forsciint.2016.03.030
- [52] Brun CN, Christensen AM, Kravarski M, Gorincour G, Schweitzer W, Thali MJ, Gascho D, Hatch GM, Ruder TD. Comparative radiologic identification with standardized single CT images of the paranasal sinuses-evaluation of inter-rater reliability. *Forensic Science International*. 2017;**280**:81-86. DOI: 10.1016/j.forsciint.2017.08.029
- [53] Belaldavar C, Kotrashetti VS, Hallikerimath SR, Kale AD. Assessment of frontal sinus dimensions to determine sexual dimorphism among Indian adults. *Journal of Forensic Dental Sciences*. 2014;**6**:25-30. DOI: 10.4103/0975-1475.127766
- [54] Tubbs RS, Elton S, Salter G, Blount JP, Grabb PA, Oakes WJ. Superficial surgical landmarks for the frontal sinus. *Journal of Neurosurgery*. 2002;**96**:320-322. DOI: 10.3171/jns.2002.96.2.0320
- [55] Amusa YB, Eziyi JAE, Akinlade O, Famurewa OC, Adewole SA, Nwoha PU, Ameye SA. Volumetric measurements and anatomical variants of paranasal sinuses of Africans (Nigerians) using dry crania. *International Journal of Medicine and Medical Sciences*. 2011;**3**:299-303
- [56] Natsis K, Karabatakis V, Tsikaras P, Chatzibalis T, Stangos N. Frontal sinus anatomical variations with potential consequences for the orbit. Study on cadavers. *Morphologie*. 2004;**88**:35-38. DOI: 10.1016/S1286-0115(04)97997-0
- [57] Pobornikova S. An x-ray investigation of the development of the frontal sinuses in children. *Folia Medica (Plovdiv)*. 1974;**16**:213-220
- [58] Nikolova S, Toneva D, Georgiev I, Dandov A, Lazarov N. Morphometric analysis of the frontal sinus: Application of industrial digital radiography and virtual endocast. *JOFRI*. 2018;**12**:31-39. DOI: 10.1016/j.jofri.2018.02.001
- [59] Nikolova S, Toneva D, Georgiev I, Yordanov Y, Lazarov N. Two cases of large bregmatic bone along with a persistent metopic suture from necropolises on the northern Black Sea coast of Bulgaria. *Anthropological Science*. 2016;**124**:145-153. DOI: 10.1537/ase.160530

- [60] Nikolova S, Toneva D, Georgiev I, Harizanov S, Zlatareva D, Hadjidekov V, Lazarov N. A CT-study of the cranial suture morphology and its reorganization during the obliteration. *Collegium Antropologicum*. 2017;**41**:125-131
- [61] Manzanares MC, Goret-Nicaise M, Dhem A. Metopic sutural closure in the human skull. *Journal of Anatomy*. 1988;**161**:203-215
- [62] Faro C, Benoit B, Wegrzyn P, Chaoui R, Nicolaidis KH. Three-dimensional sonographic description of the fetal frontal bones and metopic suture. *Ultrasound in Obstetrics & Gynecology*. 2005;**26**:618-621. DOI: 10.1002/uog.1997
- [63] Moss ML. Experimental alteration of sutural area morphology. *Anatomical Record*. 1957;**127**:569-589. DOI: 10.1002/ar.1091270307
- [64] Hinton DR, Becker LE, Muakkassa KF, Hoffman HJ. Lambdoid synostosis. I. The lamboid suture: Normal development and pathology of 'synostosis'. *Journal of Neurosurgery*. 1984;**61**:333-339. DOI: 10.3171/jns.1984.61.2.0333
- [65] Moss ML. Fusion of the frontal suture in the rat. *The American Journal of Anatomy*. 1958;**102**:141-165. DOI: 10.1002/aja.1001020107
- [66] Vu HL, Panchal J, Parker EE, et al. The timing of physiologic closure of the metopic suture: A review of 159 patients using reconstructed 3D CT scans of the craniofacial region. *The Journal of Craniofacial Surgery*. 2001;**12**:527-532
- [67] Weinzweig J, Kirschner RE, Farley A, Reiss P, Hunter J, Whitaker LA, Bartlett SP. Metopic synostosis: Defining the temporal sequence of normal suture fusion and differentiating it from synostosis on the basis of computed tomography images. *Plastic and Reconstructive Surgery*. 2003;**112**:1211-1218. DOI: 10.1097/01.PRS.0000080729.28749.A3
- [68] Bajwa M, Srinivasan D, Nishikawa H, Rodrigues D, Solanki G, White N. Normal fusion of the metopic suture. *The Journal of Craniofacial Surgery*. 2013;**24**:1201-1205. DOI: 10.1097/SCS.0b013e31829975c6
- [69] Skrzat J, Walocha J, Zawiliński J. A note on the morphology of the metopic suture in the human skull. *Folia Morphologica*. 2004;**63**:481-484
- [70] Van der Meulen J. Metopic synostosis. *Child's Nervous System*. 2012;**28**:1359-1367. DOI: 10.1007/s00381-012-1803-z
- [71] Moss ML. Premature synostosis of the frontal suture in the cleft palate patient. *Plastic and Reconstructive Surgery*. 1957;**20**:199-205
- [72] Riemenschneider PA. Trigonocephaly. *Radiology*. 1957;**68**:863-865. DOI: 10.1148/68.6.863
- [73] Bryce TH. Osteology and arthrology. In: Schäfer EA, Symington J, Bryce TH, editors. *Quain's Elements of Anatomy*. 11th ed. Vol. IV, Part I;1915. London: Longmans-Green. p. 177
- [74] Keith A. *Human Embryology and Morphology*. 6th ed. London: Edward Arnold; 1948
- [75] Woo J-K. Racial and sexual differences in the frontal curvature and its relation to metopism. *American Journal of Physical Anthropology*. 1949;**7**:215-226. DOI: 10.1002/ajpa.1330070205

- [76] Breathnach AS. Frazer'S Anatomy of the Human Skeleton. 5th ed. London: J. & A. Churchill; 1958
- [77] Romanes GJ, editor. Cunningham'S Textbook of Anatomy. 11th ed. London: Oxford University Press; 1972
- [78] Berry AC. Factors affecting the incidence of non-metrical skeletal variants. *Journal of Anatomy*. 1975;**120**:519-535
- [79] Nikolova S, Toneva D. Frequency of metopic suture in male and female medieval cranial series. *Acta Morphologica et Anthropologica*. 2012;**19**:250-252
- [80] Nikolova S, Toneva D, Georgiev I. A case of skeletal dysplasia in bone remains from a contemporary male individual. *Acta Morphologica et Anthropologica*. 2015;**22**:97-107
- [81] Ashley-Montagu MF. The Medio-frontal suture and the problem of Metopism in the primates. *The Journal of the Royal Anthropological Institute of Great Britain and Ireland*. 1937;**67**:157-201
- [82] Del Sol M, Binvignat O, PDA B, Prates JC. Metopismo no individuo brasileiro. *Revista Paulista de Medicina*. 1989;**107**:105-107
- [83] Bryce TH. Observations on Metopism. *Journal of Anatomy*. 1917;**51**:153-166
- [84] Limson M. Metopism as found in Filipino skulls. *American Journal of Physical Anthropology*. 1924;**7**:317-324. DOI: 10.1002/ajpa.1330070319
- [85] Schultz AH. The metopic Fontanelle, fissure, and suture. *Developmental Dynamics*. 1929;**44**:475-499. DOI: 10.1002/aja.1000440306
- [86] Nikolova S, Toneva D, Georgiev I. Cranial Base angulation in metopic and non-metopic cranial series. *Acta Morphologica et Anthropologica*. 2017b;**24**:45-49
- [87] McCarthy JG, Karp NS, LaTrenta GS, Thorne CH. The effect of early fronto-orbital advancement on frontal sinus development and forehead aesthetics. *Plastic and Reconstructive Surgery*. 1990;**86**:1078-1084
- [88] Locher MC, Sailer HF, Haers PE, Carls FR, Oechslin CK, Grätz KW. Development of frontal sinus following bilateral fronto-orbital osteotomies. *Journal of Cranio-Maxillofacial Surgery*. 1998;**26**:129-135
- [89] Auque J, Bracard S, Roland J, Sakka M. Effects of intracranial pressure on frontal sinus development. *Bulletin de l'Association des Anatomistes*. 1987;**71**:31-35
- [90] Du Boulay GH. *Principles of X-Ray Diagnosis of the Skull*. London: Butterworths; 1980
- [91] Fenichel GM. Increased intracranial pressure. In: *Clinical Pediatric Neurology: A Signs and Symptoms Approach*. Expert Consult. 6th ed. Philadelphia: Elsevier/Saunders; 2009
- [92] Luo C, Chen J, Liao Q, Li Q, Yang X, Li Y. Influence of iron deficiency anemia on development of thymus and spleen and adenosine deaminase activity in rats. *Hua Xi Yi Ke Da Xue Xue Bao*. 1990;**21**:63-66

- [93] Kulaksizoglu M, Ipekci SH, Gonulalan G, Ozturk M, Kaya A, Gonen MS, Cakir M: Do we need to replace GH to correct anemia in hypopituitarism? In: Proceedings of the Endocrine Society's 96th Annual Meeting and Expo; 21-24 June 2014; Chicago; SAT-0729
- [94] Katsumata S, Katsumata-Tsuboi R, Uehara M, Suzuki K. Severe iron deficiency decreases both bone formation and bone resorption in rats. *The Journal of Nutrition*. 2009;**139**:238-243. DOI: 10.3945/jn.108.093757
- [95] Reimann FV, Gedikoglu G, Talasli U. Metopism in iron deficiency disease: A roentgenological investigation. *Fortschr Roentgenstr*. 1978;**129**:246-249. DOI: 10.1055/s-0029-1231005
- [96] Reimann FV, Cedikoglu C, Celik E, Ulukurİu L, Kilicözlu I. Deformity of the skull vault due to hypertrophy of red marrow in cases of anaemia. *RoFo: Fortschritte auf dem Gebiete der Röntgenstrahlen und der Nuklearmedizin*. 1981;**135**:20-24. DOI: 10.1055/s-2008-1056822
- [97] Capriles FL. Intracranial hypertension and iron-deficiency anemia. *Archives of Neurology*. 1963;**9**:57-63. DOI: 10.1001/archneur.1963.00460080057008
- [98] Mollan SP, Ball AK, Sinclair AJ, Madill SA, Clarke CE, Jacks AS, Burdon MA, Matthews TD. Idiopathic intracranial hypertension associated with iron deficiency anaemia: A lesson for management. *European Neurology*. 2009;**62**(2):105-108. DOI: 10.1159/000222781
- [99] Rivollat M, Castex D, Hauret L, Tillier A. Ancient Down syndrome: An osteological case from saint-Jean-des-Vignes, northeastern France, from the 5-6th century AD. *International Journal of Paleopathology*. 2014;**7**:8-14. DOI: 10.1016/j.ijpp.2014.05.004
- [100] Larocca LM, Lauriola L, Ranelletti FO, Piantelli M, Maggiano N, Ricci R, Capelli A. Morphological and immunohistochemical study of Down syndrome thymus. *American Journal of Medical Genetics. Supplement*. 1990;**7**:225-230. DOI: 10.1002/ajmg.1320370745
- [101] Murdoch JC, Gray CA, McLarty DG, Ratcliffe JG. Pituitary function in Down's syndrome. *Journal of Mental Deficiency Research*. 1978;**22**:273-275. DOI: 10.1111/j.1365-2788.1978.tb00985.x
- [102] Castells S, Beaulieu I, Torrado C, Wisniewski KE, Zarny S, Gelato MC. Hypothalamic versus pituitary dysfunction in Down's syndrome as cause of growth retardation. *Journal of Intellectual Disability Research*. 1996;**40**:509-517. DOI: 10.1046/j.1365-2788.1996.802802.x
- [103] Tenenbaum A, Malkiel S, Wexler ID, Levy-Khademi F, Revel-Vilk S, Stepensky P. Anemia in children with Down syndrome. *International Journal of Pediatrics*. 2011;**5**. DOI: 10.1155/2011/813541
- [104] Zivanovic S. *Ancient Diseases: The Elements of Paleopathology*. New York: Pica Press; 1982

