

# We are IntechOpen, the world's leading publisher of Open Access books Built by scientists, for scientists

4,800

Open access books available

122,000

International authors and editors

135M

Downloads

Our authors are among the

154

Countries delivered to

TOP 1%

most cited scientists

12.2%

Contributors from top 500 universities



WEB OF SCIENCE™

Selection of our books indexed in the Book Citation Index  
in Web of Science™ Core Collection (BKCI)

Interested in publishing with us?  
Contact [book.department@intechopen.com](mailto:book.department@intechopen.com)

Numbers displayed above are based on latest data collected.  
For more information visit [www.intechopen.com](http://www.intechopen.com)



---

# Resuscitation Procedures in Emergency Setting

---

Aml Yousif Elemamali and Aftab Mohammad Azad

Additional information is available at the end of the chapter

<http://dx.doi.org/10.5772/intechopen.76165>

---

## Abstract

The physicians of the emergency department have great mission as they have to manage these critically ill patients and stabilize them by effectively using their own skills in order to improve their patients' condition. It is very important to understand when a procedure is needed in emergency situation and to make all efforts to achieve that goal in a timely and safe manner and to follow the protocols and guidelines. There are some procedures which are lifesaving and imminent to resuscitation and considered adjuncts to resuscitation. Effective and lifesaving resuscitation cannot be completed without these procedures. This chapter will help the emergency physician (EP) to better understand and develop the required technical skills to achieve the highest level of care that will have direct impact on patients' outcome.

**Keywords:** resuscitation, procedures, emergency medicine

---

## 1. Introduction

The emergency department (ED) is one of the basics of any hospital, as this department is considered the gate of the hospital and its front line. Above one third of patients who present to ED are very critically ill and need urgent care and intervention [1]. The physicians of the emergency department have great mission as they have to manage these critically ill patients and stabilize them by effectively using their own skills in order to improve their patients' condition. It is very important to understand when a procedure is needed in emergency situation and to make all efforts to achieve that goal in a timely and safe manner and to follow the protocols and guidelines. There are some procedures which are lifesaving and imminent to resuscitation and considered adjuncts to resuscitation. Effective and lifesaving resuscitation cannot be completed without these procedures. This chapter will help the emergency

physician (EP) to better understand and develop the required technical skills to achieve the highest level of care that will have direct impact on patients' outcome.

The chapter will cover the following resuscitative procedures of emergency:

- Airway management
- Rapid sequence intubation
- Needle decompression
- Tube thoracostomy
- Central venous catheter placement
- Intraosseous line placement
- Pericardiocentesis
- ED thoracotomy
- Defibrillator
- Transcutaneous pacing

## **2. Airway management**

### **2.1. Introduction**

Emergency airway management is considered one of the most difficult fields of the emergency care. In order for physicians to provide proficient and effective care, they must be trained to a competent and highly efficient level of proficiency in maintaining, assessing, and managing airways using both basic airway maneuvers and advanced skills such as rapid sequence intubation (RSI). The physician's decision-making process is the core principle of highly safe and effective airway management. The decision made by the physicians should ensure the accomplishment of airway security and improvement of ventilation and oxygenation while ensuring there are none or minimal iatrogenic errors or defaults [1].

### **2.2. Basic airway management**

The most initial part of airway management in sick patient is to assess for airway adequacy and patency and risk for compromise and take a decision for further intervention. Delivering oxygen to the lungs and ensuring a clear airway are the key principles of airway management. For this to be done, physicians must ensure the airway is guarded from foreign objects such as blood and fluids. Once breathing discontinues the body's oxygen supplies dramatically and rapidly decrease; time is the most critical part of this process of airway management which takes us back to the extreme importance of accurate decision-making when assessing adequacy of airway alongside any risks of compromise. Blood, vomit, and other foreign

bodies are the main cause of the blockade to the airways; however airway injury or swelling can also be a cause. These obstructions can be treated by many lifesaving interventions such as airway maneuvers, positioning, and correct ventilations [2–5].

### **2.3. Airway anatomy**

A complete understanding and knowledge of anatomy is important for performing any procedure. Adverse events in any procedure usually happen either due to lack of understanding of the regional anatomy or as a result of inexperience. Performing an airway procedure with a thorough understanding of airway anatomy is not exceptional. Starting by assessing the airway looking for external anatomical landmarks till the completion of intubation, an understanding of the anatomy of the airway will lead to increased success rate and reduced attempts rate and iatrogenic errors. The upper airway includes the oral and nasal cavities, the pharynx, and the larynx. The lower airway comprises the subglottic larynx, the trachea, and the bronchi. It is a complicated system that transmits filtered warm air to the lungs through the trachea and at the same time permits passage of solids and liquids to the esophagus. However, if a food particle or liquid enters the airway, a complete system of reflexes will be activated to protect its integrity [3, 4]. **Figure1** shows the anatomy of the larynx, trachea, and pharynx (graphic jump location).

### **2.4. Basic airway management techniques**

Basic airway management is the base for advanced airway skills. Although it is easy, it can be both tricky and lifesaving. In majority of patients, a combination of patient positioning, different airway maneuvers, use of airway adjuncts, and assisted ventilation will help maintain oxygenation and can be lifesaving [3].

### **2.5. Positioning**

The sniffing position is the preferable way to open the upper airway and it is achieved by flexion of the lower cervical spine and atlanto-occipital extension. It can be accomplished by putting a pillow or folded towel under the patient's head, and the physician then extends the head on the neck to align the three airway axes oral, pharyngeal, and laryngeal axes [2, 3, 6]. If cervical spine injury is suspected, maintain the neck in a neutral position. In obese patients the sniffing position can be achieved by putting a pillow under the shoulders and another pillow under the head to raise it further. Raising the head end of the trolley or bed also improves preoxygenation in obese patients by reducing the pressure of the abdominal contents on the diaphragm, thereby increasing the functional residual capacity [2].

### **2.6. Head-tilt and chin-lift maneuver**

After patient positioning, there are other movements that improve the airway more. Head tilt and chin lift one of them, to perform it, place the tips of index and middle fingers under the patient's chin and pull the mandible forward to elevate the tongue and open the airway. The thumb then can be used to open patient's mouth by depressing the lower lip.

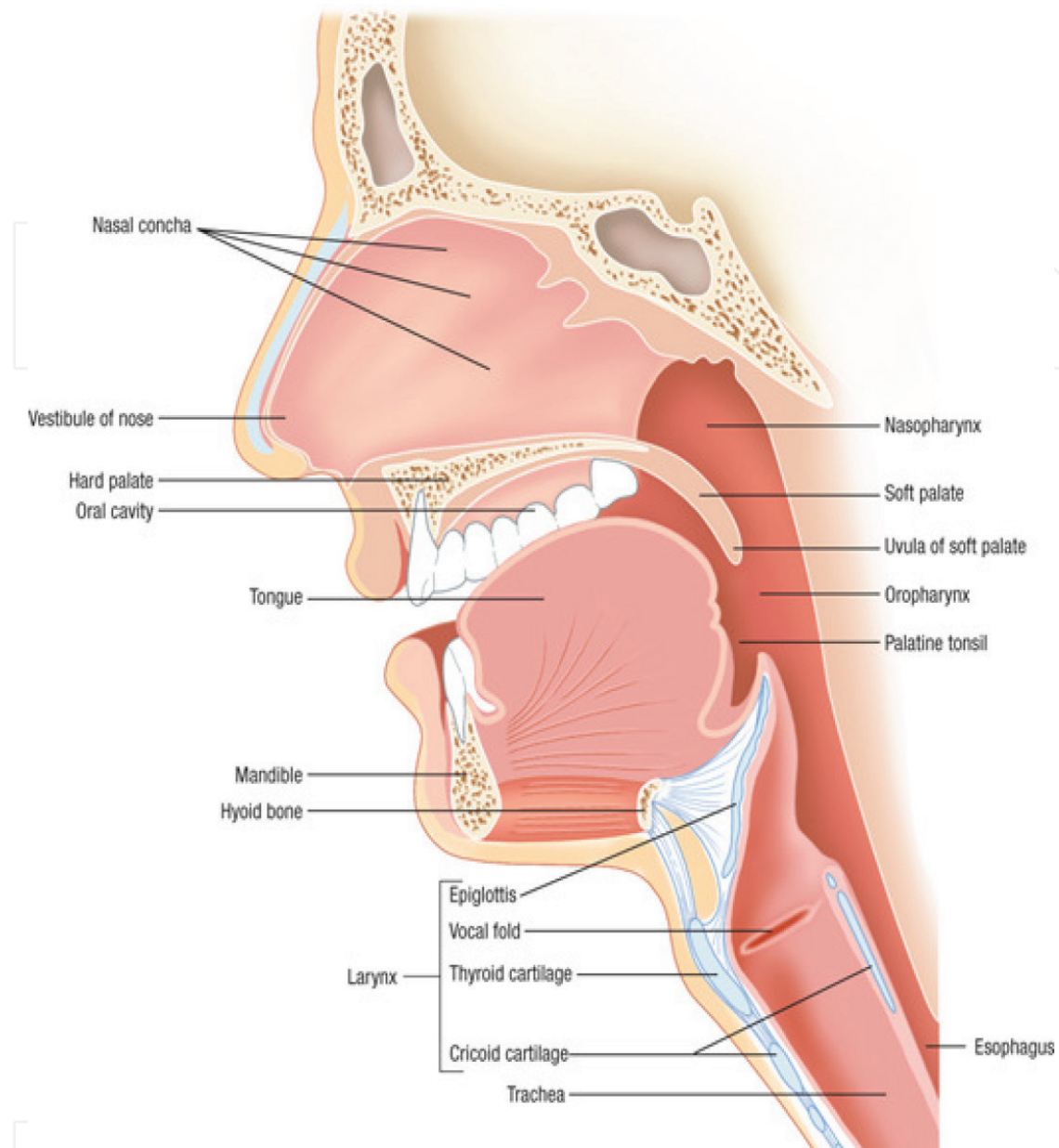


Figure 1. Airway anatomy.

### 2.7. The jaw-thrust maneuver

It is the favorite method for patients with possible cervical spine injury. To perform it, the tips of the middle or index fingers should be placed behind the angle of the mandible. Then lift the mandible upward to bring the lower incisors anterior to the upper incisors. Jaw thrust can be used together with the head tilt and chin lift and it is called the triple airway maneuver. The best description of this maneuver is head tilt, jaw thrust, and mouth opening [4] (Figure 2).

### 2.8. Suction

Patient positioning and airway opening maneuvers are usually insufficient to completely open the airway. Continuous vomits and bleeding usually need suctioning. The sucker should be used

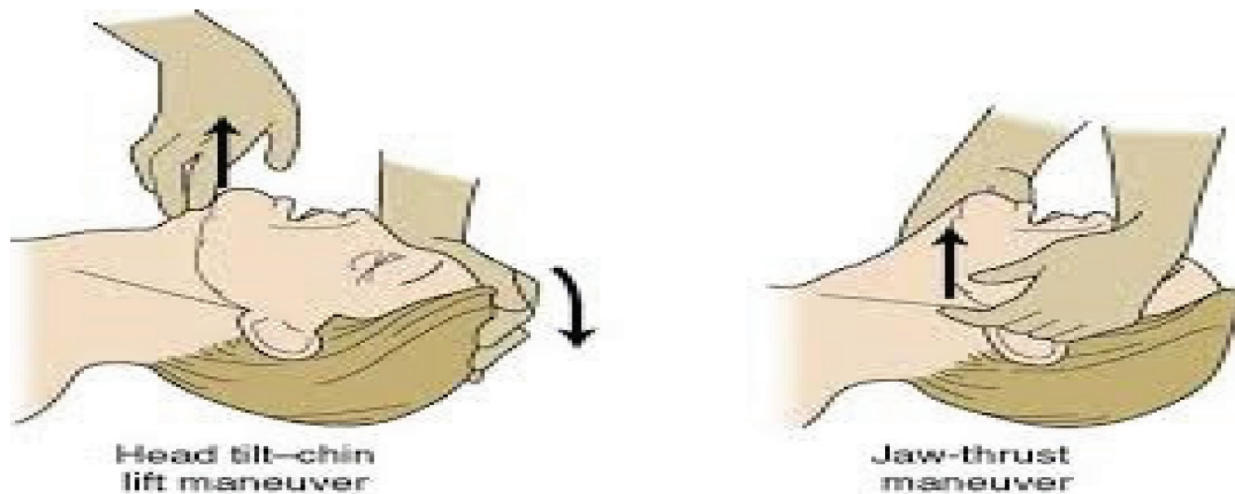


Figure 2. Head-tilt and jaw-thrust maneuver.

gently under direct vision. Using the sucker blindly might lead to airway injury, vagal stimulation, increased intracranial pressure, and vomiting. Intermediate negative pressure should be used to avoid blockage of the sucker. There are no contraindications to airway suctioning [3, 4, 6].

## 2.9. Airway adjuncts

### 2.9.1. Oropharyngeal airways

The oropharyngeal airways (OPA) are hard plastic devices with curved shape to lift the base of the tongue forward and prevent obstruction.

**Indications:** It is indicated for obstructed airway in an obtunded patient. Conscious patients will not tolerate an OPA.

**Size:** The device is sized by measuring its length from the patient's incisors to the angle of the jaw.

**Technique:** It is inserted inverted into the mouth after it passed the hard palate; the airway is rotated 180 degrees and advanced over the tongue. Another way is to use a tongue depressor to depress the tongue and advance the airway directly with no rotation needed.

**Complications:** May induce vomiting in patients with intact gag reflex, laryngospasm, raised intracranial pressure, and risk of aspiration in patients who have some airway reflexes.

**Limitations:** As a rule, any patient who tolerates an OPA airway should have a definitive airway. OPA is not a definitive airway. It helps with oxygenation and keep the airway open, but does not protect it.

### 2.9.2. Nasopharyngeal airways (NPA)

Are soft rubber tubes with a bevel at one end and a flange on the other end.

**Indications:** NPA is indicated when OPA cannot be used. It can be used to open the airway of conscious or semiconscious patients with intact airway reflexes who cannot tolerate OPA.



**Size:** The size can be estimated by measuring from the tip of the nose to the tip of the earlobe. An appropriate size of the NPA in adults is 6 mm internal diameter of an average female and 7 mm internal diameter for an average male [2, 3].

**Technique:** It is very simple. The airway should be lubricated first and then inserted gently into the nostril that looks wider and advanced it posteriorly with slight rotational movement. To improve the airflow, another airway can be inserted into the other side.

**Complications:** It may cause hemorrhage, nasal trauma, and laryngospasm and vomiting in a conscious patient with sensitive oropharynx [6].

**Limitations:** It is contraindicated to use NPA when there is a basal skull fracture or cribriform plate injury. These injuries might lead to intracranial placement of the airway. It is usually rare, and when there is life-threatening hypoxemia and where insertion of an OPA is not possible, careful insertion of NPA may be lifesaving [2].

The effectiveness of any airway maneuver or adjunct must always be assessed after it has been completed.

The oropharyngeal airway (OPA) and nasopharyngeal airway (NPA) are basic airway adjuncts. They are used to secure and open the airway, once it has been opened by either a head-tilt, chin-lift, or jaw-thrust maneuver and any objects or secretions have been removed by suctioning (**Figure 3**).

## 2.10. Oxygenation

The guidelines recommend that for most acutely ill patients, oxygen should be given to achieve a target saturation of 94–98% or 88–92% of those at risk of hypercapnic respiratory failure. Give all critically ill patients high flow oxygen 15 L/min until they are stable, and then reduce it to achieve the target saturation. These targets can be achieved by the use of nasal cannula, face mask with reservoir, or noninvasive ventilation (NIV) together with airway maneuver and adjuncts [2].



**Figure 3.** A-oropharyngeal airway, B- nasopharyngeal airway.

### **3. Rapid sequence induction**

Rapid sequence induction (RSI) is a guided protocol of steps to reduce complications and boost success. The protocol of RSI entails the administration of anesthetic induction drug, followed by muscle-relaxing drugs (neuromuscular blockade drug) to achieve complete paralysis.

RSI is the preferred method to secure an airway on an emergent basis and where there is a risk of aspiration of gastric contents. In experienced hands, it is a relatively safe procedure with few complications. The choice of pharmacologic agents used will vary by physician experience, physician preference, the clinical condition of the patient, and the pharmacology of the agents [4].

#### **3.1. Indication for intubation**

There are four clinical situations in which intubation may be indicated:

1. Apneic patient.
2. Patient with an obstructed/partially obstructed airway where basic airway care is ineffective.
3. The patient requires invasive respiratory support for oxygenation or ventilatory failure.
4. Patient in whom basic airway care is effective, but whose predicted clinical course includes a high probability of airway obstruction, aspiration, or ventilatory failure[2].

#### **3.2. Contraindications**

RSI has just few contraindications. Firstly, inexperienced intubator should not perform RSI. Secondly, when the physician is not sure of his capability to intubate a patient with difficult airway, then he has to perform awake intubation. There are also other contraindications to RSI such as the contraindications of the muscle relaxants and absence of required equipment.

#### **3.3. Preparation for RSI**

Once the decision for intubation is taken, preparation for RSI should be started. The first attempt is always the best chance, so all efforts to make it successful should be done this by a systematic approach, maximizing the preintubation physiologic parameters of the patient and good teamwork which will all increase the success rate for intubation.

#### **3.4. Assessment for difficult airway**

Before proceeding with preparations for RSI, assessment of patient for difficult airway should be done using the LEMON mnemonic which can be done easily on any critically ill patient; this is done by:



**L**-looking externally for any anatomic or external characteristics that predict difficult intubation, such as facial hair, obesity, short neck, prominent upper incisors, receding mandible, edentulous, facial trauma, and airway deformity.

**E**-evaluate the 3-3-2 rule to evaluate the airway and predict the poor visibility of the posterior pharynx.

Starting with mouth opening should be at least 4 cm which is around three fingerbreadths. If it is less than this, it predicts difficult intubation and difficult visualization on laryngoscopy.

Thyromental distance is from the top of the thyroid cartilage to the mentum with fully extended neck. It should be 3–4 fingerbreadths, and when it is less than 3, this predicts difficult view on laryngoscopy.

The final part of the 3-3-2 rule is two fingers from the floor of the mouth to the laryngeal prominence (Adam's apple).

**M**-Mallampati score is used to assess oral access for laryngoscopy by viewing patients tongue, uvula, faucial pillars, and posterior pharynx (**Figure 4**).

**O**-obesity or obstruction obesity in addition to certain infections or swelling involving the upper airways or tumors like patients with chemical or thermal burns, infections of the larynx and pharynx, epiglottitis and glottic polyps, laryngeal mass, angioedema, and neck hematoma all will affect laryngoscopy view.

**N**-neck mobility: any condition that limits neck mobility will impair the view on laryngoscopy, for example, patients with arthritis affecting cervical spine, e.g., ankylosing spondylitis, rheumatoid arthritis, and elderly [2, 7].

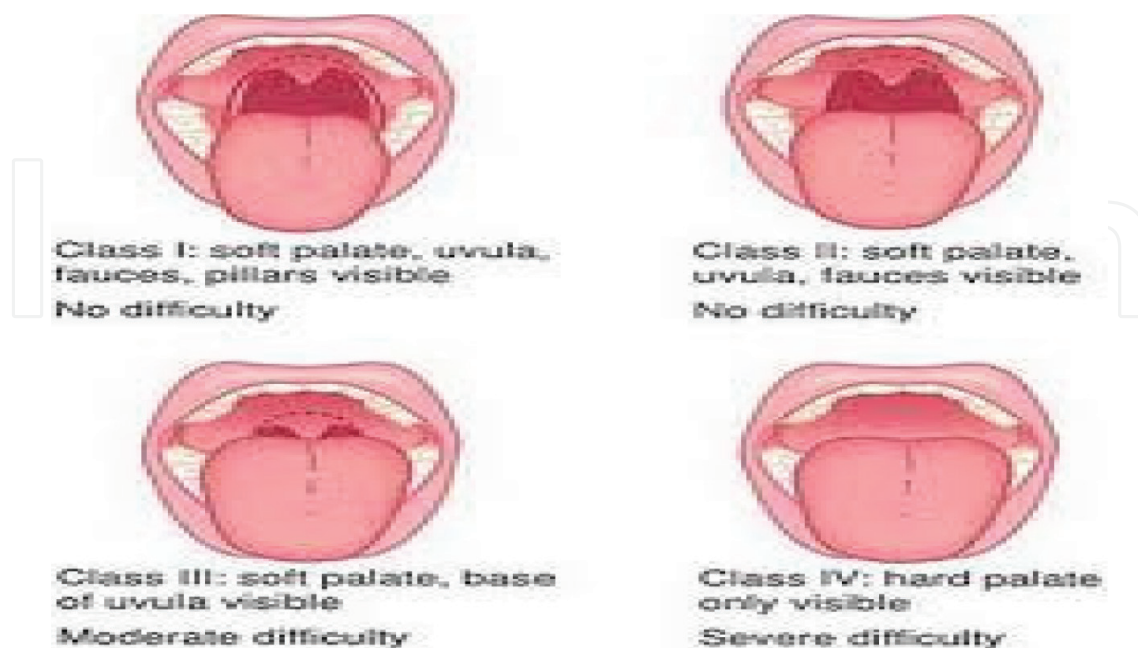


Figure 4. Mallampati score.

Once a difficult airway is predicted, EP should be prepared for it before proceeding with RSI by having other devices ready like video laryngoscopy, bougie tube, stylets, laryngeal mask airway (LMA), or a surgical airway kit, e.g., cricothyrotomy set, or awake intubation.

The most experienced EP should do the first trial and call for help early, predicting the difficulty [4, 5].

#### 3.4.1. *Equipment*

- Nonrebreather face masks (different sizes) and oxygen supply and connectors.
- Nasal cannula for oxygenation.
- Bag-valve-mask devices, different sizes.
- Laryngoscope blades and handle of different sizes with extra batteries.
- Endotracheal tubes (ETT), different sizes.
- Stylet and bougie tube.
- Oropharyngeal airways, different sizes.
- Nasopharyngeal airways, different sizes.
- Alternative airway devices.
- Yankauer suction catheter.
- Syringes, 10 and 20 ml.
- Medications drawn and labeled.
- End-tidal carbon dioxide (CO<sub>2</sub>) monitor/device.
- Crash cart.
- Resuscitation medications.
- Monitor pulse oximetry, ECG, and noninvasive blood pressure (NIBP).
- Failed intubation equipment or backup equipment should be prepared in case intubation failed. This can be a laryngeal mask airway (LMA), a cricothyroidotomy tray, and video laryngoscopy.

#### 3.4.2. *Technique*

There are three major qualities of RSI; these are preoxygenation, application of cricoid pressure, and the avoidance of positive pressure ventilation before securing the airway with endotracheal tube [4, 9]. Steps for performing RSI from start to finish:

The patient is preoxygenated with 100% O<sub>2</sub> using a nonrebreather mask or assisted ventilation using a bag-valve-mask device. This leads to enhance oxygen reserve and prevent hypoxemia during induction [2, 4, 8].

The routine practice is to preoxygenate the patient for 5 minutes. If it is not possible, then preoxygenate for 3 minutes. However, four maximal inspirations are equally effective in the cooperative patient [4, 8]. Administering oxygen using noninvasive positive pressure ventilation has the ability to improve the process of oxygenation much faster than by using the face mask.

All the equipment should be prepared before the intubation and should be checked. The laryngoscope handles and light should be checked if they are working or not. ETT cough should be checked for any air leaks. Connect the patient at the same time to a monitor including pulse oximetry, cardiac monitor, and NIBP. The nurse at the same time should prepare the required medication and label them and get an intravenous access. Record and observe patient physiologic parameters.

The patient should be positioned in the sniffing position if no cervical spine injury is suspected. If cervical spine injury is suspected, manual in-line immobilization should be maintained during the intubation.

Premedicate the patient as indicated by the condition. Lidocaine (1.0–1.5 mg/kg) or fentanyl (2–3 µg/kg) both can be given to blunt the intracranial pressure response, transient hypertension, bronchospasm, and tachycardia associated with intubation. Phenylephrine (50 µg) can be used to lessen the hypotensive effect of intubation. Administer an appropriate induction agent as indicated by the clinical setting and patient's hemodynamic status followed by a non-depolarizing agent, if no contraindication. Flush the intravenous line after each drug to ensure delivery [10].

A cricoid pressure (the Sellick maneuver) should be applied immediately and maintained till oral endotracheal intubation is completed.

Intubate the patient after administration of succinylcholine (or rocuronium) and the patient's muscles are relaxed. Confirm the correct placement of the ETT by visualizing the tube passing through the vocal cords, monitoring continuous end-tidal CO<sub>2</sub> wave on the capnography, and auscultating breath sounds at the midaxillary lines and epigastric area. Release cricoid pressure. After successful intubation, secure the tube and connect to a ventilator and adjust the sitting according to patient condition. Administer additional sedative hypnotics and analgesics as indicated by clinical scenario. Obtain a chest radiograph to confirm proper placement of the endotracheal tube [2, 4, 6, 7, 9, 10].

### 3.4.3. Complications of RSI

- Difficult or failed intubation
- Airway injury and dental trauma
- Hypoxia
- Tachycardia and bradycardia mainly in children
- Hypertension or hypotension
- Cerebral anoxia
- Myocardial ischemia
- Death

## 4. Needle decompression

Needle decompression is a lifesaving procedure used to decompress the chest when there is tension pneumothorax. Tension pneumothorax is the accumulation of air in the pleural cavity under pressure. Progressive buildup of pressure in the pleural space leads to mediastinum shift to the opposite side, lung collapse, and tracheal deviation to the unaffected side and obstructs venous return to the heart. This results in a hemodynamic instability and can lead to cardiac arrest [4, 11] (**Figure 5**).

### 4.1. Basic principle

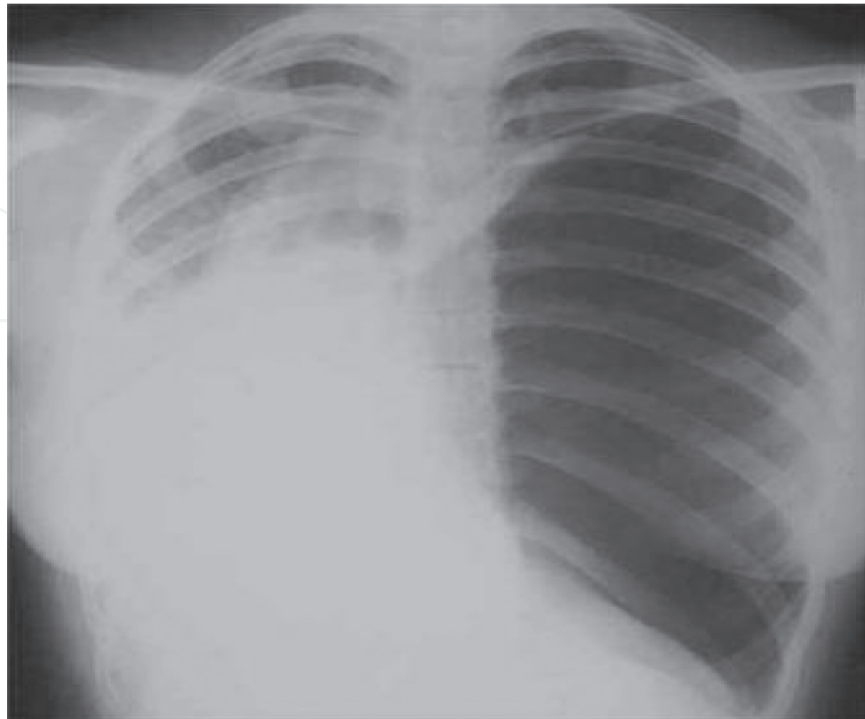
The main idea is to insert a catheter into the pleural space, thus creating a pathway for the air to escape and release the built-up pressure. It is an emergency procedure when there is tension pneumothorax and should be followed by the chest tube insertion as a definitive management [14].

Indication for emergent needle decompression.

Traumatic cardiac arrest with chest involvement

- Tension pneumothorax

That is evident clinically in patients with tachypnea, hypoxia, tachycardia, hypotension, tracheal deviation to the unaffected side, diminished breath sound, hyperresonance chest, and increased percussion note.



**Figure 5.** Radiograph of a patient with a large spontaneous tension pneumothorax.

Whenever there is deterioration in the patient's oxygenation or ventilatory status, the chest should be reexamined and tension pneumothorax should be excluded. Failure to suspect and pick it clinically will result in death.

#### 4.2. Contraindications

There is absolute contraindication for needle decompression, but in patients with polytrauma, if the injury is not salvageable, then it should be avoided [16].

#### 4.3. Equipment

- Povidone-iodine or chlorhexidine solution
- 12- to 16-gauge catheter-over-the-needle, 4.5 cm in length
- Syringe 5 or 10 ml
- Sterile gloves, gown, and face mask
- Ultrasound machine (optional) with sterile gel and probe

#### 4.4. Patient preparation

The procedure should be explained to the patient or family and he should be placed in supine position. 100% oxygen through the face mask should be administered if the patient not on mechanical ventilator. Also the patient should be connected to a monitor including cardiac monitor and pulse oximetry.

#### 4.5. Technique

The procedure should be done under aseptic technique. The EP should wear the gown, sterile gloves, mask, and cap. The anatomical landmark should be identified which is the second intercostal space at the midclavicular line on the affected side.

- Use iodine-based solution (Betadine) to clean the area that should be punctured.
- Insert a large-bore (i.e., 14 gauge or 16 gauge) needle with a catheter into the second intercostal space, perpendicular to the skin and above the superior border of the third rib at the midclavicular line, to prevent damage to the neurovascular bundle located at the second rib inferior border.

Then the catheter-over-the-needle should be advanced till reaching the pleural space. A rush of air will be heard escaping from the syringe. At this point the catheter should be advanced and the needle should be withdrawn at the same time. The catheter then should be secured in place and should be left open to air. The patient should be prepared for tube thoracostomy as needle decompression is a temporary procedure. Post insertion patient should be reevaluated and continued to be monitored, and chest X-ray should be requested. Successful placement of the catheter will be confirmed by the improvement of patient symptoms and hemodynamic status [11–14].



#### 4.6. Tips

Failure of the procedure can be due to a short needle, especially in obese patients with a thicker chest wall, so a longer needle should be used for a successful procedure [13]. Ultrasound-guided procedure can be an excellent option, and at the same time, it will confirm the presence of pneumothorax by the loss of lung's sliding movement or lung point sign which is more specific for pneumothorax. Ultrasound also can help choosing the appropriate needle length needed for the procedure.

#### 4.7. Complications

Needle thoracostomy is not a simple procedure with no complications, and it should be done when patient scenario and clinical assessment support the clinical diagnosis of tension pneumothorax [15, 16].

Complications include

- Pneumothorax (with potential to later tension pneumothorax)
- Hemothorax
- Cardiac tamponade
- Hemorrhage (which can be life-threatening)
- Loculated intrapleural hematoma
- Atelectasis and pneumonia
- Arterial air embolism (when needle thoracostomy is performed and no tension pneumothorax is present)
- Pain to the patient due to procedure itself
- Thoracic and abdominal organ injury
- Failure of the procedure or ineffective drainage of pneumothorax

#### 4.8. Chest Tube

Indications

- Hemothorax
- Abscess
- Empyema
- Traumatic pneumothorax (some)
- Spontaneous pneumothorax (some)
- Indication for main theater: >1200-ml drainage immediately after insertion or continuous 150–200 mL/hr. for 2–4 hours (**Table 1**)

#### 4.9. Relative indications

Penetrating thoracic injury and need for positive pressure ventilation.

Profound hypoxia/hypotension in patient with penetrating chest injury

- Profound hypoxia/hypotension and signs of hemothorax

#### 4.10. Contraindications

- No absolute contraindications when performed for emergent indication

##### 4.10.1. Relative contraindications

- Overlying skin infection
- Coagulopathy
- Multiple pleural adhesions

#### 4.11. Equipment needed

- Chest tube
  - 14–28F for pneumothorax
  - 32–40F for hemothorax
- Scalpel
- Kelly clamp
- Sterile drapes
- Silk sutures
- Syringes and needles for anesthesia
- Lidocaine
- Betadine
- Sterile gown/gloves
- Face shield
- Pleur-evac

#### Procedure

1. Consider antibiotic (e.g., cefazolin) dose 1–2 gm intravenously before procedure.
2. If possible, elevate head of the bed to 30–60 degrees to lower diaphragm-decreasing risk of injury to the diaphragm/intra-abdominal organs.

3. Expose insertion site by moving the upper extremity above the head on the affected side.
  - Insertion site = mid- to ant axillary line at fourth/fifth intercostal space.
    - ~Nipple line in men and inframammary crease in women.
    - Place 1–3 intercostal spaces higher in pregnant patients (especially those in the third trimester) due to elevated diaphragm.
4. Clean with Betadine and drape.
5. Confirm rib space and anesthetize with up to 5 mg/kg of lido with or without epinephrine.
  - Must anesthetize the skin, soft tissue, muscle, periosteum, and pleural space.
6. Incise along the upper border of the lower rib of the intercostal space.
7. Use curved clamp to bluntly dissect through the muscle until you reach the rib.
8. Angle the clamp to go above and over the rib and push until enter the pleural space.
9. Open the clamp and pull it out with the clamp still open to create a larger tract.
10. Premeasure chest tube from skin incision to ipsi clavicle to avoid advancing chest tube too far.
11. Clamp the proximal end of the chest tube and pass it along the tract into the pleural cavity.
  - Ensure that inner tract/incision can fit your finger and tube.
  - It helps to have your finger in the tract and pass the tube along your finger, particularly in obese patients.
12. Once in the space, remove the clamp.
13. Feed the chest tube until all the holes are inside the thoracic cavity.
  - Aim superoanterior for pneumothorax; aim posteriorly for hemothorax.
    - Controversial as to whether this is important.
14. Rotate the tube 360 degrees.
  - Reduces likelihood of tube kinking.
  - If tube rotates easily, it can help indicate correct location inside pleural cavity.
15. Attach distal end of tube to the Pleur-evac and place on suction (20–30cmH<sub>2</sub>O suction).
16. Secure tube with silk suture and cover with gauze and cloth tape.
17. Obtain CXR position of tube.

Chest tubesize	Type of patient	Underlying causes
Small (8–14 Fr)	<ul style="list-style-type: none"> <li>• Most spontaneous pneumothorax (primary and secondary)</li> <li>• Most iatrogenic pneumothorax</li> </ul>	<ul style="list-style-type: none"> <li>• Alveolar-pleural fistulae (small air leak)</li> <li>• Iatrogenic air</li> </ul>
Medium (20–28 Fr)	<ul style="list-style-type: none"> <li>• Pneumothorax on mechanical ventilation</li> <li>• Non-traumatic tension pneumothorax</li> <li>• Malignant effusion</li> </ul>	<ul style="list-style-type: none"> <li>• Bronchial-pleural fistulae (large air leak)</li> <li>• Malignant fluid</li> </ul>
Large (36–40 Fr)	<ul style="list-style-type: none"> <li>• Traumatic pneumothorax</li> <li>• Empyema</li> </ul>	<ul style="list-style-type: none"> <li>• Bleeding (hemothorax/hemopneumothorax)</li> <li>• Thick pus</li> </ul>

**Table 1.** Adult chest tubesizes.

#### 4.12. Drainage system and suction

- Spontaneous pneumothorax
  - The least amount of suction (including none) needed to maintain full expansion of the lung is appropriate.
  - Starting with Heimlich valve (no suction) or – 10 cm of water and increasing only as needed
- Fluid drainage
  - –20 cm of water
  - Increased as indicated with the goal of achieving full lung expansion
- For thoracic trauma, few data are available.
  - Start –20 cm of water

#### Complications

- Exsanguination (secondary to removing the tamponade effect of the hemothorax)
  - Clamp tube immediately; take patient to the OR for emergent thoracostomy.
- Air leak
  - Reason why you never clamp the tube once it is in place (could cause tension pneumothorax)
- Failure
- Infection

- Give prophylactic antibiotics (e.g., Ancef) to decrease rate of empyema.
- Re-expansion pulmonary edema
- Damage to nerves/vessels/heart/lung/diaphragm/abdomen
- Improper positioning of the tube
- Tension pneumothorax

#### Failure to drain

- Improper connections or leaks in the external tubing/water seal system
- Improper positioning of the tube
- Occlusion of bronchi or bronchioles by secretions or foreign body
- Tear of one of the large bronchi
- Large tear of the lung parenchyma
- Clotting of a smaller diameter chest tube or pigtail catheter by blood (may require low-dose TPA to declot pigtails)
- If pneumothorax persists or large air leak despite well-placed tube, there is a need for emergent bronchoscopy [17].

## 5. Central venous catheter placement

Central venous catheterization is one of the fundamental requirements for resuscitating critically ill patient in ED and intensive care unit (ICU).

### 5.1. Indications

Rapid venous access in emergency situation, e.g., cardiac arrest.

- Hemodynamic monitoring such as central venous pressure measurement (CVP) and central venous oxygen saturation.
- Rapid fluid and drug infusion.
- Parenteral nutrition.
- Central venous access can be used for hemodialysis and transvenous pacemaker placement.

### 5.2. Contraindications

Local infection in the area to be punctured.



Distorted anatomy-bleeding disorder.

- -Anticoagulant therapy-IV drug abuse through the access.
- -Pneumothorax on the contralateral side.

### 5.3. Equipment

-Lidocaine 1%–Needles and swabs and antiseptic solution.

Gloves, gown, cap, and mask.

- 10-ml syringe for catheter placement.
- Catheter kits–drapes and gauze pads.
- Needle holder and suture material and scissors.
- Ultrasound and sterile probe.

### 5.4. Technique

Seldinger (guidewire) technique is the most commonly used and it should be done under aseptic technique. The procedure should be explained to the patient if possible or his family and consent should be taken. All the equipment should be prepared. Patient should be placed in supine position and connected to a monitor. The selected area for puncture should be cleaned using the antiseptic solution and alcohol swabs. Locate the vein selected for puncture by anatomical landmark. It can also be done with ultrasound guidance as well.

Local anesthetic lidocaine 1% can be used at the site of puncture and sedation for patient comfort. A large-caliber needle connected to 10-ml syringe with 1-ml saline is used for the venipuncture and should be advanced slowly under negative pressure till a free flow of blood is seen in the syringe; at this point the syringe should be removed, and at the same time occlude needle and stabilize it carefully to avoid air embolism and displacement. Then thread the guidewire through the needle and remove the needle. After that insert the catheter over the guidewire. A dilator can be used before passage of the catheter over the guidewire and tight control of the guidewire at the skin should be kept during placement. Once the catheter is inserted, then guidewire should be removed, and connect the catheter to intravenous tubing after checking blood backflow and flush with saline and secure it with suture. Confirm the position by ultrasound and obtain X-ray of the chest and abdomen.

### 5.5. Complications

Arterial puncture

Air embolism and catheter embolus

Local hematoma

Pericardial tamponade

Arteriovenous fistula

Pneumothorax and hemothorax

Hemomediastinum

Neck hematoma

Tracheal obstruction or perforation

Bowel or bladder perforation

Local cellulitis and sepsis

Neurologic injury

Venous thrombosis[11].

### **5.6. Intraosseous access**

- Provides a rapid and reliable method of getting access to the systemic circulation
- Recommended by the American Heart Association if venous access cannot be quickly and reliably established[18]
- Still a widely underutilized modality[19, 20]
- Can be used to give drugs (all the drugs given through an IV line can be given through an IO line) and infuse fluids, blood, as well as contrast for imaging [21]

### **5.7. Indications**

In any situation where peripheral access is not easily available.

- During life-threatening situations such as CPR or trauma
- Burns
- Seizures
- Edema

### **5.8. Equipment**

- Intraosseous needles: All are 15 G and vary in length, 15, 25, and 45 mm.
- Manual needle and trochar devices or automated EZ IO drill. Several devices like Jamshidi needle, Sur-Fast intraosseous needle, Sussmane-Raszynski needle, FAST1 Intraosseous Infusion System, new intraosseous device(NIO), and bone injection gun(BIG) are available.
- Lidocaine or lignocaine for local anesthesia and for use before starting any infusion (running infusions is more painful than insertion due to the expansion of the medullary plexus).
- 5–10-ml syringes for aspiration and flushing.
- EZ connect IV tubing if using EZ IO set.
- Dressing.

## 5.9. Sites and technique

Take universal precautions and prepare the insertion site with an antiseptic. Use the needle size 15 mm for <40 kg, 25 mm for >40 kg, and 45 mm for proximal humerus or excessive body tissue.

**Proximal tibia:** Position the patient supine with the knee flexed, and identify the tibial tuberosity. Insert the needle two fingerbreadths distal and 1–2 cm medial to it. In a conscious patient, instill local anesthetic first. Tilt the needle caudally, away from the epiphysis. Manually insert in a screw-like motion or drill till you feel a give, remove trochar (very sharp, dispose in the sharp box), fix a syringe, and aspirate. The bone marrow is not always aspirated; flush and note for any extravasation. A needle that stands upright without support indicates correct placement. Secure with tape or dressing.

**Distal tibia:** Palpate the medial malleolus and identify the anterior and posterior borders as well as the most prominent part of the malleolus; insert the needle 2–3 cm proximal to the most prominent part in between the anterior and posterior borders of the tibia.

**Proximal humerus:** With the elbow adducted and the arm internally rotated, place the hand palm down on the abdomen, palpate the anterior shaft of the humerus till you palpate the greater tuberosity, and insert the needle about a cm above that, i.e., 1 cm above the surgical neck of the humerus.

**Other sites:** Femur, sternum, and anterior superior iliac spine (**Figure 6**).

### Complications

- Failure
- Extravasation
- Compartment syndrome
- Fracture
- Osteomyelitis
- Necrosis of the epiphyseal plate

## 6. ED thoracotomy

- Lifesaving procedure
- Reported survival rates of 2% in blunt trauma and 16% in penetrating trauma[22] to as great as 60% in a selected group of patients

### 6.1. Indications

#### 6.1.1. Penetrating chest trauma

- Previously witnessed cardiac activity (prehospital or in-hospital) or signs of life (pulse, BP, pupil reactivity, purposeful movement, and respiratory effort)

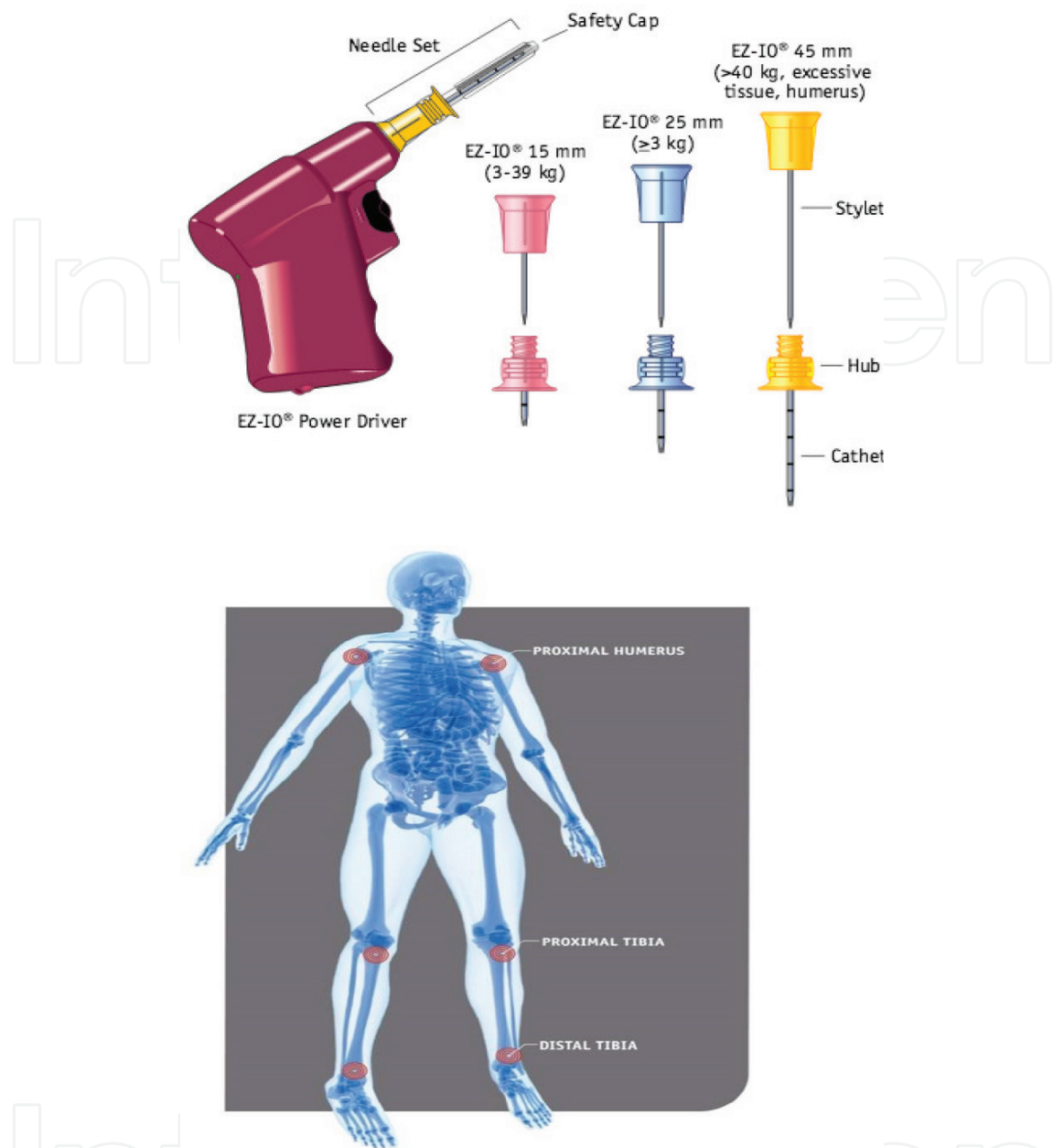


Figure 6. Intrasosseous device and sites.

- Unresponsive hypotension [systolic blood pressure (SBP) <70 mm Hg] despite vigorous resuscitation [23]

#### 6.1.2. Blunt chest trauma

- Previously witnessed cardiac activity (prehospital or in-hospital)
- Rapid exsanguination from the chest tube (>1500 mL)
- Unresponsive hypotension (SBP <70 mm Hg) despite vigorous resuscitation

The American College of Surgeons Committee on Trauma indications for EDT are as follows [24]:

- Precordial wound in a patient with prehospital cardiac arrest
- Trauma patient with cardiac arrest after arrival to ED
- Profound hypotension (<70 mm Hg) in a patient with a truncal wound who is either unconscious or an operating room is unavailable

**The Eastern Association for the Surgery of Trauma** strongly recommends resuscitative ED thoracotomy in patients presenting pulseless to the ED with signs of life after penetrating thoracic injury [25].

Can be considered for patients presenting with penetrating thoracic trauma without witnessed signs of life or cardiac activity and in penetrating abdominal trauma in traumatic arrest with prior witnessed cardiac activity and signs of life.

## 6.2. Equipment

- Sterile gloves, gown, and face shield
- Betadine and sterile drapes
- Thoracotomy set including scalpel 10 blade, Mayo scissors, rib spreaders, Gigli saw, vascular clamps, and needle holders
- Suture material
- Aortic clamp
- Chest tubes and Foley catheter
- Internal defibrillator
- Skin stapler

## 6.3. Technique

- Intubate the patient and pass the nasogastric tube.
- Initiate the mass transfusion and commence with the blood products.
- Wear your personal protective equipment.
- **Anterolateral approach:** Make an incision in the left fourth intercostal space extending from the sternum to the posterior axillary line cutting the skin, subcutaneous tissue, and intercostal muscles in one go. Apply the rib spreaders.
- **Clamshell approach:** Start as the left anterolateral approach, extend to the right in the space intercostal space, cut the sternum with the Gigli saw, and apply the rib spreader on the cut ends of the sternum.
- **Pericardiotomy:** Move the lung out of the way and incise the pericardium anterior to the phrenic nerve from the apex to the root of the aorta.
- Inspect the myocardium for injury, which can then be occluded digitally, by skin stapler, occluding it with a Foley catheter or sutures.



- Cardiac massage and internal defibrillation can be done.
- Hilar clamping can be done in case of extensive lung laceration.
- Cross-clamping of the aorta can be done in case of persistent hypotension.

#### **6.4. Contraindications**

- Non-traumatic cardiac arrest
- Blunt injury without witnessed cardiac activity (prehospital) or penetrating abdominal trauma without cardiac activity (prehospital).
- Severe head injury
- Severe multisystem injury
- Improperly trained team or insufficient equipment

### **7. Pericardiocentesis**

Pericardiocentesis is the aspiration of fluid from the pericardial space that surrounds the heart. This procedure can be lifesaving in patients with cardiac tamponade, even when it complicates acute type A aortic dissection and when cardiothoracic surgery is not available.

#### **7.1. Indications**

##### *7.1.1. Emergent pericardiocentesis*

Life-threatening hemodynamic compromise due to suspected cardiac tamponade. Cardiac arrest secondary to cardiac tamponade.

##### *7.1.2. Nonemergent pericardiocentesis*

Diagnostic pericardiocentesis for pericardial effusions (due to infectious, hemorrhagic, or malignant etiology).

##### *7.1.3. Contraindications*

There is no absolute contraindication to pericardiocentesis in hemodynamically unstable patient.

##### *7.1.3.1. Relative contraindications*

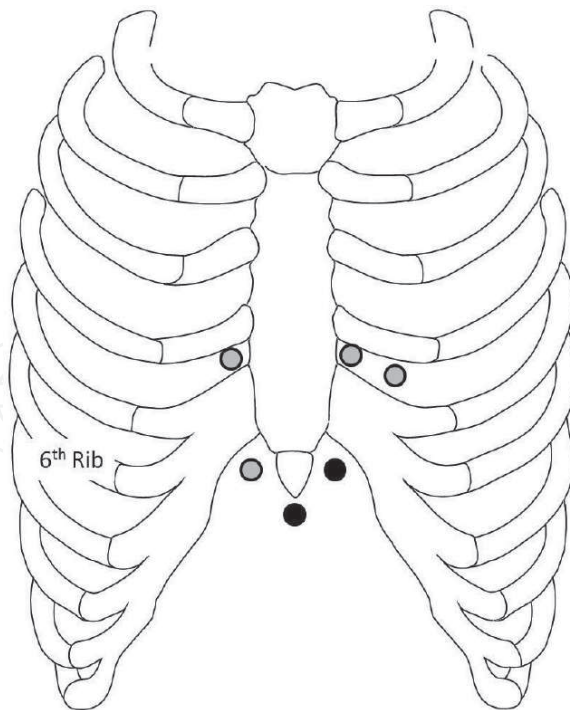
- Uncorrected bleeding disorders in stable patients
- Dialysis available for uremic patients
- Immediate surgery or thoracotomy available for trauma patients

Equipment needed: Essential equipment includes the following:

- Antiseptic solution Three-way stopcock scalpel
- Ultrasound machine with sterile probe
- Pericardiocentesis kit
- Needles, 18 ga, 1.5 in and 25 ga, 5/8 in and • Spinal needle, 18 ga, 7.5–12 cm
- Continuous cardiac or ECG monitoring
- Sterile drapes, gown, and mask
- Local anesthetic (e.g., lidocaine 1%)
- Alligator clip connector for connection to V<sub>1</sub> lead of ECG machine

#### 7.1.4. Technique

Ideally, patient should be in a semirecumbent position at 30–45 degrees so as to bring the pericardium close to the anterior chest wall; however, supine position is an acceptable alternative.



**Figure 7.** Various anatomical approaches for pericardiocentesis. Pericardiocentesis needle insertion sites. The subxiphoid and left sternocostal margins are the most commonly used sites (black dots). (Source: Medscape).

If time and situation allow, the procedure should be explained to the patient and local anesthesia should be administered at the site of procedure. Ensure IV access, with patient connected to the monitor, and supplemental oxygen. Ideally the procedure should be done under ultrasound guidance; however, if the patient is in cardiac arrest, then the procedure should be initiated as soon as possible for pericardial fluid aspiration.

There are various anatomical approaches for pericardiocentesis, as shown in the **Figure 7**, with subxiphoid approach and left parasternal margin being the most common sites (**Figure 8**).

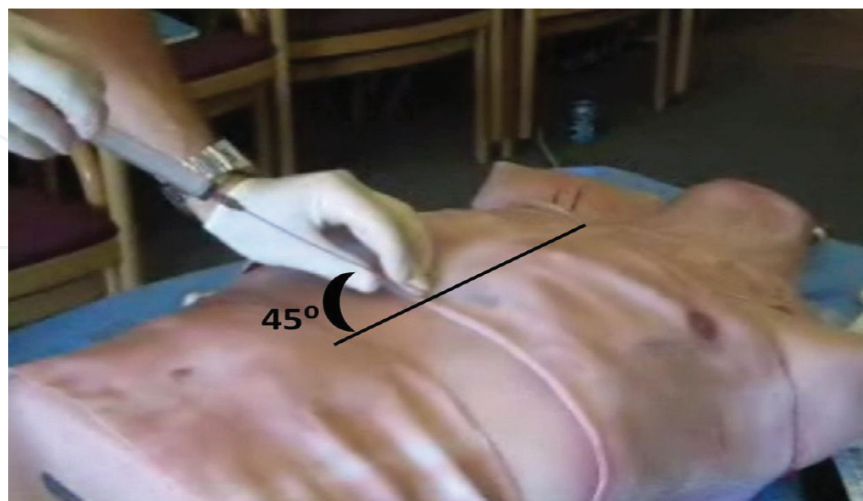
In subxiphoid approach, mark the area between the xiphoid process and left sternocostal margin, ideally 1 cm inferolaterally to the xiphoid process on the left side. Clean the area using an antiseptic solution and insert the needle (spinal needle) at 30–45 degrees, aiming toward the left shoulder, as shown in the picture.

If time permits, connect an alligator clip from the base of the spinal needle to the V<sub>1</sub> lead of an ECG machine, and use bedside ultrasound to visualize the needle tip in the pericardial as depicted in **Figure 9**.

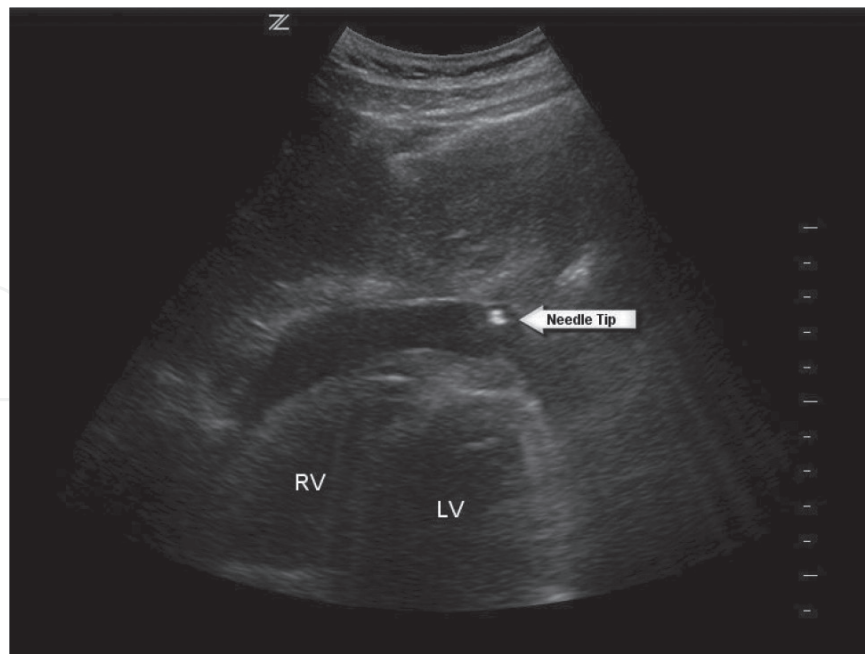
Apply constant negative pressure on the syringe until a return of fluid or blood is visualized, cardiac pulsations are felt, or abrupt change in ECG waveform is noted (**Figure 10**).

Stabilize the needle and withdraw as much fluid as possible. If a catheter-over-the-needle has been used, then the needle can be removed and catheter can be stabilized to the chest wall, with a three-way stopcock attached to allow continuous drainage of pericardial fluid.

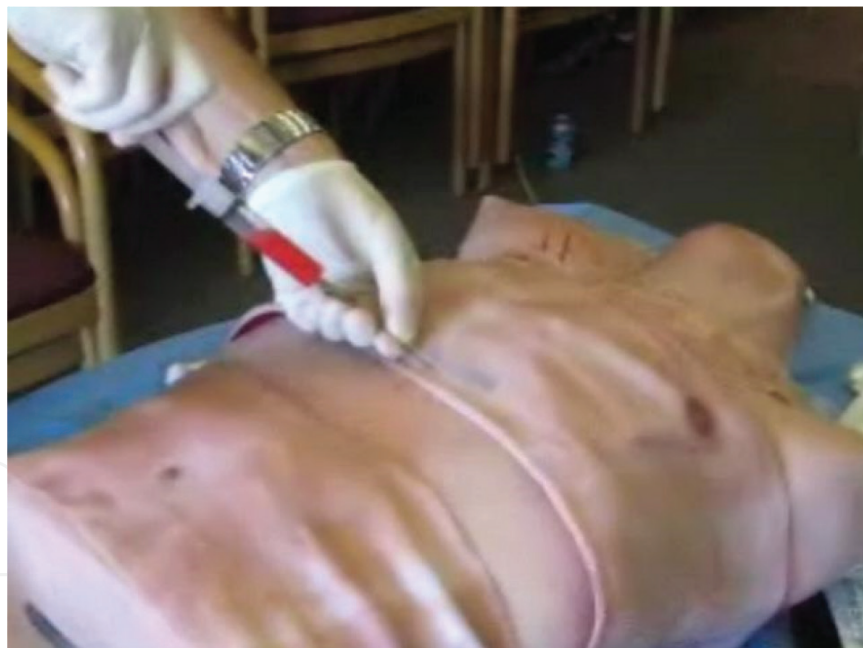The needle may move closer to the myocardium, and an injury pattern may appear on the ECG, in which case the needle should be withdrawn slightly to avoid myocardial injury.



**Figure 8.** Needle insertion: Insert the spinal needle through the skin incision directed toward the left shoulder at a 45-degree angle to the abdominal wall and 45 degrees off the midline sagittal plane.



**Figure 9.** Subxiphoid view of the heart demonstrating the needle tip within the pericardial space.



**Figure 10.** Needle insertion: slowly advance the spinal needle up to a depth of 5 cm while applying negative pressure on the syringe until a return of fluid is visualized.

## 7.2. Complications

- Dysrhythmias
- Coronary artery puncture or aneurysm
- Dry tap (failure to yield fluid)

- Pneumothorax
- Hemopericardium
- Venous air embolism
- Hepatic injury
- False-positive aspiration–intracardiac aspiration
- False-negative aspiration—clotted blood in the pericardial cavity
- Reaccumulation of pericardial fluid defibrillation

“Defibrillation” or “unsynchronized cardioversion” is the transthoracic application of unsynchronized electric current during a cardiac cycle, causing the heart muscle to contract simultaneously and, thus, terminating the abnormal electrical rhythm. This enables the sinus node to resume its normal cardiac cycle.

### **7.3. Indications**

Indications for defibrillation include the following:

- Pulseless ventricular tachycardia (VT)
- Ventricular fibrillation (VF)
- Cardiac arrest due to or resulting in VF

### **7.4. Contraindications**

Contraindications include the following:

- Dysrhythmias due to enhanced automaticity, such as in digitalis toxicity and catecholamine-induced arrhythmia
- Multifocal atrial tachycardia

### **7.5. Equipment needed**

- Defibrillators [automated external defibrillators (AEDs), semiautomated AEDs, standard defibrillators with monitors]
- Paddle or adhesive patch
- Conductive gel or paste
- ECG monitor with recorder
- Oxygen equipment
- Airway management equipment
- Emergency pacing equipment



- Blood pressure cuff (automatic or manual)
- Pulse recorder
- Oxygen saturation monitor
- Intravenous access
- Suction device
- Code cart with advanced cardiovascular life support (ACLS) medications
- Sedation medications

## 7.6. Technique

Defibrillation is performed during a cardiac arrest while the CPR is going on simultaneously. So, it is important to carry out the CPR, along with proper administration of defibrillation technique for maximum benefit. Defibrillators can deliver either in monophasic (delivers a charge in only one direction) or biphasic (delivers a charge in one direction for half of the shock and in the electrically opposite direction for the second half) waveforms. Newer defibrillators deliver energy in biphasic waveforms as they tend to successfully terminate arrhythmias at lower energies than monophasic waveform defibrillators. The defibrillation process is done in three important steps, which are as follows:

### 7.6.1. Paddle placement

Apply conductive material to the entirety of the chest.

Conductive gel or paste is most commonly used, but waxy conductive pads are also available. Generous use of conductive gel on the underside and especially along the edges of the electrode paddles is essential, both to reduce transthoracic impedance and to prevent skin burns. Paste should be applied liberally but must not run onto the skin between the paddles, because the paste may divert current over the skin surface and away from the heart.

Paddle placement on the chest wall has two conventional positions:

- Anterolateral and anteroposterior.
- In the anterolateral position, a single paddle is placed on the left fourth or fifth intercostal space on the midaxillary line. The second paddle is placed just to the right of the sternal edge on the second or third intercostal space.

In the anteroposterior position, which is preferred in patients with implantable devices, to avoid shunting current to the implantable device and damaging its system, a single paddle is placed to the right of the sternum, as above, and the other paddle is placed between the tip of the left scapula and the spine (**Figure 11**).

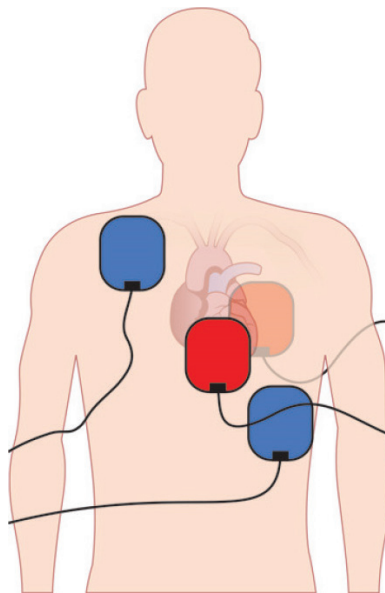
### 7.6.2. Defibrillator and Charging

Turn on the defibrillator, and turn the dial to defibrillation mode on the defibrillator (**Figure 12**).

Identify that the rhythm is a shockable rhythm. Select the energy of 360J for monophasic defibrillators or 120–200J for biphasic defibrillators, and select charge to start charging the defibrillator, which is indicated by beginning of a beep sound (**Figure 13**).

### 7.6.3. Shock delivery

As soon as the defibrillator is charged, which is indicated when the beep stops, press the shock button to deliver the shock (**Figure 14**).



**Figure 11.** Paddle placement on the chest wall.



**Figure 12.** Defibrillation and cardioversion.



Figure 13. Defibrillation and cardioversion.

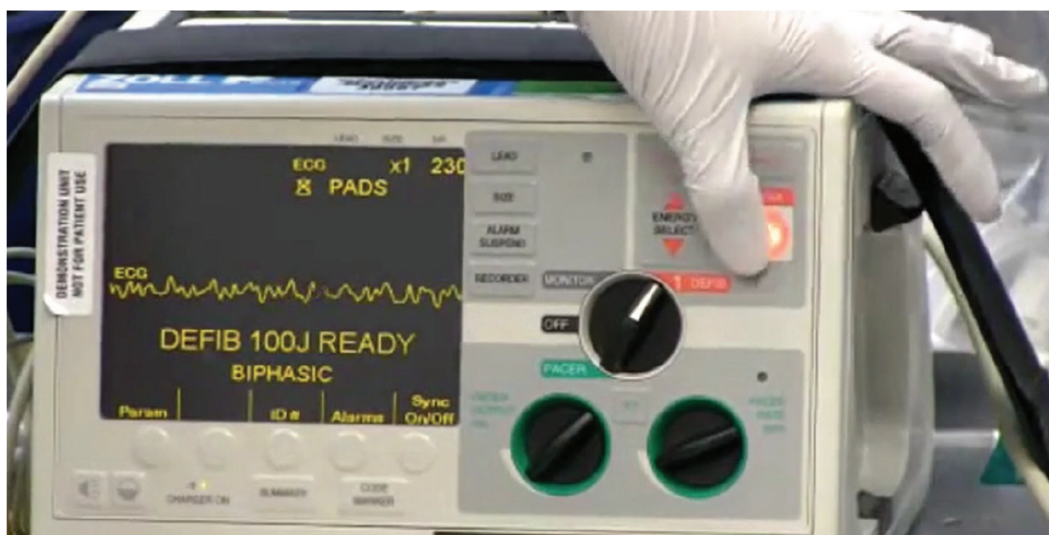


Figure 14. Defibrillation and cardioversion.

Safety is a key concern in the performance of defibrillation. Any staff member acting as a ground for the electrical discharge can be seriously injured. The operator must announce “all clear” and give staff a chance to move away from the bed before discharging the paddles.

Care must be taken to clean up spills of saline or water, because they may create a conductive path to a staff person at the bedside.

After the shock is delivered, continue the CPR.

### 7.7. Complications

- Harmless arrhythmias, such as atrial, ventricular, and junctional premature beats (commonest)

- Ventricular fibrillation (VF) resulting from high amounts of electrical energy, especially in patients with digitalis toxicity, severe heart disease, or improper synchronization of the shock with the R wave
- Thromboembolization
- Myocardial necrosis
- Hypoxia due to excessive sedation
- Chest wall skin burns (most likely are due to improper technique or electrode placement and inadequate conductive gel)
- Injuries to healthcare personnel (shock and burns)

## 8. Transcutaneous pacing

Transcutaneous pacing is a temporary means of pacing a patient's heart in an abnormally slow heart rate. It is accomplished by delivering pulses of electric current through the patient's chest, which stimulates the heart to contract in a minimally effective manner.

### 8.1. Indications

Indications for TCP can be grouped in bradyarrhythmias and tachyarrhythmias as follows:

#### 8.1.1. Bradyarrhythmias

- Symptomatic sinus node dysfunction (sinus arrest, tachybrady [sick sinus] syndrome, sinus bradycardia)
- Second- and third-degree heart block
- A-fib with slow ventricular response
- Malfunction of implanted pacemaker
- New left bundle-branch block (LBBB), right bundle-branch block (RBBB) with left axis deviation, bifascicular block, or alternating bundle-branch block
- Trauma patient with hypotension and unresponsive bradycardia
- Prophylaxis—cardiac catheterization, after open heart surgery, threatened bradycardia during drug trials for tachydysrhythmias

#### 8.1.2. Tachyarrhythmias

- Supraventricular dysrhythmias (e.g., postoperative atrial flutter)
- Ventricular dysrhythmias (monomorphic ventricular tachycardia)

- Prophylactically in cardiac catheterization, after open heart surgery and in cases of bradycardia-dependent tachycardias (e.g., torsades de pointes)

### 8.1.3. Contraindications

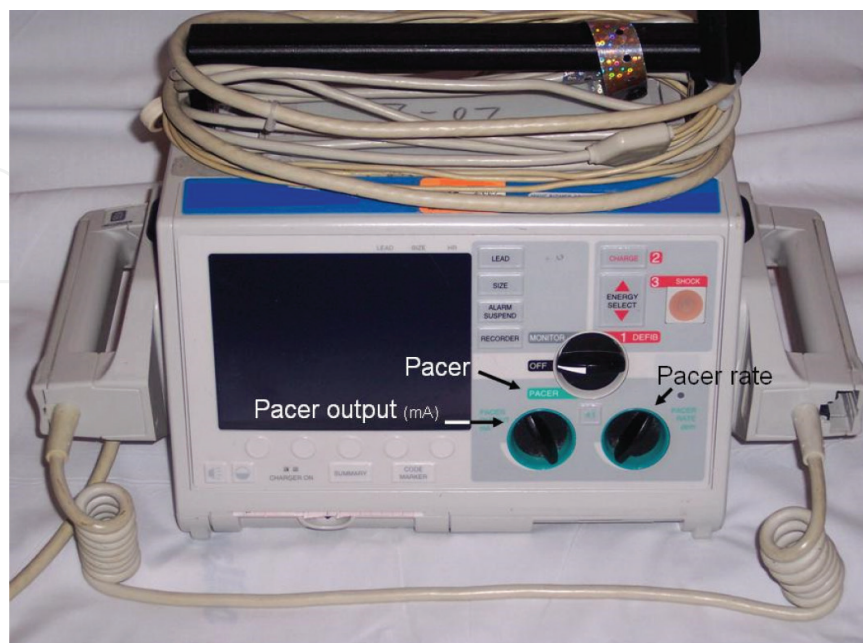There are no absolute contraindications; however, it is advisable to avoid pacing in the following conditions:

- First-degree AV block
- Mobitz type I block
- Stable escape rhythm
- Bradyarrhythmias secondary to profound hypothermia

### 8.1.4. Equipment needed

Equipment used in transcutaneous cardiac pacing includes the following (**Figure 15**):

- Pacing unit
- Cardiac monitor
- Defibrillator (see the image below)
- Pacing electrodes (pads)
- Procedural sedation/analgesia medications
- Airway equipment



**Figure 15.** Defibrillator with pacing capability.



**Preparation**The process of electrical pacing can be of significant discomfort to the patient if not prepared adequately.

It is, therefore, advised to consider analgesia or sedation to ease patient's discomfort.

Also, patient's skin should be wiped with alcohol and dried, any foreign body should be removed, and careful shaving of the excessive hair should be done, taking care to avoid abrading the skin as it can elevate the pacing threshold and increase burning and discomfort.

## 8.2. Technique

The electric pads can be placed either in anterolateral position or anteroposterior position.

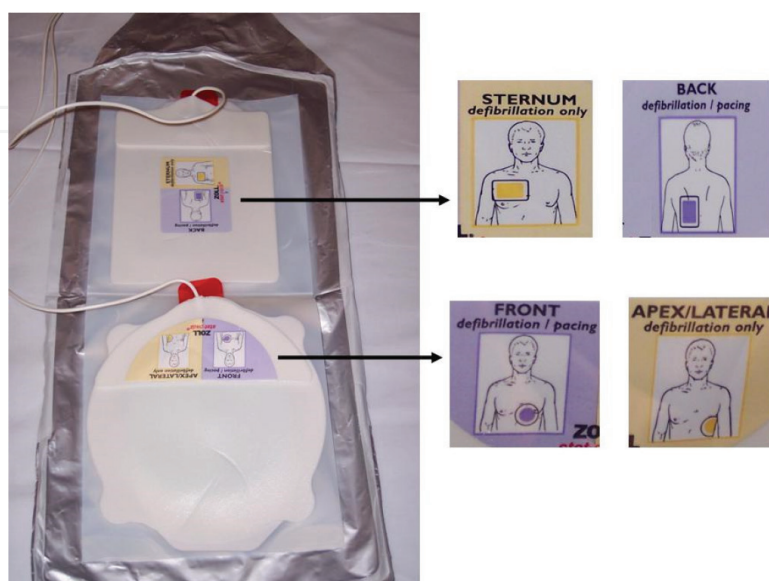
The anterior electrode should have negative polarity and should be placed at the cardiac apex or at lead V3 position.

The positive or posterior electrode should be placed inferior to the scapula or between the right or left scapula and the spine; it should not be placed over the scapula or the spine. Alternatively, the positive electrode can be placed anteriorly on the right upper part of the chest (see the image below) (**Figure 16**).

To initiate TCP, after application of pads and activating the device, turn the selection knob to the "pacer" mode, and select pacer rate of 60–80; as shown in **Figure 1**.

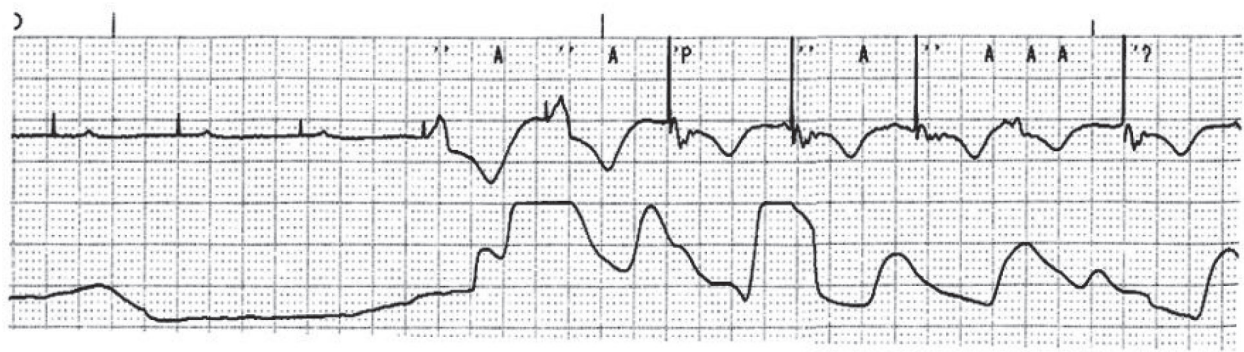
Select the current, and look for one QRS complex after each pacing spike. This is called "electrical capture." Look for corresponding pulse by checking patient's pulse (**Figure 17**). If the pulse corresponds with the electrical capture along with improved BP and clinical status of the patient, "mechanical capture" is attained as shown in **Figure 3**.

The electrical output should be started from maximum output if the patient is in cardiac arrest, and then decrease to keep 10–15 mA above the threshold to maintain adequate mechanical capture.



**Figure 16.** Pacing electrode pads of external pacing unit and locations in which each pad should be placed.





**Figure 17.** Rhythm strip showing failure to capture in the first four pacing stimuli that did not produce any pulse. When capture occurred, each pacing artifact is followed by QRS complex (albeit bizarrely shaped) and pulse.

However, in a patient who has a hemodynamically compromising bradycardia but is not in cardiac arrest, the operator should start from a low current output to get an electrical capture and slowly increase the output from the minimal setting until mechanical capture is achieved.

### 8.3. Complications

- Induction of dysrhythmias (VF)
- Burns (rarely)
- Pain/discomfort

## 9. Conclusion

The physicians of the emergency department have great mission as they have to manage critically ill patients and stabilize them by effectively using their own skills in order to improve their patients' condition. The emergency physicians should provide the best when providing lifesaving treatment to a critically ill patients either doing RSI to secure airway or inserting a central venous catheter for vasopressors and intravenous fluid administration or any other resuscitative procedure in emergency setting. In this chapter we focused on the fundamental knowledge for performing emergency procedures and what steps EP should know to deliver best care and save the patient's life. This chapter was a guide to help the emergency physician (EP) to better understand and develop the required technical skills and have the basis needed to achieve the highest level of care that will have direct impact on patients' outcome.

### Author details

Aml Yousif Elemamali\* and Aftab Mohammad Azad

\*Address all correspondence to: [aftab.azad@me.com](mailto:aftab.azad@me.com)

Department of Emergency Medicine, Hamad Medical Corporation, Doha, Qatar

## References

- [1] <http://www.lww.co.uk/emergency-medicine-toxicology/decision-making-in-emergency-critical-care;2015>
- [2] <https://www.cambridge.org/core/books/emergency-airway-management/65F6E8117405BA92AD27281939DB1EB8>
- [3] <https://www.scribd.com/document/353543024/Roberts-Hedges-Clinical-Procedures-in-Emergency-Medicine-6th-Ed-PDF-Tahir99-VRG>
- [4] <http://accessemergencymedicine.mhmedical.com/book.aspx?bookID=683>
- [5] <http://bookstore.acep.org/emergency-department-resuscitation-of-the-critically-ill-1st-ed-560000>
- [6] <https://www.amazon.com/Emergency-Medicine-National-Medical-Independent/dp/0781788846>
- [7] <https://www.elsevier.com/books/rosens-emergency-medicine-concepts-and-clinical-practice-2-volume-set/marx/978-1-4557-0605-1>
- [8] Gambee MA, Hertzka RE, Fisher DM. Preoxygenation techniques: Comparison of three minutes and four breaths. *Anesthesia and Analgesia*. 1987;**66**:468-470. [PubMed: 3578856]
- [9] Smith CE. Rapid sequence intubation in trauma. The 10th Annual Trauma Anesthesia and Critical Care Society Symposium, May 1997 (poster)
- [10] Schneider RE, Caro DA. Pretreatment agents (Chapter 16). In: Walls RM, Murphy MF, editors. *Manual of Emergency Airway Management*, 2nd ed. Philadelphia: Lippincott, Williams & Wilkins; 2004:183-188
- [11] American College of Surgeons. *Advanced Trauma Life Support Instructor Manual*. 6th ed. Chicago: American College of Surgeons; 1997. p. 150
- [12] Taylor RW, Civetta JM, Kirby RR: *Techniques and Procedures in Critical Care*. Philadelphia: Lippincott; 1990. 306
- [13] Britten S, Palmer SH, Snow TM. Needle thoracostomy in tension pneumothorax: Insufficient cannula length and potential failure. *Injury*. 1996;**27**(5):321-322. [PubMed: 8763284]
- [14] <http://www.trauma.org/thoracic/CHESTtension.html>Preparepatient
- [15] <https://www.ncbi.nlm.nih.gov/pmc/articles/PMC4613415/complications>
- [16] [http://www.emedicine.com/med/topic2793.htm#section~relevant\\_anatomy\\_and\\_contraindications](http://www.emedicine.com/med/topic2793.htm#section~relevant_anatomy_and_contraindications)
- [17] Chest tube Life in the fast lane/Wikem.org/BTS guidelines/American chest society
- [18] Intraosseous [Guideline]. Kleinman ME, Chameides L, Schexnayder SM, Samson RA, Hazinski MF, Atkins DL, et al. Part 14: Pediatric advanced life support: 2010 American

Heart Association Guidelines for Cardiopulmonary Resuscitation and Emergency Cardiovascular Care. *Circulation*. 2010 Nov 2;**122**(18 Suppl 3):S876-S908. [Medline]. [Full Text]

- [19] Bloch SA, Bloch AJ, Silva P. Adult intraosseous use in academic EDs and simulated comparison of emergent vascular access techniques. *The American Journal of Emergency Medicine*. 2013;**31**(3):622-624. DOI: 10.1016/j.ajem.2012.11.021
- [20] Hallas P, Brabrand M, Folkestad L. Reasons for not using intraosseous access in critical illness. *Emergency Medicine Journal*. 2012;**29**(6):506-507. DOI: 10.1136/emj.2010.094011
- [21] Winkler M, Talley C, Woodward C, Kingsbury A, Appiah F, Elbelasi H, et al. The use of intraosseous needles for injection of contrast media for computed tomographic angiography of the thoracic aorta. *Journal of Cardiovascular Computed Tomography*. 2017 Mar 16. [Medline]
- [22] Ed thoracotomy Hopson LR et al. Guidelines for withholding or termination of resuscitation in prehospital traumatic cardiopulmonary arrest: Joint Position Statement of the National Association of EMS Physicians and the American College of Surgeons Committee on Trauma. *Journal of the American College of Surgeons*. 2003;**196**:106
- [23] Iwata T, Inoue K, Hige M, Yamazaki K, Kawata Y, Suehiro S. Multiple thoracoabdominal gunshot wounds with complicated trajectories. *Japanese Journal of Thoracic and Cardiovascular Surgery*. 2006 Oct;**54**(10):444-447
- [24] American College of Surgeons Committee on Trauma. *Advanced Trauma Life Support*. 7th ed. Chicago, Ill: American College of Surgeons Committee on Trauma; 2004
- [25] Seamon, Mark J, Haut, Elliott R, et al. Emergency Department Thoracotomy. *Journal of Trauma*. July 2015;**79**(1):159-173