

We are IntechOpen, the world's leading publisher of Open Access books Built by scientists, for scientists

4,800

Open access books available

122,000

International authors and editors

135M

Downloads

Our authors are among the

154

Countries delivered to

TOP 1%

most cited scientists

12.2%

Contributors from top 500 universities



WEB OF SCIENCE™

Selection of our books indexed in the Book Citation Index
in Web of Science™ Core Collection (BKCI)

Interested in publishing with us?
Contact book.department@intechopen.com

Numbers displayed above are based on latest data collected.
For more information visit www.intechopen.com



Evaluation of Patients with Alopecia

Meda Sandra Orasan, Andrei Coneac and
Iulia Ioana Roman

Additional information is available at the end of the chapter

<http://dx.doi.org/10.5772/intechopen.78639>

Abstract

This chapter outlines the clinical approaches for alopecic patients that are reliable in practice. We discuss three different categories of hair evaluation options: invasive methods (biopsy), semi-invasive methods (trichogram) and noninvasive methods. Besides describing the current status of diagnosis and quantification of alopecia, the chapter provides an objective assessment of these investigation tools: detailed medical history collection by structured interview and questionnaires, clinical examination of the scalp and other hair-bearing areas, laboratory investigations, assessment of hair loss distribution (patterned/diffuse/focal), dermoscopic evaluation, assessment of alopecia severity (by pull test, hair part width, counting hair test), common scales for hair loss staging, photography of alopecic areas, biopsy, trichogram, unit area trichogram, tug test, hair mount and microscopic evaluation, electron microscopy, hair card test, hair weight determination, hair densitometry, mechanical test of hair quality and computed hair analysis. Unfortunately, the disadvantages of most of these methods generate a lack of use in clinical practice, leading to few reliable evaluation methods for patients suffering from alopecia. We underline the necessity of easy, refined and precise evaluation tools for the assessment of alopecia patients.

Keywords: alopecia, hair loss, hair shedding, hair thinning, androgenetic alopecia, female pattern hair loss, telogen effluvium, anagen effluvium, alopecia areata, trichotillomania, tinea capitis, traction alopecia, evaluation methods, dermoscopy/trichoscopy, pull test, counting hair tests, trichogram, microscopic evaluation, hair weight determination, hair densitometry, computed hair analysis

1. Introduction

Hair loss and hair thinning represent frequent complaints of both female and male patients in clinical dermatology. Establishing a correct management can be challenging, beginning from

the subjective description provided by the patient, the confirmation of a true hair disorder and its underlying pathogenesis.

Current literature describes a long list of evaluation methods for patients suffering of alopecia. The objective assessment of these methods enable us to outline the clinical approaches that are reliable in practice. There are three different categories of hair evaluation options: invasive methods (biopsy), semi-invasive methods (trichogram) and noninvasive methods (interview with detailed medical history collection and questionnaires, systemic evaluation through laboratory tests and other investigations, counting hair tests, hair pull test and tug test, hair weight determination, densitometry or HairCheck test, imaging tests such as global photographs, trichoscopy, phototrichogram, videodermoscopy, light microscopy, etc.) [1–3]. All these assessment methods have merits and demerits, but for some, the disadvantages generate a lack of use in clinical practice [4]. Also the patients seem to be more interested in performing only some of them, especially the non-invasive methods.

The diagnosis of androgenetic alopecia or female pattern hair loss is confirmed clinically and extra tests are not usually required. The dermatologist focuses on detailed medical history and physical examination, analyzing the scalp aspect, the hair loss pattern, the trichoscopic findings and sometimes the pull test results [5]. Basic hair evaluation methods also include scalp biopsy (each alopecia having a specific histopathological aspect), but this invasive method is only sometimes necessary for establishing a diagnosis [3, 6].

2. Detailed medical history

Collecting information is of main importance and can be done by carefully listening to the patients on the following subjects:

- a. **date/age of onset** (congenital or acquired),
- b. **type of onset** (sudden or insidious), correlated with other medical issues or personal events. Chronic or acute **stress**, for example, lowers the production of estrogens, leaving the genetically targeted hair follicles susceptible to testosterone action and inducing hair loss by premature onset of catagen [7].
- c. **physiological changes**, such as childbirth (1–3 months after delivery hair follicles revert to telogen and begin to fall out as a new growth cycle of hair begins) [3, 8]. While breastfeeding prolactin can delay hair loss. Miscarriage or termination also lead to significant hair loss, especially after the first 3 months of pregnancy. In babies, alopecia is physiological up to 6 months due to a decrease of hormones after birth that will induce telogen effluvium. Finally, gradual thinning and finer textured hair are common with aging (involutional alopecia) and around menopause [9].
- d. **illnesses and infections** prior to the onset of alopecia, or other possible **trigger factors** in the previous 2–5 months (high fever, chronic blood loss in women with prolonged heavy menses (anemia) or severe dietary protein deficiency, as they correlate with chronic

telogen effluvium (CTE) [7, 9]. Finding out if the patient follows a certain **diet** is also important to establish if the protein and calories intake is adequate. Anemia (lack of iron and low ferritin levels) may lead to diffuse hair thinning everywhere on the scalp, changes of hair texture (brittle hair) and strands breaking off in different lengths [9]. Sometimes an episode of telogen effluvium may uncover a latent AGA [8].

- e. **past medical history** (chronic illnesses, surgeries, autoimmune, dermatologic and psychiatric disorders, etc.). The dermatologist should identify if other dermatological or endocrinological diseases are present, and if so, they must be properly investigated and treated. Atopy, autoimmune thyroid disease and vitiligo are commonly associated with alopecia areata [10]. Female pattern hair loss is common in patients with polycystic ovary syndrome (PCOS – with clinical signs: acne, increased facial hair as part of hirsutism, irregular periods, infertility, weight gain), congenital adrenal hyperplasia (an adrenal tumor causes a conversion of the hormones normally produced, increasing the testosterone levels), etc. [11, 12].
- f. **medication** used by the patient, as some of them may induce hair loss: anticancer drugs, anticoagulants, anticonvulsants, antithyroid drugs, beta blockers, tricyclic antidepressants, and progestins with androgenic effects [7]. The contraceptive pills can act as treatment or cause of hair loss: in the first 3 months of use they determine either thicker hair regrowth or increased fall rate, especially after discontinuation [11]. Contraceptive pills with a high level of progestins may lead to hair loss, together with acne and hirsutism, and if so, they need to be switched to pills based on ethinodiol [9]. Anagen effluvium secondary to drugs is usually caused by cancer chemotherapy and immunotherapy drugs, having a more diffuse and rapid progression than telogen effluvium [13].
- g. **rate of progression**, if it has any season pattern. If the patient has noticed hair regrowth since the onset of alopecia, this rules out cicatricial alopecia. The duration and extent of the hair loss process is important for the prognosis. Early, long-lasting and severe cases of alopecia areata have a less favorable prognosis, but no correlation has been found between the number of patches at onset and the subsequent severity of the disease [10]. Frontal fibrosing alopecia has an unpredictable evolution, and as well as central centrifugal cicatricial alopecia, if not treated, will burn out [6]. The prognosis in androgenetic alopecia and female pattern hair loss depends on the treatment: once discontinued the hair regrowth will be lost in 6–12 months and the hair pattern will return to the baseline state [14, 15]. In FPHL patients, complete hair loss on the central scalp is rare, in contrast to male-pattern baldness. Chronic effluvium telogen is usually a self-limiting condition, lasting more than 6 months, while anagen effluvium is entirely reversible, with hair regrowth after 6 months [7]. Scarring (cicatricial) hair loss tends to have a generally unfavorable prognosis.
- h. **associated symptoms** such as: itching, tenderness, pain, burning sensation. It has been reported that 14% of the patients suffering of alopecia areata suffer a burning sensation and accentuated pruritus [10].
- i. **type of treatment** (topic solutions, pills, laser, etc.) patients have used and the result from their point of view. Also focus on how the patient treats their hair on a daily/monthly

basis with: chemical agents (dying, coloring, etc.), thermic agents (heat from hair curler or straightener, etc.), hair cosmetics (dry shampoo, hair stimulating shampoo, balm, hair tonic, hairspray, gel, mousse or topical camouflaging fibers, etc.) and their frequency of use [11, 16].

- j. the **family history of alopecia**, autoimmune, dermatologic or psychiatric disorders [17]. Androgenetic alopecia or alopecia areata may exist in the family, but cicatricial alopecias rarely occur in family members (except Central Centrifugal Cicatricial Alopecia). In a personal study, 57% of the patients with female pattern hair loss had a positive family history: the mother in 29% of the cases, the father in 21% of the situations [16].
- k. **race of the patient** is also important. For example, central centrifugal cicatricial alopecia occurs in black women, resembling lichen planopilaris [6]. Dissecting cellulitis of the scalp is frequent mostly in black adolescents and adult males.
- l. **different types of alopecia that may sometimes coexist**: alopecia areata with trichotillomania [18], both patchy and diffuse alopecia areata with androgenetic alopecia (AGA) [8, 13], female pattern hair loss (FPHL) with frontal fibrosing alopecia (FAA) [19].

2.1. Structured interview: standardized flowchart

A standardized chart represents an easy evaluation tool for the patient's course over time, so no data will be omitted or forgotten. It collects important information at each patient visit, providing a good overview and it is also a helpful reminder of all the items of interest, helping the dermatologist to pass through all necessary tests. The flow chart can contain the symptoms of the patients, the clinical sign, the dermoscopy findings, the pull and tug tests results, the extent of hair loss, laboratory results, biopsy results, treatments performed, etc. [6]. One can use a standard flow chart already published and applied in clinical practice or design a new chart that suits his own needs.

2.2. Questionnaires

Several questionnaires have been used so far for hair loss patients to assess the quality of life and associated lifestyle patterns. One study used the Hairdex, lifestyle indexes, Symptom check list 90R and output psychiatric rating scales, but the major complaint of the patients when completing the survey was that all together, the 4 questionnaires contained more than 120 questions, which was both time consuming and tiring [20]. In a personal research we developed and used for FPHL patients a new questionnaire, more concise (26 questions), time effective (30 min) and full of relevant information [20]. Our questionnaire collected data upon demographic items (race, age, level of education, urban/county environment), illness-specific data (patients complaint, status of scalp visibility/severity of disease, duration of hair loss, type of hair), risk factors (family history of alopecia, scalp diseases, possible cause of hair fall, cosmetic products and devices used on hair, covering of hair with products or items), psychosocial consequences (affected self-confidence, affected mood, how often they think of hair loss, what aspects of life are disturbed by alopecia), treatment (prescribed by doctor, therapy already performed, therapy the patient would like to perform, the main purpose for

the treatment in patients opinion), and last but not least the evaluation of the questionnaire (useful and easy to complete) [14].

Questionnaires of hair loss are available online (for printing or online completion) on the websites of different clinical practice offices and need to be completed before the first visit. The majority of the questionnaires refer to diffuse shedding or thinning, but some also have a hair loss in patches section. Ranging from 22 to 35 questions, they gather information about the background of hair loss, past medical history, diet and medication history, hair care practices.

Even though questionnaires seem to please the patients and to gather a large volume of information in a short period of time, some of the subjects do complain that it is a more distant kind of approach and that they lack the interaction with the doctor.

3. Clinical examination

For alopecic patients, the clinical examination begins as soon as they enter the doctor's office as you can notice right away if the scalp is visible across the room, if hair thinning is present [6]. For most of the cases you can assess from the first glimpse the **extent of alopecia**: localized or diffuse.

Pay attention to the patient's **hair style**, as it might try to hide the alopecic areas, but also gives you hints about how the patient treats the hair, underlying possible **risk factors** [5, 17]. Ask the patients if they use back combing, hair curling wand or hair straightener, decolorizer, hair dye, or mechanic aggression. Overuse of heat and chemical treatments leads to hair shaft damage and hair loss, also to an increased tendency to develop traction alopecia [21]. Patients with traction alopecia usually wear their hair in positions which induce prolonged and repetitive tension on the hair (for example pony tails or braids) [6]. The presence of retained hairs along the frontal and/or temporal rim, is called the "fringe sign" and is a useful clinical marker present in both early and late traction alopecia [22].

The evaluation of an alopecic patient should include the **examination of other hair-bearing sites** besides the scalp in order to determine if hair loss is present in: eyebrows, eyelashes, limbs, axillae or pubic area [23]. The examination of the **skin, nails, oral or genital mucous membranes** is also needed (for evidence of associated dermatoses, such as lichen planus) [3, 11, 24].

After a thorough clinical examination in order to evaluate impaired vision, defective hearing, dysmorphic features, clues to autoimmune or metabolic diseases, or ectodermal anomalies, the dermatologist should rule out if the patient has a condition defined by sparse hair (autosomal recessive hypotrichosis—wooly, easily broken hair) or loss of hair (alopecia). Then decide what type of alopecia it is: localized or diffuse, scarring or non-scarring [25].

In order to establish a diagnosis, the doctor will inspect the scalp for inflammation, scaling, erythema, follicular openings, then examine the pattern distribution and determine the hair density, finally study the caliber, fragility, length and shape of hair shaft [2, 23].

3.1. Scalp assessment

For clinical examination, the patient must remove hair pieces, pins, clips, braids, hair extensions and preferably sit on a chair than on the examination table [6]. **Good lighting** is essential, when pictures are taken [6, 11]. The dermatologist must examine the hair and scalp from above, then proceed with a magnifying light or dermatoscope for trichoscopic assessment. A thorough examination requires a serial parting of the hair starting at the center of the scalp, with fingertips, disposable combs or the wooden end of a Q-tip [6].

If during the clinical exam, diminished or absent **follicular ostia** is noticed, a diagnosis of cicatricial alopecia is most likely positive and the detailed history of the patient should be guided in this direction [6]. In patients with darkly pigmented skin, in which it is difficult to appreciate the follicular ostia, it is recommended to perform the skin biopsy.

The area with hair loss must be examined closely to determine whether it is **bare** as “as baby’s bottom” (characteristic of alopecia areata) **or it maintains residual hairs** or fine textured and miniaturized hairs, as in AGA [13, 22].

The **color of the affected scalp** is also important (pink, peach-colored or skin colored, with hypo- or hyperpigmentation, with telangiectasias, with erythema present perifollicular or in patches, etc.).

The scalp must be examined for **signs of atrophy or scaling** (perifollicular or in patches), for **edema, papules, pustules, crusts, follicular hyperkeratosis, ulceration and scarring** [22, 24].

Atrophy, loss of follicular openings and tufted hair are usually present in scarring hair loss (in non-scarring hair loss they are absent), while erythema, scaling or pustules may be present in both types of alopecia. An almost normal scalp skin with a pale, shiny or mildly scarred aspect is present in frontal fibrosing alopecia, a form of lichen planopilaris [19, 21].

Most of the time, patients leave their hair unwashed and uncombed for the doctors’ appointment to show how oily it is or how much hair falls down when combing [5, 11]. In a personal study we have reported that 68% of the patients suffering of female pattern hair loss presented also hyperseborrhea and 7% had seborrheic dermatitis with annoying pruritus [14].

Hyperseborrhea is the hyperactivity of sebaceous glands leading to an excessive production of sebum with immediate symptoms such as itchiness and pain. Hormonal imbalances, metabolic disorders (nutrition and elimination), digestive problems (hepatic and intestinal dysfunctions), nervous factors and stress favor its appearance. Hyperseborrhea may lead to: hair loss, accelerated skin whitening, oily hair, hair blemishes and deterioration, bad-smelling skin, folliculitis, acne, pityriasis steatoides, seborrheic dermatitis [11, 13].

Seborrheic dermatitis is not infectious, but it involves the proliferation of yeast normally present on one’s skin (malassezia yeast being lipophilic, the sebum becomes a source of food). The sebum usually represents a scalp protection barrier with antibacterial and antidehydration property, that moisturizes, protects and waterproofs the hair shaft. Seborrheic dermatitis may non-specifically cause diffuse hair loss as hair follicles find an unsuitable development environment in inflamed skin which will generate a shorter anagen [24].

3.2. Pattern or distribution of hair loss assessment

By analyzing the extent, pattern or distribution of hair loss (focal patchy, patchy all over, diffuse, central, intact frontal hairline, loss of hair in the eyebrows, eyelashes, limbs, axillae, pubic area, etc.) the dermatologist can rule out some diseases in the differential diagnosis process.

3.2.1. Diseases with patterned hair loss

There are some hair loss conditions which seem to affect a certain part of the scalp. For example, **androgenetic alopecia (AGA)** has an early age of onset with an “M shaped” hair thinning over the frontal area and parietal scalp, but conserving a greater density in the occipital scalp [11, 13, 14, 20] (**Figure 1**).

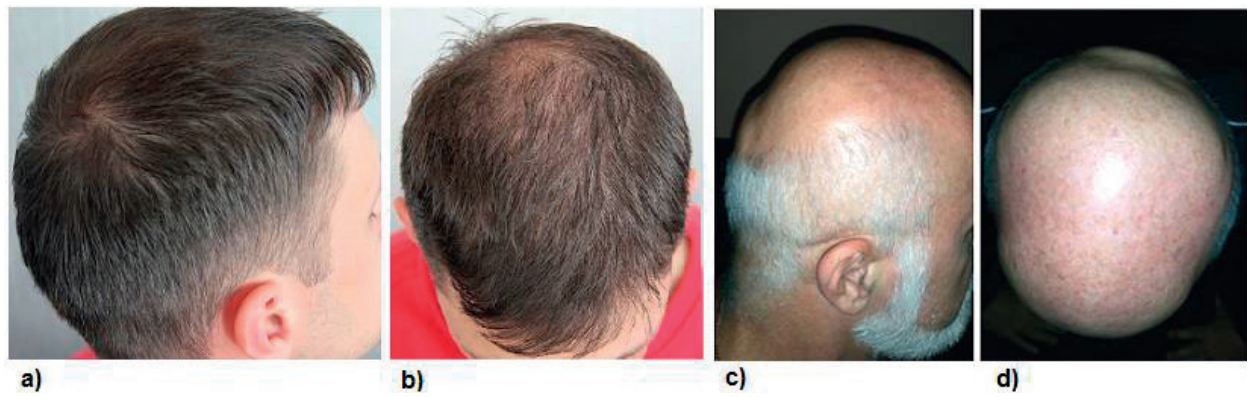


Figure 1. Male pattern suffering of androgenetic alopecia (AGA), grading on Hamilton-Norwood scale: (a) grade II lateral view; (b) grade II view from above scalp; (c) grade VI lateral view; and (d) grade VI view from above.

In the **female pattern hair loss (FPHL)** there is a “Christmas tree” progression of hair loss (central thinning) or it can happen in a diffuse manner, but with the retention of the frontal hairline [3, 16]. Advance thinning occurs in the frontal hairline and above the ears, when markedly elevated circulating androgens are present [5, 26]. The dermatologist must check if clinical signs and symptoms of androgen are present (menstrual irregularities, infertility, hirsutism, severe cystic acne, virilization, galactorrhea) [25]. Common complaints in females might be that the hair does not grow in length any more or that the pony tail is smaller in girth [8]. The clinical diagnosis of AGA and FPHL is supported by the pattern of hair thinning, the presence of miniaturized hairs (increased spacing between hairs, shorter and fine hairs of various lengths and diameters) and usually lack of increased shedding [8, 9, 11] (**Figure 2**).

AGA and FPHL are mostly seen as hair thinning conditions above the ears, sometimes extending posteriorly to the occipital hairline [27]. Another affected area is at the nape of the patients (**back of the scalp**) and possible causes are: the ‘ophiasis’ form of alopecia areata, Frontal fibrosing alopecia with hair loss starting as a band-like distribution around the frontal hairline but also at the sides, just behind the ears, Monilethrix (abnormality in how the hair shaft is produced, leading to hair breakage), overuse of heat and chemical treatments leading to hair shaft damage and hair loss at the nape [20, 21].

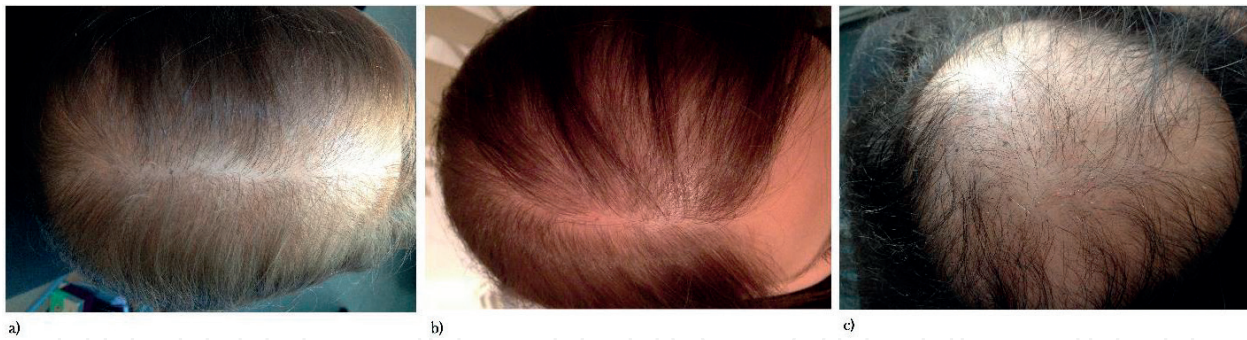


Figure 2. Female pattern hair loss, grading on Ludwig scale: (a) grade I, (b) grade II, and (c) grade III.

The “moth-eaten” pattern of hair loss is the most common type and it is considered to be a pathognomonic manifestation of **secondary syphilis** [28]. Still, in some cases, alopecia can be the only presenting feature of syphilis, without any other clinical feature such as roseola syphilitica, mucous patches, condylomata lata, and ophthalmologic or auditory findings. Differential diagnosis is hard when the hair loss is not just moth-eaten, it is diffuse or both. Syphilitic alopecia can mimic alopecia areata both clinically and histopathologically, with lack of “exclamation point” hairs, characteristic of alopecia areata. Syphilitic alopecia can resemble a noninflammatory *Tinea capitis*, but laboratory testing of scrapings will indicate the presence of fungus. Trichotillomania can also be suspected, but it would be confirmed by history and findings of a biopsy [28].

3.2.2. Diseases with diffuse hair loss

Chronic telogen effluvium (CTE) affects women in the fourth to sixth decade, with a sudden onset (frequently related to physiologic and emotional stress) of marked shedding of telogen hairs (which sometimes is prolonged) from the entire scalp, yet scalp hair density appears normal or minimally decreased. The dermatologist will not see miniaturized follicles at examination [9]. **Anagen effluvium** occurs days to weeks after chemotherapy in 65% of the cases and the hair loss is reversible [11, 13] (**Figure 3**).



Figure 3. Female patient suffering of telogen effluvium: (a) clinical view and (b) patient brought a small plastic bag full of the hair collected during the standardized wash test.

DUPA or diffuse unpatterned alopecia in males is characterized by hair thinning on the top (without progression to complete baldness) and diffuse miniaturization throughout the occipital area also, being a contraindication for hair transplant [23].

Alopecia areata can affect any hair-bearing area, being described as alopecia totalis (scalp hair loss), or universal (loss of all hairs from body and scalp, including eyebrows, eyelashes, etc.) [10].

Induced metabolic disorders lead to diffuse hair loss [11].

The presence of alopecia in infants and children may be due to congenital or acquired causes. Congenital diffuse hair loss could consist of congenital hypotrichosis/atrichia or hair shaft anomalies, such as Nethersons (bamboo hair, atrophy), Menkes (beaded hair) or Monilethrix (wiry hair, pale skin, pili torti). Acquired **diffuse hair loss in children** occurs in history of prolonged illness (telogen effluvium) or exposure to radio/chemotherapy (anagen effluvium). Medical conditions such as thyroid disorders or hyperpituitarism can also cause diffuse hair loss [29, 30].

3.2.3. Diseases with focal hair loss

Alopecia areata most often affects the scalp and is described as acute circumscribed hair loss (80% of the patients having just a single patch). The clinical diagnosis is made by the aspect of hairless patches with a normal skin and preserved follicular ostia [10] (**Figure 4**).

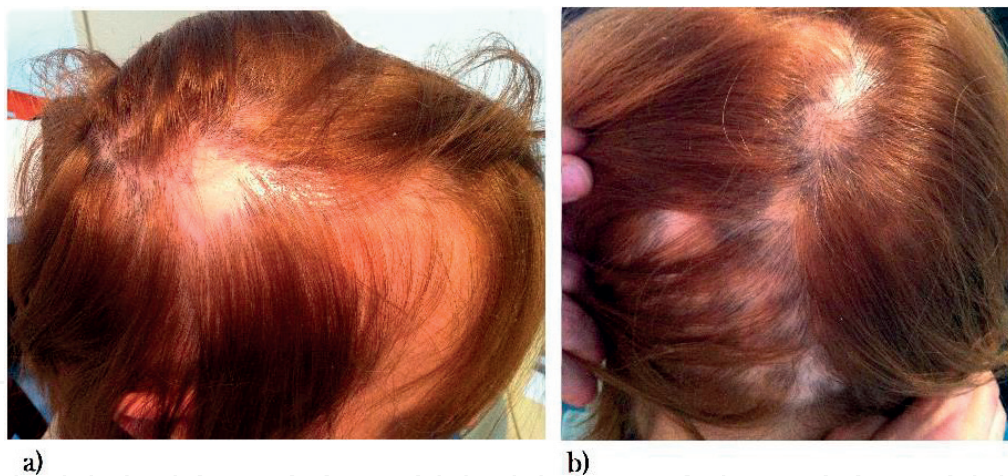


Figure 4. Female patient suffering of alopecia areata (AA), having: (a) a single AA patch and (b) multiple, confluent AA patches.

Tinea capitis represents a dermatophyte infection of the hair shaft and follicles, leading to fragile and easily broken hair [13, 24].

Trichotillomania is a type of alopecia with irregular patches, determined by the patient who twirls or pulls his hair compulsively. Patches occur especially frontoparietal, progressing backward and may include eyelashes and eyebrows, being described as incomplete thinning with stubble [8, 23].

Traction alopecia refers to frontal and temporal loss of hair. Not only some hair styles cause traction alopecia, but also facelifts, due to the tightening and trimming of the skin. The dermatologist must distinguish traction hair loss from hair loss recession due to frontal fibrosing alopecia or alopecia areata [3, 24].

Primary cicatricial alopecias have many subtypes mostly presenting patchy hair loss and some of them cellulitis or folliculitis. The clinical features of **lichen planopilaris** are itchy, multifocal or central patches on scalp and nonscalp areas with follicular hyperkeratosis and perifollicular erythema. **Chronic cutaneous lupus erythematosus** presents single or multifocal patches with intense activity in the patch center, ulceration, follicular plugging, atrophy and depigmentation. **Brocq pseudopelade** consists of small or large irregular patches on the scalp with no detectable symptoms or inflammation, with end-stage burnout. Clinically **folliculitis decalvans** is described as a single patch of complete alopecia on the hair-bearing periphery of the scalp (it expands circumferentially, slowly over the years) and pustules, honey-colored crusting and tufting. **Dissecting cellulitis of the scalp** presents multiple fluctuant nodules across the scalp, interconnected by sinus tracts and sometimes patients also suffer from acne conglobate [6, 29].

The congenital focal **hair loss in infants and children** may be due to traumatic events (birth trauma) or nevoid conditions, such as velvety smooth (nevus sebaceous), warty (epidermal nevus) or absent overlying skin (aplasia cutis). Acquired focal hair loss in children occurs in trichotillomania (with irregularly broken hair due to mechanic repetitive traction performed by the child itself), tinea capitis or ringworm (fungal infection which leads to patchy bald spots with red, flaky scaling, easy pluckability of hairs and cervical lymphadenopathy) or alopecia areata (smooth, round, totally bald areas with the detection of exclamation point hair in trichoscopy and nail pits). Even traction alopecia (from tight ponytails) can result in focal hair loss [30, 31].

3.3. Dermoscopy

Trichoscopy represents the dermoscopy imaging of the scalp and hair. Pigmented patterns must be assessed by dermatoscope with an interface solution, while interfollicular patterns are visualized only with a polarizing light source (or filter) or a videodermoscope, as direct contact can produce bleaching [32–34].

Trichoscopic evaluation of the scalp is based on the observation of follicular patterns (white dots—destroyed follicles that are replaced by fibrous tracts, yellow dots—follicular infundibulum with degenerating keratinocytes and sebum, black dots—stubs of cadaverized hair, fractured before emerging from the scalp), interfollicular patterns (pigment pattern and vascular pattern with interfollicular simple red loops or twisted loops or arborizing red lines) and hair shaft characteristics (specific features in various genetic and inflammatory disorders) [35–37].

The assessment of the scalp must begin with the observation of the follicles presence, suggesting a noncicatricial disease. Afterwards, the examiner must identify if yellow dots are present and if so, focus on the hair diameter.

AGA trichoscopic characteristics are: hair shaft diameter variation of more than 20% hair shaft (miniaturization), peripilar halo in early stages, predominance of follicles bearing single hair, hypertrophy of sebaceous glands [11]. In severe AGA cases trichoscopy shows the presence of empty follicular ostia, brown dots and honeycomb-like pigmented network in bald, sun-exposed areas [38]. The latest reports indicate that although miniaturization of hairs (progressive thinning of hairs) is a specific feature of AGA and FPHL, it is also found in alopecia areata and traction alopecia cases [39].

For FPHL, a study suggests that 2 major criteria (more than 4 yellow dots in a field of view in frontal area/a lower mean hair thickness in frontal area/more than 10% thin hairs <0.03 mm in frontal area) or one major and two minor criteria (ratio of single-hair units, frontal area to occiput $>2:1$ /ratio of vellus hairs frontal area to occiput $>1.5:1$ /ratio of hair follicles with perifollicular discoloration frontal area to occiput $>3:1$) are necessary for a trichoscopic diagnosis with a 98% specificity [40]. Previously, FPHL has been diagnosed on two dermoscopic criteria: more than 20% variability in hair shaft diameter and more than 7 short regrowing hairs in the frontal scalp [11, 41] (**Figure 5**).

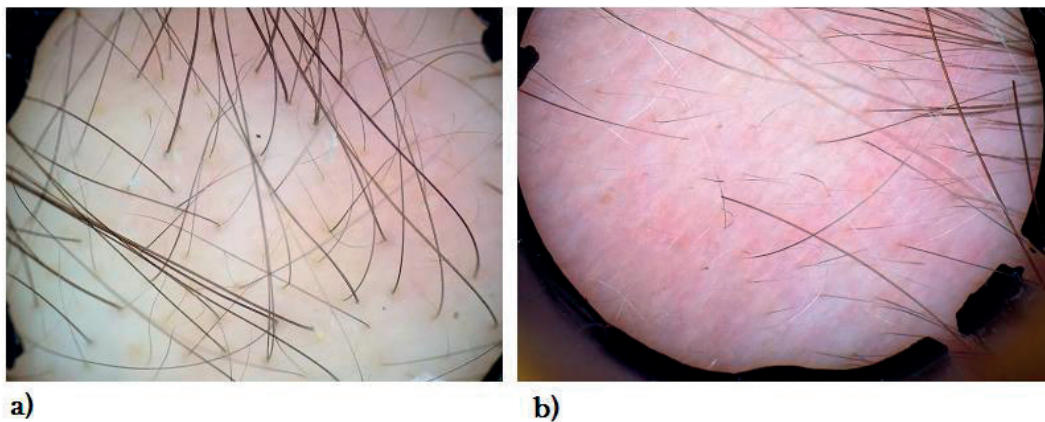


Figure 5. Trichoscopy of (a) AGA patient (hair miniaturization with diameter diversity $>20\%$, thin hair, predominance of follicles bearing single hair, peripilar halo, yellow dots, vellus regrowing hair) b) AA patient (exclamation marks, cadaverized hairs-black dots, yellow dots) (DermLite DL100).

The dermatologist must identify if black dots are present, which is suggestive for AA, trichotillomania or tinea capitis (black dots tinea).

In trichoscopy, AA presents: yellow dots with short vellus hairs or empty follicles, dystrophic and tapered hairs and black dots representing cadaverized broken hairs. The trichogram may show dystrophic fractured and telogen roots [36] (**Figure 6**).

Trichotillomania is usually recognized by: curled hairs with hair shafts of variable length, longitudinal splitting of hair shafts and coiled fractured hair shafts. New trichoscopy findings that seem to be specific features of trichotillomania are: flame hairs, the V-sign, hook hairs, hair powder and tulip hairs [42].

Telogen effluvium is a diagnosis of exclusion as it is described by decreased hair density and presence of empty follicles. It is differentiated from AGA due to the absence of a certain site predilection, hair shaft diameter variation or peripilar halo [32].

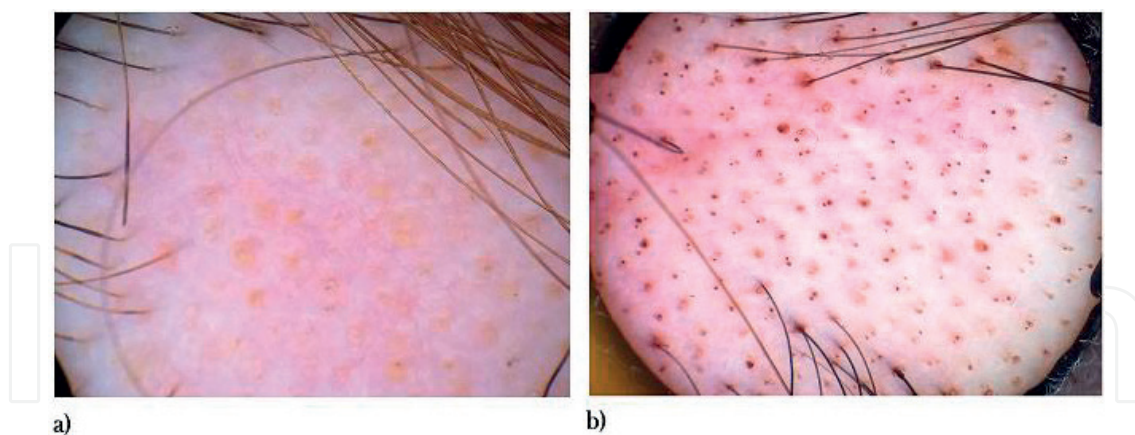


Figure 6. Trichoscopic aspect of (a) chronic AA patient (keratotic plugs in the follicular openings) and (b) hair dye on the scalp surface in an AA female patient (dye is within the follicular openings, simulating interfollicular hyperpigmentation and dots) (DermLite DL100).

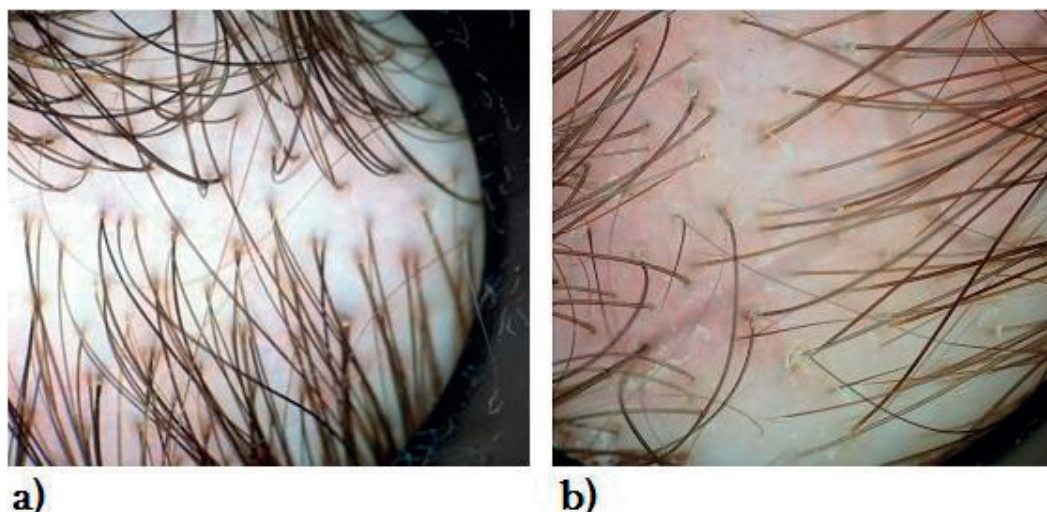


Figure 7. Trichoscopy of: (a) normal scalp, patient without alopecia and (b) patient with lichen planopilaris (peripilar scale, reduced hair density, erythema) (DermLite DL100).

If the trichoscopic assessment of the scalp does not reveal the presence of the follicles, but milky-red or ivory-white areas lacking follicular openings, the dermatologist must think of forms of cicatricial alopecia.

Dissecting cellulitis characteristic findings are: “3D” yellow dots imposed over dystrophic hairs, large, yellow amorphous areas and pinpoint white dots with a whitish halo [7]. Early stages of the disease may mimic AA findings, while the exclamation mark hairs and white dots are markers of disease chronicity [43, 44].

Trichoscopy features in *Tinea capitis* are: comma shaped stubs/hairs, black dots tinea (stub of broken hair shafts with scaling), blotchy pigmentation, erythema, scaling, pustules and follicular scale-crust formation. It has fluorescence in UV examination [32].

Lichen planopilaris (LPP) can be identified by: peripilar casts, target pattern “blue-gray dots”, spared intervening follicles, white dots. Trichogram examination may show anagen roots [45] (Figure 7).

The most characteristic trichoscopy features in Discoid lupus erythematosus (DLE) of the scalp are thick arborizing vessels and large yellow dots, atrophy, complete follicular paucity/plugs, hyperkeratotic scales and dark brown pigmentation. A good prognostic factor of hair regrowth is represented by the presence of Red dots, difficult to be observed in brown skin color patients [46] (Figure 8).

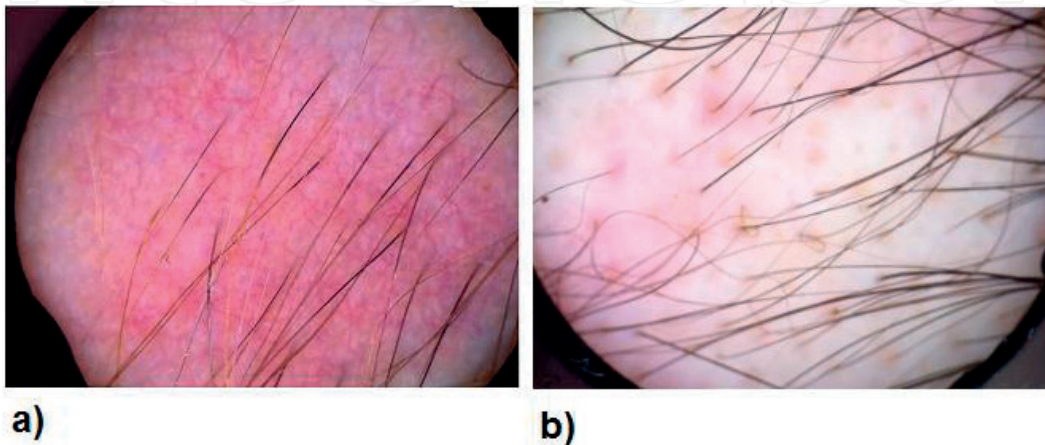


Figure 8. Trichoscopic aspect of (a) discoid lupus erythematosus (arborizing vessels with red lines and dots, large yellow dots) and (b) pigtail hair in an AGA patient (DermLite DL100).

Hair shaft disorders have a particular aspect: beaded shaft in monilethrix, brush fractures in trichorrhexis nodosa, shaft nodes in trichorrhexis invaginata, twisted shafts in pili torti [35, 47, 48].

Advantages of trichoscopy: it represents a handy and reliable tool for establishing a diagnosis, it allows a rapid examination of different areas of the scalp, easy capturing of photographs for documentation and comparison with pre-treatment images [33, 36, 38]. The disadvantages are that the examiner needs to acquire the skill and expertise necessary for a correct interpretation, to take into account the race (trichoscopy of vascular patterns is difficult in darker populations) and the shampooing habits of the patient (yellow dots may not be present in freshly washed scalp) [32, 49].

3.4. Videodermoscopy

Videodermoscopy represents a noninvasive tool for the observation of the scalp skin and hair, being a useful tool in the evaluation of hair loss, both for differential diagnosis and for prognostic evaluation [34, 50].

The videodermoscopy devices have the ability to capture digital images in a high resolution (magnification available up to 1000×) and to store them for later comparison. It is an adjuvant of trichoscopy and a prior step to performing a biopsy, also helping the dermatologist decide which is the right place to take the skin sample from [50].

4. Assessment of severity

4.1. The pull test

The dermatologist should briefly describe the method to the patient and tell him that the hair will be gently pulled several times. The technique will be repeated in different parts of the scalp: at a margin of a hair loss patch (in alopecia areata or trichotillomania) to see if it is active and in an unaffected scalp area to see if there is pendant activity, if the new grown hairs are stable [3, 5]. In diffuse telogen effluvium, androgenetic alopecia and female pattern hair loss, the two sites that are examined are: frontal (2 cm behind the forehead and lateral) and occipital (2 cm lateral from the occipital protuberance) [51].

Using the thumb and forefinger, the dermatologist will grasp a small section of hair (about 60 strands) close to the scalp and gently but firmly slide the fingers away from the scalp at a 90° angle along the entire length of the hair swatch (**Figure 9**). The number of extracted hairs is

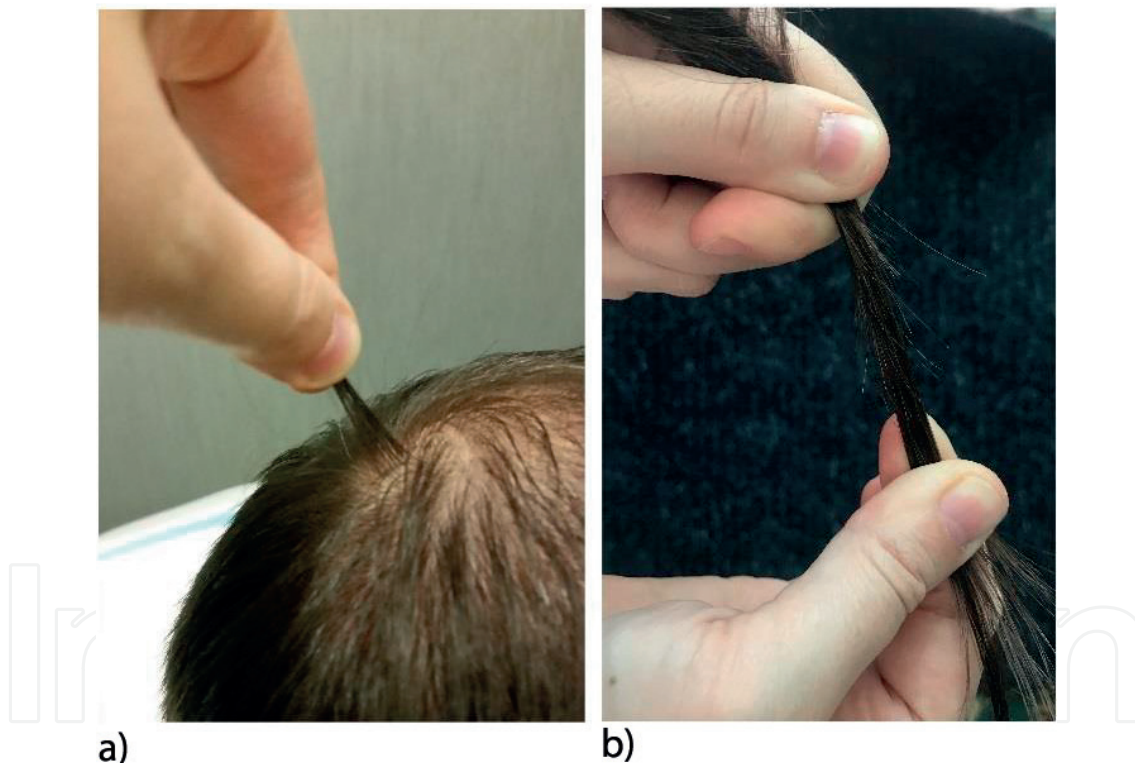


Figure 9. (a) The pull test and (b) the tug test.

counted [11]. If 6 more than 10% of the hair strands fall at the test, it means that the patient has an active hair loss, with one of the following differential diagnosis: telogen effluvium, anagen effluvium, loose anagen syndrome (common in young children), early androgenetic alopecia or female pattern hair loss or advanced alopecia areata. Also, it is important to establish what type of bulb do the extracted hairs present: anagen bulbs or telogen bulbs. Anagen bulb hairs

are not usually pulled easily out of the scalp, but they may be extracted in a pull test in the following situations: active primary cicatricial (scarring) alopecia, loose anagen syndrome or anagen arrest during chemotherapy [6]. An active phase of CTE would show a positive test with 6–8 telogen roots in light microscopy, while a loose anagen syndrome would present a highly positive pull test with anagen hair roots mostly lacking the hair sheath (anagen dysplastic) [37]. In Alopecia areata, after a positive pull test, a light microscopy assessment would show dystrophic anagen and telogen stage. In active AGA, the examiner can find a positive test in vertex and negative in the occipital area. In the active phase of anagen or telogen effluvium an increased number of anagen or anagen dysplastic hairs or normal telogen hairs would fall. Trichotillomania patients have a negative pull test.

The pull test has several disadvantages, being a rough and no standardized method, due to the different pulling strength of each investigator, not uniformly distributed over the hair bundle and variations of density or thickness of hair shafts. Mention should be made that on the day of shampooing, the pull test can be negative, as the telogen hairs have been rinsed away [37]. The pull test is currently performed in clinical practice, but it is useful only if the same examiner performs it in acute phase of hair loss in the more severe conditions for diagnosis and therapeutic follow-up [37].

4.2. Hair part width assessment

Assessment of hair density is important in patients with active hair shedding or thinned hair. Hair part width is a test used for the assessment of hair density in different areas of the scalp: frontal, vertex, occipital, etc. In a scalp area with normal density, the hair parting with a comb discovers a very fine and thin line, while an alopecia area has an irregular line with small clear areas on both sides of the part line (**Figure 10**). The dermatologist must take into consideration the fact that usually, the hair density on the vertex is lower and that thinning increases with age [51].

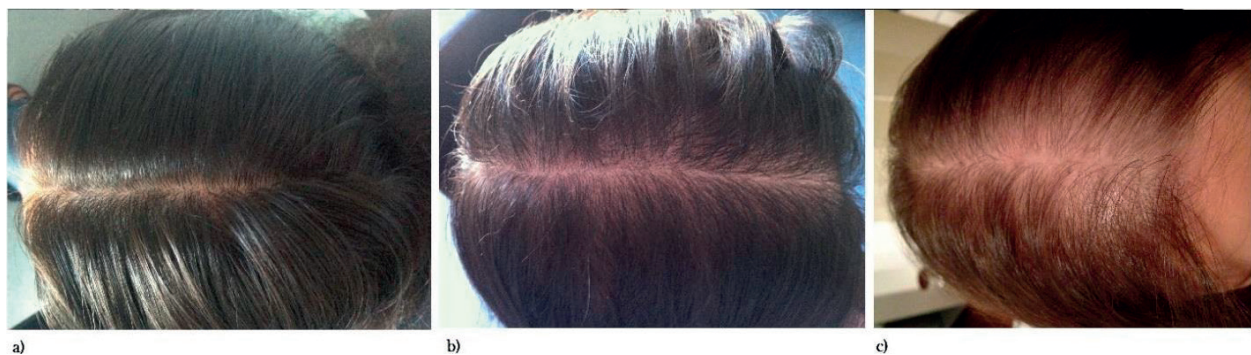

Figure 10. Hair part width assessment in female patients: (a) healthy subject, without alopecia, (b) telogen effluvium subject, and (c) female pattern hair loss grade II on Ludwig scale.

4.3. Counting hair tests

Literature reports that shedding over 100 hairs per day is abnormal, but for the patients with advanced stages (who already lost more than 50% of the hair), around 50% hairs/day

represents increased shedding. Usually when patients loose around 80–100 hairs/day they address the doctor's office. The number of 100 hairs per day (in telogen phase, representing 10% of hairs on the scalp, which could contain up to 100,000 hairs) is taken as an approximate value, it was not validated as a standard reference and it cannot be globally applied to all the patients suffering of alopecia [5, 11, 52].

The number of hairs shed can be misleading in women who do not comb their hair after shampooing and leave it to dry naturally, because when their hands 'comb' through the hair many loose hairs will appear on the fingers [5].

More refined ways of assessing hair loss were needed and dermatologists have developed the following counting hair tests:

Daily hair count is recommended to be performed by the patients who observe intense hair shedding on the brush, comb, pillow, floor, in the washing tub. The patient would collect all the hairs shed during a day and place them in a plastic bag, then handle it to the doctor [4, 5]. The test could provide inaccurate results because numerous hairs usually escape detection and it is disliked by the patients who complain that it is stressful and difficult to perform [2, 4, 5].

The 60 second hair count test consists of the following steps: using the same comb/brush for combing the hair for 60 seconds (over a sheet of contrasting color for easier collection of hairs) from the back top moving to the front of the scalp, repeating the procedure before three consecutive shampooings, counting of hairs from comb/brush plus sheet and recording the value. This procedure must be repeated monthly, for 6 months. The researchers applied this test to 60 men, not previously diagnosed with alopecia and concluded that the similarity between investigator and subject hair counts indicates a reliably hair count technique. The low intra patient variability proved dependable results over a longer period of time. The test seems a simple, practical and objective tool for monitoring conditions associated with hair shedding, but needs to be applied to FPHL patients as well [52].

For the **standardized wash test** patients have to restrain from shampooing for 5 days, then wash the hair in a basin with a gauze (covered drain) that allows the collection of the hairs (**Figure 3**). This non-invasive method involves the counting of hairs, but the results cannot be properly interpreted because a hair loss considered normal can range between 30–70 and 200–250 hairs on shampooing days [4, 37, 43]. The wash test is usually disliked by the patients because it involves a bad self-hygiene and unpleasant hair aspect that could interfere with daily activities [5, 11].

The daily hair count and standardized wash test were not practical methods for monitoring hair shedding, so improved tests were developed [52].

The modified wash-test was developed by Rebora et al. and involves the same technique: washing the patient's hair 5 days after the last shampoo in a sink with covered drain. The collected hair is analyzed by the doctor and separated upon length: under 3 cm (belonging to short telogen vellus hairs), intermediate (between 3 and 5 cm) and long (above 5 cm). The test provides the total number of telogen hairs and the percentage of telogen vellus hairs and makes the difference between FPHL (with increased rate of vellus hairs, around 59%) and telogen effluvium (less than 4%). The test is difficult to apply to patients with very short hair and curly hair [53].

Both washing tests have the following disadvantages: unstandardized method with difficulties because of the shampoo, water, duration, strength of the massage and significantly time-consuming.

4.4. Common scales for staging of hair loss

Staging of hair loss patients is important in assessing the disease severity, to record the progression of alopecia or determine the response to therapy. Various classification systems have been suggested from simple versions based on the recession of the hairline to advanced multifactorial ones, based on morphological and dynamic parameters that affect both the scalp and the hair [54]. Hamilton (1951)-Norwood (1975) classification for males and Ludwig (1997) scale for women are the most commonly used [12, 27, 55] (**Figures 1 and 2**).

An easy to memorize and novel classification for alopecia in both genders is the Basic and Specific classification (2007), which includes the shape of the anterior hairline (basic classification with four types: L, M, C, U) and the hair density on distinct areas such as frontal and vertex (specific classification with two types F and V) [54].

The photographic assessment of hair loss severity developed by Sinclair (2004) (scalp with hair parted in the center), was especially useful in chronic telogen effluvium [54] (**Figure 3**). Recently, Martínez-Velasco et al., issued the hair shedding visual scale, considered a fast and effective method of evaluating hair-shedding amounts in an office setting [41].

5. Photographs of the affected areas

Besides being present in the Sinclair scale (as a classification of the degree of hair loss severity), photographs are used for their general purpose, documentation of alopecia extent or evaluation of treatment efficacy (**Figure 10**).

Photographs should include both close-up views and global views to identify nearby landmarks. Four standard views (vertex, midline, frontal, temporal) should be captured with the same camera, magnification and lighting conditions [56]. The Canfield technique is the most commonly used for alopecic patients and needs the following requirements to be fulfilled: little extraneous information such as distracting clothes or backgrounds, a certain stereotactic position of the device and of the patient's chin and forehead, the same hair preparation each time (the doctor or a technician should perform the same hair parting each time, comb the hair), and the hair should be clean and dry. Oily or wet scalps have increased reflection, revealing more skin than hair, giving the false impression of less hair. In order to record the patient's cosmetic state at each follow-up visit it is recommended that the patient maintains the same hairstyle and hair color in order to decrease the variability of the technique and assure an easy assessment [5, 11]. The serial photographic documentation of hair loss or hair regrowth represents an objective and useful assessment method only if the doctor uses a regimented approach at each photographic session [56]. Up to the present, clinical researchers studying androgenetic alopecia used controlled photography to determine the efficacy of therapy, but this technique should be applied to various types of alopecia [5, 56].

In spite of its advantages, the imaging tests do encounter some problems in female patients, who usually try to hide the hair loss condition by changing the hairstyle (cutting the hair shorter to let the impression of more volume) and the color (dying the hair into brighter shades in order to give the impression of increased density and hide the alopecic areas) [5, 11]. Global photographs can be combined with other evaluation methods, such as: trichogram, phototrichogram, TrichoScan or hair weighting [26, 37, 50].

Recently, photography of alopecic scalps has overpassed its medical use and has become a form of art meant to raise awareness about alopecia areata, in a project by Sigriour Frimannsdottir called Baldwin (meaning strength).

6. Assessment of hair characteristics with different tests

6.1. Trichogram

The trichogram is used for hair root and hair cycle investigation. It is semi-invasive: 60–80 hairs are plucked with a rubber-armed forceps in a quick pull perpendicular to the scalp, in the direction of hair growth. Two areas of interest are investigated in AGA, diffuse effluvium and loose anagen hair: the occipital area (2 cm lateral from protuberans occipitalis) and 2 cm behind the frontal line and 2 cm from the midline respectively. In AA the investigation focuses on the border of the alopecia patch and on the contralateral, unaffected side. After hair collection, the bulbs are placed on a glass slide, in an embedded medium for later examination. Hair roots are investigated under magnification lens or a low-power microscope and the number of hairs in each stage of the hair cycle is provided as percentage of the total number of plucked hairs [57]. Besides being laborious and time-consuming, the technique has another disadvantage: the superfluous remaining hair dyes in furrows mimic hair leading to false results [37].

6.2. Unit area trichogram

The unit area trichogram represents a semi-invasive quantitative method used until now in clinical trials to observe hair growth cycle and monitor different hair growth therapies [57]. It focuses on the main growth parameters: hair follicle density, proportion of anagen fibers, hair shaft diameter. The investigated scalp area is degreased with an acetone:isopropanol (60:40) mixture to remove surface lipids and the hair is plucked from an area of more than 30 mm² with a single smooth action in the direction of hair growth to minimize root trauma. The hairs are mounted on a double-sided tape and ordered by length. By microscopic analysis the investigator will establish the hair growth phase and measure the hair length, the major and minor axis of hair to determine the hair shaft diameter. The disadvantages of the method are: patient discomfort, extended hair regrowth time until obtaining any test results, time consuming, unsuitable for a large number of patients [37, 57].

6.3. The tug test

The tug test is performed when hair fragility and hair shaft abnormalities are suspected [5]. With the fingers of one hand, a section of hair is grasped, holding it near the root while the distal ends or hair tips are plucked (as plucking feathers) [6] (**Figure 9**). The dermatologist tugs to see if the strands break in the middle into small bits. If positive, the test gives information about hair brittleness or fragility [3, 11].

The hair feathering test is usually performed in patients who complain that their hair does not grow or breaks off. The distal 2–3 cm of hairs are rubbed between the thumb and index finger, then a brisk pull is made on the ends of the hairs. A positive test would reveal short broken hair fragments on the examiner's fingers [37]. The next step is the light microscopic inspection of the hair shaft to discover the underlying defect.

6.4. Hair mount

The short segments of hair shaft from the tug test are placed on a clean microscope slide. The examiner must place them parallel to each other. One or two drops of mounting medium such as Permunt or similar, are used on slide and hair, then a cover slip is placed, avoiding the presence of air bubbles. The slide is then examined under a light microscope [6].

6.5. Microscopic evaluation

The following equipment is necessary when assessing the hair: a stereomicroscope with a magnification up to 100× (for the initial examination of mounted and unmounted hairs), a high-quality transmitted light microscope (examine and identify the microscopical characteristics of hairs in a range of 40–400×) or a high-quality transmitted light comparison microscope (for comparing the microscopical characteristics of hairs). For comparison microscopy it is desirable to have a second hair examiner verify the microscopical hair association that may have probative value. Usually hair comparisons are conducted among hairs from the same somatic region, with hairs of similar length, each with a root present or in a similar growth phase as the questioned hair [58].

A polarized light microscope is helpful in order to examine certain features and to determine the cross-sectional shapes of the hairs.

The hair examiner should be familiar with the instruction manual, maintenance requirements, performance and calibration checks and color balance. The hair sample may present adhering material (if considered significant it should be removed and preserved for later analysis) which can be removed by washing or cleaning the hair, then allowing it to dry prior to mounting [58].

Macroscopical and stereomicroscopical examinations enable the description of hair characteristics (color, length, shape, texture, etc.) and the identification of hairs suitable for microscopic comparison or the ones which have roots suitable for DNA analysis [11, 59]. Microscopical examination is helpful to complete the hair wash tests for hair cycle phase differentiation, shaft abnormalities and morphologic appearance of the distal tip [37] (**Figure 11**).




Figure 11. Embedded hair roots under 10× magnification (optical digital microscopy Leica DMD108): (a) catagen hair in a female with telogen effluvium and (b) telogen hair in an AGA patient.

Macroscopical examinations are useful for observing hair characteristics such as color (white, blonde, red, brown, black), hair shaft form (straight, arched, wavy, curly, twisted, tightly coiled, crimped), hair length (in cm) or hair shaft overall thickness (fine, medium, coarse).

Microscopic examination enables the observer to describe the color, natural pigmentation (pigment size, pigment aggregation, aggregate size, pigment density, pigment distribution) or the color treatments performed, such as dyes (permanent, semipermanent, temporary), bleaches or lighteners. Hair characteristics assessment performed by microscope include the shaft description: diameter (in μm), cross-sectional shape (round, oval, triangular, flattened), shaft configurations (buckling, convoluting, shouldering, undulating, splitting, regular), medulla/cuticle/cortex configurations, description of proximal ends with root present (telogen/catagen/anagen/sheathed/follicular tag/ postmortem banding/putrid) or root absent (severed, decomposed, crushed), and description of distal ends (tapered or uncut tips, rounded or abraded, square cut, angular cut, frayed, split, crushed, broken or singed).

Acquired characteristics are also available for analysis and include: artifacts (nits or lice, old, fungal tunnels, insect bite marks, debris or blood), artificial treatments other than color (hair sprays, gels, permanents, cosmetics), environmental/chemical/mechanical damage markers and hair abnormalities (pili annulati, trichoschisis, monilethrix, trichorrhexis nodosa, trichorrhexis invaginati, pili torti, trichonodosis, trichoptilosis) [58, 59].

In pili annulati the hair is stripped, with a pattern of light and dark banding. Trichoschisis represents a sudden shaft break across the diameter of the fiber with the localized absence of the cuticle at the site of fracture. In monilethrix, individual strains of hair have a “beaded appearance”, like the beads of a necklace, presenting a periodic narrowing of the hair shaft [47]. The abnormality in trichorrhexis nodosa is the formation of nodes along the shaft as a response to physical or chemical trauma [37]. Trichorrhexis invaginata (bamboo hair) is due to abnormal keratinization leading to weak hair shaft cortex at specific points along its length. In pili torti, hair has a flattened shaft with clusters of narrow twists at irregular intervals.

Trichonodosis is characterized by knotted hair on the distal portion of the shaft, sometimes due to mechanical factors such as scratching or combing. In trichoptilosis, hairshafts become dry and exhibit splitting or fraying of the hair due to excessive exposure to chemical, thermal or hairdressing procedures [48]. If the hair shaft is apparently normal in microscopy, other tests can be performed, such as: KOH mount or root exam [59].

Besides the presence of the above mentioned genetic hair shaft abnormalities, the individual hairs in an affected area may be notably curly or kinky due to dermal fibrosis and subsequent follicular torsion [6].

Electron microscopy is distinguished by its high spatial resolution in the nanometer range, compared to optical microscopy. Even though it reveals higher details, the pretreatment required of the hair is more extensive and usually leads to artifacts. Another type of microscopy used for hair is atomic force microscopy (AFM), which uses the principles of scanning tunneling microscope and the stylus profilometer in order to provide 3D images with high resolution at the nanometer scale, together with qualitative and quantitative measurements of the sample [37]. AFM is limited to the measurement of the topographic morphology perpendicular to the sample plane (re-entrant surfaces and surface information cannot be detected), so it is not used in clinical practice.

6.6. The contrasting felt examination (hair card test)

The purpose of this test is to evaluate the number of new hair strands that are growing and to examine the health of the hair shafts. Good lighting is essential. The dermatologist creates a part in the hair and uses a small rectangular index card with black felt glue on one side and white felt on the opposite side [5, 11]. The hair card is placed as close to the skin surface as possible and is used on the scalp, brows, eyelashes, etc. Hairs shaft and tips will be held by the doctor against the contrasting black or white background, depending on the color of the hair, for maximal contrast (if dark hair is examined, use the white side) (**Figure 12**). New hair strands, fine short miniature or broken hairs will project up along the edges of the felt card, so that they can be counted and examined [5]. If the distal ends are tapered or pointed (like the ends of the eyelashes) they indicate new hairgrown [6]. If the distal ends are blunt or straight, they may have been broken or cut. If some of the new short hair is thinner in diameter than the rest, it indicates miniaturization [6]. The test is useful in the recognition of very thin strands in telogen effluvium, short vellus hairs (with miniaturization) in AGA and FPHL patients or short strands with broken tips in hair shaft abnormality disorders.

The hair card has a ruler portion which can be used for measuring: the length of new growth, the dimension of hair loss area or the temporal recession [6] (**Figure 12**). Using the ruler side of the hair card, one can measure the distance from the lateral end of the brow to the apex of the temporal recession (in males the normal distance would be 6–6.5 cm) [6].

6.7. Hair weight determination

Hair weight determination involves the selection of a scalp area (usually an area of 1.34 cm² in the frontoparietal region), where the hair is clipped under magnification to a length of 1 mm at

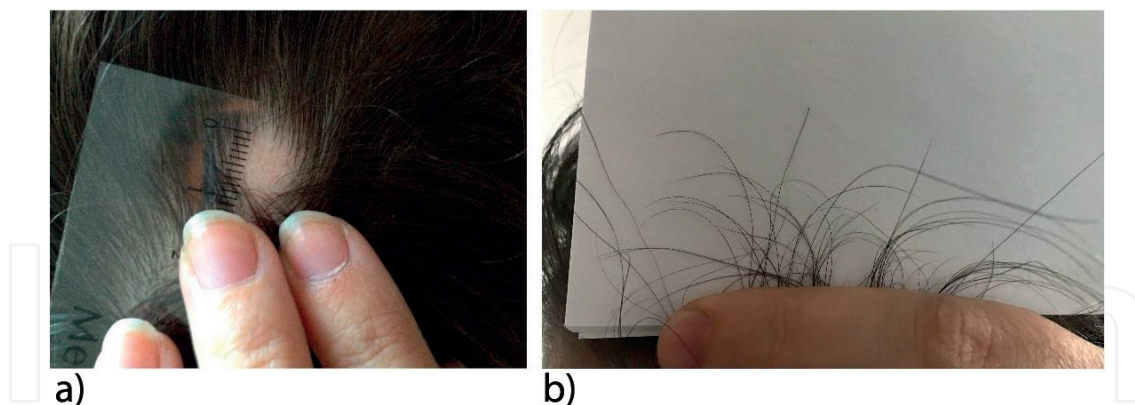


Figure 12. (a) Measurement of AA single patch dimensions using a ruler and (b) the hair card test performed on a telogen effluvium female patient.

baseline, the scalp is permanently marked by tattoos, the hair is allowed to grow for a period of time (from 4 to 24 months, depending on the treatment performed), then clipped again, collected carefully and weighed by an experienced technician [5, 11]. The method is a quantitative one, but unfortunately it is not standardized and precise. It has been used in clinical trials, but was not applied in clinical practice due to its demerits: time consuming, no immediate results are available, no specific scalp areas to be assessed, improper capturing of the hairs, frequent mistakes during the clipping process, incomplete trimming of hairs from that area, unspecified time for regrowth [4, 49]. Also, the method has been rejected by the patients, especially female patients who do not agree to have the hairs clipped/cut from visible scalp areas, such as the frontal area [5].

6.8. Hair densitometry

This determination was classically performed since 1993 with a densitometer: a handheld magnification lens device with an opening of 10 mm^2 , used to check for miniaturization of the hair shaft, to describe the follicular unit composition and to assess the hair density [50]. First, the doctor clips the hair, about 1 mm short, and the instrument is then placed on the scalp. Then the total number of hairs in the field are count, the number of hairs per follicular unit is assessed, as well as the diameter of the hair, looking in particular for abnormal levels of miniaturization (decreased hair shaft diameter) [5].

In practice, hair densitometry is used to evaluate a patient's candidacy for hair transplantation, as it assesses a person's donor hair supply and anticipates the esthetic outcome of the hair restoration procedure [50]. Otherwise, the method is extremely laborious and tiring, less accurate than computed hair analysis.

A modern version for determining hair densitometry is the HairCheck device (Divi International Co., Miami), a cross-section trichometer. This quantitative method enables a precise evaluation, since it indirectly measures the density (n/cm^2) and diameter (μm) of hairs by directly determining the cross-sectional area of all the hairs in a premeasured area of scalp skin [50]. The measurements are performed without cutting the hair, by using an inked four legged device and selecting an area of 4 cm^2 . The hair from that area is gathered with a pinhead tool, then

clipped between fingertips and introduced as a bundle in the J type hook of the measuring device [4, 60]. The HairCheck tool produces a compression of the hair bundle which is engineered to deliver the same predetermined load and the force without damaging the captured hair [60]. On a LED display appears the trichometric index, which represents the height of the compact bundle in its capture chamber, with a value between 75 and 100, expressed as square millimeters of hair per square centimeter of skin $\times 100$ ($\text{mm}^2/\text{cm}^2 \times 100$). Several tests done by Cohen have proved its accuracy and concluded that there was a direct correlation between the bundle's cross-sectional area and the number of surgical silk fibers/filaments, the diameter of the filaments and their dry weight [60, 61]. The HairCheck method is used to quantify by comparison the amount of hair lost or gained and it is extremely helpful as it offers regrowth information by direct assessment of the hair mass (on density and diameter changes) [4]. In one personal study on FPHL, we have successfully used the HairCheck assessment on monitoring the patients' evolution under treatment [5, 11] (**Figure 13**).

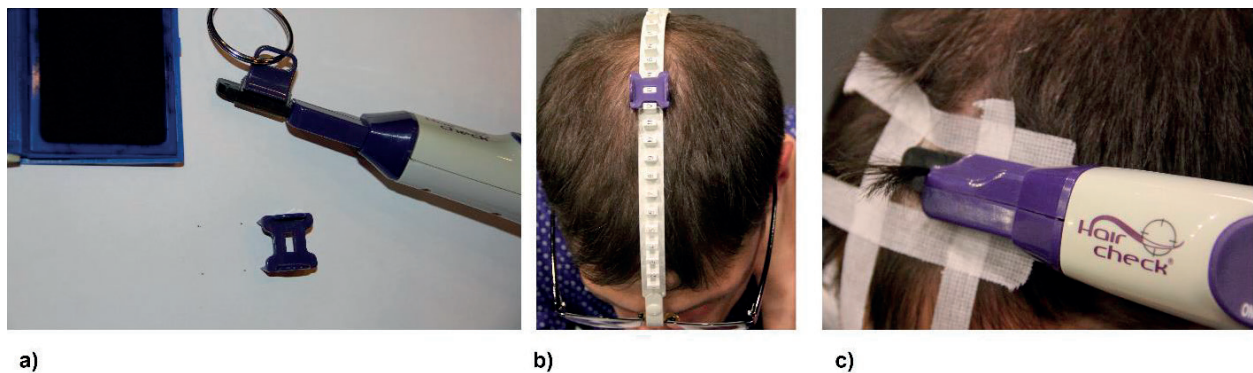


Figure 13. Hair density measurement also known as hair mass index (HMI) with the HairCheck device: (a) pinhead tool (area for measurement), a template with inkpad to demarcate a pre-measured site, calibration tool; (b) a locating strip attached to glasses; and (c) the determination of hair mass by compressing the hair bundle in the J hook of the device.

The HairCheck device offers also the possibility to determine the hair breakage index (HBI) or percentage of broken hairs, which is performed with a proximal and a distal HMI measurement on the same isolated bundle (**Figure 14**).




Figure 14. Hair breakage index (HBI) measured with the HairCheck device (a) at proximal part of the hair bundle and (b) at the distal part of the hair bundle (tip of hair stand).

6.9. Computed hair analysis

Conventional approach to evaluate an alopecic patient implies visual evaluation, which may hinder an objective assessment. For this reason, several researchers tried to develop a quantitative method using a computer-aided imaging system. A study has used a series of digital image processing techniques to measure the width of central balding area of FPHL: the balding area was identified by the computer, which measured the ellipse of balding [26]. The values obtained were significantly correlated with the Savin clinical scale.

A reliable computer-aided imaging system besides staging the severity of the alopecia, could also monitor hair loss and treatment responses.

TrichoScan is a new device, based on epiluminescence microscopy, combined with automatic digital image analysis for the measurement of human hair, focusing of the following 4 parameters: hair density (number per cm^2), hair diameter (μm), hair growth rate (mm per day), and anagen/telogen ratio [54]. The investigator chooses and clips an area of hair loss between normal hair and the balding region. Images are obtained by pressing onto the scalp a digital camera with rigid "contact lens" (so they are taken at the same distance from the scalp) fitted with a close-up microscopy attachment [37].

TrichoScan represents an automated image analysis tool that can determine the surface, miniaturized hair density, terminal hair density, percentage of terminal and miniaturized hair, anagen and telogen percentage. The device is precise and has an intraclass correlation of approximately 97% for different TrichoScan operators. The advantages of the TrichoScan examination make it a useful tool to assess placebo versus treatment, to compare different capacities of hair growth promoting substances, to study AGA and diffuse hair loss, to evaluate the effects of drugs and laser treatment on hypertrichosis and hirsutism [62]. One disadvantage consists of the fact that gray or fair colors have limited contrast with light scalp skin and need to be dyed for 15 min with a solution provided with TrichoScan, that needs to be mixed 1:1 with development cream.

Literature reports underline that computer-aided imaging systems are valuable methods of quantifying hair loss, than can assist the physicians in evaluating the balding area more precisely for clinical staging.

6.10. Optical coherence tomography

Optical coherence tomography is used for measuring hair shaft longitudinal and transverse diameters, cross-section-surface area and hair shape, similar to histology, but in vivo. This procedure uses low-coherence interferometry to produce a two-dimensional image of optical scattering from internal tissue microstructures analogous to ultrasonic pulse-echo image, which works with ultrasound. The results consist of a running time of a near-infrared signal to a studied specimen and back, that will be compared to a known reference signal [37].

6.11. Hair analysis methods

Hair analysis methods are used for the evaluation of genetic disorders, the investigation of physicochemicals properties of hair in disease, the study of exposure to certain substances, etc. Plucked hairs from the temporal area are preferred. The hair should be uncontaminated: a non-exposed part of a growing anagen hair fiber or close to the infundibulum of the hair follicle. The sample of hair is cleaned and put through a number of spectrographic processes capable of identifying as many as 40 trace elements [37].

6.12. Mechanical tests of hair quality (elasticity, strength, fragility)

The evaluation tools for the physical properties of hair focus on the integrity of the internal structure of the fiber and its alteration due to environment, cosmetics or treatments applied. The measurements of mechanical properties are easy to perform and the most common is the tensile property test, which focuses on the stress/strain curve of single hair fibers and is measured with an extensometer. The hair is fixed between two ferrules in a sample cassette of the instrument and a constant speed of extension is exerted until the hair fiber breaks [37].

7. Scalp biopsy

A scalp biopsy is recommended to be taken as soon as the dermatologist suspects cicatricial alopecia [5].

7.1. Scalp biopsy technique and requirements

There are some requirements for the patient, such as refraining from topical steroids usage (Clobetasol, Betamethasone, Fluocinonide, Clobex, Luxiq, etc.) for 1 week prior to the biopsy. On the day of the biopsy the hair should be washed and without any hairspray, gel, mousse or topical camouflaging fibers and agents (Toppik, DermMatch, Couvre, etc.) [21]. Certain lifestyle choices (smoking, excessive drinking) increase the risk of side effects such as bleeding and slow healing [11]. The best position for scalp biopsy harvesting is with the patient sitting down on a chair, leaning over the examination table, bracing their head with their hands, also known as “the Thinker position” [5]. For a biopsy from the occipital scalp, the patient may lie on the examination table facedown or sit on a chair and rest his head down on the evaluation table, “taking a nap on the school desk position” (**Figure 15**).

The doctor should select an active hair-bearing area with an advanced thinning and a preferred positive anagen pull test (more than six hair fall), clean the area and disinfect it with alcohol, iodine or similar solution, sometimes trim a few hairs from the area [9, 21]. Some dermatologists select an area with active inflammatory disease (early thinning with visible erythema and mild scaling), an incipient one, not with end-stage changes of scarring [63]. This type of area is preferable in cicatricial alopecia, in which it is highly recommended to take the biopsy

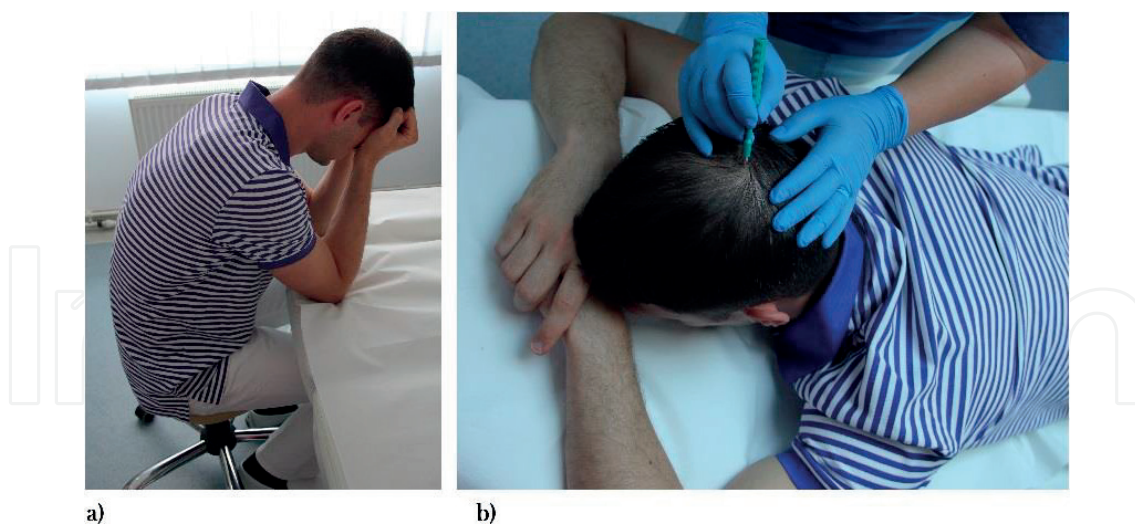


Figure 15. Positioning of the patient for scalp biopsies and injections: (a) sitting on a stool, leaning over the exam table, bracing their forehead “the Thinker position” and (b) patient lying on the examination table facedown.

at the periphery where compounding is not present. Taking biopsy specimens of tuft of hairs (polytrichia or compounding follicles) is not helpful as these nonspecific structures are end-stage features of many cicatricial alopecias, including lichen planopilaris, central centrifugal cicatricial alopecia, also lupus [63].

Local anesthesia is usually performed with 1% lidocaine with epinephrine and the wait time should be 10 min for a maximum vasoconstriction. Hemostasis can be performed with the help of an assistant using gauze squares and Q-tip [5]. Scalp samples can be obtained either by classic surgical collection in an elliptical incision of the skin or by punch biopsy [9]. The most common method is by using a 4 mm-punch biopsy (12.6 mm²) for vertical sectioning or horizontal sectioning [55]. The punch tool is placed on top of the scalp, pressure is applied until the doctor samples down to subcutis and with the help of the needle the excised skin is removed [11]. Some dermatologists consider that both vertical and transverse sections of scalp biopsy specimens are needed. Transverse sections seem to provide a better assessment of the histological features than vertical sections in specimens provided by alopecia areata patients [64]. On the other hand, some dermatopathologists strongly prefer vertical sections, especially in cicatricial alopecias, as they allow the assessment of alopecias associated with interface changes, lichenoid infiltrates and subcutaneous pathology [63]. The vertical sectioning biopsy technique represents a qualitative approach, including just 10% of the hair follicles, and being susceptible to sampling errors. On the other hand, the transverse section is a quantitative approach providing all the hair follicles present in the biopsy, offering data of follicular cycling, as well as morphometric evaluation of the hair follicles throughout their entire length. The transverse biopsy enables the detection of even focal pathology and is preferred in most of the cases of nonscarring alopecia, because of the larger number of follicular structures that can be studied [55].

The dermatologist can close the defect with suture with classic stitches (which should be removed in 10–14 days) or dissolving stitches (which dissolve fully in 6–8 weeks) [11]. In case of punch biopsy, a single stitch is common or some dermatologists leave the wound open [9]. The

next day after the biopsy the washing and shampoo is allowed, usual product used on scalp can be used the day after, while dying and coloring of hair is permitted 1 week after the biopsy [63].

7.2. Scalp biopsy results

Besides sending the biopsy specimen to the dermatopathologist, the dermatologist must provide the patient characteristics (age, race), duration of condition and clinical pattern, and sometimes a photograph is helpful, if available. There are differences in normal hair densities depending on race, also certain racial groups have higher predilections for some diseases [63, 65].

If the biopsy provides a diagnostic, it can offer information about a systemic disease (discoid lupus erythematosus, sarcoidosis, lichen planus follicularis, necrobiosis lipoidica diabetorum, etc.), an infection (fungal, bacterial, protozoan) or even a neoplasm (basal cell carcinoma in the morpheaform, squamous cell carcinoma, metastatic carcinoma in the alopecia neoplastica form, lymphoma or adnexal tumors, etc.). If the biopsy is not diagnostic, the dermatologist should suspect a hereditary disorder or trauma/injury (mechanical trauma, burn, caustic agent, exposure to radiation, etc.) [64].

In **AGA**, the biopsy sample contains increased number of miniaturized hairs, abundant enlarged sebaceous glands and minimal inflammation. A ratio of terminal (T) to vellus (v) ratio 3:1 or less is considered to be diagnostic [63, 64, 65].

Patchy and diffuse alopecia areata present peribulbar lymphocytic infiltrate around anagen hair bulbs, rich in helper T cells, evidence of an autoimmune process. Alopecia areata should be suspected when high percentages of telogen hairs are present, even if the peribulbar infiltrate is not present. Both types of AA may sometimes coexist with Androgenetic alopecia [5, 9, 64].

Histologically in **LPP** the pathologist can find two patterns: hair follicles and the perifollicular dermis mainly involved in the pathologic process (with no involvement of the interfollicular structures) or the pathologic changes extended to the interfollicular epidermis and papillary dermis [55]. Direct immunofluorescence shows the presence of colloid bodies in the peri-infundibular area staining with IgM, while the immunohistochemistry staining shows a significant alteration in the basement membrane structure, which differentiates it from active DLE lesions [66].

The distinctive clinical features of **DLE** of the scalp are the presence of erythema, scaling, telangiectasia, mottled hyperpigmentation within the areas of scarring alopecia and the presence of hyperkeratotic papules in the central part of the bald area in DLE, while in LPP it is present at the margin of the alopecia patch [67]. When routine histological findings are equivocal, direct immunofluorescence (DIF) helps, but light microscopy should be performed before DIF. The suggestive findings are: multiple immunoreactants deposits around hair follicles (not seen in other scarring alopecias) typically IgG and IgM, in a special pattern (bright in intensity, continuous, perifollicular, and granular) [67].

7.3. Scalp biopsy complications

Patients should be aware that a small scar will be present permanently in the area where the biopsy was taken, resulting in a new area with no hair regrowth [9, 19].

As with any medical procedure, there are some possible preoperative, intraoperative and postoperative risks [68]. Preoperative risks can be related to the used anesthetic. Performing of a patch test is recommended if true sensitivity to the anesthesia is suspected, in order to avoid an anaphylaxis, situation which rarely occurs. History of syncopal attacks are important, as a vasovagal attack can be present in this clinical setting [68]. Intraoperative risks involve bleeding, difficulty in closing the skin defect, pain and discomfort caused by insufficient anesthesia [68].

Postoperative risks such as pain, discomfort, bleeding, swelling, tenderness develops, and some of the symptoms can be relieved by medication, prescribed by the dermatologist. Besides scarring and hyperpigmentation, postoperative infection develops in 22% of the cases, but it can be easily treated with antibiotic. Another possible complication consists of temporary numbness or weakness, due to nearby nerve structures damage, which usually represents a nonpermanent situation [68].

8. Laboratory investigations

There are no laboratory tests indicated in AGA male patients who are using topical minoxidil or finasteride [3].

Extensive hormonal testing is not required in female patients, unless symptoms and signs of androgen excess are present (hirsutism, acne, virilization, etc.). The female patients who require endocrine evaluation are identified with careful inquiry regarding: menstrual irregularity, history of infertility, galactorrhea, etc. If positive, laboratory measurement of the following hormones is necessary, in order for the dermatologist to have a clinical evidence of the androgen excess: serum total testosterone, free testosterone, dehydroepiandrosterone sulfate (DHEA-s) and prolactin levels [3, 34]. All the above plus the follicle stimulation hormone (FSH) and luteinizing hormone (LH) are recommended to be performed in FPHL. Habif recommends that testosterone-estradiol-binding globulin (TeBG) should be also tested, in order to obtain the level for the total testosterone/TeBG ratio [17, 26]. If elevated, this androgenic index may indicate a pituitary disease (e.g., pituitary prolactinoma 8).

Tosti considers that 30% of all hair loss is caused by polycystic ovary syndrome PCOS and for diagnostic a pelvic ultrasonography is required [3].

Every patient with hair loss should have the following baseline studies: complete blood count (CBC) and iron study including serum iron and ferritin to rule out iron deficiency [12]. Also, thyroid function tests (free T3, free T4 and TSH) and serum thyroid autoantibody (anti-TG and anti-TPO levels) need to be done to rule out a possible thyroid disease, especially in telogen effluvium [3, 53, 60]. Estimation of blood cadmium (Cd) levels may be important in cases of chronic telogen effluvium as its toxicity can be an underlying hidden cause [69].

Other common causes of hair loss investigated by measurement of different serum levels: serum thyrotropin and vitamin D 25OH (deficient serum levels of the vitamin are present in AA patients and inversely correlate with disease severity) [70]. In AA it is also recommended to test: erythrocyte sedimentation rate (ESR) and rheumatoid factor (RF).

In order not to miss other possible factors, antinuclear antibodies (ANA) test is performed for the diagnostic of systemic lupus erythematosus. Reagin plasma response (RPR or VDRL) test is necessary to rule out syphilis.

In tinea capitis, the following tests are recommended: culture swab, potassium hydroxide (KOH) examination and fluorescence examination with Wood's lamp. In dissecting cellulitis of the scalp discharge is common and should be cultured [12, 60].

If all the laboratory results are normal, the dermatologist can consider:

- Other nutritional deficiency (malnutrition, sprue, zinc deficiency)
- Trauma (Trichotillomania, traction alopecia)
- Hereditary syndromes [8, 57]

Laboratory investigations are not only used as diagnosis tools, but are also necessary in the treatment initialization or evaluation. Systemic medication that inhibits androgen production or its effects (spironolactone, cyproterone acetate, flutamide) represents a second-line treatment in FPHL. For safety purposes, women taking spironolactone should have potassium levels checked prior to therapy [3, 12]. Women taking antiandrogens or oral contraceptives at 3–4 months after the onset of therapy must have the levels of free testosterone and dehydroepiandrosterone (DHEA)-sulfate measured [13, 14].

9. Conclusion

Although dermatologists have a large number of evaluation methods for hair loss and hair regrowth, most of them are not standardized and their applicability is limited in clinical setting. The majority of these evaluation methods are rejected by the patients because they are too invasive, time consuming and difficult to perform or involve a bad hygiene and hair aspect that interferes with daily activities. Taking into consideration all these problems that occur in clinical practice we underline the necessity of more refined and precise evaluation tools for assessing hair loss patients.

Conflict of interest

The authors have no conflict of interest to declare.

Author details

Meda Sandra Orasan^{1*}, Andrei Coneac² and Iulia Ioana Roman³

*Address all correspondence to: meda2002m@yahoo.com

1 Department of Physiopatology, Iuliu Hatieganu University of Medicine and Pharmacy, Cluj-Napoca, Romania

2 Department of Histology, Iuliu Hatieganu University of Medicine and Pharmacy, Cluj-Napoca, Romania

3 Department of Physiology, Iuliu Hatieganu University of Medicine and Pharmacy, Cluj-Napoca, Romania

References

- [1] Piérard GE, Piérard-Franchimont C, Marks R, Elsner P, EEMCO Group (European Expert Group on Efficacy Measurement of Cosmetics and Other Topical Products). EEMCO guidance for the assessment of hair shedding and alopecia. *Skin Pharmacology and Physiology*. 2004 Mar-Apr;**17**(2):98-110
- [2] Chamberlain AJ, Dawber RP. Methods for evaluating hair growth. *The Australasian Journal of Dermatology*. 2003;**44**(1):10-18
- [3] Gordon KA, Tosti A. Alopecia: Evaluation and treatment. *Clinical, Cosmetic and Investigational Dermatology*. 2011;**4**:101-106. DOI: 10.2147/CCID.S10182
- [4] Dhurat R, Saraogi P. Hair evaluation methods: Merits and demerits. *International Journal of Trichology*. 2009;**1**(2):108-119
- [5] Orasan M, Coneac A, Orasan RI. Non-invasive methods of evaluation in female pattern hair loss: Common problems in clinical practice. *Indian Journal of Applied Research*. 2013;**3**(9):12-16
- [6] Price V, Mirmirani P, editors. *Cicatricial Alopecia. An Approach to Diagnosis and Management*. New York: Springer-Verlag; 2011. 104 p. DOI: 10.1007/978-1-4419-8399-2
- [7] Malkud S. Telogen effluvium: A review. *Journal of Clinical and Diagnostic Research*. 2015;**9**(9):WE01-WE03. DOI: 10.7860/JCDR/2015/15219.6492
- [8] Carolyn TC. Alopecia in women. *American Family Physician*. 2003;**67**(5):1007-1014
- [9] Werner B, Mulinari-Brenner F. Clinical and histological challenge in the differential diagnosis of diffuse alopecia: Female androgenetic alopecia, telogen effluvium and alopecia areata—Part II. *Anais Brasileiros de Dermatologia*. 2012;**87**(6):884-890. DOI: 10.1590/S0365-05962012000600010
- [10] Finner AM. Alopecia areata: Clinical presentation, diagnosis, and unusual cases. *Dermatologic Therapy*. 2011;**24**(3):348-354. DOI: 10.1111/j.1529-8019.2011.01413.x

- [11] Orasan MS. Hair and Alopecia. Risoprint: Cluj-Napoca; 2015. 140 p
- [12] Mubki T, Rudnicka L, Olszewska M, Shapiro J. Evaluation and diagnosis of the hair loss patient: Part II. Trichoscopic and laboratory evaluations. *Journal of the American Academy of Dermatology*. 2014;**71**(431):e1
- [13] GoodHeart HP. Photoguide to common skin disorders. In: Diagnostic and Management. Philadelphia, USA: Lippincott Williams&Wilkins; 2009. p. 756
- [14] Adil A, Goldwin M. The effectiveness of treatments for androgenetic alopecia: A systematic review and meta-analysis. *Journal of the American Academy of Dermatology*. 2017;**77**(1):136-141.e5. DOI: 10.1016/j.jaad.2017.02.054
- [15] Camacho-Martínez FM. Hair loss in women. *Seminars in Cutaneous Medicine and Surgery*. 2009;**28**(1):19-32. DOI: 10.1016/j.sder.2009.01.001
- [16] Orăsan MS, Mitrea DR, Coneac A, Mureșan A. The psychosocial consequences of androgenetic alopecia in women and possible risk factors. *Clujul Medical*. 2013;**86**(1):20-26
- [17] Habif T. *Clinical Dermatology*. 6th ed. Philadelphia, USA: Saunders; 2015. 1064 p
- [18] Brzezinski P, Cywinska E, Chiriac A. Report of a rare case of alopecia areata coexisting with trichotillomania. *International Journal of Trichology*. 2016;**8**(1):32-34. DOI: 10.4103/0974-7753.179388
- [19] Pirmez R, Duque-Estrada B, Abraham LS, et al. It's not all traction: The "pseudo-fringe sign" in frontal fibrosing alopecia. *The British Journal of Dermatology*. 2015;**173**(5):1336-1338. DOI: 10.1111/bjd.14005
- [20] Sawant N, Chikhalkar S, Mehta V, Ravi M, Madke B, Khopkar U. Androgenetic alopecia: Quality of life and associated lifestyle patterns. *International Journal of Trichology*. 2010;**2**(2):81-85. DOI: 10.4103/0974-7753.77510
- [21] Donovan Medical. Nape hair loss. Available from: [at: https://donovanmedical.com/hair-blog/nape-hair-loss#sthash.sEI6E4zT.dpuf](https://donovanmedical.com/hair-blog/nape-hair-loss#sthash.sEI6E4zT.dpuf) [Accessed: 2018-02-25]
- [22] Samrao A, Price VH, Zedek D, Mirmirani P. The "fringe sign" – A useful clinical finding in traction alopecia of the marginal hair line. *Dermatology Online Journal*. 2015;**17**(11):1
- [23] Shapiro J, Wiseman M, Lui H. Practical management of hair loss. *Canadian Family Physician*. 2000;**46**:1469-1477
- [24] Rapini RP, Bologna JL, Jorizzo JL. *Dermatology: 2-Volume Set*. St. Louis: Mosby; 2007. p. 2500
- [25] Phillips TG, Slomiany WP, Allison R. Hair loss: Common cause and treatment. *American Family Physician*. 2017;**96**(6):371-378
- [26] Hung PK, Waitao Chu T, Tsai RY, Kung CW, Lin SJ, Chen CM. Quantitative assessment of female pattern hair loss. *Dermatologica Sinica*. 2015;**33**:142-145
- [27] Ramos PM, Miot HA. Female pattern hair loss: A clinical and pathophysiological review. *Anais Brasileiros de Dermatologia*. 2015;**90**(4):529-543. DOI: 10.1590/abd1806-4841.20153370

- [28] Qiao J, Fang H. Moth-eaten alopecia: A sign of secondary syphilis. *Canadian Medical Association Journal*. 2013;**185**(1):61. DOI: 10.1503/cmaj.120229
- [29] Mendiratta V, Jabeen M. Hair loss and its management in children. *Expert Review of Dermatology*. 2011;**6**(6):581-590
- [30] Al-Refu K. Hair loss in children: Common and uncommon causes; clinical and epidemiological study in Jordan. *International Journal of Trichology*. 2013;**5**(4):185-189. DOI: 10.4103/0974-7753.130393
- [31] Filbrandt R, Rufaut N, Jones L, Sinclair R. Primary cicatricial alopecia: Diagnosis and treatment. *Canadian Medical Association Journal*. 2013;**185**(18):1579-1585. DOI: 10.1503/cmaj.111570
- [32] Jain N, Doshi B, Khopkar U. Trichoscopy in alopecias: Diagnosis simplified. *International Journal of Trichology*. 2013;**5**(4):170-178. DOI: 10.4103/0974-7753.130385
- [33] Tosti A. Hair shaft disorders. In: Tosti A, editor. *Dermoscopy of Hair and Scalp: Pathological and Clinical Correlation*. Illustrated ed. USA: CRC Press; 2007. pp. 51-53
- [34] Ross EK, Vincenzi C, Tosti A. Videodermoscopy in the evaluation of hair and scalp disorders. *Journal of the American Academy of Dermatology*. 2006;**55**:799-806
- [35] Rudnicka L, Rakowska A, Kerzeja M, Olszewska M. Hair shafts in trichoscopy: Clues for diagnosis of hair and scalp diseases. *Dermatologic Clinics*. 2013;**31**(4):695-708. DOI: 10.1016/j.det.2013.06.007
- [36] Kharkar V, Khopkar U. Dermoscopy and trichoscopy in diseases of the brown skin. In: *Overview of Trichoscopy*. 1st ed. New Delhi: Jaypee; 2012. pp. 169-181
- [37] Blume-Peytavi U, Whiting DA, Trueb RM. *Hair Growth and Disorders*. Berlin Heidelberg: Springer-Verlag; 2008. p. 564
- [38] Miteva M, Tosti A. Hair and scalp dermatoscopy. *Journal of the American Academy of Dermatology*. 2012 Nov;**67**(5):1040-1048. DOI: 10.1016/j.jaad.2012.02.013
- [39] de Lacharrière O, Deloche C, Misciali C, Piraccini BM, Vincenzi C, Bastien P, et al. Hair diameter diversity: A clinical sign reflecting the follicle miniaturization. *Archives of Dermatology*. 2001;**137**:641-646
- [40] Rakowska A, Slowinska M, Kowalska-Oledzka E, Olszewska M, Rudnicka L. Dermoscopy in female androgenic alopecia: Method standardization and diagnostic criteria. *International Journal of Trichology*. 2009;**1**:123-130
- [41] Martínez-Velasco MA, Vázquez-Herrera NE, Maddy AJ, Asz-Sigall D, Tosti A. The hair shedding visual scale: A quick tool to assess hair loss in women. *Dermatology and Therapy*. 2017;**7**(1):155-165. DOI: 10.1007/s13555-017-0171-8
- [42] Rakowska A, Slowinska M, Olszewska M, Rudnicka L. New trichoscopy findings in trichotillomania: Flame hairs, V-sign, hook hairs, hair powder, tulip hairs. *Acta Dermatovenereologica*. 2014;**94**(3):303-306. DOI: 10.2340/00015555-1674

- [43] Jackson EA. Hair disorders. *Primary Care*. 2000;**27**(2):319-332
- [44] Segurado-Miravalles G, Camacho-Martinez F, Arias-Santiago S, et al. Trichoscopy of dissecting cellulitis of the scalp: Exclamation mark hairs and white dots as markers of disease chronicity. *Journal of the American Academy of Dermatology*. 2016;**75**(6):1267-1268. DOI: 10.1016/j.jaad.2016.08.035
- [45] Baquerizo Nole KL, Nusbaum B, Pinto GM, Miteva M. Lichen planopilaris in the androgenetic alopecia area: A pitfall for hair transplantation. *Skin Appendage Disorders*. 2015;**1**(1):49-53. DOI: 10.1159/000381588
- [46] Tosti A, Torres F, Misciali C, Vincenzi C, Starace M, Miteva M, et al. Follicular red dots: A novel dermoscopic pattern observed in scalp discoid lupus erythematosus. *Archives of Dermatology*. 2009;**145**:1406-1409
- [47] Rakowska A, Slowinska M, Kowalska-Oledzka E, Rudnicka L. Trichoscopy in genetic hair shaft abnormalities. *Journal of Dermatological Case Reports*. 2008 Jul 7;**2**(2):14-20. DOI: 10.3315/jdcr.2008.1009
- [48] Singh G, Miteva M. Prognosis and management of congenital hair shaft disorders with fragility—Part I. *Pediatric Dermatology*. 2016;**33**(5):473-480. DOI: 10.1111/pde.12894
- [49] Olsen EA. Current and novel methods for assessing efficacy of hair growth promoters in pattern hair loss. *Journal of the American Academy of Dermatology*. 2003;**48**:252-253
- [50] Bernstein RM, Rassman WR. Densitometry and video-microscopy. *Hair Transplant Forum International*. 2007;**17**(2):49-51
- [51] Trueb RM. *Female Alopecia: Guide to Successful Management*. Berlin Heidelberg: Springer-Verlag; 2013. 204 p
- [52] Wasko AC, Marckley CL, Sperling LC, Mauger D, Miller JJ. Standardizing the 60-second hair count. *Archives of Dermatology*. 2008;**144**(6):759-762
- [53] Rebora A, Guarrera M, Baldari M, Vecchio F. Distinguishing androgenetic alopecia from chronic telogen effluvium when associated in the same patient. A simple noninvasive method. *Archives of Dermatology*. 2005;**141**:1243-1245
- [54] Gupta M, Mysore V. Classifications of patterned hair loss: A review. *Journal of Cutaneous and Aesthetic Surgery*. 2016;**9**(1):3-12. DOI: 10.4103/0974-2077.178536
- [55] Sinclair R, Jolley D, Mallari R, Magee J. The reliability of horizontally sectioned scalp biopsies in the diagnosis of chronic diffuse telogen hair loss in women. *Journal of the American Academy of Dermatology*. 2004;**51**:189-199
- [56] Canfield D. Photographic documentation of hair growth in androgenetic alopecia. *Dermatologic Clinics*. 1999;**17**(2):261-269. DOI: 10.1016/S0733-8635(05)70085-1
- [57] Blume-Peytavi U, Orfanos CE. Microscopy of the hair—the trichogram. In: Serup J, Jemec GBE, Grove GL, editors. *Handbook of Non-Invasive Methods and the Skin*. 2nd ed. Boca Raton, FL: CRC Press; 2006. pp. 875-881

- [58] Forensic Human Hair Guidelines. Forensic Human Hair Examination Guidelines; Apr 2005. Available from: https://www.nist.gov/sites/default/files/documents/2016/09/22/forensic_human_hair_examination_guidelines.pdf [Accessed: 2018-03-02]
- [59] Adya KA, Inamadar AC, Palit A, Shivanna R, Deshmukh NS. Light microscopy of the hair: A simple tool to “untangle” hair disorders. *International Journal of Trichology*. 2011;**3**(1):46-56. DOI: 10.4103/0974-7753.82124
- [60] Cohen BH. The cross-section trichometer: A new device for measuring hair quantity, hair loss and hair growth. *Dermatologic Surgery*. 2008;**34**(7):900-910
- [61] Wikramanayake TC, Mauro LM, Tabas IA, Chen AL, Llanes IC, Jimenez JJ. Cross-section trichometry: A clinical tool for assessing the progression and treatment response of alopecia. *International Journal of Trichology*. 2012;**4**(4):259-264. DOI: 10.4103/0974-7753.111221
- [62] Hoffmann R. TrichoScan: A novel tool for the analysis of hair growth in vivo. *The Journal of Investigative Dermatology. Symposium Proceedings*. 2003;**8**(1):109-115
- [63] Keller DM. Biopsy scalp area for alopecia diagnosis. Available from: <https://www.mdedge.com/edermatologynews/article/115124/dermatology/biopsy-scalp-area-alopecia-diagnosis>. [Accessed: 2018-03-05]
- [64] Singh K, Sharma S, Singh UR, Bhattacharya SN. A comparison of vertical and transverse sections in the histological diagnosis of alopecia areata scalp biopsy specimens. *International Journal of Trichology*. 2016;**8**(3):111-115. DOI: 10.4103/0974-7753.188964
- [65] Al-Refu K. Scalp biopsy and diagnosis of common hair problems. In: Suran LF, editor. *Skin Biopsy-Diagnosis and Treatment*. Croatia: InTech; 2013. 184p. DOI: 10.5772/46018
- [66] Al-refu K, Goodfield M. Basement membrane changes in lichen planopilaris. *Journal of the European Academy of Dermatology*. 2009;**23**(11):1289-1293
- [67] Costner MI, Sontheimer RD. Skin manifestations of rheumatologic multisystem diseases: Lupus erythematosus. In: Freedberg IM et al., editors. *Fitzpatrick’s Dermatology in General Medicine*. 6th ed. New York : McGraw-Hill, Medical Pub. Division. 2003. pp. 1677-1776
- [68] Scalp biopsies: everything you need to know to diagnose hair loss. Hairloss Revolution. Available at: <https://www.hairlossrevolution.com/scalp-biopsies/>. [Accessed: 2018-02-24]
- [69] Abdel Aziz AM, Sh Hamed S, Gaballah MA. Possible relationship between chronic telogen effluvium and changes in lead, cadmium, zinc, and iron total blood levels in females: A case-control study. *International Journal of Trichology*. 2015;**7**(3):100-106. DOI: 10.4103/0974-7753.167465
- [70] Aksu Cerman A, Sarikaya Solak A, Kivanc AI. Vitamin D deficiency in alopecia areata. *The British Journal of Dermatology*. 2014;**170**(6):1299-1304. DOI: 10.1111/bjd.12980