

# We are IntechOpen, the world's leading publisher of Open Access books Built by scientists, for scientists

4,800

Open access books available

122,000

International authors and editors

135M

Downloads

Our authors are among the

154

Countries delivered to

TOP 1%

most cited scientists

12.2%

Contributors from top 500 universities



WEB OF SCIENCE™

Selection of our books indexed in the Book Citation Index  
in Web of Science™ Core Collection (BKCI)

Interested in publishing with us?  
Contact [book.department@intechopen.com](mailto:book.department@intechopen.com)

Numbers displayed above are based on latest data collected.  
For more information visit [www.intechopen.com](http://www.intechopen.com)



---

# The Permanent Maxillary and Mandibular Premolar Teeth

---

Işıl Çekiç Nagaş, Ferhan Eğılmez and  
Bağdagül Helvacioğlu Kivanç

Additional information is available at the end of the chapter

<http://dx.doi.org/10.5772/intechopen.79464>

---

## Abstract

The permanent premolar teeth are placed between the anterior teeth and molars. Eight premolars are found in the permanent dentition, four per arch and two in each quadrant. The main function of premolars is to assist the canines in regard to tear and pierce the food and supplement the grinding of the molars during mastication. The other functions are to support the corners of the mouth reinforce esthetics during smiling and maintain the vertical dimension. Detailed morphology of the permanent premolar teeth is narrated in a pointwise and systematic manner in this chapter.

**Keywords:** teeth, premolars, dental anatomy

---

## 1. Introduction

The premolars develop from four lobes with the exception of the mandibular second premolar which develops from five lobes. The facial surfaces of the premolars develop from three facial lobes like anterior teeth. Likewise, the lingual surfaces of most premolars develop from one lingual lobe like anterior teeth. While mandibular first premolars develop from four lobes (mesial, distal, buccal, and lingual) just like the anterior teeth and maxillary premolars, mandibular second premolars often develop from five lobes (mesial, buccal, distal, mesiolingual, and distolingual lobes). That is why the term “bicuspid” signifies “two cusps,” widely used to describe premolars, may be inappropriate for this group of teeth since the mandibular premolars may show a variation in the number of cusps from one to three. In anterior teeth, the lingual lobe forms the cingulum of the incisors and canines. However, in premolar teeth, this lobe forms the lingual cusps. The lingual cusps of mandibular premolars are less prominent

---

than the buccal cusps. There are no deciduous premolars. These teeth erupt at the position previously occupied by the deciduous molars.

Timing of teeth eruption can be affected by many factors such as gender, environmental factors and genetic conditions and differs from population to population [1–3]. The agenesis of lower second premolars and maxillary lateral incisors are the most frequent and it could be radiographically documented if the median age of emergence of these teeth was passed [1]. On the other hand, caries in primary molar teeth or early extraction of second primary molar could accelerate the eruption time of permanent premolars [1]. The classic sequences of teeth eruption in the maxillae is as follows: first molar, central incisor, lateral incisor, first premolar, canine, second premolar and second molar whereas in the mandible, central incisor, first molar, lateral incisor, canine, first premolar, second premolar and second molar [2]. In addition, generally, in girls, the maxillary canine can be expected before the second premolar, and the mandibular second premolar can be expected before second molar; in boys both orders are reversed [3].

The detailed descriptions of morphologies of from all aspects, chronology of development, form and function, the common characteristics of the permanent premolar teeth were presented in this chapter. In addition, the major differences between these teeth were given in a pointwise and systematic manner [4–11].

## 2. The permanent maxillary premolars

### 2.1. Permanent maxillary first premolars

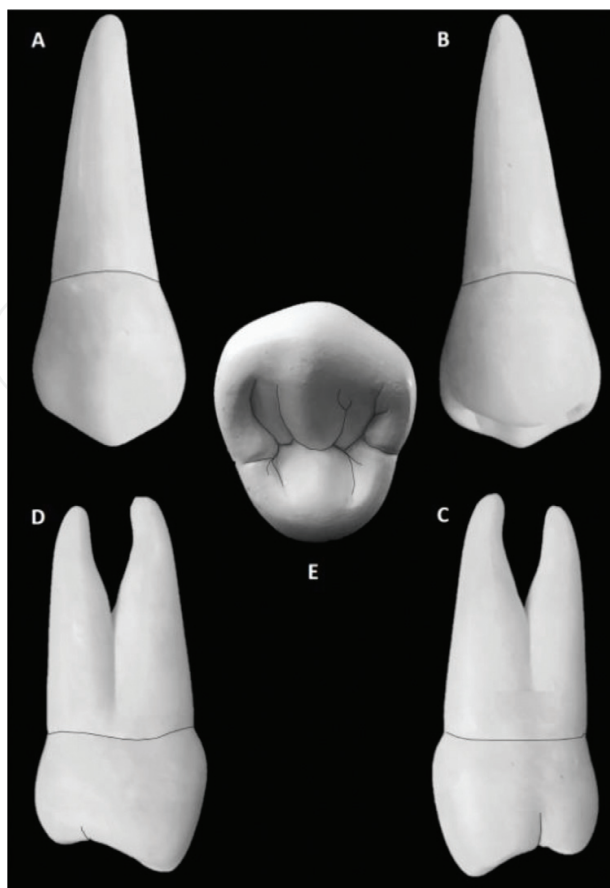
The maxillary first premolar is the fourth permanent tooth from the median line in the maxillary arch, located laterally from both the maxillary canines of the mouth but mesial from both maxillary second premolars. It is the first posterior tooth. Chronologic development of the maxillary first premolar is given in **Table 1**.

In the universal system of notation, the right permanent maxillary first premolar is shown as “#5,” and the left one is shown as “#12.” According to the international notation, the right permanent maxillary first premolar is shown as “14,” and the left one is shown as “24.” Besides, in the Palmer notation, the right permanent maxillary first premolar is symbolized as “4,” the left one is symbolized as “4.”

The image of maxillary first premolar from all aspects is seen in **Figure 1**. A. Buccal, B. Lingual, C. Mesial, D. Distal, E. Occlusal.

Development stage	Years
Initiation of calcification	1 ½–1 ¾ years
Enamel completion	5–6 years
Eruption	10–11 years
Root completion	12–13 years

**Table 1.** Chronologic development of the maxillary first premolar teeth.



**Figure 1.** Maxillary first premolar tooth from different aspects. A. Buccal, B. Lingual, C. Mesial, D. Distal, E. Occlusal.

The buccolingual dimension is higher than the mesiodistal dimension. The buccal, lingual, and distal surfaces of the crown display convexities in different degrees.

### 2.1.1. Buccal aspect

The pentagonal or trapezoidal shape of the crown is noticeable from the facial aspect. With this form of the crown, the permanent maxillary first premolar appears to be similar to those of the maxillary canine and second premolar. While the canine has a larger size crown with a more prominent cusp tip, the second premolar has a smaller crown with a less prominent cusp tip. Additionally, the crown is smaller in the cervico-occlusal dimension than any anterior tooth, but larger than that of the second premolar or permanent molars. The greatest mesiodistal width of the crown is about 2 mm less at the cervical region.

The buccal surface is convex with the exception of the developmental depressions. The well-developed middle buccal lobe forms a continuous ridge from the tip of the buccal cusp to the cervical margin. This ridge is called as “buccal ridge” and demarcates the three developmental lobes. Mesiobuccal and distobuccal developmental depressions exist on both mesial and distal sides of the buccal ridge. These depressions divide the occlusal portion of the buccal surface into vertical thirds, consisting of mesiobuccal, distobuccal, and buccal lobes. Mesiobuccal and distobuccal lobes serve to emphasize strong mesiobuccal and distobuccal line angles on the crown. The imbrication lines are in parallel and semicircular forms and also common in the cervical third of the buccal surface.

From this aspect, cervical line of the crown is convex. In addition, the curvature depth is less at the cervical margin of the crown than those of anterior teeth. The crest curvature of the cervical line is almost placed at the center of the root.

The mesial contour of the crown presents a shallow concavity extending from the cementoenamel junction to the mesial contact area. The highest contour of mesial curvature is at the contact area and located near the junction of the occlusal and middle thirds. The mesial margin of the buccal cusp is lying from the contact area to the tip of the buccal cusp and it creates the mesio-occlusal angle. This margin is less curved and longer than the distal slope of the buccal cusp.

The buccal cusp tip is placed slightly toward the distal. Therefore, unequal two portions are seen at the buccal aspect of the crown of occlusal outlines. A concavity or notch may be observed as a result of the developmental depressions passing over the occlusal margin.

The distal contour of the crown presents more concave and straighter form below the cementoenamel junction than that of mesial contour. The crest curvature of the distal contact area is located slightly more occlusally.

### *2.1.2. Lingual aspect*

The tooth is narrower mesiodistally at the lingual than at the buccal. Therefore, the crown converges toward the lingual cusp. The lingual ridge is barely defined. Both the buccal and lingual cusp tips are visible from this aspect, since the lingual cusp is shorter than the buccal cusp. The lingual cusp of the maxillary first premolar is the shortest of the four maxillary premolar cusps.

The lingual portion of the crown is convex and has a spheroidal form. The cervical line at this aspect is regular, with symmetrical curvature toward the root and the crest of curvature is centered on the root. The proximal outlines of the crown at the lingual aspect are convex. These outlines are convex and continuous with the mesial and distal slopes of the lingual cusp. If the tooth presents the severe mesial concavity, the mesial outline may be concave.

The lingual cusp tip is situated well anterior (mesial) to the mid-buccolingual diameter of the crown, so the two cusp tips are not placed on the same axis. This cusp tip is not as sharply pointed as the buccal cusp tip. The mesio-occlusal slope of the lingual cusp is shorter than the disto-occlusal slope.

The developmental depressions, grooves, or pits are normally not found on the lingual surface.

### *2.1.3. Mesial aspect*

From the proximal aspects, all maxillary posterior teeth are present in trapezoidal geometric form. The buccal cusp is longer than the lingual cusp by 1 mm or occasionally more. Well-marked mesial and distal ridges are seen in both cusps. The mesial surface of the crown displays a concavity toward the cementoenamel junction. This concavity extends cervically on the mesial surface and joins a deep developmental depression of the root area. This mesial developmental depression is sometimes called "the canine fossa" and located cervically to the mesial contact area. There is a groove called "mesial marginal groove," that is usually present on the mesial

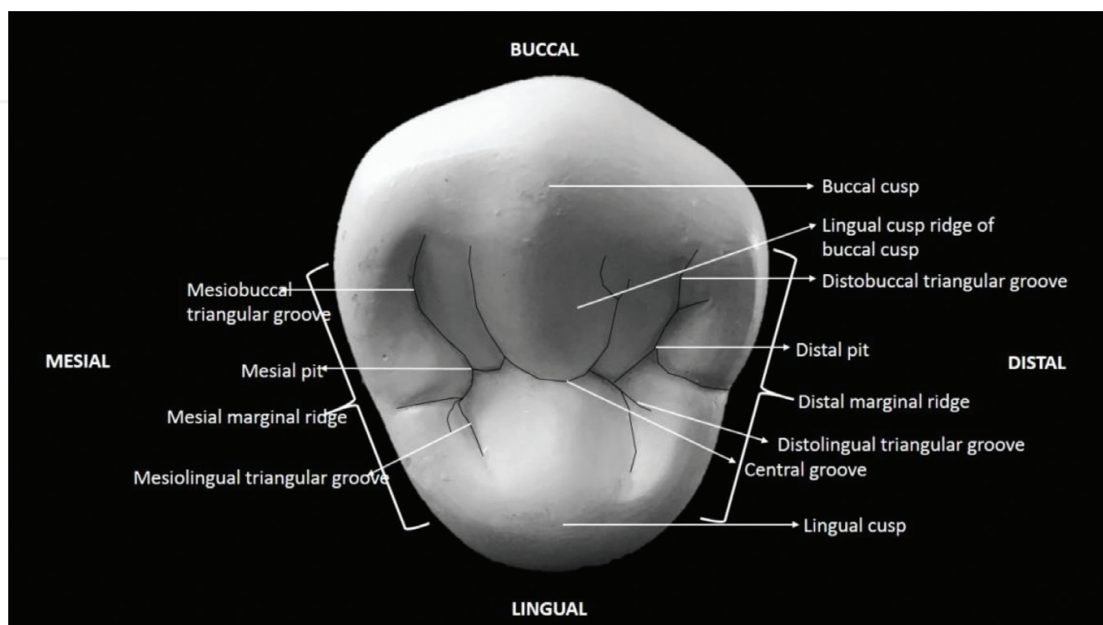
surface of the crown. This groove extends across the mesial marginal ridge from the occlusal surface. Mesial developmental depression and mesial marginal groove are the specific landmarks of maxillary first premolars that help to distinguish the maxillary first premolar tooth from the maxillary second premolar. The facial contour of the crown is convex with the height of contour located at the junction of cervical and middle third. The lingual contour is also convex form of an even arc, with its crest of contour located within the middle third of the crown. The occlusal margin is formed by the mesial marginal ridge. This margin is slightly concave.

#### 2.1.4. Distal aspect

From the distal aspect, a maxillary first premolar tooth is remarkably similar to the mesial view, except this side of the crown is slightly shorter occlusocervically. There are also other differences including the general convexity of the distal surface at all directions. This surface does not exhibit the concavity, which is present on the mesial surface. However, there may sometimes be a flattening in the cervical of the contact area and buccal of the center of the distal surface. Moreover, the curvature of cervical line is occlusally less on the distal than on the mesial. The buccal outline is convex. Buccal crest curvature is in the gingival third. The lingual outline is symmetrically convex with the lingual crest curvature that is in the middle third. The distal marginal ridge is located at a more cervical level. There is normally no deep developmental groove crossing the distal marginal ridge. In the rare instances when it is present, it is shallow and insignificant.

#### 2.1.5. Occlusal aspect

The schematic description of the occlusal table is given in **Figure 2**. From the occlusal aspect, the maxillary first premolar can be described as hexagonal or six-sided figure. This form is made up of the mesiobuccal, mesial, mesiolingual, distolingual, distal, and distobuccal sides.



**Figure 2.** The schematic description of the occlusal table of the maxillary first premolar tooth.



The crown is wider buccolingually than mesiodistally. In addition, the mesiobuccal and distobuccal sides are almost equal, whereas the mesial side is shorter than the distal side, and the mesiolingual side is shorter than the distolingual side.

The outline of the crown at the buccal surface is generally convex. The prominent buccal ridge contributes to this convexity. However, when the buccal developmental depressions are deep, they may create slight concavities in the outline on the mesiobuccal and distobuccal sides of the buccal ridge.

The lingual outline is almost equally convex in semicircular arch form. Mesial and distal margins are relatively straight, and they converge toward the lingual. If the mesial marginal groove is prominent, a dip might be seen in the mesial outline of the crown.

#### 2.1.5.1. Occlusal table components

The cusp ridges and marginal ridges limit the occlusal surface of the maxillary first premolar. Two cusps (buccal and lingual) are placed at the occlusal table. The buccal cusp is generally sharper, longer, and wider than the lingual cusp. On the buccal cusp, the buccal ridge descends from the cusp tip cervically to the buccal surface. The mesial and distal ridges descend from the cusp tip to their respective point angles. The buccal cusp has four inclined planes. These planes are called as mesiobuccal inclined plane, distobuccal inclined plane, mesiolingual inclined plane, and distolingual inclined plane. During the active occlusion, the lingual inclines of the buccal cusps of the maxillary posterior teeth determine the path of the supporting cusps during normal lateral and protrusive working excursions.

The lingual cusp is generally smaller than the buccal cusp. The lingual cusp tip is offset toward the mesial. The lingual cusp ridge extends from the cusp tip lingually to the central area of the occlusal surface. This cusp also presents four cusp ridges and four inclined planes located and named in the same manner as those of the buccal cusp.

The crest of the distal contact area is somewhat buccal to that of the mesial contact area, and the crest of the buccal ridge is somewhat distal to that of the lingual ridge. The crests of curvature represent the highest points on the buccal and lingual ridges and the mesial and distal contact areas. When two triangular ridges join, after traversing the tooth buccolingually, they form a “*transverse ridge*.” The union of the two triangular ridges forms this transverse ridge. In other words, the lingual cusp ridge of the buccal cusp and the buccal cusp ridge of the lingual cusp form the transverse ridge of the occlusal surface.

From the occlusal aspect, close observation reveals that the mesiodistal dimension of the crown is narrower than the buccolingual dimension. The major structures, pits, and grooves are the primary anatomic features. The supplemental grooves are not present in most cases on the occlusal surface of maxillary first premolar teeth. For this reason, the occlusal surface is relatively smooth. A well-defined “*central developmental groove*” divides the surface buccolingually. A “*mesial marginal developmental groove*” extends from the central developmental groove and crosses the mesial marginal ridge and ends on the mesial surface of the crown.

Two developmental grooves connect to the central groove inside the mesial and distal marginal ridges. These grooves are the “*mesiobuccal developmental groove*” and the “*distobuccal developmental*

groove." The connections of the grooves are located at opposite ends of the central developmental groove, and deeply pointed. These grooves usually end in a deep depression in the occlusal surface called the "mesial" and "distal developmental pits."

The triangular depression that harbors the mesiobuccal developmental groove is located just distal to the mesial marginal ridge and called the "mesial triangular fossa." Likewise, the depression in the occlusal surface, just mesial to the distal marginal ridge, is called the "distal triangular fossa."

### 2.1.6. Root

Root contour form of the maxillary first premolar from the buccal aspect still bears a close resemblance to the maxillary canine. However, it is about 3–4 mm shorter than maxillary canine. The maxillary first premolar tooth with two roots presents a smooth and convex lingual root with a blunter root apex than the buccal root apex. The root trunk is flattened at this aspect above the cervical line. The bifurcation of the roots is located near the apical third, with no developmental groove.

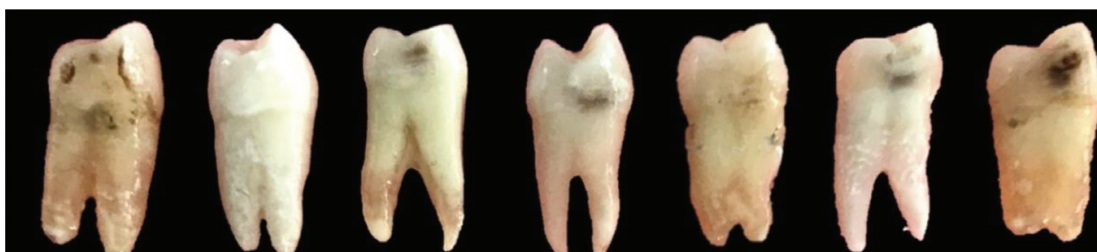The average measurements of the maxillary first premolar are shown in **Table 2**.

The average measurements of the maxillary first premolar (in mm)							
Cervico-occlusal length of crown	Length of root	Mesiodistal diameter of crown	Mesiodistal diameter of crown at cervix	Buccolingual diameter of crown	Buccolingual diameter of crown at cervix	Curvature of cervical line-mesial	Curvature of cervical line-distal
8.5	14.0	7.0	5.0	9.0	8.0	1.0	0.0

**Table 2.** The average measurements of the maxillary first premolar teeth. Variations: The crown and root of this tooth exhibit some variations (**Figure 3**).

## 2.2. Permanent maxillary second premolars

The permanent maxillary second premolar is the fifth tooth from the midline. The maxillary second premolars closely resemble the maxillary first premolar and supplement the latter in function. The maxillary second premolar tooth shares a mesial contact with the maxillary first premolar and a distal contact with the maxillary first molar. This tooth is a succedaneous tooth, replacing the deciduous maxillary second molar. Chronologic development of the maxillary second premolar is given in **Table 3**.



**Figure 3.** The crown and root variations of the maxillary first premolar teeth.



Development stage	Years
Initiation of calcification	2
Enamel completion	6–7
Eruption	10–12
Root completion	12–14

**Table 3.** Chronologic development of the maxillary second premolar teeth.

In the universal system of notation, the right permanent maxillary first premolar is shown as “#4,” and the left one is shown as “#13.” According to the international notation, the right permanent maxillary first premolar is shown as “15,” and the left one is shown as “25.” Besides, in the Palmer notation, the right permanent maxillary first premolar is symbolized as “ $\underline{5}$ ” while the left one is symbolized as “ $\underline{5}$ .”

The crown of the maxillary second premolar has a less angular appearance, giving a more rounded effect than the maxillary first premolar. In addition, the crown is usually smaller in cervico-occlusal and mesiodistal dimensions. It has two cusps of nearly same size. The second premolars also vary from the first premolars in that they generally have single root. Usually, the root length of the maxillary second premolar is almost similar with that of the first premolar. More variations are observed with second premolar teeth.

The image of maxillary second premolar from all aspects is seen in **Figure 4**; A. Buccal, B. Lingual, C. Mesial, D. Distal, E. Occlusal.

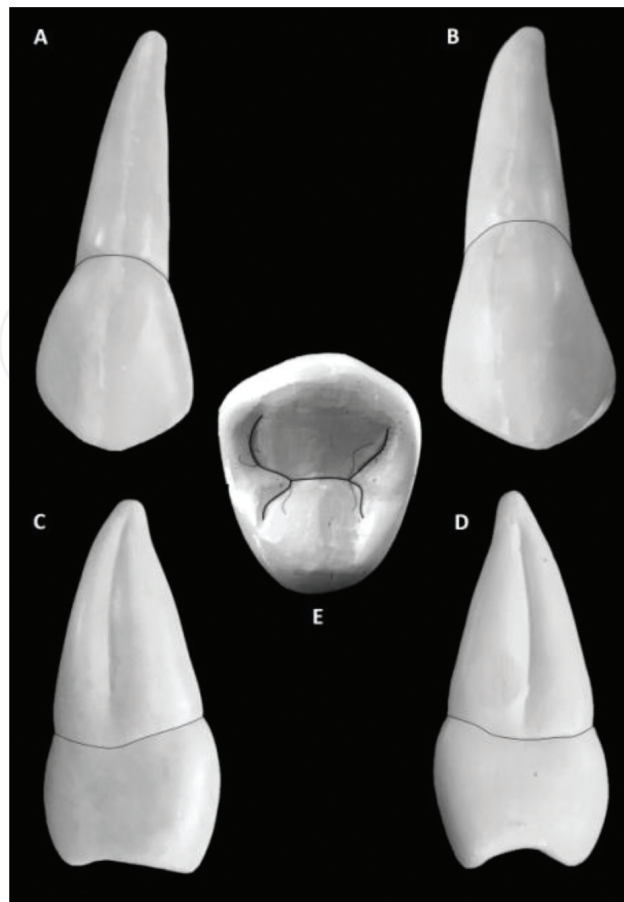
### 2.2.1. Buccal aspect

From the buccal view, the crown of the maxillary second premolar has a trapezoidal form. The buccal cusp of the second premolar is not as long as that of the first premolar. In addition, the buccal cusp appears to be less pointed. The mesial outline of the crown is slightly convex from cervix to the point where it joins the mesial slope of the buccal cusp. The distal outline is more convex than the mesial outline. The cervical outline on buccal view is slightly convex and curves in an apical direction. The tooth is thicker at the cervical portion than the maxillary first premolar.

The cusp tip is offset to the mesial; hence, the mesio-occlusal slope of the buccal cusp ridge is slightly shorter than the disto-occlusal slope. The opposite is true for the first premolar. The buccal ridge of the crown may be less prominent than that of the first premolar.

### 2.2.2. Lingual aspect

The crown of the maxillary second premolar has a trapezoidal form at the lingual aspect. From the lingual view, little variation can be seen except that the lingual cusp is almost having the same length as the buccal cusp. In addition, the lingual cusp tip is not quite so far offset to the mesial. The cervical outlines of the crown at this aspect present that the cervical line is less



**Figure 4.** Maxillary second premolar tooth from different aspects. A. Buccal, B. Lingual, C. Mesial, D. Distal, E. Occlusal.

curved apically than the buccal view. The occlusal outline is formed by the lingual cusp tip and its cusp slopes.

### 2.2.3. Mesial aspect

The mesial aspect shows the difference in cusp length between the first and second premolars. The cusps of the second premolar are shorter, with the buccal and lingual cusps more nearly the same length. Greater distance between the cusp tips widens the occlusal surface buccolingually.

Developmental depressions are not seen on the mesial surface of the crown as on the first premolar. The crown surface is convex. A shallow developmental groove appears on the single tapered root. There is no canine fossa or canine groove on this surface. The more equal size of the cusps is also noted. Both the contact area and marginal ridge are found at a slightly more cervical level than on the mesial of the first premolar.

### 2.2.4. Distal aspect

The distal view of the second premolars has the same features with the first premolars. Since the distal contact of second premolar is with the first molar, the contact area is slightly larger in

size, when compared to the first premolar. Both the distal contact area and marginal ridge are located at a slightly more cervical level than on the distal of the first premolar. The distal root depression is deeper than the mesial depression on the maxillary second premolar.

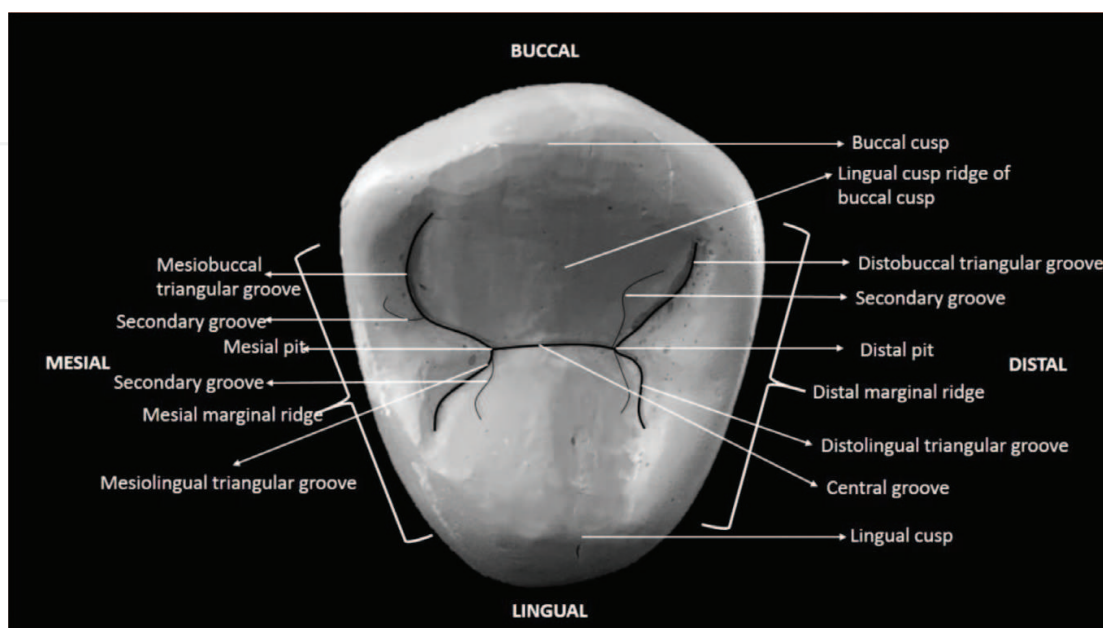
### 2.2.5. Occlusal aspect

The schematic description of occlusal table is given in **Figure 5**. The outline of the crown of the second premolar is more rounded or oval rather than hexagonal shape at this aspect. However, there may be some exceptions about this form. More distance between the cusp tips buccolingually than on the first premolar may be noted. Hence, the lingual cusp is almost as wide as the buccal. The grooves are shorter, shallower, and more irregular than in the first premolar. The central developmental groove is also shorter and more irregular. This groove has numerous supplementary grooves radiating from the central groove. This arrangement gives the occlusal surface a more wrinkled appearance.

### 2.2.6. Root

The root is usually single and shows a longitudinal groove on the mesial and distal surfaces, but may occasionally be double. The distal root depression is deeper than the mesial depression on the maxillary second premolar. Division of the root of the second premolar is rare; in about 15%. Root length is normally as great, or slightly greater than the root structure of the first premolar. The root is wider buccolingually than mesiodistally. It is often deflected slightly to the distal in its apical portion.

The average measurements of the maxillary second premolar are shown in **Table 4**.

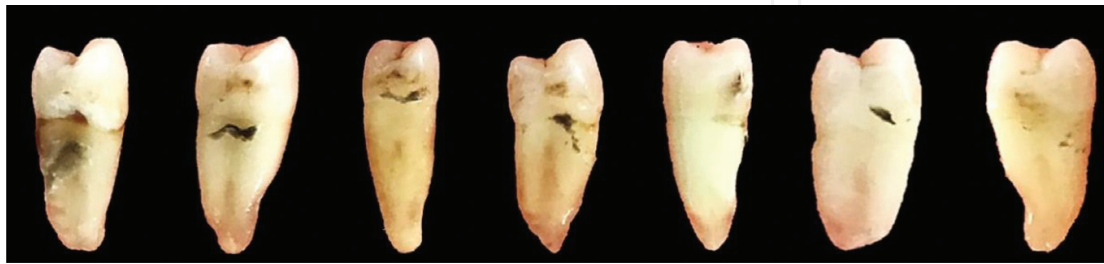

**Figure 5.** The schematic description of occlusal table of the maxillary second premolar tooth.

The average measurements of the maxillary second premolar (in mm)

Cervico-occlusal length of crown	Length of root	Mesiodistal diameter of crown	Mesiodistal diameter of crown at cervix	Buccolingual diameter of crown	Buccolingual diameter of crown at cervix	Curvature of cervical line-mesial	Curvature of cervical line-distal
8.5	14.0	7.0	5.0	9.0	8.0	1.0	0.0

**Table 4.** The average measurements of the maxillary second premolar teeth. Variations: The crown and root of this tooth also exhibit variations and anomalies (**Figure 6**).



**Figure 6.** The crown and root variations of the maxillary second premolar teeth.

### 3. The permanent mandibular premolars

#### 3.1. Permanent mandibular first premolars

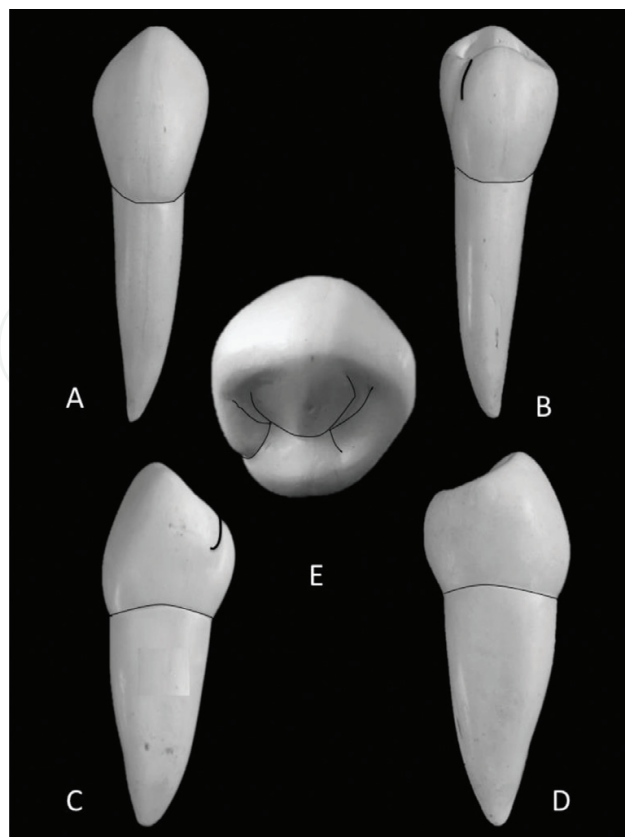
Chronologic development of the permanent mandibular first premolar is given in **Table 5**.

In the universal system of notation, the right permanent mandibular first premolar is shown as “#28,” and the left one is shown as “#21.” According to the FDI notation, the right permanent mandibular first premolar is shown as “44,” and the left one is shown as “34.” Additionally, in the Palmer notation, the right permanent mandibular first premolar is symbolized as “ $\overline{4}$ ,” the left one is symbolized as “ $\overline{4}$ .”

The image of mandibular first premolar from all aspects is given in **Figure 7**. A. Buccal, B. Lingual, C. Mesial, D. Distal, E. Occlusal.

Development stage	Years
Initiation of calcification	1 ¾–2 years
Enamel completion	5–6 years
Eruption	5–6 years
Root completion	10–13 years

**Table 5.** Chronologic development of the mandibular first premolar teeth.



**Figure 7.** Mandibular first premolar tooth from different aspects. A. Buccal, B. Lingual, C. Mesial, D. Distal, E. Occlusal.

### 3.1.1. Buccal aspect

The mandibular first premolar is similar to a mandibular canine and second premolar from buccal aspect. It has nearly same buccolingual measurement as a canine and has a sharp buccal cusp. The occlusocervical dimension of this tooth is less than all anterior teeth. However, this dimension is greater than that of the second premolar or any molar.

The buccal surface of mandibular first premolar is convex both occlusogingivally and mesiodistally. The crown is inclined lingually, and therefore, the tip of the buccal cusp is situated on the vertical axis of the root. The buccal height of contour is in the cervical third level of the surface. There is well-developed middle buccal lobe (buccal ridge) between the developmental depressions in mesiobuccal and distobuccal sides. The mesial cusp ridge is shorter than the distal cusp ridge.

The contour of the mesial margin is concave from the contact area to the cervical line joining the mesio-occlusal slope to create the mesio-occlusal angle. The outline continuing from the contact area to the cusp is convex. The height of contour (mesial contact area) is in the middle third at the center of the crown cervico-occlusally.

The distal margin is slightly shorter than mesial margin. In addition, the outline is concave from the contact area to the cervical line and the contact area is broader than the mesial contact



area. The height of contour (distal contact area) is approximately at the same level with the mesial contact area.

The buccal cervical line is slightly curved toward the apex and in comparison with the anterior teeth; the depth of curvature is less than that of the anterior teeth.

The buccal cusp tip divides the occlusal outline into two portions, the mesio-occlusal and disto-occlusal slopes, or mesial and distal cusp ridges. The disto-occlusal cusp ridge is longer than mesio-occlusal, moving the sharp cusp tip toward the mesial. Besides, both of the ridges are slightly concave.

### 3.1.2. Lingual aspect

Since the lingual cusp is smaller and shorter than buccal cusp, the buccal section of the occlusal surface could be seen from the lingual aspect. In addition, the crown is narrower mesiodistally on the lingual surface than on the buccal surface. Therefore, most of the mesial and distal parts could be seen from this aspect. This surface is convex in all directions and no ridge is present as seen on the buccal aspect. The lingual height of contour is in the middle third level of the surface.

The most characteristic feature of this tooth is the mesiolingual developmental groove between mesial marginal ridge and lingual cusp.

Since the lingual surface is shorter than buccal surface, both margins are shorter in lingual surface than buccal surface. Different from other teeth, mesial marginal ridge of mandibular first premolar teeth is shorter than distal marginal ridge. Additionally, mesial contact area is more cervically located than distal contact area.

The lingual cervical line is slightly curved toward the apex and narrower than buccal cervical line.

The lingual cusp tip and ridges are approximately at same level with the occlusal surface. Both of cusp tips are mesially offset, and the lingual cusp tip is in alignment with the buccal triangular ridge. There are mesial and distal occlusal fossae on each sides of occlusal surface.

### 3.1.3. Mesial aspect

Similarly with all the mandibular posterior teeth, the crown is in rhomboidal shape from the mesial aspect. While the buccal cusp is centered over the root, the lingual cusp tip is aligned with the lingual border of the root.

The buccal outline is convex starting from the cervical line to the buccal cusp tip. In addition, the height of contour is in the cervical third of the crown.

When compared with the buccal outline, this outline has more convexity. This margin is shorter than buccal margin. The lingual height of contour is at the middle third of crown. The “*mesiolingual developmental groove (mesial marginal groove)*” is visible from mesial aspect near the lingual margin.

The cervical line is slightly curved about 1 mm toward the occlusal surface. The occlusal outline is a concave arc inclining lingually. In addition, the buccal section of the transverse ridge is sloping to the lingual direction at an approximately 45° angle.

#### 3.1.4. Distal aspect

Similarly with the mesial aspect, the crown is in rhomboid shape. Additionally, buccal/lingual margins are similar. While there is no distolingual developmental groove, there is a distal marginal groove in this aspect of mandibular first premolar.

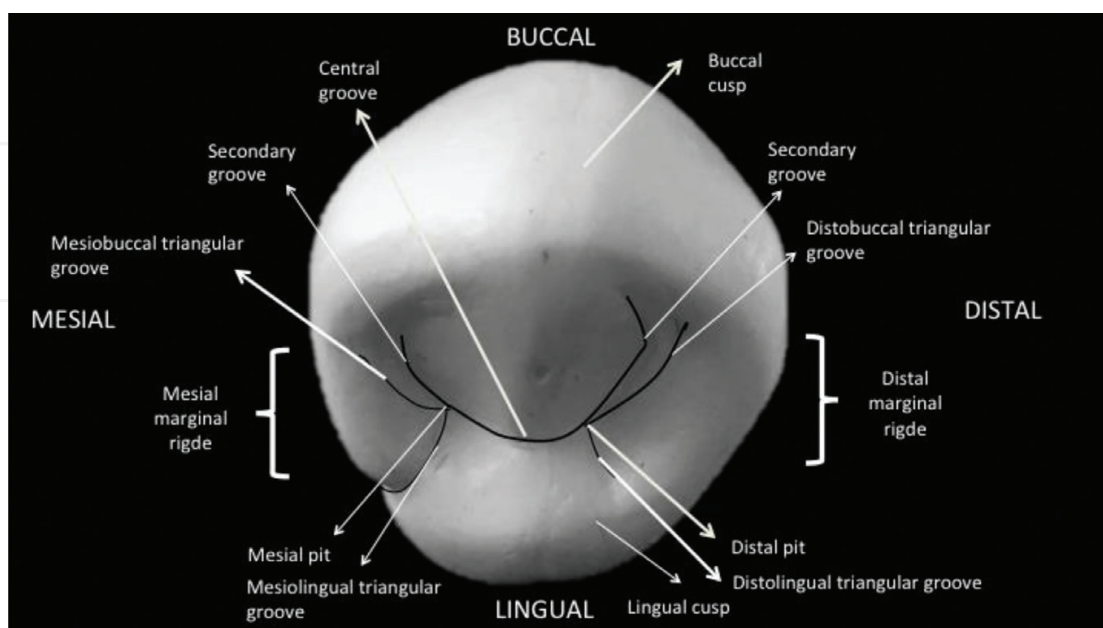
The cervical line on the distal surface has less curvature than mesial cervical curvature (less than 1 mm). The distal contact area is wider than the mesial contact area, since the contact tooth is second premolar.

The distal marginal ridge is not sloping lingually as the mesial. It is in a horizontal position, making the ridge perpendicular to the long axis of the tooth. It is located more occlusally than mesial marginal ridge.

#### 3.1.5. Occlusal aspect

The schematic description of the occlusal table is given in **Figure 8**. The shape of the crown is rhomboid or like a diamond. Since the crown is lingually inclined, from this aspect, most of the buccal surface could be seen. The difference between buccolingual and mesiodistal dimension is approximately 0.5 mm. The cusp tip is in the mesial half, and therefore, the distal half is a little bit larger than the mesial half.

The buccal margin has a pronounced convexity. This outline is also convex. However, it is shorter than the buccal outline. It continues up to the mesiolingual developmental groove.



**Figure 8.** The schematic description of the occlusal table of the mandibular first premolar tooth.

The mesial marginal ridge has an angle less than 90° at the point that it connects with the mesiobuccal cusp ridge.

The convexity of the distal outline is more apparent than the mesial outline. It forms a right angle where it meets with the distobuccal cusp ridge.

#### 3.1.5.1. Occlusal table components

Mandibular first premolar has two cusps, a buccal and a lingual. The buccal cusp is the functional cusp, and it is larger than the lingual cusp. Additionally, the buccal cusp tip is slightly mesial to the center and located at the buccal half of the occlusal surface. The lingual cusp is very small and is like a tubercle. It is the nonfunctional cusp as it is a mandibular tooth. The crown converges lingually. The cusp has four cusp ridges as follows: "*mesiobuccal, distobuccal, mesiolingual and distolingual.*"

The "*buccal and lingual triangular ridges*" form the "*transverse ridge*" in the central groove area.

"*Mesial and distal marginal ridges*" are well-developed marginal ridges. Mesial marginal ridge is shorter and is interrupted by mesiolingual developmental groove. The distal marginal ridge is more prominent and joins with the distolingual cusp ridge.

"*Mesial and distal fossae*" are present on the occlusal surface. They are bordered by the transverse ridge, the marginal ridges, and the mesial and distal cusp ridges of the two cusps. While the mesial fossa is linear in shape with the mesial developmental groove, the distal fossa is more circular.

The "*central developmental groove*" connects the "*mesial pit*" to the "*distal pit.*" "*Mesiobuccal triangular groove*" extends from mesial pit in a mesiobuccal direction. Similarly, "*mesiolingual triangular groove*" extends from the mesial pit in a mesiolingual direction. "*Mesiolingual developmental groove*" is between mesial marginal ridge and mesiolingual cusp ridge. Similarly, with the mesial grooves, "*distobuccal triangular developmental groove*" extends from distal pit in a distobuccal direction, and "*distolingual triangular developmental groove*" has a distolingual direction starting from distal pit.

#### 3.1.6. Root

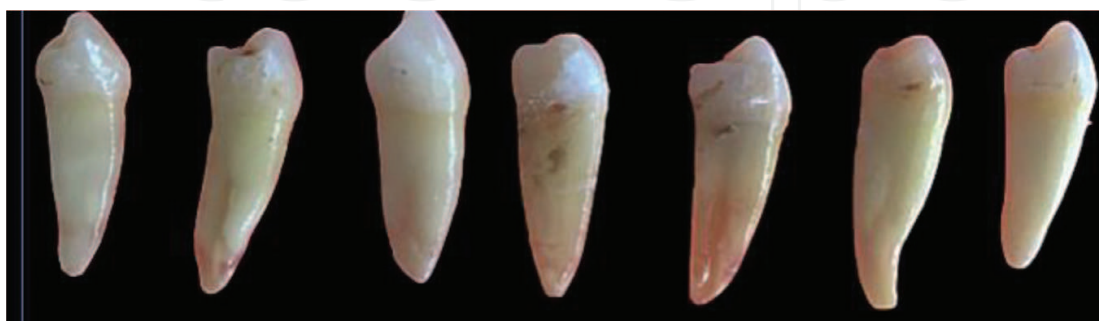In general, a mandibular first premolar has a single and straight root with a sharp apex. The root tapers from cervical to the apical region and is often curved distally. Rarely, a buccal and a lingual root or two buccal and one lingual root are present. The buccolingual section is wider than mesiodistal section. The height of contour of buccal surface is in the center of the root. The root is approximately 3 or 4 mm shorter than that of the mandibular canine. From the mesial aspect, the root is in a tapered form from the cervical line to the apical region. Despite the convexity in mesial and distal surfaces, longitudinal grooves are present in these surfaces, mostly deepest one in the mesial surface. The lingual surface is much narrower than buccal surface allowing most of the mesial and distal surfaces of the root to be seen. The convexity of distal surface is more prominent than mesial surface.

The average measurements of the mandibular first premolar are shown in **Table 6**.

The average measurements of the mandibular first premolar (in mm)

Cervico-occlusal length of crown	Length of root	Mesiodistal diameter of crown	Mesiodistal diameter of crown at cervix	Buccolingual diameter of crown	Buccolingual diameter of crown at cervix	Curvature of cervical line-mesial	Curvature of cervical line-distal
8.5	14.0	7	5	7.5	6.5	1	0

**Table 6.** The average measurements of the mandibular first premolar teeth. Variations: The crown and root of this tooth exhibit some variations (**Figure 9**).



**Figure 9.** The crown and root variations of the mandibular first premolar teeth.

### 3.2. Permanent mandibular second premolar

Chronologic development of the mandibular second premolar is given in **Table 7**.

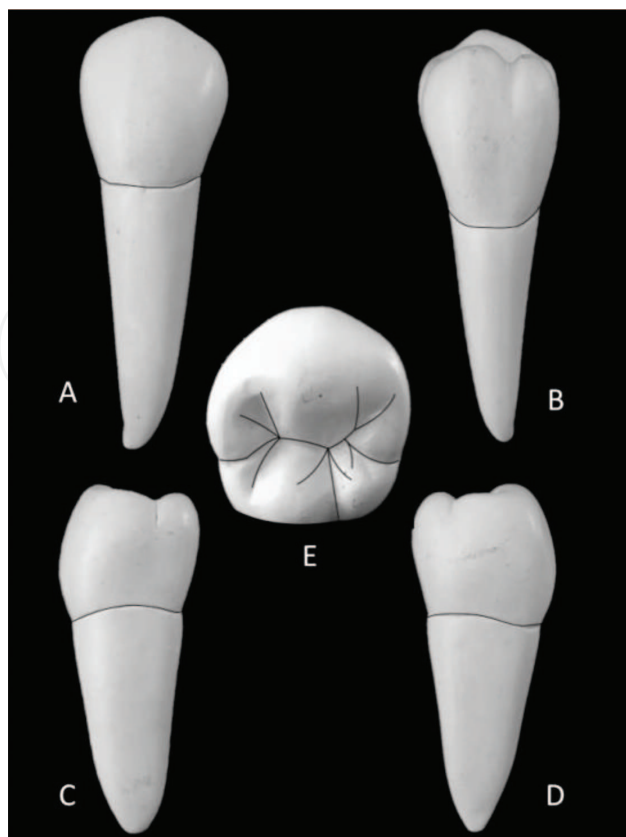
In the universal system of notation, the right permanent mandibular second premolar is shown as “#29,” and the left one is shown as “#20.” According to the FDI notation, the right permanent mandibular second premolar is shown as “45,” and the left one is shown as “35.” Furthermore, in the Palmer notation, the right permanent mandibular second premolar is symbolized as “ $\overline{5}$ ” while the left one is symbolized as “ $\overline{5}$ .”

The image of mandibular second premolar from all aspects is seen in **Figure 10**. A. Buccal, B. Lingual, C. Mesial, D. Distal, E. Occlusal.

The mandibular second premolar is the fifth permanent tooth from the median line in the mandibular arch, located between the mandibular first premolars and first molars. Since the occlusal table is broader and similar to that of posterior teeth, this tooth has a function more like a molar.

Development stage	Years
Initiation of calcification	2.25–2.5 years
Enamel completion	6–7 years
Eruption	11–12 years
Root completion	13–14 years

**Table 7.** Chronologic development of the mandibular second premolar teeth.



**Figure 10.** Mandibular second premolar tooth from different aspects. A. Buccal, B. Lingual, C. Mesial, D. Distal, E. Occlusal.

Despite the similarities in general form of the second premolar with the first premolar, there are differences between them except buccal surface. There are two common forms: three-cusp type (“Y” groove pattern) exhibiting two lingual cusps and two-cusp type (“U” and “H” groove pattern).

### 3.2.1. Buccal aspect

Considering the buccal aspect, a mandibular second premolar has a larger crown and longer root than first premolar. The buccal cusp is not so long and not as sharp as first premolar. The cusp tip is approximately at the center of the tooth in mesiodistal direction, therefore the distobuccal and mesiobuccal slopes are equal in dimension.

The buccal surface is convex. Furthermore, mesial and distal outlines are convex except near the cervical region. The mesiobuccal and distobuccal cusp ridges are not angulated too much.

The contact areas in mesial and distal regions are situated at the middle third. Since the distal contact is a molar tooth, the distal contact area is broader than mesial contact. Additionally, the height of contour is similar to that of first premolar.

### 3.2.2. Lingual aspect

Since there are two different forms of mandibular second premolar, the lingual aspect of a second premolar has some variations. The lingual surface is convex and smooth. In addition, it



is slightly narrower and shorter than the buccal surface. However, this surface is wider and longer than that of first premolar. The mesial, distal, and cervical outlines are similar to first premolar. The lingual cusps are as high as buccal cusp; therefore, small part or none of the occlusal surface could be seen. The height of contour of the lingual surface is found approximately at the occlusal third of the crown.

#### 3.2.2.1. Two-cusp type

Two cusps—a buccal and a lingual—are present in this form. While no lingual groove exists in the lingual surface, a lingual depression could be found in the distal portion.

#### 3.2.2.2. Three-cusp type

In this type, there are mesiolingual and distolingual cusps, where the first one is the wider and the longer one. Distolingual cusp is often sharper than mesiolingual cusp. There is a “*lingual groove*” between the lingual cusps extending to the lingual surface.

#### 3.2.3. Mesial aspect

From the mesial aspect, the shape is rhomboidal like the proximal aspect of all mandibular posterior teeth. Besides, mesial surface is convex except the concavity situated near the gingival region.

This tooth is not inclined lingually as much as the first premolar. Therefore, the tip of the buccal is not centered over the root, usually located at the junction of the buccal and middle thirds. Besides, the lingual cusp is in alignment with the lingual surface of the root.

The buccal surface is more curved than lingual surface. The buccal height of contour is found slightly occlusal of the cervical line, and lingual height of contour is approximately at the occlusal third.

The mesial marginal ridge lies horizontally and is perpendicular to the long axis of the tooth. Additionally, it is located more occlusally than distal marginal ridge. Therefore, limited part of the occlusal surface is visible. There is no mesiolingual developmental groove.

The cervical line has a slight occlusal curvature.

In two-cusp type, while no lingual groove exists in the lingual surface, a lingual depression could be found in the distal portion. In three-cusp type, only the mesiolingual cusp could be seen from this aspect.

#### 3.2.4. Distal aspect

In three-cusp type, both of the mesiolingual and distolingual cusps are visible from this aspect. The distal surface is also convex and similar to the mesial surface except some differences:

- The distal marginal ridge is more concave and cervically located than mesial marginal ridge. Therefore, this surface is shorter than mesial occlusocervically. The occlusal surface could be seen from this aspect to a certain extent.

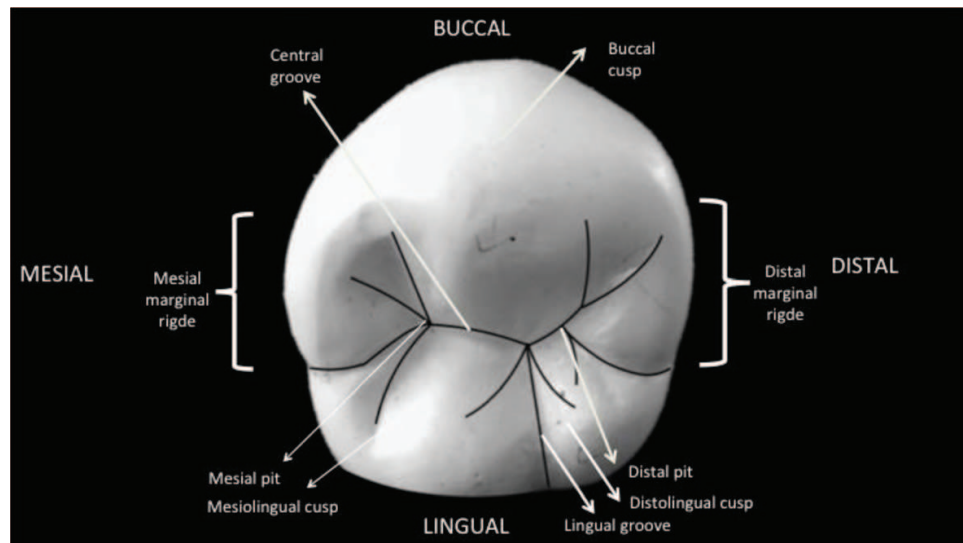
- The distal contact area is located similarly with the mesial contact. Since the distal contact is with the first molar, it is wider buccolingually than mesial contact area.

### 3.2.5. Occlusal aspect

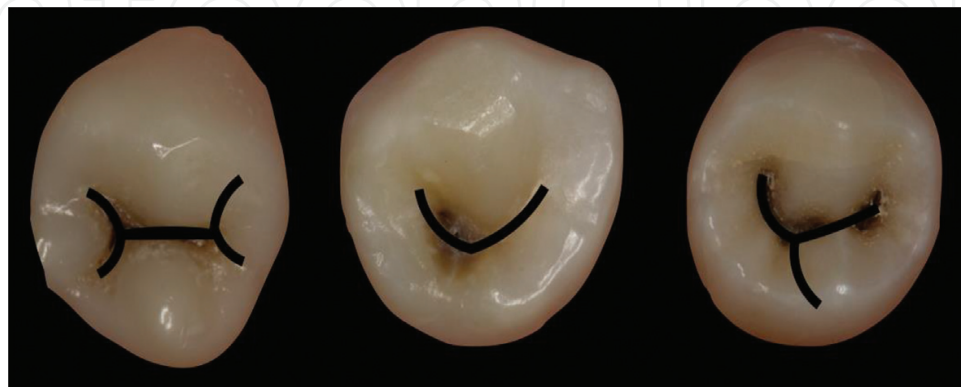The schematic description of the occlusal table is given in **Figure 11**. There are two common forms for the occlusal morphology of the mandibular second premolar. In both types of second premolars, there is “*central groove*” extending between mesial pit and distal pit.

#### 3.2.5.1. Three-cusp type

Three-cusp type is the more common and square-shaped one. It has a “*Y*” groove pattern (**Figure 12A**). The variation of groove patterns is presented in **Figure 12**. A. “*H*” groove pattern, B. “*U*” groove pattern, C. “*Y*” groove pattern.



**Figure 11.** The schematic description of the occlusal table of the mandibular second premolar tooth.



**Figure 12.** The variations of groove patterns of the mandibular second premolar tooth. A. “*H*” groove pattern, B. “*U*” groove pattern, C. “*Y*” groove pattern.

This type of mandibular second premolar has three cusps in the following order from largest to smallest: the buccal cusp, the mesiolingual cusp, and the distolingual cusp.

In both of the arches at the occlusal aspect, the tooth becomes narrower toward the lingual half and the distal half. However, three-cusp second premolars are an exception that the crown is wider in the lingual and distal half than the buccal and mesial half.

In three-cusp type, "*mesiolingual triangular groove, mesiobuccal triangular groove, mesial marginal groove, distolingual triangular groove, distobuccal triangular groove and distal marginal groove*" exist. Each of the cusps has "*mesial and distal cusp ridges*" and "*a triangular ridge*" connecting the cusp tip with the center of the occlusal surface. There are "*mesial and distal triangular fossae*." Mesial triangular fossa originates from "*mesial pit*." Distal triangular fossa originates from "*distal pit*." The "*central pit*" is in the center of the occlusal surface in the three-cusp type.

There are three deep developmental grooves (mesial developmental groove, distal developmental groove, and lingual developmental groove) connecting at the central pit. "*Mesial developmental groove*" extends from the central pit to the mesial triangular fossa. "*Distal developmental groove*" runs from the central pit to the distal triangular fossa. "*Lingual developmental groove*" is lying between two lingual cusps.

### 3.2.5.2. Two-cusp type

Two-cusp type is more rounded and has a "*U*" or "*H*" groove pattern (**Figure 12B** and **C**). The buccal cusp is larger than lingual cusp. No central pit and lingual developmental groove exists. The buccal and lingual cusp triangular ridges connect and create a "*transverse ridge*."

### 3.2.6. Root

A mandibular second premolar has a single and tapered root having a curvature to the distal side. When compared with first premolar, the root is wider and longer than that of first premolar. The apex is inclined to distal side. Buccal surface is convex. There are longitudinal grooves on the proximal sides. In distal aspect, the longitudinal grooves are in the middle third. However, longitudinal depression is rarely seen on the mesial surface. The lingual surface is slightly convex and narrower than buccal surface. Some part of the mesial and distal sides of this tooth might be seen from this aspect.

The average measurements of the mandibular second premolar are shown in **Table 8**.

The average measurements of the mandibular second premolar (in mm)

Cervico-occlusal length of crown	Length of root	Mesiodistal diameter of crown	Mesiodistal diameter of crown at cervix	Buccolingual diameter of crown	Buccolingual diameter of crown at cervix	Curvature of cervical line-mesial	Curvature of cervical line-distal
8	14.5	7	5	8	7	1	0

**Table 8.** The average measurements of the mandibular second premolar teeth. Variations: The crown and root of this tooth also exhibit some variations (**Figure 13**).

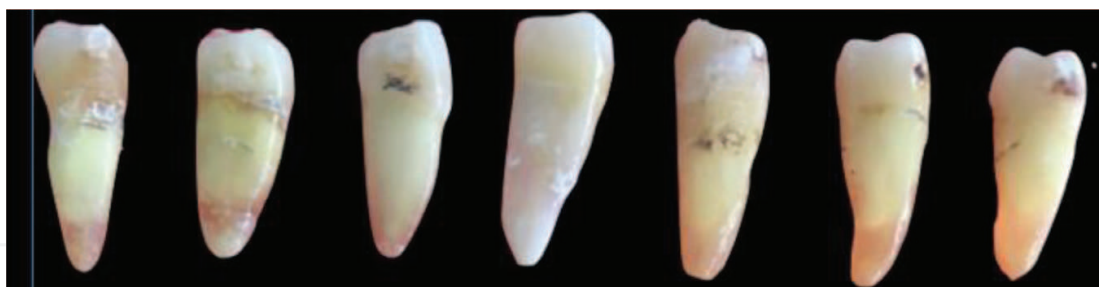

Figure 13. The crown and root variations of the mandibular second premolar teeth.

#### 4. The differences between maxillary and mandibular premolars

There are several general characteristics, which aid in differentiating the maxillary premolars from other posterior teeth and mandibular premolars. The maxillary first and second premolars appear more alike than mandibular premolars. However, maxillary first premolar crowns are generally larger than the second premolars. In addition, in the mandible, the first premolar is considerably smaller than those. From mesial and distal aspects, mandibular premolar crowns appear to be tilted lingually relative to their roots, whereas maxillary premolar crowns are aligned more directly. Maxillary premolars possess two cusps of nearly equal size. The mandibular premolars may have more than two cusps, and the lingual cusps are normally less prominent than the facial cusps. The buccal cusp is longer than the lingual cusp/cusps in all premolar teeth. This difference is the most prominent for mandibular first premolars and the least prominent for maxillary second premolars. The maxillary first premolar frequently has two root branches, whereas the other premolars have one root.

#### Author details

Işıl Çekiç Nagaş<sup>1</sup>, Ferhan Eğilmez<sup>1</sup> and Bağdagül Helvacıoğlu Kivanç<sup>2\*</sup>

\*Address all correspondence to: bagdagulkivanc@gmail.com

1 Department of Prosthodontics, Faculty of Dentistry, Gazi University, Ankara, Turkey

2 Department of Endodontics, Faculty of Dentistry, Gazi University, Ankara, Turkey

#### References

- [1] Almonaitiene R, Balciuniene I, Tutkuvienė J. Standards for permanent teeth emergence time and sequence in Lithuanian children, residents of Vilnius city. *Stomatologija*. 2012;**14**(3): 93-100

- [2] Kochhar R, Richardson A. The chronology and sequence of eruption of human permanent teeth in Northern Ireland. *International Journal of Paediatric Dentistry*. 1998;8(4):243-252
- [3] Almonaitiene R, Balciuniene I, Tutkuviene J. Factors influencing permanent teeth eruption. Part one—general factors. *Stomatologija*. 2010;12(3):67-72
- [4] Scott JH, Symons NBB. *Introduction to Dental Anatomy*. 9th ed. New York: Butter & Tanner Ltd; 1982
- [5] Sicher H, Du Brul EL. *Sicher's Oral anatomy*. 7th ed. Mosby co. St. Louis; 1980
- [6] Berkovitz BKB, Holland GR, Moxham BJ. *Color Atlas & Textbook of Oral Anatomy Histology and Embryology*. 2nd ed. Mosby co. St. Louis; 1992
- [7] Brand RW, Isselhard DE. *Anatomy of Oral structures*. 7th ed. Mosby co. St. Louis; 2003
- [8] Scheid RC, Weiss G. *Woelfel's Dental Anatomy and Its Relevance to Dentistry*. 8th ed. China: Lippincott Williams and Wilkins; 2012
- [9] Nelson SJ. *Wheeler's Dental Anatomy, Physiology and Occlusion*. 10th ed. China: Elsevier Health Sciences; 2014
- [10] Fuller JL, Denehy GE, Schulein TM. *Concise Dental Anatomy and Morphology*. 4th ed. USA: Univ of Iowa Office of State; 2001
- [11] Rashmi GS. *Textbook of Dental Anatomy, Physiology and Occlusion*. 1st ed. New Delhi: Jaypee Brothers Medical Publishers Ltd; 2014