

We are IntechOpen, the world's leading publisher of Open Access books Built by scientists, for scientists

4,800

Open access books available

122,000

International authors and editors

135M

Downloads

Our authors are among the

154

Countries delivered to

TOP 1%

most cited scientists

12.2%

Contributors from top 500 universities

**WEB OF SCIENCE™**Selection of our books indexed in the Book Citation Index
in Web of Science™ Core Collection (BKCI)

Interested in publishing with us?
Contact book.department@intechopen.com

Numbers displayed above are based on latest data collected.

For more information visit www.intechopen.com

Neglected Tropical Diseases with an Impact on Kidney Function

Geraldo Bezerra da Silva Junior,
Ana Amélia Reis Jereissati,
Ane Karoline Medina Neri,
Danielli Oliveira da Costa Lino,
Juliana Gomes Ramalho de Oliveira and
Elizabeth De Francesco Daher

Additional information is available at the end of the chapter

<http://dx.doi.org/10.5772/intechopen.78981>

Abstract

Neglected tropical diseases are a group of infectious diseases caused by infectious and parasitic agents that occur in a large part of the world affecting millions of people and can complicate matters with serious organ damage. The kidneys can be affected in many of these diseases, including Chagas disease, dengue, leishmaniasis, leprosy, and schistosomiasis. In this chapter, we describe the mechanisms by which the kidneys are damaged in the setting of these diseases, the clinical manifestations, and the current available treatment options. We also describe the recent novel biomarkers that are under investigation for the early diagnosis of kidney injury in the course of these diseases and the future perspectives.

Keywords: tropical diseases, neglected diseases, kidney diseases, acute kidney injury

1. Introduction

The World Health Organization (WHO) lists a group of communicable diseases that currently affects more than one billion people in more than 100 countries and cost billions of dollars every year [1]. These diseases have the common characteristics of affecting predominantly poor people living in precarious conditions, with close contact with vectors and domestic

animals, and also facing difficulties to access health-care facilities. The 2018 WHO list of neglected tropical diseases includes Buruli ulcer, Chagas disease, dengue, chikungunya, dracunculiasis, echinococcosis, foodborne trematodiasis, human African trypanosomiasis, leishmaniasis, leprosy, onchocerciasis, rabies, scabies and other ectoparasites, schistosomiasis, soil-transmitted helminthiasis, snakebite envenoming, taeniasis/cysticercosis, trachoma, yaws, lymphatic filariasis, mycetoma, chromoblastomycosis, and other deep mycoses [1]. The kidneys are frequently affected in these diseases, and in some cases, the complications increase the risk of death. In this chapter, we discuss the main neglected tropical diseases, which complicate matters with kidney involvement.

2. Chagas disease

Chagas disease (or American trypanosomiasis) is the infection caused by the flagellated protozoan *Trypanosoma cruzi* and transmitted by insects of the family Triatominae, the *Triatoma infestans*, known as “kissing bugs” (in Brazil: “barbeiro”; in Argentina, Bolivia, Chile, and Paraguay: “vinchuca”; in Colombia: “pito”; in Venezuela: “chipo”; and in Central America: “chinche”) [2]. The transmission occurs through the inoculation of *T. cruzi* in the blood of the host, through the insect stool left next to the site of the bites. The infection can also occur through the ingestion of the infected insects (contaminated food), blood transfusion, organ donation, or vertical transmission [3]. Kidney involvement in Chagas disease is seldom described and rarely studied [4].

The disease is endemic in 21 Latin American countries, and the highest prevalence is registered in Bolivia, Argentina, Paraguay, Ecuador, El Salvador, and Guatemala [3]. In Brazil, there was a significant decrease in incidence due to the vector control program, and now the disease is predominantly seen as chronic cases with cardiac or gastrointestinal manifestations [5, 6].

Clinical manifestations of Chagas disease can be divided into acute and chronic phase [3, 4]. The acute phase manifests with fever, signs of inflammation at the inoculation site, unilateral palpebral edema (Romaña sign), lymphadenopathy, and hepatosplenomegaly [3]. Severe acute Chagas infection is rare and occurs in less than 5% of the cases, manifesting with acute myocarditis, pericardial effusion, and meningoencephalitis [3]. The chronic phase develops in 10–30% of infected individuals and is characterized by heart disease and gastrointestinal disease (megaesophagus and megacolon) [7, 8].

T. cruzi has the ability to act as a parasite to a great variety of cells, including kidney cells [4]. There is evidence of functional and structural kidney abnormalities after *T. cruzi* infection, associated with reduction in renal blood flow, proximal tubular damage, and inflammatory interstitial infiltrate. An observation is made of an increased production of pro-inflammatory cytokines and nitric oxide, as well as renal function loss associated with high parasitic load [9–12]. In the acute phase, the renal lesion is related to cardiovascular dysfunction, due to a transitory decrease in renal blood flow, which was demonstrated in experimental models [11, 13]. Glomerulonephritis is reported in *T. cruzi* infection and also demonstrated in

experimental studies [14, 15]. The pathophysiology of kidney involvement in Chagas disease is associated with immunological process and includes autoantibodies production [16, 17]. There are reports that in the chronic phase of the disease, glomerular deposits of IgM occur at early stages, with intense inflammatory response, resulting in immune complex formation, which leads to glomerulonephritis [9]. The exact mechanism by which *T. cruzi* causes kidney disease is still to be elucidated [4].

Treatment of Chagas disease is based on antitrypanosomal drugs, which is indicated for all acute and congenital cases, reactivated cases, and chronic disease in individuals <18 years [3]. Specific treatment is currently recommended even for patients with the chronic forms of the disease, despite achieving lower cure rates than in acute phase [6]. The main available drugs are benznidazole (dose for adults: 5 mg/kg/day; for children: 5–10 mg/kg/day) and nifurtimox (dose for adults: 8–10 mg/kg/day; for children: 15 mg/kg/day), for 60 days.

3. Dengue and other endemic arbovirosis

Dengue is the most common arbovirosis in the world, there are more than 2 billion people living in endemic areas [18], and it is the second most common disease transmitted by mosquitoes, following malaria [19]. Tropical countries face repeated outbreaks of the disease. In Brazil, the most recent outbreaks have affected millions of people [20, 21]. In recent years, other arbovirosis has caused epidemics in the Caribbean region and Latin America: chikungunya fever and Zika virus infection, and renal involvement has already been reported [22–27].

Clinical manifestations vary according to patients' age, and the incubation period varies from 3 to 14 days. The majority of patients are asymptomatic or have a mild disease characterized by fever, headache, myalgia, arthralgia, retroorbital pain, and maculopapular rash, which has been known as dengue fever [19, 28]. Severe forms of the disease, characterized by coagulation disturbances, increased vascular permeability, and hemorrhagic manifestations, are classically known as dengue hemorrhagic fever and can evolve to dengue shock syndrome [19]. There is evidence that severe cases of dengue are increasing, complicating with organ damage, including kidney involvement [14, 18].

Renal abnormalities in dengue include hydroelectrolyte disturbances, acute kidney injury (AKI), and, less frequently, glomerulonephritis, rhabdomyolysis, and hemolytic uremic syndrome [18, 29–31]. AKI seems to be more frequent in adults than in children with dengue and is associated with hypotension, sepsis, multiple organ dysfunction, and use of vasoactive drugs [30–37]. Direct kidney damage caused by dengue virus is described through cytopathic effect of viral proteins on glomerular and tubular cells, associated with immunological mechanisms mediated by viral antigens deposited on glomerular structures and tissue damage by immune complex deposition [18, 31, 38]. Other factors that mediate renal lesions in Dengue are hemodynamic instability, hemolysis, rhabdomyolysis, and nephrotoxic drug use. Autopsy studies show evidence of acute tubular necrosis, predominantly in the proximal tubules, hemorrhage, and edema, more accentuated in the medullary region [29, 38]. Dengue-associated AKI usually has a favorable outcome, with recovery in around 2 weeks [18]. Among patients

with chronic kidney disease, dengue is associated with high mortality [18]. Among renal transplant patients, dengue fever also presents favorable outcomes and does not significantly affect the allograft function [39].

Chikungunya infection is another arbovirosis that has been responsible for large epidemic in recent years, causing self-limited disease in most cases, with predominant symptoms being fever and arthralgias [22, 23], but renal involvement has been reported in fatal cases [22, 24]. A series of 10 autopsies from Colombia evidenced that renal involvement is frequent, with serum creatinine at admission varying from 1.2 to 8.9 mg/dl (median 2.8 mg/dl), and the main histopathological findings were glomerular involvement (glomerular edema, nephrosclerosis, and membranoproliferative glomerulonephritis) and acute tubular necrosis [22, 24]. Similar to what is seen in dengue infection, transplanted patients who acquire Chikungunya infection seem to have a milder disease, with less severe arthralgia, and this could be due to immunosuppressant drug effects [25]. The acute viral infection also seems not to significantly affect the renal allograft [25].

Zika is another arbovirosis that usually causes a mild infection, which is predominated by fever, arthralgias (milder than in dengue and chikungunya), and a typical rash with pruritus, which was brought to the attention of the Public Health authorities in 2015—the outbreak occurred in Brazil affecting a large number of people and causing neurologic disturbances in newborns, including microcephaly [26, 27]. Renal involvement has been recently described in experimental studies, which demonstrated that the Zika virus has the potential to infect different types of kidney cells, including podocytes, endothelial and mesangial cells, and the virus can also be detected in the urine, which is an evidence of the kidneys as reservoirs of the virus and a potential source for the transmission [26, 27]. These findings also suggest that patients infected with Zika virus are at risk of developing glomerulonephritis, as expected in the other arbovirosis.

There is no specific treatment for dengue, as well as for the other arbovirosis, so it consists in supportive measures and depends on clinical manifestations [40]. Treatment basis include hydration (oral or venous, depending on disease severity), resting and symptomatic medication (antipyretics, analgesics), and avoiding the use of anti-inflammatory drugs. Correction of metabolic and electrolyte disturbances is crucial and if instituted early can prevent complications [18]. Dengue vaccines are under research and the available ones present good results in individuals with previous exposure to the virus [41].

4. Leishmaniasis

Leishmaniasis is the tropical disease caused by the parasites from the genus *Leishmania*, transmitted by mosquitoes *Phlebotomus* and *Lutzomyia*, with the majority of cases concentrated in Latin America, South East Asia, East Africa, and, less frequently, Europe [42, 43]. There are 12–15 million infected people in the world, and 350 million are at risk [43]. Approximately, 1.5–2 million new cases of leishmaniasis are registered in the world each year [43], and 90% of cases are concentrated in India, Ethiopia, Somalia, Sudan, and Brazil [44–46].

The disease can be asymptomatic or manifest as a localized disease in the skin (cutaneous leishmaniasis) or affect different organs (visceral leishmaniasis, also known as kala-azar or black fever). Incubation period can vary from few weeks to years, and the main symptoms and signs include insidious low-grade fever, pallor, splenomegaly, hepatomegaly, fatigue, weakness, hyporexia, and weight loss [42, 47]. In endemic areas, such as northeast of Brazil, the most affected individuals with visceral leishmaniasis are children [28]. Laboratory abnormalities are common and are typically characterized by pancytopenia, associated with hyperglobulinemia and hypoalbuminemia [28].

Kidney involvement in visceral leishmaniasis has been studied in both cutaneous form of leishmaniasis (American cutaneous leishmaniasis), in which tubular dysfunction predominates [48], and visceral leishmaniasis, in which renal lesions seem to be more frequent and severe [49]. Immunological mechanisms seem to be the key components of kidney injury in leishmaniasis, with immune complex deposition, T cell activation, and inflammatory process, leading to glomerulonephritis and interstitial nephritis [49–51]. Clinically, renal involvement in visceral leishmaniasis can manifest with acute kidney injury (AKI), mild-to-moderate proteinuria, hematuria, leukocyturia, hydroelectrolyte disturbances, and tubular defects—urinary concentration and acidification defects, which can persist even after specific treatment [52–54]. Glomerular disease in leishmaniasis is characterized to be mesangial proliferative, with immune complex deposition, and can complicate with rapidly progressive glomerulonephritis [55, 56]. Microalbuminuria is the most frequent renal abnormality found in patients with visceral leishmaniasis (around 40%), evidencing important glomerular filtration barrier defect caused by the infection process [57, 58]. AKI has also been reported in a considerable number of patients (more than 30%); it seems to be more frequent and severe in adults and is associated with hypokalemia, leukopenia, and use of amphotericin B [53, 59]. AKI was also associated with hyponatremia, hypoalbuminemia, hyperglobulinemia, and secondary infections in children with visceral leishmaniasis [60]. New biomarkers are under investigation aiming to detect early kidney injury in tropical diseases, including leishmaniasis. The most studied by now are the neutrophil gelatinase-associated lipocalin (NGAL), kidney injury molecule-1 (KIM-1), and monocyte chemoattractant protein-1 (MCP-1) [61–63]. NGAL has been associated with AKI in visceral leishmaniasis, presenting good accuracy for the early diagnosis of AKI, and is a promisor tool for the identification of patients at risk of developing severe disease [64].

Treatment consists of anti-Leishmania drugs, and the standard treatment is pentavalent antimonials [42, 43]. The most commonly used drug is meglumine, but the biggest problem is its toxicity (cardiotoxicity). The second choice is amphotericin B, which has nephrotoxicity as the main adverse effect [42, 43].

5. Leprosy

Leprosy is a chronic disease caused by the *Mycobacterium leprae*, an acid-fast bacillus, characterized to be incapacitating and to cause organ failure in some cases, including kidney disease

[49, 65, 66]. The disease is highly contagious, but few people develop the disease once there is natural resistance to the bacillus [65]. This is one of the oldest diseases known to affect humankind, with reports in the Bible [67].

There are reports of leprosy in 138 countries, with world prevalence of 0.2 cases per 10,000 inhabitants in 2015 [68]. The number of new cases in this same year was 211,973 cases, evidencing continued transmission (2.9 cases per 100,000 inhabitants). India and Brazil are responsible for the highest majority of cases in the world [68].

The spectrum of manifestations depends on the host's immunity and response to *M. leprae*, and the incubation period is long, going from 6 months to 10–20 years [65, 66]. During the course of the disease, there are "reactional states," in which the immune system reacts against the bacilli, exacerbating the clinical manifestations. The disease can be classified as paucibacillary and multibacillary, according to the number of skin lesions and bacilli found in skin smears [65, 66]. Besides affecting the skin, leprosy characterizes to cause peripheral nerve damage [65] and can complicate with systemic involvement, including nephropathy [49].

Kidney involvement in leprosy has been described for the first time a long time ago in autopsy studies and includes different types of glomerular lesions, such as epithelioid granulomas, and also Hansen's bacillus in renal parenchyma [49]. It is found in all forms of the disease but is more frequent in multibacillary forms [69, 70]. The most common leprosy-associated glomerular disease is mesangial proliferative glomerulonephritis and other histologic types are also found: acute proliferative glomerulonephritis, membranous glomerulonephritis, rapidly progressive glomerulonephritis, and others. Chronic tubulointerstitial nephritis and amyloidosis have also been described in the course of leprosy, leading to chronic kidney disease [71, 72]. The mechanics by which *M. leprae* infection leads to kidney disease are not completely understood [49], and it is probably associated with immunological phenomena. Complement reduction and immune complex deposition in glomerular basement membrane have been described [73–75]. Oxidative stress also plays a role in leprosy nephropathy. There is evidence of subclinical kidney damage even in patients with controlled infection. The levels of urinary MCP-1 are increased in leprosy patients and are associated with microalbuminuria levels and amount of bacilli of skin smears [76]. Renal tubular disturbances have also been described in leprosy, including concentration and acidification defects [77]. AKI can also occur in leprosy and seems to be associated to glomerulonephritis complications or secondary to the use of nephrotoxic drugs, mainly anti-inflammatory drugs and rifampicin, which are used in leprosy therapeutic scheme. Leprosy nephropathy seems to have changed in recent years, becoming a milder disease, characterized by micro-hematuria and mild proteinuria, which tends to recover after specific treatment [78].

Treatment consists of specific multi-drug therapy, reactional state treatment, prevention of disabilities, and psychosocial support. Specific therapy includes rifampicin and dapsone for paucibacillary patients (for 6 months) and rifampicin, dapsone, and clofazimine for multibacillary patients (for 12 months). Corticosteroids may be used for reactional states. Leprosy-associated end-stage kidney disease may require renal replacement therapy, which includes dialysis or transplantation, and immunosuppression for renal transplanted patients seems not to alter the response to leprosy-specific treatment [49].

6. Schistosomiasis

Schistosomiasis is the parasitic disease caused by organisms of the genus *Schistosoma*, which affects more than 200 million people in the world and is endemic in some tropical areas of the globe [79, 80]. It is the second most frequent parasitic disease, after malaria, and is still an important infection-associated cause of death [81].

The definitive host is the men, where the adult parasite reproduces and eliminates its eggs, which contaminated water resources [79]. In nature, disease transmission depends on the presence of snails from the family *Planorbidae* and genus *Biomphalaria*, and the men acquire the infection when the cercariae penetrate through the skin. The presence of the parasite in the human organism is relatively harmless, and the manifestations depend on immune response to different stages of the parasite in the body [82]. The disease can manifest as an acute syndrome, also known as Katayama syndrome, which is more common among travelers or immigrants in endemic areas with no immunity to *Schistosoma* and is characterized by fever, malaise, myalgia, headache, and abdominal pain, which can last from 2 to 10 weeks [80]. Depending on the patient's immune system response, the disease can progress to the chronic forms, in which predominate the intestinal form, in the case of *S. mansoni*, *S. japonicum* and *S. mekongi* infections. Patients with poor immune regulation develop severe fibrosis and hepatosplenic disease with periportal fibrosis [80]. The species *S. haematobium*, which occurs in some parts of Africa, affects the urogenital system, manifesting mainly by hematuria [80–82]. Other symptoms described in the infection by *S. haematobium* include hematospermia and inflammation in other structures in men—epididymis, testicles, spermatic cord and prostate, and women—hypertrophic/ulcerative lesions of the vulva, vagina, and cervix [82].

Kidney involvement in schistosomiasis is described and predominates in the form of glomerulonephritis [79]. In schistosomiasis, there are circulating antigens of adult parasite, and its eggs can be found in different organs, including the kidneys [79]. Acute kidney injury (AKI) is also described, with high prevalence in endemic areas, affecting as high as more than 40% of patients with the chronic forms of the disease [79]. Schistosomal glomerulonephritis is classically associated with the hepatosplenic form and ranges from asymptomatic disease to nephrotic syndrome [79]. Renal histopathological analysis evidences immune complex deposition, with schistosomal antigens in the glomerular basement membrane, as well as the presence of schistosomal eggs and granulomas. The mechanism of these lesions includes immunological phenomena, with response directed against parasite's antigens and immune complex formation and deposition in the glomeruli [83–86]. There is also evidence of polyclonal B-lymphocytes activation [87], but it is not sufficient to induce the process of nephritis, so more recent studies suggest the participation of autoimmune mechanisms [88]. The most common pattern of glomerular disease in schistosomiasis is mesangial proliferative and membranoproliferative glomerulonephritis [89, 90]. There are deposits of IgM, IgG, and C3 [91]. Amyloidosis has also been described [79, 92] but is less frequent, although it is always a possible pattern of kidney disease in any infectious disease with chronic evolution. Schistosomal glomerulonephritis can be classified in five types: mesangial proliferative glomerulonephritis, membranoproliferative glomerulonephritis, focal and segmental glomerulosclerosis, exudative glomerulonephritis, and amyloidosis [91]. Granuloma formation in the kidney is also a possible but rare complication of schistosomiasis [92]. Tubular

dysfunction also occurs in schistosomiasis, mainly urinary concentration dysfunction, which can be found in as high as 85% of patients with the hepatosplenic form in endemic areas [93]. Even in patients infected with *S. mansoni*, without clinically significant disease, there is evidence of renal inflammation, which was shown through increased urinary levels of MCP-1 [94].

Treatment is based on specific drugs, the first choice being praziquantel [80, 82], which has action against all *Schistosoma* species and provides cure rates above 80% [82]. The recommended dose is 40 mg/kg for *S. haematobium* and *S. mansoni*, and 60 mg/kg for *S. japonicum* [82].

Table 1 summarizes the main aspects of kidney involvement in the neglected tropical diseases discussed in this chapter.

Figure 1 illustrates the general pathophysiology of kidney involvement in tropical infectious and parasitic diseases.

Disease	AKI	CKD	Histopathological features	Novel biomarkers
Chagas	Yes	Probable, associated with cardiac involvement and heart failure	Deposits of IgM, IgG, C3, mesangial deposits, renal infarction, tubulointerstitial damage, renal infarction	—
Dengue	Yes	Rare	Deposits of IgM, IgG, C3, and less frequently IgA, acute tubular necrosis, glomerulonephritis	—
Leishmaniasis	Yes, associated with drugs, mainly amphotericin B	Possible, associated with amyloidosis and other complications	Deposits of IgM, IgG, C3, different types of glomerulonephritis, most common: mesangial and membranoproliferative, tubulointerstitial lesions, amyloidosis, tubular dysfunction	NGAL, early predictor of AKI, associated with microalbuminuria
Leprosy	Yes	Possible, associated with amyloidosis and other complications	Deposits of IgM, IgG, C3, different types of glomerulonephritis, mainly mesangial and membranoproliferative, but also rapidly progressive glomerulonephritis, tubulointerstitial nephritis, amyloidosis, tubular dysfunction	MCP-1, associated with renal inflammation
Schistosomiasis	Yes	Not common	Deposits of IgM, IgG, C3, different types of glomerulonephritis, mainly mesangial and membranoproliferative, amyloidosis, tubular dysfunction	MCP-1, associated with renal inflammation

AKI: acute kidney injury; CKD: chronic kidney disease; NGAL: neutrophil gelatinase-associated lipocalin; MCP-1: monocyte chemoattractant protein-1.

Table 1. Kidney involvement in neglected tropical diseases.

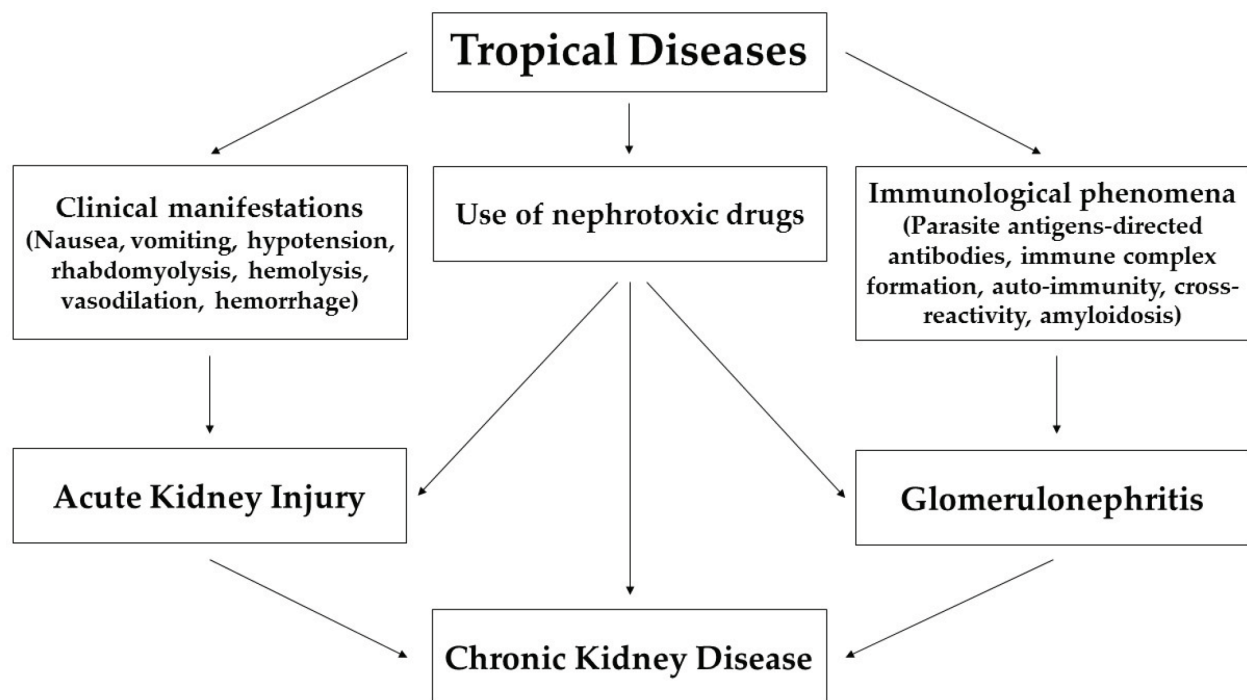


Figure 1. General pathophysiology of kidney involvement in tropical infectious and parasitic diseases.

7. Conclusion

Neglected tropical diseases represent a global public health problem, affecting billions of people and requiring billions of dollars to treat and control. Authorities should have in mind that the key approach to these diseases, including kidney disease itself, is prevention, which is far from ideal, mainly in the developing world. Governments should also have in mind that the main determinant factors for the perpetuation of the neglected tropical diseases in the world in the sum of poor living conditions (lack of sanitation, potable water, piped water, garbage collection, education, domestic animal control, disease-vector control, environmental problems, lack of urbanization plans, and many others), and they have responsibility for the control of these diseases [95]. Many complications can arise from these diseases, and one of the most frequent and severe is kidney disease. The main pathophysiologic factors include immunological phenomena and hemodynamic abnormalities. Endemic diseases, such as dengue, chikungunya, and Zika virus infection, which have affected millions of people in the last few years, are having increasing evidences of kidney involvement in severe cases. In the majority of cases, kidney involvement in these diseases develops as a complication when the patient has poor or delayed access to health care. Research is being conducted to better control these diseases, including vaccine development. Concerning tropical diseases-associated kidney injury, the current “hot-topic” research is to detect this complication through novel biomarkers in order to provide an early and more specific management aiming to avoid or stop renal function loss and then prevent permanent renal insufficiency. Physicians attending patients with tropical diseases should always evaluate renal function, once renal involvement is frequent, and renal recovery is possible if adequate management is provided.

Acknowledgements

We would like to thank our partner institutions, which provided technical support to develop our clinical studies on tropical diseases, in special the Hospital São José de Doenças Infecciosas, Centro de Assistência Toxicológica do Instituto Dr. José Frota, Hospital Geral de Fortaleza, Hospital Universitário Walter Cantídio, and the Edson Queiroz Foundation/University of Fortaleza. We also thank the Conselho Nacional de Desenvolvimento Científico e Tecnológico (CNPq) for providing research grants for our group (GBSJ and EFD—bolsistas de produtividade em pesquisa, PQ-2), and the Fundação Cearense de Apoio ao Desenvolvimento Científico e Tecnológico—FUNCAP, which supports the research on novel kidney injury biomarkers for our study group (edital PPSUS 01/2017).

Conflict of interest

The authors declare there are no conflicts of interest regarding this work.

Author details

Geraldo Bezerra da Silva Junior ^{1*}, Ana Amélia Reis Jereissati¹, Ane Karoline Medina Neri¹, Danielli Oliveira da Costa Lino¹, Juliana Gomes Ramalho de Oliveira¹ and Elizabeth De Francesco Daher²

*Address all correspondence to: geraldobezerrajr@unifor.br

1 University of Fortaleza, Fortaleza, Ceará, Brazil

2 Federal University of Ceará, Fortaleza, Ceará, Brazil

References

- [1] World Health Organization. Neglected Tropical Diseases [Internet]. 2018. Available from: http://www.who.int/neglected_diseases/diseases/en/ [Accessed: 2018-03-29]
- [2] Maudlin I, Holmes PH, Miles MA, editors. The Trypanosomiasis. Wallingford: CABI Publishing; 2004. 614 p. DOI: 10.1079/9780851994758.0000
- [3] Pérez-Molina JA, Molina I. Chagas disease. *Lancet*. 2018;**391**:82-94. DOI: 10.1016/S0140-6736(17)31612-4
- [4] Silva Junior GB, Antunes VVH, Motta M, Barros EJG, Daher EF. Chagas disease-associated kidney injury—A review. *Nefrología Latinoamericana*. 2017;**14**:22-26. DOI: 10.1016/j.nefrol.2016.12.001

- [5] Vinhaes MC, Dias JCD. Chagas disease in Brazil. *Cad Saúde Pública (Rio de Janeiro)*. 2000;**16**:7-12. DOI: 10.1590/S0102-311X2000000800002
- [6] Dias JCP, Ramos Junior AN, Gontijo ED, Luquetti A, Shikanai-Yasuda MA, Coura JR, et al. II Consenso Brasileiro em Doença de Chagas, 2015. *Epidemiologia e Serviços de Saúde*. 2016;**25**:7-86. DOI: 10.5123/s1679-49742016000500002
- [7] Maguire JH. Trypanosoma. In: Gorbach S, Bartlett J, Blacklow N, editors. *Infectious Diseases*. 2nd ed. Philadelphia: Lippincott, Williams & Wilkins; 2004. pp. 2327-2334
- [8] Teixeira ARL, Nascimento R, Sturm NR. Evolution and pathology in Chagas disease—A review. *Memórias do Instituto Oswaldo Cruz*. 2006;**101**:463-491. DOI: 10.1590/S0074-02762006000500001
- [9] Costa RS, Monteiro RC, Lehuen A, Joskowicz M, Noël LH, Droz D. Immune complex-mediated glomerulopathy in experimental Chagas' disease. *Clinical Immunology and Immunopathology*. 1991;**58**:102-114. DOI: 10.1016/0090-1229(91)90152-Z
- [10] Oliveira GM, Masuda MO, Rocha NN, Schor N, Hooper CS, Araújo-Jorge TC, Henriques-Pons A. Absence of Fas-L aggravates renal injury in acute *Trypanosoma cruzi* infection. *Memórias do Instituto Oswaldo Cruz*. 2009;**104**:1063-1071. DOI: 10.1590/S0074-02762009000800002
- [11] Cumbinho LC, Pizzini CC, Oliveira FS, Batista W, Oliveira GM. Cardiorenal interaction during the acute phase of experimental *Trypanosoma cruzi* infection: The influence of aldosteron and the AT1 receptor on mortality. *Journal of Experimental and Integrative Medicine*. 2012;**2**:199-206. DOI: 10.5455/jeim.070512.or.029
- [12] Lemos JRD, Rodrigues WF, Miguel CB, Parreira RC, Miguel RB, Rogerio AP, et al. Influence of parasite load on renal function in mice acutely infected with *Trypanosoma cruzi*. *PLoS One*. 2013;**8**:e71772
- [13] Oliveira GM, da Silva TM, Batista WS, Franco M, Schor N. Acute *Trypanosoma cruzi* experimental infection induced renal ischemic/reperfusion lesion in mice. *Parasitology Research*. 2009;**106**:111-120. DOI: 10.1371/journal.pone.0071772
- [14] Bruijn JA, Oemar BS, Ehrich JH, Oemar BS, Ehrich JM. Anti-basement membrane glomerulopathy in experimental trypanosomiasis. *Journal of Immunology*. 1987;**139**:2482-2488
- [15] Van Velthuysen MLF, Bruijn JA, Van Leer EHG, Fleuren GJ. Pathogenesis of trypanosomiasis-induced glomerulonephritis in mice. *Nephrology, Dialysis, Transplantation*. 1992;**7**:507-515
- [16] Rickman WJ, Cox HW. Association of autoantibodies with anemia, splenomegaly, and glomerulonephritis in experimental African trypanosomiasis. *The Journal of Parasitology*. 1979;**65**:65-73
- [17] Tarleton RL. Chagas disease: A role for autoimmunity? *Trends in Parasitology*. 2003;**19**:447-451. DOI: 10.1016/j.pt.2003.08.008

- [18] Gurugama P, Jayarajah U, Wanigasuriya K, Wijewickrama A, Perera J, Seneviratne SL. Renal manifestations of dengue virus infections. *Journal of Clinical Virology*. 2018;**101**:1-6. DOI: 10.1016/j.jcv.2018.01.001
- [19] McFee RB. Selected mosquito borne illnesses—Dengue. *Disease-a-Month*. DOI: 10.1016/j.disamonth.2018.01.011
- [20] Fares RC, Souza KP, Añez G, Rios M. Epidemiological scenario of dengue in Brazil. *BioMed Research International*. 2015;**2015**:321873. DOI: 10.1155/2015/321873
- [21] Antonio FJ, Itami AS, de Picoli S, Teixeira JJV, Mendes RDS. Spatial patterns of dengue cases in Brazil. *PLoS One*. 2017;**12**:e0180715. DOI: 10.1371/journal.pone.0180715
- [22] Mercado M, Acosta-Reyes J, Parra E, et al. Renal involvement in fatal cases of chikungunya virus infection. *Journal of Clinical Virology*. 2018;**103**:16-18. DOI: 10.1016/j.jcv.2018.03.009
- [23] Amin P, Silva GS, Hidalgo J, Jiménez JIS, Karnad DR, Richards GA. Chikungunya: Report from the task force on tropical diseases by the World Federation of Societies of intensive and critical care medicine. *Journal of Critical Care*. 2018. DOI: 10.1016/j.jcrc.2018.04.004
- [24] Mercado M, Acosta-Reyes J, Parra E, Pardo L, Rico A, Campo A, Navarro E, Viasus D. Clinical and histopathological features of fatal cases with dengue and chikungunya virus co-infection in Colombia, 2014 to 2015. *Euro Surveill*. 2 Jun 2016;**21**(22). DOI: 10.2807/1560-7917.ES.2016.21.22.30244. <https://www.ncbi.nlm.nih.gov/pubmed/27277216>
- [25] Pierrotti LC, Lopes MIBF, Nascimento APD, et al. Chikungunya in kidney transplant recipients: A series of cases. *International Journal of Infectious Diseases*. 2017;**64**:96-99. DOI: 10.1016/j.ijid.2017.09.009
- [26] Chen J, Yang YF, Chen J, et al. Zika virus infects renal proximal tubular epithelial cells with prolonged persistency and cytopathic effects. *Emerging Microbes and Infections*. 2017;**6**(8):e77. DOI: 10.1038/emi.2017.67
- [27] Alcendor DJ. Zika virus infection of the human glomerular cells: Implications for viral reservoirs and renal pathogenesis. *The Journal of Infectious Diseases*. 2017;**216**(2):162-171. DOI: 10.1093/infdis/jix171
- [28] Veronesi R, Focaccia R, editors. *Tratado de Infectologia*. 5th ed. São Paulo: Atheneu; 2015. 2380 p
- [29] Póvoa TF, Alves AMB, Oliveira CAB, Nuovo GJ, Chagas VLA, Paes MV. The pathology of severe dengue in multiple organs of human fatal cases: Histopathology, ultrastructure and virus replication. *PLoS One*. 2014;**9**:e83386. DOI: 10.1371/journal.pone.0083386
- [30] Upadhaya BK, Sharma A, Khaira A, et al. Transient IgA nephropathy with acute kidney injury in a patient with dengue fever. *Saudi Journal of Kidney Diseases and Transplantation*. 2010;**21**:521-525
- [31] Lizarraga KJ, Nayer A. Dengue-associated kidney disease. *Journal of Nephropathology*. 2014;**3**:57-62. DOI: 10.12860/jnp.2014.13

- [32] Lima EQ, Nogueira ML. Viral hemorrhagic fever-induced acute kidney injury. *Seminars in Nephrology*. 2008;**28**:409-415. DOI: 10.1016/j.semnephrol.2008.04.009
- [33] Laoprasopwattana K, Pruekprasert P, Dissaneewate P, et al. Outcome of dengue hemorrhagic fever-caused acute kidney injury in Thai children. *The Journal of Pediatrics*. 2010;**157**:303-309. DOI: 10.1016/j.jpeds.2010.02.008
- [34] Khalil MAM, Sarwar S, Chaudry MA, Maqbool B, Khalil Z, Tan J, Yaqub S, Hussain SA. Acute kidney injury in dengue virus infection. *Clinical Kidney Journal*. 2012;**5**:390-394. DOI: 10.1093/ckj/sfs117
- [35] Mehra N, Patel A, Abraham G, Reddy YN, Reddy YN. Acute kidney injury in dengue fever using acute kidney injury network criteria: Incidence and risk factors. *Tropical Doctor*. 2012;**42**:160-162. DOI: 10.1258/td.2012.120023
- [36] Repizo LP, Malheiros DM, Yu L, et al. Biopsy proven acute tubular necrosis due to rhabdomyolysis in a dengue fever patient: A case report and review of literature. *Revista do Instituto de Medicina Tropical de São Paulo*. 2014;**56**:85-88. DOI: 10.1590/S0036-46652014000100014
- [37] Oliveira JFP, Burdmann EA. Dengue-associated acute Kidney injury. *Clinical Kidney Journal*. 2015;**8**:681-685. DOI: 10.1093/ckj/sfv106
- [38] Boonpucknavig V, Bhamarapravati N, Boonpucknavig S, Futrakul P, Tanpaichitr P. Glomerular changes in dengue hemorrhagic fever. *Archives of Pathology & Laboratory Medicine*. 1976;**100**:206-212
- [39] Costa SD, Silva Junior GB, Jacinto CN, Martiniano LV, Amaral YS, Paes FJ, et al. Dengue fever among renal transplant recipients: A series of 10 cases in a tropical country. *The American Journal of Tropical Medicine and Hygiene*. 2015;**93**:394-396. DOI: 10.4269/ajtmh.15-0038
- [40] Lee TH, Lee LK, Lye DC, Leo YS. Current management of severe dengue infection. *Expert Review of Anti-infective Therapy*. 2017;**15**:67-78. DOI: 10.1080/14787210.2017.1248405
- [41] Robinson ML, Durbin AP. Dengue vaccines: implications for dengue control. *Current Opinion in Infectious Diseases*. 2017;**30**:449-454. DOI: 10.1097/QCO.0000000000000394
- [42] Pace D. Leishmaniasis. *Journal of Infection*. 2014;**69**:S10-S18. DOI: 10.1016/j.jinf.2014.07.016
- [43] Torres-Guerrero E, Quintanilla-Cedillo MR, Ruiz-Esmenjaud J, Arenas R. Leishmaniasis: A review. *F1000Res*. 2017;**6**:750. DOI: 10.12688/f1000research.11120.1
- [44] World Health Organization. Leishmaniasis: epidemiological situation. Available from: <http://www.who.int/leishmaniasis/burden/en/> [Accessed: 2017-08-01]
- [45] Bern C, Desjeux P, Cano J, et al. Leishmaniasis worldwide and global estimates of its incidence. *PLoS One*. 2012;**7**:1-12. DOI: 10.1371/journal.pone.0035671

- [46] Ready PD. Epidemiology of visceral leishmaniasis. *Clinical Epidemiology*. 2014;**6**:147-154. DOI: 10.2147/CLEP.S44267
- [47] van Griensven J, Diro E. Visceral leishmaniasis. *Infectious Disease Clinics of North America*. 2012;**26**:309-322. DOI: 10.1016/j.idc.2012.03.005
- [48] Oliveira RA, Diniz LF, Teotônio LO, Lima CG, Mota RM, Martins A, et al. Renal tubular dysfunction in patients with American cutaneous leishmaniasis. *Kidney International*. 2011;**80**:1099-1106. DOI: 10.1038/ki.2011.251
- [49] Silva Junior GB, Guardão Barros EJ, Daher EF. Kidney involvement in leishmaniasis—A review. *The Brazilian Journal of Infectious Diseases*. 2014;**18**:434-440. DOI: 10.1016/j.bjid.2013.11.013
- [50] Sartori A, De Oliveira AV, Roque-Barreira MC, et al. Immune complex glomerulonephritis in experimental kala-azar. *Parasite Immunology*. 1987;**9**:93-103. DOI: 10.1111/j.1365-3024.1987.tb00491.x
- [51] Salgado Filho N, Ferreira AF, Costa JML. Involvement of the renal function in patients with visceral leishmaniasis (kala-azar). *Revista da Sociedade Brasileira de Medicina Tropical*. 2003;**36**:217-221. DOI: 10.1590/S0037-86822003000200004
- [52] Lima Verde FAA, Daher EF, Dos Santos MG, et al. Renal tubular dysfunction in human visceral leishmaniasis (kala-azar). *Clinical Nephrology*. 2009;**71**:492-500. DOI: 10.5414/CNP71492
- [53] Oliveira MJC, Silva Junior GB, Abreu KL, et al. Risk factors for acute kidney injury in visceral leishmaniasis (kala-azar). *The American Journal of Tropical Medicine and Hygiene*. 2010;**82**:449-453. DOI: 10.4269/ajtmh.2010.09-0571
- [54] Daher EF, Rocha NA, Oliveira MJ, et al. Renal function improvement with pentavalent antimonial agents in patients with visceral leishmaniasis. *American Journal of Nephrology*. 2011;**33**:332-336. DOI: 10.1159/000324914
- [55] Efstratiadis G, Boura E, Giamalis P, Mandala E, Leontsini M, Tsiaouisis G, Memmos D. Renal involvement in a patient with visceral leishmaniasis. *Nephrology, Dialysis, Transplantation*. 2006;**21**:234-235. DOI: 10.1093/ndt/gfi157
- [56] Enriquez R, Sirvent AE, Padilla S, et al. Membranoproliferative glomerulonephritis due to visceral leishmaniasis in an HIV patient. *American Journal of Case Reports*. 2015;**16**:8-11. DOI: 10.12659/AJCR.892641
- [57] Clementi A, Battaglia G, Floris M, et al. Renal involvement in leishmaniasis: A review of the literature. *NDT Plus*. 2011;**4**:147-152. DOI: 10.1093/ndtplus/sfr008
- [58] Elnojomi NA, Musa AM, Younis BM, et al. Surrogate markers of subtle renal injury in patients with visceral leishmaniasis. *Saudi Journal of Kidney Diseases and Transplantation*. 2010;**21**:872-875

- [59] Rocha NA, Oliveira MJ, Franco LF, et al. Comparative analysis of pediatric and adult visceral leishmaniasis in Brazil. *Pediatric Infectious Disease Journal*. 2013;**32**:e182-e185. DOI: 10.1097/INF.0b013e3182814eae
- [60] Libório AB, Rocha NA, Oliveira MJ, et al. Acute kidney injury in children with visceral leishmaniasis. *The Pediatric Infectious Disease Journal*. 2012;**31**:451-454. DOI: 10.1097/INF.0b013e318247f533
- [61] Ichimura T, Bonventre JV, Bailly V, et al. Kidney injury molecule-1 (KIM-1), a putative epithelial cell adhesion molecule containing a novel immunoglobulin domain, is up-regulated in renal cells after injury. *The Journal of Biological Chemistry*. 1998;**273**:4135-4142. DOI: 10.1074/jbc.273.7.4135
- [62] Mishra J, Dent C, Tarabishi R, et al. Neutrophil gelatinase-associated lipocalin (NGAL) as a biomarker for acute renal injury after cardiac surgery. *Lancet*. 2005;**365**:1231-1238. DOI: 10.1016/S0140-6736(05)74811-X
- [63] Kim MJ, Tam FWK. Urinary monocyte chemoattractant protein-1 in renal disease. *Clinica Chimica Acta*. 2011;**412**:2022-2030. DOI: 10.1016/j.cca.2011.07.023
- [64] Meneses GC, Daher EF, Silva Junior GB, Libório AB, Martins AC. Serum neutrophil gelatinase-associated lipocalin levels predict acute kidney injury in visceral leishmaniasis [abstract]. *Journal of the American Society of Nephrology*. 2016;**27**:242
- [65] Lastória JC. Leprosy: Review of the epidemiological, clinical, and etiopathogenic aspects – Part 1. *Anais Brasileiros de Dermatologia*. 2014;**89**:205-218. DOI: 10.1590/abd1806-4841.20142450
- [66] Talhari C, Talhari S, Penna GO. Clinical aspects of leprosy. *Clinics in Dermatology*. 2015;**33**:26-37. DOI: 10.1016/j.clindermatol.2014.07.002
- [67] Grzybowski A, Nita M. Leprosy in the bible. *Clinics in Dermatology*. 2016;**34**:3-7. DOI: 10.1016/j.clindermatol.2015.10.003
- [68] World Health Organization. Leprosy elimination. *Epidemiology*. Available from: <http://www.who.int/lep/epidemiology/en/>. [Accessed: 2018-03-28]
- [69] Silva Junior GB, Daher EF. Renal involvement in leprosy: Retrospective analysis of 461 cases in Brazil. *The Brazilian Journal of Infectious Diseases*. 2006;**10**:107-112. DOI: 10.1590/S1413-86702006000200007
- [70] Daher EF, Silva GB Jr, Cezar LC, Lima RS, Gurjão NH, Mota RM, et al. Renal dysfunction in leprosy: A historical cohort of 923 patients in Brazil. *Tropical Doctor*. 2011;**41**:148-150. DOI: 10.1258/td.2011.100436
- [71] Lomonte C, Chiarulli G, Cazzato F, Giammaria B, Marchio G, Losurdo N, Antonelli M, Casucci F, Basile C. End-stage renal disease in leprosy. *Journal of Nephrology*. 2004;**17**:302-305

- [72] Silva Junior GB, Barbosa OA, Barros RM, Carvalho P d R, Mendoza TR, Barreto DM, et al. Amyloidosis and end-stage renal disease associated with leprosy. *Revista da Sociedade Brasileira de Medicina Tropical*. 2010;**43**:474-476. DOI: 10.1590/S0037-86822010000400031
- [73] Peter KS, Vijayakumar T, Vasudevan DM, Devi KR, Mathew MT, Gopinath T. Renal involvement in leprosy. *Leprosy in India*. 1981;**53**:163-178
- [74] Grover S, Bobhate SK, Chaubey BS. Renal abnormalities in leprosy. *Leprosy in India*. 1983;**55**:286-291
- [75] Sengupta U, Ramu G, Sinha S, Ramanathan VD, Desikan KV. Immunoglobulins in the urine of leprosy patients. *International Journal of Leprosy and Other Mycobacterial Diseases*. 1983;**51**:409-410
- [76] Meneses GC, Libório AB, Daher EF, Silva Juniof GV, Costa MF, Pontes MA, Martins AM. Urinary monocyte chemotactic protein-1 (MCP-1) in leprosy patients: Increased risk for kidney damage. *BMC Infectious Diseases*. 2014;**14**:451. DOI: 10.1186/1471-2334-14-451
- [77] Oliveira RA, Silva GB Jr, Souza CJ, Vieira EF, Mota RM, Martins AM, et al. Evaluation of renal function in leprosy: A study of 59 consecutive patients. *Nephrology Dialysis Transplantation*. 2008;**23**:256-262. DOI: 10.1093/ndt/gfm568
- [78] Polito MG, Moreira SR, Nishida SK, Mastroianni Kirsztajn G. It is time to review concepts on renal involvement in leprosy: Pre- and post-treatment evaluation of 189 patients. *Renal Failure*. 2015;**37**:1171-1174. DOI: 10.3109/0886022X.2015.1057470
- [79] Silva Junior GB, Duarte DB, Barros EJG, Daher EF. Schistosomiasis-associated kidney disease: A review. *Asian Pacific Journal of Tropical Disease*. 2013;**3**:79-84. DOI: 10.1016/S2222-1808(13)60018-3
- [80] Colley DG, Bustinduy AL, Secor WE, King CH. Human schistosomiasis. *Lancet*. 2014;**383**:2253-2264. DOI: 10.1016/S0140-6736(13)61949-2
- [81] Chala B, Torben W. An epidemiological trend of urogenital schistosomiasis in Ethiopia. *Frontiers in Public Health*. 2018;**6**:60. DOI: 10.3389/fpubh.2018.00060
- [82] Barsoum RS, Esmat G, El-Baz T. Human schistosomiasis: Clinical perspective: Review. *Journal of Advanced Research*. 2013;**4**:433-444. DOI: 10.1016/j.jare.2013.01.005
- [83] Duarte DB, Vanderlei LA, de Azevêdo Bispo RK, Pinheiro ME, da Silva Junior GB, De Francesco Daher E. Acute kidney injury in schistosomiasis: A retrospective cohort of 60 patients in Brazil. *The Journal of Parasitology*. 2015;**101**:244-247. DOI: 10.1645/13-361
- [84] Carlier Y, Bout D, Bina JC, Camus D, Figueiredo JF, Capron A. Immunological studies in human schistosomiasis. *The American Journal of Tropical Medicine and Hygiene*. 1975;**24**:949-954
- [85] Madwar MA, Volier A. Circulating soluble antigens and antibody in schistosomiasis. *British Medical Journal*. 1975;**1**:435-436

- [86] Moriearty PL, Brito E. Elution of renal anti-schistosome antibodies in human *Schistosomiasis mansoni*. The American Journal of Tropical Medicine and Hygiene. 1977; **26**:717-722
- [87] Hillyer GV, Lewert RM. Studies on renal pathology on hamsters infected with *Schistosoma mansoni* and *S. japonicum*. The American Journal of Tropical Medicine and Hygiene. 1974; **23**:404-411
- [88] van Velthuysen MLF, Florquin S. Glomerulopathy associated with parasitic infections. Clinical Microbiology Reviews. 2000; **13**:55-66
- [89] Brito T, Gunji J, Camargo ME, Penna DO, Silva LC. Advanced kidney disease in patients with hepatosplenic Mansonii schistosomiasis. Revista do Instituto de Medicina Tropical de São Paulo. 1970; **12**:225-235
- [90] Lambertucci JR, Otoni A, Reis MA. Nephrotic syndrome in hepatosplenic schistosomiasis mansoni. Revista da Sociedade Brasileira de Medicina Tropical. 2007; **40**:492-493. DOI: 10.1590/S0037-86822007000400028
- [91] Brito T, Nussenzveig I, Carneiro CRW, Silva AMG. Schistosoma mansoni associated glomerulopathy. Revista do Instituto de Medicina Tropical de São Paulo. 1999; **41**:269-272. DOI: 10.1590/S0036-46651999000500001
- [92] Barsoum RS. Schistosomal glomerulopathies. Kidney International. 1993; **44**:1-12
- [93] Duarte DB, Vanderlei LA, Bispo RK, Pinheiro ME, da Silva GB Jr, Martins AM, Meneses GC, Daher EdF. Renal function in hepatosplenic schistosomiasis—An assessment of renal tubular disorders. PLoS One. 2014; **9**:e115197. DOI: 10.1371/journal.pone.0115197
- [94] Hanemann AL, Libório AB, Daher EF, Martins AM, Pinheiro MC, Sousa MS, Bezerra FS. Monocyte chemotactic protein-1 (MCP-1) in patients with chronic schistosomiasis mansoni: Evidences of subclinical renal inflammation. PLoS One. 2013; **8**:e80421. DOI: 10.1371/journal.pone.0080421
- [95] Buosi APA, Bezerra RT. A responsabilidade do Estado no controle das doenças negligenciadas: ensaio crítico. 1st ed. Novas edições acadêmicas: Beau Bassin; 2018. p. 52. ISBN: 978-620-2-188-30-2

