

We are IntechOpen, the world's leading publisher of Open Access books Built by scientists, for scientists

4,800

Open access books available

122,000

International authors and editors

135M

Downloads

Our authors are among the

154

Countries delivered to

TOP 1%

most cited scientists

12.2%

Contributors from top 500 universities



WEB OF SCIENCE™

Selection of our books indexed in the Book Citation Index
in Web of Science™ Core Collection (BKCI)

Interested in publishing with us?
Contact book.department@intechopen.com

Numbers displayed above are based on latest data collected.
For more information visit www.intechopen.com



L-PRF: A “Super” Biomaterial for Naturally Guided Hard/Soft Tissue Bioengineering and Regeneration of Oro-Dental, Periodontal and Jaw Defects

Ziyad S. Haidar

Additional information is available at the end of the chapter

<http://dx.doi.org/10.5772/intechopen.78672>

Abstract

Leukocyte and platelet-rich fibrin (L-PRF) is a 3-D autogenous biomaterial derived via simple and rapid centrifugation of whole blood patient samples, in the absence of anti-coagulants, bovine thrombin, additives or any gelifying agents. A relatively new “revolutionary” step in second generation platelet concentrate-based therapeutics, clinical effectiveness of L-PRF remains highly-debatable, whether due to preparation protocol variability, limited evidence-based clinical literature and/or inadequate understanding of its biocomponents. This critical review provides an update on the application of L-PRF during oral surgery procedures, in human Randomized and Controlled Clinical Trials only (up to February 2016). Accordingly, autologous L-PRF is often associated with early bone formation and maturation; accelerated soft-tissue healing; and reduced post-surgical pain and discomfort. L-PRF is a simple, malleable and safe biomaterial suitable for use in oral surgery. An innovative tool in Regenerative Dentistry, L-PRF is a strong alternative and possibly cost-effective biomaterial for oral-tissue regeneration. Preparation protocols require revision and standardization. Furthermore, a good analysis of its rheological properties, biocomponents and their bioactive function would enhance the validity, comprehension and therapeutic potential of the reported findings or observations; a step closer towards a new era of “super” dental biomaterials and bioscaffolds.

Keywords: tissue engineering, regeneration, leukocyte, platelet, fibrin, growth factors, dentistry, oral surgery, periodontology, osteogenesis, grafts

1. Introduction

Despite significant improvements, in reconstruction techniques and materials, during last decades, the regeneration of defects remains a challenge [1]. Indeed, current clinical approaches

used to reconstruct and heal complex defects, including different bone grafting methods, such as autologous bone grafts, allografts, bone-graft substitutes, distraction osteogenesis, and/or guided bone regeneration, are deemed restricted, on a daily basis. This is often multi-factorial; whether due to limited self-renewal capacity of the defect and/or the limited donor supply, increased morbidity, risk of antigenicity and foreign body reactions, associated with the grafts used. Operative-associated time and cost contribute as well. Hence, the art and science of oro-maxillo-facial reconstruction is of great interest for contemporary oral and maxillofacial surgeons; in search for better bioengineering strategies and biomaterials: a core driver for biodental research, today [2].

Briefly, *Platelet Concentrates* are autologous blood extracts obtained through centrifugation of whole blood samples. The preparation procedure allows the gathering and concentration of platelets and other therapeutic blood constituents (fibrinogen/fibrin, growth factors, leukocytes and circulating cells), in clinically-usable preparations (surgical adjuvants), which may enhance, accelerate and promote tissue (hard and soft) wound healing and regeneration [3]. Despite promising clinical observations, their overall effectiveness remains debated to date. This is mainly due to: mixed/variable clinical outcomes, limited high-quality evidence-based literature, and poor characterization of end-products (and preparation protocols) used in studies; and - until recently - lack of proper terminology systems to classify these preparations [4]. Indeed, the first “classification” consensus [5] was published in 2009, describing 4 different Platelet Concentrate sub-families, based on variability in biological content (fibrin and cell), properties (gelification) and potential applications: pure platelet-rich plasma (P-PRP), leukocyte and platelet-rich plasma (L-PRP), pure platelet-rich fibrin (P-PRF) and leukocyte and platelet-rich fibrin (L-PRF) [5]. Today, it can be safely stated that, in oral and maxillofacial surgery, the L-PRF sub-family [4–6] is receiving the most attention, mainly due to simplicity, user-friendliness and cost-effectiveness, when compared to the PRPs.

L-PRF is a second generation autologous platelet concentrate of whole venous blood [4, 6]. A slowly- and strongly-polymerized fibrin gel (**Figure 1**) rich in growth factors, platelets, leukocytes (almost half of the initial blood harvest) and lymphocytes, is collected, following simple and rapid (~10 min) centrifugation (*please note that preparation protocols vary*—**Table 1**) of blood, in vacutainer tubes, without anti-coagulant. The gathered clot (or biomaterial) is stable, resilient, strong, adhesive and malleable, where it can be cut or adapted into different anatomical defects and applications: used directly as filling material, mixed with bone grating material, or compressed into a strong fibrin membrane. Alongside this established clinical ease of use

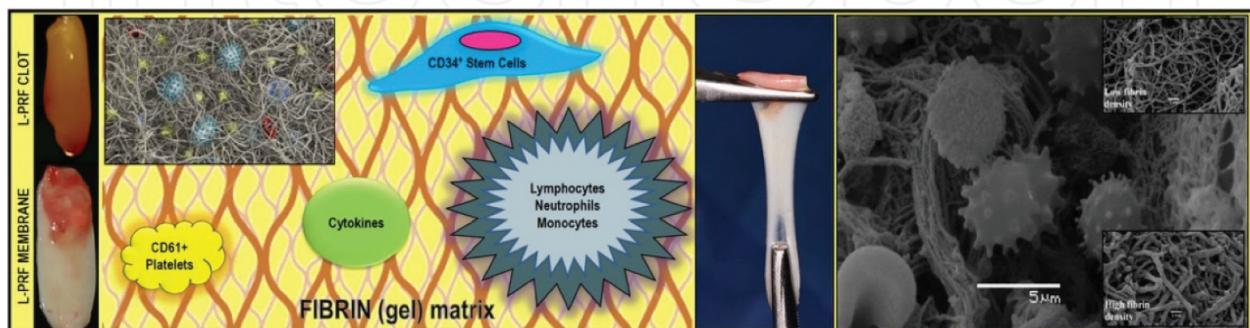


Figure 1. L-PRF clinical presentation and composition/architecture illustration. (A) Clinical presentations of L-PRF clot and membrane. (B) Schematic representation of L-PRF biocomponents. (C) Resiliency and malleability of L-PRF. (D) SEM (scanning Electron microscope) micrograph of the L-PRF membrane displaying its polymerized interconnected fibrin network and large living cell population-content.

For the most reproducible and clinically-usable L-PRF clots and membranes (and best possible clinical outcome), the following protocol is recommended:

Collect a 5-9 mL whole venous blood sample into 2-3 sterile 6 mL glass-coated plastic vacutainer tubes (without anti-coagulant).

Centrifuged immediately for 10-12 minutes at 2700-3000 revolutions per minute (rpm) using a high-quality table centrifuge.

Collect L-PRF clot carefully from the middle portion of the tubes. Typically, three compartments should be evident in the tube - **UPPER:** straw-colored acellular plasma (**PPP**), **MIDDLE:** yellowish fibrin clot (**FC**); and **LOWER:** red-colored lower fraction containing red blood cells (**RBCs**). Remove the upper layer to collect the middle fraction; 2 mm below to the lower dividing line.

The collected clot can then be used directly as filling material, mixed with bone grating material (L-PRF plug/block) or compressed into a strong L-PRF membrane, using a surgical box designed to prepare it without damage (shown in Figure 3A).

REMINDER: Quick handling is critical to obtain bioactive L-PRF clots charged with serum and platelets.




Table 1. Recommendations for L-PRF preparation.

and handling, the biochemical composition of the L-PRF by-products provides it with attractive hemostatic, angiogenic, osteogenic, anti-inflammatory, anti-microbial, pain-inhibitory and wound healing characteristics [3, 7, 8]. This critical review aims to provide the clinical reader with an up-to-date evidence-based presentation on the evaluation of L-PRF use and application for oro-maxillo-facial tissue regeneration, from high-quality Randomized and Controlled Clinical Trials. Thus, *in vitro*, *in vivo* and *case report* studies were excluded from analysis.

2. Materials and methods

A structured literature search (Figure 2) was performed on PUBMED (October 2015–February 2016) using MESH terms “Platelet-rich fibrin” and “Platelet-rich plasma” according to the

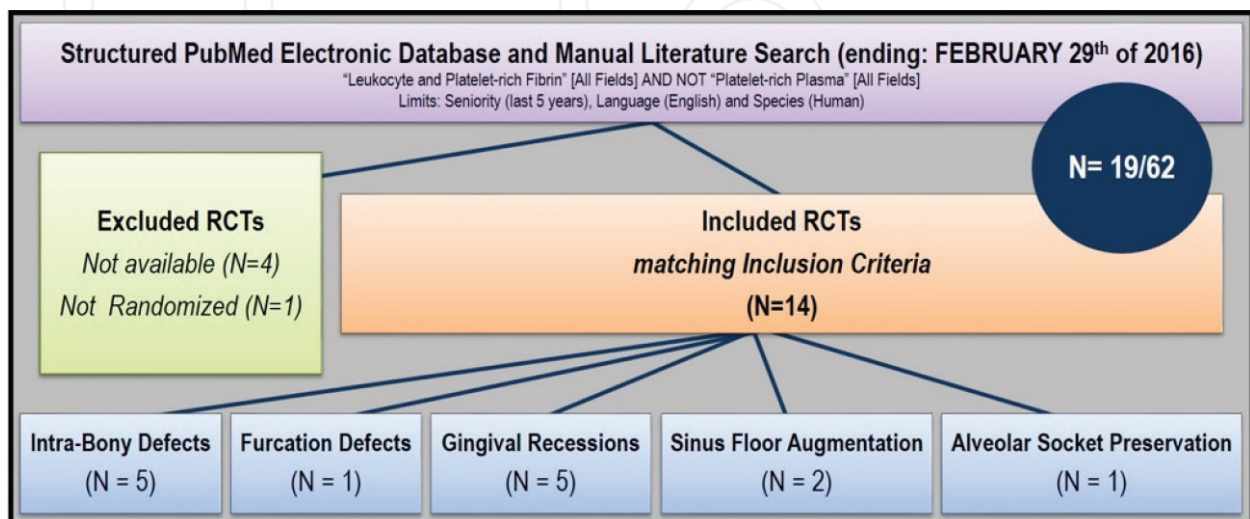


Figure 2. Flow-chart of literature search strategy and results.

Application	N° Patients/Defects	Groups	Follow-up (month)	Main Result	REF
IBD	32/32	1) L-PRF + open flap surgery 2) Open flap surgery	9	All sites healed uneventfully. PD reduction, CAL gain, defect fill, percentage defect fill and post-treatment gingival margin stability were significantly greater in the L-PRF treated group. (P<0.05).	(11)
IBD	15/30	1) L-PRF + open flap surgery 2) Open flap surgery	12	All sites healed uneventfully. PD reduction, CAL gain, radiographic IBD depth reduction and post-treatment gingival margin stability were significantly higher in the L-PRF group. Statistically significant higher patient acceptance and healing index in L-PRF vs. control.	(10)
IBD	35/56	1) L-PRF + open flap surgery 2) Open flap surgery	9	All sites healed uneventfully. PD reduction, CAL gain and radiographic IBD defect fill were significantly higher in the L-PRF group. GMS higher in L-PRF group.	(12)
IBD	17/34	1) L-PRF + Bio-Oss® 2) L-PRF	6	All sites healed uneventfully. Both groups showed significant PD reduction, CAL gain and IBD fill. Intergroup differences were also significant and favored the L-PRF/Bio-Oss group.	(13)
IBD	10/20	1) L-PRF + DFDBA 2) DFDBA	6	Both groups experienced significant PD reduction, CAL gain, IBD fill and IBD resolution. Intergroup differences were statistically significant only for PD reduction and CAL gain favoring the L-PRF/DFDBA group.	(14)
PFD	18/38	1) L-PRF + Open flap surgery 2) Open Flap surgery	9	All sites healed uneventfully. No significant visual differences between groups were noticed. Complete clinical closure was achieved in 66.7% of the defects in the L-PRF group. Within residual furcation defects, 5/6 were reduced from grade II to grade I, and one defect remained grade II. Significantly greater PD reduction, CAL gain and defect-fill was noticed in the L-PRF treated group vs. control.	(16)
Gingival Recession	15/30	1) L-PRF + CAF 2) CAF	6	Both groups experienced statistically significant RD reduction, CAL gain and KTW increase at all time intervals (P<0.05). Intergroup differences were statistically significant and favored the L-PRF group. Mean percentage of root coverage for the test and control group were 100% and 68.44%, respectively. Differences between groups were statistically significant and favored the L-PRF group.	(18)
Gingival Recession	20/67	1) L-PRF + CAF 2) CAF	6	With exception of CAL gain and Gingival Tissue Thickness (GTH) increase, the addition of L-PRF to CAF failed to produce significant additional clinical benefits (vs. CAF-alone). Percentage root coverage, full root coverage, GMS and recession width (RW) reduction were significantly higher in CAF controls than L-PRF treated sites, after 6 months.	(19)
Gingival Recession	20/40	1) L-PRF + CAF 2) EMD + CAF	12	Both groups experienced statistically significant RD reduction, PD reduction and KTW increase. Intergroup differences were significant only for KTW increase and favored the EMD group. Mean root coverage was 70.5 ± 11.76% in the EMD group and 72.1 ± 9.55% in the L-PRF group. Complete root coverage was achieved in 60% of the EMD sites and 65% of the L-PRF sites. <i>No intergroup comparison was carried out.</i> Healing index of the L-PRF group after the first week was significantly superior to that of EMD. Non-significant differences between groups were found after 2 weeks post surgery. Three patients of the EMD group and 1 of the L-PRF group experienced severe pain. All patients in the EMD group reported greater discomfort. Analysis of the first five days post-surgery revealed statistically significant differences between both groups favoring L-PRF (less pain).	(20)
Gingival Recession	22/44	1) L-PRF + CAF 2) SCTG + CAF	6	Both groups experienced a statistically significant decrease in RD, RW, RA plus an increase in CAL gain, KTW and GTH. Intergroup differences were non-significant. Higher yet non-significant gingival margin stability was reported for the L-PRF group. Percentage of root coverage and complete root coverage were 92.7% and 72.7% in the test group and 94.2% and 77.3% in the control group. No statistical significant differences between both groups were found (P>0.05). All sites healed uneventfully however control group reported complications (i.e., pain) related to the palate donor site.	(22)
Gingival Recession	15/30	1) L-PRF + CAF 2) CTG + CAF	6	Both groups experienced a significant CAL gain, RD reduction and GMS. Intergroup differences were non-significant. Both groups experienced a statistically significant increase in KTW. Intergroup differences were statistically significant and favored the CTG group. Mean root coverage for the L-PRF group was 88.68 ± 10.65% and 91.96 ± 15.46% for the control group. Complete root coverage was achieved in 75.85% of cases in the L-PRF group and 79.56% of cases in the control group. Inter-group differences were non-significant. Healing Index values of the L-PRF group during the first two weeks were statistically superior to those of CTG control. One patient from the L-PRF group and 7 of the CTG group experienced severe pain. Also, all patients of the control group reported some discomfort. Pain intensity was statistically superior in the CTG during the first week.	(21)
Maxillary Sinus Augmentation (Graft)	10/11	1) L-PRF + Bio-Oss® 2) Bio-Oss®	6	Healing was uneventful for all patients. Both groups exhibited adequate amount and density of radiographic mineralized tissue plus similar composition, distribution and inflammation of histological structures. Intergroup differences were non-significant. Percentage of newly formed bone was about 1.4 times greater in L-PRF group (18.35 ± 5.62% vs. 12.95 ± 5.33% of control). Percentage of residual bone substitute material was about 1.5 times greater in control group (28.54% ± 12.01% vs. 19.16 ± 6.89% of L-PRF). The bone-to-bone substitute contact was 21.45 ± 14.57% and 18.75 ± 5.39% in L-PRF and control group. Intergroup differences were non-significant.	(26)
Maxillary Sinus Augmentation (Membrane)	6/12	1) L-PRF 2) Bio-Gide®	5	Wound healing was uneventful for all patients. No soft tissue in-growths were observed in both groups. Surfaces seemed homogenous with visible bone-substitute material embedded into newly-formed bone. Average amount of vital bone and bone substitute were 17.0% and 15.9% in the L-PRF group. Control group had 17.2% and 17.3%. <i>No intergroup comparisons were carried out.</i>	(27)
Alveolar Socket Preservation	20/40	1) L-PRF 2) Empty (blood clot)	3	Soft tissue healing was significantly better in L-PRF group vs. controls (Laundry, Turnbull and Howley Soft Tissue Healing Index). Early bone formation/maturation was noticed for experimental sites vs. controls. Differences were significant only at 8 weeks post-extraction and favored L-PRF group. Higher bone density was noticed in L-PRF group vs. controls. Intergroup differences were non-significant. Mean post-surgical pain (measured by VAS score) was reduced in L-PRF group vs. non-L-PRF controls; at day 1. By day 7 no intergroup differences were noticed.	(31)

Table 2. Summary of clinical literature (RCTs) on L-PRF use in dentistry.

following search strategy: "Platelet-rich fibrin" [All Fields] NOT "Platelet-rich plasma" [All Fields]. Results were limited by: Seniority (5 years since publication), Language (English), Availability (Full-text) and Species (Human). Inclusion criteria were: (a) randomized clinical trials (RCTs) using (b) Choukroun's L-PRF (not PRF) in (c) Oro-Maxillo-Facial procedures. Initial search resulted in 62 articles, 19 of which met the inclusion criteria (**Table 2**). Five articles were excluded due to quality/availability lack of randomization. Due to the high heterogeneity, results are presented in a narrative format.

3. Results and discussion

3.1. L-PRF in the treatment of periodontal intrabony defects (IBDs)

Periodontal tissue regeneration has been defined as the formation of new cementum, alveolar bone, and a functional periodontal ligament on a previously-diseased tooth-supporting root surface. Due to limited intrinsic regenerative potential, IBDs are a common and challenging sequel of periodontal disease. Meta-analyses demonstrated that, treatment with conservative open flap debridement, produces an Average Clinical Attachment (CAL) gain of 2.0 mm [9]. While about 1.5 mm may be attributed to newly formed bone; bone-fill does not implicate the regeneration of new attachment to the root [9]. In this context, L-PRF appears promising for regeneration of the whole periodontal attachment system (**Figure 3A and B**). Five RCTs addressing the prospective application of L-PRF in the treatment of Periodontal IBD were found. The identified studies allowed for the following comparisons: (a) L-PRF/Open flap surgery vs. Open flap surgery [10–12], (b) L-PRF/Bio-Oss® constructs (Bio-Oss®, Geistlich Pharma North America, Inc.) vs. L-PRF [13] and (c) L-PRF/DFDBA constructs vs. DFDBA (Demineralized Freeze-Dried Bone Allograft) [14]. All patients included in those studies were periodontally stable and systemically healthy individuals who presented: similar bilateral IBD of at least 5 mm probing depth, located in vital asymptomatic teeth with no furcation involvement. Studies evaluating the addition of L-PRF to conventional open flap procedure reported the biomaterial notably improving both, clinical and radiographic parameters of IBDs, after 9 [11, 12] and 12 months [10]. A significant increase in probing depth (PD) reduction, CAL gain, post-treatment.

Gingival Margin Stability [(GMS) *less post-treatment gingival recession*], bone defect fill and percentage bone defect fill were noticed in all L-PRF-treated sites vs. controls [10–12]. Interestingly, higher patient acceptance was also associated with use of L-PRF. Most probably, this is attributed to the accelerated wound healing and pain-inhibitory properties [10, 11]. The presented PD reduction and CAL gain values were superior to previously-reported values in meta-analysis performed for open flap surgery [9], suggesting the additional benefits of L-PRF over the conventional approach. Treatment with L-PRF/particulate bone-graft substitutes (Bio-Oss® [13] and DFDBA [14]) provided additional statistically-significant benefits, in terms of PD reduction, CAL gain and bone defect fill vs. graft substitutes, after 6 months. Nonetheless, the absence of "simultaneously-run" L-PRF-alone control renders it difficult to

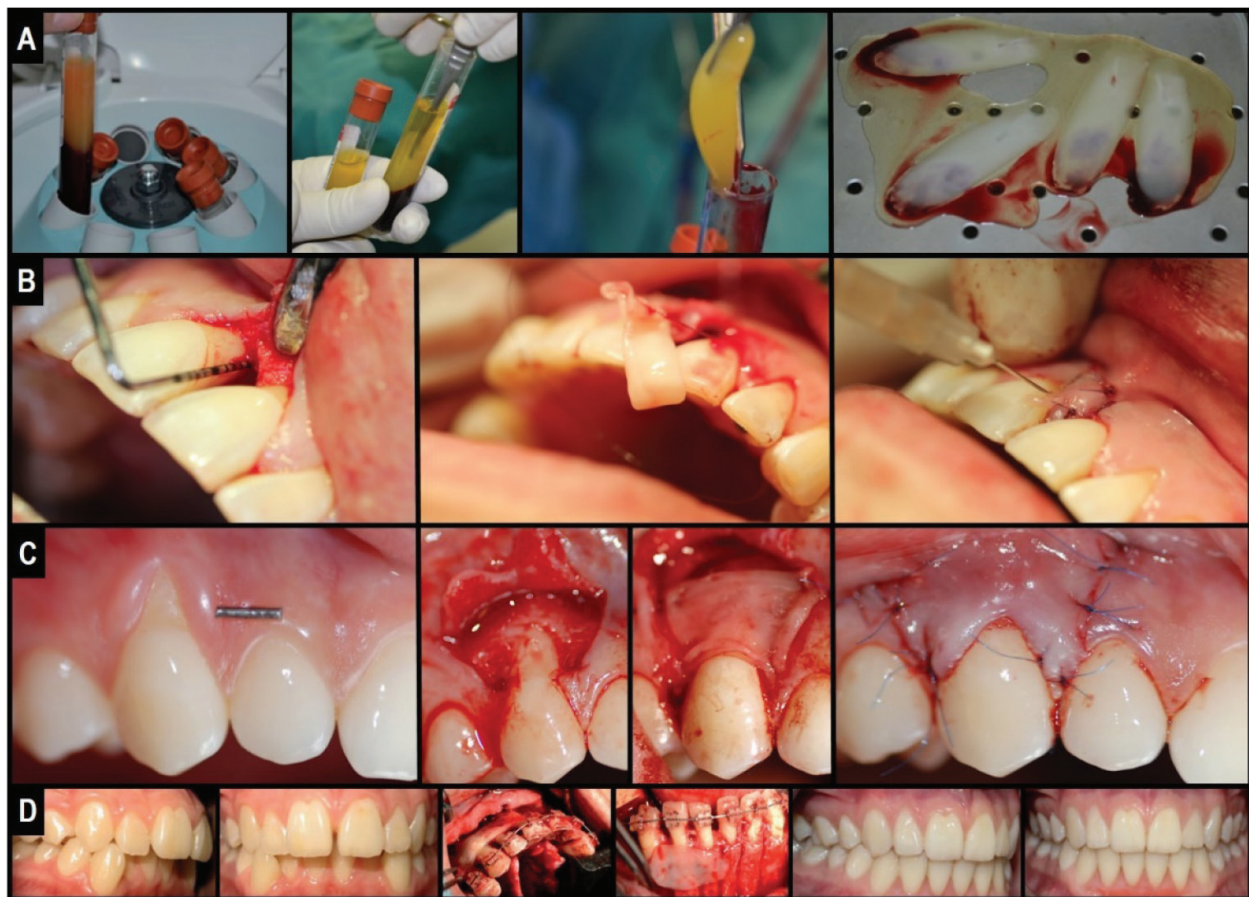


Figure 3. Clinical illustration of L-PRF application in Oro-Maxillo-facial surgery defect regeneration: Natural guided tissue bioengineering using L-PRF as a “bio-scaffold”. (A) L-PRF membrane preparation. (B) Clinical application in IBD. (C) Clinical application under CAF. (D) Clinical application in PAOO.

distinguish between the effects of L-PRF and other potential variables in the study. Thus, while promising, additional studies are deemed essential in order to appropriately determine (quantifiably) the effectiveness and advantages of L-PRF application over particulate bone-grafts use.

3.2. L-PRF in the treatment of periodontal furcation defects (PFDs)

Molars with furcation involvement (resulting from periodontitis) have higher rates of periodontal breakdown and poorer prognosis, than single-rooted teeth [15]. Contemporary treatment options often include the use of regenerative materials and bone grafts; however, the introduction of L-PRF seems promising for better therapeutic outcomes. In our analyses, 1 RCT addressing the therapeutic use of L-PRF in PFDs was found [16]. The study compared L-PRF/open flap vs. open flap debridement alone, in the treatment of grade II mandibular defects. Included patients were periodontally-stable and systemically healthy, with similar bi-lateral grade II buccal furcation defects (at least 5 mm probing depth and ≥ 3 mm horizontal probing depth), in vital asymptomatic mandibular first molars.

L-PRF use significantly improved clinical and radiographic parameters of conventional open flap debridement. After 9 months, complete clinical closure of the defect was achieved in

66.7% of L-PRF-treated sites. Severity within residual defects was reduced in 5/6 sites (degree I), whereas one defect remained in degree II. Significantly greater PD reduction, CAL gain and radiographic vertical defect fill was reported on experimental sites vs. controls. L-PRF use was also associated with a greater post-treatment GMS [16].

3.3. L-PRF in the treatment of miller class I and II gingival recessions

Gingival recessions are characterized by the apical migration of the gingival margin with subsequent root surface exposure. If left untreated, the condition may lead to other problems including: deficient esthetics, dentine hypersensitivity and higher risk of dental caries [17]. Available treatment options include the use of: (a) Coronally Advanced Flaps (CAF); (b) Connective Tissue Grafts (CTG); and (c) Sub-epithelial Connective Tissue Grafts (SCTG). On their own, the aforementioned techniques have important limitations such as (a) unpredictable long-term root coverage (i.e. CAF decreases from 89% to 58.8% after 6 months), (b) limited gain of keratinized tissue width (KTW); important to prevent recurrence, and (c) adverse post-surgical effects such as pain/discomfort, swelling, flap necrosis, etc. [17]. In this review, five RCTs evaluating the application of L-PRF in the treatment of gingival recessions were identified and included. The studies allowed for the following comparisons: (a) L-PRF/CAF vs. CAF [18–19]; (b) L-PRF/CAF vs. EMD (Enamel Matrix Derivate)/CAF [20]; (c) L-PRF/CAF vs. CTG [21]; and (d) L-PRF/CAF vs. SCTG [22]. Similar to previous RCTs, all patients included herein were periodontally-stable and systemically healthy; presented with: similar bi-lateral Miller Class I or II gingival recessions (>2 mm depth) localized on vital teeth, without restorations. According to Padma et al., the addition of L-PRF to CAF improved both, clinical outcomes and post-treatment stability of CAF [18]. After 6 months, the authors reported (significantly) more Recession Depth (RD) reduction, CAL gain and KTW increase in all L-PRF-treated sites vs. controls. Interestingly, post-treatment GMS was also higher in the test group with 100% root coverage after 6 months vs. 64.88% in controls [18]. However, in contrary with this RCT, Aroca et al. reported limited clinical benefits when using the L-PRF/CAF approach [19]. Herein, CAL gain and Gingival Tissue Thickness (GTH) were the only benefiteres of the combination; whereas percentage root coverage, full root coverage, GMS and Recession Width (RW) reduction were significantly higher in CAF-alone controls than the test group [19]. Such "contradictory" results may be partially explained by deficient study design, which, not only failed to adequately include blind examiners (leading to potential bias in favor of the "traditional" approach), yet also included: multiple adjacent gingival recessions (with poorer prognosis than single/localized recessions); heavy smokers (in which healing response is usually altered); and the L-PRF were stored in a 4°C refrigerator until use (L-PRF protocols often recommend immediate/fresh use). Indeed, emerging evidence states that growth factor release from L-PRF initiates as early as 5 min from preparation/centrifugation. Hence, storage could have altered its properties and thereby diminished or deteriorated its clinical potential. When compared to other root coverage procedures (EMD/CAF, CTG and SCTG), the L-PRF/CAF approach showed similar clinical outcomes regarding RD reduction, CAL gain, mean root coverage (%) and complete root coverage (%). KTW increase was the only exception, with both EMD/CAF and CTG controls showing higher KTW than L-PRF-treated groups [20–22]. Interestingly, all studies reported significantly faster healing and fewer complications (pain and discomfort) when L-PRF was used [20–22]. Findings are notable, especially when

comparing with SCTG (the current “*gold standard*” technique for treating Miller Class I and II gingival recessions); indicating that L-PRF/CAF could be a safer and less invasive alternative to current grafting techniques, and a more cost-effective strategy or approach than EMD is in treating Miller Class I and II gingival recessions (**Figure 3C**).

3.4. L-PRF in sinus floor augmentation

Resorption of the upper jaw bone after tooth loss is a frequent problem faced in posterior maxillary implant placement due to lack of sufficient bone mass for anchorage. Common maxillary sinus augmentation techniques provide a solution via increasing the available bone height at the expense of sacrificing volume of the maxillary sinus [23]. Traditionally, autologous bone grafts and resorbable membranes are used to promote osteogenesis and avoid soft tissue in-growth into the surgical site. However, donor site morbidity and size restrictions, latter resorption of the graft and high-cost of membranes, are main disadvantages [24, 25]. In this context, L-PRF appears to provide a promising alternative overcoming such limitations. In this review, two RCTs evaluating the use of L-PRF in lateral window sinus augmentation were found. Applications were performed either as: (a) grafting material (L-PRF/Bio-Oss® constructs vs. Bio-Oss®) [26] or (b) absorbable covering membrane for the lateral osteotomy window (L-PRF vs. Geistlich Bio-Gide®) [27]. In both studies, included subjects were systemically healthy adults with maxillary atrophy (defined as <5 mm residual bone crest height measured in OPG/orthopantomogram). Smoking status was not assessed. The addition of L-PRF to Bio-Oss® bone-substitute revealed neither advantages nor disadvantages over Bio-Oss®-alone controls [26]. After 6 months, clinical and radiographic examinations revealed both groups exhibiting similar amounts and density of mineralized tissues, with no signs of material resorption. Histological evaluations also showed non-significant differences regarding: (a) percentage of newly formed bone, (b) percentage of residual Bio-Oss®, (c) bone-to-bone-substitute contact, and (d) post-treatment inflammatory reactions [26]. Regarding coverage of lateral osteotomy sinus window, L-PRF use resulted in a similar amount of vital bone formation (%) and residual bone-substitute when compared to Bio-Gide® controls (L-PRF: 17.0 and 15.9%, Bio-Gide®: 17.2 and 17.3%, differences are not statistically-significant). Overall, despite a slightly superior to no coverage at all (12.1%), it can be stated that results were similar to those reported using other conventional membranes (collagen: 17.6%; e-PTFE: 16.9%) [27]. Within the presented limitations in both RCTs, evidence suggests that L-PRF is a safe, simple to use and handle, and cost-effective alternative to traditional bone grafts and absorbable membranes; in low-income patients, pursuing maxillary sinus augmentation procedures.

3.5. L-PRF in alveolar ridge preservation

Post-extraction changes in alveolar bone compromise prosthodontic rehabilitation with fixed, removable and/or implant-supported prosthesis. Alveolar Ridge Preservation (ARP) is a technique which involves the use of grafting and barrier materials in order to significantly reduce post-extraction bone loss [28]. L-PRF has been demonstrated to accelerate/enhance bone repair [29, 30], promote fibroblast proliferation [3, 30] and increase vascularity [31]; thereby potentially favoring the post-extraction healing process and the ARP approach. Yet, a single

RCT evaluating the use of L-PRF in ARP was identified, according to the inclusion criteria set herein [32]. This sole study compared the application of L-PRF vs. natural blood clots in post-extraction sockets of third molars. Patients were systemically healthy and non-smoking adults requiring bi-lateral mandibular third molar removal. The use of L-PRF significantly improved post-extraction soft tissue healing after 7 days [32]. Early and significantly-higher radiographic bone formation/maturation was noticed in the L-PRF treated sites vs. controls, at 8 weeks. By 12 weeks, inter-group differences were non-significant. Radiographic bone density (measured by gray scale value) at 12 weeks increased in the biomaterial group compared to controls, nonetheless, the differences were not significant [32]. Similar to other studies, L-PRF reduced early post-surgical pain (VAS scale) on day 1; however inter-group differences were not significant by day 7 [32].

3.6. Personal expertise: L-PRF in periodontally accelerated osteogenic orthodontics

In our own pilot prospective observational study [30] involving a cohort of 11 patients (with informed consent) receiving a Wilcko’s modified **PAOO** (Periodontally Accelerated Osteogenic Orthodontics—*a somewhat new surgical procedure which allows faster tooth movement via combining orthodontic forces with corticotomy and grafting of alveolar bone plates*) technique with L-PRF (incorporated into the graft and as covering membrane), accelerated wound healing with no signs of infection or adverse reactions was evident (**Figure 3D**). Post-surgical pain, inflammation and infection were recorded for 10 days post-operatively, while the overall orthodontic treatment and post-treatment stability were followed up to 2 years. In our data analysis, post-surgical pain was found to be either “mild” (45.5%) or “moderate” (54.5%); immediate post-surgical inflammation was recorded as either “mild” (89.9%) or “moderate” (9.1%); and, resolution was marked to begin on day 4 where most patients experienced either “mild” or no inflammation (72.7 and 9.1%, respectively). Interestingly, complete resolution was achieved in all patients by day 8, the average orthodontic treatment time was calculated at 9.3 months and all cases were stable throughout. Thus, we concluded that combining L-PRF with traditional bone grafts (L-PRF plug or block) potentially accelerates wound healing and reduces post-surgical pain, inflammation and infection without interfering with tooth movement and/or post-orthodontic stability, over an extended 2-year observational period; thereby alleviating the need for analgesics and anti-inflammatory medications [30].

4. Conclusions and closing remarks

Tissue regeneration and anatomical reconstruction in defects of the oro-maxillo-facial complex have been always a critical and controversial issue. Both, quality and quantity of the regenerated tissues are important to consider, esthetically and functionally. Practically, the surgeon is faced with an ample collection of regenerative techniques and materials to choose from. *How can one select the “ideal” or “best-fit” strategy and procedure for an optimal clinical outcome? Evidence-based studies? Level of evidence?* To the best of our knowledge, this is the first review of Randomized Controlled Clinical Trials on L-PRF use and application in Oral

Surgery. While the available literature is found to be highly-limited, L-PRF *can be* indicated as an innovative *tool* for contemporary oro-maxillo-facial tissue regeneration and bioengineering. Indeed, existing evidence suggests that L-PRF improves early wound healing and promotes post-surgical bone formation/maturation. However, it is noteworthy that a clearer consensus seems to be present regarding its significant beneficial impact on post-surgical pain and discomfort control, regardless the type of procedure. Unlike its predecessors, new L-PRF preparations tend to function more as biologically-active biomaterials and scaffolds for the delivery of autologous cells, cytokines and growth factors.

Thus, L-PRF should be considered a “living tissue” preparation for natural guided tissue regeneration and not simply a “growth factor-rich” surgical adjuvant. Yet, it is safe to say that this remains an un-explored territory in Dental Biomaterial (Dental Bioengineering) Research, in general.

Our group is currently investigating the potential of incorporating oral-derived mesenchymal stem cells or growth-factor embedded nanoparticles within the L-PRF, as “*super*” or “*smart*” bio-scaffolds, to further boost, with predictability, bone formation, soft tissue healing, treatment time and post-surgical stability, in advanced oro-maxillo-facial surgical procedures such as Periodontally-Accelerated Osteogenic Orthodontics.

Our research extends to investigate the potential of L-PRF in reducing the need for prescription drugs following invasive surgical procedures such as third molar extraction and cysts resections.

Finally, we are vigorously working on characterizing the rheological and biological variations of L-PRF, alongside partnering up with nurses, physicians and dentists to standardize the preparation protocol, for use in other therapeutic indications.

Acknowledgements

Dr. Nelson Pinto for providing the SEM micrographs and Dr. Macarena Llompart for providing the clinical photographs for L-PRF use in periodontics (**Figure 3B/C**).

Conflicts of interest

The author of this review article declares having no conflict of interest of any form or nature with any platelet concentrate product, protocol, technique or company.

Funding

This work was supported by generous funding and operating grants provided to the BioMATX Research Group, part of CIIB (Centro de Investigación e Innovación Biomédica), through

the Faculty of Dentistry and PMI (Plan de Mejoramiento Institucional en Innovación I+D+i), Department for Research, Development and Innovation, Universidad de los Andes, Santiago de Chile. The author acknowledges supplementary operating funding provided from CONICYT-FONDEF Chile under awarded project/grant (national) # **ID16I10366** (2016–2019) and Fondo de Ayuda a la Investigación FAI - Universidad de los Andes No. **INV-IN-2015-101** (2015–2019).

Author details

Ziyad S. Haidar^{1,2,3,4*}

*Address all correspondence to: zhaidar@uandes.cl

1 BioMAT'X, Facultad de Odontología, Universidad de los Andes, Santiago, Chile

2 Plan de Mejoramiento Institucional (PMI) en Innovación I+D+i, Universidad de los Andes, Santiago, Chile

3 Programa de Doctorado en BioMedicina, Facultad de Medicina, Universidad de los Andes, Santiago, Chile

4 Centro de Investigación e Innovación Biomédica, Facultad de Medicina, Universidad de los Andes, Santiago, Chile

References

- [1] Habibovic P, de Groot K. Osteoinductive biomaterials—Properties and relevance in bone repair. *Journal of Tissue Engineering and Regenerative Medicine*. 2007;**1**:25-32. DOI: 10.1002/term.5
- [2] Haidar ZS. NanoDentistry: Perspectives on the role of NanoBiotechnology in biomaterials, pharmaceuticals and BioDental tissue engineering. *EC Dental Science*. 2015;**3**:506-507
- [3] Dohan DM, Choukroun J, Diss A, Dohan SL, Dohan AJJ, Mouhyi J, Gogly B. Platelet-rich fibrin (PRF): A second-generation platelet concentrate. Part II: Platelet-related biologic features. *Oral Surgery, Oral Medicine, Oral Pathology, Oral Radiology, and Endodontics*. 2006;**101**:e45-e50. DOI: 10.1016/j.tripleo.2005.07.009
- [4] Del Corso M, Vervelle A, Simonpieri A, Jimbo R, Inchingolo F, Sammartino G, Dohan Ehrenfest DM. Current knowledge and perspectives for the use of platelet-rich plasma (PRP) and platelet-rich fibrin (PRF) in oral and maxillofacial surgery. Part 1: Periodontal and dentoalveolar surgery. *Current Pharmaceutical Biotechnology*. 2012;**13**:1207-1230
- [5] Dohan Ehrenfest DM, Rasmusson L, Albrektsson T. Classification of platelet concentrates: From pure platelet-rich plasma (P-PRP) to leucocyte- and platelet-rich fibrin (L-PRF). *Trends in Biotechnology*. 2009;**27**:158-167. DOI: 10.1016/j.tibtech.2008.11.009
- [6] Simonpieri A, Del Corso M, Vervelle A, Jimbo R, Inchingolo F, Sammartino G, Dohan Ehrenfest DM. Current knowledge and perspectives for the use of platelet-rich plasma

- (PRP) and platelet-rich fibrin (PRF) in oral and maxillofacial surgery. Part 2: Bone graft, implant and reconstructive surgery. *Current Pharmaceutical Biotechnology*. 2012;**13**:1231-1256
- [7] Dohan DM, Choukroun J, Diss A, Dohan SL, Dohan AJJ, Mouhyi J, Gogly B. Platelet-rich fibrin (PRF): A second-generation platelet concentrate. Part III: Leucocyte activation: A new feature for platelet concentrates? *Oral Surgery, Oral Medicine, Oral Pathology, Oral Radiology, and Endodontics*. 2006;**101**:e51-e55. DOI: 10.1016/j.tripleo.2005.07.010
- [8] Bielecki T, Dohan Ehrenfest DM, Everts PA, Wiczowski A. The role of leukocytes from L-PRP/L-PRF in wound healing and immune defense: New perspectives. *Current Pharmaceutical Biotechnology*. 2012;**13**:1153-1162
- [9] Lang NP. Focus on intrabony defects—Conservative therapy. *Periodontology*. 2000;**22**: 51-58
- [10] Rosamma Joseph V, Raghunath A, Sharma N. Clinical effectiveness of autologous platelet rich fibrin in the management of infrabony periodontal defects. *Singapore Dental Journal*. 2012;**33**:5-12. DOI: 10.1016/j.sdj.2012.10.003
- [11] Thorat M, Pradeep AR, Pallavi B. Clinical effect of autologous platelet-rich fibrin in the treatment of intra-bony defects: A controlled clinical trial: Platelet-rich fibrin and periodontal regeneration. *Journal of Clinical Periodontology*. 2011;**38**:925-932. DOI: 10.1111/j.1600-051X.2011.01760.x
- [12] Sharma A, Pradeep AR. Treatment of 3-wall intrabony defects in patients with chronic periodontitis with autologous platelet-rich fibrin: A randomized controlled clinical trial. *Journal of Periodontology*. 2011;**82**:1705-1712. DOI: 10.1902/jop.2011.110075
- [13] Lekovic V, Milinkovic I, Aleksic Z, Jankovic S, Stankovic P, Kenney EB, Camargo PM. Platelet-rich fibrin and bovine porous bone mineral vs. platelet-rich fibrin in the treatment of intrabony periodontal defects: Xenograft and platelet-rich fibrin in intrabony defects. *Journal of Periodontal Research*. 2012;**47**:409-417. DOI: 10.1111/j.1600-0765.2011.01446.x
- [14] Bansal C, Bharti V. Evaluation of efficacy of autologous platelet-rich fibrin with demineralized-freeze dried bone allograft in the treatment of periodontal intrabony defects. *Journal of Indian Society of Periodontology*. 2013;**17**:361-366. DOI: 10.4103/0972-124X.115663
- [15] Goldman MJ, Ross IF, Goteiner D. Effect of periodontal therapy on patients maintained for 15 years or longer. A retrospective study. *Journal of Periodontology*. 1986;**57**:347-353. DOI: 10.1902/jop.1986.57.6.347
- [16] Sharma A, Pradeep AR. Autologous platelet-rich fibrin in the treatment of mandibular degree II furcation defects: A randomized clinical trial. *Journal of Periodontology*. 2011;**82**:1396-1403. DOI: 10.1902/jop.2011.100731
- [17] Cortellini P, Pini Prato G. Coronally advanced flap and combination therapy for root coverage. Clinical strategies based on scientific evidence and clinical experience. *Periodontology* 2000. 2012;**59**:158-184. DOI: 10.1111/j.1600-0757.2011.00434.x

- [18] Padma R, Shilpa A, Kumar PA, Nagasri M, Kumar C, Sreedhar A. A split mouth randomized controlled study to evaluate the adjunctive effect of platelet-rich fibrin to coronally advanced flap in Miller's class-I and II recession defects. *Journal of Indian Society of Periodontology*. 2013;**17**:631-636. DOI: 10.4103/0972-124X.119281
- [19] Aroca S, Keglevich T, Barbieri B, Gera I, Etienne D. Clinical evaluation of a modified coronally advanced flap alone or in combination with a platelet-rich fibrin membrane for the treatment of adjacent multiple gingival recessions: A 6-month study. *Journal of Periodontology*. 2009;**80**:244-252. DOI: 10.1902/jop.2009.080253
- [20] Jankovic S, Aleksic Z, Milinkovic I, Dimitrijevic B. The coronally advanced flap in combination with platelet-rich fibrin (PRF) and enamel matrix derivative in the treatment of gingival recession: A comparative study. *The European Journal of Esthetic Dentistry*. 2010;**5**:260-273
- [21] Jankovic S, Aleksic Z, Klokkevold P, Lekovic V, Dimitrijevic B, Kenney EB, Camargo P. Use of platelet-rich fibrin membrane following treatment of gingival recession: A randomized clinical trial. *The International Journal of Periodontics & Restorative Dentistry*. 2012;**32**:e41-e50
- [22] Eren G, Atilla G. Platelet-rich fibrin in the treatment of localized gingival recessions: A split-mouth randomized clinical trial. *Clinical Oral Investigations*. 2014;**18**:1941-1948. DOI: 10.1007/s00784-013-1170-5
- [23] Boyne PJ, James RA. Grafting of the maxillary sinus floor with autogenous marrow and bone. *Journal of Oral Surgery*. 1980;**38**:613-616
- [24] Cordaro L. Bilateral simultaneous augmentation of the maxillary sinus floor with particulated mandible. Report of a technique and preliminary results. *Clinical Oral Implants Research*. 2003;**14**:201-206. DOI: 10.1034/j.1600-0501.2003.140210.x
- [25] Van den Bergh JP, ten Bruggenkate CM, Krekeler G, Tuinzing DB. Sinusfloor elevation and grafting with autogenous iliac crest bone. *Clinical Oral Implants Research*. 1998;**9**:429-435
- [26] Zhang Y, Tangl S, Huber CD, Lin Y, Qiu L, Rausch-Fan X. Effects of Choukroun's platelet-rich fibrin on bone regeneration in combination with deproteinized bovine bone mineral in maxillary sinus augmentation: A histological and histomorphometric study. *Journal of Cranio-Maxillo-Facial Surgery*. 2012;**40**:321-328. DOI: 10.1016/j.jcms.2011.04.020
- [27] Gassling V, Purcz N, Braesen JH, Will M, Gierloff M, Behrens E, Açil Y, Wiltfang J. Comparison of two different absorbable membranes for the coverage of lateral osteotomy sites in maxillary sinus augmentation: A preliminary study. *Journal of Cranio-Maxillo-Facial Surgery*. 2013;**41**:76-82. DOI: 10.1016/j.jcms.2012.10.015
- [28] Hämmerle CHF, Araújo MG, Simion M, Osteology Consensus Group. Evidence-based knowledge on the biology and treatment of extraction sockets. *Clinical Oral Implants Research*. 2011;**2012**(23):80-82. DOI: 10.1111/j.1600-0501.2011.02370.x

- [29] Pripatnanont P, Nuntanaranont T, Vongvatcharanon S, Phurisat K. The primacy of platelet-rich fibrin on bone regeneration of various grafts in rabbit's calvarial defects. *Journal of Cranio-Maxillo-Facial Surgery*. 2013;**41**:e191-e200. DOI: 10.1016/j.jcms.2013.01.018
- [30] Munoz F, Jiménez C, Espinoza D, Vervelle A, Beugnet J, Haidar Z. Use of leukocyte and platelet-rich fibrin (L-PRF) in periodontally accelerated osteogenic orthodontics (PAOO): Clinical effects on edema and pain. *Journal of Clinical and Experimental Dentistry*. 2016;**8**:e119-e124. DOI: 10.4317/jced.52760
- [31] Chen Y, Niu Z, Xue Y, Yuan F, Fu Y, Bai N. Improvement in the repair of defects in maxillofacial soft tissue in irradiated minipigs by a mixture of adipose-derived stem cells and platelet-rich fibrin. *The British Journal of Oral & Maxillofacial Surgery*. 2014;**52**:740-745. DOI: 10.1016/j.bjoms.2014.06.006
- [32] Singh A, Kohli M, Gupta N. Platelet rich fibrin: A novel approach for osseous regeneration. *Journal of Maxillofacial and Oral Surgery*. 2012;**11**:430-434. DOI: 10.1007/s12663-012-0351-0. © 2018 by the authors. Submitted for possible open access publication under the terms and conditions of the Creative Commons Attribution (CC BY) license (<http://creativecommons.org/licenses/by/4.0/>)