

# We are IntechOpen, the world's leading publisher of Open Access books Built by scientists, for scientists

4,800

Open access books available

122,000

International authors and editors

135M

Downloads

Our authors are among the

154

Countries delivered to

TOP 1%

most cited scientists

12.2%

Contributors from top 500 universities



WEB OF SCIENCE™

Selection of our books indexed in the Book Citation Index  
in Web of Science™ Core Collection (BKCI)

Interested in publishing with us?  
Contact [book.department@intechopen.com](mailto:book.department@intechopen.com)

Numbers displayed above are based on latest data collected.  
For more information visit [www.intechopen.com](http://www.intechopen.com)



---

# Carbon Fibers in Biomedical Applications

---

Naveen Kumar, Anil Kumar Gangwar and  
Khangembam Sangeeta Devi

Additional information is available at the end of the chapter

<http://dx.doi.org/10.5772/intechopen.75826>

---

## Abstract

Three-dimensional growth of fibroblasts on carbon fibre mesh and assessment of biocompatibility by *in vitro* and *in vivo* examination was done. Suitable size carbon fiber mesh after sterilization, placed in six well cell culture plate. The mesh was co-cultured with p-MEF cells. At different time intervals the viability and proliferation of the p-MEF cells was evaluated. The primary objective of this study was biological evaluation of carbon fibre mesh which can be used for creation of three-dimensional scaffolds for tissue engineering. Among the possible forms of implants, fibrous matrices are highly promising for the tissue regeneration by acting as a cell-supporting scaffold. Results of *in vitro* observations of the morphology p-MEF cells seeded on the surface of carbon fibre mesh shows adhesions and attachment of fibroblasts cells to carbon fibres on day 3 post seeding. They attached firmly and were uniformly spread along the fibres on day 5 postseeding and mostly spindle-shaped and cover almost all their surface on day 7 postseeding and such a spreading of cells indicates good adhesions and biocompatibility of carbon fibres. *In vivo* examination of retrieved sample on day 30 post implantation shows that carbon fibre mesh was covered by dense thick fibrous connective tissue.

**Keywords:** carbon fibers, carbon fiber mesh, primary mouse embryo fibroblasts (p-MEF), *in vitro* examination, *in vivo* examination

---

## 1. Introduction

Carbon fiber (CF) consists of a multitude of unique physical, chemical and biological characteristics that can be utilized and exploited for a number of diverse applications. Being light weight, high strength, and chemically stable, so they are applied in various fields including aeronautical

science and space science. Investigation of applications of carbon fibers to biomaterials was started 30 or more years ago, and various products have been developed. It is used widely in imaging equipment structures to support limbs being X-rayed or treated with radiation.

Carbon fiber is frequently supplied in the form of a continuous tow wound onto a reel. The tow is a bundle of thousands of continuous individual carbon filaments held together and protected by an organic coating, or size, such as polyethylene oxide (PEO) or polyvinyl alcohol (PVA). Each carbon filament in the tow is a continuous cylinder with a diameter of 5–10 micrometers and consists almost exclusively of carbon. The earliest generation had diameters of 16–22 micrometers and later fibers have diameters that are approximately 5 micrometers. Precursors for carbon fibers are polyacrylonitrile (PAN), rayon and pitch.

The latest technological progress has realized nanolevel control of carbon fibers, applications to biomaterials have also progressed to the age of nanosize. Carbon fibers with diameters in the nanoscale (carbon nanofibers) dramatically improve the functions of conventional biomaterials and make the development of new composite materials possible. Carbon nanofibers also open possibilities for new applications in regenerative medicine and cancer treatment. The first three-dimensional constructions with carbon nanofibers have been realized, and it has been found that the materials could be used as excellent scaffolding for bone tissue regeneration. We have developed an innovative approach for the use of CF as a scaffold in the repair of tendon and ligaments and as a suture material for repair of hernial ring.

Carbon as an inert element has advantages over other materials because it is a basic constituent of tissues. The high proportion of tissues of living organisms is composed of carbon compounds so it should be tolerated by the tissues. Over the past 25 years various carbon materials have been investigated in many areas of medicine [1, 2].

The physical and chemical properties of CFs are also determined by their microstructure. This is particularly important in the case of CFs used in medicine. One of the earliest medical uses of CFs was replacement or repair of ligaments and tendons [3–5]. Most of the studies on carbon fibrous implants confirm that CFs do not inhibit tissue growth, and thus can act as a scaffold for tissue proliferation [3, 6]. Controversy surrounds the mechanism of the disintegration and removal of the implanted CFs. A histological study showed that the CFs gradually broke down and migrated into the nearest lymph nodes with no apparent detrimental effect [6]. In all instances the CFs acted as a scaffold that allowed the regeneration of tendon and ligament. In contrast to these investigations, Morris et al. [7] showed that fragmentation of fibers did not occur and implant debris was not found in the regional nodes. Moreover, CFs induced significantly more tissue ingrowth than polypropylene mesh at 6–12 months postoperatively. A probable elimination mechanism by erosion of carbon particles and their retention in the fibrous capsule surrounding the implant [8]. Although the results of most investigations of CFs in vivo were evaluated as good, several authors were skeptical as to the superiority of carbon fibrous implants over other prosthetic materials [9, 10]. Carbon fibers were considered to be a good candidate biomaterial for total hip replacement and internal fixation in the form of composites [11]. In spite of controversial results with CFs used for replacement and reconstruction of ligaments and tendons, several other clinical studies were undertaken. The different results obtained in evaluating CFs as a biomaterial can probably be explained by the

use of different types of carbon fibers of different physical, structural and chemical properties, resulting from many technological parameters. Most of the papers concerning examinations of CFs for medical purposes describe neither the type of carbon fibers used nor their fundamental properties determining their behavior in a biological environment. We will discuss the use of carbon fibers in biomedical applications under different headings:

- In vitro biocompatibility evaluation
- In vivo biocompatibility evaluation
  - Subcutaneous implantation of carbon fibers
  - Carbon fibers in repair of abdominal wall defects
  - Carbon fiber mesh in reconstruction of abdominal wall defects
  - Carbon fibers for gap repair of flexor tendons
- Clinical applications

## 2. In vitro biocompatibility evaluation

### 2.1. Introduction

Tissue engineering is the process of creating functional three dimensional (3-D) tissue by combining cells with scaffolds to facilitate cell growth, organization and differentiation. The most important aspect of tissue engineering is the adhesion and proliferation of cells on scaffold material. Biocompatibility of CFs has been the subject of numerous researches. Some of investigators concluded that CFs induces the growth of new tissue [12]. However, there were also announcements questioning biocompatibility of CFs [13–15]. The different opinions regarding biocompatibility of CFs may be explained by the use of different types of CFs of different physical, structural and chemical properties, resulting from many technological parameters [15, 16]. It has been demonstrated that the cellular response to the fibrous carbon material depends on the degree of crystallinity of the material; therefore only selected types of CFs are suitable for tissue treatment purposes [16–18].

The fibroblasts are common cells present in the connective tissue that synthesizes and continuously secretes precursors of extra cellular matrix. Fibroblasts play an important role in regeneration of new tissue due to their growth accelerating property of tissue cells by secreting several growth factors and extra cellular matrix (ECM). Primary mouse embryonic fibroblasts (p-MEFs) have a number of properties making them an attractive cell culture model. Compared to other primary explant cultures they are easy to establish and maintain, proliferate rapidly resulting in large numbers of cells produced from a single embryo within several days. Major histocompatibility complex (MHC) Class II antigens are present on the transplanting cells which is responsible for graft rejection. Fibroblasts lack these surface molecules and this makes them relatively immunologically inert.

In the present study, carbon fiber mesh was cut in desired size and after sterilization, placed in six well cell culture plates. The mesh was co-cultured with p-MEF cells. At different time intervals the viability and proliferation of the MEF cells was evaluated. The primary objective of this study was biological evaluation of carbon fiber mesh which can be used for creation of three-dimensional scaffolds for tissue engineering. Carbon fiber used as scaffold for tissue regeneration could simultaneously serve as a support for drug delivery or biologically active agents which would stimulate the tissue growth. Therefore, in this study, we investigated the behavior of carbon fiber mesh in biological environments and their interaction with cells and tissues under in vitro and in vivo conditions.

## 2.2. Materials and methods

In vitro tests in cell cultures were performed in Biomaterials and Bioengineering Laboratory, Division of Surgery, Indian Veterinary Research Institute, Izatnagar, Uttar Pradesh, India. Prior to cell culture, the carbon fiber mesh was autoclaved at the temperature of 120°C for 30 min. The primary mouse embryo fibroblasts culture (p-MEF) was done as per standard protocol. The cells obtained were washed twice with DMEM containing antibiotics and were centrifuged at 2500 rpm for 8–10 min. The cells were resuspended in cell growth media (DMEM-Low glucose) containing 10% FBS and antibiotics (Mixture of 100 units/ml penicillin and 100 µg/ml streptomycin). The cells were counted countess cell counting kit (Invitrogen) and plated at an average of  $2.2 \times 10^5$  cells/cm<sup>2</sup> in T-25 flasks. They were maintained at 37°C in a humidified atmosphere of 5% CO<sub>2</sub> in CO<sub>2</sub> incubator. Day after the primary culture, the spindle shaped fibroblast cells were observed and the non-adherent/dead cells were removed by changing the medium. When the cells attained 80–90% confluency (as assessed by observing under inverted microscope, the cells were passaged into new culture flask. Culture medium was removed and cells were washed twice with HBSS (with antibiotic). The cells were detached from the culture flask by using 2 ml of 0.5% of trypsin. The trypsin activity was stopped by adding equal volume of culture medium containing FBS and flushed properly to get the attached cells in the suspension.

After the primary culture, when adherent cells reached to 90% confluency, they were detached with 0.25% trypsin-EDTA solution. Growth medium i.e. DMEM containing 10% fetal bovine serum was added and mixed properly to get single cell suspension. The carbon fiber mesh was cut into small pieces and washed 4–5 times with antibiotics containing Dulbecco's Modified Eagle Medium (DMEM) and was placed in wells of the culture plate. The cells were seeded at the rate of  $2 \times 10^4$  cells/cm<sup>2</sup>. It was maintained at 37°C in a humidified atmosphere of 5% CO<sub>2</sub> in a CO<sub>2</sub> incubator. The growth media was changed after 48 h. The seeded mesh was observed and processed for morphological assessment on day 3, 5 and 7 postseeding. Morphological examination was performed using Scanning Electron Microscopic Examination. The seeded mesh was fixed in 2% glutaraldehyde for SEM examination.

## 2.3. Results and discussion

A good amount of p-MEF cells were cultured from a single pregnant mouse. Cells were plated in a T-25 flask. A large number of spherical cells were observed under phase contrast microscope. Cells were maintained in CO<sub>2</sub> incubator and observed daily under inverted

phase contrast microscope to assess the viability and proliferation of cells. The cells showed characteristic growth and adherence pattern in vitro and proliferated rapidly to complete the monolayer in 4 days. The morphology of in vitro cultured cells clearly indicated the presence of primary mouse embryo fibroblasts. Effects of the tested materials on the adhesion, growth and morphology of cells on the fibers were evaluated by SEM examination.

Morphology of carbon fiber mesh showed that carbon fibers filaments were closely woven. In vitro observations of the morphology of cells seeded on the surface of carbon fiber mesh showed that they attached firmly and were uniformly spread along the fibers on day 5 post seeding and mostly spindle-shaped. They cover almost all their surface on day 7 post seeding and such a spreading of cells indicates good adhesions and biocompatibility of carbon fibers. The assumption that carbon as the fundamental element in biological tissues would not induce adverse reactions encouraged scientists to use carbon fibers in medicine as the implantable biomaterial [18]. In the field of regenerative medicine carbon materials are becoming increasingly attractive as they can be modified to be integrated into human bodies for promotion of tissue regeneration and treatment of various diseases.

### **3. In vivo biocompatibility evaluation**

#### **3.1. Subcutaneous implantation of carbon fibers**

##### *3.1.1. Materials and methods*

Carbon fibers and mesh were implanted subcutaneously on either side of the spine in four Wistar rats. Animals were anesthetized using xylazine and ketamine anesthetic combination. The animals were restrained in sternal recumbency. Dorsal thoracic area was prepared for aseptic surgery. On either side of the spine 1 cm long skin incision was given lateral to the spine on both left and right side and subcutaneous pouches were created. The implants were pushed in the pockets and the skin incision was closed with simple interrupted sutures using polyamide suture no 1-0. The Carbon fibers and mesh were retrieved back on day 30 post-operatively. The retrieved implants were preserved in 10% formalin saline solution. The tissues were processed by routine paraffin embedding technique and the sections were cut at 5 micron thickness. The sections were stained with hematoxylin and eosin (H & E) stain.

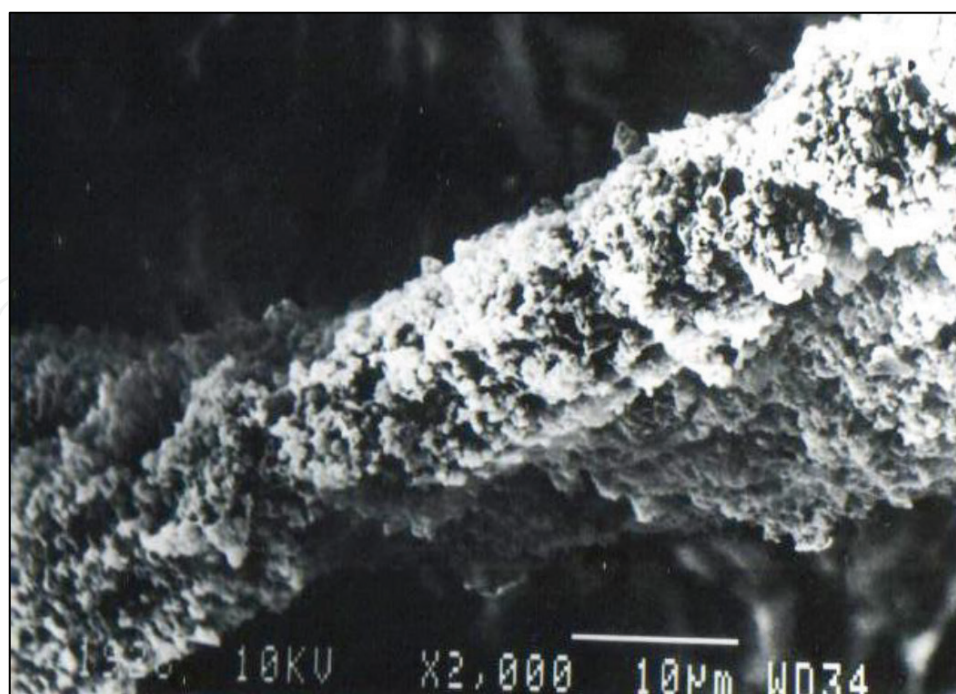
##### *3.1.2. Results and discussion*

Retrieved sample on day 30 post implantation shows that carbon fibers and mesh were covered by dense thick fibrous connective tissue. Complications like infection or pus formation was not seen in the vicinity of any implanted biomaterials. The tissue response to implanted materials was more pronounced as observed in SEM examination. The implant was agglomerated and surrounded with granulation tissue. Individual carbon fiber was adhered with thick granulation tissue which included different types of cells and shows high biocompatibility of carbon fibers which was clearly observed in high magnification (**Figure 1**).

In histopathological examination foreign body-type multinucleated giant cells were observed to be accompanied with some eosinophils and mast cells. The structure of the muscle tissue surrounding the implant was regular. There was increased number of fibroblasts at day 30 post implantation. Histological observation revealed that carbon fibers stimulated extensive fibrocellular reaction with minimal infiltration of inflammatory cells at the site.

Based on microscopic observations we have confirmed that adhesion of cells to carbon fiber mesh. According to in vivo studies, carbon fiber mesh due to their porosity enables more efficient growing of cells and connective tissue within the structure of implant. Biocompatibility of carbon fibers has been the subject of numerous researches, however individual researchers implemented it in their own experiments without further physical and chemical characterization, and also without specifying the sterilization methods, so that cases of toxic effects of fiber degradation products on the human body were also reported [19–21].

Carbon fibers in many cases were well tolerated by the recipient and did not cause the around foreign body reactions [16]. Moreover the tendon or ligament newly developed on a carbon scaffold was morphologically very similar and functionally identical to the replaced natural structure [22]. It has been demonstrated by the later studies that the cellular response to the fibrous carbon material depends on the degree of crystallinity of the material; highly crystalline, high modulus fibers are not suitable for medical purposes, while amorphous fibers are excellent for implants [16]. Grabinski et al. [23] reported that toxicity of carbon materials depends also of dimensions and after 24 h the carbon nanotubes showed increased cellular toxicity when compared to the carbon fibers and carbon nanofibers. Our results clearly demonstrated the excellent biocompatibility of those carbon fibers; however, they also clearly



**Figure 1.** SEM examination showing individual carbon fiber adhered with thick granulation tissue having different types of cells.

confirmed that biological activity is even more desirable. Three thousand filaments of carbon fibers were used to reconstruct the experimentally created full thickness linear abdominal wall defects in rabbits [24].

### **3.2. Carbon fibers in repair of abdominal wall defects**

#### *3.2.1. Introduction*

The successful reconstruction of abdominal wall defect is challenge to surgeon. Prosthetic materials like small intestine mucosa [25], human dura mater [26], polyester fabric [27], expanded polytetrafluoroethylene [28] have been used in reconstruction of large abdominal wall defects. Problems peculiar to each of these prosthetic materials have reduced prolonged and widespread clinical acceptance. Ideally, carbon fiber not only provides structural strength, but also acts as a scaffold on which the body may lay down collagen to complete the repair particularly in long term [29]. Braided carbon fibers have a place in the repair of tendon [30, 31]. So we have studied the carbon fibers in repair of abdominal wall defect in rabbits.

#### *3.2.2. Materials and methods*

Sixteen New Zealand white rabbits of either sex were randomly divided into two equal groups (group I and II) of 8 animals. Mid ventral abdominal region was chosen for the purpose of study. Food for 18 h and water for 6 h was withheld before operation. The ventral abdominal area was prepared for aseptic surgery and the operation was performed under general anesthesia. The animals were retained in dorsal recumbency. After skin incision a linear full thickness defect of 3 cm in the mid ventral aspect of abdominal wall was created and repaired with continuous suture pattern using 3000 filaments of carbon fiber and 1-0 black braided nylon, in-group I and II, respectively. Injection streptopenicillin @ 100 mg/kg body wt. and Injection diclofenac sodium @ 2 mg/kg body wt. were given intramuscularly for 3 days in all animals. The surgical wound was cleaned with povidone iodine and dressed daily with antiseptic ointment. Skin sutures were removed till the completion of skin healing.

#### *3.2.3. Results and discussion*

Surgical wounds appeared apparently healthy throughout the period of observation in both the groups. None of the wound showed any complication like gaping or infection. Gross observations at day 7 shows more vascularity around carbon fibers at the site and on day 30, the carbon fibers were covered by white fibrous tissue. On day 60 the carbon fibers including knots were completely buried under the newly formed tissue. Carbon fibers were well tolerated macroscopically with no evidence of infection or sinus formation. Increased vascularity observed in the present study at the site repaired with carbon fibers was also observed by Kumar et al. [31] following reconstruction of superficial digital flexor tendon with carbon fibers in crossbred calves. Increased vascularity at the reconstruction site is the normal response to injury which is essential for reabsorption of clot and dead cells and finally in the



laying down of fibrous tissue [32]. Uniform covering of prosthetic material with a layer of white connective tissue of variable thickness due to formation of fibrous connective tissue and subsequently laying of collagen fibers was observed [27].

On the contrary, in group I, the carbon fiber implant in the rabbit abdominal wall defect had induced extensive fibrous tissue (collagen fiber) reaction. The inflammatory cells were almost found negligible in the stroma, which indicates the host tissue tolerance to carbon fibers as described by Kumar [33]. The deposition of more collagen fibers in the healing tissue and chronic cell reaction adjacent to the carbon fibers/fibrils along with macrophages, few foreign body giant cells and microgranulomas have similarly been observed by earlier workers in relation to carbon fibers and Mersilene mesh [29, 34]. Subsequent to repair of abdominal wall defect with PTFE and Marlex mesh similar findings were also reported [35]. The chronic cellular reaction persisted throughout the observation period of 90 days in the form of microgranulomas and foreign body giant cells around carbon fibrils [31].

### **3.3. Carbon fiber mesh in reconstruction of abdominal wall defects**

#### *3.3.1. Introduction*

A large abdominal wall defect presents a difficult problem for the surgeon. Conventional techniques involving no artificial reinforcement of the abdominal wall run a high risk of recurrence. In repairing the large abdominal wall defects, surgeons have used prosthetic materials of different composition and structures to replace lost tissue [36]. Carbon fibers have been used successfully for reconstruction of tendon [30, 31]. It elicits a strong stimulus to collagen formation and grows stronger with age [37]. Ideally, carbon fibers not only provide structural strength, but also act as a scaffold on which the body may lay down collagen to complete the repair process, particularly in long term [29]. Keeping in view the possible advantage of carbon fibers, the present study was conducted for reconstruction of abdominal wall defects with carbon mesh in rabbits.

#### *3.3.2. Materials and methods*

Clinically healthy adult New Zealand white rabbits (12) of either sex were divided randomly into groups I and II having 8 animals in group I and 4 animals in group II (control). Mid-ventral abdominal region was chosen for the purpose of study. Food for 18 h and water for 6 h was withheld before operation. The ventral abdominal area was prepared for aseptic surgery and operation was performed under general anesthesia. Thiopental sodium (2.5%) was injected intravenously in the ear vein "to effect" for anesthesia. A full thickness 2 × 3 cm defect in mid-ventral abdominal wall was created and immediately repaired with carbon mesh in animals of group I. The carbon mesh was prepared from the carbon sheet. The carbon sheet was cut in desired shape and size. The carbon mesh was washed in acetone and autoclaved before use. In animals of group II the linear abdominal muscular wall incision was made and repaired with black braided nylon. Daily dressing of suture line with povidone iodine was done till recovery.

### 3.3.3. Results and discussion

Collagen and hydroxyproline content increased gradually up to 30 days in both the groups. However, significant ( $P < 0.05$ ) increase was observed up to day 60 in group I and up to day 30 in group II animals. Elastin percentage increased in the healing tissue in both the groups up to 30th day. On the basis of the present study it can be concluded that the carbon mesh can be used for the reconstruction of large abdominal wall defects. Carbon fibers were used for the repair of experimental large abdominal incisional hernias in sheep [34]. The carbon fibers were well tolerated by animals and no herniation was reported in 20 sheep repaired with carbon fibers. Greenstein et al. [38] used polylactic acid carbon mesh for repair of experimentally created ventral hernias in rats. In another experimental study fascial defects in dogs were repaired with carbon fibers. Bilateral defects (1 cm square) were made in the fascia of the back and mechanical strength and stiffness at the sites were measured 3–12 months after operation. Defects repaired with carbon fibers were significantly stronger 12 months after operation compared with defects repaired with polypropylene mesh and unrepaired defects [39]. It is concluded that carbon fiber mesh act as biocompatible material and significantly increases mechanical strength at the repair site. It stimulated fibroplasias, resulted in strong fibrous reaction at the site. Experimental results in animals have been reported but on perusal in literature no report was found using carbon fiber mesh for the repair of external abdominal hernias in clinical cases.

## 3.4. Carbon fibers for gap repair of flexor tendons

### 3.4.1. Introduction

Formation of gap between cut ends and peritendinous adhesions after surgical repair are the major problems in tendon reconstruction. Carbon fibers have been used to fill the gap between the cut ends of the tendon in horses, rabbits, dogs, sheep and donkey. Biocompatibility and non-carcinogenicity coupled with the ability to sustain tissue growth are the rationale for the utilization of filamentous carbon as a synthetic substitute. Carbon as an inert element has advantages over other materials because it is a basic constituent of tissues. The high proportion of the tissues of living organisms is composed of carbon compounds so it is well tolerated by the tissues. An ideal biomaterial is that “instead of fighting” biology it should “smoothly integrate into living tissue.” The present study describes the use of carbon fibers for gap repair of tendon.

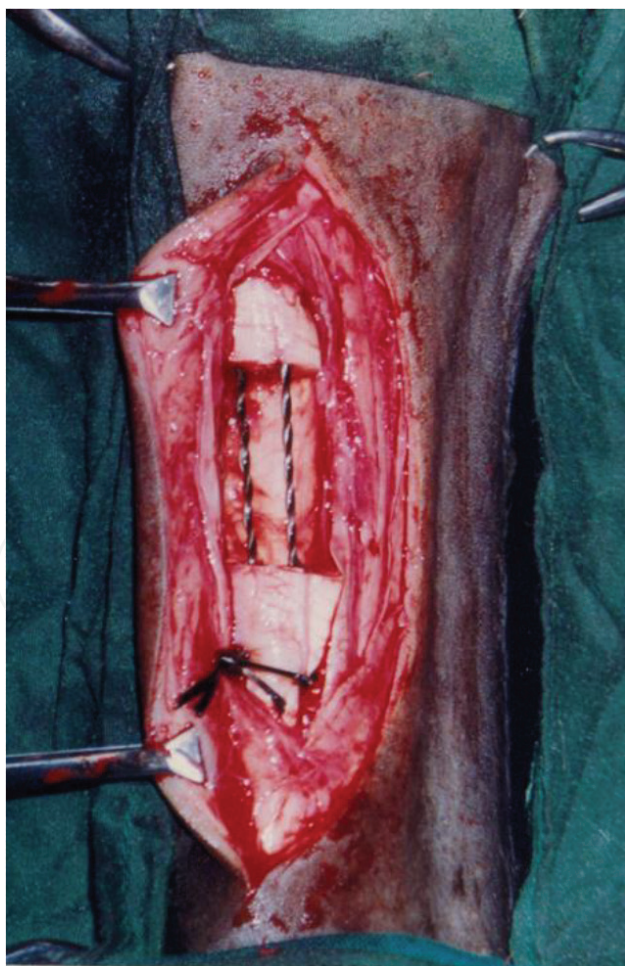
### 3.4.2. Materials and methods

Twenty-four tenorrhaphies were performed at the mid-metatarsal region in 12 crossbred calves under xylazine–ketamine spinal analgesia having 6–18 months of age and weighing 120–250 kg. A 2.5-cm long gap was created in the superficial digital flexor (SDF) tendon and immediately repaired with carbon fibers. About 3000 carbon fibrils (diameter of each filament was 7.5 micron) were taken and allowed to recoil upon themselves to form a two ply twist implant of 6000 carbon fibrils filament. They were threaded in straight cutting suturing needle with fine nylon suture material used to tow these carbon fibers. This implant was

washed with acetone for 2 min before autoclaving. Under epidural anesthesia a curvilinear incision was made at mid medial metatarsal region and superficial digital flexor tendon (SDF) was exposed. A 2.5 cm long defect was created in the SDF. The cut ends of SDF tendon were repaired with carbon fibers using modified locking loop suture pattern (**Figure 2**). The skin incision was closed with nylon sutures. Both the hind limbs were utilized for the study. The animals were evaluated on the basis of clinical, radiological, gross, histopathological and scanning electron microscopic observations.

### 3.4.3. Results and discussion

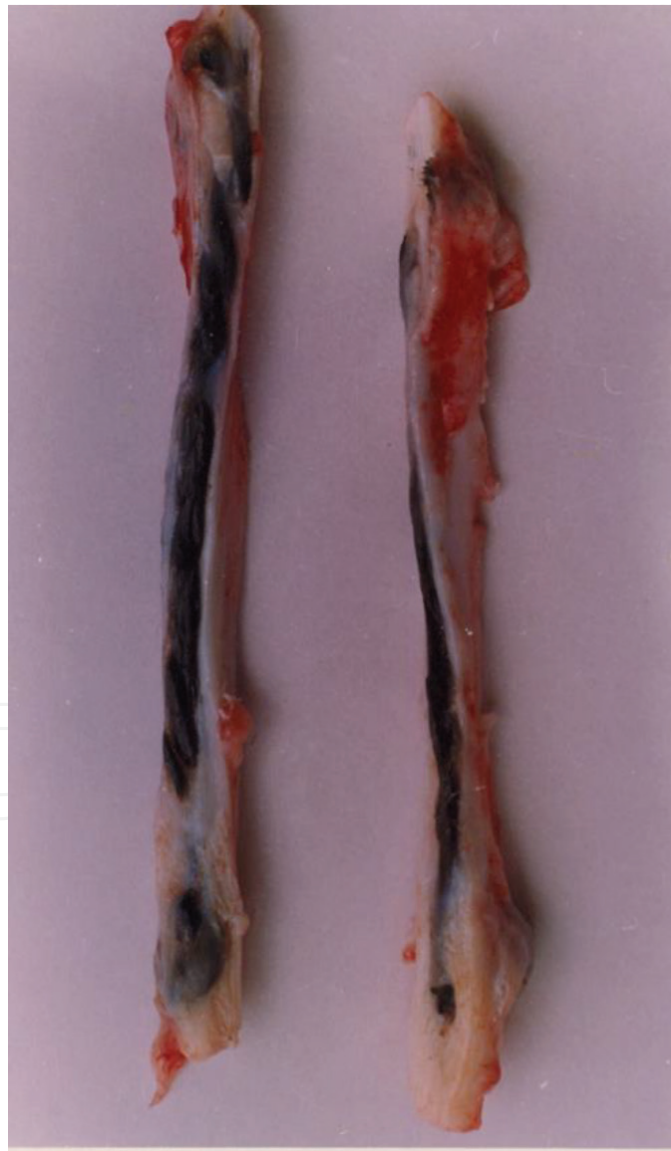Clinical examination revealed a slight increase ( $P > 0.05$ ) in rectal temperature, heart and respiratory rate for 2–4 days post-operation. Milder pain and exudation as well as earlier restoration of tendon gliding movements and weight bearing were seen. Air-tendogram in the carbon fiber group on day 30 revealed restoration of continuity across the defect of the tendon. Regression of peritendinous adhesions and swelling at the reconstructed site at later stages was observed indicative by the clear demarcation among these structures. On day 90 the tendon at the reconstructed site attained near normal thickness and density. Angiography



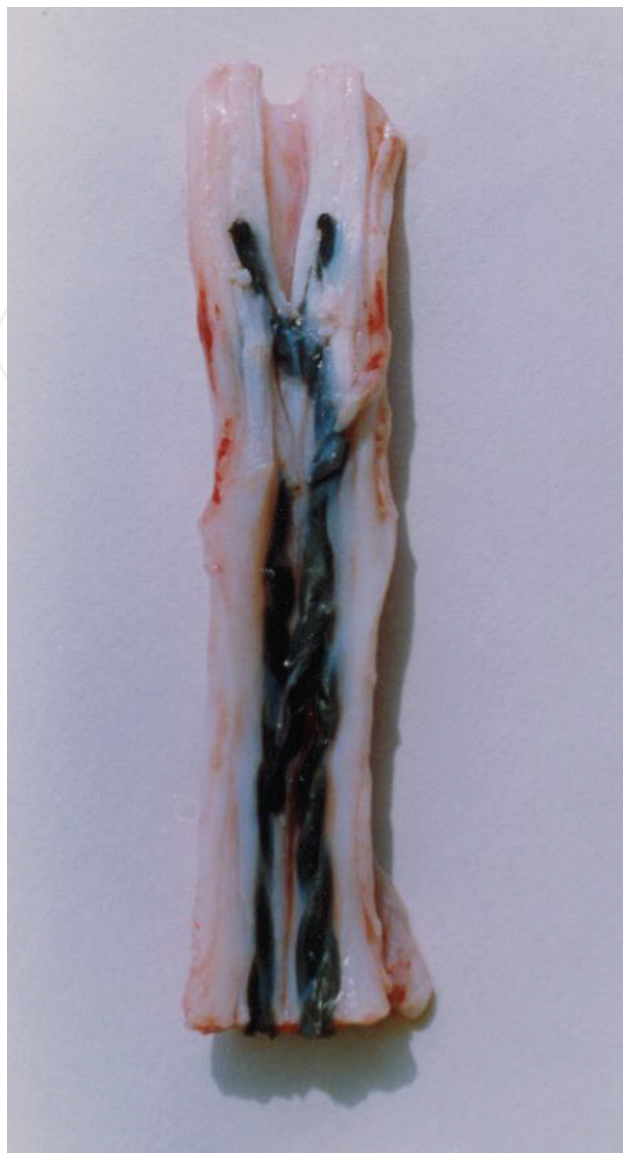**Figure 2.** Repair of 2.5 cm long defect in SDF tendon using carbon fibers.

showed hypervascularization at the reconstructed site on day 14 in the carbon fiber group. On days 30 and 90, blood vessels were normally organized.

Gross observations showed filling of the defect with granulation tissue with more vascularity on day 7, which was less prominent at day 14). On day 30, the neotendon formed was slightly thicker and comparable to normal tendon in appearance and texture (**Figure 3**). On day 90, it exhibited all the characteristics of a fully developed tendon. A longitudinal split section showed intact carbon fibers strand surrounded by neo tendon. Peritendinous adhesions were maximum on day 7, and later on reduced gradually (**Figure 4**). Microscopically, an acute inflammatory reaction in the periphery of carbon fibers was observed on day 7. Immature fibroblasts were arranged in a haphazard pattern at this stage. By day 14, numerous newly formed capillaries and comparatively more mature fibroblasts were present in between and



**Figure 3.** Gross observation on day 30, split section showing formation of neotendon.



**Figure 4.** Gross observation on day 90 and its split section exhibiting all characteristics of a fully developed tendon.

around the carbon fibers which were aligning parallel to the longitudinal axis of the tendon. By day 30 the healing tissue exhibited longitudinal orientation of collagen fibers and was at a more advance stage of maturation. By day 90, the neotendon formed simulated the picture of normal tendon. Scanning electron microscopic observation revealed formation of neotendon between carbon fiber strands, resulting in thickening of the implant. Longitudinal grooving on the carbon fiber filaments was also observed. In later stages parallel collagen fibers resembling normal tendon were observed.

#### **4. Clinical applications**

Successful repair of abdominal wall defect requires closure of defect without undue tension on suture line. To reduce the recurrence rates, surgeons had used prosthetic materials of different structures and composition to bridge the tissue defects of large hernias that cannot

be approximated primarily without placing excess tension on the suture line. Carbon mesh is available as a prosthetic sheet for bridging abdominal wall defects. This material is inert and has been proved to be biocompatible in experimental trials in rabbits [40]. In the present study carbon mesh was utilized in the treatment of cattle with abdominal wall hernias where repair by direct tissue approximation could not be accomplished without unacceptable tension across the suture line.

#### 4.1. Materials and methods

Six crossbred heifers aged between 12 and 18 months with congenital umbilical hernias without complication were taken up in this study. After washing with acetone for 2 min, the mesh was autoclaved. The animals were kept on fasting for 24 h before surgery. Preoperatively all these animals received antibiotic therapy and surgery was carried out in dorsoventral recumbency. Analgesia at the site of operation was achieved by field block by using 2% Lignocaine hydrochloride. After preparing the site aseptically, a semicircular skin incision was made over the swelling. The subcutaneous tissue, abdominal muscles and hernial rings were separated. Carbon mesh was implanted subfascially. Interrupted sutures were then placed 1.5 cm from the edge of prosthesis and 1.5 cm apart, circumscribing the edges of the musculofascial defect by using Vetafil (1.1 mm). In all herniorrhaphies, the mesh was strengthened with Vetafil by using vest over pant technique. The skin incision was closed in routine manner. Injection Oxytetracycline for 5 days and Injection Diclofenac sodium for 3 days were administered intramuscularly. Antiseptic dressing was done with Betadine till suture removal. Sutures were removed on 12th postoperative day.

#### 4.2. Results and discussion

All the animals were partially anorectic for 2 days thereafter feeding pattern was completely normal. Carbon mesh was well tolerated by all animals. Carbon mesh acted as a biocompatible scaffold and did not degrade or loose strength [38]. Slight inflammatory swelling was observed at the operated site, which may be due to tissue reaction to surgical trauma [41].

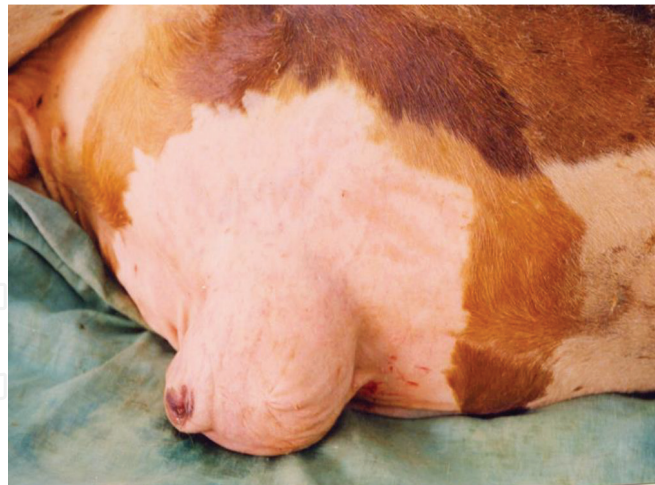Seroma formation after hernioplasty with different biomaterials in human beings was also reported [42] and this complication was treated by aspiration and compression [36]. In present study, infection at the mesh-implanted site was not observed. It may be due to preoperative use of antibiotics in all the animals. Judicious use of local and systemic antibiotics was useful in decreasing the infection rate. Excessive tension on suture line forced the suture line to cut the tissue by progressive aseptic necrosis [43]. Hard swelling at the reconstruction site was recorded on day 12 in all animals, which gradually decreased and subsided completely between 34 and 40 days. This may be due to excessive production and deposition of fibrous tissue in the interstices of the mesh [29]. Later on decrease in hard swelling may be due to gradual disintegration of carbon fibers, phagocytosis and removal of debris. Carbon fiber implant induced extensive fibrous tissue reaction with neovascularization around it. The inflammatory cells were almost negligible in the stroma which indicated the host tissue reaction tolerance to carbon fibers [44]. The deposition of more collagen fibers in the healing tissue and chronic cell reaction adjacent to the carbon fibrils along with macrophages, few foreign body giant cells and microgranulomas has been reported [29].

Two cases of umbilical hernia in dogs have been successfully repaired using carbon fibers as suture materials [45]. The hernial ring was about 3 cm in diameter in both the cases. Carbon fibers filaments (6000 filaments of 7.5 micron diameter) were used to repair the hernial ring. There was an uneventful recovery without untowards reaction. Braided carbon fibers as a suture material for the repair of hernia in a buck and in buffalo calf with no untoward reaction have been used successfully [46]. Use of carbon fibers for the reconstruction of abdominal wall defects has been reported [47]. About 3000 carbon fibrils were taken and allowed to recoil upon themselves to form a two ply twist implant of 6000 carbon fibrils filament. This implant was washed with acetone for 2 min before autoclaving. They were used as sutures for the closing hernial ring. Carbon fibers have the advantage of being a non-irritable biomaterial of reasonable tensile strength. These fibers evoked less inflammatory response. Abundant fibrous tissue was produced around the carbon fibers.

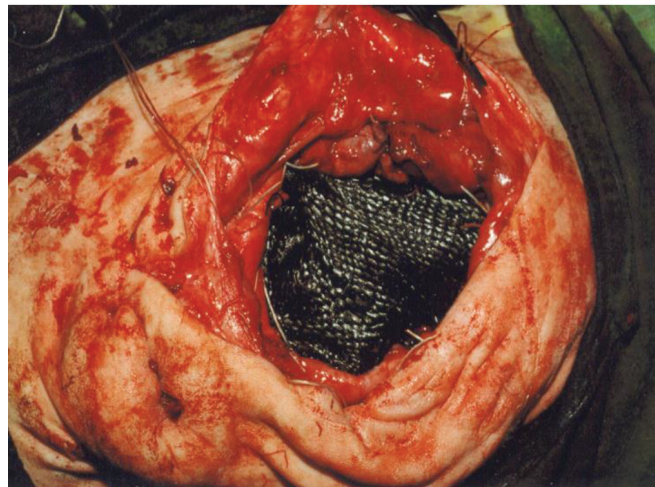
During a 3-year period (2001–2004) 18 animals were surgically treated because of abdominal wall defects [48]. Out of 18 animals 8 were bovines, 5 caprines and 5 canines. In each case the defect was repaired with carbon fibers. Carbon fibers were placed either in simple interrupted pattern or as mattress overlapping pattern. All the cases were successfully treated and no complication was observed up to 6 months postoperatively. In the present study 6000 filaments of carbon fibers have been used for the repair of external abdominal wall defects/hernias in 18 clinical cases of different species of animals having the hernial ring size range from 1.5 to 8 cm in diameter with good results.

Carbon fibers for the *repair* of congenital *umbilical hernias* in five buffalo calves aged 5–13 months have been used. The size of the hernial rings in different animals ranged from 5 to 7 cm in diameter [49]. About 3000 carbon fibrils were taken and allowed to recoil upon themselves to form a two ply twist implant of 6000 carbon fibrils filament. This implant was washed with acetone for 2 min before autoclaving. Carbon fibers have the advantage of being a non-irritable biomaterial of reasonable tensile strength. These fibers evoked less inflammatory response and abundant fibrous tissue response around the carbon fibers. The amount of fibrosis increased with time with a gradual transition of stress from the carbon fibers to the induced fibrous tissue. The wound was healed by first intention in all the animals. Gangwar et al. [50] reported the *use* of carbon fibers for the *repair* of *umbilical hernias* in six cow calves. The size of the hernial rings in different animals ranged from 5 to 7 cm in diameter. About 3000 carbon fibrils were taken and allowed to recoil upon themselves to form a two ply twist implant of 6000 carbon fibrils filament. All the animals recovered completely. No complication was observed at the repair site.

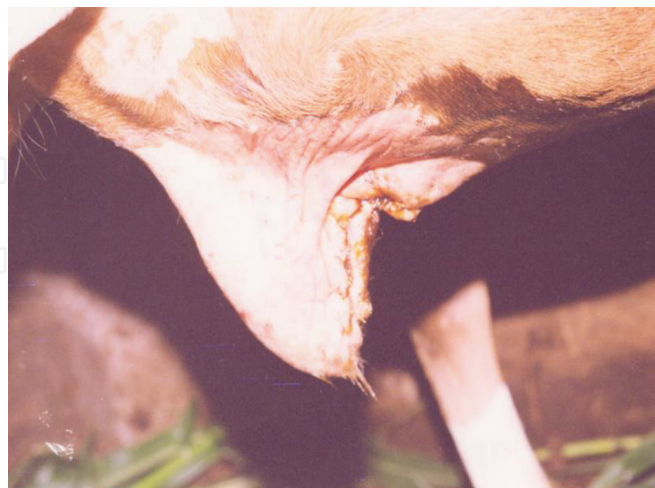Successful repair of large umbilical hernia in a crossbred heifer has been reported using carbon sheet. The hernial ring size was 12 × 10 cm in diameter. The carbon sheet was applied as inlay graft and sutured with hernial ring by silk sutures. The animal show uneventful recovery and no complication were observed up to 6 months postoperatively [51]. Similarly in another case carbon mesh was used to repair large umbilical hernia in a crossbred male calf as inlay graft where the hernial ring size was 8 × 10 cm in diameter. The animal show uneventful recovery and no complication were observed up to 3 months postoperatively [52] (**Figure 5a–c**).



(a)



(b)



(c)

**Figure 5.** Large umbilical hernia in a crossbred male calf repair with carbon mesh (a) crossbred male calf showing large umbilical hernia (b) opening of hernial sac and placing of carbon mesh for repair of hernial ring as inlay graft (c) complete closure of defect after skin suturing.



During a 4-year period (2001–2005) 9 animals (8 bovines and 1 caprine) were surgically treated for abdominal wall defects (hernia). In each case the defect was repaired with carbon mesh. All the cases were successfully treated and no complication was observed up to 6 months postoperatively. In the present study carbon fiber mesh have been used for the repair of external abdominal wall defects/hernias having the hernial ring size ranged from 6 to 15 cm in diameter with good results. This is probably the first report in which carbon fiber mesh has been successfully used for the repair of abdominal wall defects in clinical cases [53].

Use of carbon cloth/carbon fiber mesh for the repair of abdominal hernias in animals was reported with good results [54]. Similarly, Gangwar et al. [55] used carbon fiber mesh for the repair of external abdominal wall defect in a calf having the hernial ring size of 8 cm in diameter with satisfactory results. Kh Sangeeta Devi et al. [56] operated six crossbred heifers, 12–18 months old, with congenital umbilical hernia using carbon mesh. Results revealed that all animals were clinically healthy after the surgery. Inflammation gradually decreased between 34 and 40 days postoperatively. With significant increase in erythrocyte sedimentation rate up to 30 days. Total leukocyte count and neutrophils returned to normal after 30 days. Histopathological lesions showed that the carbon fiber implant induced extensive fibrous reaction with neovascularization. It is concluded that the carbon mesh can be used for successful reconstruction of umbilical hernia in cattle.

## Author details

Naveen Kumar<sup>1\*</sup>, Anil Kumar Gangwar<sup>2</sup> and Khangembam Sangeeta Devi<sup>3</sup>

\*Address all correspondence to: naveen.ivri1961@gmail.com

1 Division of Surgery, ICAR-Indian Veterinary Research Institute, Bareilly, Uttar Pradesh, India

2 Department of Surgery and Radiology, College of Veterinary Sciences and Animal Husbandry, Narendra Deva University of Agriculture and Technology, Faizabad, Uttar Pradesh, India

3 Department of Surgery and Radiology, College of Veterinary Sciences and Animal Husbandry, Narendra Deva University of Agriculture and Technology, Faizabad, Uttar Pradesh, India

## References

- [1] Blazewicz M, Blazewicz S, Wajler C. Mechanical and implant behaviour of chemically modified carbon braids. *Ceramics International*. 1994;**20**:99-103
- [2] Carranza-Bencano A, Armas-Padron JR, Gili-Miner M, Lozano MA. Carbon fiber implants in osteochondral defects of the rabbit patella. *Biomaterials*. 2000;**21**:2171-2176

- [3] Forster IW, Ralis ZA, McKibbin B, Jenkins DHR. Biological reaction to carbon fiber implants. *Clinical Orthopaedics and Related Research*. 1978;**131**:299-307
- [4] Miller JH. Comparison of the structure of neotendons induced by implantation of carbon or polyester fibres. *Journal of Bone and Joint Surgery*. 1984;**66**:131-139
- [5] Jenkins DHR. Ligament induction by filamentous carbon fibre. *Clinical Orthopaedics*. 1985;**197**:86-90
- [6] Becker HP, Rosenbaum D, Zeithammel G, Gnann R, Bauer G, Gerngross H, Claes L. Tenodesis versus carbon fiber repair of ankle ligaments: A clinical comparison. *Clinical Orthopaedics*. 1996;**325**:194-202
- [7] Morris DM, Haskins R, Marino AA, Misra RP, Rogers S, Fronczak S, James AA. Use of carbon fibres for repair of abdominal wall defects in rats. *Surgery*. 1990;**107**:627-631
- [8] More N, Baquey C, Barthe X, Rouais F, Rivel J, Trinqueste M, Marchand A. Biocompatibility of carbon-carbon materials: In vivo study using <sup>14</sup>C labelled samples. *Biomaterials*. 1988;**9**:198-202
- [9] Strover AE, Firer P. The use of carbon fibre implants in anterior ligament surgery. *Clinical Orthopaedics*. 1985;**196**:88-98
- [10] Alexander H, Weiss AB, Parsons JR. Ligament repair and reconstruction with absorbable polymer coated carbon fibre. *Journal of Orthopaedic Surgery and Research*. 1987;**3**:1-14
- [11] Christel P, Claes L, Brown SA. Carbon-reinforced composites in orthopedic surgery. In: Szycher M, editor. *High Performance Biomaterials. A Comprehensive Guide to Medical and Pharmaceutical Application*. Lancaster, PA: Technomic Publishing Company; 1991. pp. 499-518
- [12] Jenkins DHR, Forster IW, McKibbin B, Ralis ZA. Induction of tendon and ligament formation by carbon implantation. *Journal of Bone and Joint Surgery*. 1977;**59B**:53-57
- [13] Jenkins DHR. The repair of cruciate ligaments with flexible carbon fibre. A longer term study of the induction of new ligaments and of the fate of the implanted carbon. *Journal of Bone and Joint Surgery*. 1978;**60B**:520-522
- [14] Rohe K, Braun A, Cotta H. Ligament replacement with carbon fibre implants in rabbits: Light and transmission electron microscopic studies. *Zeitschrift für Orthopädie und Ihre Grenzgebiete*. 1986;**124**:569-577
- [15] Pesakova V, Klezl Z, Balik K, Adam M. Biomechanical and biological properties of the implant material carbon-carbon composite covered with pyrolytic carbon. *Journal of Materials Science. Materials in Medicine*. 2000;**11**:793-798
- [16] Blazewicz M. Carbon materials in the treatment of soft and hard tissue injuries. *European Cells & Materials*. 2001;**2**:21-29
- [17] Czajkowska B, Blazewicz M. Phagocytosis of chemically modified carbon materials. *Biomaterials*. 1997;**18**:69-74

- [18] Debnath UK, Fairclough JA, Williams RL. Long-term local effects of carbon fibre in the knee. *The Knee*. 2004;**11**:259-264
- [19] Adams D, Williams DF. Carbon fiber-reinforced carbon as a potential implant material. *Journal of Biomedical Research*. 1978;**2**:35-42
- [20] Bokros JC, Arkins RJ, Shim HS, Houbold AD, Agrawal NK. Carbon in prosthetic devices. In: Deviney ML, O'Grady TM, editors. *Petroleum Derived Carbons*. Washington, DC: American Chemical Society; 1976
- [21] Mortier J, Engelhardt M. Foreign body reaction in carbon fiber prosthesis implantation in the knee joint-case report and review of the literature. *Zeitschrift für Orthopädie und Ihre Grenzgebiete*. 2000;**138**:390-394
- [22] Demmer P, Ed FRCS, Glas FRCS, Fowler M, Marino AA. Use of carbon fibre in the reconstruction of knee ligaments. *Clinical Orthopaedics and Related Research*. 1991;**271**: 225-232
- [23] Grabinski C, Hussain S, Lafdi K, Braydich-Stolle L, Schlager J. Effect of dimension on biocompatibility of carbon nanomaterials. *Carbon*. 2007;**45**:2828-2835
- [24] Gangwar AK, Sharma AK, Kumar N, Maiti SK, Gupta OP, Goswami TK, Singh R. Carbon fibres for the repair of abdominal wall defects in rabbits. *Carbon Science*. 2005;**6**:15-24
- [25] Dalla-Vecchia L, Engum S, Kogon B, Jensen E, Davis M, Grosfeld J. Evaluation of small intestine submucosa and acellular dermis as diaphragmatic prostheses. *Journal of Pediatric Surgery*. 1999;**34**:167-171
- [26] Takahashi M, Ono K, Wakakuwa R, Sato O, Tsuchiya Y, Kanya G, Nitta K, Tajima K, Wada K. Use of human dura mater allograft for the repair of a contaminated abdominal wall defect. *Surgery Today*. 1994;**24**:468-472
- [27] Shoukry M, El-Keiey M, Hamouda M, Gadallah S. Commercial polyester fabric repair of abdominal hernias and defects. *The Veterinary Record*. 1997;**140**:606-607
- [28] Gillion JF, Begin GF, Marecos C, Fourtaniar G. Expanded polytetrafluoroethylene patches used in the intraperitoneal or extraperitoneal position for repair of incisional hernias of the anterolateral abdominal wall. *American Journal of Surgery*. 1999;**174**:16-19
- [29] Cameron AEP, Taylor DEM. Carbon-fibre versus Marlex mesh in the repair of experimental abdominal wall defects in rats. *The British Journal of Surgery*. 1985;**72**:648-650
- [30] Kumar N, Sharma AK, Sharma AK, Satish K. Carbon fibres and plasma preserved tendon allografts for gap repair of flexor tendon in bovines: Gross, microscopic and scanning electron microscopic observations. *Journal of Veterinary Medicine Series A*. 2002;**49**(5):269-276
- [31] Kumar N, Sharma AK, Singh GR, Gupta OP. Carbon fibres and plasma preserved tendon allografts for gap repair of flexor tendon in bovines: Clinical, radiological and angiographical observations. *Journal of Veterinary Medicine Series A*. 2002;**49**(3):161-168

- [32] Silver IA. Basic physiology of wound healing in the horse. *Equine Veterinary Journal*. 1982;**14**:7-15
- [33] Kumar N. Carbon fibres and plasma preserved homologous grafts for gap repair of flexor tendon in bovines [PhD thesis]. Izatnagar, Uttar Pradesh: Deemed University, Indian Veterinary Research Institute; 1997
- [34] Nurse CJ, Jenkins DHR. The use of flexible carbon fibre in the repair of experimental large abdominal incisional hernias. *The British Journal of Surgery*. 1980;**67**:135-137
- [35] Bellon JM, Bujan J, Contreras LA, Mastin ACS, Junado F. Comparison of a new type of polytetrafluoroethylene patch (Mycro mesh) and polypropylene prosthesis (Marlex) for repair of abdominal wall defects. *Journal of the American College of Surgeons*. 1996;**183**:11-118
- [36] Deysine M. Hernia repair with expanded polytetrafluoroethylene. *American Journal of Surgery*. 1992;**163**:422
- [37] Layson RL, Channon GM, Jenkins DHR, Ralis ZA. Flexible carbon fibre in late ligamentous reconstruction for instability of the knee. *Journal of Bone and Joint Surgery*. 1984;**66B**:196-200
- [38] Greenstein SM, Murphy TF, Rush BF Jr, Alexander H. Evaluation of polylactic acid-carbon mesh for repair of ventral herniorrhaphy. *American Journal of Surgery*. 1986;**151**:635-639
- [39] Morris DM, Hindman J, Marino AA. Repair of fascial defects in dogs using carbon fibres. *The Journal of Surgical Research*. 1998;**80**:300-303
- [40] Gangwar AK, Sharma AK, Kumar N, Sangeeta Devi K, Maiti SK, Gupta OP, Singh R. Reconstruction of large abdominal wall defects with carbon mesh in rabbits: Gross, histopathological and histochemical studies. *The Indian Journal of Animal Sciences*. 2010;**80**:117-120
- [41] Bauer JJ, Salky BA, Gelernt IM, Kreel I. Repair of large abdominal wall defects with expanded polytetrafluoroethylene (PTFE). *Annals of Surgery*. 1987;**206**:765
- [42] Koukourou A, Lyon W, Rice J, Wattchow DA. Prospective randomized trial of polypropylene mesh compared with nylon darn in inguinal hernia repair. *The British Journal of Surgery*. 2001;**88**:931
- [43] Kennedy GM, Matyas JA. Use of expanded polytetrafluoroethylene in the repair of difficult hernias. *American Journal of Surgery*. 1999;**168**:304
- [44] Ralis ZA, Forster IW. Choice of the implantation site and other factors influencing the carbon fiber tissue reaction. *Journal of Bone and Joint Surgery*. 1981;**63-B**:295-296
- [45] Sharma AK, Kumar N, Gangwar AK, Maiti SK, Kumar N. Use of carbon fibres for the repair of umbilical hernia in dogs. *Journal of Canine Development and Research*. 2002;**2**:65-68

- [46] Kumar N, Sharma AK, Gangwar AK, Maiti SK, Gupta OP. Use of braided carbon fibres for the repair of hernia in buck and buffalo calf. In: Xth IAAVR Conference; 14-15 April 2003; Palampur; 2003, Abstract 03:25
- [47] Kumar N, Sharma AK, Kumar S. Use of carbon fibres for the reconstruction of abdominal wall defects. In: International Workshop on Carbon Materials for Energy Applications; 24-25 November 2004; New Delhi; Abstract in Fibres and Composites; 2004. p. 52
- [48] Kumar N, Sharma AK, Gangwar AK, Maiti SK, Gupta OP, Kumar N, Mathur RB. Carbon fibres for the repair of external abdominal hernias in bovines, caprines and canines: A review of 18 clinical cases. *Carbon Science*. 2006;7:81-86
- [49] Sangeeta Devi K, Gangwar AK, Singh HN. Carbon fiber as a prosthetic material for reconstruction of congenital umbilical hernias in buffalo calves. *Indian Journal of Veterinary Surgery*. 2008;29(1):42
- [50] Gangwar AK, Sharma AK, Kumar N, Sangeeta Devi K. Use of braided carbon fibres in the repair of umbilical hernia in bovines. *The Indian Veterinary Journal*. 2008;85:430-431
- [51] Kumar N, Sharma AK, Gangwar AK, Maiti SK, Kumar N. Successful use of carbon sheet in surgical management of large umbilical hernia in a crossbred heifer. In: 90th Indian Science Congress Association, Part-II, Advance Abstract, Section of Animal, Veterinary and Fishery Sciences; 2003. p. 97
- [52] Kumar N, Sharma AK, Gangwar AK, Maiti SK, Kumar N. Use of carbon mesh in surgical management of large umbilical hernia. In: XXVI ISVS Annual Conference; 2003. pp. 31-32
- [53] Kumar N, Sharma AK, Maiti SK, Gangwar AK, Kumar N. Carbon fibre mesh for the repair of abdominal hernias in bovines and caprines: A review of nine clinical cases. *Carbon Letters*. 2007;8:269-273
- [54] Kumar N, Sharma AK, Maiti SK. Carbon cloth for repair of abdominal hernias in animals. In: 95th Indian Science Congress; Visakhapatnam, 3-7 January, 2008; Section II: Animal, Veterinary and Fishery Sciences, Abstract 118; 2008. p. 90
- [55] Gangwar AK, Sharma AK, Kumar N, Sangeeta Devi K. Prosthetic hernioplasty with carbon mesh in a calf. *The Indian Veterinary Journal*. 2008;85:658-659
- [56] Sangeeta Devi K, Gangwar AK, Singh HN, Kumar N. Studies on carbon mesh repair of congenital umbilical hernia in bovine. *The Indian Veterinary Journal*. 2010;87:139-141