

We are IntechOpen, the world's leading publisher of Open Access books Built by scientists, for scientists

4,800

Open access books available

122,000

International authors and editors

135M

Downloads

Our authors are among the

154

Countries delivered to

TOP 1%

most cited scientists

12.2%

Contributors from top 500 universities



WEB OF SCIENCE™

Selection of our books indexed in the Book Citation Index
in Web of Science™ Core Collection (BKCI)

Interested in publishing with us?
Contact book.department@intechopen.com

Numbers displayed above are based on latest data collected.
For more information visit www.intechopen.com



Percutaneous Reconstruction Techniques: Popliteal Artery Approach for Chronic Total Occlusion of Superficial Femoral and Iliac Arteries

Omer Tanyeli

Additional information is available at the end of the chapter

<http://dx.doi.org/10.5772/intechopen.78045>

Abstract

Peripheral artery disease (PAD) is one of the most common diseases affecting quality of life. Claudication is the most frequent sign. If left untreated, PAD may cause serious daily life disturbances and may cause extremity losses, especially in elderly and diabetic patients. Restoration of blood flow from the aorta to the femoral arteries and from the femoral arteries to the popliteal arteries necessitates complex operational procedures. Most of these patients have concomitant coronary diseases. In such patients, open surgical repair with vascular grafts by the aid of general anesthesia increases both mortality and morbidity. Although femoral arteries are the most common site for PAD, iliac impairment is not so rare. In patients with combined iliac and femoral artery diseases, popliteal artery approach is a safe and effective technique for percutaneous revascularization. In this chapter, we share our experience with interventional percutaneous revascularization through popliteal approach, mainly using drug eluting balloons and stents, by the aid of mechanical thrombectomy devices with the highlights of current literature review.

Keywords: peripheral artery disease, popliteal artery approach, stenting, balloon angioplasty, mechanical atherectomy, total occlusion

1. Introduction

PAD is third most common cause of cardiovascular mortality and mortality worldwide, following coronary artery disease and stroke [1]. Although the exact number of patients suffering from PAD is unknown, it is commonly agreed that there is a global increase in the amount of patients mainly by increased age and life expectancy of the populations, mainly

in underdeveloped countries. Fowkes et al. reported that there were 202 million people estimated to suffer from PAD, with a stronger change in the prevalence of low- and middle-income countries [1].

Elderly patients with diabetes mellitus and smoking habits are under great risk for PAD. Hyperlipidemia or hypertension is less likely to be the predisposing factors for the development of PAD.

Intermittent claudication (IC) is the most common symptom factor affecting quality of life. In order to improve walking distance, and prevent extremity losses, a wide variety of treatment strategies are offered including lifestyle changes, medical therapy, supervised exercise therapy, interventional procedures and surgical revascularization.

Ever since Seldinger discovered the needle-in, wire-in, needle-out, catheter in, interventional radiologists and cardiologists gained a favorable expertise not only in diagnosis of cardiovascular diseases, but also for treatment of vascular lesions. Over the past decade, with improvement of diagnostic procedures, catheter-based treatment strategies also increased and now almost became the first-line treatment strategy in almost all vascular diseases, mainly being performed by new generation qualified vascular surgeons and interventionists. Balloon angioplasty or stenting for a stenotic segment of the superficial femoral artery (SFA) became a routine process and endovascular procedures for complex chronic total occlusions (CTO) are more commonly being treated with interventional procedures using mechanical thrombectomy/atherectomy devices, which put the common surgical revascularization techniques in second order. In this chapter, we aimed to discuss the treatment of iliofemoral PAD, using combined endovascular treatment strategies, mainly focusing on the retrograde popliteal artery (PA) approach.

2. Peripheral artery disease

On the basis of anatomical and functional considerations, lower extremity occlusive PAD can be defined as atherosclerotic arterial disease and arterial narrowing, causing a mismatch between the blood supply and demand. Whatever is the cause, this mismatch results in symptoms including IC, exercise limitations, rest pain or tissue loss. These two definitions help divide the PAD patients into asymptomatic or symptomatic disease states [2]. About 10% of men at the age of 65 years are affected by atherosclerotic PAD. This ratio increases to 20% in men and women ≥ 75 years [3]. Besides its common nature, most of the patients remain asymptomatic and the disease is underdiagnosed. For every symptomatic patient with PAD, up to six patients are asymptomatic and miss the diagnosis. In a study of patients with PAD including 60-year-old men and women, Schroll et al. found that only 19% of patients were symptomatic [4].

2.1. The frequency of PAD location

Determining the location of PAD is crucial for decision-making and planning the treatment. The PAD may be classified according to the location of the involved arterial segment as aortoiliac, femoropopliteal and tibioperoneal segment. Location of PAD segment may vary

according to gender, associated disease, especially diabetes mellitus (DM) and the age group. Motsumi et al. reported that diabetic patients have severe occlusive disease involving the tibioperoneal segment [5]. Diabetic patients also have diffuse nature of PAD. Patients with DM, hypertension, dyslipidemia and smoking habits have significant occlusive disease of the femoropopliteal arterial segment. Smoking obviously increases the severity of arterial occlusive disease in the femoropopliteal segment or more proximal arterial segments. Diehm et al. reported that smoking had a higher relative risk ratio for severe involvement of the aortoiliac segment [6]. Interestingly, aortoiliac involvement in female diabetic patients was uncommon, irrespective of risk factor grouping and they had relative sparing of the arterial foot arch compared to their male counterparts [5].

When the frequency of the involved arterial segment in PAD was analyzed, researchers found that femoropopliteal location was the most common [6–8]. The involvement of femoropopliteal arterial segment varied between 47.3% and 77% in these studies. On the contrary, there are also a few studies reporting different results, mainly in the younger age groups. A study mainly focused on relatively younger age groups (<50 years) with early-onset PAD demonstrated that these patients had 65% aortoiliac disease [9]. In another study, common femoral arteries (CFA) were more commonly affected than the distal arterial segment (57.6% and 42.9%, respectively) [10]. In this study, older age, male sex, diabetes, heart failure and critical limb ischemia were more significantly associated with distal disease, whereas female sex, smoking, hypertension, dyslipidemia, coronary heart disease, cerebrovascular disease and chronic obstructive pulmonary disease were more significantly associated with proximal disease.

PAD resulting from atherosclerosis is a multisegmental disease in about two-thirds of symptomatic patients [11]. About 25–50% of patients have stenoses and/or occlusions in two or more segments [7, 12]. Knowing the fact that multisegmental disease affects about one in every 2–4 patients, determining the access site before any interventional procedure is very important.

2.2. Characteristics of Iliofemoral peripheral artery disease

Patients with PAD may have different symptoms depending on the anatomical location of the diseased arterial segments, onset of disease (acute or chronic) or presence/absence of the collateral circulation. Since the disease is progressive in nature, the patients may remain asymptomatic for years until the luminal obstruction is >50%. During this period, patients may have IC in strenuous exercise or may remain completely asymptomatic as stated earlier. As the disease progresses, and the luminal obstruction is >50%, patients may have progressively worsening IC, and the walking distance becomes to decrease. In following years, if the patient is left untreated symptoms intensify to rest pain, arterial ulceration, tissue loss or amputation.

There is a significant correlation between the severity of limb ischemia and the distribution of PAD. IC is usually associated with proximal lesions, and critical limb ischemia is associated with crural involvement. Proximal aortoiliac disease may cause thigh, hip, or buttock pain while walking and they are usually preceded by calf pain. Distal tibial or peroneal obstructions may result in ankle or foot pain while walking [13]. PAD patients with more severe and limb-threatening ischemia usually have multisegment involvement.

Patients with distal disease had poorer prognosis compared with patients without distal disease, independent of age, sex, comorbid conditions, medication (lipid-lowering and aspirin) use and resting ankle-brachial index (ABI), whereas patients with proximal disease showed no difference in prognosis after similar adjustment compared with patients without proximal disease. These findings suggest PAD is complex and heterogeneous and not a uniform entity [10].

The mortality for asymptomatic PAD is similar to that of mild to moderately symptomatic patients. Besides its beneficial effect on diagnosis of the disease, ankle-brachial index is also shown to correlate with the overall mortality of the disease [14]. The majority of these patients die of vascular causes such as cardiac, cerebrovascular, or other vascular diseases. The main reason for morbidity or mortality is either myocardial infarction or stroke. All-cause mortality is approximately 30% at 5 years, 50% at 10 years and 70% at 15 years [15]. In a population study, large-vessel involvement in PAD patients was significantly predictive of all-cause mortality in both genders with a relative risk of 4–5, independent of other cardiovascular risk factors. Isolated small-vessel PAD was unrelated to mortality. In that study, large-vessel PAD involved all arteries above the level of ankle [16]. Ogt et al. also found that the relative risk of mortality was elevated from 2- to 7-fold in men and women with multi- and unisegmental disease involving the aortoiliac and femoropopliteal segments. In the same study, the presence of tibioperoneal disease did not significantly increase mortality [8].

2.3. Diagnosis of iliofemoral peripheral artery disease

Depending on basic medical rules, the initial evaluation should include a careful history and physical examination. Knowing the fact that almost half of patients with PAD remain asymptomatic, suspicion of PAD for a clinician is very important. Shoes and socks should be removed for assessment of distal perfusion. Any signs of peripheral ischemia, peripheral pulses, skin color, toe nails, hair loss and trophic skin changes should be noted. Every sign of physical examination should be compared to the contralateral extremity. Abdomen should also be palpated for any potential abdominal aortic aneurysm. The blood pressure should be measured in both arms.

Upon suspicion and physical examination findings, referral to the vascular laboratory should be the initial step. The diagnostic tests should start by noninvasive methods. These noninvasive tests are also important for the follow-up of patients or disease progress.

The ABI is the single best initial screening test to perform in a patient suspected for PAD. A ratio of <0.90 is considered abnormal, with mild obstruction defined as a ratio of 0.71–0.90, moderate as 0.41–0.70 and severe when the ABI is <0.40 . The higher arm blood pressure is used for the ABI ratio calculation [17]. The overall accuracy of the ABI to establish the diagnosis of lower extremity PAD has been validated with a sensitivity of 79–95% and a specificity of 96–100%, based on different studies [18, 19]. It is a reproducible technique, cheap and can also be used for screening and initial evaluation of target population, as well as assessment of disease progression. In patients with noncompressible arteries due to medial calcification such as elderly, diabetes and end-stage renal disease, toe-brachial index calculation may be helpful and values <0.7 are considered diagnostic for lower extremity PAD [20].

Treadmill exercise testing can be helpful, especially in patients with normal ABI during resting, such as in patients with isolated iliac artery stenosis. A decrease in ABI of 15–20% with

exercise is considered diagnostic for PAD. Climbing stairs, walking in the highway or 6-min walking test can also be performed not only for differentiation of claudication from pseudo-claudication, but also objectively assess the limitations of the patients and help to prescribe patient specific exercise programs. They are also important for patient follow-ups and disease progress [21].

Pulse volume recordings and Doppler waveform techniques are other techniques that can provide accurate information even in patients with noncompressible vessels. The normal waveform is triphasic. Loss of triphasic pattern and analysis of the peak velocity can localize the area of stenosis. They may be used to establish the initial diagnosis, assess the location and severity of PAD as well as follow-up of patients after any revascularization procedures [17].

Although they are not the first diagnostic test of choice in diagnosis of PAD, computed tomography angiography (CTA), magnetic resonance angiography (MRA) and digital subtraction angiography (DSA) are the other techniques that allow direct visualization of the vasculature in PAD patients.

CTA may be used with either intra-venous or intra-arterial contrast agents. The sensitivities and specificities are >95% for identifying stenosis >50% and for correctly identifying occlusions [22]. CTA produces images of vascular structures in cross-sectional slices that can be reformatted into three-dimensional angiographic-like images. CTA not only shows the intraluminal space, but also shows the surrounding tissue. For this reason, it visualizes calcification well, which is advantageous when considering revascularization strategies [23]. The main disadvantage is radiation exposure and the use of large volumes of iodinated contrast media, which limits its use in acute renal failure patients or patients with borderline renal function.

MRA is a useful diagnostic method in determining the location and stenosis severity in PAD patients. MRA may identify outflow vessels which may not be visualized by conventional angiography [24]. MRA has a high sensitivity and specificity for detecting acute occlusive disease when compared with DSA [25]. It is very useful for preoperative evaluation of the PAD patient in order to make a road-map, whether surgical or endovascular revascularization. **Figure 1** shows MRA of two different patients showing total occlusion of SFA.

MRA may also be used for postoperative follow-up of patients. A meta-analysis comparing MRA with catheter angiography demonstrated that sensitivity and specificity of MRA for detection of stenoses >50% were both in the range of 90–100% [26]. The main limitation of MRA is that it tends to overestimate the degree of stenosis because of turbulence; it cannot scan patients with pacemakers or defibrillators; metal stents or clips can obscure vascular flow; and use of gadolinium rarely may cause renal toxicity and nephrogenic systemic fibrosis in patients with elevated creatinine [17].

In our daily practice, there are some patients who are planned for endovascular interventions for critical stenoses, but not critically stenotic by DSA. Also, patients with previous stent in iliac/SFAs may also be misdiagnosed as occluded by MRA; that is why each patient needs a careful physical examination before MRA including comparative ABI. Duplex ultrasound scanning (DUS) may also give supportive data in these patients.

Contrast angiography provides detailed information about the vasculature, including minor collateral vessels, run-off and the flow speed, and is recommended as 'gold standard' method

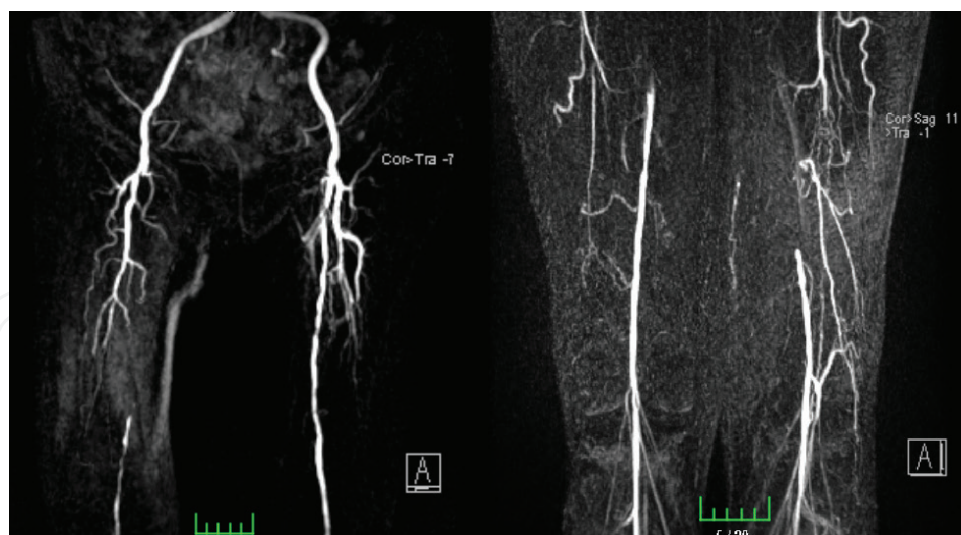


Figure 1. Contrast enhanced MR angiography, showing total occlusion of superficial femoral artery and well developed collateral circulation.

for evaluation of patients with PAD, especially when revascularization is considered. Image quality is enhanced by digital subtraction. The major advantage of DSA is the ability to selectively evaluate individual vessels, to obtain physiologic information such as pressure gradients and to serve as a platform for percutaneous intervention [23]. Angiography carries risk of any interventional procedure such as bleeding, infection, vascular damage, dissection, pseudoaneurysm formation and atheroembolism. Any of these factors can be reduced by experience of the interventionist [17]. As seen with other techniques, the use of contrast agent carries risk of contrast induced nephropathy, as well as anaphylactoid reactions. Angiography should not only be thought solely as a diagnostic method; at the same time, it also offers therapeutic options that are discussed later in this chapter.

Angiography, either noninvasive or invasive, should not be performed for the anatomic assessment of patients with PAD without leg symptoms because delineation of anatomy will not change treatment for this population.

3. Treatment options for iliofemoral peripheral artery disease

The management of lower extremity PAD is one of the most challenging problems for vascular surgeons/interventionists. As the population age increases and diagnostic tools improve, it is not surprising that the amount of patients seeking for treatment of PAD also increase day by day.

Treatment of any PAD, including iliofemoral PAD, can be classified into four categories including risk factor modification, exercise and cardiovascular rehabilitation, pharmacologic therapy, and invasive methods including surgery and interventional procedures [2]. Patients should not only be aware of their PAD, but also be informed and searched for other related diseases, including cerebrovascular and cardiovascular diseases. All the goals of these

therapeutic options are to improve symptoms and quality of life, at the same time decrease cardiovascular event rates.

3.1. Risk factor modification

Since cardiovascular events are the major cause of death in patients with PAD, modification of atherosclerotic risk factors should be the mainstay of risk factor modification. Smoking cessation and aggressive glycemic control in diabetic patients, both represent the most dominant risk factors for PAD, are very important [17]. Smoking cessation among patients with symptomatic PAD does not improve walking capacity, but may reduce the severity of claudication and the risk of developing critical limb ischemia [27].

In addition to smoking cessation and glycemic control in PAD patients, hyperlipidemia should be treated to reduce the risk of cardiovascular events in patients with atherosclerosis. Statin treatment is shown to have beneficial effects in reducing pain-free walking distance in patients with PAD, so that there is a positive effect on IC [28].

Hypertension is associated with a two- to three-fold increased risk for PAD. Hypertension guidelines support the aggressive treatment of blood pressure in patients with atherosclerosis, indicating PAD. In this high-risk group the current recommendation is a goal of <140/90 mmHg and < 130/80 mmHg if the patient also has diabetes or renal insufficiency [29]. Regarding drug choice, all drugs that lower blood pressure are effective at reducing the risk of cardiovascular events. Most patients will require multiple agents to achieve desired blood pressure goals [21]. The angiotensin-converting enzyme (ACE) inhibitor drugs have also shown benefit in PAD, possibly beyond blood-pressure lowering in high-risk groups [30]. Beta-adrenergic blocking drugs have previously been discouraged in PAD because of the possibility of worsening IC symptoms. However, this concern has not been supported by randomized trials, especially for cardioselective beta-blockers; therefore, beta-adrenergic blocking drugs can be safely used in patients with claudication [31].

3.2. Exercise and cardiovascular rehabilitation

In patients with claudication, there is a considerable body of evidence to support the clinical benefits of a supervised exercise program in improving exercise performance and community-based walking ability [21]. Apart from medical therapy, exercise significantly improves walking time and overall walking ability in patients with IC and should be considered as a primary efficacious treatment in PAD. Several studies have suggested that some level of supervision is necessary to achieve optimal results (general, unstructured recommendations to exercise by the physician do not result in any clinical benefit). In prospective studies of supervised exercise conducted for 3 months or longer, there are clear increases in treadmill exercise performance and a lessening of claudication pain severity during exercise [32]. Current ACC/AHA guidelines recommend a supervised exercise therapy as a first-line treatment for IC, as it is equally effective as endovascular revascularization in the treatment of patients with IC [33]. Whether asymptomatic or symptomatic, any patients taking support for PAD (either medical or surgical/interventional), exercise therapy (namely structured exercise therapy) should be considered, not only to improve IC, but also for motivation and promote risk factor modification.

3.3. Pharmacologic therapy

Apart from medical therapies used to modify risk factors for PAD (antihypertensive, antidiabetic and antihyperlipidemic drugs), there are some drugs that are shown to improve IC or prevent occlusion-reocclusion after surgery/interventional procedures.

Based on the currently available literature, all patients with PAD should receive antiplatelet therapy to reduce cardiovascular risk with a slight preference for clopidogrel monotherapy. Antiplatelet therapy with aspirin alone (range 75–325 mg per day) or clopidogrel alone (75 mg per day) is recommended to reduce MI, stroke and vascular death in patients with symptomatic PAD [33]. The CAPRIE (clopidogrel versus aspirin in patients at risk of ischemic events) trial demonstrated a benefit of clopidogrel as compared with aspirin in cardiovascular risk reduction and bleeding events in a population of patients with symptomatic atherosclerotic vascular disease, including a subgroup of patients with symptomatic PAD [34]. However, there are two important subgroups that benefit from a different medical regime. Those receiving a venous bypass graft will have the most benefit when treated with a vitamin K antagonist and those receiving a below-knee prosthetic bypass graft will benefit the most when dual antiplatelet therapy (ASA and clopidogrel) [35].

Probably, the most effective pharmacologic treatment proven to be effective in relief of symptoms and improving IC in patients with PAD is cilostazol. ACC/AHA guideline strongly recommends the use of cilostazol in patients with PAD (class of recommendation IA) [33]. In a Cochrane review including 15 double-blind RCTs with a total of 3718 participants, cilostazol was associated with improvement in claudication symptoms but no changes in cardiovascular deaths or quality of life when compared with placebo [36]. The main limitation of the drug is congestive heart failure. Pentoxifylline is a xanthine and also acts as a nonselective inhibitor of phosphodiesterases, which causes an increase in intracellular cyclic AMP and decreased synthesis of tumor necrosis factor alpha and leukotrienes. It acts by improving red blood cell deformability, thus reducing blood viscosity as well as decreasing platelet aggregation and thrombus formation. By these properties, it was one of the agents used in PAD treatment. In a multicenter randomized control trial of pentoxifylline, cilostazol, or placebo for patients with moderate-to-severe claudication, there was no difference between pentoxifylline and placebo in the primary endpoint of maximal walking distance [37]. Therefore, pentoxifylline is not recommended as a treatment for claudication [33].

3.4. Invasive methods

An individualized approach to revascularization for claudication is recommended for each patient to optimize outcome. If a strategy of revascularization for claudication is undertaken, the revascularization strategy should be evidence based and can include endovascular revascularization, surgery, or both [33]. When deciding for an invasive method for treatment of PAD, patient's symptoms, localization of the affected arterial segment, patient specific factors including age, co-morbid diseases should be taken into consideration with a favorable risk-benefit ratio, with all combination therapies listed earlier.

In the last decade-or-two, endovascular procedures became one of the most popular concerns for treatment of PAD. There are numerous randomized clinical trials that compared endovascular procedures to various combinations of medical treatment with or without exercise programs.

When the aortoiliac disease is the concern, endovascular procedures are effective as a revascularization option for patients with lifestyle-limiting claudication and hemodynamically significant aortoiliac occlusive disease (class of recommendation IA) [33]. The CLEVER trial enrolled only patients with aortoiliac disease and compared endovascular therapy to supervised exercise therapy and to medications alone. At 6-month follow-up, both the endovascular therapy and supervised exercise groups had improved peak walking time compared with medication alone, with a greater improvement in the supervised exercise group [38]. The ERASE trial randomized patients with claudication and aortoiliac (as well as femoropopliteal) disease to endovascular revascularization plus supervised exercise or supervised exercise alone. After 1 year, patients in both groups had significant improvements in walking distances and health-related QoL, with greater improvements in the combined-therapy group [39].

When the femoropopliteal disease is the concern, endovascular procedures are reasonable as a revascularization option for patients with lifestyle-limiting claudication and hemodynamically significant femoropopliteal disease (class of recommendation IIa) [33]. There are a number of randomized clinical trials that showed short-term beneficial effects with endovascular treatment of femoropopliteal disease for claudication versus supervised exercise training or medical therapy, with benefit that diminishes by 1 year [40]. In a systematic review that included randomized clinical trials that enrolled patients with femoropopliteal disease, authors reported that endovascular treatment of claudication improved walking parameters and quality of life [41]. The durability of endovascular treatment for claudication is directly related to vessel patency. Long-term patency is greater in the iliac artery than in the femoropopliteal segment [33].

Since SFA and popliteal arteries are the most common sites of obstruction in PAD patients, when the surgery is the concern, femoropopliteal bypass is one of the most widely performed surgical processes in these patients with claudication. There is a clear and consistent primary patency benefit for autogenous vein versus to prosthetic grafts for popliteal artery bypass [42]. PTFE grafts should be preferred over Dacron grafts for femoropopliteal bypass when there is lack of autogenous grafts.

In this chapter, apart from the surgical revascularization, mainly endovascular treatment options for iliofemoral PAD and access sites will be discussed.

4. Endovascular management of iliofemoral lesions

Among those with appropriate indications for intervention, the procedure of choice, whether surgical or endovascular, depends on surgeon's/interventionist's experience, localization of the diseased arterial segment, anatomical suitability of disease and patient related factors, such as comorbid diseases. Most of the endovascular procedures are performed using local anesthesia on an outpatient manner.

Although the radiologists and cardiologists were the main pioneers of endovascular procedures, in the last decade, by the formation of hybrid operating rooms, vascular and cardiovascular surgeons became the leader of these interventional procedures. As a cardiovascular surgeon, in the last decade, we shared our patients with radiologists and cardiologists only for the reason that they had cath labs. The only way to re-face the patient was at the end of an unsuccessful attempt for percutaneous procedure, or a complication, such as rupture of the

artery, pseudoaneurysm formation, bleeding, or emboli and so on. All the interventions can be of-course performed by different departments, but any department should be capable of fixing their own complications, related to their interventions. In this decade, probably one of the most important advancement in PAD diseases was involvement of vascular surgeons in the world of endovascular and hybrid procedures.

Given the widespread availability of percutaneous procedures, major vascular society guidelines recommend initial percutaneous revascularization. The endovascular techniques for the treatment of patients with lower extremity ischemia include balloon angioplasty, stents, stent-grafts and plaque debulking procedures. Although long segment stenosis/occlusions, multifocal stenoses, eccentric and calcified lesions are more prone to surgical revascularization, use of total occlusion catheters, rotational thrombectomy/atherectomy devices made these complex lesions also treatable with endovascular procedures.

In general, the outcomes of revascularization depend upon the extent of the disease in the subjacent arterial tree (inflow, outflow and the size and length of the diseased segment). IN TASC-II guideline, 'A' lesions represent those which yield excellent results from, and should be treated by, endovascular means; 'B' lesions offer sufficiently good results with endovascular methods that this approach is still preferred first, unless an open revascularization is required for other associated lesions in the same anatomic area; 'C' lesions produce superior enough long-term results with open revascularization that endovascular methods should be used only in patients at high risk for open repair; and 'D' lesions do not yield good enough results with endovascular methods to justify them as primary treatment [21]. For treatment of TASC A lesions, the choice of treatment is endovascular, whereas it is surgery for TASC D lesions. Endovascular treatment is the preferred treatment for type B lesions and surgery is the preferred treatment for good-risk patients with type C lesions, which should be decided on a patient basis. The same is also recommended for femoropopliteal lesions.

The technical and clinical success rate of percutaneous transluminal angioplasty (PTA) of femoropopliteal artery stenoses in all series exceeds 95% [43]. Device developments such as hydrophilic guide wires and technical developments, such as subintimal recanalization, provide high recanalization rates in total occlusions of more than 85% [44]. The technique of subintimal angioplasty is not as dependent on length, but rather on the presence of normal vessel above and below the occlusion to allow access [45]. There is general agreement that for acute failure of PTA of an SFA lesion, stent placement is indicated.

The mechanism of endovascular treatment using balloon angioplasty and stenting is based on plaque disruption and displacement within the arterial wall. By this way, the atheroma is not removed but pressed or crushed by the balloon and redistributed inside and along the arterial wall. Endovascular atherectomy may be performed under local anesthesia using standard caliber arterial sheaths, ranging from 4 to 8 Fr, and provides the theoretical advantage over balloon angioplasty that plaque is removed rather than pressed against the arterial wall, and subsequent balloon dilation is optional depending on the debulking effect. This contributes to substantial luminal gain with less barotrauma even if postdilation is performed, decreasing the risk of dissection and/or neointimal hyperplasia, while avoiding stent placement [46]. In order to improve patency, the combination of lesion debulking using percutaneous

atherectomy and subsequent drug-coated balloon application has been implemented. Drug-coated balloons are proved to be an effective treatment option that does not require a permanent stent [47].

Atherosclerotic iliac artery disease is increasingly being treated with endovascular techniques. A number of new stent technologies can be utilized with high long-term patency, including self-expanding stents, balloon-expandable stents and covered stents, but comparative data on these stent types and in more complex lesions are lacking. Iliac stent choice can be largely categorized into choosing either a balloon-expandable or self-expanding stent based on lesion characteristics (i.e., calcified, fibrous, soft, eccentric, concentric, focal, diffuse, etc.), access site, introducer size, vessel tortuosity and lesion location [48].

For the last few years, our main strategy in treating iliac and femoropopliteal lesions are endo-first, if the lesion has suitable anatomy. For the patients with long segment stenosis and calcified lesions, we prefer rotational atherectomy for debulking of atherosclerotic plaque and then dilatation with drug-coated balloons. If there is a residual dissection, stenting is preferred. Mainly balloon inflatable stents are preferred for proximal iliac lesions, since the plaque over the iliac segments are generally stiff and prone to re-occlusion. For common and SFAs, our main preference is self-expanding nitinol stents, unless the problem is not solved by drug-coated balloons. As surgeons, we always should think of a possibility of reocclusion in these patients and that is why, stenting in the popliteal and distal CFAs should be avoided for alternative surgical sites.

4.1. Retrograde popliteal artery approach for femoral and iliac arterial lesions

To go inside a building, we should open the door first with the right key and in order to perform complex interventions, choosing the right access site is mandatory. There are several access sites described in the literature for endovascular procedures including ipsilateral retrograde common femoral access, ipsilateral antegrade common femoral access, superficial femoral access, contralateral common femoral access, retrograde popliteal access, pedal access, aortic access, radial access and so on. Whatever is the access site, the main goal is to approach stenotic/occluded arterial segments and perform endovascular interventions with success avoiding complications. Since PAD is not a uniform disease, and coexistence of femoral and iliac lesions are present in favorable amount of patients, retrograde contralateral common femoral access can result in procedural failure, especially in patients with unfavorable anatomy of the aortic bifurcation.

The SFA occlusions are generally managed by antegrade ipsilateral or retrograde contralateral femoral approach ending in intraluminal or subintimal recanalization of the vessel lumen [49]. In case of failure, a retrograde popliteal access is considered a valid alternative [50].

The retrograde popliteal approach is a type of subintimal arterial flossing with antegrade-retrograde intervention; it was first described by Tonnesen et al. in 1988 [51]. The main indications for this technique are a short SFA stump, flush occlusion or tandem common/SFA lesions and failure of antegrade approach. Also, coexistence of femoral and iliac lesions necessitates contralateral femoral approach; crossover in the abdominal aorta may complicate

the procedure in patients with angled iliac arteries and aorta. Also, in chronic total occlusions (TASC D), it may be rather difficult to crossover the aorta by the atherectomy devices, even if the patient had normal anatomy in the aortic segment. In SFA lesions, the access over the inguinal region may rather be hard, especially in obese patients.

For the abovementioned patients, popliteal access is a useful method for interventional procedures. The procedure begins in prone position. Prone position has the advantage of contralateral popliteal artery use, either for proximal visualization of the totally occluded artery, or crossover if the retrograde access is not successful. Puncture of the artery and replacement of sheath should always be made by the aid of an ultrasonography, since the popliteal vein is in close proximity to the popliteal artery and sometimes lies over the artery. Visualization of the vein and artery avoids iatrogenic AV fistula formation (**Figure 2**). Since majority of the patients have absent/weak popliteal artery pulses, ultrasonography aided catheterization should always be part of routine practice. After placement of 6–8 Fr sheath, a hydrophilic 0.0035 wire is advanced, and supported either by a slightly angled diagnostic catheter or total occlusion catheter. In total occlusions, the lesion is usually crossed intinally/subintimally by the aid of 6 Fr total occlusion catheter. Confirming that the guidewire is in the patent true lumen proximally, verification is made by angiography. In total occlusion of femoral/iliac arteries, our strategy is to make debulking of atherosclerotic plaque with rotational atherectomy devices and then use drug-coated balloons, or stents according to type and localization of the lesions (**Figure 3**).

A good preoperative evaluation is important before the procedure. Minimum popliteal artery diameter should be at least 4 mm. Local anesthesia should not be made too much in amount

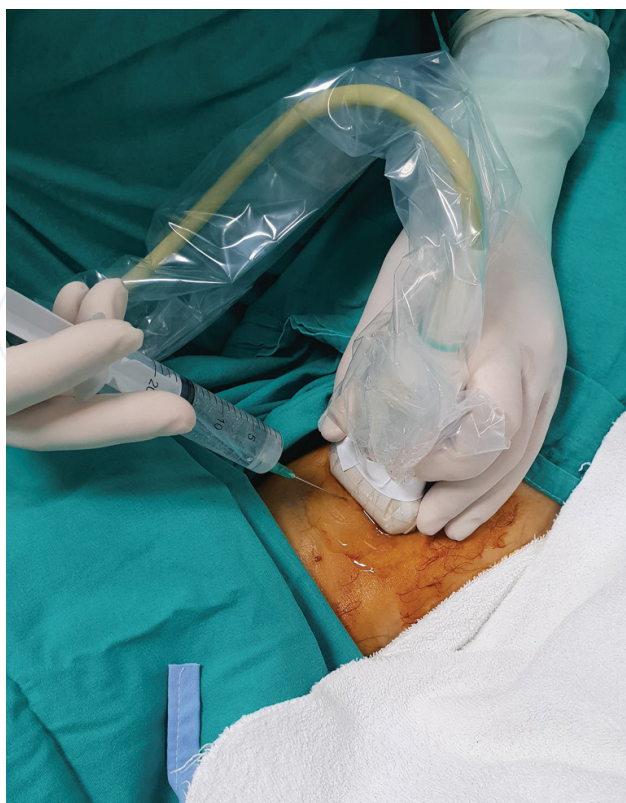


Figure 2. Popliteal artery access using ultrasonography probe after application of minimal local anesthesia.

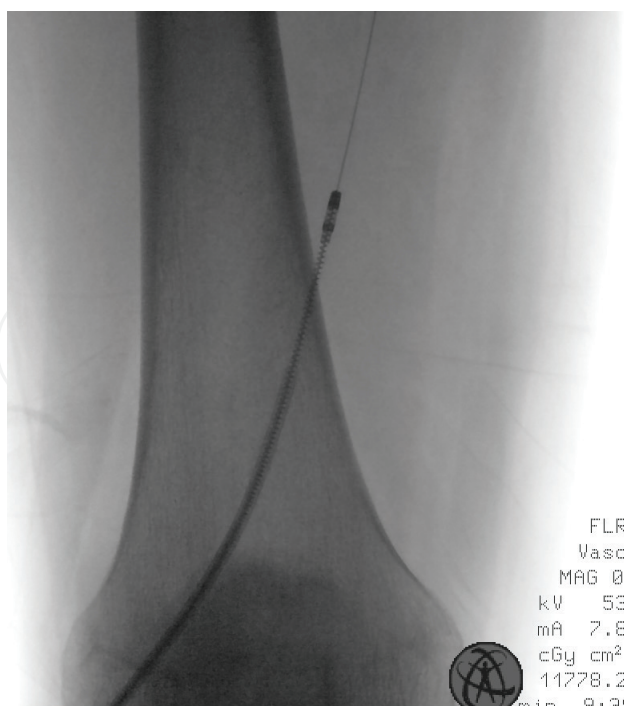


Figure 3. Rotational mechanical atherectomy catheter inserted through the 8F sheath over the popliteal artery in a retrograde fashion.

not to cause compression of the vasculature and obtain a clear image of ultrasound. Just a little amount of local anesthesia is usually enough; after insertion of the needle and guidewire, additional local anesthetic provides comfort of the patient.

Popliteal access is also advantageous in patients with occluded femoropopliteal artery bypass grafts. The atherectomy/thrombectomy can be made either from the native artery or the occluded graft, which usually results in high operational success in our cases. Videos (<https://mts.intechopen.com/download/index/process/195/authkey/b9bb94b883d527ae-1b201a3ea2901c84>) shows pre- and post-procedural angiograms showing total opening of SFA after rotational mechanical atherectomy and drug-coated balloons.

Subintimal guidewire extension and atherectomy usually results in residual dissection in the entry area; but since the direction of dissection is opposite to the direction of flow, in our opinion, this access becomes advantageous. As mentioned before, vascular surgeons should always leave a potential area for future surgical revascularization in the popliteal and common femoral arteries (CFA), after an eventful reocclusion of these segments.

The main disadvantage of this process is mainly based on the prone position of the patient. In complex cases, prolonged procedural times may disturb patients, especially if the patient has chronic obstructive pulmonary disease. Direct cannulation of the artery needs experience of ultrasonography and a learning curve in the very first few cases. Hematoma and post-procedural lack of compression may be overcome by routine use of vascular closure devices (**Figure 4**). Vascular closure devices are especially important when 6F or 8F sheaths are used for vascular access in the popliteal region; because, after the interventional procedure is completed, external compression may cause runoff failure, leading acute obstruction of the popliteal artery.

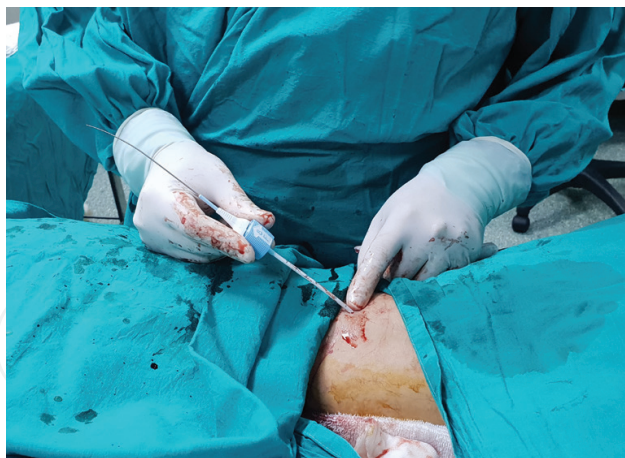

Figure 4. At the end of the endovascular procedure, popliteal artery is closed by vascular closure device to avoid compression.

Retrograde transpopliteal approach is an innovative technique that allows complex endovascular procedures, and should be a part of every vascular interventional's skill set. Proper case selection, operator experience and appropriate technique are essential for clinical and procedural success.

5. Conclusions

PAD is one of the most common diseases affecting quality of life, especially in the elderly population. Since most of these patients are asymptomatic, a careful physician should always be suspicious about the diagnosis. Symptomatic patients should be encouraged to structured exercise therapy, in combination with risk factor modification, pharmacological treatment and invasive treatment strategies when needed.

Endovascular treatment options and the number of procedures dramatically increased in the last decade. A careful preoperative evaluation and plan should be made to achieve success in interventional procedures. Although femoral arteries are the most common site for PAD, iliac impairment is not so rare. In patients with combined iliac and femoral artery diseases, popliteal artery approach is a safe and effective technique for percutaneous revascularization. Interventionists should always have an alternative plan and access site in their reserve for the success of complex procedures.

Conflict of interest

None.

Notes/Thanks/Other declarations

Thanks Prof. Dr. Niyazi Gormus, for his expert opinion, patience and excellent guidance in our practice.

Author details

Omer Tanyeli

Address all correspondence to: otanyeli@gmail.com

Department of Cardiovascular Surgery, Meram Medicine Faculty, Necmettin Erbakan University, Konya, Turkey

References

- [1] Fowkes FG, Rudan D, Rudan I, Aboyans V, Denenberg JO, McDermott MM, et al. Comparison of global estimates of prevalence and risk factors for peripheral artery disease in 2000 and 2010: A systematic review and analysis. *Lancet*. 2013;**382**:1329-1340. DOI: 10.1016/S0140-6736(13)61249-0
- [2] Dieter RS, Chu WW, Pacanowski JP, McBride PE, Tanke TE. The significance of lower extremity peripheral artery disease. *Clinical Cardiology*. 2002;**25**:3-10
- [3] Criqui MH, Fronek A, Barrett-Connor E, Klauber MR, Gabriel S, Goodman D. The prevalence of peripheral arterial disease in a defined population. *Circulation*. 1985;**71**: 510-515
- [4] Schroll M, Munck O. Estimation of peripheral arteriosclerotic disease by ankle blood pressure in a population study of 60-year-old men and women. *Journal of Chronic Diseases*. 1981;**34**:261-269
- [5] Motsumi MJ, Naidoo NG. Pattern and distribution of peripheral arterial disease in diabetic patients with critical limb ischemia (Rutherford clinical category 4-6). *South African Journal of Surgery*. 2017;**55**:48-54
- [6] Diehm N, Shang A, Silvestro A, Dick F, Schmidli J, Mahler F, et al. Association of cardiovascular risk factors with pattern of lower limb atherosclerosis in 2659 patients undergoing angioplasty. *European Journal of Vascular and Endovascular Surgery*. 2006;**31**:59-63
- [7] Haltmayer M, Mueller T, Horvath W, Luft C, Poelz W, Haidinger D. Impact of atherosclerotic risk factors on the anatomical distribution of peripheral arterial disease. *International Angiology*. 2001;**20**:200-207
- [8] Vogt MT, Wolfson SK, Kuller LH. Segmental arterial disease in the lower extremities: Correlates of disease and relationship to mortality. *Journal of Clinical Epidemiology*. 1993;**46**:1267-1276
- [9] Barretto S, Ballman KV, Rooke TW, Kullo IJ. Early-onset peripheral arterial occlusive disease: Clinical features and determinants of disease severity and location. *Vascular Medicine*. 2003;**8**:95-100
- [10] Chen Q, Smith CY, Bailey KR, Wennberg PW, Kullo IJ. Disease location is associated with survival in patients with peripheral artery disease. *Journal of the American Heart Association*. 2013;**2**:e000304

- [11] Aboyans V, Desormais I, Lacroix P, Salazar J, Criqui MH, Laskar M. The general prognosis of patients with peripheral arterial disease differs according to the disease localization. *Journal of the American College of Cardiology*. 2010;**55**:898-903
- [12] Weinberg I, Giri J, Calfon MA, Hawkins BM, Weinberg MD, Margey R, et al. Anatomic correlates of supra-normal ankle brachial indices. *Catheterization and Cardiovascular Interventions*. 2013;**81**:1025-1030
- [13] Halperin JL. Evaluation of patients with peripheral vascular disease. *Thrombosis Research*. 2002;**106**:303-311
- [14] Criqui MH, Langer R, Fronek A, Feigelson H, Klauber M, McCann T, et al. Mortality over a period of 10 years in patients with peripheral artery disease. *The New England Journal of Medicine*. 1992;**326**(6):381
- [15] TASC Working Group. Management of peripheral arterial disease. *Journal of Vascular Surgery*. 2000;**31**:1-296
- [16] Criqui MH, Coughlin SS, Fronek A. Noninvasively diagnosed peripheral arterial disease as a predictor of mortality: Results from a prospective study. *Circulation*. 1985;**72**:768-773
- [17] Kasapis C, Gurm HS. Current approach to the diagnosis and treatment of femoral-popliteal arterial disease. A systematic review. *Current Cardiology Reviews*. 2009;**5**:296-311
- [18] Fowkes FG. The measurement of atherosclerotic peripheral arterial disease in epidemiological surveys. *International Journal of Epidemiology*. 1988;**17**:248-254
- [19] Lijmer JG, Hunink MG, van den Dungen JJ, Loonstra J, Smit AJ. ROC analysis of noninvasive tests for peripheral artery disease. *Ultrasound in Medicine & Biology*. 1996;**22**:391-398
- [20] Carter SA, Tate RB. Value of toe pulse waves in addition to systolic pressures in the assessment of the severity of peripheral arterial disease and critical limb ischemia. *Journal of Vascular Surgery*. 1996;**24**:258-265
- [21] Norgren L, Hiatt WR, Dormandy JA, Nehler MR, Harris KA, Fowkes FG, et al. Inter-society consensus for the management of peripheral arterial disease (TASC II). *European Journal of Vascular and Endovascular Surgery*. 2007;**33**(Suppl 1):1-75
- [22] Sun Z. Diagnostic accuracy of multislice CT angiography in peripheral artery disease. *Journal of Vascular and Interventional Radiology*. 2006;**17**:1915-1921
- [23] Chen Q, Shi Y, Wang Y, Li X. Patterns of disease distribution of lower extremity peripheral artery disease. *Angiology*. 2015;**66**:211-218
- [24] Carpenter JP, Baum RA, Holland GA, Barker CF. Peripheral vascular surgery with magnetic resonance angiography as the sole preoperative imaging modality. *Journal of Vascular Surgery*. 1994;**20**:861-869
- [25] Huegeli RW, Thalhammer C, Jacob AL, Jaeger K, Bilecen D. Intra-arterial MR-angiography on an open-bore MR-scanner compared to digital-subtraction angiography of the

infra-popliteal runoff in patients with peripheral arterial occlusive disease. *European Journal of Radiology*. 2008;**66**:519-525

- [26] Nelemans PJ, Leiner T, de Vet HC, van Engelsehoven JM. Peripheral arterial disease: Meta-analysis of the diagnostic performance of MR angiography. *Radiology*. 2000;**217**:105-114
- [27] Girolami B, Bernardi E, Prins MH, Ten Cate JW, Hettiarachchi R, Prandoni P, et al. Treatment of intermittent claudication with physical training, smoking cessation, pentoxifylline, or nafronyl: A meta-analysis. *Archives of Internal Medicine*. 1999;**159**:337-345
- [28] Baigent C, Keech A, Kearney PM, Blackwell L, Buck G, Pollicino C, et al. Efficacy and safety of cholesterol-lowering treatment: Prospective meta-analysis of data from 90056 participants in 14 randomised trials of statins. *Lancet*. 2005;**366**:1267-1278
- [29] Chobanian AV, Bakris GL, Black HR, Cushman WC, Green LA, Izzo JL Jr, et al. Seventh report of the joint National Committee on prevention, detection, evaluation, and treatment of high blood pressure. *Hypertension*. 2003;**42**:1206-1252
- [30] Yusuf S, Sleight P, Pogue J, Bosch J, Davies R, Dagenais G. Effects of an angiotensin-converting-enzyme inhibitor, ramipril, on cardiovascular events in high-risk patients. The heart outcomes prevention evaluation study investigators. *The New England Journal of Medicine*. 2000;**342**:145-153
- [31] Radack K, Deck C. Beta-adrenergic blocker therapy does not worsen intermittent claudication in subjects with peripheral arterial disease. A meta-analysis of randomized controlled trials. *Archives of Internal Medicine*. 1991;**151**:1769-1776
- [32] Hiatt W, Wolfel E, Meier R, Regensteiner J. Superiority of treadmill walking exercise vs. strength training for patients with peripheral arterial disease. Implications for the mechanism of the training response. *Circulation*. 1994;**90**:1866-1874
- [33] Gerhard-Herman MD, Gornik HL, Barrett C, Barshes NR, Corriere MA, Drachman DE, et al. AHA/ACC guideline on the Management of Patients with Lower Extremity Peripheral Artery Disease: A report of the American College of Cardiology/American Heart Association task force on clinical practice guidelines. *Journal of the American College of Cardiology*. 2016, 2017;**69**:e71-e126
- [34] CAPRIE Steering Committee. A randomised, blinded, trial of clopidogrel versus aspirin in patients at risk of ischaemic events (CAPRIE). *Lancet*. 1996;**348**:1329-1339
- [35] Vos C, Vahl AC. Anticoagulation and antiplatelet therapy in patients with peripheral arterial disease of the femoropopliteal arteries. *The Journal of Cardiovascular Surgery*. 2018;**59**:164-171
- [36] Bedenis R, Stewart M, Cleanthis M, Robless P, Mikhailidis DP, Stansby G. Cilostazol for intermittent claudication. *Cochrane Database of Systematic Reviews*. 2014:CD003748
- [37] Dawson DL, Cutler BS, Hiatt WR, Hobson RW 2nd, Martin JD, Bortey EB, et al. A comparison of cilostazol and pentoxifylline for treating intermittent claudication. *The American Journal of Medicine*. 2000;**109**:523-530

- [38] Murphy TP, Cutlip DE, Regensteiner JG, Mohler ER, Cohen DJ, Reynolds MR, et al. Supervised exercise, stent revascularization, or medical therapy for claudication due to aortoiliac peripheral artery disease: The CLEVER study. *Journal of the American College of Cardiology*. 2015;**65**:999-1009
- [39] Fakhry F, Spronk S, van der Laan L, Wever JJ, Teijink JA, Hoffmann WH, et al. Endovascular revascularization and supervised exercise for peripheral artery disease and intermittent claudication: A randomized clinical trial. *Journal of the American Medical Association*. 2015;**314**:1936-1944
- [40] Nordanstig J, Taft C, Hensäter M, Perlander A, Osterberg K, Jivegard L. Improved quality of life after 1 year with an invasive versus a noninvasive treatment strategy in claudicants: Oneyear results of the invasive revascularization or not in intermittent claudication (IRONIC) trial. *Circulation*. 2014;**130**:939-947
- [41] Vemulapalli S, Dolor RJ, Hasselblad V, Subherwal S, Schmit KM, Heidenfelder BL, et al. Comparative effectiveness of medical therapy, supervised exercise, and revascularization for patients with intermittent claudication: A network meta-analysis. *Clinical Cardiology*. 2015;**38**:378-386
- [42] Pereira CE, Albers M, Romiti M, Brochado-Neto FC, Pereira CA. Meta-analysis of femoropopliteal bypass grafts for lower extremity arterial insufficiency. *Journal of Vascular Surgery*. 2006;**44**:510-517
- [43] Muradin G, Bosch J, Stijnen T, Hunink M. Balloon dilation and stent implantation for treatment of femoropopliteal arterial disease: Metaanalysis. *Radiology*. 2001;**221**:137-145
- [44] London N, Srinivasan R, Naylor A, Hartshorne T, Ratliff D, Bell P, et al. Subintimal angioplasty of femoropopliteal artery occlusions: The long-term results. *European Journal of Vascular Surgery*. 1994;**8**:148-155
- [45] Desgranges P, Boufi M, Lapeyre M, Tarquini G, van Laere O, Losy F, et al. Subintimal angioplasty: Feasible and durable. *European Journal of Vascular and Endovascular Surgery*. 2004;**28**:138-141
- [46] Katsanos K, Spiliopoulos S, Reppas L, Karnabatidis D. Debulking atherectomy in the peripheral arteries: Is there a role and what is the evidence? *Cardiovascular and Interventional Radiology*. 2017;**40**:964-977
- [47] Katsanos K, Spiliopoulos S, Karunanithy N, Krokidis M, Sabharwal T, Taylor P. Bayesian network meta-analysis of nitinol stents, covered stents, drug-eluting stents, and drug-coated balloons in the femoropopliteal artery. *Journal of Vascular Surgery*. 2014;**59**:1123-1133
- [48] Aggarwall V, Waldo SW, Armstrong EJ. Endovascular revascularization for aortoiliac atherosclerotic disease. *Vascular Health and Risk Management*. 2016;**12**:117-127

- [49] Dumantepe M. Retrograde popliteal access to percutaneous peripheral intervention for chronic total occlusion of superficial femoral arteries. *Vascular and Endovascular Surgery*. 2017;**51**:240-246
- [50] Narins CR. Access strategies for peripheral arterial intervention. *Cardiology Journal*. 2009;**16**:88-97
- [51] Tonnesen KH, Sager P, Karle A, Henriksen L, Jorgensen B. Percutaneous transluminal angioplasty of the superficial femoral artery by retrograde catheterization via the popliteal artery. *Cardiovascular and Interventional Radiology*. 1988;**11**:127-131

IntechOpen

