

We are IntechOpen, the world's leading publisher of Open Access books Built by scientists, for scientists

4,800

Open access books available

122,000

International authors and editors

135M

Downloads

Our authors are among the

154

Countries delivered to

TOP 1%

most cited scientists

12.2%

Contributors from top 500 universities



WEB OF SCIENCE™

Selection of our books indexed in the Book Citation Index
in Web of Science™ Core Collection (BKCI)

Interested in publishing with us?
Contact book.department@intechopen.com

Numbers displayed above are based on latest data collected.
For more information visit www.intechopen.com



Arthroscopic Technique to Treat Articular Cartilage Lesions in the Patellofemoral Joint

Anell Olivos-Meza, Antonio Madrazo-Ibarra and
Clemente Ibarra Ponce de León

Additional information is available at the end of the chapter

<http://dx.doi.org/10.5772/intechopen.76617>

Abstract

Cartilage lesions are frequent in routine knee arthroscopy (63%). Among these injuries, 11–23% are located in patella and 6–15% in the trochlea. Treatment of cartilage lesions in patellofemoral joint (PFJ) represents a challenge because of its complex access, high axial loading, and shearing forces. These factors explain the 7% of good results in the PFJ versus 90% in femoral condyles for autologous chondrocyte implantation (ACI). Microfracture (MF) as the first line of treatment has revealed limited hyaline-like cartilage formation in comparison to ACI. This fibrocartilage deteriorates with the time resulting in inferior biomechanical properties. Important issues that enhance the results of cartilage repair procedures in PFJ are associated with the restoration of the joint balance as unloading/realignment techniques. In the literature, there is no description of any convenient *arthroscopic technique* for ACI. The reported techniques usually require to set up the patient in prone position to perform the arthroscopy making it difficult to treat associated knee malalignment or instability. Others are open techniques with more risk of morbidities, pain, and complications and longer recovery time. In this chapter, we will describe a novel all-arthroscopic technique to treat cartilage lesions in the patella that permits the correction and treatment of associated lesions in the same patient position.

Keywords: cartilage lesions, patellofemoral joint, arthroscopic treatment, autologous chondrocyte implantation, knee

1. Introduction

The patella is the biggest sesamoid bone in the body. The main functions of the patella are to direct forces of the quadriceps and to protect the deeper knee joint and the quadriceps tendon

from frictional forces [1, 2]. Posteriorly the patella is covered by a thick hyaline cartilage which decreases friction in the PFJ and allows a correct and smooth flexion of the knee. The patella contact area changes when knee flexion increases showing maximum contact between 60 and 90° of flexion.

The patellofemoral pain syndrome is very common in the general population. It is often seen in young people with high physical activity level in both competitive and recreational sports. Patellar malalignment and instability with or without articular cartilage lesions (ACL) are usually the source of pain. Repetitive microtrauma as well as acute severe trauma can lead to damage of the articular cartilage of the patella and when those lesions are not treated produces severe pain, disability, and poor quality of life. The accurate detection and treatment of ACL are essential for the proper function of the knee. However, when those lesions are left untreated, it can alter normal distribution of weight-bearing forces and may lead the development of early osteoarthritis (OA) [3].

Articular cartilage injuries are commonly found in knee arthroscopies (61–63%). The majority of these lesions are found in the medial femoral condyle (58%), while chondral lesions affecting the patella are the second most common (11%) location [4, 5]. Hielle et al. found that 17% of patients having arthroscopy had an articular cartilage injury located in the patella or trochlea [4]. Nomura et al. also found 35 patients with severe articular cartilage injuries in the patella out of 37 patients with a first-time acute patellar dislocation [6]. Articular cartilage lesions of the PFJ can be especially challenging because of the complex biomechanical environment and the significant forces experienced within this compartment during weight-bearing activity. Given the poor intrinsic capacity of cartilage to heal, surgical intervention is often necessary for symptomatic relief.

Basic nonsurgical management is recommended as an initial treatment modality to treat chondral lesion of patellofemoral joint for at least 6 months [7]. This option is recommended for patients without significant pain and without mechanical symptoms. Anti-inflammatory medications, activity modification, weight loss, and muscle strengthening have been shown to improve pain [8, 9]. However, surgical management is recommended when symptoms are persistent despite the nonsurgical treatment and when the function is limited by symptoms. Surgical options depend on the lesion size, depth, location, and status of the underlying subchondral bone. Microfracture, ACI, DeNovo juvenile chondrocyte implantation, osteochondral autograft transfer, and osteochondral allograft transplantation are considered cartilage restoration procedures for PFJ.

Autologous chondrocyte implantation is currently the preferred and most effective procedure in the management ACL. Microfractures have shown great short-term results for well-contained lesions less than 2 cm²; however, 47–80% of patients have shown functional deterioration between 18 and 36 months after microfracture technique. Some authors attribute this decline to incomplete defect filling and poor integration with the surrounding normal cartilage as well as an inferior capacity of the fibrocartilage to resist articular stress [10–14]. ACI is considered a first-line surgical treatment in large lesions (>4 cm²) and in secondary treatment for patients with persistent symptoms following treatment with another procedure [15]. However, outcomes of ACI in PFJ have shown mixed results. Pascual-Garrido et al. reported a

statistically significant improvement in patients treated with isolated ACI on the basis of several functional scoring systems as well as a 71% satisfaction rate in patients [16]. In a follow-up by Brittberg et al., 81% of the patients had good to excellent results at 2 years and 83% at 5–11-year follow-up [17].

ACI performed in conjunction with anteromedialization (AM) of the patella for the correction of malalignment has shown better results with significant improvements in functional and satisfaction outcomes [16].

As with most orthopedic procedures, less invasive procedures such as arthroscopy are being preferred because of the decreased associated comorbidity and the accelerated postoperative rehabilitation for earlier return to full physical function [18]. Biant et al. found that the viability of cells in ACI technique was 16 times higher for open approach-delivered implants than those delivered arthroscopically. However, no clinical outcomes were evaluated since it was a cadaveric experiment [19]. On the other hand, Edwards et al. showed that patients with arthroscopic ACI required a significantly shorter hospital stay after their procedure and presented fewer post-surgery complications than those who underwent ACI performed through a mini-open arthrotomy [20].

Recent advances in our understanding of focal chondral lesions, surgical techniques, and surgical technology have provided a new array of treatment options for symptomatic patients with cartilage lesions of the PFJ. The aim of the present chapter is to describe a surgical procedure for the arthroscopic ACI in the patellofemoral joint.

2. Arthroscopic chondrocyte implantation in the PFJ

Before implantation surgery, a knee arthroscopy was performed for biopsy. Two to three osteochondral cylinders of 4-mm diameter were taken from a non-weight-bearing area of the knee (**Figure 1**). Samples were processed in the laboratory for chondrocyte isolation, in vitro expansion, and cell-polymer construct formation as Masri et al. described [21]. In a second arthroscopic procedure, the constructs with cultured chondrocytes were implanted.

After regional anesthesia the patient was settled in supine position; the knee was prepared and draped in a conventional manner. A tourniquet was placed around the proximal thigh, although normally it was not insufflated. A conventional longitudinal anterolateral portal was established for arthroscopic examination of the knee joint using a superolateral portal for irrigation. The articular cartilage injury was identified, measured, and prepared for construct implantation.

2.1. Arthroscopic chondrocyte implantation in the trochlea

Cartilage lesion was measured and debrided to leave stable walls (**Figure 2A**). When the lesion was in the medial trochlea, an oblique anteromedial portal was established over the lesion to have perpendicular access. If the lesion was on the lateral trochlea, the anterolateral portal was extended proximally or distally to allow perpendicular access. A 2-mm hole

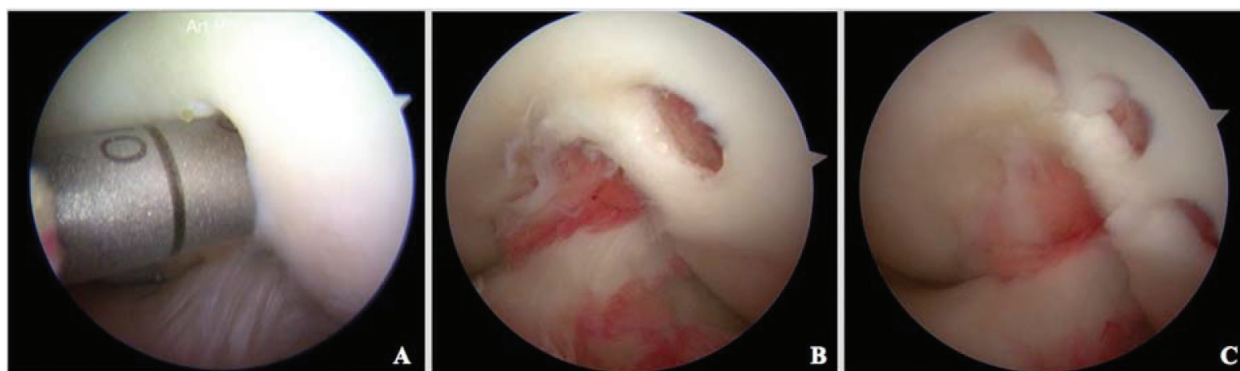

Figure 1. Osteochondral biopsy harvesting. (A) An osteochondral harvester (COR; DePuy Mitek, Raynham, MA) was used to get one to three 4-mm diameter biopsies in a non-weight-bearing area adjacent to the intercondylar notch (B and C).

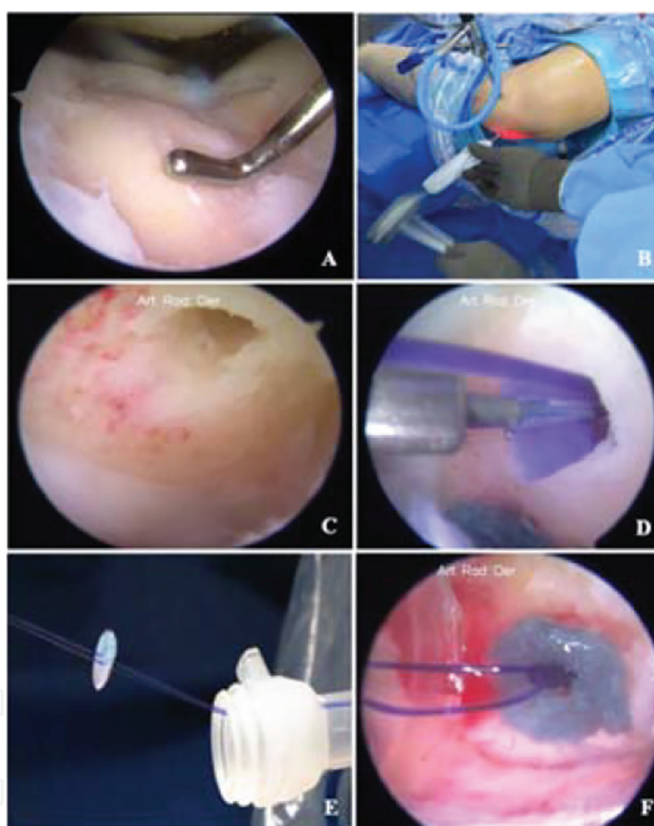


Figure 2. Matrix chondrocyte implantation in trochlear lesions. (A) Cartilage lesion is measured and debrided with a curette to leave stable walls. (B–D) A 1.7-mm hole was made in the center the lesion, and an absorbable anchor charged with 0-PDS suture is inserted. (E) The implant is fixed with self-locking arthroscopic sliding knot and two or three additional half-hitch knots.

was made in the center of every centimeter of cartilage lesion. An absorbable 1.9-mm anchor (MINILOK, Depuy Synthes Mitek, Raynham, MA) with 0-PDS suture (Ethicon, Somerville, NJ) was inserted through the anteromedial or anterolateral portal (**Figure 2B–D**). The cell-scaffold disk was prepared on the side table. An 8-mm transparent cannula was then inserted

through the portal directly over the lesion, and the sutures from the anchor were pulled outside the joint through an arthroscopic cannula (**Figure 2E**). The anchor sutures were passed in the construct through two needles (20 G × 32 mm); the construct was slide into the joint to place it in the bottom of the cartilage lesion. A self-locking arthroscopic sliding knot was used to fix the implant (**Figure 2F**). Once the construct was sitting in place at the bottom of the lesion, the knot was tightened by pulling on the wrapping limb of the suture, and two additional half-hitch knots were tied with the assistance of a knot pusher. The sutures were then cut flush to the knot and the cannula was retrieved. Stability of the implant was then tested with the probe, and the knee was taken through a range of motion to verify the stability and permanence of the implant at the repair site.

2.2. Arthroscopic chondrocyte implantation in patella

Implantation of constructs in patella is performed with the use of an anterior cruciate ligament tibial guide (ACUFEX; Smith-nephew, Andover, MA) with different grades of angulation. Standard arthroscopy evaluation is done to evaluate additional lesions.

The cartilage lesion is identified, measured, and debrided. The tibial guide is introduced either through medial or lateral portal to have easy access to the lesion (**Figure 3A**). Using the elbow aimer of the tibial guide, the angle was adjusted depending on the better position of the tip over the center of the lesion (**Figure 3D**). Two holes are drilled with a cable wire (Kirschner 0.062") from the anterior cortex of the patella to the subchondral bone (**Figure 3B and E**); the holes are placed in the center of every 10 mm of cartilage lesion. The cable wires

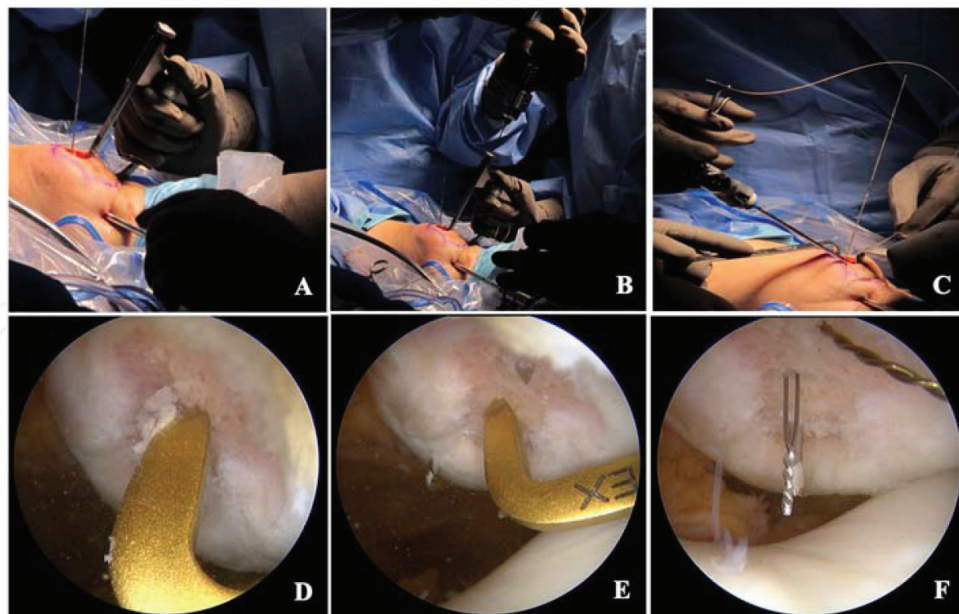


Figure 3. Arthroscopic chondrocyte implantation in patella. (A and D) The ACL tibial guide is introduced by the portal that permits better position to the center of the lesion. (B and E) Two holes are drilling from the anterior cortex of the patella to the subchondral bone at the center of the lesion. (C and F) An anterior skin incision is made over the patella; deep direction is necessary to visualize the entrance of both cable wires. Cable wires are removed with the drill, and a chia passer is inserted in every hole until it is visible into the joint space.

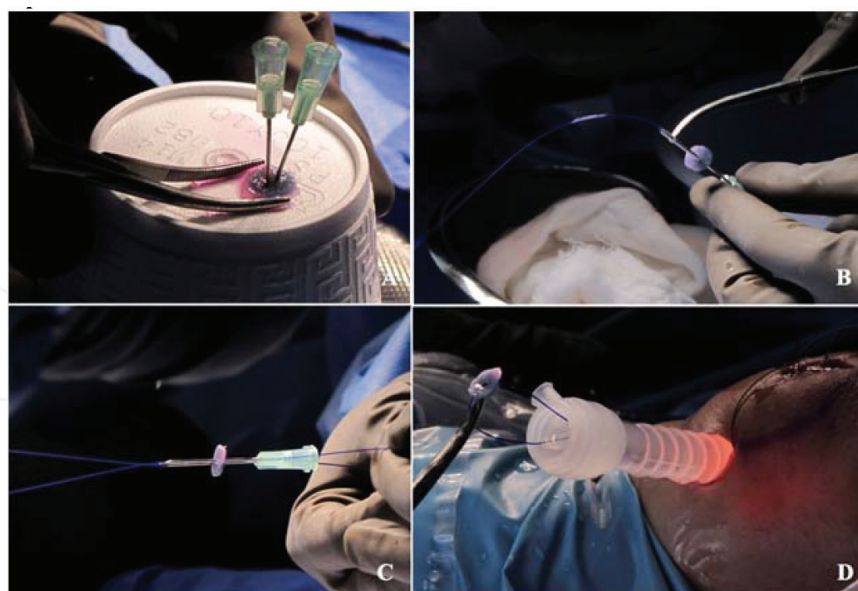


Figure 4. Preparation of the chondrocytes construct with a 0-PDS suture. (A) Two needles (20 G \times 32 mm) are inserted in the center of the construct leaving 2 mm of distance. (B and C) The ends of 0-PDS are passed through the needles. (D) Once the PDS is placed in position, needles are removed, the ends of the PDS are introduced in the loop of every chia passer, and the construct is pulled slowly through a 10-mm cannula.

are left in place, while the tibial guide is removed from the joint. A 15-mm skin incision is performed anterior to the patella connecting the two cable wires (**Figure 3C**). Deep dissection is performed until the periosteum to identify the cable wires; then those are removed with the drill, and a wire passer (CHIA PERCPASSER, Suture Passer Depuy Synthes Mitek, Raynham, MA) is inserted in every hole from anterior cortex of the patella to the inside until the chips are visible and accessible into the joint space by the scope (**Figure 3F**). The chia tip is advanced into the joint and is grabbed with a grasper from either medial or lateral portals.

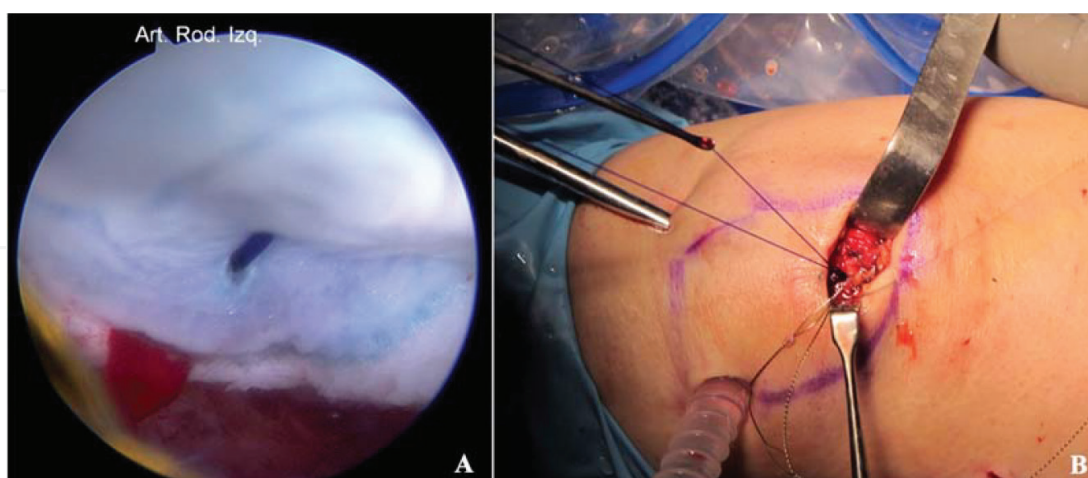


Figure 5. Fixation of the construct. (A and B) Once the construct is placed in the bottom of the lesion, three to four sliding knots are tied over the anterior cortex of the patella. Notice that different to trochlear implantation in patellar technique the knots are out of the articular space.

In the back table, the construct was prepared before using two percutaneous needles (20 G × 32 mm) that were inserted in the center (**Figure 4A**). One 0-PDS suture is folded, and its ends are passed in the construct through the needle tips (**Figure 4B** and **C**). Once PDS is placed in the center of the construct, needles are removed.

A 10 mm cannula is placed in the chosen portal where the chia passers were grabbed; every end of the 0-PDS suture with the construct is introduced in the loop of the wire passer and then pulled to introduce the construct into the joint (**Figure 4D**). Once the construct is placed in the bottom of the lesion (**Figure 5A**), a non-sliding knot was performed and tied over the anterior cortex of the patella outside the joint (**Figure 5B**). Steps are repeated if more than one construct is needed. Portals and accessory incision are closed in the traditional manner.

3. Conclusion

Arthroscopic autologous chondrocyte implantation in the PFJ is a reproducible and safety technique that permits the early recovery of the patient and the treatment of concomitant lesions as patellar realignment and/or ligament reconstruction.

3.1. Take-home points

- The described technique is recommended for focal cartilage lesions with healthy and stable cartilage around the lesion.
- During the lesion debridement, it is necessary to leave stable walls of normal cartilage and take out the calcified layer.
- Correction of associated lesions as instability or malalignment is mandatory to enhance better results in the treatment of cartilage lesions of PFJ.

Acknowledgements

This work was supported by the Mexican Council of Science (CONACyT) Grant SALUD-PDCPN-2013-2101-215138 and Technology, Science, and Innovation Secretary Grants SECITI 079 BIS/2013 and SECITI/INR/GOB-25/2013.

Conflict of interest

The authors declare that there is no conflict of interest with respect to the research, authorship, and/or publication of this chapter.

A. Appendices and nomenclature

Indications for proposed technique in PFJ cartilage lesions

Lesion	Technique
Focal lesion medial facet + patellar dislocation	Arthroscopic ACI + MPFL reconstruction
Focal lesion medial facet + patellar dislocation + lateral patellar inclination	Arthroscopic ACI + MPFL reconstruction + lateral retinacular release
Focal lesion lateral facet + lateral patellar inclination	Arthroscopic ACI + lateral retinacular release
Focal lesion lateral facet + lateral patellar inclination + lateral hiperpresion	Arthroscopic ACI + lateral retinacular release + Tibial Tuberosity Osteotomy

Postoperative management and rehabilitation

Stage	Week	Process	Indication
Cellular proliferation	4–6	Chondrocyte stimulation	Continuous passive motion (6–8 h a day)
	4		Full weight bearing in patients with PFJ lesions
	8–12		Weight bearing with toe or heel-touch for femoral condyle defects
Transition	16–24	Matrix expansion	Weight bearing for poorly contained lesions and patients with multiple lesions
Remodeling	24–48	Cartilage hardens	Strength within 80–90% of contralateral extremity
			Perform ADL

Important considerations

Surgical treatment for cartilage lesions in PFJ is recommended when patient has persistent symptoms despite conservative treatment

Satisfactory results are reported in the treatment of isolated cartilage lesions in the patella with ACI (65%); however, when ACI was combined with unloading tibial tubercle osteotomy (AMZ), better results are found (85%)

Clinically both microfracture and autologous chondrocyte implantation improve significantly over time after treatment. However, studies have demonstrated that quantitative assessment with T2-mapping in ACI is more similar to native cartilage than microfracture after 12 months.

Author details

Anell Olivos-Meza¹, Antonio Madrazo-Ibarra¹ and Clemente Ibarra Ponce de León^{2*}

*Address all correspondence to: cibarra.corresponding@hotmail.com

1 Orthopedic Sports Medicine and Arthroscopy Service, Instituto Nacional de Rehabilitación, Mexico City, Mexico

2 Instituto Nacional de Rehabilitación, Mexico City, Mexico

References

- [1] Fox AJSA, Wanivenhaus FF, Rodeo SAS. The basic science of the patella: Structure, composition, and function. *The Journal of Knee Surgery*. 2012;**25**(2):127-141
- [2] Tecklenburg KK, Dejour DD, Hoser CC, et al. Bony and cartilaginous anatomy of the patellofemoral joint. *Knee Surgery, Sports Traumatology, Arthroscopy*. 2006;**14**(3):235-240
- [3] Insall JJ, Falvo KAK, Wise DWD. Chondromalacia patellae. A prospective study. *The Journal of Bone and Joint Surgery. American Volume*. 1976;**58**(1):1-8
- [4] Hjelle K, Solheim E, Strand T, et al. Articular cartilage defects in 1,000 knee arthroscopies. *Arthroscopy*. 2002;**18**(7):730-734
- [5] Widuchowski WW, Widuchowski JJ, Trzaska TT. Articular cartilage defects: Study of 25,124 knee arthroscopies. *The Knee*. 2007;**14**(3):177-182
- [6] Nomura E, Inoue M, Kurimura M. Chondral and osteochondral injuries associated with acute patellar dislocation. *Arthroscopy*. 2003;**19**(7):717-721
- [7] Kramer K. Management of patellar and trochlear chondral injuries. *Operative Techniques in Orthopaedics*. 2007;**17**(4):10-10
- [8] Strauss EJE, Fonseca LEL, Shah MRM, et al. Management of focal cartilage defects in the knee—Is ACI the answer? *CORD Conference Proceedings*. 2011;**69**(1):63-72
- [9] Chiu JKWJ, Wong Y-MY, Yung PSHP, et al. The effects of quadriceps strengthening on pain, function, and patellofemoral joint contact area in persons with patellofemoral pain. *American Journal of Physical Medicine & Rehabilitation*. 2012;**91**(2):98-106. Illustrates important non-operative modalities for the treatment of patellofemoral chondral defects
- [10] Mithoefer K, McAdams T, Williams RJ, et al. Clinical efficacy of the microfracture technique for articular cartilage repair in the knee: An evidence-based systematic analysis. *The American Journal of Sports Medicine*. 2009;**37**(10):2053-2063. This study shows evidence as to the efficacy of microfracture as a modality of treatment for chondral lesions about the knee
- [11] Kreuz PC, Erggelet C, Steinwachs MR, et al. Is microfracture of chondral defects in the knee associated with different results in patients aged 40 years or younger? *Arthroscopy*. 2006;**22**(11):7-7
- [12] Williams RJR, Harnly HWH. Microfracture: Indications, technique, and results. *Instructional Course Lectures*. 2007;**56**:419-428
- [13] Frisbie DDD, Trotter GWG, Powers BEB, et al. Arthroscopic subchondral bone plate microfracture technique augments healing of large chondral defects in the radial carpal bone and medial femoral condyle of horses. *Veterinary Surgery*. 1999;**28**(4):242-255
- [14] Gudas RR, Kalesinskas RJR, Kimtys VV, et al. A prospective randomized clinical study of mosaic osteochondral autologous transplantation versus microfracture for the treatment

of osteochondral defects in the knee joint in young athletes. *Arthroscopy*. 2005;**21**(9): 10-10

- [15] Strauss EJ, Galos DK. The evaluation and management of cartilage lesions affecting the patellofemoral joint. *Current Reviews in Musculoskeletal Medicine*. 2013 Jun;**6**(2): 141-149. DOI: 10.1007/s12178-013-9157-z. PubMed PMID: 23392780; PubMed Central PMCID: PMC3702778
- [16] Pascual-Garrido C, Slabaugh MA, L'Heureux DR, Friel NA, Cole BJ. Recommendations and treatment outcomes for patellofemoral articular cartilage defects with autologous chondrocyte implantation: Prospective evaluation at average 4-year follow-up. *The American Journal of Sports Medicine*. 2009 Nov;**37**(Suppl 1):33S-41S. DOI: 10.1177/0363546509349605 Epub 2009 Oct 27. PubMed PMID: 19861699
- [17] Brittberg MM, Peterson LL, Sjögren-Jansson EE, et al. Articular cartilage engineering with autologous chondrocyte transplantation. A review of recent developments. *The Journal of Bone and Joint Surgery. American Volume*. 2003;**85**(A Suppl 3):109-115
- [18] Erggelet C, Sittinger M, Lahm A. The arthroscopic implantation of autologous chondrocytes for the treatment of full-thickness cartilage defects of the knee joint. *Arthroscopy*. 2003;**19**(1):108-110. DOI: 10.1053/jars.2003.50025
- [19] Biant LC, Simons M, Gillespie T, McNicholas MJ. Cell viability in arthroscopic versus open autologous chondrocyte implantation. *The American Journal of Sports Medicine*. 2017 Jan;**45**(1):77-81. DOI: 10.1177/0363546516664338. Epub 2016 Oct 1. PubMed PMID: 27613761
- [20] Edwards PK, Ebert JR, Janes GC, Wood D, Fallon M, Ackland T. Arthroscopic versus open matrix-induced autologous chondrocyte implantation: Results and implications for rehabilitation. *Journal of Sport Rehabilitation*. 2014 Aug;**23**(3):203-215. DOI: 10.1123/jsr.2013-0042. Epub 2014 Apr 3. PubMed PMID: 24700445
- [21] Masri M, Lombardero G, Velasquillo C, Martinez V, Neru R, Villegas H, Ibarra C. Matrix-encapsulation cell-seeding technique to prevent cell detachment during arthroscopic implantation of matrix-induced autologous chondrocyte implantation. *Arthroscopy Journal*. 2006;**22**(6):23-24. DOI: 10.1016/j.arthro.2006.04.048