

# We are IntechOpen, the world's leading publisher of Open Access books Built by scientists, for scientists

4,800

Open access books available

122,000

International authors and editors

135M

Downloads

Our authors are among the

154

Countries delivered to

TOP 1%

most cited scientists

12.2%

Contributors from top 500 universities



WEB OF SCIENCE™

Selection of our books indexed in the Book Citation Index  
in Web of Science™ Core Collection (BKCI)

Interested in publishing with us?  
Contact [book.department@intechopen.com](mailto:book.department@intechopen.com)

Numbers displayed above are based on latest data collected.  
For more information visit [www.intechopen.com](http://www.intechopen.com)



---

## Bicuspid Aortic Valve

---

Ayşe İnci Yıldırım and Aysu Türkmen Karaağaç

Additional information is available at the end of the chapter

<http://dx.doi.org/10.5772/intechopen.76643>

---

### Abstract

Bicuspid aortic valve (BAV) is one of the most common congenital diseases, affecting 1–2% of the general population. Although most of them are sporadic, some familial cases have also been detected. BAV is a complex developmental and progressive pathology, which may present with various clinical findings from newborn to adulthood. It may be suspected during cardiac auscultation or may be diagnosed by echocardiography incidentally. Some BAV cases may remain symptomless for years, with findings like valvular stenosis, insufficiency, or dilatation in the ascending aorta, whereas some others may present with early severe aortic valve dysfunction, premature congestive heart failure, and aortic aneurysms even in the newborn period. Such heterogeneous presentations of BAV phenotypes may be associated with congenital, genetic, and/or connective tissue abnormalities. The natural course of BAV is nonpredictable, it may lead to severe morbidity and mortality.

**Keywords:** aortopathy, aortic regurgitation, aortic stenosis, aortic dilatation, aortic dissection

---

### 1. Introduction

Bicuspid aortic valve (BAV) is one of the most common congenital heart diseases. It is phenotypically variable and genetically heterogeneous. The prevalence of the disease has been determined according to the results of echocardiographic screening and necropsy studies. Some patients with isolated BAV may remain asymptomatic throughout their lives, so they may be diagnosed accidentally in echocardiographic screening. Although it is difficult to define the real incidence of BAV, it is accepted to have a prevalence of 0.5–2% in the general population, with a higher prevalence in males than females: M/F = 3/1 [1, 2]. The clinical presentation of BAV is highly variable. Its major manifestations are aortopathy, valvular

dysfunctions, endocarditis, and dissection. In the patients presenting with valvular dysfunction earlier in life, aortic regurgitation (AR) is more common, whereas aortic stenosis (AS) is more prevalent later in life, after the fourth decade. Valve phenotypes, genetic, and hemodynamic factors have been proposed as underlying mechanisms of aortopathy. Ascending aortic aneurysm is generally due to aortopathy and hemodynamics; however, the aortic root aneurysm is considered to be a consequence of aortopathy rather than hemodynamics, especially in younger patients. The asymptomatic BAV patients with normal valvular function require surgical treatment less frequently than those with valvular dysfunction and aortopathy during their lives.

Moreover, BAV may be associated with several genetic disorders with cardiovascular manifestations such as hypoplastic left-heart syndrome, congenital left-sided obstructive lesions (coarctation of aorta, Shone complex), ventricular septal defect, and syndromic conditions (Turner, Loeys Dietz). This chapter enrolls only the isolated bicuspid aortic valves.

## 2. Genetic and inheritance

### 2.1. Associated with genetic syndrome

Although most of the BAV patients are sporadic or familial, some may have the symptoms known genetic syndromes as Trisomy 18, Williams syndrome, and Turner syndrome. The highest penetrance of BAV (>30%) occurs in woman with Turner syndrome caused by partial or complete absence of one X chromosome [3]. In the general population, BAV is more prevalent in men than women, suggesting that the loss of genes on the X chromosome may predispose to BAV phenotype [3, 4].

### 2.2. Familial inheritance and genetic etiologies

The heritability of BAV is now well established; however, the genes linked to the defect remain largely unknown. Autosomal dominant, X-linked, and familial modes of inheritance have been reported. BAV heritage revealed a high incidence of familial clustering. The study performed in the Canadian population revealed that 11 of 30 families (36%) had at least 1 additional member with BAV, and the recurrence rate in first-degree relatives was 9% [5]. Another study reported that 100 out of 448 subjects in a Mediterranean population had BAVs, 348 of which were first-degree relatives. In this study, the BAV recurrence rate in the first-degree relatives was 4.6%. This value was clearly lower than that in the Canadian population. The populations or geographic areas may affect the prevalence of BAVs [6].

Epidemiologic studies have demonstrated that BAV is heritable and follows an autosomal dominant mode of transmission with reduced penetrance and variable expressivity [7, 8]. Through the linkage analysis of BAV pedigrees, investigators have found multiple genetic loci and chromosomes associated with BAV disease [7–16]. The most significantly associated genes and the chromosomes they are located on are shown in **Table 1**. However, some of these gene mutations have been found to be related with aortopathies. Several mouse studies have showed that the NOTCH1 gene mutation plays an important role in the development of

Candidate genes	Chromosomal regions
TGFBR2 (Transforming growth factor, beta receptor II)	3p24.1
NKX2.5 (NK2 Homeobox 5)	5q35.1
NOTCH1 (Translocation-associated notch protein TAN-1)	9q34.3
ACTA2 (Actin, alpha 2)	10q23.31
MYH6 (Myosin heavy chain 6)	14q11.2
MYH7 (Myosin heavy chain 7, cardiac muscle, beta)	14q11.2
FBN1 (Fibrillin 1)	15q21.1
ENG (Endoglin)	9q34.11
AXIN1 (Axin 1)	16p13.3
KCNJ2 (Potassium channel, inwardly rectifying subfamily J, member 2)	17q24.3
GATA5 (GATA binding protein 5)	20q13.33
PDIA2 (Protein disulfide isomerase family A, member 2)	16p13.3
TGFBR 1 (Transforming growth factor, beta receptor I)	9q22.33

**Table 1.** Genes with association with bicuspid aortic valve.

ascending aorta aneurysm and BAV [8, 9, 16]. Although the FBN1 gene mutation frequently accompanies Marfan syndrome, its association with BAV and ascending aorta dilatation has been shown in a recent study [17]. The pathologic hallmark of aortic aneurysm is medial degeneration. Disruption of the smooth muscle cells' (SMC) contractility due to mutations may lead to aortic aneurysm. Mutations in the MYH11 and ACTA2 genes are associated with the familial thoracic aortic aneurysms [18].

Consequently, BAV and aortopathy are complex multifactorial and multigenetic pathologies. Genetic, epigenetic, and environmental modifiers may be responsible for the variable penetrance and phenotypic expression [4].

### 3. Aortic root

#### 3.1. Embryology of aortic root

Cardiac and valve morphogenesis occur in early fetal life. Actually the abnormal valvulogenesis of BAV has not been clearly understood. Earlier theories proposed that abnormal blood flow across the developing valves would result in the failure of cusp separation. Current theories suggest that cell migration, signaling pathway, and genetic susceptibility are the main factors in the development of BAV disease.

The embryonic heart and aorta are developed from three precursor cells: proepicardial cells, cardiogenic mesodermal cells (contribute to first and second heart fields [SHfs]), and neural crest cells. Second heart field (SHF) and the cardiac neural crest (CNC) contribute to the

development of aortic root, ascending aorta, and aortic arc. Paraxial mesoderm plays role in the development of descending aorta [19, 20]. First heart field (FHF) forms the early embryonic heart tube that contributes to the left ventricle and a portion of the right ventricle and atria. SHF contributes to the myocardium of the outflow tract to form the truncus arteriosus. Mesenchymal cells originating from the migrating cardiac neural crest cells reach the outflow tract cushions and contribute to the formation of the aortic and pulmonary valves together with the endocardially derived mesenchymal cells. Abnormal migration of neural crest cells has been postulated as a common pathway that results in BAV and aortopathy [21–24].

Several proteins are used to determine the positional and functional relationship of various cellular populations during embryogenesis. Conical Wnt, non-conical Wnt, TGF- $\beta$ , fibroblast growth factor, bone morphogenetic protein, and Notch are some important proteins in the development of aortic valve and aorta. Errors of this pathway may result in various outflow tract structural abnormalities including BAV disease [11, 16, 19, 23].

### 3.2. Histopathology of the aorta

The normal aortic valve involves three layers. The first layer is the inner intimal layer, which consists of endothelial cells. The second layer is the thicker medial layer formed of smooth muscle cells (SMCs) and elastin. The elastin is arranged in fenestrated sheets (lamellae) between which collagen fibers, thin layers of proteoglycan-rich extra-cellular matrix (ECM), and SMCs are located. Thin elastic fibers embed lamellae into a three-dimensional network and connect them with SMCs. The third layer is the strong adventitial layer with collagen fibers wrapping the aorta [25, 26]. The relatively high collagen content of the adventitia prevents vascular rupture at extremely high pressures [27]. SMC and ECM play an important role both in the normal tissue development and in the main mechanical function of the aortic media [2, 28, 29]. SMCs are the major cell types of the aortic wall that synthesize and organize the ECM with the elastic fiber network in the arterial wall [25, 26, 30]. SMCs also provide lamellar organization, depending on the diameter and stress applied upon the vessels during embryogenesis. ECM, mainly composed of elastin and collagen, is important for the aortic strength and flexibility to withstand the arterial blood pressure [26]. The number of lamella is greater in larger vessels facing greater wall tension and it seems to remain stable after birth. In the normal aorta, SMCs have a little active role in managing wall tension; microfibrillar structure is the major passive contributor [26, 30]. As the vessel wall matures, SMCs condense down around the endothelial tube to form the circumferential layers, which will finally define the elastic lamellae of the mature vessel [30].

### 3.3. Pathogenesis of aortopathy

Aortopathy is very complex pathology, in which both cellular and extracellular mechanisms are involved. Possible mechanisms for aortopathy in patients with BAV include medial degeneration (elastic fiber fragmentation and smooth muscle cell apoptosis), fibrillin-1 deficiency, increased metalloproteinase (MMP), and decreased MMP tissue inhibitor expression.

Medial degeneration: Failure of the balance between the synthesis and degradation of ECMs in the aortic wall leads to aortic aneurysm. Especially elastin is the major fibrillar component

in the arterial wall, so its destruction directly leads to the expansion of aorta. Moreover, some intrinsic medial degenerative differences have been identified between TAV and BAV patients. While degeneration in TAVs has been attributed to inflammation and accelerated aging, it has been attributed to the maturation defect in BAVs. Several BAV studies have revealed noninflammatory loss of vascular SMCs, less-differentiated vascular SMC, low laminin A/C, and progerin expression as the other causes of medial degeneration [27, 30, 31]. The total thickness of the aortic media is the same for BAV and TAV aortas, but the distance between the elastic lamellae is greater and the lamellae themselves are thinner and more fragmented in BAV patients [30, 32]. It was suggested that matrix disruption and SMC apoptosis were earlier in BAVs with stenosis than TAVs with respect to the dilatation of aorta [33]. The patients with ascending aorta dilatation with BAV showed lesser cystic medial necrosis (focal loss of vascular smooth muscle cell (VSMC) nuclei in the media) than those with TAV [30]. Nondilated BAV aortas may have higher rates of vascular SMC apoptosis, particularly at the convexity, where wall stress is expectedly higher. Stress-dependent BAV matrix changes may trigger early apoptosis [33].

**Deficiency of fibrillin-1:** Maturation defect is maintained in the dilated aortic wall in BAV patients. Fibrillin-1, which stabilizes the vascular wall, is secreted by the SMC. It is low in BAV patients because of the immaturity of SMC [21]. Deficiency of fibrillin-1 results in vascular SMC detachment, matrix disruption, and apoptosis, which ultimately result in a fragile aorta, less suited to deal with stress associated with valvular dysfunction. Decreased levels of fibrillin-1 may also lead to thinning and weakening of the aortic wall. Some studies have showed that aortic tissues in BAVs have significantly less fibrillin-1 than TAV aortas [34, 35].

**Increased activity of MMPs:** To date, most studies have focused on MMP-2 and MMP-9, which belong to a subclass of MMP. An increase in MMPs, enzymes that process or degrade the extracellular matrix, may lead to the weakening of the aortic wall and may be associated with the development of aortic aneurysms. In particular, MMP-2 and MMP-9, secreted from macrophages, which have infiltrated the inflammatory site, are known as powerful proteinases that degrade elastin fiber. BAV patients have dilated aortas with a higher content of MMP and a lower level of tissue inhibitor of MMP compared to TAV patients, indicating an increased collagen turnover. MMP-9 has been closely associated with the formation of abdominal aortic aneurysms [31, 36]. MMP-2 has been identified as a key molecular modulator and a circulation biomarker of aortic dilation in patients with BAV [36]. Several markers as c-Kit (a marker for differentiated vascular SMCs), pc-Kit (phosphorylated state of c-Kit, triggered by the presence of MMP9), HIF1a (influencing hypoxia-inducible-factor-1alpha), and endothelial nitric oxide synthase might play an important role in the pathogenesis of the aortopathy [31]. Increased collagen turnover and decreased collagen cross-linking may be another factor in the formation of aneurysms in BAV cases [37].

## **4. Phenotypic presentation of aortic valve and root**

### **4.1. Morphology of bicuspid aortic valve**

Normal aortic valve is tricuspid, meaning it possesses three leaflets (or cusps: the left coronary, the right coronary, and non-coronary cusps, named after their relationship to the coronary

arteries). However, BAV is formed of two functional leaflets. There are two types of BAV. The typical one is the most frequent and is formed of two leaflets of unequal size with complete or incomplete fusion of two cusps. Adjacent cusps fuse into a single cusp, that is generally bigger than its counterpart cusp, but these fused cusps are smaller than two normal cusps combined. In such cases, there may be one or two raphe. The term “raphe” refers to the fused area of two underdeveloped cusps turning into malformed commissure between both cusps [28, 29]. The second and less commonly encountered type of BAV is “true BAVs,” which have leaflets equal in size with no raphe [28]. Morphology of the aortic valve is defined according to spatial position of cusps, fusion types, and the number of raphe. The valve morphologies, raphe number, and fusion types are shown in **Table 2**. The fusion positions between the right and left coronary cusps (RL BAV), right and non-coronary cusps (RN BAV), and true BAVs are shown in **Figure 1**. The most prevalent aortic valve morphologies are RL BAV phenotypes and second, RN BAV phenotypes, and the least common are LN BAV phenotypes [28, 29, 38, 39].

## 4.2. Aortic phenotype

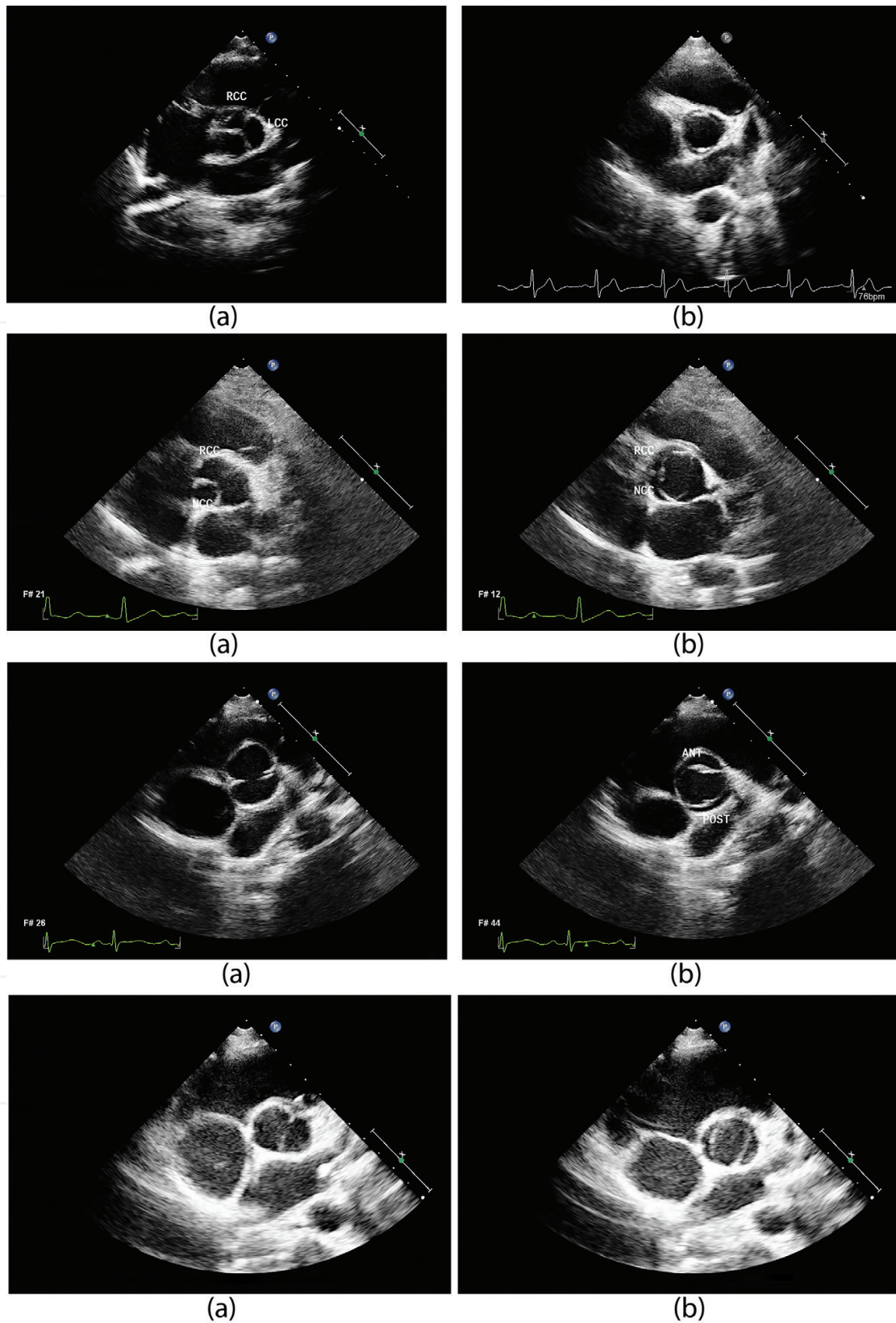
The aorta is anatomically composed of ascending aorta, aortic arch, thoracic aorta, and abdominal aorta. The aortic root contains aortic sinuses, aortic valve, and coronary ostia. The tubular portion of the ascending aorta begins at a point distal to the aortic root (sinotubular junction) and ends at the origin of the innominate artery. The aortic arch includes the origins of innominate artery, the left common carotid artery, and the left subclavian artery [40]. **Figure 2** shows the echocardiographic images and the measurements of aortic root, tubular portion of the ascending aorta, and aortic arc. There are computerized tomography images of various aortic phenotypes in **Figure 3**.

Several classifications have been made according to the structure, diameter of aorta, and the extent of aortic dilatation. BAV aortopathies generally present with ascending aorta dilatation or root dilatation or both. The types of aortopathies are summarized in **Table 3**. The most common types of aortic dilatation which are seen are the ascending aorta and varying degrees of aortic root. This type was associated with an older age at diagnosis (>50 years), valvular stenosis, and the RL BAV fusion pattern [29, 40, 41]. Isolated dilatation of the aortic root is a rare type and associated with younger age at diagnosis (<40 years), male sex, aortic

Morphology of aortic valve	Type 1	Type 2	Type 3
Raphe present (Complete or incomplete fusion)	Right–left coronary cusps fusion (RL BAV)	Right-non-coronary cusps fusion (RN BAV)	Left-non-coronary cusps fusion (LN BAV)
Valve opening	Anterior–posterior	Right–left	Right–left
Raphe number*	1 raphe	2 raphe	
Raphe absent	Anterior–posterior	Right–left	Right–left
Valve opening			

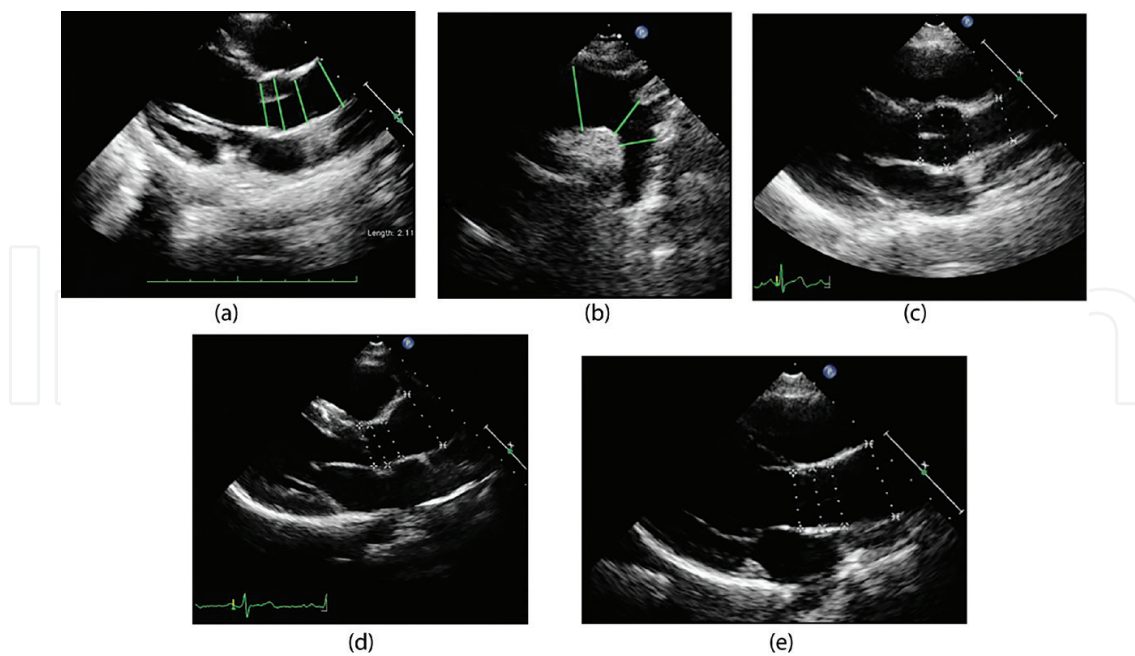
\*Type 0: no raphe

**Table 2.** The bicuspid aortic valve morphologies, fusion types, and raphe number.



**Figure 1.** Echocardiographic views of commissural fusion patterns of BAVs and true BAVs. In the first view: Right-left coronary cusp fusion a) closed b) opened position; in the second view: Right non coronary cusp fusion a) closed b) opened position; in the third view: true BAV anterior-posterior valve position a) closed b) opened position; in the fourth view: True BAV right-left position a) closed b) opened position. RCC: right coronary cusp, LCC: left coronary cusp, NCC: non coronary cusp, ANT: anterior, POST: posterior.





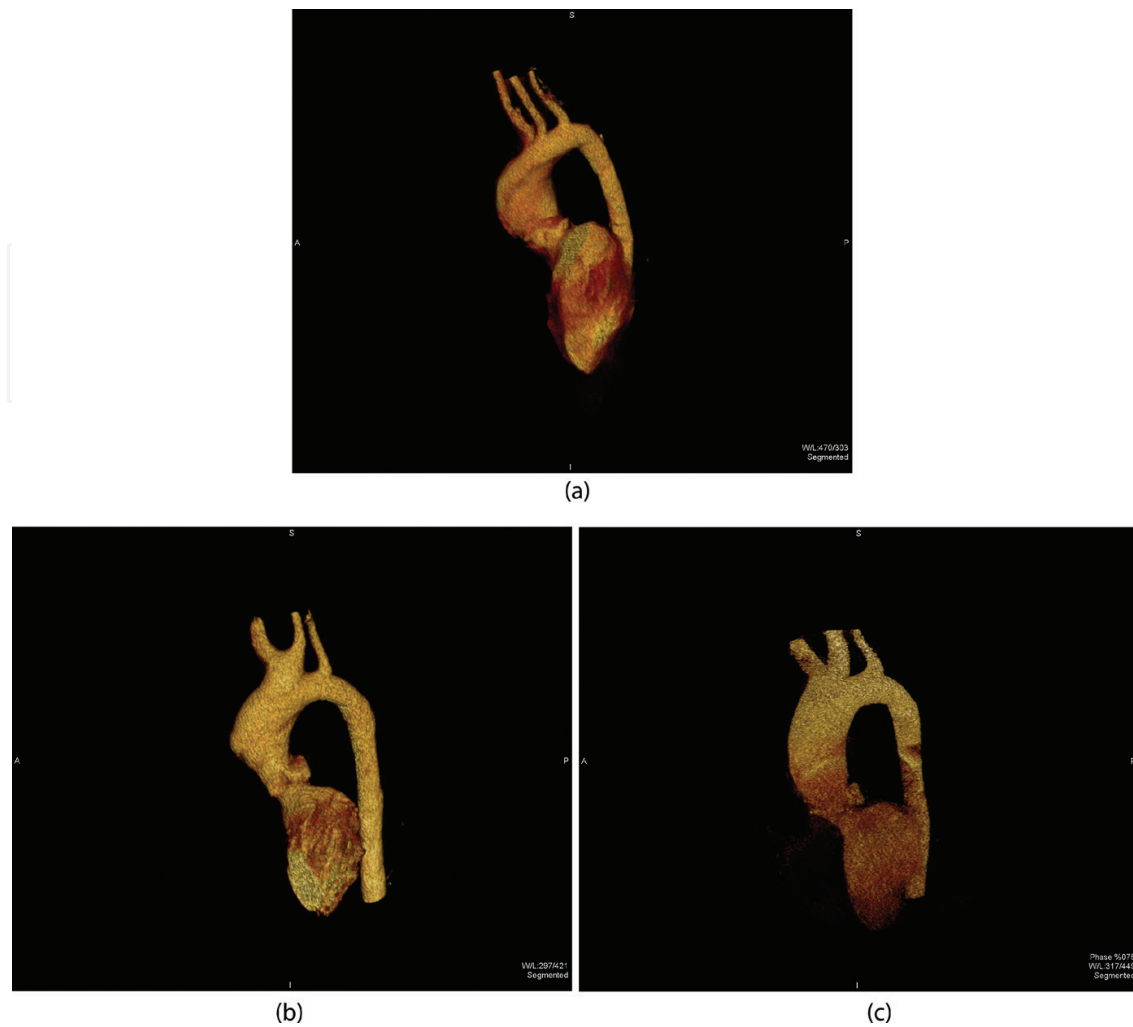
**Figure 2.** Echocardiographic images revealing the measurements of a) aortic root in the long axis view at the annular, sinus valsalva, sinotubular junction and ascending aorta levels b) aortic arc at the transverse arc, isthmus and descending aorta levels c) sinus valsalva dilatation in long axis view d) ascending aorta dilatation in which aortic root was spared in long axis view e) aortic root and ascending aorta dilatation in long axis view.

regurgitation, and aortopathy. This type was considered most likely to be related with a genetic cause [29, 40–42].

### 4.3. Aortic dilatation

Aortic dimensions are generally measured at the levels of annulus, sinus Valsalva, sinotubular junction (STJ), ascending aorta, aortic arch, descending aorta, and abdominal aorta, from inner edge to inner edge, at the end of diastole in the echocardiographic evaluation. **Figure 3** shows computerized tomography images of aortic root and ascending aorta. Because the aorta increases in diameter with somatic growth in children, the aortic diameter is typically corrected, mostly for body surface area (BSA), age, and gender. It is important to evaluate children under the age of 18 according to the z scores of these measurements. Aorta is accepted to have dilatation if the aortic z score is  $>2$ , aortic/expected aortic diameter is  $>1.15$ , or it is 2 SD above the mean expected diameter. Aortic dilation was defined as mild (z score  $>2$  and  $\leq 4$ ), moderate (z score  $>4$  and  $\leq 6$ ), or severe/aneurysm (z score  $>6$  or  $>6$  SD above the mean for BSA) [43]. In adults, aortic dilatation is present if the diameter of sinus Valsalva is  $>35$  mm, ascending aorta diameter is  $>34$ – $38$  mm, and an aneurysm is present if the aortic/expected diameter is  $>1.4$  or ascending aorta is  $>45$  mm [44–47].

Aortic dilatation may begin early in life and progress with age. It is three times more common in BAV patients than in TAVs [48]. In total, 40% of patients in referral centers were reported to have BAV-associated aortopathy [49]. BAV patients have significantly larger proximal aorta than those with TAV, even in the absence of significant valvular hemodynamic disturbance. Children with BAV have larger sinus Valsalva and ascending aorta, which increase in size at a higher rate than TAVs [48, 50]. Studies showed that aortic aneurysm also was more common



**Figure 3.** Three dimensional computerized tomography images showing a) ascending aorta dilatation b) sinus valsalva and ascending aorta dilatation extended to arcus aorta c) aortic root and ascending aorta dilatation.

in BAV than in TAV patients. The most common type of dilatation of aorta in BAVs was the ascending aorta dilatation, root dilatation was the second, and the least common was the root dilatation together with the ascending aorta [44, 48, 51]. Aortic aneurysms in BAVs commonly involve aortic root, ascending aorta, and aortic arch [42].

The relationship between the aortic valve structure and dilatation has been investigated in several studies. It was reported that RL BAV phenotype was usually associated with aortic root and/or sinus Valsalva and/or proximal aortic dilatation [28, 29, 44, 49, 52–55]. RN BAV phenotype was more commonly associated with ascending aorta dilatation and LN BAV phenotypes with aortic root dilatation [29, 56]. In addition, the RN BAV phenotype was associated with a more rapid growth of the ascending aorta [43]. On the contrary, a relationship between the RL BAV phenotypes and increased risk of rapid aortic dilatation in BAV patients has been reported [57]. Clinical variation of the BAV patients may be related to different etiological entities of cusp phenotypes. Recently preclinical studies have shown that RN and RL cusps' fusion have different pathogenesis [58, 59]. In contrast to these studies, only minor differences in aortic shape can be demonstrated in different BAV phenotypes. Aortic dilatation was primarily caused by intrinsic mechanisms of the aortic wall regardless of valve type [48].

Classification					
Shafer et al. [28]	Type N (normal root) Ascending < sinuses >STJ	Type A (ascending dilatation) Ascending > sinuses >STJ	Type E (effaced roots) Sinuses < STJ		
Fazel et al. [43]	Cluster I Aortic root alone	Cluster II Tubular ascending aorta alone	Cluster III Tubular portion and transverse arch	Cluster IV Aortic root and tubular portion with tapering across the transverse arch	
Verma et al. [41]	Type 1 Dilatation of tubular ascending aorta primarily along convexity of aorta, with mild-to-moderate root dilatation	Type 2 Arch dilatation with involvement of tubular ascending aorta, with relative sparing of root	Type 3 Isolated aortic-root involvement with normal tubular ascending aorta and arch dimensions		

STJ: sinotubular junction

**Table 3.** Aortic dilatation pattern.

#### 4.4. Hemodynamic effect

Flow abnormalities, related to turbulent and helical flow patterns, as a result of the asymmetric movement of valve leaflets, may be a major contributor to aortic dilation in BAV. Even normally functioning BAVs may have abnormal transvalvular flow patterns, resulting in regional increases in wall shear stress [60, 61]. The asymmetric opening of even “clinically normal” BAV has been demonstrated. The orifice of the open BAV has been shown to be irregular and dome shaped due to the restricted motility of conjoined leaflets. This asymmetric and morphologically stenotic orifice leads to a nonaxial, turbulent transvalvular flow jet, which propagates eccentrically toward the wall of ascending aorta [61]. Restricted systolic conjoint cusp motion may cause flow deflection even if the BAV is normofunctional on echocardiographic evaluation. Systolic flow deflection toward the right, affecting the right anterolateral-ascending wall, has been demonstrated by magnetic resonance imaging (MRI) [62]. Abnormal cusp motions of BAV, including folding or wrinkling of the valve tissue and increased cusp doming during the cardiac cycle, may result in altered flow characteristics even when the cusps are not stenotic [63].

MRI studies have shown that RL BAV phenotype is associated with rightward flow deviation (flow jet directed toward the right anterior aortic wall, which is then propagated in a right-handed helical direction) and dilatation of tubular portion of the ascending aorta. Right anteriorly oriented flow jet may also result in larger aortic root dimensions and asymmetric dilatation of midascending tract [53]. However, RN BAV phenotype has been linked to the leftward deviation (flow jet directed toward left posterior aortic wall) and diffuse dilatation of the ascending aorta extending to the arch [64, 65]. The RN BAV phenotypes have shown more severe hemodynamic flow abnormalities than the RL BAV phenotypes [65].

The increase in regional wall shear stress may explain the RL BAV phenotype with dilatation of the aortic root and asymmetric dilatation of the tubular ascending aorta. Conversely, a RN BAV phenotype may result in a flow toward the posterior aorta, with increased wall shear stress at the right posterior aspect of the aorta leading to dilatation of the aortic arch [39].

#### 4.5. Aortic regurgitation and stenosis

BAV disease is strongly associated with different degrees of stenosis, regurgitation, and mixed presentations. Although most of the neonates and infants remain asymptomatic, dysfunction may present in older ages. Valve interventions may be necessary in a minority, mainly early in life, typically for aortic stenosis (AS) [66]. The progression of stenosis is probably similar to that of TAV stenosis but it becomes manifested at least 5–10 years earlier in patients with BAV [67]. AS and aortic regurgitation (AR) are equally found in TAVs and BAVs with normal aortic dimensions. If the aorta is dilated, AS is predominantly associated with BAV, whereas AR is with TAV [48].

Aortic aneurysms associated with AS have been considered to be poststenotic dilatation because of the chronic impact of the high-flow velocity turbulent transvalvular jet on the aortic wall. Aortic stenosis in BAVs may present a significant additional risk for patients with aneurysm [68]. However, not the severity of AS, but the degree of ascending aorta dilation and the presence of moderate or more AR is associated with higher aortic root and ascending aortic diameter z scores [43]. Moderate–severe AR is generally associated with larger sinus Valsalva diameters compared with normally functioning aortic valve and AS. On the other hand, moderate–severe AS is associated with a larger ascending aortic diameter compared with the normally functioning aortic valve without AR [55]. It is very confusing whether the AR causes aortic root dilatation or if the *visa versa* is true, so careful follow-up of these patients is important to understand which presents earlier. The root aneurysm and AR with BAV has been linked more often to a genetic/aortopathy cause, which occurs earlier in life, independent of hemodynamic factors [44]. In young adults, it has been shown that RN BAV pattern is more commonly associated with moderate or severe AS and moderate or more AR when compared with other BAV phenotypes. In addition, RN BAV phenotype is associated with progressive valve dysfunction and is strongly predictive of valve intervention when compared with RL BAV phenotype [39, 66]. Similarly, AS has been revealed to be more common in RN BAV phenotype, whereas AR is most commonly encountered in the patients with NL BAV and RL BAV phenotypes [45, 56, 69]. Consequently, despite a variety of study results, it can be concluded that RN or RL BAV phenotypes may show progression and AS or AR may accompany with both valve morphologies.

## 5. Diagnosis

Most patients with BAV are unaware of the diagnosis until elderly because the symptoms and physical findings are usually absent for many years. Unless echocardiography is requested for other indications, the diagnosis is usually made at the time of an adverse cardiovascular outcome.

The systolic ejection murmur of the aortic stenosis, auscultated on the left side of the sternum, and the diastolic murmur of the aortic regurgitation, heard mainly on the apex, are highly valuable in the diagnosis. In the current area, transthoracic echocardiogram usually confirms the diagnosis of BAV disease. For the confirmation, the valve must be visualized in systole and diastole in the short axis view. The valve openings are fish-mouth shaped. Diastolic images can be misleading because the cusp fusion in the larger leaflet of a bicuspid valve may simulate a tri-leaflet valve in the closed position. It may be more difficult to make the diagnosis if there is an incomplete fusion between the cusps. The valve closure is usually eccentric and the leaflets show doming in the long axis views.

It may be difficult to make the diagnosis in the obese patients due to the nonqualified, blurred vision. In such cases, the diagnosis can be established by means of transoesophageal echocardiography (TEE) or cardiac MRI or computerized tomography (CT) imaging.

## 6. Clinical course

The clinical course of BAV patients is highly non-predictable. The factors determining the prognosis are older age, RN or RL BAV phenotype, flow dynamics (right-handed flow), male gender, elevated systolic blood pressure, smoking, presence of valvular and ventricular dysfunctions, aortic dilatation, endocarditis, high total cholesterol levels, valve degeneration score, and genetic predisposition [45, 69]. Aneurysm formation, aortic dissection, severe valvular dysfunction, and endocarditis are the most important causes of morbidity and mortality of BAV disease. AR is the most common complication in younger patients, more common in males, whereas AS is more common in elderly and females [45, 55]. In addition, RN BAV phenotype is strongly predictive of valve intervention when compared with RL BAV phenotype. RN BAV phenotype has a fourfold risk of time-related valve intervention compared with RL BAV phenotype during childhood [39, 66].

Some BAV cases may present with severe stenosis or regurgitation especially in infants or children. Children who present with AS in infancy have more severe disease and poor outcomes. Fortunately, balloon valvuloplasty is the successful treatment of choice for severe AS in this age group because of very little calcification [70].

With respect to the BAV manifestations, it is estimated that only 1 in 50 children would have a clinically significant valve disease by adolescence. The majorities of BAV patients have relatively normal valve function and remain undiagnosed until 40 years of age, when stenosis develops because of leaflet calcification. In total, 53% of the BAV patients with isolated AS undergo valve replacement [65, 70, 71]. In the elderly population, AS is the most common presentation which causes 75% of patients to undergo surgery, while AR was the reason for intervention in only 13–16% of BAV patients [45, 72]. Asymptomatic adults without significant valve dysfunction enjoy excellent long-term survival with a 10- and 20-year survival rate of 97 and 90%, respectively, identical to the expected survival of the population matched for age and sex [73]. Mean follow-up of 15 years showed a 6.7% death ratio, 1.4% of which were related with the aortic valve endocarditis, 0.47% with AS, and 0.47% with AR. In total, 18.3% of these patients underwent aortic valve surgery, most of which were due to severe AS [73]. The 10-year survival rate of the asymptomatic young adults with BAV was found to be 96%.

Aortic valve and ascending aorta surgery were performed in 29% of these patients [46]. On the other hand, patients with BAV-AR and root aneurysm have shown a higher risk of aortic dissection and rupture [74].

Aortic dissection occurs 9 times more often and at an average of 1 decade earlier among patients with BAV than those with TAV [63]. The patients with BAV and aortic aneurysm >4.5 cm have been found eight times more likely to undergo an aortic dissection [75]. The patients with BAV-AR have a tenfold higher risk of post-AVR aortic dissection than the patients with BAV-AS [76]. The aortic dissection rate in BAVs has been found to be 0.77% and the frequency of aortic dissection is 0.1% per patient's year of follow-up [45].

The aortic diameter at the baseline is also an important predictor of aortic dilatation. In children under 18 years old, ascending aorta z score has been shown to progress with time and an initial z score > 2 with the presence of AS has been accepted as a clinical marker for higher z scores in early adulthood [48]. The z scores of 4 or above, present in 13% of the patients under 18 years old, have been considered to reveal significant aortic dilation which predicts the subsequent aneurysm development [75]. Relevantly, it has been shown that an aortic diameter of 4 cm or more at the baseline evaluation independently predicts the subsequent development of aneurysm. The incidence of aortic dissection in these patients during 16 years of follow-up was 3.1%, significantly higher than the general population [75]. Dissection rates in the patients with the aortic diameters of above 3.5, 4.5, and 5.5 cm are 8.5, 57.1, and 10%, respectively [77]. The aortic size larger than 4.5 cm or aortic cross-sectional area/height > 8–10 should be considered for concurrent aortic valve and ascending aorta surgery [78, 79].

BAV types can predict the progression of aortic valve dysfunction or the development of aortic aneurysms [80]. The presence of a raphe has been associated with a higher prevalence of significant AS and AR, which increase the need for surgery. Despite the higher mortality in patients with BAV and raphe, raphe is not independently associated with increased all-cause mortality.

## 7. Treatment strategies

### 7.1. Medical treatment

Beta-adrenergic blockers, angiotensin converting enzyme inhibitors, and angiotensin receptor blockers are the antihypertensive agents of choice. Beta-adrenergic blockers have the theoretical advantage of reducing aortic wall shear stress, whereas angiotensin receptor blockers have been shown to reduce the rate of aortic growth in patients with Marfan's syndrome [24]. The studies about the various treatment modalities are continuing vigorously.

### 7.2. Intervention

During childhood, insertion of a prosthetic valve is suboptimal because of the continuing growth of the child. Fortunately, at this stage, the aortic valve is usually not calcified and valvuloplasty can successfully disrupt the commissural fusion and relieve obstruction. Valvuloplasty is the interventional strategy of choice in children and in some young adults with BAV and AS [70].

### 7.3. Surgical treatment

Patients who have an aortic root or ascending aorta with a diameter of 45–50 mm may be considered for surgery only if they have high-risk features such as a family history of aortic dissection, rupture, or sudden death, and an aortic growth rate of more than 5 mm per year and if there is no need for valvular surgery [81]. Currently, aortic root surgery is not usually performed if the root measurement is <45 mm, or ratio of maximum ascending aorta area to body-height ratio is <10 cm<sup>2</sup>/m [82]. Guidelines recommend ascending aortic replacement in patients with BAV if the ascending aortic diameter is ≥50 mm. Concomitant aortic surgery is suggested if the diameter exceeds 45 mm [83]. Nonetheless, some authors have recommended ascending aorta surgery at 40 mm along with concomitant aortic valve regurgitation (AVR), if the operation risk is low and expected survival is 1 decade or longer. Moreover, many surgeons consider reinforcing or replacing the ascending aorta at the time of valve surgery if there is an increased risk of further root dilation [84–86]. Aortic root dilatation may progress after AVR in the patients with pure AR. BAV patients with AR and root dilatation of 40–50 mm (root phenotype) are associated with significant risk (34%) of post-AVR aortic events. Therefore, simultaneous aortic root surgery is suggested in the patients with BAV-AR and aortic root diameter > 40 mm during their initial AVR procedure [86]. Some of the surgeons recommend aortic repair at the time of BAV surgery if either the aortic diameter exceeds approximately 45 mm or the aortic cross-sectional area/height is above 8–9 cm<sup>2</sup>/m or z score is above 7 [82].

## 8. Conclusion

BAV is a very common, congenital, phenotypically variable, and genetically heterogeneous heart disease. It has a complex developmental process and distinct morphological phenotypes. The clinical course is highly non-predictable. Children with BAV are mostly asymptomatic. However, the cases with severe AS may be encountered early in life and need intervention. Aortic dilatation and valvular dysfunction may begin in infancy and make progress with age. The factors determining the prognosis of BAV disease are older age, RN or RL BAV phenotype, flow dynamics (right-handed flow), male gender, elevated systolic blood pressure, smoking, presence of valvular and ventricular dysfunctions, aortic dilatation, endocarditis, high total cholesterol levels, valve degeneration score, and genetic predisposition. Surgery is recommended for the patients with severe valvular dysfunction (AS, AR), aortic dilatation, or aneurysm.

## Author details

Ayşe Inci Yıldırım\* and Aysu Türkmen Karaağaç

\*Address all correspondence to: ayildirimmd@yahoo.com

University of Healthy Sciences Kartal Koşuyolu Heart and Research Hospital, Istanbul, Turkey

## References

- [1] Basso C, Boschello M, Perrone C, Meceren A, Cera A, Bicego D, Thiene D, D Dominics E. An echocardiographic survey of primary school children for bicuspid aortic valve. *The American Journal of Cardiology*. 2004;**93**:661-663
- [2] Fedak PW, Verma S, David TE, Leask RL, Weisel RD, Butany J. Clinical and pathophysiological implications of a bicuspid aortic valve. *Circulation*. 2002;**106**(8):900-904
- [3] Klásková E, Zapletalová J, Kaprálová S, Šnajderová M, Lebl J, Tüdös Z, Pavlíček J, Černá J, Mihál V, Stará V, Procházka M. Increased prevalence of bicuspid aortic valve in turner syndrome links with karyotype: The crucial importance of detailed cardiovascular screening. *Journal of Pediatric Endocrinology and Metabolism*. 2017;**30**(3):319-325
- [4] Prakash SK, Bossé Y, Muehlschlegel JD, Michelena HI, Limongelli G, Della Corte A, Pluchinotta FR, Russo MG, Evangelista A, Benson DW, Body SC, Milewicz DM. A roadmap to investigate the genetic basis of bicuspid aortic valve and its complications: Insights from the international BAVCon (bicuspid aortic valve consortium). *The Journal of the American College of Cardiology*. 2014;**64**(8):832-839
- [5] Huntington K, Hunter AG, Chan KL. A prospective study to assess the frequency of familial clustering of congenital bicuspid aortic valve. *The Journal of the American College of Cardiology*. 1997;**30**(7):1809-1812
- [6] Robledo-Carmona J, Rodríguez-Bailón I, Carrasco-Chinchilla F, Fernández B, Jiménez-Navarro M, Porrás-Martin C, Montiel-Trujillo A, García-Pinilla JM, Such-Martínez M, De Teresa-Galván E. Hereditary patterns of bicuspid aortic valve in a hundred families. *The International Journal of Cardiology*. 2013;**168**(4):3443-3449
- [7] Cripe L, Andelfinger G, Martin LJ, Shooner K, Benson DW. Bicuspid aortic valve is heritable. *The Journal of the American College of Cardiology*. 2004;**44**(1):138-143
- [8] Laforest B, Nemer M. GATA5 interacts with GATA4 and GATA6 in outflow tract development. *Developmental Biology*. 2011;**358**:368-378
- [9] Martin LJ, Ramachandran V, Cripe LH, Hinton RB, Aldenfinger G, Tabangin M, Shooner K, Keddache M, Benson DW. Evidence in favor of linkage to human chromosomal regions 18q, 5q and 13q for bicuspid aortic valve and associated cardiovascular malformations. *Human Genetics*. 2007;**121**:275-284
- [10] Goh D, Han L, Judge D. Linkage of familial bicuspid aortic valve with aortic aneurysm to chromosome 15q. *The American Journal of Human Genetics*. 2002;**71**:211
- [11] Choudhury N, Bouchot O, Rouleau L, Tremblay D, Cartier R, Butany J, Mongrain R, Leask RL. Local mechanical and structural properties of healthy and diseased human ascending aorta issue. *Cardiovascular Pathology*. 2009;**18**(2):83-91
- [12] Yassine NM, Shahram JT, Body SC. Pathogenic mechanisms of bicuspid aortic valve aortopathy. *Frontiers in Physiology*. 2017;**8**:687. DOI: 10.3389/fphys.2017.0068



- [13] Foffa I, Ait Ali L, Panesi P, Festa P, Botto N, Necoli C, Andreassi MG. Sequencing of NOTCH1, GATA1, TGFBR1 and TGFBR2 genes in familial cases of bicuspid aortic valve. *BMC Medical Genetics*. 2013;**14**:44
- [14] Qu XK, Qiu XB, Yuan F, Wang J, Zhao CM, Liu XY, Zhang XL, Li RG, Xu YJ, Hou XM, Fang WY, Liu W, Yang YQ. A novel NKX2.5 loss-of-function mutation associated with congenital bicuspid aortic valve. *The American Journal of Cardiology*. 2014;**114**:1891-1895
- [15] Girdauskas E, Schulz S, Borger MA, Mierzwa M, Kuntze T. Transforming growth factor-beta receptor type II mutation in a patient with bicuspid aortic valve disease and intra-operative aortic dissection. *The Annals of Thoracic Surgery*. 2011;**91**:70-71
- [16] Koenig SN, LaHaye S, Feller JD, Rowland P, Hor KN, Trask AJ, Janssen PM, Radtke F, Lilly B, Garg V. 2017 Notch1 haploinsufficiency causes ascending aortic aneurysms in mice. *JCI Insight*. 2017;**2**(21)
- [17] Pepe G, Nistri S, Giusti B, Sticchi E, Atlanasio M, Porciani C, et al. Identification of fibrillin 1 gene mutations in patients with bicuspid aortic valve (BAV) without Marfan syndrome. *BMC Medical Genetics*. 2014:15-23
- [18] Milewicz DM, Guo DC, Tran-FaduluV LAL, Papke CL, Inamoto S, et al. Genetic basis of thoracic aortic aneurysms and dissections, focus on smooth muscle cell contractile dysfunction. *The Annual Review of Genomics and Human Genetics*. 2008;**9**:283-302
- [19] Jiang X, Rowitch DH, Soriano P, McMahon AP, Sucov HM. Fate of the mammalian cardiac neural crest. *Development*. 2000;**127**:1607-1616
- [20] Waldo KL, Kumiski DH, Wallis KT, Stadt HA, Hutson MR, Platt DH, et al. Conotruncal myocardium arises from a secondary heart field. *Development*. 2001;**128**(16):3179-3188
- [21] Snarr BS, Kern CB, Wessels A. Origin and fate of cardiac mesenchyme. *Developmental Dynamics*. 2008;**237**:2804-2819
- [22] Plein A, Fantin A, Ruhrberg C. Neural crest cells in cardiovascular development. *Current Topics in Developmental Biology*. 2015;**111**:183-200
- [23] Jiao J, Xiong W, Wang L, Yang J, Qiu P, Hirai H, et al. Differentiation defect in neural crest-derived smooth muscle cells in patients with aortopathy associated with bicuspid aortic valves. *eBioMedicine*. 2016;**10**:282-290
- [24] Groenink M, den Hartog AW, Franken R, Radonic T, de Waard V, Timmermans J, et al. Losartan reduces aortic dilatation rate in adults with Marfan syndrome: A randomized controlled trial. *European Heart Journal*. 2013;**34**:3491-3500
- [25] Humphrey D, Schwartz MA, Tellides G, Milewicz DM. Role of mechanotransduction in vascular biology focus on thoracic aortic aneurysms and dissections. *Circulation Research*. 2015;**116**(8):1448-1461
- [26] Wagenseil JE, Mecham RP. Vascular extracellular matrix and arterial mechanics. *Physiological Reviews*. 2009;**89**:957-989

- [27] Thompson RW, Geraghty PJ, Lee JK. Abdominal aortic aneurysms: Basic mechanisms and clinical implications. *Current Problems in Surgery*. 2002;**39**:110-230
- [28] Sievers HH, Schmidtke C. A classification system for the bicuspid aortic valve, from 304 surgical specimen. *The Journal of Thoracic and Cardiovascular Surgery*. 2007;**133**(5):1226-1233
- [29] Schaefer BM, Lewin MB, Stout KK, Gill E, Prueitt A, Byers PH, et al. The bicuspid aortic valve: An integrated phenotypic classification of leaflet morphology and aortic root shape. *Heart*. 2008;**94**:1634-1638
- [30] Grewal N, Gittenberger-de Groot AC, Poelmann RE, Klautz RJ, Lindeman JH, Goumans MJ, Palmes M, Mohamed SA, Sievers HH, Bogers AJ. Ascending aorta dilation in association with bicuspid aortic valve: A maturation defect of the aortic wall. *The Journal of Thoracic and Cardiovascular Surgery*. 2014;**148**(4):1583-1590
- [31] Grewal N, Gittenberger-de Groot AC, Marco C, DeRuiter MC, Klautz RJ, Poelmann MRE, et al. Bicuspid aortic valve: Phosphorylation of c-kit and downstream targets are prognostic for future aortopathy. *European Journal of Cardio-Thoracic Surgery*. 2014;**45**:831-839
- [32] Nataatmadja M, West M, West J, Summers K, Walker P, Nagata M. Abnormal extracellular matrix protein transport associated with increased apoptosis of vascular smooth muscle cells in Marfan syndrome and bicuspid aortic valve thoracic aortic aneurysm. *Circulation*. 2003;**108**:II329-II334
- [33] Della Corte A, Quarto C, Bancone C, Castaldo C, Di Meglio F, Nurzynska D, De Santo LS, De Feo M, Scardone M, Montagnani S, Cotrufo M. Spatiotemporal patterns of smooth muscle cell changes in ascending aortic dilatation with bicuspid and tricuspid aortic valve stenosis: Focus on cell-matrix signaling. *Journal of Thoracic and Cardiovascular Surgery*. 2008;**135**:8-18
- [34] Fedak PW, de Sa MP, Verma S, Nili N, Kazemian P, Butany J, Strauss BH, Weisel RD, David TE. Vascular matrix remodeling in patients with bicuspid aortic valve malformations: Implications for aortic dilatation. *Journal of Thoracic and Cardiovascular Surgery*. 2003;**126**(3):797-806
- [35] Paes Leme M. Molecular evaluation of the great vessels of patients with bicuspid aortic valve disease. *Revista Brasileira de Cirurgia Cardiovascular*. 2003;**18**:148-156
- [36] Ikonomidis JS, Jones JA, Barbour JR, Stroud RE, Clark LL, Kaplan BS, et al. Expression of matrix metalloproteinases and endogenous inhibitors within ascending aortic aneurysms of patients with bicuspid or tricuspid aortic valves. *Journal of Thoracic and Cardiovascular Surgery*. 2007;**133**:1028-1036
- [37] Broberg CS, Therrien J. Understanding and treating aortopathy in bicuspid aortic valve. *Trends in Cardiovascular Medicine*. 2015;**25**:445-451
- [38] Pees C, Behnke IM. Morphology of the bicuspid aortic valve and elasticity of the adjacent aorta in children. *The American Journal of Cardiology*. 2012;**110**:1354-1360

- [39] Fernandes SM, Sanders SP, Khairy P, Jenkins KJ, Gauvreau K, Lang P, Simonds H, Colan SD, et al. Morphology of bicuspid aortic valve in children and adolescents. *The Journal of the American College of Cardiology*. 2004;**44**:1648-1651
- [40] Verma S, Siu SC. Aortic dilatation in patients with bicuspid aortic valve. *The New England Journal of Medicine*. 2014;**370**(20):1920-1929
- [41] Girdauskas E, Borger MA, Secknus MA, Girdauskas G, Kuntze T. Is aortopathy in bicuspid aortic valve disease a congenital defect or a result of abnormal hemodynamics? A critical reappraisal of a one sided argument. *The European Journal of Cardio-Thoracic Surgery*. 2011;**39**:809-814
- [42] Fazel SS, Mallidi HR, Lee RS, Sheehan MP, Liang D, Fleischman D, Herfkens R, Mitchell RS, Miller DC. The aortopathy of bicuspid aortic valve disease has distinctive patterns and usually involves the transverse aortic arch. *Journal of Thoracic and Cardiovascular Surgery*. 2008;**135**(4):901-907
- [43] Fernandes S, Khairy P, Graham DA, Colan SD, Galvin TC, Sanders SP, et al. *Heart*. 2012;**98**:1014-1019
- [44] Della Corte A, Bancone C, Quarto C, Dialetto G, Covino F, E Scardone M, et al. Predictors of ascending aortic dilatation with bicuspid aortic valve, a wide spectrum of disease expression. *European Journal of Cardio-Thoracic Surgery*. 2007;**31**:397-404
- [45] Tzemos N, Therrien J, Yip J, Thanassoulis G, Tremblay S, Jamorski MT, et al. Outcomes in adults with bicuspid aortic valves. *JAMA*. 2008;**300**(11):1317-1325
- [46] Beroukhim RS, Kruzick TL, Taylor AL, Gao D, Yetman AT. Progression of aortic dilation in children with a functionally normal bicuspid aortic valve. *The American Journal of Cardiology*. 2006;**98**:828-830
- [47] Merckx R. Aortic diameter growth in children with a bicuspid aortic valve. *American Journal of Cardiology*. 2017;**120**:131-136
- [48] Jackson V, Petrini J, Caidahl K, Eriksson MJ, Liska J, Eriksson P, Franco-Cereceda A. Bicuspid aortic valve leaflet morphology in relation to aortic root morphology: A study of 300 patients undergoing open-heart surgery. *The European Journal of Cardio-Thoracic Surgery*. 2011;**40**:118-124
- [49] Masri A, Kalahasti V, Alkharabsheh S, Svensson LG, Sabik JF, Roselli EE, et al. Characteristics and long-term outcomes of contemporary patients with bicuspid aortic valves. *Journal of Thoracic and Cardiovascular Surgery*. 2016;**151**:1650-1651
- [50] Gurvitz M, Chang RK, Drant S, Allada V. Frequency of aortic root dilation in children with a bicuspid aortic valve. *American Journal of Cardiology*. 2004;**94**(10):1337-1340
- [51] Holmes KW, Lehmann CU, Dalal D, Nasir K, Dietz HC, Ravekes WJ, Thompson WR, Spevak PJ, et al. Progressive dilation of the ascending aorta in children with isolated bicuspid aortic valve. *American Journal of Cardiology*. 2007;**99**:978-983

- [52] Khoo C, Cheung C, Jue J. Patterns of aortic dilatation in bicuspid aortic valve-associated aortopathy. *Journal of the American Society of Echocardiography*. 2013;**26**:600-605
- [53] Russo CF, Cannata A, Lanfranconi M, Vitali E, Garatti A, Bonacina E. Is aortic wall degeneration related to bicuspid aortic valve anatomy in patients with valvular disease? *The Journal of Thoracic and Cardiovas Surgery*. 2008;**136**:937-942
- [54] Mahadevia R, Barker AJ, Schnell S, Entezari P, Kansal P, Fedak PW, et al. Bicuspid aortic cusp fusion morphology alters aortic three-dimensional outflow patterns, wall shear stress, and expression of aortopathy. *Circulation*. 2014;**129**:673-682
- [55] Roman MJ, Pugh NL, Devereux RB, Eagle KA, Holmes K, LeMaire SA, et al. GenTAC investigators aortic dilatation associated with bicuspid aortic valve: Relation to sex, hemodynamics, and valve morphology (the National Heart Lung and Blood Institute-Sponsored National Registry of Genetically Triggered Thoracic Aortic Aneurysms and Cardiovascular Conditions). *American Journal of Cardiology*. 2017;**120**(7):1171-1175
- [56] Huang FQ, Le Tan J. Pattern of aortic dilatation in different bicuspid aortic valve phenotypes and its association with aortic valvular dysfunction and elasticity. *Heart Lung Circulation*. 2014;**23**(1):32-38
- [57] Thanassoulis G, Yip JW, Filion K, Jamorski M, Webb G, Siu SC, et al. Retrospective study to identify predictors of the presence and rapid progression of aortic dilatation in patients with bicuspid aortic valves. *Nature Reviews Cardiology*. 2008;**5**(12):821-828
- [58] Fernandez B, Duran AC, Fernandez-Gallego T, Fernandez MC, Such M, Arque JM, et al. Bicuspid aortic valves with different spatial orientations of the leaflets are distinct etiological entities. *The Journal of the American College of Cardiology*. 2009;**54**:2312-2318
- [59] Phillips HM, Mahendran P, Singh E, Anderson RH, Chaudhry B, Henderson DJ. Neural crest cells are required for correct positioning of the developing outflow cushions and pattern the arterial valve leaflets. *Cardiovascular Research*. 2013;**99**:452-460
- [60] Braverman AC. The bicuspid aortic valve and associated aortic disease; in valvular heart disease. In: Otto CM, Bonow RO, editors. *A companion to Braunwald's Heart Disease*, 4th ed. Philadelphia: Saunders/Elsevier; 2013. pp. 179-198
- [61] Robicsek F, Thubrikar JM, Cook JW, Fowler B. The congenitally bicuspid aortic valve: How does it function? Why does it fail? *Annals of Thoracic Surgery*. 2004;**77**:177
- [62] Della Corte A, Bancone C, Conti CA, Votta E, Redaelli A, Del Viscovo L, Cotrufo M. Restricted cusp motion in right-left type of bicuspid aortic valves: A new risk marker for aortopathy. *The Journal of Thoracic and Cardiovascular Surgery*. 2012;**144**(2):360-369
- [63] Braverman AC. Aortic involvement in patients with a bicuspid aortic valve. *Heart*. 2011;**97**:506-513
- [64] Burris NS, Hope MD. Bicuspid valve-related aortic disease: Flow assessment with conventional phase contrast MRI. *Academic Radiology*. 2015;**22**(6):690-696

- [65] Bissell MM, Hess AT, Biasioli L, Glaze SJ, Loudon M, Pitcher A, Davis A. Aortic dilation in bicuspid aortic valve disease flow pattern is a major contributor and differs with valve fusion type. *Circulation. Cardiovascular Imaging*. 2013;**6**:499-507
- [66] Fernandes SM, Khairy P, Sanders SP, Colan SD. Bicuspid aortic valve morphology and interventions in the young. *The Journal of the American College of Cardiology*. 2007;**49**:2211-2214
- [67] Roberts WC, Ko JM, Jm K. Frequency by decades of unicuspid, bicuspid, and tricuspid aortic valves in adults having isolated aortic valve replacement for aortic stenosis, with or without associated aortic regurgitation. *Circulation*. 2005;**111**:920-925
- [68] Davies RR, Kaple RK, Mandapati D, Gallo A, Botta DM, Elefteriades JA, et al. Natural history of ascending aortic aneurysms in the setting of an unreplaced bicuspid aortic valve. *The Annals of Thoracic Surgery*. 2007;**83**(4):1338-1344
- [69] Koenraadt WCM, Grewal N, Gaidoukevitch OY, DeRuijter MC, Gittenberger-de Groot AC, Bartelings MM. The extent of the raphe in bicuspid aortic valves is associated with aortic regurgitation and aortic root dilatation. *Netherlands Heart Journal*. 2016;**24**(2):127-133
- [70] Siu SC, Silversides CK. Bicuspid aortic valve disease. *The Journal of the American College of Cardiology*. 2010;**55**:2789-2800
- [71] Lewin MB, Otto CM. The bicuspid aortic valve adverse outcomes from infancy to old age circulation. 2005;**111**(7):832-834
- [72] Collins MJ, Butany J, Borger MA, Strauss BH, David TE. Implications of a congenitally abnormal valve: A study of 1025 consecutively excised aortic valves. *Journal of Clinical Pathology*. 2008;**61**:530-536
- [73] Michelena HI, Desjardins VA, Avierinos JF, Russo A, Nkomo VT, Sundt TM, et al. Natural history of asymptomatic patients with normally functioning or minimally dysfunctional bicuspid aortic valve in the community. *Circulation*. 2008;**117**:2776-2784
- [74] Girdauskas E, Disha K, Raisin HH, Secknus MA, Borger MA, Kuntze T. Risk of late aortic events after an isolated aortic valve replacement for bicuspid aortic valve stenosis with concomitant ascending aortic dilation. *The European Journal of Cardio-Thoracic Surgery*. 2012;**42**:832-837
- [75] Michelena HI, Khanna AD, Mahoney D, Margaryan E, Toplisky Y, Suri RM, et al. Incidence of aortic complications in patients with bicuspid aortic valves. *JAMA*. 2011;**306**:1104-1112
- [76] Girdauskas E, Rouman M, Disha K, Espinoza A, Misfeld M, Borger MA, et al. Aortic dissection after previous aortic valve replacement for bicuspid aortic valve disease. *The Journal of the American College of Cardiology*. 2015;**66**:1409-1411
- [77] Davies RR, Gallo A, Coady MA, Tellides G, Botta DM, Burke B, et al. Novel measurement of relative aortic size predicts rupture of thoracic aortic aneurysms. *The Annals of Thoracic Surgery*. 2006;**81**:169-177

- [78] Svensson LG, Kim KH, Blackstone EH, Rajeswaran J, Gillinov AM, Mihaljevic T, et al. Bicuspid aortic valve surgery with proactive ascending aorta repair. *Journal of Thoracic and Cardiovascular Surgery*. 2011;**142**, 622-629:e1-e3
- [79] Abdulkareem N, Soppa G, Jones S, Valencia O, Smelt J, Jahangiri M. Dilatation of the remaining aorta after aortic valve or aortic root replacement in patients with bicuspid aortic valve: A 5-year follow-up. *The Annals of Thoracic Surgery*. 2013;**96**:43-49
- [80] Kong WK, Delgado V, Poh KK, Regeer MV, Ng AC, McComack L, et al. Prognostic implications of raphe in bicuspid aortic valve anatomy. *JAMA Cardiology*. 2017;**2**:285-292
- [81] Hiratzka LF, Bakris GL, Beckman JA, Bersin RM, Carr VF, Casey DE, et al. ACCF/AHA/AATS/ACR/ASA/SCA/SCAI/SIR/STS/SVM guidelines for the diagnosis and management of patients with thoracic aortic disease: A report of the American College of Cardiology Foundation/American Heart Association task force on practice guidelines, American Association for Thoracic Surgery, American College of Radiology, American Stroke Association, Society of Cardiovascular Anesthesiologists, Society for Cardiovascular Angiography and Interventions, Society of Interventional Radiology, Society of Thoracic Surgeons, and Society for Vascular Medicine. *Circulation*. 2010, 2010;**121**(13):e266-e369
- [82] Svensson LG, Adams DH, Bonow RO, Kouchoukos NT, Miller DC, O'Gara PT, et al. Aortic valve and ascending aorta guidelines for management and quality measures: Executive summary. *The Annals of Thoracic Surgery*. 2013;**95**:1491-1505
- [83] Vahanian A, Alfieri O, Andreotti F, Antunes MJ, Baron-Esquivias G, Baumgartner H, et al. Guidelines on the management of valvular heart disease (version 2012). *The European Journal of Cardio-Thoracic Surgery*. 2012;**42**:S1-S44
- [84] Wald O, Korach A, Shapira OM. Should aortas in patients with bicuspid aortic valve really be resected at an earlier stage than tricuspid? PRO. *Clinical Cardiology*. 2010;**28**:289-298
- [85] Russo CF, Mazzetti S, Garatti A, Ribera E, Milazzo A, Bruschi G, et al. Aortic complications after bicuspid aortic valve replacement: Long-term results. *The Annals of Thoracic Surgery*. 2002;**74**:S1773-S1776. discussion S1792-9
- [86] Girdauskas E, Disha K, Rouman M, Espinoza A, Borger MA, Kuntze T. Aortic events after isolated aortic valve replacement for bicuspid aortic valve root phenotype, echocardiographic follow-up study. *The European Journal of Cardio-Thoracic Surgery*. 2015;**48**:e71-e76

