

# We are IntechOpen, the world's leading publisher of Open Access books Built by scientists, for scientists

4,800

Open access books available

122,000

International authors and editors

135M

Downloads

Our authors are among the

154

Countries delivered to

TOP 1%

most cited scientists

12.2%

Contributors from top 500 universities



WEB OF SCIENCE™

Selection of our books indexed in the Book Citation Index  
in Web of Science™ Core Collection (BKCI)

Interested in publishing with us?  
Contact [book.department@intechopen.com](mailto:book.department@intechopen.com)

Numbers displayed above are based on latest data collected.

For more information visit [www.intechopen.com](http://www.intechopen.com)



---

# Procurement of Abdominal Organs in Multi-Organ Donation in Deceased Donor

---

Bulang He, Xiuwu Han and Michael A. Fink

Additional information is available at the end of the chapter

<http://dx.doi.org/10.5772/intechopen.77308>

---

## Abstract

Organ procurement is an essential step for organ transplantation, from which a quality organ is received for subsequent transplantation. As the demand for organ transplantation continues to grow, multi-organ donation including the heart, lung, liver, pancreas, kidneys, and small intestine from one potential donor is always a priority to meet the demand. The donor is generally rigorously assessed for suitability of organ donation prior to proceeding to organ procurement. The quality of the organ from multi-organ procurement is usually satisfactory without jeopardizing its transplantation. In this chapter, the surgical technique for procurement of the organs from the abdomen is described. Some alternative techniques have also been discussed. Some pictures are inserted to facilitate understanding of the surgical procedure.

**Keywords:** abdomen, multi-organ procurement, liver, pancreas, small intestine, kidney

---

## 1. Introduction

Organ transplantation is a definitive treatment for patients with end stage of organ failure. It is one of the greatest advancements in medicine in the twentieth century. Organ transplant is a life-saving treatment and improves the quality of life. Organ donation and procurement are essential steps for performance of the organ transplantation. Organ donors are classified as live organ donors, donation after brain death (DBD), and donation after circulatory death (DCD). Rigorous assessment of a potential donor is mandatory prior to proceeding organ procurement. For DBD and DCD donors, procurement of multi-organs is always the priority to ultimately benefit multiple recipients without jeopardizing the graft function [1, 2].

---

The surgical technique for abdominal multi-organ procurement is based on the anatomy and has been evolved over the decades as a result of the increased demand for organ transplantation [2–5]. In this chapter, the surgical technique is described with some pictures inserted to facilitate understanding of the progress of the surgery.

## 2. Preparation in theater

It is mandatory for the surgeon in charge to check the documents: certification of brain death of the donor, the consent form for organ and tissue donation, signature of the hospital delegation, and the patient serology test. The team time-out should be carried out. The communication is confirmed between the surgeon and anesthetist for administration of medications at various stages. One dose of intravenous antibiotics is given intravenously, as well as 1 g of methylprednisolone prior to surgery. One dose of mannitol 20 g is given after completion of abdominal dissection. Heparin 25,000 IU is administered following cardiac team dissection prior to the cold perfusion.

If the pancreas is retrieved for organ transplantation, 100 ml of half-strength betadine (5%) is injected through the nasogastric tube that is then clamped off during procedure to retain betadine solution in the duodenum.

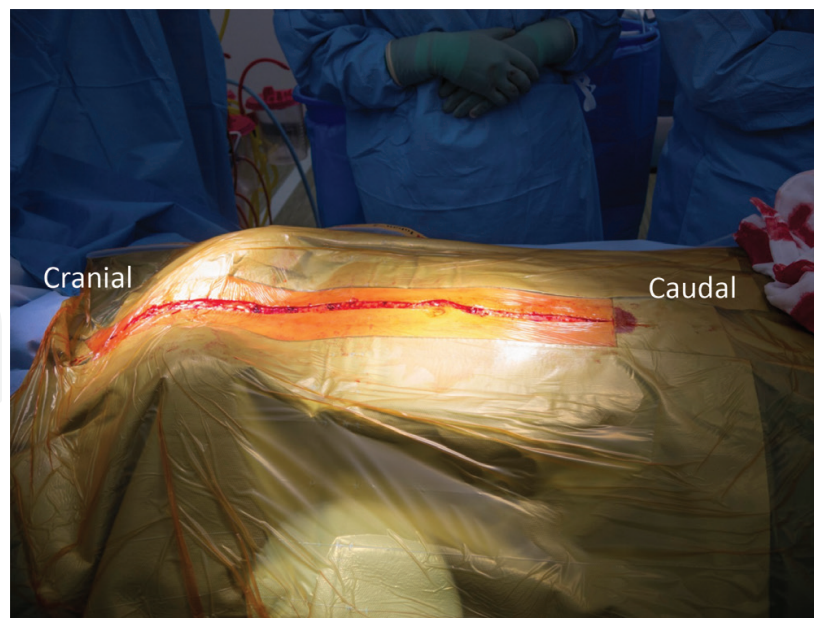
Preparation and drape: under sterile condition, the surgical area from the lower part of the chin to the proximal one-third of the thigh is prepared. The hairs are shaved. The dressing and central venous catheter or femoral catheter is reorganized to ensure the surgical field is clean and neat for preparation and drape.

## 3. Surgical procedure

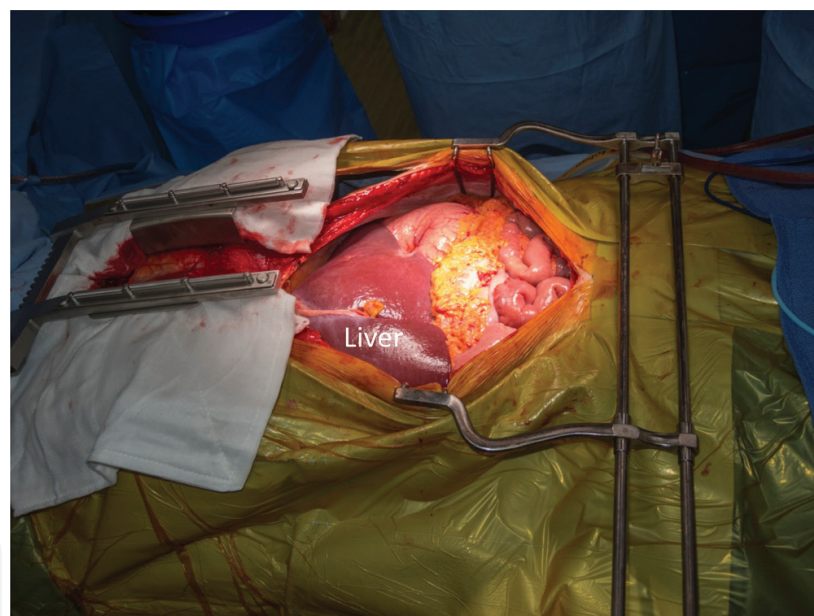### 3.1. Dissection of the organs with normal circulation (warm dissection)

#### 3.1.1. Open of the abdomen and chest

An incision is made from suprasternal notch to the point just above the symphysis pubis (**Figure 1**). The abdominal cavity is entered first, and a Balfour retractor is placed to have adequate exposure of the abdomen (**Figure 2**). The round ligament of the liver is divided and tied as well as the falciform ligament of the liver. Examination of intra-abdominal organs is carried out to exclude potential malignant disease. The quality of the liver is usually assessed at this stage, and liver biopsy should be taken if any concern is raised. The biopsy is taken by using F18 Trucut needle from the left and right lobe. An additional wedge biopsy is also taken for the frozen section and histopathology examination. Following that, the soft tissue over the sternum is cut opened by diathermy along the line for sternotomy. A tunnel is created behind the sternum by insertion of a pair of long Metzenbaum scissors to ensure that the posterior side of the sternum is clean from soft tissue attachment. The sternum is sawed open with bone wax applied to the cut surface. Hemostasis is reassured by using diathermy to all active bleeders. A sternal retractor is placed to open the chest. The pleura and pericardium are remained intact at this stage (**Figure 2**). If the donor had previous sternotomy for cardiac surgery, then the wires



**Figure 1.** Incision for multi-organ procurement.



**Figure 2.** Retractors placed for exposure of abdominal organs.

over the sternum are removed, and a resternotomy saw is used for precise cut with caution. A surgical pack is placed over the chest wound to give the cardiothoracic team a nice clean field for subsequent heart and lung dissection. Now, the concentration is directed to the dissection of abdominal organs.

### 3.1.2. Dissection of the distal aorta

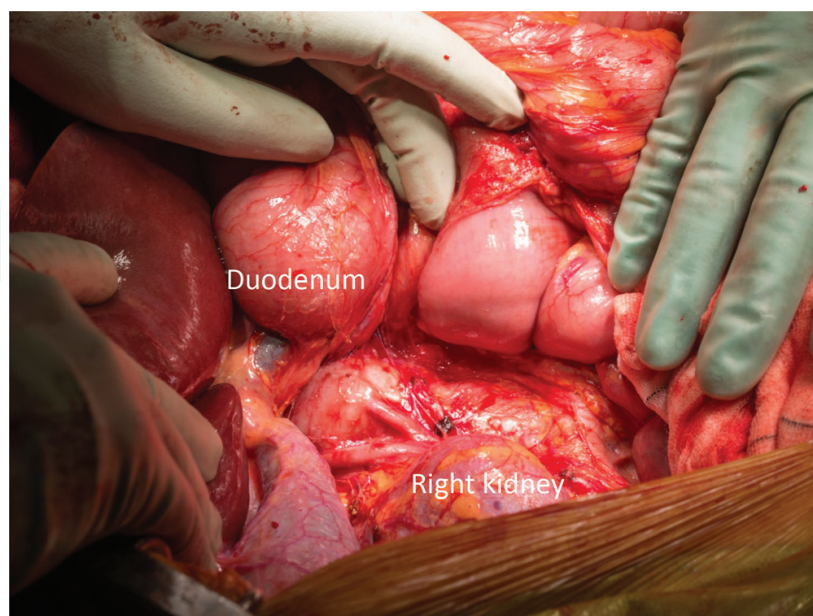
The retro peritoneum is incised along the white line of Toldt from the cecum to the hepatic flexure. The dissection is continued along the retroperitoneal avascular plane superiorly and



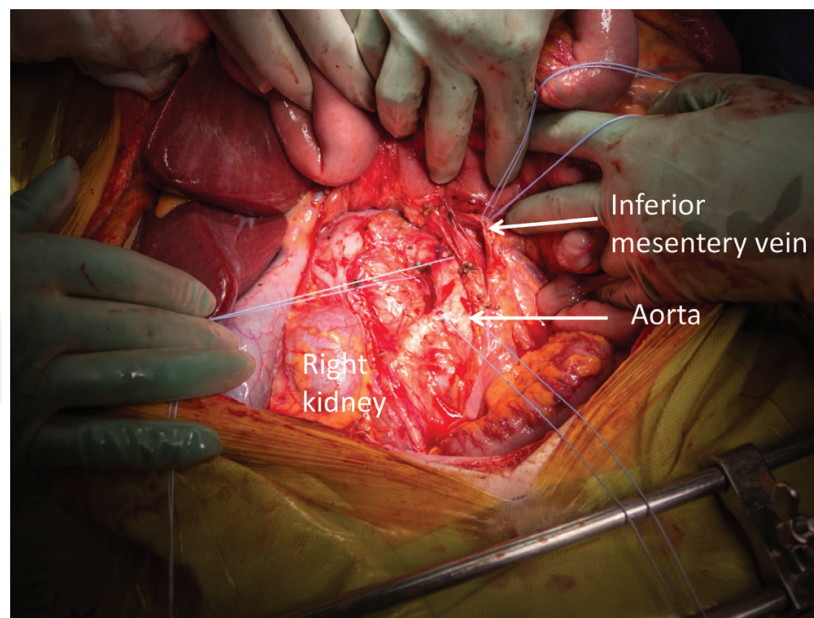
medially to mobilize and retract ascending colon medially. The right ureter is easily identified and preserved with the surrounding tissue. The dissection is continued by a Cattell-Braasch and Kocher maneuver. The inferior duodenal fold is divided allowing broad exposure of the inferior vena cava (IVC) and aorta (**Figure 3**). The left renal vein should be well visualized at this stage, and superior mesentery artery is palpated at its origin from the aorta. The distal segment of the aorta is dissected, and inferior mesentery artery is ligated and divided allowing the distal segment of aorta exposed adequately. A size 2 Dacron tie is placed around the aorta at the level proximal to the bifurcation of the common iliac arteries, which is used for ligation of distal aorta prior to cold perfusion (**Figure 4**). The second size 2 Dacron tie is placed around the aorta a few centimeters proximally that is used for tying the cannula after its insertion to the aorta for cold perfusion. At this stage, the inferior mesentery vein (IMV) is readily visualized along the edge of dissected mesentery of sigmoid colon lateral to the proximal jejunum. If the portal system perfusion is required, then a segment of IMV can be dissected, and a 2/0 tie is encircled for cannula placement at later stage immediately prior to aorta cannula insertion (**Figure 4**). Currently, most transplant units do not perform in situ portal perfusion but give 500 ml of cold UW perfusion to the portal vein on the back table when packing the liver.

### 3.1.3. Dissection of the liver

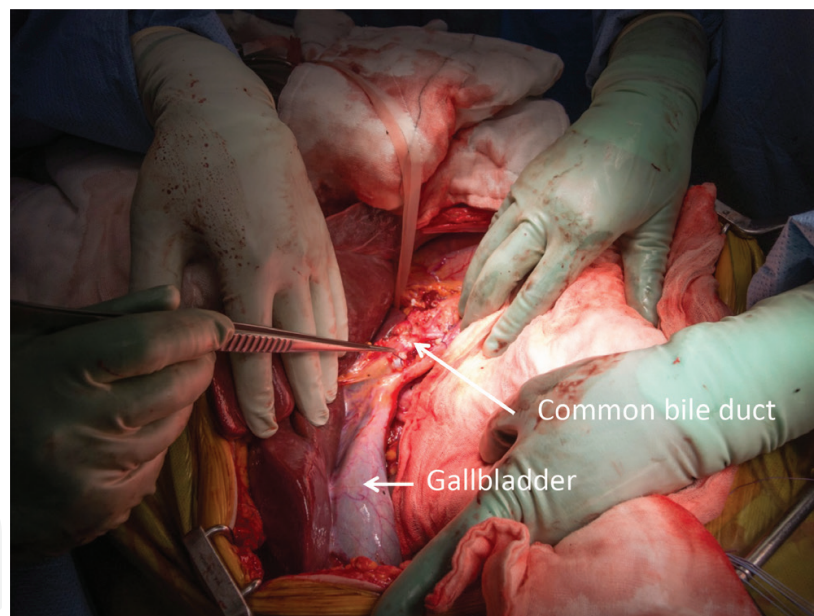
Following dissection of the aorta, the attention is directed to the liver. The left triangle ligament of the liver is divided to free the left lobe of the liver. The hepato-gastric ligament is divided, but it is usually checked for left accessory hepatic artery that usually arises from the left gastric artery. It should be preserved if present. The common bile duct is identified and transected at the level close to the duodenum (**Figure 5**). The portal vein is then visualized. At this stage, it is usually checked whether there is a right accessory or replacement of hepatic artery posteriorly to the portal vein by palpation via the omentum of foramen (Winslow). It



**Figure 3.** Cattell-Braasch and Kocher maneuver for exposure of retroperitoneal structure.

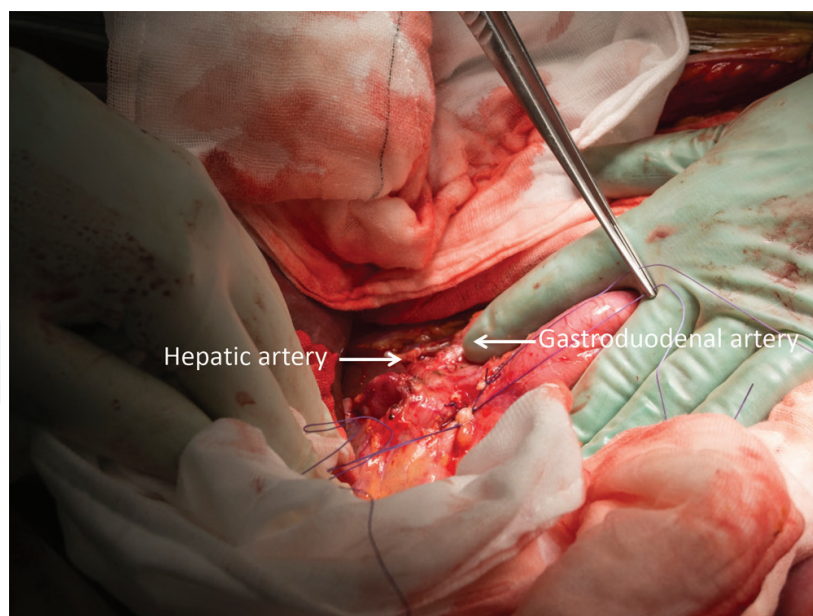


**Figure 4.** The distal aorta and inferior mesentery vein dissected.



**Figure 5.** Transection of the common bile duct.

usually arises from the superior mesentery artery. The hepato-duodenal ligament is divided. The right gastric artery and veins are tied and divided. The proper hepatic artery as well as the gastroduodenal artery is identified. A short length of gastroduodenal artery is dissected (**Figure 6**). Dissection of proper hepatic artery is continued toward celiac trunk. Then, the splenic artery and left gastric artery is seen, and a short segment is dissected, respectively, which is readily for transection after cold perfusion during procurement. The left gastric vein may be encountered, which is ligated and divided. The liver dissection is now completed.



**Figure 6.** The proper hepatic artery and gastroduodenal artery dissected.

#### 3.1.4. *Pancreas dissection*

The superior edge of the pancreas is partly exposed after dissection of proper hepatic artery. Then, the gastrocolic ligament is divided and ligated between the stomach and transverse colon. So, the anterior surface of the pancreas is visualized. The division is continued along the greater curvature of the stomach to its fundus, and gastrosplenic ligament is divided. The texture of the pancreas is properly assessed for suitability of transplantation. The spleen is always remained with the pancreas for procurement as a handle to prevent manipulation over the pancreas and reduce the risk of pancreatitis. The transverse mesocolon is divided as well as splenic-colon ligament on the left and duodenocolic ligament on the right side, and the inferior edge of the pancreas is exposed. The dissection is continued along the sigmoid colon and ascending colon allowing the colon retracted inferiorly or outside of the abdomen (this part of dissection can be done after cold perfusion). The superior mesentery vein (SMV) and superior mesentery artery (SMA) are identified inferiorly to the pancreas and anteriorly to the third part of the duodenum, which are slung with a 2/0 Vicryl tie, respectively, and subsequently tied and divided during pancreas procurement after cold perfusion.

#### 3.1.5. *Dissection of the small intestine*

In rare circumstance, procurement of the small intestine may be required as part of multi-organ donation. In such case, the abdominal multi-organ procurement should be performed by the team who performs intestinal transplantation. After the laparotomy, the intestine is examined and wrapped in a surgical pack. The entire large intestine is dissected and placed caudally outside of the abdomen. The ileal branches of the ileocolic artery are preserved. Proximally, the small intestine is divided at the jejunum 5–10 cm post Treitz, and distally the small intestine is divided near the ileocecal valve by GIA stapler. A mark suture is placed at the jejunal end for orientation of the intestinal graft at transplantation. The small intestine is lifting upward, and the



mesentery is dissected posteriorly along the avascular retroperitoneal attachments. A short segment of the superior mesentery artery and vein is dissected inferiorly to the pancreas and anteriorly to the fourth part of the duodenum by dividing some small arterial branches or venous tributaries. Care must be taken to avoid injury to the inferior pancreaticoduodenal artery, which arises proximal to the origin of the middle colic artery and supplies pancreas head [6, 7].

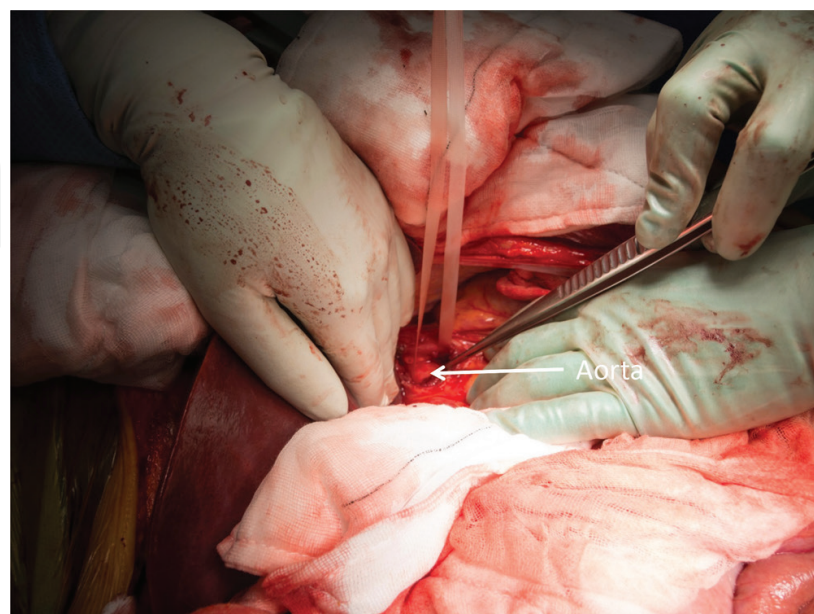
### 3.1.6. Dissection of the aorta under the diaphragm

The last dissection before the cold perfusion is to dissect supra celiac aorta under the diaphragm. The hepato-esophagus ligament is divided, and the esophagus is retracted left laterally. The aorta pulse is palpated, and the overlayer crus is divided to expose the aorta. A thin fascia layer is incised, and the aorta is freed from the surrounding attachment. A nylon type is slung over this segment of the aorta that is subsequently tied when the cold perfusion is commenced to limit the perfusion to the abdominal organs (**Figure 7**). Care must be taken not to injure the aorta in particular when trying to free the posterior part of the aorta for bringing through the nylon type. This part can be done later if the risk of bleeding is predicted. Alternatively, the segment of thoracic aorta in the left chest can be dissected and slung with a nylon type.

At this stage the warm dissection to the multi-abdominal organs is completed. The gallbladder is incised open and flushed with normal saline until the outflow at the common bile duct becomes clear. The cardiothoracic team is informed for scrubbing and proceeds to heart-lung dissection.

### 3.1.7. Insertion of the perfusion cannula into the aorta for cold perfusion (in situ cooling of the organs)

A cold perfusion line is set up at this stage, and a large cannula is connected to the perfusion line. The air bubbles are removed from the line.



**Figure 7.** A segment of the aorta under the diaphragm dissected and slung with a nylon tape.



After heart-lung dissection, Heparin 25,000 IU is given intravenously. The distal part of the aorta is tied by pre placed Dacron tie just above the bifurcation of the common iliac arteries. A vascular clamp is placed onto the aorta about 5 cm proximally to this tie to block the blood flow to this segment of the aorta where an arteriotomy is made. The cannula is inserted via arteriotomy and is tied by a pre placed Dacron tie. The cannula is secured and the vascular clamp is removed. At this point, the cold perfusion is commenced simultaneously with cardiothoracic perfusion. The IVC is divided just below the right atrium above the diaphragm for draining the blood and perfusion fluid. Attention is made to leave adequate length of IVC with the liver at suprahepatic end. Alternatively, incision of IVC can be made at the lower part just proximal to the level of confluence of common iliac veins. A suction tube can be placed into the vena cava for adequate drainage of the perfusion fluid. At least, three sets of suction line are used to have proper evacuation of the blood and fluid during perfusion period. At the same time, the ice slush is poured into the abdominal cavity over the liver, pancreas, kidney, and intestine for immediate topical cooling of the organs. Usually, 2 L of Hartman fluid is used for initial flush of the blood followed by 4 L of UW preservation solution. The organs are checked in the meantime to ensure that the progression of perfusion is adequate. The in situ cold perfusion takes about 20 min.

### **3.2. Procurement of abdominal organs (cold procurement)**

#### *3.2.1. Procurement of the small intestine*

After completion of the cold perfusion, the small intestine is harvested first. The superior mesentery artery and vein are divided below the origin of inferior pancreaticoduodenal artery, and the entire small intestine is removed and placed in ice-slush filled basin for package and transportation. The bowel contents are remained in the intestine and are managed at the time of transplantation. The small intestine can be harvested en bloc with liver and pancreas, and separation is performed on the back table [6, 7].

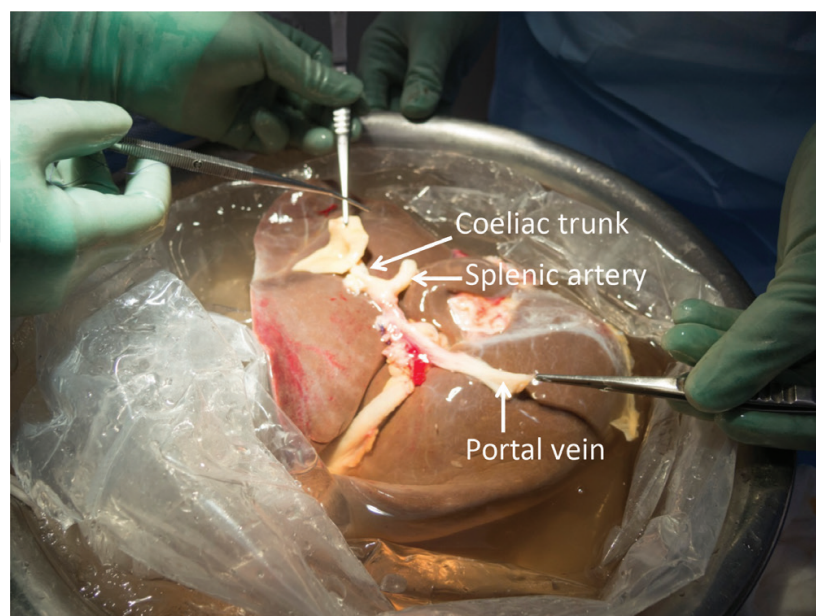
#### *3.2.2. Procurement of the liver*

Following procurement of the heart and lung by cardiothoracic team, the liver is taken first for the abdominal organs if the small intestine is not for procurement. The gastroduodenal artery is tied and divided. The portal vein is divided at the level of 1 cm proximal to the junction of splenic vein and superior mesentery vein if the pancreas is retrieved for transplantation. Otherwise, the division can be at the level of the confluence of splenic vein and SMV. The splenic artery is divided 0.5 cm from its origin arising from the celiac trunk as well as left gastric artery. However, if the left accessory hepatic artery is present arising from the left gastric artery, then the left gastric artery is preserved on the celiac trunk for its continuity to the left hepatic accessory artery. Along the celiac trunk, the celiac complex and lymphatic tissues are divided at the left side of aorta, and the aorta is exposed. An aortic patch is excised around the ostium of the celiac trunk. If the right accessory or replacement hepatic artery is present, then the SMA is better included in the aortic patch with celiac trunk. If the pancreas is also harvested for transplant, then the SMA is divided just above the level where the accessory hepatic artery arises. So, both liver and pancreas are suitable for transplant without jeopardizing its vasculature. After that the attention is directed to the IVC. The anterior wall of the IVC is incised transversely above the level of renal vein. Both entrance of left and right renal vein

is checked, and the IVC is transected. The IVC is lifted anteriorly by insertion of a finger from the suprahepatic end, and its posterior side is dissected to reach the suprahepatic end. The posterior side of the IVC is dissected superiorly to the level of division just below the atrium. Care is taken during IVC dissection without jeopardizing the quality of renal vein for kidney transplantation. The right hepatic triangle ligament is dissected, and part of the diaphragm is taken with the liver during the procurement. The liver is now removed freely from the abdomen and immersed in the ice-slush filled basin (**Figure 8**). One technical point is that the liver laceration is easy to occur at the location where the adhesion band is present. Therefore, gentle handling of the liver is emphasized during the dissection and procurement of the liver at all times to avoid the potential injury.

### 3.2.3. Procurement of the pancreas

The pancreas can be retrieved in favor with liver as an en bloc as described in a separate paragraph. Here, we describe a technique for pancreas retrieval as a subsequent procedure following the liver procurement. A 6/0 Prolene suture is placed at the transection of the port vein and splenic artery, respectively, as a mark during the liver procurement if known the pancreas is also procured. A segment of duodenum is routinely procured with the pancreas as exocrine drainage. A GIA stapler is used to divide the duodenum from the stomach distal to the pylorus. Care is taken to ensure that the NGT tube is positioned proximal to the pylorus without being caught in the GIA stapler. A reload GIA is needed to divide the distal part of the duodenum at the level of the fourth part of the duodenum or at the beginning of the jejunum. The distal part of the SMA and SMV is tied, respectively, by pre placed 2/0 Vicryl tie and divided. The transverse mesocolon is divided to free the inferior edge of the pancreas. On the left the dissection is continued to the splenic flexure and on the right to the duodeno-colic ligament, which are divided together with the root of mesentery. So, the pancreas with attached duodenum is now free from its attachment. Then, the pancreas is lifted anteriorly



**Figure 8.** Liver graft harvested and immersed in ice slush.

by holding the spleen, and the dissection to its posterior attachment is performed from the tail toward the body of the pancreas. At this point, the SMA is excised with a small aortic patch, and the pancreas is removed from abdomen and placed in the ice-slush filled basin. Care must be taken during excision of the SMA without jeopardizing the renal artery [2].

#### 3.2.4. Procurement of the liver and pancreas as an en bloc

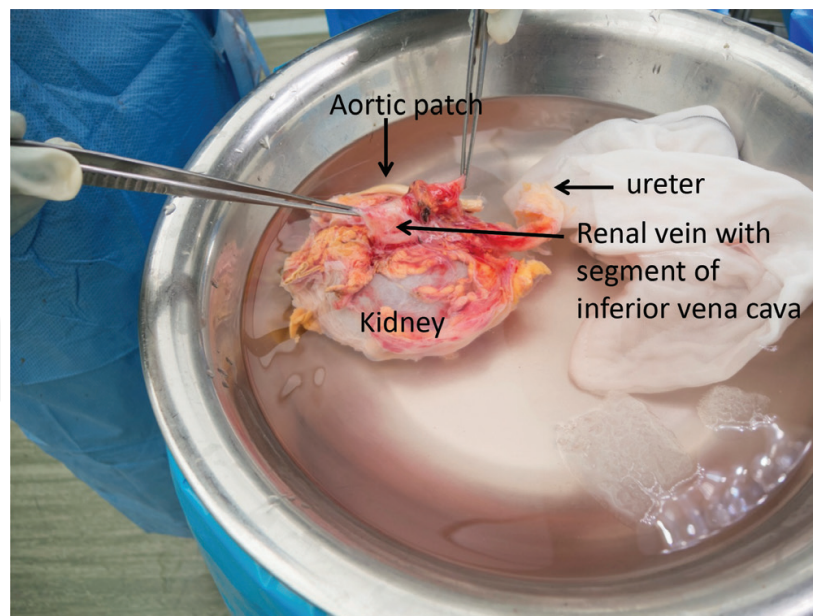
The liver and pancreas are preferred to have en bloc procurement to minimize warm ischemic injury to these organs. Following cold perfusion, the proximal and distal part of the duodenum is transected by using GIA stapler at the level distal to the pylorus and the fourth part of the duodenum, respectively. The distal part of the SMA and SMV is tied by pre placed 2/0 Vicryl tie and divided. The Transverse mesocolon is divided, and the division is continued on the left to the splenic flexure and on the right to the duodenocolic ligament, which are also divided and the colon retracted inferiorly. The spleen is lifted anteriorly as a handle of the pancreas for dissection posterior to the pancreas. The SMA is excised at the inferior edge with a small aortic patch that is extended superiorly to include the celiac trunk on the same aortic patch. The left gastric artery is divided. The attention is directed to the IVC. The IVC is divided just proximal to the level of the entrance by the renal veins, and the dissection to its posterior is continued superiorly to reach the suprahepatic end of the IVC. At this stage, the liver and pancreas are free to be removed from the abdominal cavity and immersed in an ice basin for separation from each other on the back table [2].

#### 3.2.5. Procurement of the kidneys

The kidneys are the lastly procured abdominal organs. Therefore, care must be taken during cooling and procurement phase to ensure that the kidneys are properly cooled by placing enough ice slush at its surrounding, in particular at its posterior and lateral sides [8].

The right kidney is retrieved first. The bowel is placed superiorly, and the kidneys, the vena cava, and the aorta are left in situ. The perfusion cannula is removed, and the aorta is transected at this level. The superior end of the aorta is also transected at the level where the SMA aortic patch is excised. The left renal vein is excised with a small patch from the vena cava and dissected away from the aorta. The anterior part of the aorta is split open as well as the posterior part of the aorta. Care is taken to keep an equal aortic patch with each side of the renal artery. The renal arteries are inspected at this point and are remained on its patch. The IVC is transected at the level of the confluence of common iliac veins. The right ureter is divided at the level of iliac vessels. The ureter is lifted anteriorly, and its posterior is dissected toward the kidney along the plane anterior to the major psoas muscle. Care is taken to retain plenty of surrounding tissues with the ureter. Then, the kidney is lifted anteriorly within Gerota's fascia together with the ureter, and its posterior side is dissected from the psoas muscle. The dissection is continued posteriorly to the IVC, and the right half of the aortic patch until the kidney is free from the attachment. The right kidney is then removed as a pack from the abdomen and placed in the basin filled with ice slush (**Figure 9**). Care is taken to ensure that the dissection is along the surface of the psoas muscle and spine. So, the injury to the renal artery and renal vein is prevented. The left kidney is procured in the same method as the right kidney.





**Figure 9.** Right kidney harvested and immersed in ice slush.

### 3.2.6. Procurement of the kidney on en bloc

Alternatively, the kidneys can be procured on en bloc [5] and separated in the ice basin on a back table. The technique is faster to remove the kidney from the abdomen and minimize the risk of warm ischemic injury. In particular, it is preferred for procurement of the kidneys in DCD donors. The bowel is retracted anteriorly and superiorly. The kidneys, the aorta, and the vena cava are left in situ. The aorta and vena cava is transected at the level of its arteriotomy for the cannula. The right ureter is identified and divided at the level crossing over the iliac vessels as well as the left ureter. The ureter is dissected toward the renal hilum with plenty of surrounding tissues to prevent the injury to its blood supply. The dissection is continued superiorly along the plane posterior to Gerota's fascia but anterior to the psoas muscle and spine until reaching the superior end of the aorta and vena cava. Both kidneys are procured and placed in an ice basin on the back table. During the dissection, the assistant holds up both kidneys with ureters anteriorly to facilitate the dissection.

The kidneys are separated on the back table. The left renal vein is excised with a patch at its entrance to the IVC. The anterior side of the aorta is cleaned and incised along its midline allowing the equivalent patch to each side of the renal artery. Similarly, the posterior side of the aorta is incised along the midline. The ostium of the renal artery is inspected as well as the numbers of the renal artery are checked. The kidneys are now separated from each other. The kidney is inspected as described above and packed for transportation.

### 3.2.7. Procurement of the iliac vessels

A segment of the iliac arteries and veins are harvested as long as possible toward the distal part of the femoral artery and veins. The iliac artery and vein can be taken separately or together as one bundle. Care is taken to avoid injury by over pulling on the vessels. The vessels are stored in a sterile jar with UW solution and packed with two more layers of sterile bags for transportation.



The iliac arteries and veins are routinely retrieved for vascular reconstruction during liver and pancreas transplantation. In pancreas transplantation, the common iliac artery, the external iliac artery, and the internal iliac artery are used as a “Y” graft for reconstruction to the stumps of the splenic artery and SMA and then anastomosed to the recipient common iliac artery at the transplantation. Generally, one set of iliac vessels is sent with the liver, and another set is sent with the pancreas.

## 4. Organ package and the transportation

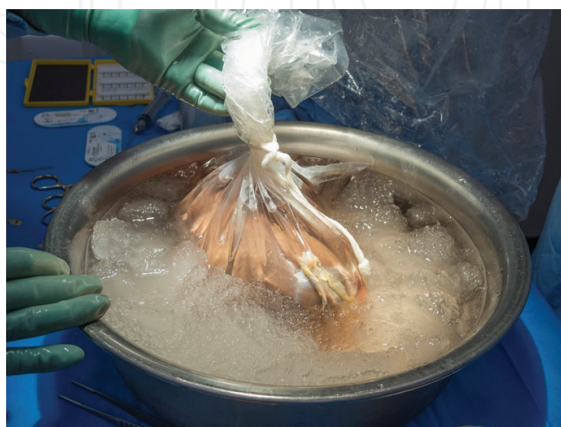All the organs will be further inspected on the back table to ensure its quality and suitability for transplantation. Communication with the transplant surgeon at the recipient end is strongly encouraged to achieve the best outcome for organ transplantation [9].

### 4.1. Liver

The liver is inspected in the basin. Five hundred milliliter of UW solution (4°C) is perfused to the portal vein system. The common bile duct is flushed with 200 ml of UW solution by using a syringe. The liver is placed into the first sterile bag filled with 700–1000 ml of UW solution, and the bag is tied. The first bag is then placed into the second sterile bag filed with 1 L cold normal saline and tied. The second bag is placed into the third sterile bag and then tied. The liver in the three-layered bag is then placed in the Iskey filled with ice blocks for transportation to the recipient hospital with the document secured in the Iskey (**Figure 10**) [7].

### 4.2. Pancreas

The pancreas is inspected to ensure its quality for transplantation without injury from the procurement and then is packed by the same method as for the liver. It is placed in the Iskey with retrieved vessels for transportation to the recipient hospital. Often, the pancreas is allocated with the left kidney to the same recipient for simultaneous pancreas-kidney transplantation (SPKT). Care is taken to avoid manipulation over the pancreas. Perfusion to the pancreas on the back table is not recommended to avoid perfusion injury and pancreatitis.



**Figure 10.** Package of the liver. The first bag filled with UW solution.

### **4.3. Kidneys**

Each kidney is inspected by dissection open the perinephric fat. The quality of perfusion is checked and the mass lesion is excluded. The kidney is placed in the first sterile plastic bag that is filled with 500 ml of UW solution and tied. The first bag is placed into the second bag that is filled with 1 L cold normal saline and tied. The second bag is placed into the third bag and tied. The kidney is placed in the Iskey and buried in the ice blocks for transportation with the document enclosed.

## **5. Conclusion**

Multi-organ procurement is essential for organ transplantation, and proper training is mandatory. It usually involves a few transplant units for organ allocation prior to confirmation of the surgical time. The communication between all parties is very important to minimize the ischemic time and achieve the good outcome for organ transplantation. It should be bore in mind that the anatomical variation may be encountered during the surgery, and care must be taken to avoid any damage to the vessels and organs, which may jeopardize the organ transplantation. Establishment of a surgical protocol is encouraged to achieve a national-wide standard and consistence for organ sharing among the transplant units.

## **Acknowledgements**

We would like to acknowledge DonateLife of Western Australia for their contribution.

## **Conflict of interest**

There is no conflict of interest.

## **Author details**

Bulang He<sup>1\*</sup>, Xiuwu Han<sup>2</sup> and Michael A. Fink<sup>3</sup>

\*Address all correspondence to: [bulang.he@health.wa.gov.au](mailto:bulang.he@health.wa.gov.au)

1 Medical School, The University of Western Australia, Sir Charles Gairdner Hospital, Nedlands, Perth, Australia

2 Beijing Chaoyang Hospital (West Campus), Capital Medical University, Beijing, China

3 Department of Surgery/Austin Health, Medicine Dentistry and Health Sciences, The University of Melbourne, Australia

## References

- [1] Farinelli PA, Padin JM, Troncoso JC, et al. Short- and long-term outcomes of every graft recovered during a multi-organ procurement procedure including the intestine. *Transplantation Proceedings*. 2014;**46**:2090-2095
- [2] Fridell JA, Powelson JA, Kubal CA, et al. Retrieval of the pancreas allograft for whole-organ transplantation. *Clinical Transplantation*. 2014;**28**:1313-1330
- [3] Merkel FK, Jonasson O, Bergan JJ. Procurement of cadaver donor organs: Evisceration technique. *Transplantation Proceedings*. 1972;**4**:585-589
- [4] Rosenthal JT, Shaw BW Jr, Hardesty RL, Griffith BP, Starzl TE, Hakala TR. Principles of multiple organ procurement from cadaver donors. *Annals of Surgery*. 1983;**198**:617-621
- [5] Starzl TE, Hakala TR, Shaw BW Jr, et al. A flexible procedure for multiple cadaveric organ procurement. *Surgery, Gynecology and Obstetrics*. 1984;**158**:223-230
- [6] Wunderlich H, Brockmann JG, Voigt R, et al. DTG procurement guidelines in heart beating donors. *Transplant International: Official Journal of the European Society for Organ Transplantation*. 2011;**24**:733-757
- [7] Abu-Elmagd K, Fung J, Bueno J, et al. Logistics and technique for procurement of intestinal, pancreatic, and hepatic grafts from the same donor. *Annals of Surgery*. 2000;**232**:680-687
- [8] Salazar-Banuelos A, Monroy-Cuadros M, Henriquez-Cooper H. Retro-peritoneal cooling for kidney preservation from multi-organ cadaver donors. *American Journal of Surgery*. May 2018;**215**(5):802-803
- [9] <https://www.tsanz.com.au/standalonepages/documents/201512thFebruary-OTAVs1ReleaseVersionFinal.pdf>. Surgical Technique for Deceased Donor Abdominal Organ Procurement

IntechOpen