

We are IntechOpen, the world's leading publisher of Open Access books Built by scientists, for scientists

4,800

Open access books available

122,000

International authors and editors

135M

Downloads

Our authors are among the

154

Countries delivered to

TOP 1%

most cited scientists

12.2%

Contributors from top 500 universities



WEB OF SCIENCE™

Selection of our books indexed in the Book Citation Index
in Web of Science™ Core Collection (BKCI)

Interested in publishing with us?
Contact book.department@intechopen.com

Numbers displayed above are based on latest data collected.
For more information visit www.intechopen.com



Combined Glaucoma and Cataract: An Overview

Jesús Jiménez-Román, Carolina Prado-Larrea,
Luis Laneri-Pusineri and Roberto Gonzalez-Salinas

Additional information is available at the end of the chapter

<http://dx.doi.org/10.5772/intechopen.73584>

Abstract

Glaucoma and cataract frequently coexist in our elderly population regardless of geographical location or ethnicity. Cataract extraction alone has demonstrated to reduce intraocular pressure in eyes either with or without glaucoma. However, this chapter focuses on how cataract surgery might be combined with different glaucoma surgical procedures, such as trabeculectomy, non-penetrating procedures and minimally invasive procedures (MIGS), as well as implantation of drainage devices like the Trabectome[®] and the iStent[®], both used for trabecular flow increase; the CyPass[®] implant, which acts by increasing the uveoscleral flow; the XEN[®] implant that facilitates the drainage of the aqueous humor from the anterior chamber to the subconjunctival space and finally the endocyclophotocoagulation that decreases the aqueous humor production. Current surgical options will be discussed, focusing on recently reported studies, analyzing the clinical aspects that influence the choice for each surgical treatment.

Keywords: MIGS, glaucoma, cataract, IOP, combined surgery, novel glaucoma procedures

1. Introduction

Cataract and glaucoma are ranked as the leading causes of blindness worldwide (51 and 8%, respectively). Cataract and glaucoma frequently coexist in our patient population. Phacoemulsification combined with trabeculectomy has historically been the preferred surgical approach for concurrently managing cataract and glaucoma. The severity of glaucoma must be taken into account for all cases of cataract surgery in glaucoma patients. In case of a refractory glaucoma; when more than three types of medication are required, with associated early stage cataract; it is advisable to postpone any phacoemulsification procedure until after

glaucoma surgery. However, all cases must be evaluated individually, and cataractogenous effect of the procedure should be considered in this situation. Moreover, cataract extraction performed after a filtering surgery may lead to a reduction of the bleb function.

2. When to combine surgeries and how to minimize complications

In the last few years, glaucoma surgery has undergone great advances when we are talking about surgical treatment of the glaucoma, one of the main points about this is combining cataract and glaucoma surgery [1].

We can combine cataract surgery with different glaucoma surgeries, such as trabeculectomy, implantation of drainage devices, non-penetrating procedures and minimally invasive procedures (MIGS) to mention a few [1].

The success of them depends on several factors among which they can mention:

- Type of glaucoma
- Severity of damage
- Amount and time of use of topical medicine
- Previous surgery/s
- Type of surgery to be performed

Within this last group of surgeries are procedures and devices that seek to derive the aqueous humor toward the Schlemm's channel, the suprachoroidal space, to the subconjunctival space and that reduce the aqueous humor production [1].

This opens a range of possibilities for the treatment of glaucoma, mainly in early stages of the disease, which turns it into a useful resource for the control of glaucoma and making it an option with fewer risks and complications than the classic procedures [1].

2.1. Newer surgical alternatives

Among the methods that can be used, FDA-approved, are Trabectome® and iStent® for use since 2006 and 2012, respectively, both used for trabecular flow increase, the recently approved CyPass® implant in 2016, acts by increasing the uveoscleral flow, the XEN® implant that facilitates the drainage of the aqueous humor from the anterior chamber to the subconjunctival space and finally the endocyclophotocoagulation that decreases the aqueous humor production [2].

It has now been established that the MIGS techniques are prepared for a decrease in intraocular pressure (IOP) at least 20% to be considered effective. In addition to being considered as safe, this means a very low incidence of adverse effects and complications, especially those that affect the patient's vision.

The efficacy and safety of some devices have been demonstrated by many multicenter studies [2].

The hypotensive effect of these techniques may be additional if combined with cataract surgery, phacoemulsification specifically, with this combination is reporting the IOP description up to 40% [4]. The fact that those are techniques with a lower IOP decrease should not be seen as a problem and it is a mistake to compare these techniques with the standard surgery of glaucoma, trabeculectomy with mitomycin C, since they are not designed to replace the latter to fill the gap between medical treatment and more aggressive surgeries [3].

Any patient who undergo phacoemulsification of the lens gives us an opportunity to combine the surgery with a minimally invasive procedure of glaucoma. Due to the efficacy and safety profile, these procedures should be used in cases of mild-to-moderate glaucoma. Regarding the type of glaucoma, they are performed in open-angle primary and secondary to pseudoexfoliation and pigment, except for endocyclophotocoagulation that can be used in other types of glaucoma. With all this, MIGS would help us gain time and delay, as far as possible, more aggressive surgery [3].

In situations in which we combine cataract surgery with some minimally invasive procedure, it is not easy to differentiate what proportion of the hypotensive effect is due to cataract surgery and how much is due to the MIGS procedure. We can say that the hypotensive effect of cataract surgery alone reported by different authors is 2–4 mmHg in a variable period of time (1–7 years) [2, 3].

Some recommendations to facilitate the procedure or implantation of devices and to reduce the rate of intra and postoperative complications are: familiarization with the technique and/or device to be implanted, use of the surgical microscope with different viewing angles, correct use of surgical gonioscopes and previous experience in procedures or surgeries involving surgical manipulation of the angle [2].

According to a meta-analysis, comparing the efficacy of iStent combined with cataract surgery versus phacoemulsification alone in patients with glaucoma and cataract, the decrease in IOP was greater in the group in whom iStent was placed and this effect is even greater if more implantation is performed of a device [4].

2.2. Combined phacoemulsification and canaloplasty

Mention will be made of some of the minimally invasive procedures currently performed, beginning with canaloplasty. This procedure consists in the creation of two overlapping scleral flaps, the probing of the Schlemm's canal with a catheter designed for that effect and the introduction of a suture with the aid of the same catheter and then knotted at its free ends to achieve a canal distension and a tension in the tissues of the trabecular meshwork with the consequent opening of the trabecular meshwork, ending with a watertight suture of the superficial flap. Better results are obtained when this procedure is combined with phacoemulsification of the lens. The reduction obtained is approximately 40% to 3 years with a success of up to 65–82% [5, 6].

2.3. Combined phacoemulsification and iStent®

Another available procedure is the iStent implant, which consists of a metal device that is implanted at the level of the trabecular meshwork to create a bypass between the anterior chamber and the Schlemm's canal. It is the smallest device that is implanted throughout the body as depicted in **Figure 1**. The method may be done in isolation or in combination with phacoemulsification of the lens; if implanted in conjunction with surgery of the lens, the moment in which it is implanted is variable, being able to be before or after the extraction of the lens, taking into account that it must be done with the pupil in miosis and under the direct visualization of the angle through a gonioscens. The hypotensive effect of this device increases when it is associated with cataract surgery in the same surgical act, as well as with the number of implanted devices [4].

If we compare the IOP results, between cataract surgery and cataract surgery plus iStent implantation in PAOG patients with at least one medication and IOP ≥ 19 mmHg, at 15 months the IOP reduction was 17.3% and a 80% medication reduction in the iStent group, compared to 9% IOP reduction and 32% medication reduction (cataract surgery alone) [8].

Almost all of the randomized controlled trials show a mild IOP reduction (between 10 and 20%). But when multiple iStents are implanted with cataract extraction, the IOP reduction is up to 40% with three stents, attention has turned toward using multiple iStents [7].

For multiple iStents alone (without cataract surgery), using the second-generation iStent inject among phakic and pseudophakic subjects, the results show a 29–48% IOP reduction from medicated baseline. At 1 year after implantation of two stents, 66% had IOP ≤ 18 mmHg off of medication, and the mean IOP reduction among all was 40% [8].

2.4. Combined phacoemulsification and CyPass®

One device used to increase drainage through the uveoscleral pathway is the CyPass Micro-stent, which creates a communication between the suprachoroidal space and the anterior chamber. The CyPass Micro-stent is a fenestrated micro-stent made with a biocompatible




Figure 1. iStent implant at the level of the trabecular meshwork to create a bypass between the anterior chamber and the Schlemm's canal.

polyamide, 6.35 mm in length and an external diameter of 510 μm . It is introduced under gonioscopic visualization at the level of the union of the scleral spur with the band of the ciliary body by a curved guide to follow the contour of the sclera along the supraciliary space. Through physical and mechanical properties and a series of retaining rings at the proximal end of the device, the stability of the device is ensured in the supraciliary space. Different studies have shown that the implantation of this device decreases IOP both in isolation and in combination with cataract surgery, with an IOP decrease of approximately 30–35%, and this effect is maintained over time, as well as in the use of hypotensive medication from 1.4 drugs to 0.2 on average. The complications that can be observed after the implantation of this device are few and include loss of visual acuity, corneal edema, iris inflammation, cyclodialysis, hypotonia, migration or obstruction of the device and increase of IOP [9, 10].

CyPass with cataract extraction demonstrate a favorable safety profile. The mean IOP reduction was 5.5 mmHg (from 21.1 ± 5.91 to 15.6 ± 0.53 mmHg) which means a 37% decrease from baseline IOP and a 50% reduction in glaucoma medications [11].

This are the results at one-year follow-up from CyPass implantation alone in a recent multicenter interventional study. Baseline IOP was reduced from 24.5 ± 2.8 mmHg with 2.2 ± 1.1 medications to 16.4 ± 5.5 mmHg with 1.4 ± 1.3 medications at 12 months. This was a 34.7% reduction in IOP. About 83% of eyes avoided conventional incisional glaucoma surgery [11].

2.5. Combined phacoemulsification and endocyclophotocoagulation

Cyclophotocoagulation, initially with a transscleral probe, typically used in refractory glaucoma. Recent reports demonstrate the safety and efficacy of endocyclophotocoagulation (ECP) in the treatment of mild-to-moderate glaucoma. Similar to other MIGS, it is conjunctival-sparing, blebless, and can be combined with cataract surgery. The laser endoscope probe can be inserted through a temporal 2.4 mm clear corneal wound into the anterior chamber and sulcus (filled with OVD). With direct visualization of the ciliary processes, the visible portion of the ciliary process are treated with the diode laser (Iridex Oculight, Mountain View) at 200 mW mean power and continuous duration. Approximately 270° of ciliary processes must be treated to the point of blanching and shrinking of the tissue. Overtreatment is defined by extreme blanching and a popping sound, which indicates an air-bubble explosion [12].

A 3-year outcomes of a prospective nonrandomized matched-control study comparing ECP with cataract extraction versus cataract extraction alone in medically controlled OAG, showed a 10.1% IOP reduction and a 73% medication reduction at 2 years in the treatment group. The control group (cataract surgery alone) showed a 0.8% IOP reduction and a 17% medication reduction at 2 years [12].

Another author reported retrospective results of endocyclophotocoagulation and cataract extraction versus cataract extraction alone in mild-to-moderate glaucoma patients, the combined group had a 14.5% IOP reduction with 85% medication reduction at 36 months. The control group (phacoemulsification alone) 12.4% IOP reduction and a 13.3% medication reduction at 36 months. While there was no significant difference in the IOP reduction

between groups, there was a significant difference in medication reduction. At 36 months, the 61.4% of the combined group versus 23.3% of the control group achieved an outcome of 20% IOP reduction with a decrease of at least one ocular hypotensive medication [13].

2.6 Combined phacoemulsification and Ex-PRESS®

The Ex-PRESS Glaucoma Filtration Device (Alcon Laboratories Inc., Fort Worth, TX) is a bio-compatible [14], non-valved stainless steel device, designed to offer a fast and simple glaucoma filtering device [15] and to provide a lower complication rate with a more stable early postoperative course [16]. Initially it was implanted through full-thickness sclera, directly under the conjunctiva, allowing aqueous drainage into the subconjunctival space [17], alone or in a combined procedure including phacoemulsification, as depicted in **Figure 2**. This technique however, was associated with a higher rate of complications: persistent hypotony, flat anterior chamber, choroidal detachment, suprachoroidal hemorrhage, conjunctival scarring and implant extrusion [18–21]. In 2005, Dahan and Carmichael [15] described an alternative device to be implanted under a scleral flap; these modifications provided satisfactory IOP control and reduced postoperative complications rates.

In a retrospective study by Lan et al. [22] that described the long-term outcomes of the Ex-Press Device combined with phacoemulsification in patients with primary open-angle glaucoma (POAG) and primary angle-closure glaucoma (PACG) and founded a lower postoperative IOP on the POAG group, in addition to more hypotony when compared to the PACG group. Three years after surgery the cumulative complete and qualified success rates were 63.3 and 83.3% (POAG) and 53.3 and 73.3% (PACG), respectively.

Huerta et al. [23] evaluated the efficacy and safety of the Ex-Press device in combination with cataract surgery. After 1-year follow-up, 59.5% of patients had IOP control without medications and 10.8% with one medication. Complications in the early period included ocular hypotony and uveal effusion in 5%, as well as one case of re-intervention after 1-year due to uncontrolled IOP.

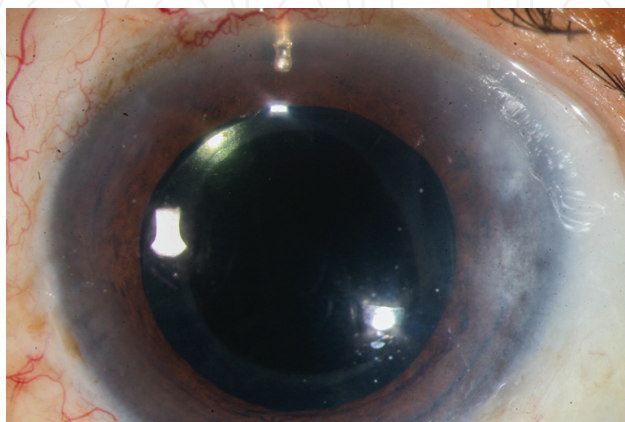


Figure 2. The Ex-PRESS Glaucoma Filtration Device implanted through full-thickness sclera in to the anterior chamber.

3. Impact of cataract surgery on intraocular pressure

The leading cause of age-related, reversible blindness is cataract and the leading cause of irreversible blindness worldwide is glaucoma, the incidence of both cataract and elevated intraocular pressure, with or without glaucoma, increases with age [24]. There have been various reports of the effect of cataract surgery on intraocular pressure (IOP) in glaucomatous and non-glaucomatous eyes, however, the magnitude and clinical significance of these changes continues to be debated. Some studies found a significant IOP reduction whereas others reported no significant change [25], depending on the type of glaucoma.

Intraocular pressure is the only known modifiable risk factor for the development and progression of glaucoma and intraocular pressure-lowering therapy delays its progression [26]. In glaucoma patients, the indication of cataract surgery differs from other patients, depending on various factors such as disease stage, preoperative IOP, number of medications, gonioscopy appearance, age and the experience and skills of the surgeon. Therefore every surgeon should recognize the influence of cataract surgery on IOP control in each type of glaucoma [27].

Previous reports of the effect of cataract surgery in IOP have reflected great variability in IOP reduction, related to angle anatomy, preoperative IOP and anterior chamber depth [28–30]. Identify which patient would experience an IOP-lowering response with cataract surgery alone could modify surgical decision-making.

3.1. Cataract surgery and open-angle glaucoma

In glaucomatous and normal eyes, cataract surgery produces a reduction in IOP, although these effects are more pronounced in patients with primary angle-closure glaucoma (PACG), there has been noticed a reduction in IOP also in POAG.

In a prospective study, Elgin et al. [31] compared the effect of cataract surgery on anterior segment parameters measured by optical biometry in patients with primary open-angle glaucoma (POAG) and pseudoexfoliation glaucoma (PSX), IOP decreased postoperatively 1.9 mmHg and 3.1 mmHg in each group, they also observed a significant increase in anterior chamber depth in both groups with a greater increase in PSX patients probably related to ciliary zonular laxity.

In a retrospective study of the Swedish National Cataract Register Data, Charlotta Zetterström et al. [24] found that after cataract surgery, patients with glaucoma had a larger reduction in IOP than the group of patients who did not have glaucoma and patients with glaucoma and PSX had significantly greater IOP reduction than patients without these diagnoses. They also found that when high IOP was given as an indication for surgery, the IOP reduction after cataract surgery was greater.

Shingleton et al. [32] retrospectively evaluated the change in IOP and glaucoma medications after cataract surgery in glaucoma patients, glaucoma suspects and normal patients. At 3 years follow-up IOP decreased 1.4 mmHg in glaucoma patients and glaucoma suspects and 1.7 mmHg in normal patients, the number of glaucoma medications in the glaucoma group

did not show any significant change at follow-up and they found that after 3 years, 85% of the glaucoma patients had IOP less than or equal to their preoperative IOP, with the same number of glaucoma medications or less. Despite being a retrospective study it demonstrated a sustained reduction in IOP after cataract removal.

Slabaugh et al. [33] in a retrospective study of 157 patients with POAG found a decrease in IOP by a mean of 1.8 mmHg after phacoemulsification at 1 year follow-up but 38% had worsening of IOP control including 24% that needed additional medications or laser trabeculoplasty and 0.6% that required trabeculectomy. Among patients that did not have any change in medications, higher preoperative IOP, older age and deeper anterior chamber depth were associated with lower postoperative IOP.

The American Academy of Ophthalmology in a recent assessment investigated the long-term effect of phacoemulsification on IOP in patients with POAG, PSX and PACG [34]. They found that higher IOP before phacoemulsification is the single most common significant factor associated with a greater drop in IOP after phacoemulsification and concluded that for patients with POAG controlled with 1 or 2 medications, phacoemulsification alone results in a decrease in IOP (-13%) and medication requirement (-12%) although 26% of patients experience worse IOP control after phacoemulsification and may require additional medications, laser treatment or both.

3.2. Cataract surgery and angle-closure glaucoma

The prevalence of primary angle-closure glaucoma is highest in Asia (1.09%) and there is an estimated of 23.4 million cases worldwide for 2020 [35].

Patients with chronic primary angle-closure glaucoma (PACG) have an altered trabecular meshwork architecture with fewer spaces and fused trabecular beams, these changes are the result of mild, recurrent subacute attacks of angle closure that lead to chronic angle-closure glaucoma [36].

In a large percent of patients, there are multiple mechanisms for angle-closure glaucoma as pupillary blocking and plateau iris, in those patients residual angle-closure post iridotomy would result in poor control of IOP, in those patients lens extraction may resolve residual angle closure [37]. Previous studies demonstrated that lens extraction has the ability to lower IOP, lens extraction would widen the angle even without structural alterations of plateau iris because the lens plays a central role in the pathogenesis of PACG, its increased thickness, relative anterior positioning and progression of its thickness result in narrowing of the anterior chamber.

Lens extraction reduces diurnal IOP fluctuations, IOP levels and the number of anti glaucoma medication in PACG with previous laser iridotomy, the change in IOP fluctuation values correlates positively with the change in anterior chamber deep an preoperative IOP fluctuation [38]. Thus patients with narrowest angles might experience a greater benefit from cataract surgery alone depending on the proportion of the angle that has been permanently closed by peripheral anterior synechiae.

In 1998, Gunning and Greve [39] retrospectively evaluated the long-term effects of extraction of incipient cataracts or clear lenses in patients with subacute or chronic angle-closure glaucoma, after a mean follow-up of 52.6 months glaucoma control was achieved in 68% of patients, they concluded that the choice of first a cataract procedure with the option of a future trabeculectomy may be a more attractive approach in patients with subacute or chronic angle-closure glaucoma than trabeculectomy followed by an optional cataract procedure.

In the EAGLE trial, they assessed the efficacy and of clear lens extraction versus laser peripheral iridotomy and topical medical treatment as first-line therapy in people with newly diagnosed primary angle closure and intraocular hypertension or primary angle-closure glaucoma. After a mean follow-up of 36 months, clear lens extraction showed greater efficacy and was more cost-effective than laser peripheral iridotomy, they concluded that clear lens extraction should be considered as an option for first-line treatment [40].

In a prospective study, Tham et al. [41] compared phacoemulsification alone versus combined phacotrabeculectomy in patients with PACG medically controlled, after 2 years follow-up combined surgery resulted in less topical glaucoma drugs but there were no differences in glaucomatous progression, also combined surgery was associated with more postoperative complications.

In another prospective study, Tham et al. [42] also compared phacoemulsification versus trabeculectomy in patients with PACG medically uncontrolled, after 1 year follow-up, there was a significant and comparable reduction in IOP in both groups but trabeculectomy was more effective in reducing dependence on glaucoma drugs also with more postoperative complications. In the phacoemulsification group, only 27% did not require IOP-lowering medications or further surgery after 24 months.

The decision of a cataract surgery alone versus a combined surgery should be made taking account of the type of glaucoma, the severity of the disease and the IOP. Patients with a mild damage and a controlled IOP with topical medications are good candidates for cataract surgery alone.

4. Surgical complications in combined surgery

Patients after glaucoma surgery have an increased risk of cataract formation or progression, approximately 50% of patients will require cataract surgery within the first years after trabeculectomy surgery [43].

Phacoemulsification in presence of a functioning filtration bleb increases the risk of bleb failure in 33%, there are changes in bleb morphology that results in elevations in intraocular pressure (IOP), increased glaucoma medications or additional surgical treatment [44, 45].

The coexistence of cataract and glaucoma in the same patient can follow different strategies such as glaucoma surgery first, cataract surgery first or combined surgery, it depends of the type of glaucoma, the severity of the disease, target intraocular pressure, patients age and the preference of the surgeon.

4.1. Phacotrabeculectomy

Although a staged approach of trabeculectomy followed by cataract surgery has demonstrated successful refractive results, with the last improvements in phacoemulsification and trabeculectomy, phacotrabeculectomy stills a surgical option for some patients with cataract and glaucoma. The indications for phacotrabeculectomy are the simultaneous presence of a visually significant cataract and medically uncontrolled glaucoma, advanced glaucomatous optic nerve damage or visual field loss. A combined approach has the advantages of reduced overall cost, reduced anesthesia and surgery time and less recovery time.

In a retrospective study, Jin et al. [46] evaluated the outcomes after phacotrabeculectomy in consecutive patients. Over 60 patients included in the study, hyphema and hypotony developed in three eyes in the early postoperative period. Bleb hemorrhage occurred in two eyes and cleared within 2 weeks without incident, one eye had a bleb leak that resolved after conservative treatment. The most frequent late complication was posterior capsule opacification requiring capsulotomy in six eyes. Bleb revision was performed in two eyes for dysesthetic bleb 2–3 years after surgery. A second trabeculectomy and an injection of 5-fluorouracil were performed each in one eye, for poor filtration. In this study, the rate of complications was remarkable lower compared with other reports.

In another retrospective study in Singapore [47], the complications after phacotrabeculectomy with Mitomycin C were evaluated, the mean follow-up was 47 months. Most of the postoperative complications occurred within the first month: hypotony in 25.6%, hyphema and shallow anterior chamber in 10% each one. About 11.3% of patients required surgical intervention: bleb needling with antimetabolite use in 4.4%, implant of glaucoma drainage device 1.3%, anterior chamber reformation 1.3% and lens repositioning 0.6%, the majority of complications were transient and self-limiting. They concluded that close and active monitoring is critical in the early postoperative period to prevent complications and surgical failure.

There are reports of tilt and decentration of intraocular lens (IOLs) after phacoemulsification in patients with glaucoma; those are more common in eyes with pseudoexfoliation syndrome or closed-angle glaucoma.

In combined surgery, the changes in anterior chamber depth, axial length, changes in corneal curvature, iridectomy and fluctuations of IOP could affect the accuracy of the IOL power calculation and its position. Ong et al. [48] in a retrospective study investigated the refractive outcome of phacotrabeculectomy compared with a sequential approach, they found a greater myopic refractive prediction error and mean absolute error in the combined group. They advocate the surgeon aim for a slightly more hyperopic result for the combined approach to achieve results closer to emmetropia.

4.2. Combined phacoemulsification and glaucoma drainage implant

In the case of phacoemulsification combined with a glaucoma drainage device operative complications include anterior and/or posterior capsule tears, vitreous loss and IOL-capsular bag subluxation. Cataract extraction combined with implant insertion produce a moderate to severe reduction in IOP (hypotony) lasting for 1–14 days or more, after which the IOP return to safe levels. Other complications include hyphema, anterior chamber shallowing, choroidal

detachment associated with varying degrees of hypotony and IOP spikes [49]. Distended and symptomatic blebs could be seen in these patients and, most infrequently, diplopia.

Corneal decompensation after insertion of drainage devices and cataract extraction was likely to be due to pre-existing endothelial loss caused by previously uncontrolled IOP, but it is possible that endothelial injury may also be aggravated during phacoemulsification [39]. The hypertensive phase defined as elevated IOP in the presence of a functioning bleb and a patent tube and occurring up to 9 months after surgery was found to occur in similar rate than in the isolated drainage implant surgery (22–50%) [49–51]. Tube erosion and occlusion show no difference between tube implant alone and when it is combined with cataract extraction [49–51].

4.3. Phacoemulsification and non-penetrating surgeries

There are several options to manage patients with both cataract and open-angle glaucoma and the rates of complications are different in non-penetrating surgeries compared with trabeculectomy. One of the advantages of phacoemulsification with non-penetrating surgeries versus phacotrabeculectomy is a lower incidence of postoperative inflammation and other immediate complications like hyphema and shallow anterior chamber.

In a retrospective study, Schoenberg et al. [52] compared the surgical outcomes between phaco canaloplasty and phacotrabeculectomy. There were no differences in overall failure rates between the two groups, in the phacotrabeculectomy group two patients had a decrease in vision but only one was related to the surgery. Five patients in each group required revision of the surgical site at the slit lamp for management of elevated IOP.

The most common complication in the phacocanaloplasty group was hyphema (27.7%) and resolved over a 2 week period in all patients. There were some serious complications during follow-up, one patient in each group developed choroidal effusion, one patient had a suprachoroidal hemorrhage and two developed hypotony maculopathy in the phacotrabeculectomy group. They concluded that phacocanaloplasty is an excellent option in patients with mild-to-moderate open-angle glaucoma but despite the higher risks of serious complications phacotrabeculectomy may be a good choice in patients with advanced glaucoma requiring greater IOP reduction.

A retrospective study [53] compared the outcomes of phacotrabeculectomy versus phacoemulsification-deep sclerectomy, there were no cases of bleb infections or endophthalmitis, hypotony occurred in only two patients who underwent laser goniopuncture after phacoemulsification-deep sclerectomy. The frequency of late bleb leaks was significantly higher in the phacotrabeculectomy group, there was a low incidence of immediate side effects in both groups but there was a high incidence of intraoperative perforations (15.7%) in the phacoemulsification-deep sclerectomy group.

A recent survey of the American Glaucoma Society [54] assessed the surgical practice patterns among their members in various clinical settings. In the case of a patient without prior incisional surgery and with a visually significant cataract, 24% of surgeons performed phacotrabeculectomy with mitomycin C, 22% phacoemulsification with minimally invasive glaucoma surgery and 9% phacoemulsification with a glaucoma drainage device versus 44% of surgeons that preferred phacoemulsification alone.

The surgical approach for a patient with cataract and glaucoma has evolved over the years, improvements in previous surgical techniques and new available surgical options with less rates of complications has changed practice patterns among glaucoma surgeons.

5. Novel surgical approaches in cataract surgery

Cataract and glaucoma are ranked as the leading causes of blindness worldwide (51 and 8%, respectively) [55]. Both the cataract and glaucoma can coexist in elderly patient population. An estimate of 20% of cataract procedures performed annually in the USA has glaucoma or ocular hypertension. A combined cataract extraction with trabeculectomy has been the preferred surgical approach for managing cataract and glaucoma [56].

In developed countries, glaucoma is the second leading cause of irreversible blindness and this burden tends to increase as the population ages [57]. Similarly, for cataract, whose prevalence is also age-related the global prevalence of 15.5% increases to 45.9% in those over 75 years and is expected to duplicate by 2020 [58].

Cataract surgery has been demonstrated to reduce IOP in glaucoma patients as well as in non-glaucomatous eyes, with variable magnitude depending on anterior chamber depth, angle configuration or the presence of concomitant pathology as pseudoexfoliation syndrome [34]. Additionally, several series have demonstrated a greater IOP reduction postoperatively in elderly patients, females, eyes with an axial length ≤ 21 mm, and PXF patients [59]. Also, another beneficial effect of cataract removal can be observed in the capacity to increase the accuracy of functional and structural analyses currently used for diagnosing and evaluating glaucoma and its progression, since a visually significant cataract may act as an obstacle to these tests. Therefore, we can presume that combined treatment could be established, with cataract surgery being part of glaucoma treating standardized procedures.

5.1. Simultaneous or sequential cataract and glaucoma surgery

Currently, a variety of surgical procedures are available: first, phacoemulsification cataract extraction alone. Second, sequential glaucoma surgery and cataract extraction, and finally combined surgery. Phacoemulsification alone is suggested for controlled glaucoma patients with moderate and non-progressive visual field defect [59].

The severity of glaucoma must be taken into account for all cases of cataract surgery in glaucoma patients'. In case of a refractory glaucoma, when more than three types of medication are required, with associated early stage cataract, it is advisable to postpone any phacoemulsification procedure until after glaucoma surgery [61]. Moreover, when phacoemulsification cataract extraction is performed after glaucoma surgery, it is advisable to verify bleb function, which could be reduced. For these cases, combined surgery is more beneficial due to an improvement on intraocular pressure decrease when compared to phacoemulsification alone [60, 61].

5.2. Femtosecond-assisted cataract surgery in glaucoma

Femtosecond laser-assisted cataract surgery (FLACS), a new technology that was firstly introduced in 2008 has shown promising treatment outcomes, has realized increasing popularity [62]. Non-inferiority has been established relative to manual cataract surgery, and some reports have suggested superiority relative to manual methods [63]. Potential advantages include customized corneal incisions and capsulotomy position, precision in shape and size of capsulotomy, custom lens fragmentation patterns, endothelial cell loss reduction and better refractive stability and predictability [63].

To date, many studies have attempted to compare the outcome and complications of FLACS and conventional phacoemulsification cataract surgery. Some studies have shown better visual acuity recovery and lower endothelial cell loss after FLACS when compared with conventional phacoemulsification, in non-glaucoma patients [64, 65]. However, in glaucoma patients, the use of FLACS alone or in combination to filtering glaucoma surgery have been optimal, when taking into account postoperative visual recovery, corneal cell integrity and functionality [65].

With femtosecond laser technology and intraoperative image guidance, options for overcoming major challenges in otherwise difficult cataract cases are now available [66]. Preoperative assessment of pupil dilation (4.0 mm or greater) and presence of iridocorneal or iridolenticular adhesions is important in determining whether a patient with Peters anomaly is a candidate for femtosecond laser-assisted cataract extraction. Iridocorneal or iridolenticular adhesions that encroach on the central 4.0 mm of the visual axis may interrupt the laser capsulotomy and may necessitate decentration of the capsulotomy or exclusion of the patient [62].

During femtosecond laser pretreatment in cataract surgery, suction is applied to stabilize the eye before laser anterior capsulotomy, main incision construction and lens fragmentation [67]. Recently reported data from femtosecond pretreatment in cataract surgery suggest that the above-mentioned vacuum application transiently increases intraocular pressure (IOP) [62, 67]. Moreover, large increases in IOP can cause vascular or rhegmatogenous events; however, Schultz et al., reported recently that during femtosecond pretreatment, the IOP increase in healthy eyes is small (mean peak increase 18.5 mmHg from baseline) and appears to be well tolerated [68]. Currently, it is not known whether glaucoma patients are more predisposed to the acute complications or whether their response to vacuum applied during femtosecond laser pretreatment differs from that of patients without glaucoma [69]. Furthermore, a significant increase in IOP during laser pretreatment could result in nerve fiber damage and glaucoma progression.

5.3. Combined FLACS and glaucoma

5.3.1. Preoperative assessment

Laser-assisted cataract surgery patients should be evaluated for glaucoma. Therefore, a number of factors should be taken into account.

1. Glaucoma family history: it has been shown that people with familiar predisposition for glaucoma have increased risk of developing ocular hypertension and glaucoma. In

addition, these patients can develop glaucoma/OHT at a younger age. Therefore, glaucoma and visual field assessment is mandatory for patient's undergoing cataract surgery [70].

2. Elevated IOP remains the most important, modifiable, risk factor for developing glaucoma. However, a single IOP measurement is not sufficient to assess the actual risk of glaucoma, especially when there are other coexisting risk factors, taking into account that transient increase on intraocular pressure is going to be induced by the docking procedure during laser pretreatment [71].
3. Other ophthalmic diseases: pigment dispersion as well as pseudoexfoliation syndrome have been associated to secondary open-angle glaucoma [72, 73]. Previous reports have demonstrated that the presence of pigment dispersion syndrome does not affect the results of refractive surgery; however, topical antiglaucoma medication before surgery can modify the healing process thus the corneal wound can last longer [74].
4. Hypermetropia: hypermetropes are more likely to have narrow anterior chamber angles and a case of acute angle closure after LASIK in a hypermetropic patient has been reported. Pre-operative gonioscopy will help the surgeon to recognize patients with narrow angles [75].

5.4. Toric IOL in glaucoma patients

Cataract surgery has gradually changed from vision rehabilitation to refractive surgery, which aims to achieve the best visual quality with minimal surgical trauma. With improvements of surgical techniques, postoperative corneal astigmatism has become a key factor affecting postoperative visual quality. Surgical astigmatism is caused by many factors, of which surgical incision is the main factor. The application of phacoemulsification on a clear corneal incision can cause slight reverse astigmatism, suggesting that the healing process of clear corneal incision directly affects changes of corneal astigmatism. This astigmatism is caused by the structure of the corneal incision, and corneal biomechanical changes.

Femtosecond laser-assisted cataract surgery (FLACS), which includes lens fragmentation, clear corneal incisions, and limbal relaxing incisions, was first reported by Nagy et al. [64]. The clinical application of the femtosecond laser has led to new developments for cataract surgery. The femtosecond laser system can make ladder-like multi-plane incisions in which the inner surface is enclosed. That is, the ladder between the corneal surface and matrix is made first to improve the impermeability of the incision, maintain intraocular pressure (IOP) and anterior chamber stability and prevent leakage of aqueous humor, thus reducing the incidence of endophthalmitis. The femtosecond laser system was first used to complete the phacoemulsification steps including capsulorhexis, nucleus fragmentation and clear corneal incision. The patients were then subjected to phacoemulsification to complete the entire cut along the tunnel made in former steps using a puncture knife [65].

Pseudoexfoliation is related to both glaucoma and cataract. Particularly, these patients have a tendency to achieve a poor pupil dilation; in addition to weak zonules, iridodonesis, phacodonesis or lens subluxation [75, 76]. In addition, patients with PXF may have higher pressures in the postoperative phase [76].

Toric IOLs might also not be successful in patients with an unstable capsular bag, or pseudo-exfoliation and/or weak zonules, as the lens and bag may rotate or tilt once implanted, altering the patients' vision. There is a potential error if a toric IOL is implanted at the same time a glaucoma procedure is done, since a glaucoma surgery might induce keratometric changes depending on sutures and their tension, and further changes may occur if those sutures are removed or lysed, negating any benefit from the toric implant [77].

5.5. Multifocal IOLs

Multifocal intraocular lenses platforms are indeed valid options for glaucoma patients; however some considerations should be noted regarding its selection. Several lenses affect the monitoring of visual fields, recent reports by Inoue et al., revealed that multifocal IOLs can reduce contrast sensitivity and may alter raw values, gray scale and mean deviation values. Further, increased glare may reduce the sensitivity [77]. In addition, multifocal IOL implants cause significant nonspecific reduction in mean deviation (MD) values in automated perimetry in healthy eyes with multifocal compared to monofocal intraocular lens (IOL) implants on Humphrey Visual Field 10-2 testing that does not improve with time or neuroadaptation [77, 78]. Multifocal IOL implants may be inadvisable in patients where central visual field reduction may not be tolerated, such as macular degeneration, retinal pigment epithelium changes and glaucoma.

Long-term medical therapy used for several glaucoma patients can induce some degree of pupil rigidity, and in these cases, it is advisable to avoid multifocal IOLs if pupil diameter is less than 3.5 mm. Nevertheless, diffractive multifocal IOLs, which are not pupil-size dependent, can be considered for these patients. Irregular-shaped pupils, however, may increase the photopic symptoms and glare [77–79].

It is important to emphasize that multifocal platforms can be safely used in glaucoma suspects and ocular hypertensive patients with no disk or visual field damage who have been stable. In addition, glaucoma patients with early or mild visual field damage that has been controlled and stable, as well as glaucoma patients with a level of glaucoma in the fellow eye that is similar, and not severe, advanced or progressive.

Large trials providing scientific evidence-based data on the impact of multifocal IOL's in glaucoma patients, decisions regarding the implantation in a glaucoma patient should be individualized, taking into account patients' motivation and the rate of progression of glaucoma.

6. Conclusions

Cataract surgery is one of the most performed surgeries in the developed world. In addition to its significant impact on visual acuity, it has a proven potential effect on IOP decrease, but does not reduce IOP peaks [55]. More than 20 million Americans over 40 have cataract symptoms and more than 3 million cataract surgeries are performed in this country each year [80]. On the other hand, cataracts and glaucoma are the main causes of blindness in the world (51 and 8%,

respectively). Glaucoma is the second cause of irreversible blindness, which increases with age [56]. Having both the same trend factor (age), they often coexist. Cataract has an overall prevalence of 15.5%, which increases to 45.9% in subjects older than 75 years and is estimated to be doubling by 2020 [58].

Does cataract and glaucoma coexistence represent a natural key to the management to both conditions? The answer to this question is under discussion, but it is important to note that 30% of patients who underwent cataract surgeries in the United States in the Medicare program had concomitant glaucoma [80, 81]. In addition, another study revealed that 9.1% of patients diagnosed with cataract coexist with the diagnosis of glaucoma [82].

Combined surgery seems to be the most understandable approach in the management of these two conditions. Cataract surgery in conjunction with conventional filtering procedures, such as trabeculectomy and valve implants, is indicated in patients with moderate to severe damage, although there is not real consensus [83, 84].

An important aspect of combined surgery is IOP peaks reduction. Traditional combined surgery produces a significant reduction on IOP, but with a higher risk of complications.

It is at this point that MIGS represents a revolution in combined surgery for glaucoma patients, certainly the IOP reduction is moderate (20%), but the complications number is reduced, it is an additional option to mild glaucoma or topical drug intolerance.

With the advent of these devices, a new vision is established in the glaucoma management, in earlier stages, leaving behind the traditional concept of glaucoma surgery in moderate or severe damage, even more the combination of these procedures with phacoemulsification, defines a new paradigm not only in the IOP control, also in a more audacious and timely visual rehabilitation, inclusive some cases premium lens implant.

On the other hand, the implementation of these novel techniques, require a prominent knowledge of the angular anatomy and be a surgeon experienced in glaucoma surgery, moreover, provides the opportunity to experts in phacoemulsification, to perform minimally invasive techniques and to do appropriate management in glaucomatous patients with mild damage. Cataract surgery with MIGS is an alternative in scrupulously selected patients (mild and moderate). There is insufficient evidence of the long-term intraocular pressure with these devices and techniques (MIGS) may become the most popular surgery in the glaucoma management and with a greater cost-benefit compared to topical treatment; however, there is not enough evidence on this, so it is advisable to consult it constantly and be cautious in the patient selection. Moreover, it is essential to recognize the inherent benefit of the combined procedure and the impact on the visual health and quality of life of our patients.

Conflict of interest

The authors certify that they have NO affiliations with or involvement in any organization or entity with any financial interest (such as honoraria; educational grants; participation in speakers' bureaus; membership, employment, consultancies, stock ownership or other equity

interest; and expert testimony or patent-licensing arrangements) or non-financial interest (such as personal or professional relationships, affiliations, knowledge or beliefs) in the subject matter or materials discussed in this manuscript.

Author details

Jesús Jiménez-Román¹, Carolina Prado-Larrea¹, Luis Laneri-Pusineri¹ and Roberto Gonzalez-Salinas^{2*}

*Address all correspondence to: dr.gonzalezsalinas@gmail.com

1 Glaucoma Department, Asociación para Evitar la Ceguera, Mexico City, Mexico

2 Research Department, Asociación para Evitar la Ceguera, Mexico City, Mexico

References

- [1] Martínez de la Casa JM. Cirugía de glaucoma mínimamente invasiva (MIGS): Dónde estamos y hacia dónde caminamos. *Archivos de la Sociedad Española de Oftalmología*. 2012;**87**(11):351-352
- [2] Caprioli J, Kim JH, Friedman DS, Kiang T, Moster MR, Parrish RK, Rorer EM, Samuelson T, Tarver ME, Singh K, Eydelman MB. Special commentary: Supporting innovation for safe and effective minimally invasive glaucoma surgery. *Ophthalmology*. 2015; **122**(9):1795-1801
- [3] Saheb H, Ahmed II. Micro-invasive glaucoma surgery: Current perspectives and future directions. *Current Opinion in Ophthalmology*. 2012;**23**(2):96-104
- [4] Malvankar-Mehta MS, Iordanous Y, Chen YN, Wang WW, Patel SS, Costella J, Hutnik CM. iStent with phacoemulsification versus phacoemulsification alone for patients with glaucoma and cataract: A meta-analysis. *PLoS One*. 2015;**10**(7):e0131770
- [5] Bull H, von Wolff K, Körber N, Tetz M. Three-year canaloplasty outcomes for the treatment of open-angle glaucoma: European study results. *Graefe's Archive for Clinical and Experimental Ophthalmology*. 2011;**249**(10):1537-1545
- [6] Tetz M, Koerber N, Shingleton BJ, von Wolff K, Bull H, Samuelson TW, Lewis RA. Phacoemulsification and intraocular lens implantation before, during, or after canaloplasty in eyes with open-angle glaucoma: 3-year results. *Journal of Glaucoma*. 2015;**24**(3):187-194
- [7] Nguyen Q. Combined Cataract Surgery and MIGS: Which Procedures will Be a Match Made in Heaven? March/April: *Glaucoma Today*; 2013
- [8] Fea AM. Phacoemulsification versus phacoemulsification with micro-bypass stent implantation in primary open-angle glaucoma: Randomized double-masked clinical trial. *Journal of Cataract & Refractive Surgery*. 2010;**36**(3):407-412

- [9] Vold S, Ahmed II, Craven ER, Mattox C, Stamper R, Packer M, Brown RH, Ianchulev T, CyPass Study Group. Two-year COMPASS trial results: Supraciliary microstenting with phacoemulsification in patients with open-angle glaucoma and cataracts. *Ophthalmology*. 2016;**123**(10):2103-2112
- [10] García-Feijoo J, Rau M, Grisanti S, Höh H, Erb C, Guguchkova P, Ahmed I, Grabner G, Reitsamer H, Shaarawy T. Supraciliary micro-stent implantation for open-angle glaucoma failing topical therapy: 1-year results of a multicenter study. *American Journal of Ophthalmology*. 2015;**159**(6):1075-1081
- [11] Hoeh H, Vold SD, Ahmed IK, Anton A, Rau M, Singh K, Chang DF, Shingleton BJ, Ianchulev T. Initial clinical experience with the CyPass micro-stent: Safety and surgical outcomes of a novel supraciliary microstent. *Journal of Glaucoma*. 2016;**25**(1):106-112
- [12] Francis BA, Berke SJ, Dustin L, Noecker R. Endoscopic cyclophotocoagulation combined with phacoemulsification versus phacoemulsification alone in medically controlled glaucoma. *Journal of Cataract & Refractive Surgery*. 2014;**40**(8):1313-1321
- [13] Siegel MJ, Boling WS, Faridi OS, Gupta CK, Kim C, Boling RC, Citron ME, Siegel MJ, Siegel LI. Combined endoscopic cyclophotocoagulation and phacoemulsification versus phacoemulsification alone in the treatment of mild to moderate glaucoma. *Clinical & Experimental Ophthalmology*. 2015;**43**(6):531-539
- [14] Nyska A, Glovinsky Y, Belkin M, Epstein Y. Biocompatibility of the ex-PRESS miniature glaucoma drainage implant. *Journal of Glaucoma*. 2003;**12**(3):275-280
- [15] Dahan E, Carmichael TR. Implantation of a miniature glaucoma device under a scleral flap. *Journal of Glaucoma*. 2005;**14**(2):98-102
- [16] Condon GP, Moster MR. Minimizing the invasiveness of traditional trabeculectomy surgery. *Journal of Cataract & Refractive Surgery*. 2014;**40**(8):1307-1312
- [17] Traverso CE, De Feo F, Messas-Kaplan A, Denis P, Levartovsky S, Sellem E, Badalà F, Zagorski Z, Bron A, Belkin M. Long term effect on IOP of a stainless steel glaucoma drainage implant (Ex-PRESS) in combined surgery with phacoemulsification. *British Journal of Ophthalmology*. 2005;**89**(4):425-429
- [18] Stewart RM, Diamond JG, Ashmore ED, Ayyala RS. Complications following Ex-PRESS glaucoma shunt implantation. *American Journal of Ophthalmology*. 2005;**140**(2):340-3e1
- [19] Tavolato M, Babighian S, Galan A. Spontaneous extrusion of a stainless steel glaucoma drainage implant (Ex-PRESS). *European Journal of Ophthalmology*. 2006;**16**(5):753-755
- [20] Dahan E. Subconjunctival insertion of Ex-PRESS R-50 miniature glaucoma implant. *Journal of Cataract & Refractive Surgery*. 2008;**34**(5):716
- [21] Garg SJ, Kanitkar K, Weichel E, Fischer D. Trauma-induced extrusion of an Ex-PRESS glaucoma shunt presenting as an intraocular foreign body. *Archives of Ophthalmology*. 2005;**123**(9):1270-1272

- [22] Lan J, Sun DP, Wu J, Wang YN, Xie LX. Ex-PRESS implantation with phacoemulsification in POAG versus CPACG. *International Journal of Ophthalmology*. 2017;**10**(1):51
- [23] Huerva V, Soldevila J, Ascaso FJ, Lavilla L, Muniesa MJ, Sánchez MC. Evaluation of the Ex-PRESS® P-50 implant under scleral flap in combined cataract and glaucoma surgery. *International Journal of Ophthalmology*. 2016;**9**(4):546
- [24] Zetterström C, Behndig A, Kugelberg M, Montan P, Lundström M. Changes in intraocular pressure after cataract surgery: Analysis of the Swedish National Cataract Register Data. *Journal of Cataract & Refractive Surgery*. 2015;**41**(8):1725-1729
- [25] Mathalone N, Hyams M, Neiman S, Buckman G, Hod Y, Geyer O. Long-term intraocular pressure control after clear corneal phacoemulsification in glaucoma patients. *Journal of Cataract & Refractive Surgery*. 2005;**31**(3):479-483
- [26] Heijl A, Leske MC, Bengtsson B, Hyman L, Bengtsson B, Hussein M. Reduction of intraocular pressure and glaucoma progression. *Archives of Ophthalmology*. 2002;**120**(10):1268-1279
- [27] Prata TS, Ushida M, Dorairaj S. Cataract surgery alone cannot be considered an IOP-lowering procedure for open-angle glaucoma patients: An evidence-based perspective. *Arquivos Brasileiros de Oftalmologia*. 2015;**78**(5):V-I
- [28] Issa SA, Pacheco J, Mahmood U, Nolan J, Beatty S. A novel index for predicting intraocular pressure reduction following cataract surgery. *British Journal of Ophthalmology*. 2005;**89**(5):543-546
- [29] Yang HS, Lee J, Choi S. Ocular biometric parameters associated with intraocular pressure reduction after cataract surgery in normal eyes. *American Journal of Ophthalmology*. 2013;**156**(1):89-94
- [30] Huang G, Gonzalez E, Lee R, Chen YC, He M, Lin SC. Association of biometric factors with anterior chamber angle widening and intraocular pressure reduction after uneventful phacoemulsification for cataract. *Journal of Cataract & Refractive Surgery*. 2012;**38**(1):108-116
- [31] Elgin U, Şen E, Şimşek T, Tekin K, Yılmazbaş P. Early postoperative effects of cataract surgery on anterior segment parameters in primary open-angle glaucoma and pseudoexfoliation glaucoma. *Turkish Journal of Ophthalmology*. 2016;**46**(3):95
- [32] Shingleton BJ, Pasternack JJ, Hung JW, O'donoghue MW. Three and five year changes in intraocular pressures after clear corneal phacoemulsification in open angle glaucoma patients, glaucoma suspects, and normal patients. *Journal of Glaucoma*. 2006;**15**(6):494-498
- [33] Slabaugh MA, Bojikian KD, Moore DB, Chen PP. The effect of phacoemulsification on intraocular pressure in medically controlled open-angle glaucoma patients. *American Journal of Ophthalmology*. 2014;**157**(1):26-31

- [34] Chen PP, Lin SC, Junk AK, Radhakrishnan S, Singh K, Chen TC. The effect of phacoemulsification on intraocular pressure in glaucoma patients: A report by the American Academy of Ophthalmology. *Ophthalmology*. 2015;**122**(7):1294-1307
- [35] Tham YC, Li X, Wong TY, Quigley HA, Aung T, Cheng CY. Global prevalence of glaucoma and projections of glaucoma burden through 2040: A systematic review and meta-analysis. *Ophthalmology*. 2014;**121**(11):2081-2090
- [36] Sihota R, Lakshmaiah NC, Walia KB, Sharma S, Pailoor J, Agarwal HC. The trabecular meshwork in acute and chronic angle closure glaucoma. *Indian Journal of Ophthalmology*. 2001;**49**(4):255
- [37] Nonaka A, Kondo T, Kikuchi M, Yamashiro K, Fujihara M, Iwawaki T, Yamamoto K, Kurimoto Y. Cataract surgery for residual angle closure after peripheral laser iridotomy. *Ophthalmology*. 2005;**112**(6):974-979
- [38] Özyol P, Özyol E, Sül S, Baldemir E, Çavdar S. Intra-ocular pressure fluctuation after cataract surgery in primary angle-closure glaucoma eyes medically controlled after laser iridotomy. *Acta Ophthalmologica*. 2016 Nov;**94**(7):e528-e533
- [39] Gunning FP, Greve EL. Lens extraction for uncontrolled angle-closure glaucoma: Long-term follow-up. *Journal of Cataract & Refractive Surgery*. 1998;**24**(10):1347-1356
- [40] Azuara-Blanco A, Burr J, Ramsay C, Cooper D, Foster PJ, Friedman DS, Scotland G, Javanbakht M, Cochrane C, Norrie J. EAGLE study group. Effectiveness of early lens extraction for the treatment of primary angle-closure glaucoma (EAGLE): A randomised controlled trial. *The Lancet*. 2016;**388**(10052):1389-1397
- [41] Tham CC, Kwong YY, Leung DY, Lam SW, Li FC, Chiu TY, Chan JC, Chan CH, Poon AS, Yick DW, Chi CC. Phacoemulsification versus combined phacotrabeculectomy in medically controlled chronic angle closure glaucoma with cataract. *Ophthalmology*. 2008;**115**(12):2167-2173
- [42] Tham CC, Kwong YY, Baig N, Leung DY, Li FC, Lam DS. Phacoemulsification versus trabeculectomy in medically uncontrolled chronic angle-closure glaucoma without cataract. *Ophthalmology*. 2013;**120**(1):62-67
- [43] Collaborative Normal Tension Glaucoma Study Group. Comparison of glaucomatous progression between untreated patients with normal-tension glaucoma and patients with therapeutically reduced intraocular pressures. *American Journal of Ophthalmology*. 1998;**126**(4):487-497
- [44] Klink J, Schmitz B, Lieb WE, Klink T, Grein HJ, Sold-Darseff J, Heinold A, Grehn F. Filtering bleb function after clear cornea phacoemulsification: A prospective study. *British Journal of Ophthalmology*. 2005;**89**(5):597-601
- [45] Awai-Kasaoka N, Inoue T, Takihara Y, Kawaguchi A, Inatani M, Ogata-Iwao M, Tanihara H. Impact of phacoemulsification on failure of trabeculectomy with mitomycin-C. *Journal of Cataract & Refractive Surgery*. 2012;**38**(3):419-424

- [46] Jin GJ, Crandall AS, Jones JJ. Phacotrabeculectomy: Assessment of outcomes and surgical improvements. *Journal of Cataract & Refractive Surgery*. 2007;**33**(7):1201-1208
- [47] Chen DZ, Koh V, Sng C, Aquino MC, Chew P. Complications and outcomes of primary phacotrabeculectomy with mitomycin C in a multi-ethnic asian population. *PLoS One*. 2015;**10**(3):e0118852
- [48] Ong C, Nongpiur M, Peter L, Perera SA. Combined approach to phacoemulsification and trabeculectomy results in less ideal refractive outcomes compared with the sequential approach. *Journal of Glaucoma*. 2016;**25**(10):e873-e878
- [49] Woodcock MG, Richards JC, Murray AD. The last 11 years of Molteno implantation at the University of Cape Town. Refining our indications and surgical technique. *Eye*. 2008;**22**(1):18-25
- [50] Chung AN, Aung T, Wang JC, Chew PT. Surgical outcomes of combined phacoemulsification and glaucoma drainage implant surgery for Asian patients with refractory glaucoma with cataract. *American Journal of Ophthalmology*. 2004;**137**(2):294-300
- [51] Valenzuela F, Browne A, Srur M, Nieme C, Zanolli M, López-Solís R, Traipe L. Combined phacoemulsification and Ahmed glaucoma drainage implant surgery for patients with refractory glaucoma and cataract. *Journal of Glaucoma*. 2016;**25**(2):162-166
- [52] Schoenberg ED, Chaudhry AL, Chod R, Zurakowski D, Ayyala RS. Comparison of surgical outcomes between phacocanaloplasty and phacotrabeculectomy at 12 months' follow-up: A longitudinal cohort study. *Journal of Glaucoma*. 2015;**24**(7):543-549
- [53] Funnell CL, Clowes M, Anand N. Combined cataract and glaucoma surgery with mitomycin C: Phacoemulsification-trabeculectomy compared to phacoemulsification-deep sclerectomy. *British Journal of Ophthalmology*. 2005;**89**(6):694-698
- [54] Vinod K, Gedde SJ, Feuer WJ, Panarelli JF, Chang TC, Chen PP, Parrish RK. Practice preferences for glaucoma surgery: A survey of the American Glaucoma Society. *Journal of Glaucoma*. 2017;**26**(8):687-693
- [55] Pascolini D, Mariotti SP. Global estimates of visual impairment: 2010. *British Journal of Ophthalmology*. 2012;**96**(5):614-618
- [56] Budenz DL, Gedde SJ. New options for combined cataract and glaucoma surgery. *Current Opinion in Ophthalmology*. 2014;**25**(2):141-147
- [57] Quigley HA, Broman AT. The number of people with glaucoma worldwide in 2010 and 2020. *British Journal of Ophthalmology*. 2006;**90**(3):262-267
- [58] Asbell PA, Dualan I, Mindel J, Brocks D, Ahmad M, Epstein S. Age-related cataract. *The Lancet*. 2005;**365**(9459):599-609
- [59] Guan H, Mick A, Porco T, Dolan BJ. Preoperative factors associated with IOP reduction after cataract surgery. *Optometry and Vision Science*. 2013;**90**(2):179-184

- [60] Marchini G, Ceruti P, Vizzari G, Berzaghi D, Zampieri A. Management of concomitant cataract and glaucoma. *Dev Ophthalmol*. 2017;**59**:155-164
- [61] Liaska A, Papaconstantinou D, Georgalas I, Koutsandrea C, Theodosiadis P, Chatzistefanou K. Phaco-trabeculectomy in controlled, advanced, open-angle glaucoma and cataract: Parallel, randomized clinical study of efficacy and safety. *Seminars in Ophthalmology*. 2014;**29**(4):226-235
- [62] Hou JH, Crispim J, Cortina MS, De La Cruz J. Image-guided femtosecond laser-assisted cataract surgery in Peters anomaly type 2. *Journal of Cataract & Refractive Surgery*. 2015;**41**(11):2353-2357
- [63] Chan E, Mahroo OA, Spalton DJ. Complications of cataract surgery. *Clinical & Experimental Optometry*. 2010;**93**(6):379-389
- [64] Nagy ZZ. New technology update: Femtosecond laser in cataract surgery. *Clinical ophthalmology (Auckland, NZ)*. 2014;**8**:1157
- [65] Conrad-Hengerer I, Al Juburi M, Schultz T, Hengerer FH, Dick HB. Corneal endothelial cell loss and corneal thickness in conventional compared with femtosecond laser-assisted cataract surgery: Three-month follow-up. *Journal of Cataract & Refractive Surgery*. 2013;**39**(9):1307-1313
- [66] Mastropasqua L, Toto L, Mastropasqua A, Vecchiarino L, Mastropasqua R, Pedrotti E, Di Nicola M. Femtosecond laser versus manual clear corneal incision in cataract surgery. *Journal of Refractive Surgery*. 2014;**30**(1):27-33
- [67] Kerr NM, Abell RG, Vote BJ, Toh TY. Intraocular pressure during femtosecond laser pretreatment of cataract. *Journal of Cataract & Refractive Surgery*. 2013;**39**(3):339-342
- [68] Schultz T, Conrad-Hengerer I, Hengerer FH, Dick HB. Intraocular pressure variation during femtosecond laser-assisted cataract surgery using a fluid-filled interface. *Journal of Cataract & Refractive Surgery*. 2013;**39**(1):22-27
- [69] Darian-Smith E, Howie AR, Abell RG, Kerr N, Allen PL, Vote BJ, Toh TY. Intraocular pressure during femtosecond laser pretreatment: Comparison of glaucomatous eyes and nonglaucomatous eyes. *Journal of Cataract & Refractive Surgery*. 2015;**41**(2):272-277
- [70] Leske MC, Nemesure B, He Q, Wu SY, Hejtmancik JF, Hennis A. Barbados Family Study Group. Patterns of open-angle glaucoma in the Barbados Family Study. *Ophthalmology*. 2001;**108**(6):1015-1022
- [71] Williams AL, Gatla S, Leiby BE, Fahmy I, Biswas A, De Barros DM, Ramakrishnan R, Bhardwaj S, Wright C, Dubey S, Lynch JF. The value of intraocular pressure asymmetry in diagnosing glaucoma. *Journal of Glaucoma*. 2013;**22**(3):215-218
- [72] Ritch R, Prata TS, De Moraes CG, Vessani RM, Costa VP, Konstas AG, Liebmann JM, Schlötzer-Schrehardt U. Association of exfoliation syndrome and central retinal vein occlusion: An ultrastructural analysis. *Acta Ophthalmologica*. 2010;**88**(1):91-95

- [73] Siddiqui Y, Ten Hulzen RD, Cameron JD, Hodge DO, Johnson DH. What is the risk of developing pigmentary glaucoma from pigment dispersion syndrome? *American Journal of Ophthalmology*. 2003;**135**(6):794-799
- [74] Jabbur NS, Tuli S, Barequet IS, O'Brien TP. Outcomes of laser in situ keratomileusis in patients with pigment dispersion syndrome. *Journal of Cataract & Refractive Surgery*. 2004;**30**(1):110-114
- [75] Paciuc M, Velasco CF, Naranjo R. Acute angle-closure glaucoma after hyperopic laser in situ keratomileusis. *Journal of Cataract & Refractive Surgery*. 2000;**26**(4):620-623
- [76] Jimenez-Roman J, Lazcano-Gomez G, Martínez-Baez K, Turati M, Gullías-Cañizo R, Hernández-Zimbrón LF, Ochoa-De la Paz L, Zamora R, Gonzalez-Salinas R. Effect of phacoemulsification on intraocular pressure in patients with primary open angle glaucoma and pseudoexfoliation glaucoma. *International Journal of Ophthalmology*. 2017;**10**(9):1374
- [77] Ichhpujani P, Bhartiya S, Sharma A. Premium IOLs in glaucoma. *Journal of Current Glaucoma Practice*. 2013;**7**(2):54
- [78] Inoue M, Bissen-Miyajima H, Yoshino M, Suzuki T. Wavy horizontal artifacts on optical coherence tomography line-scanning images caused by diffractive multifocal intraocular lenses. *Journal of Cataract & Refractive Surgery*. 2009;**35**(7):1239-1243
- [79] Farid M, Chak G, Garg S, Steinert RF. Reduction in mean deviation values in automated perimetry in eyes with multifocal compared to monofocal intraocular lens implants. *American Journal of Ophthalmology*. 2014;**158**(2):227-231
- [80] Centers for Disease Control and Prevention. U.S. Outpatient Surgeries on the Rise [internet]. Available at: www.cdc.gov/media/pressrel/2009/r090128.htm. [Accessed January 15, 2014]
- [81] Cullen KA, Hall MJ, Golosinskiy A. *Ambulatory Surgery in the United States, 2006*. US Department of Health and Human Services, Centers for Disease Control and Prevention, National Center for Health Statistics; 2009
- [82] Tseng VL, Yu F, Lum F, Coleman AL. Risk of fractures following cataract surgery in Medicare beneficiaries. *Journal of the American Medical Association*. 2012;**308**(5):493-501
- [83] Lochhead J, Casson RJ, Salmon JF. Long term effect on intraocular pressure of phacotrabeculectomy compared to trabeculectomy. *British Journal of Ophthalmology*. 2003;**87**(7):850-852
- [84] Ogata-Iwao M, Inatani M, Takihara Y, Inoue T, Iwao K, Tanihara H. A prospective comparison between trabeculectomy with mitomycin C and phacotrabeculectomy with mitomycin C. *Acta Ophthalmol*. 2013 Sep;**91**(6):e500-e501

