

We are IntechOpen, the world's leading publisher of Open Access books Built by scientists, for scientists

4,800

Open access books available

122,000

International authors and editors

135M

Downloads

Our authors are among the

154

Countries delivered to

TOP 1%

most cited scientists

12.2%

Contributors from top 500 universities



WEB OF SCIENCE™

Selection of our books indexed in the Book Citation Index
in Web of Science™ Core Collection (BKCI)

Interested in publishing with us?
Contact book.department@intechopen.com

Numbers displayed above are based on latest data collected.
For more information visit www.intechopen.com



Thyroid Cancer: Diagnosis, Treatment and Follow-Up

Mira Siderova

Additional information is available at the end of the chapter

<http://dx.doi.org/10.5772/intechopen.77163>

Abstract

Thyroid cancer is the most common malignancy of the endocrine system and it is usually presented as nodular goiter, the last being extremely a common clinical and ultrasound finding. The widespread use of ultrasonography during the last decades has resulted in a dramatic increase in the prevalence of clinically inapparent thyroid nodules, which only in 5.0–10.0% harbor thyroid carcinoma. The goal of the initial sonographic assessment of thyroid nodules is to distinguish benign nodules that could be managed conservatively from those with suspicious or malignant features requiring further management, including fine needle aspiration biopsy (FNAB), some axillary molecular techniques and thyroid surgery. Since over 90% of malignant thyroid nodules are differentiated thyroid carcinomas (DTCs) with good prognosis, it is necessary to establish strict criteria for diagnosis, treatment and follow-up in order to minimize the potential harm of over-treatment of low-risk patients and to provide adequate therapy to patients at high risk. This often requires an interdisciplinary approach involving endocrinologists, surgeons, pathologists, radiologists and oncologists.

Keywords: thyroid cancer, thyroid nodules, ultrasound, fine needle aspiration biopsy, surgery, radioiodine, follow-up

1. Introduction

Nodular thyroid disease is a common clinical problem and palpable thyroid nodules are found in approximately 3–7% of the population [1]. Comparing to palpation as the detection method, ultrasound (US) increases the prevalence 10-fold, reaching between 20 and 76% with higher rates in women, older age groups and endemic areas [2, 3]. Thyroid carcinoma is the most common endocrine cancer [4], diagnosed in about 5–10% of thyroid nodules [1, 5]. An American survey predicts that by 2019, papillary thyroid carcinoma will be the third most common malignancy in women [6]. Over the last 30 years, the annual incidence of thyroid carcinoma in the

USA has nearly tripled from 4.9 to 14.3/100,000 [7]. It is believed that this increase is largely due to the improved diagnosis and detection of carcinomas smaller than 2 cm, whereas the mortality rate of this disease has not changed and remains at a level of 0.5/100,000 [8]. However, an analysis by Lim et al. of 77,276 thyroid cancer patients published in 2017 estimates an increase in the mortality rate for advanced-stage papillary thyroid cancer [9].

The Chernobyl accident in 1986 marked a new era in thyroid carcinoma incidence. The risk of developing thyroid cancer, especially in Ukraine, Belarus, Western Russia and neighboring countries, is estimated to be highest for those who were then under the age of 9, and especially under the age of 5, and probably have taken a large dose radioactive iodine through milk and dairy products [10]. It is estimated that the Chernobyl accident will result in 16,000 new cases of thyroid cancer by 2065 [10]. In the coming years, an increasing number of newly diagnosed thyroid carcinomas is expected in Japan, related to the Fukushima accident in April 2011. All these factors led to the development in 2015 of the American Thyroid Association (ATA) management guidelines for adults with thyroid nodules and differentiated thyroid cancer [5].

Differentiated thyroid carcinoma (DTC), including papillary (classical and variants) and follicular carcinoma, accounts for over 90% of cases of thyroid cancer and is the main subject of this review. Medullary and anaplastic carcinomas are rare and prognostically less favorable.

2. Preoperative diagnosis of thyroid carcinoma

Two diagnostic procedures play a major role in the preoperative diagnosis of thyroid cancer—the ultrasound (US) examination of the neck, revealing one or more thyroid nodules and the fine needle aspiration biopsy (FNAB). With the discovery of a thyroid nodule, a complete history and physical examination focusing on the thyroid gland and cervical lymph nodes should be performed. Family history of thyroid carcinoma, prior head or neck irradiation, a growing or fixed nodule with neck lymphadenopathy, male gender as well as some age groups (< 18 and > 70 years of age) are clinical factors that are associated with a higher risk of thyroid carcinoma [11, 12].

The next diagnostic step is the clarification of thyroid function by obtaining a serum TSH. If the serum TSH is subnormal, besides serum levels of free T4 and T3, a radionuclide thyroid scan should be performed to document whether the nodule is hyperfunctioning (“hot”), isofunctioning (“warm”) or nonfunctioning (“cold”) [12]. Autonomously functioning thyroid nodules (toxic or hyperfunctioning nodules) do not need further cytologic evaluation because the incidence of malignancy is exceedingly low [5, 12]. On the contrary, a higher serum TSH level, even within the upper part of the reference range, is associated with an increased risk of malignancy [13]. Experimental studies have shown that thyroid cell proliferation is TSH dependent and that highly differentiated thyroid carcinomas retain this response to TSH. Suppressive thyroxine treatment for differentiated thyroid cancer is also based on this TSH dependence [14].

2.1. Ultrasound examination

Most guidelines do not recommend routine population US screening. However, thyroid ultrasound is mandatory for individuals with a family history of thyroid carcinoma, previous

head or neck irradiation (e.g., radiotherapy for concomitant lymphoma), palpable nodules in the neck, symptoms of dysphonia, dysphagia, dyspnea and cervical lymphadenopathy [12].

Neck US is a key examination in the management of thyroid nodules and in the last two decades, it has become an indispensable tool for detecting thyroid nodules and for accurately determining their size, number and structure [15]. By definition, a thyroid nodule is a discrete lesion within the thyroid gland that is radiologically distinct from the surrounding thyroid parenchyma [16]. The US examination should select the suspicious nodule for subsequent FNAB according to the “degree of suspicion” determined by the presence of some of the following malignancy-specific characteristics [17]:

- a solid hypoechoic structure and especially marked hypoechogenicity;
- irregular margins—if more than 50% of the circumference of the nodule is unclearly separated from the surrounding parenchyma, the margins are considered irregular, as well as if microlobulations or spiculae exist. The missing “halo” sign, which indicates that it is difficult to delineate margins, is not equivalent to irregular margins, the last being clearly visible but showing an infiltrative course [5];
- the presence of microcalcifications—tiny hyperechoic spots that are equal to or less than 1 mm in diameter without posterior acoustic shadowing. They are common in papillary thyroid carcinoma and pathologically represent psammoma bodies.
- “taller-than-wide” shape, anterior–posterior diameter exceeds the transversal diameter of the nodule (AP/T ratio > 1) on a transverse or longitudinal plane [18, 19].
- intranodular blood flow detected by color or power Doppler is explained by the formation of new blood vessels needed for the fast proliferating tumor cells [20, 21]. Although intranodular hypervascularity is observed in about half of thyroid carcinomas, it is a nonspecific finding. Perinodular blood flow is usually seen in benign nodules, but 22% of malignant nodules also show perinodular blood flow. The results of previous studies are somewhat contradictory regarding Doppler [19].
- presence of enlarged cervical lymph nodes with suspicions for malignancy characteristics (e.g., round shape, absence of hilus, thyroid-like structure, presence of microcalcifications, cystic degeneration, abnormal vascularity pattern).

Other US characteristics are still debatable, for example, an increase in nodular size/volume (50% increase in volume), large coarse and irregular-shaped dystrophic calcifications (frequently seen in all types of nodules and may reflect previous hemorrhage and tissue necrosis) and rim or “egg-shell” calcifications (malignancy is suspected if the “egg-shell” is interrupted, with small extrusive soft-tissue component). According to most studies, the nodule size and number (solitary nodules or multinodular goiter) are not suggestive of malignancy, although a meta-analysis of Campanella indicates a higher malignancy risk for single nodules (OR, 1.43) and for nodule size ≥ 4 cm (OR, 1.63) [11].

There are also some US features suggestive of benignity of the nodule—pure cysts with anechoic structure, spongiform nodules, halo sign, smooth margins, dorsal acoustic enhancement, presence of a gentle continuous halo, dorsal acoustic enhancement, hyperechoic structure, uninterrupted eggshell calcifications as well as significant decrease in size over time [22].

Apart from the interobserver variation in the assessment, the US criteria associated with malignancy have various sensitivity and specificity, and unfortunately, none of them alone is strong enough to prove or rule out malignancy efficiently (**Table 1**). This is why some teams have tested certain combinations of US features to increase the diagnostic accuracy of this imaging technique. The concurrent presence of two sonographic criteria doubles the probability of malignancy; a combination of three raises the malignancy risk to 72.7% [30]. According to Papini et al. the combination of a hypoechoic structure and at least one of the following US features—irregular borders or microcalcifications or intranodular blood flow—reaches 87% sensitivity and would miss only 13% of the carcinomas among the nonpalpable nodes [25].

In 2017 the European Thyroid Association (ETA) created a novel European Thyroid Imaging and Reporting Data System, called **EU-TIRADS**, providing a risk stratification of thyroid nodules [31]. It consists of a 6-point scale for risk stratification with increasing risks of malignancy and is based on the “classic pattern” concept [31]:

- **EU-TIRADS 1** category refers to a US examination where no thyroid nodule is found; there is no need for FNAB.
- **EU-TIRADS 2** category comprises benign nodules with a risk of malignancy close to 0%, presented on sonography as pure/anechoic cysts (**Figure 1A**) or entirely spongiform nodules (**Figure 1B**). Both of these US appearances are sufficient to rule out malignancy without the need for FNAB, unless the last is performed for therapeutic purposes—that is, cyst evacuation in case of compressive symptoms. The benign cyst is a purely cystic nodule which does not have any wall thickening or any solid component that could be identified by Doppler US. Cysts which are divided into separate compartments by septa also belong to this benign category. Bright echogenic spots with posterior comet-tail artifact represent a benign finding, in fact a reverberation of the US signal related to presence of microcrystals in colloidal nodules. The spongiform nodule (also “puff pastry” structure) is composed of tiny cystic spaces involving the entire nodule, separated by numerous isoechoic septa, and is considered benign [5, 12, 22, 31].
- **EU-TIRADS 3** is the low-risk category (malignancy risk: 2–4%) which includes oval-shaped, isoechoic or hyperechoic nodules with smooth margins and no high-risk features (**Figure 1C and D**). FNA is recommended only for nodules >20 mm [31, 32]. For nodules with an inhomogeneous structure, the presence of any hypoechoic areas classifies the nodule as intermediate risk (see below).
- **EU-TIRADS 4** is the intermediate-risk category with an estimated risk of malignancy between 6 and 17% [31, 32]. This category is presented by mildly hypoechoic nodules with oval shape, smooth margins and without any features of high risk (**Figure 1E**). FNA should be performed if nodule’s diameter is >15 mm. As it is evident, the difference between the low-risk (EU-TIRADS 3) and the intermediate-risk category (EU-TIRADS 4) lies in the echogenicity of the solid part of the nodule. The estimated risk of malignancy varies between 6 and 17% and some US features may modulate it. For example, cystic areas, the presence of comet-tail artifacts, peripheral vascularity or high elasticity lowers the malignancy risk, whereas interrupted rim macrocalcifications, a thick or discontinuous halo, predominantly central vascularity, and low elasticity may increase the risk [31].

US feature	Author	Year	Nodules (number)	Sensitivity (%)	Specificity (%)
Solid hypoechoic structure	Kim et al. [23]	2002	155	26.5	94.3
	Peccin et al. [24]	2002	289	44.0	83.0
	Papini et al. [25]	2002	494	87.1	43.4
	Capelli et al. [26]	2007	5198	81.0	47.0
	Moon et al. [27]	2008	8024	41.4	92.2
Irregular margins	Brito et al.* [28]	2014	18288	73.0	56.0
	Remonti et al ** [29]	2015	12786	62.7	62.3
	Kim et al. [23]	2002	155	55.1	83.0
	Peccin et al. [24]	2002	289	56.0	80.0
Microcalcifications	Papini et al. [25]	2002	494	77.5	85.0
	Capelli et al. [26]	2007	5198	53.0	81.0
	Moon et al. [27]	2008	8024	48.3	91.8
	Brito et al.* [28]	2014	18288	56.0	79.0
	Remonti et al ** [29]	2015	12786	50.5	83.1
	Kim et al. [23]	2002	155	59.2	85.8
	Peccin et al. [24]	2002	289	56.0	94.0
Intra-nodular blood flow	Papini et al. [25]	2002	494	29.0	95.0
	Capelli et al. [26]	2007	5198	72.0	71.0
	Moon et al. [27]	2008	8024	44.2	90.8
	Brito et al.* [28]	2014	18288	54.0	81.0
	Remonti et al ** [29]	2015	12786	39.5	87.8
	Papini et al. [25]	2002	494	74.2	80.8
Taller-than-wide shape	Capelli et al. [26]	2007	5198	62.0	50.0
	Brito et al.* [28]	2014	18288	48.0	53.0
	Remonti et al ** [29]	2015	12786	49.5	78.0
	Kim et al. [23]	2002	155	32.7	92.5
Size >10 mm	Moon et al. [27]	2008	8024	40.0	91.4
	Brito et al.* [28]	2014	18288	53.0	93.0
	Remonti et al ** [29]	2015	12786	26.7	96.6
Size >10 mm	Papini et al. [25]	2002	494	61.3	32.0
	Capelli et al. [26]	2007	5198	77.0	35.0
	Brito et al.* [28]	2014	18288	57.0	40.0

*a metaanalysis of 31 studies

**a meta-analysis of 41 studies

Table 1. Sensitivity and specificity of different US characteristics, studied by different research groups.

- **EU-TIRADS 5** encompasses the high-risk category nodules with at least one of the following US features: marked hypoechogenicity, nonoval shape, irregular margins and microcalcifications. The risk of malignancy varies between 26 and 87% [33, 34], generally increasing with the number of suspicious US characteristics. FNA is recommended for high-risk nodules if they exceed 10 mm in size. In case of benign cytology of such a suspicious nodule, FNAB should be repeated within 3 months to reduce the rate of false-negative samples. Patients with subcentimeter nodules with highly suspicious US features (microcarcinomas) and no abnormal lymph nodes can have the choice of active surveillance or FNAB. The last is recommended if the nodule shows enlargement or is accompanied by abnormal lymph node/s, highly suspicious of lymph node metastatic disease [31].

2.1.1. The problem of thyroid incidentalomas

A thyroid incidentaloma is defined as an unexpected, asymptomatic thyroid tumor discovered during the investigation of an unrelated condition. The widespread use of various high-sensitive imaging methods (US, CT, MRI, FDG PET) leads to accidental detection of nonpalpable thyroid nodules, some of which may prove to be malignant [35]. It is believed that the

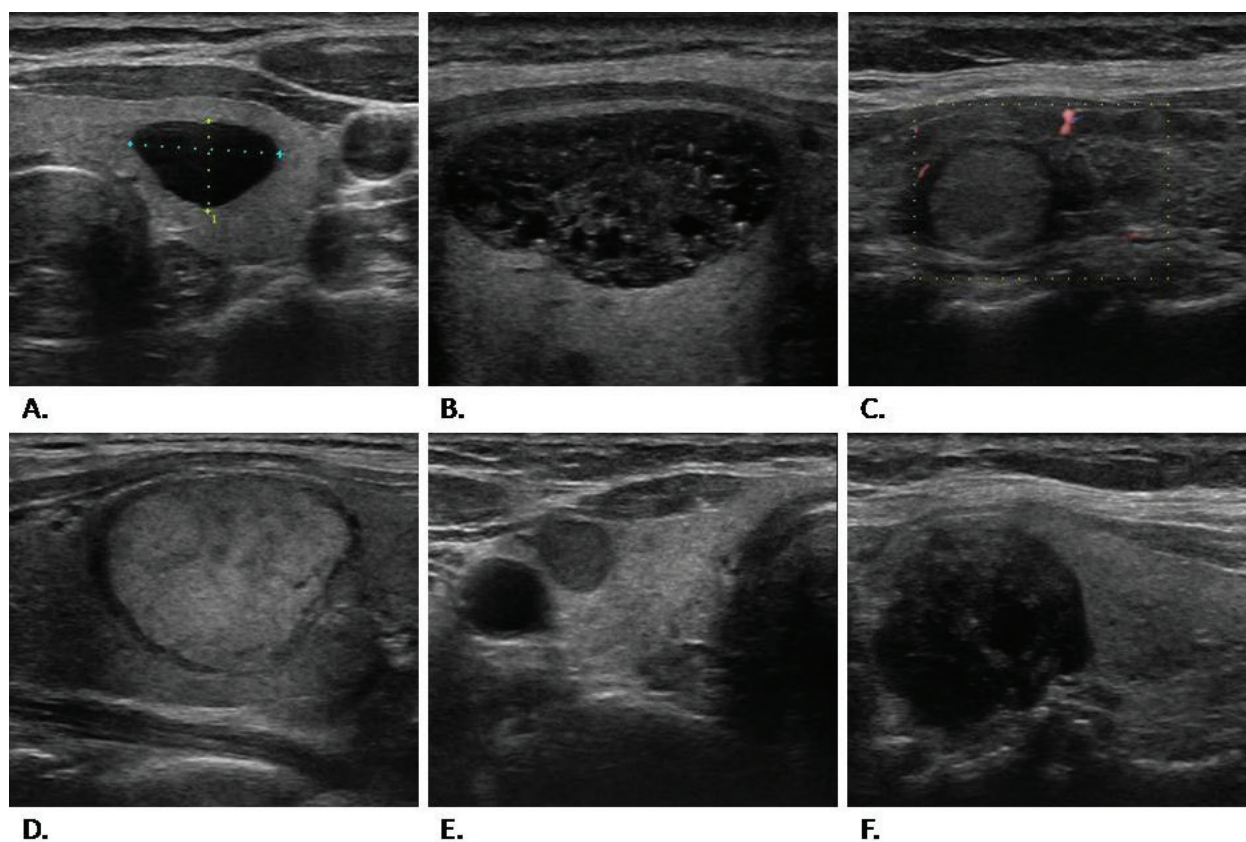


Figure 1. US images of different thyroid nodules, classified according to EU-TIRADS. A. A pure cyst in the left thyroid lobe (EU-TIRADS 2). B. A spongiform nodule with comet-tail artifacts (EU-TIRADS 2). C. An isoechoic nodule with continuous halo (EU-TIRADS 3). D. A hyperechoic nodule with a hypoechoic halo (EU-TIRADS 3). E. A hypoechoic nodule with borderline antero-posterior to transversal ratio (EU-TIRADS 4). F. A highly suspicious nodules with marked hypoechogenicity, non-oval shape, irregular margins, and microcalcifications (EU-TIRADS 5).

increased incidence of thyroid carcinoma is mainly due to detection of microcarcinomas ≤ 1 cm as incidentalomas [36]. The estimated risk of malignancy varies according to the method of discovery. In the absence of clinical risk factors, the risk of malignancy in thyroid incidentalomas diagnosed on neck US, CT or MRI is 5–13%, which is more or less the same as the risk among all thyroid nodules [31, 32, 36, 37]. This implies a mandatory US assessment before the decision for FNAB. In contrast, the risk of malignancy when diagnosed by focal FDG uptake on a PET scan (F-18 fluoro-deoxy-glucose positron emission tomography) is much higher, around 30% [38]. Although the FDG PET is performed in the context of another oncological disease, most FDG PET-positive thyroid incidentalomas are differentiated thyroid cancers and not intrathyroidal metastases from other malignancies [38].

2.1.2. US elastography

Sonoelastography is a noninvasive dynamic technique that uses US to provide an estimation of tissue stiffness by measuring the degree of distortion under the application of an external force. US elastography has been applied to study the hardness/elasticity of nodules to differentiate malignant from benign lesions [39]. Real-time ultrasound elastography (RTE) is the most commonly used method in thyroid clinics. The nodule chosen by the operator and taken in to the area of interest is subjected to repeated pressure pulses applied by the probe. Tissue distortion is then processed by a special software and presented by a US elastogram over the B-mode image in a color scale that ranges from red, for components with greatest elastic strain (*i.e.*, softest components), to blue for those with no strain (*i.e.*, hardest components). The US elastographic image is then matched with an elasticity color scale and classified as: score 1—elasticity in the whole nodule; score 2—elasticity in a large part of the nodule; score 3—elasticity only at the periphery of the nodule; score 4—no elasticity in the nodule; score 5—no elasticity in the nodule and part of the surrounding tissue [39, 40]. The probability of malignancy raises with increasing hardness of the nodule and decreasing elasticity, respectively. A strain index (SI) could be calculated as a ratio of the nodule strain divided by the strain of the softest part of the surrounding normal tissue. The cut-off of SI for malignancy was estimated to be 2.9 in a study of Magri in 661 nodules [41]. Others proposed a higher cut-off of 3.85 for detecting malignant thyroid nodules [42].

2.2. Fine needle aspiration biopsy (FNAB) with cytology assessment

Fine needle biopsy (with or without aspiration) is the most accurate preoperative diagnostic method for distinguishing malignant from benign thyroid nodules [43]. It is a minimally invasive and safe method, which can be performed to hospitalized patients as well as in outpatient settings. It is recommended that the yielded cytological material is then evaluated according to the Bethesda classification in one of the following six categories [44]:

1. **Nondiagnostic or unsatisfactory** are specimens that do not meet the criteria for adequacy due to different reasons—an insufficient number of follicular cells, obscuring blood or clotting artifact, thick smears, air drying of alcohol-fixed smears and others. A thyroid FNA specimen is considered satisfactory for evaluation if it contains at least six groups of follicular cells, each group composed of at least 10 cells [45]. Cyst-fluid-only (CFO) cases

representing cystic thyroid nodules, richly vascularized nodules and pronounced fibrosis in Hashimoto thyroiditis may also result in nondiagnostic specimens. A repeated biopsy with ultrasound guidance is recommended for the unsatisfactory specimens. The risk of malignancy in this category is from 1 to 4%.

2. **Benign cytology** comprises benign follicular nodules (adenomatoid nodules, colloid nodules, etc), lymphocytic (Hashimoto) thyroiditis and granulomatous (subacute) thyroiditis. A “benign” or “negative for malignancy” result is obtained from 60 to 70% of all thyroid FNABs, thus avoiding unnecessary surgery in the majority of the patients. Surgery is indicated for very big nodules (usually over 4 cm) causing compression or cosmetic concerns. The benign category carries very low risk of malignancy (0–3%) and if during the US follow-up the nodule shows more than 50% increase in volume or “suspicious” sonographic changes, a repeated FNAB is indicated [44].
3. **Atypia of undetermined significance (AUS) or follicular lesion of undetermined significance (FLUS)** refers to cytological specimens with follicular arrangement and scant colloid that do not fulfill the criteria for the other categories (4, 5, rarely 6). The estimated risk of malignancy varies between 5% and 15%. The recommended management is clinical correlation and a repeated FNA which may lead to a more definitive interpretation. However, the physician may choose not to repeat the FNA but observe the nodule clinically or, alternatively, refer the patient to operation due to clinical and/or sonographic concerns [44, 46].
4. **Follicular neoplasm (FN) or suspicious for a follicular neoplasm (SFN)**—the specimens typically have high cellularity, and colloid is scant or absent. Since the differentiation between follicular carcinoma and adenoma is made on the basis of capsular and/or vascular invasion, that are visible only on histology, FNAB reports them by this summary term “follicular neoplasm,” requiring a definitive diagnostic histology procedure, usually lobectomy. The risk of malignancy in the category of FN/SFN amounts to 15–30% [44, 47].
5. **Suspicious for malignancy** is a cytology suggestive of malignancy without meeting all criteria for the definitive diagnosis of papillary or medullary carcinoma or very rarely lymphoma. The likelihood of definitively confirmed malignancy is approximately 70% and a surgery is recommended [44, 46].
6. **Malignant cytology** indicates that the cytomorphic features of the cells are conclusive for malignancy—usually papillary thyroid carcinoma (PTC), more rarely anaplastic, medullary cancer, lymphoma or a metastatic lesion of another origin. Thyroidectomy is indicated for this category. The positive predictive value of a malignant FNA interpretation is from 97–99% [44].

Most guidelines recommend surgical removal of nodules with cytology corresponding to Bethesda categories 3, 4, 5, and 6 [5, 13]. Preoperatively, clinical staging is performed through US and/or CT for neck cervical lymph nodes engagement [5, 12]. A CT/MRI is also indicated in selected cases to determine the local invasion of trachea and surrounding structures. In cases of suspicious neck lymphadenopathy, an FNAB of the lymph node with cytological assessment can be combined with a measurement of thyroglobulin/calcitonin in the wash out of the needle [48].

2.3. Molecular testing

Bethesda indeterminate categories 3 and 4 comprise the so-called “gray zone” in thyroid cytopathology. Further stratification of malignancy risk and, respectively, the decision for surgery could be made by some ancillary techniques as molecular testing. The largest studies of preoperative molecular markers in patients with indeterminate FNA cytology have, respectively, evaluated a seven-gene panel of genetic mutations and rearrangements (BRAF, RAS, RET/PTC, PAX8/PPRA γ) [49], a gene expression classifier (167 GEC, mRNA expression of 167 genes) [50] and galectin-3 immunohistochemistry (cell blocks) [51]. Due to the lack of a single optimal molecular test to exclude malignancy and the high cost of these ancillary techniques, they are still not routinely recommended. In the absence of molecular diagnosis, surgical removal of all undetermined lesions and follicular neoplasms is recommended [5].

3. Role of staging and risk stratification in differentiated thyroid carcinoma (DTC) patients

Disease staging is recommended for all patients with DTC not only as a requirement of the cancer registries but also as a factor determining the following treatment, risk assessment, and prediction of disease recurrence or persistence as well as disease mortality. Moreover, in the last years, risk stratification for thyroid cancer patients has changed from a single-point assessment at the time of the diagnosis and initial treatment to a more dynamic and changing overtime risk evaluation [16, 52].

TO	No evidence of primary tumor
T1a	Tumor < 1 cm in greatest dimension. limited to the thyroid. without extrathyroidal extension
T1b	Tumor between 1 cm and 2 cm, without extrathyroidal extension
T2	Tumor between 2 cm and 4 cm, without extrathyroidal extension
T3	Tumor > 4 cm in its greatest dimension. limited to the thyroid gland or Any tumor with minimal extrathyroidal spread (e.g., extension into sternothyroid muscle or perithyroid soft tissues)
T4a	Any tumor. with extension beyond the thyroid capsule and invasion of subcutaneous tissue. larynx. trachea. esophagus. or recurrent laryngeal nerve
T4b	Tumor of any size, with invasion of prevertebral fascia or encasing carotid artery or mediastinal vessels
NO	No metastatic lymph nodes (LNs)
N1a	Metastases to LNs in level VI (pretracheal, paratracheal, and prelaryngeal LNs)
N1b	Metastases to unilateral, bilateral, or contralateral cervical LNs (levels I, II, III, IV, or V) or retropharyngeal or superior mediastinal region (level VII)
MO	No distant metastases
M1	Distant metastases

Table 2. AJCC 7th edition of TNM classification system for differentiated thyroid carcinoma (adapted from the AJCC cancer staging manual. Seventh edition (adapted from edge et al. [53]).

The initial staging of each patient is performed post-operatively mainly on the basis of the histology report, according to the seventh edition of the TNM classification of the American Joint Committee of Cancer (AJCC), presented on **Table 2** [53]. Additionally to the TNM score, the age of the patient is also important, as young age (≤ 45 years) is considered a favorable factor upstaging the young patients with any T, any N and M0 in stage I and, respectively, young patients with distant metastases in stage II. However, some studies have questioned this “young age benefit” in the presence of lymph node metastases [54].

The initial risk stratification is based on the TNM staging, as well as the type of tumor histology. ATA guidelines from 2015 proposed some additional prognostic variables as the extent of lymph node involvement presented as the number and size of lymph metastases, mutational status and degree of vascular invasion as the number of affected vessels that were not present in previous stratification systems (**Table 3**).

Low ATA risk	<p>Papillary thyroid carcinoma (with all of the following):</p> <ul style="list-style-type: none"> • No local (LNs) or distant metastases • Complete resection of the primary tumor (assessed macroscopically) • No tumor invasion of local tissues and structures • The histological subtype does not belong to the aggressive ones (e.g., tall cell, columnar cell or hobnail cell variant) • No vascular invasion • Clinical N0 or < 5 N1 micrometastases (< 2 mm) • If ^{131}I is administered, there are no uptake outside the thyroid bed (no metastatic foci) on the post-therapeutic whole-body scan (WBS) <p>Intrathyroidal encapsulated follicular variant of papillary carcinoma</p> <p>Intrathyroidal, well differentiated follicular carcinoma with capsular invasion and no or minor (< 4 vessels) vascular invasion</p> <p>Intrathyroidal, papillary microcarcinoma, unifocal or multifocal, including BRAF^{V600E} mutated (if known)</p>
Intermediate ATA risk	<p>Microscopic invasion of tumor into the soft tissues surrounding the thyroid</p> <p>RAI uptake outside the thyroid bed (metastatic foci) on the posttherapeutic whole-body scan (WBS)</p> <p>Aggressive histology (e.g., tall cell, columnar cell or hobnail cell variant, diffuse sclerosing variant)</p> <p>PTC with vascular invasion</p> <p>Clinical N1 or > 5 metastatic LNs with size < 3 cm</p> <p>Multifocal papillary microcarcinoma with extrathyroidal extension and BRAF^{V600E} mutated (if known)</p>
High ATA risk	<p>Macroscopic invasion of tumor into the perithyroidal soft tissues</p> <p>Incomplete tumor resection</p> <p>Distant metastases</p> <p>High postoperative serum thyroglobulin suggestive of distant metastases</p> <p>LN metastasis with any of the LNs > 3 cm</p> <p>Follicular thyroid cancer with extensive vascular invasion (> 4 foci of vascular invasion)</p>

Table 3. Initial risk stratification (adapted from ATA 2015 guidelines [5]).

Ongoing (dynamic) risk stratification reflects the changes of recurrence risk during the follow-up period, which depends on the natural history of the disease and the patient's response to therapy (see Section 5 on the follow-up of patients with DTC).

4. Treatment

Initial treatment of DTC includes surgery and post-operative administration of radioiodine (if indicated) and the initiation of levothyroxin therapy. In rare cases (locally aggressive thyroid cancer), external beam radiotherapy to the neck is also indicated.

4.1. Surgery

4.1.1. *Thyroid surgery*

Thyroid surgery is an important element of the initial therapy for thyroid carcinoma. The recommended extent of thyroid surgery in patients with FNAB and cytology of malignant thyroid nodule (not medullary carcinoma) depends on the nodule size:

- A tumor larger than 4 cm, or with a gross extrathyroidal extension, or clinically metastatic lymph nodes or proven distant metastases, requires a total or near-total thyroidectomy as initial surgical intervention in order to remove all primary tumor mass [5].
- For tumors >1 cm and < 4 cm without extrathyroidal invasion, with no clinical data of lymph node metastases, the initial surgical procedure can be either bilateral (total or near-total thyroidectomy) or unilateral (lobectomy). Lobectomy may be sufficient for low-risk papillary and follicular carcinomas. Total thyroidectomy (TT) can be considered by the treatment team, especially if consequent radioiodine ablation (RAI) is planned. TT also enables a reliable follow-up, since thyroglobulin used as a tumor marker is expected to be undetectable if the thyroid is removed.
- For tumors <1 cm (small, unifocal and intrathyroidal carcinoma), without extrathyroidal extension and without lymph nodes involvement, thyroid lobectomy is sufficient unless there are other indications to remove the contralateral lobe as concurrent Graves' disease or benign nodules in the contralateral lobe [5, 52].

4.1.2. *Lymph node dissection*

- Therapeutic central-compartment (level VI) lymph dissection of the neck is recommended in addition to the total thyroidectomy for patients with clinical evidence of involved central lymph nodes [5].
- Prophylactic central-compartment neck dissection should be considered in patients with PTC with no clinical data on central neck LNs' involvement in cases that lateral neck nodes are involved or when the primary tumor is advanced (T3 or T4).

- Thyroidectomy without prophylactic central neck lymph dissection is suitable for small (T1 or T2), noninvasive, PTC without clinically engaged LNs and for most follicular carcinomas [5].
- Therapeutic lateral-compartment lymph node dissection is recommended for patients with biopsy-proven metastatic lateral lymph nodes [55].

4.1.3. Completion thyroidectomy

Completion thyroidectomy is a reoperation to completely remove residual thyroid parenchyma and should be offered to patients for whom total thyroidectomy would have been indicated if the diagnosis was known prior to the initial surgery. This underlines the importance of routine referral of patients with nodular goiter to FNAB, since malignant or suspicions for malignancy cytology suggests a one-step operation (total or near-total thyroidectomy) in contrast to a suboptimal operation (lobectomy) for preoperatively unspecified carcinoma which could require a second operation (completion thyroidectomy), the latter being often difficult to perform due to adhesions and neck changes after the previous operation [4, 5].

4.2. Post-operative radioiodine (RAI) treatment

Post-operative administration of ^{131}I aims to destroy the remnant in the thyroid bed, as well as microscopic tumor foci, thus reducing the likelihood of recurrence [56, 57]. The ablation of residual normal thyroid tissue allows adequate long-term follow-up and early detection of recurrence based on serum Tg and whole-body scintigraphy (WBS). The high activity ^{131}I , given as a therapeutic dose (from 30 to 100 mCi), can also be used for diagnostic purposes by conducting a WBS from 2 to 5 days after the iodine administration, thus detecting small invisible with diagnostic doses (from 1 to 3 mCi) foci [57].

However, RAI remnant ablation is not routinely recommended after thyroidectomy for all DTC patients. For patients with low ATA risk and tumor ≤ 1 cm, there is no evidence that RAI improves disease-related survival and is not recommended [5, 56, 57]. For patients with low ATA risk and tumor size between 1 and 4 cm, RAI is not routinely recommended, but it can be considered in aggressive histology and vascular invasion. Moreover, for low-risk patients, preference is given to the use of lower activities (30 mCi). For intermediate risk patients, the data on the survival benefits of RAI is controversial, and RAI is recommended for larger tumor size (> 4 cm) and age above 45 years [5]. In high-risk patients (with LN metastases, extrathyroidal spreading and distant metastases), RAI is generally indicated and in doses of 100 mCi [5].

If RAI therapy or diagnostic testing (WBS, stimulated thyroglobulin measurement) is planned, a TSH stimulation should be achieved before these procedures. TSH level may rise through two methods: thyroid hormone withdrawal or application of recombinant human TSH (rhTSH, Thyrogen). Levothyroxine (LT4) should be withdrawn for 4–6 weeks to induce transient hypothyroidism with TSH > 30 mU/l that can stimulate iodine uptake (diagnostic or therapeutic) and Tg release. Liothyronine (LT3) may be substituted for LT4 in the initial weeks, but LT3 should be withdrawn for at least 2 weeks before testing/therapy. During the withdrawal period, patients experience signs and symptoms of hypothyroidism which may

be severe and substantially impair their quality of life [58]. Cardiovascular, respiratory, CNS and psychiatric diseases worsen, as well as renal and liver function, requiring dose adjustment of concomitant medications in comorbid patients [59]. Besides, prolonged TSH stimulation may be associated with increased growth of metastatic tissue [16].

Alternatively, to overcome the inconvenience of this thyroid hormone withdrawal, rhTSH has been developed, and numerous studies have demonstrated its safety, noninferiority of remnant ablation efficacy and Tg secretion, a definite superiority regarding quality of life, especially in patients with significant comorbidities, and also benefits for patients unable to mount an endogenous TSH rise [60, 61].

4.3. Hormonal therapy

Treatment with thyroid hormone is well established and its goal is (1) to correct the post-operative/post-radiation hypothyroidism and (2) to suppress the growth of neoplastic cells by reducing TSH levels [62]. Thus, thyroid hormone treatment provides replacement and suppressive therapy at the same time.

Since thyroid cell proliferation and differentiation is TSH dependent and the presence of functional TSH receptors has been documented in most DTCs, the rationale for thyroid hormone administration is to inhibit TSH secretion. According to 2015 ATA guidelines the initial TSH suppression is considered as the following:

- High-risk DTC patients require initial TSH suppression to below 0.1 mU/L [4, 5].
- For intermediate-risk DTC patients, initial TSH suppression of 0.1–0.5 mU/L is recommended [5, 61].
- Low-risk patients who have undergone remnant ablation should maintain TSH at the lower end of the reference range (0.5–2 mU/L) if Tg is undetectable or TSH at or slightly below the lower limit of normal (0.1–0.5 mU/L) if Tg is low but detectable. For low-risk patients who have undergone lobectomy, TSH may be maintained in the mid-to-lower reference range (0.5–2 mU/L) while surveillance for recurrence is continued [5, 61].

4.4. Other therapies

In the very rare cases of RAI refractory DTC patients with metastatic, rapidly progressive and symptomatic disease, kinase inhibitors may be considered after a careful evaluation of the potential risks and benefits of such therapies [5].

5. Follow-up of patients with DTC

Most differentiated thyroid cancers are characterized by an indolent course with low morbidity and mortality. The methods used in the long-term follow up of patients with DTC are clinical examination, US (with special focus on the thyroid bed and lymph node status of the

neck), serum thyroglobulin measurement with anti-Tg-antibodies, ^{131}I WBS and in selected cases CT, MRI and positron emission tomography (^{18}F -FDG-PET).

It is recommended that Tg is always assessed together with anti-Tg antibodies. In the presence of positive anti-Tg-antibodies, the interpretation of thyroglobulin is complicated [62, 63]. Often, this necessitates a WBS that can visualize recurrence in negative Tg (false negative due to the presence of anti-Tg-antibodies). In the positive for anti-Tg-antibodies' patients (e.g., PTC on the background of Hashimoto thyroiditis), the dynamic changes in serum levels of these antibodies may serve as an indirect marker for remission (decreasing titers of antibodies) or recurrence of the disease (rising titers) [64].

^{18}F -FDG-PET is indicated in the case of high-risk patients with elevated thyroglobulin and negative radioiodine WBS [65].

Based on the clinical, laboratory and imaging results, a novel nomenclature was introduced in order to describe the status of the patient during follow-up, excellent response, biochemical incomplete response, structural incomplete response and indeterminate response to treatment [5]. Thus, the response to therapy determines the ongoing risk stratification, which further guides the long-term follow-up and the management decisions.

- **Excellent therapeutic response** or absence of persistent disease for patients who have undergone surgery and RAI ablation is defined by the presence of all following three criteria (4, 5, 63):
 1. no clinical evidence of tumor;
 2. no imaging evidence of tumor
 - a. no RAI uptake outside the thyroid bed on the post-treatment or subsequent diagnostic WBS
and/or
 - b. no US data for recurrence in thyroid bed or suspicious neck LNs
 3. Low serum Tg during TSH suppression ($\text{Tg} < 0.2 \text{ ng/mL}$) and after stimulation with thyroxin withdrawal or rhTSH ($\text{Tg} < 1 \text{ ng/mL}$) in the absence of anti-Tg antibodies.
- **Biochemical incomplete response** is characterized by abnormal thyroglobulin ($\text{Tg} > 1 \text{ ng/mL}$ during suppressive therapy and $> 10 \text{ ng/mL}$ after stimulation) in the absence of a localizable disease. If associated with stable or declining serum Tg values, a biochemical incomplete response should lead to continued observation with ongoing TSH suppression. Rising Tg or anti-Tg antibody values requires prompt additional imaging and potentially additional therapies [5, 16].
- **Structural incomplete response is determined by persistence or new identification of loco-regional or distant metastases. The management (additional treatment or ongoing observation) depends on** the size, location, rate of growth, RAI avidity, ^{18}F -FDG avidity and specific pathology of the structural lesions [5].

- **Indeterminate response** constitutes nonspecific biochemical or structural findings. This includes patients with Tg between 0.2 and 1 ng/ml during suppressive therapy and stimulated Tg between 1 and 10 ng/mL or nonspecific imaging findings as US data of sub-centimeter avascular thyroid bed nodules or atypical LNs, faint uptake in the thyroid bed on WBS [5]. If these nonspecific findings become suspicious during the follow-up or if Tg or anti-Tg antibody levels are rising, additional imaging or biopsy with cytology evaluation and wash-out Tg measurement in suspicious LNs are indicated [66].

The initial LT4 treatment is reassessed during the long-term follow-up of DTC patients and the following **long-term serum TSH levels** are recommended:

- For patients with a structural incomplete response to treatment during the follow-up, TSH level should be maintained ≤ 0.1 mU/L in the absence of contraindications [5]. The risk of therapeutically induced subclinical hyperthyroidism affects the cardiovascular system (rhythm disorders, atrial fibrillation) and the bones (osteopenia, osteoporosis) [62].
- For patients with a biochemical incomplete treatment response, the serum TSH should be maintained between 0.1 and 0.5 mU/L, taking into account the initial ATA risk, Tg level, Tg dynamics over time and the risk of TSH suppression [5, 62].
- For high-risk cancer patients who have an excellent (clinically and biochemically disease free) or indeterminate response to therapy, serum TSH may be maintained between 0.1 and 0.5 mU/L for up to 5 years after which the degree of TSH suppression can be reduced with continued surveillance for recurrence [5].
- Patients with excellent therapeutic response (clinically and biochemically disease free), patients with an initial low-risk and intermediate response and those who did not carry out remnant ablation may maintain their TSH in the lower half of the reference range (from 0.5 to 2 mU/L) [67].

6. Conclusion

The cornerstones of the preoperative diagnosis of thyroid cancer are the careful US examination, FNAB and cytology assessment of the suspicious thyroid nodules. An interdisciplinary team comprising endocrinologists, surgeons, pathologists, radiologists and oncologists should guide the patient through the diagnostic and treatment process. Strict criteria have been introduced for treatment options and follow-up on the base of initial and ongoing risk assessment in order to minimize the potential harm of over-treatment of low-risk patients and to provide adequate therapy to patients at high risk.

Conflict of interest

I declare no conflict of interest.

Author details

Mira Siderova^{1,2*}

*Address all correspondence to: mirasiderova@abv.bg

1 Medical University of Varna, Bulgaria

2 University Hospital "St. Marina" Varna, Clinic of endocrinology and metabolic diseases, Bulgaria

References

- [1] Hegedüs L. Clinical practice. The thyroid nodule. *The New England Journal of Medicine*. 2004;**351**:1764-1771. DOI: 10.1056/NEJMcp031436
- [2] David C, Speirs A. The thyroid incidentaloma – Ignore or investigate? *Journal of Ultrasound in Medicine*. 2007;**26**:1367-1371. DOI: 10.7863/jum.2007.26.10.1367
- [3] Guth S, Theune U, Aberle J, Galach A, Bamberger CM. Very high prevalence of thyroid nodules detected by high frequency (13 MHz) ultrasound examination. *European Journal of Clinical Investigation*. 2009;**39**:699-706. DOI: 10.1111/j.1365-2362.2009.02162.x
- [4] Pacini F, Schlumberger M, Dralle H and European Thyroid Cancer Task force. European consensus for the management of patients with differentiated thyroid carcinoma of the follicular epithelium. *European Journal of Endocrinology*. 2006;**154**:787-803. DOI: 10.1530/eje.1.02158
- [5] Haugen BR, Alexander EK, Bible KC, Doherty GM, Mandel SJ, Nikiforov YE, et al. 2015 American Thyroid Association management guidelines for adult patients with thyroid nodules and differentiated thyroid cancer. *Thyroid*. 2016;**26**(1):1-133. DOI: 10.1089/thy.2015.0020
- [6] Aschebrook-Kilfoy B, Schechter RB, Shih YC, Kaplan EL, Chiu BC, Angelos P, et al. The clinical and economic burden of a sustained increase in thyroid cancer incidence. *Cancer Epidemiology, Biomarkers & Prevention*. 2013;**22**:1252-1259. DOI: 10.1158/1055-9965.EPI-13-0242
- [7] Davies L, Welch HG. Current thyroid cancer trends in the United States. *JAMA Otolaryngology, Head & Neck Surgery*. 2014;**140**:317-322. DOI: 10.1001/jamaoto.2014.1
- [8] Davis L, Welch HG. Increasing incidence of thyroid cancer in the United States. *JAMA*. 2006;**295**(18):2164-2167. DOI: 10.1001/jama.295.18.2164
- [9] Lim H, Devesa SS, Sosa JA, Check D, Kitahara CM. Trends in thyroid cancer incidence and mortality in the United States, 1974-2013. *Journal of the American Medical Association*. 2017 Apr 4;**317**(13):1338-1348. DOI: 10.1001/jama.2017.2719

- [10] Cardis E, Krewski D, Boniol M, Drozdovitch V, Darby S, Gilbert E, et al. Estimates of the cancer burden in Europe from radioactive fallout from the Chernobyl accident. *International Journal of Cancer*. 2006;**119**:1224-1235. DOI: 10.1002/ijc.22037
- [11] Campanella P, Ianni F, Rota CA, Corsello SM, Pontecorvi A. Quantification of cancer risk of each clinical and ultrasonographic suspicious feature of thyroid nodules: A systematic review and meta-analysis. *European Journal of Endocrinology*. 2014;**170**:R203-R211. DOI: 10.1016/S0140-6736(03)12488-9
- [12] Gharib H, Papini E, Paschke R, Duick DS, Valcavi R, Hegedüs L, Vitti P. AACE/AME/ETA medical guidelines for clinical practice for the diagnosis and management of thyroid nodules. *Endocrine Practice*. 2010;**16**(Suppl 1):1-42. DOI: 10.4158/10024.GL
- [13] Boelaert K, Horacek J, Holder RL, Watkinson JC, Sheppard MC, Franklyn JA. Serum thyrotropin concentration as a novel predictor of malignancy in thyroid nodules investigated by fine-needle aspiration. *Journal of Clinical Endocrinology and Metabolism*. 2006;**91**:4295-4301. DOI: 10.1210/jc.2006-0527
- [14] Biondi B, Filetti S, Schlumberger M. Thyroid hormone therapy and thyroid cancer: A reassessment. *Nature Clinical Practice. Endocrinology & Metabolism*. 2005;**1**:32-40. DOI: 10.1038/ncpendmet0020
- [15] Paschke R, Hegedüs L, Alexander E, Valcavi R, Papini E, Gharib H. Thyroid nodule guidelines: Agreement, disagreement and need for future research. *Nature Reviews Endocrinology*. 2011;**7**:354-361
- [16] Schlumberger M, Pacini F, Tuttle RM. *Thyroid tumors*. 4th ed. ESTIMPRIM; 2016. ISBN 978-2-7466-7881-1
- [17] Sipos JA. Advances in ultrasound for the diagnosis and management of thyroid cancer. *Thyroid*. 2009;**19**(12):1363-1372. DOI: 10.1089/thy.2009.1608
- [18] Moon WJ, Baek JH, Jung SL, Kim DW, Kim EK, Kim JY, et al. Korean Society of Thyroid Radiology (KSThR); Korean Society of Radiology. Ultrasonography and the ultrasound-based management of thyroid nodules: Consensus statement and recommendations. *Korean Journal of Radiology*. 2011;**12**:1-14. DOI: 10.3348/kjr.2011.12.1.1
- [19] Gürsoy A, Erdoğan MF. Ultrasonographic approach to thyroid nodules: State of art. *Thyroid International*. 2012;**3**:1-15
- [20] Iared W, Shigueoka DC, Cristofoli JC, Andriolo R, Atallah AN, Ajzen SA, et al. Use of color Doppler ultrasonography for the prediction of malignancy in follicular thyroid neoplasms: Systematic review and meta-analysis. *Journal of Ultrasound in Medicine*. 2010;**29**:419-425
- [21] Sprindzuk M. Angiogenesis in malignant thyroid Tumors. *World Journal of Oncology*. 2010;**1**(6):221-231. DOI: 10.4021/wjon263e
- [22] Bonavita JA, Mayo J, Babb J, Bennett G, Oweity T, Macari M, et al. Pattern recognition of benign nodules at ultrasound of the thyroid: Which nodules can be left alone? *American Journal of Roentgenology*. 2009;**193**:207-213. DOI: 10.2214/AJR.08.1820

- [23] Kim EK, Park CS, Chung WY, Oh KK, Kim DI, Lee JT, et al. New sonographic criteria for recommending fine-needle aspiration biopsy of nonpalpable solid nodules of the thyroid. *AJR. American Journal of Roentgenology*. 2002;**178**:687-691. DOI: 10.2214/ajr.178.3.1780687
- [24] Peccin S, de Castro JA, Furlanetto TW, Furtado AP, Brasil BA, Czepielewski MA. Ultrasonography: Is it useful in the diagnosis of cancer in thyroid nodules? *Journal of Endocrinological Investigation*. 2002;**25**:39-43
- [25] Papini E, Guglielmi R, Bianchini A, Crescenzi A, Taccogna S, Nardi F, et al. Risk of malignancy in nonpalpable thyroid nodules: Predictive value of ultrasound and color-Doppler features. *The Journal of Clinical Endocrinology and Metabolism*. 2002;**87**:1941-1946. DOI: 10.1210/jcem.87.5.8504
- [26] Cappelli C, Castellano M, Pirola I, Cumetti D, Agosti E, Gandossi E, et al. The predictive value of ultrasound findings in the management of thyroid nodules. *The Quarterly Journal of Medicine*. 2007;**100**:29-35. DOI: 10.1093/qjmed/hcl121
- [27] Moon WJ, Jung SL, Lee JH, Na DG, Baek JH, Lee YH, et al. Benign and malignant thyroid nodules: US differentiation— Multicenter retrospective study. *Radiology*. 2008;**247**:762-770. DOI: 10.1148/radiol.2473070944
- [28] Brito JP, Gionfriddo MR, Al Nofal A, Boehmer KR, Leppin AL, Reading C, et al. The accuracy of thyroid nodule ultrasound to predict thyroid cancer: Systematic review and meta-analysis. *The Journal of Clinical Endocrinology and Metabolism*. 2014;**99**:1253-1263. DOI: 10.1210/jc.2013-2928
- [29] Remonti LR, Kramer CK, Leitiro CB, Pinto LC, Gross JL. Thyroid ultrasound features and risk of carcinoma: A systematic review and meta-analysis of observational studies. *Thyroid*. 2015;**25**:538-550. DOI: 10.1089/thy.2014.0353
- [30] Siderova M, Hristozov K, Krasnaliev I, Softova E. Correlation between sonographic features predictive of malignancy and fine needle aspiration biopsy cytology results of thyroid nodules. *Endocrinologia*. 2013;**18**(2):60-70
- [31] Russ G, Bonnema SJ, Erdogan MF, Durante C, Ngu R, Leenhardt L. European thyroid association guidelines for ultrasound malignancy risk stratification of thyroid nodules in adults: The EU-TIRADS. *European Thyroid Journal*. 2017;**6**:225-237. DOI: 10.1159/000478927
- [32] Yoon JH, Lee HS, Kim EK, Moon HJ, Kwak JY. Malignancy risk stratification of thyroid nodules: Comparison between the thyroid imaging reporting and data system and the 2014 American Thyroid Association management guidelines. *Radiology*. 2016;**278**:917-924. DOI: 10.1148/radiol.2015150056
- [33] Kwak JY, Han KH, Yoon JH, Moon HJ, Son EJ, Park SH, et al. Thyroid imaging reporting and data system for US features of nodules: A step in establishing better stratification of cancer risk. *Radiology*. 2011;**260**:892-899. DOI: 10.1148/radiol.11110206
- [34] Russ G, Bigorgne C, Royer B, Rouxel A, Bienvenu-Perrard M. The thyroid imaging reporting and data system (TIRADS) for ultrasound of the thyroid. *Journal de Radiologie*. 2011;**92**:701-713. DOI: 10.1016/j.jradio.2011.03.022

- [35] Russ G, Leboulleux S, Leenhardt L, Hegedüs L. Thyroid incidentalomas: Epidemiology, risk stratification with ultrasound and workup. *European Thyroid Journal*. 2014 Sep;**3**(3): 154-163. DOI: 10.1159/000365289
- [36] Morris LG, Sikora AG, Tosteson TD, Davies L. The increasing incidence of thyroid cancer: The influence of access to care. *Thyroid*. 2013;**23**:885-891. DOI: 10.1089/thy.2013.0045
- [37] Shetty SK, Maher MM, Hahn PF, Halpern EF, Aquino SL. Significance of incidental thyroid lesions detected on CT: Correlation among CT, sonography, and pathology. *American Journal of Roentgenology*. 2006;**187**:1349-1356. DOI: 10.2214/AJR.05.0468
- [38] Soelberg KK, Bonnema SJ, Brix TH, Hegedus L. Risk of malignancy in thyroid incidentalomas detected by 18F-fluorodeoxyglucose positron emission tomography: A systematic review. *Thyroid*. 2012;**22**:918-925. DOI: 10.1089/thy.2012.0005
- [39] Rago T, Santini F, Scutari M, Pinchera A, Vitti P. Elastography: New developments in ultrasound for predicting malignancy in thyroid nodules. *The Journal of Clinical Endocrinology and Metabolism*. 2007;**92**(8):2917-2922. DOI: 10.1210/jc.2007-0641
- [40] Kwak JY, Kim EK. Ultrasound elastography for thyroid nodules: Recent advances. *Ultrasonography*. 2014;**33**(2):75-82. DOI: 10.14366/usg.13025
- [41] Magri F, Chytiris S, Capelli V, Gaiti M, Zerbini F, Carrara R, Malovini A, Rotondi M, Bellazzi R, Chiovato L. Comparison of elastographic strain index and thyroid fine-needle aspiration cytology in 631 thyroid nodules. *Journal of Clinical Endocrinology and Metabolism*. 2013;**98**(12):4790-4797. DOI: 10.1210/jc.2013-2672
- [42] Wang H, Brylka D, Sun LN, Lin YQ, Sui GQ, Gao J. Comparison of strain ratio with elastography score system in differentiating malignant from benign thyroid nodules. *Clinical Imaging*. 2013;**37**(1):50-55. DOI: 10.1016/j.clinimag.2012.04.003
- [43] Kim MJ, Kim EK, Park SI, Kim BM, Kwak JY, Kim SJ, et al. US-guided fine needle aspiration of thyroid nodules: Indications, techniques, results. *Radio Graphics*. 2008;**28**(7):1869-1886. DOI: 10.1148/rg.287085033
- [44] Cibas E, Ali SZ. The Bethesda system for reporting thyroid cytopathology. *American Journal of Clinical Pathology*. 2009;**132**:658-665. DOI: 10.1309/AJCPPHLWMI3JV4LA
- [45] Kini SR. Specimen adequacy and assessment, reporting system. In: *Thyroid Cytopathology: An Atlas and Text*. Philadelphia, PA: Lippincott Williams & Wilkins; 2008. pp. 17-26
- [46] Yassa L, Cibas ES, Benson CB, Frates MC, Doubilet PM, Gawande AA, et al. Long-term assessment of a multidisciplinary approach to thyroid nodule diagnostic evaluation. *Cancer*. 2007;**111**:508-516. DOI: 10.1002/cncr.23116
- [47] Baloch ZW, Livolsi VA. Follicular-patterned lesions of the thyroid: The bane of the pathologist. *American Journal of Clinical Pathology*. 2002;**117**:143-150. DOI: 10.1309/8VL9-ECXY-NVMX-2RQF
- [48] Torres MR, Nóbrega Neto SH, Rosas RJ, Martins AL, Ramos AL, da Cruz TR. Thyroglobulin in the washout fluid of lymph-node biopsy: What is its role in the follow-up of differentiated thyroid carcinoma? *Thyroid*. 2014 Jan;**24**(1):7-18. DOI: 10.1089/thy.2013.0244

- [49] Nikiforov YE, Ohori NP, Hodak SP, Carty SE, Le Beau SO, Ferris RL, et al. Impact of mutational testing on the diagnosis and management of patients with cytologically indeterminate thyroid nodules: A prospective analysis of 1056 FNA samples. *Journal of Clinical Endocrinology and Metabolism*. 2011;**96**:3390-3397. DOI: 10.1210/jc.2011-1469
- [50] Alexander EK, Kennedy GC, Baloch ZW, Cibas ES, Chudova D, Diggans J, et al. Preoperative diagnosis of benign thyroid nodules with indeterminate cytology. *The New England Journal of Medicine*. 2012;**367**:705-715. DOI: 10.1056/NEJMoa1203208
- [51] Bartolazzi A, Orlandi F, Saggiorato E, Volante M, Arecco F, Rossetto R, et al. Galectin-3-expression analysis in the surgical selection of follicular thyroid nodules with indeterminate fine-needle aspiration cytology: A prospective multicentre study. *The Lancet Oncology*. 2008;**9**:543-549. DOI: 10.1016/S1470-2045(08)70132-3
- [52] Hay ID, Thompson GB, Grant CS, Bergstralh EJ, Dvorak CE, Gorman CA, et al. Papillary thyroid carcinoma managed at the Mayo Clinic during six decades (1940-1999): Temporal trends in initial therapy and long-term outcome in 2444 consecutively treated patients. *World Journal of Surgery*. 2002;**26**:879-885. DOI: 10.1007/s00268-002-6612-1
- [53] Edge SB, Byrd DR, Compton CC, Fritz AG, Greene FL, Trotti A. Thyroid cancer staging. In: Edge SB, Byrd DR, Compton CC, Fritz AG, Greene FL, Trotti A, editors. *AJCC Cancer Staging Manual*. 7th ed. New York: Springer-Verlag; 2010. pp. 59-64. ISBN 978-0-387-88442-4
- [54] Adam MA, Pura J, Goffredo P, Dinan MA, Reed SD, Scheri RP, et al. Presence and number of lymph node metastases are associated with compromised survival for patients younger than age 45 years with papillary thyroid cancer. *Journal of Clinical Oncology*. 2015;**33**:2370-2375. DOI: 10.1200/JCO.2014.59.8391
- [55] Zaydfudim V, Feurer ID, Griffin MR, Phay JE. The impact of lymph node involvement on survival in patients with papillary and follicular thyroid carcinoma. *Surgery*. 2008;**144**:1070-1077. DOI: 10.1016/j.surg.2008.08.034
- [56] Jonklaas J, Cooper DS, Ain KB, Bigos T, Brierley JD, Hauge, et al. Radioiodine therapy in patients with stage I differentiated thyroid cancer. *Thyroid*. 2010;**20**:1423-1424. DOI: 10.1089/thy.2010.0308
- [57] Sawka AM, Brierley JD, Tsang RW, Thabane L, Rotstein L, Gafni A, et al. An updated systematic review and commentary examining the effectiveness of radioactive iodine remnant ablation in well-differentiated thyroid cancer. *Endocrinology and Metabolism Clinics of North America*. 2008;**37**:457-480. DOI: 10.1016/j.ecl.2008.02.007
- [58] Dow KH, Ferrell BR, Anello C. Quality-of-life changes in patients with thyroid cancer after withdrawal of thyroid hormone therapy. *Thyroid*. 1997;**7**:613-619. DOI: 10.1089/thy.1997.7.613
- [59] Kreisman SH, Hennessey JV. Consistent reversible elevations of serum creatinine levels in severe hypothyroidism. *Archives of Internal Medicine*. 1999;**159**:79-82

- [60] Dueren C, Dietlein M, Luster M, Plenzig F, Steinke R, Grimm J, et al. The use of thyrogen in the treatment of differentiated thyroid carcinoma: An intraindividual comparison of clinical effects and implications of daily life. *Experimental and Clinical Endocrinology & Diabetes*. 2010;**118**:513-519. DOI: 10.1055/s-0029-1234086
- [61] Robbins RJ, Driedger A, Magner J. Recombinant human thyrotropin-assisted radioiodine therapy for patients with metastatic thyroid cancer who could not elevate endogenous thyrotropin or be withdrawn from thyroxine. *Thyroid*. 2006;**16**:1121-1130. DOI: 10.1089/thy.2006.16.1121
- [62] Biondi B, Cooper DS. Benefits of thyrotropin suppression versus the risks of adverse effects in differentiated thyroid cancer. *Thyroid*. 2010;**20**:135-146. DOI: 10.1089/thy.2009.0311
- [63] Bachelot A, Cailleux AF, Klain M, Baudin E, Ricard M, Bellon N, et al. Relationship between tumor burden and serum thyroglobulin level in patients with papillary and follicular thyroid carcinoma. *Thyroid*. 2002;**12**:707-711. DOI: 10.1089/105072502760258686
- [64] Spencer C, Fatemi S. Thyroglobulin antibody (TgAb) methods - strengths, pitfalls and clinical utility for monitoring TgAb-positive patients with differentiated thyroid cancer. *Best Practice & Research Clinical Endocrinology & Metabolism*. 2013;**27**:701-712. DOI: 10.1016/j.beem.2013.07.003
- [65] Leboulleux S, Schroeder PR, Schlumberger M, Ladenson PW. The role of PET in follow-up of patients treated for differentiated epithelial thyroid cancers. *Nature Clinical Practice. Endocrinology & Metabolism*. 2007;**3**:112-121. DOI: 10.1038/ncpendmet0402
- [66] Grani G, Fumarola A. Thyroglobulin in lymph node fine-needle aspiration washout: A systematic review and meta-analysis of diagnostic accuracy. *The Journal of Clinical Endocrinology and Metabolism*. 2014 Jun;**99**(6):1970-1982. DOI: 10.1210/jc.2014-1098
- [67] Sugitani I, Fujimoto Y. Does postoperative thyrotropin suppression therapy truly decrease recurrence in papillary thyroid carcinoma? A randomized controlled trial. *The Journal of Clinical Endocrinology and Metabolism*. 2010;**95**:4576-4583. DOI: 10.1210/jc.2010-0161

